

# We are IntechOpen, the world's leading publisher of Open Access books Built by scientists, for scientists

6,900

Open access books available

186,000

International authors and editors

200M

Downloads

Our authors are among the

154

Countries delivered to

TOP 1%

most cited scientists

12.2%

Contributors from top 500 universities



WEB OF SCIENCE™

Selection of our books indexed in the Book Citation Index  
in Web of Science™ Core Collection (BKCI)

Interested in publishing with us?  
Contact [book.department@intechopen.com](mailto:book.department@intechopen.com)

Numbers displayed above are based on latest data collected.  
For more information visit [www.intechopen.com](http://www.intechopen.com)



# Persistent Ectopic Pregnancy After Laparoscopic Linear Salpingostomy for Tubal Pregnancy: Prevention and Early Detection

Shigeo Akira, Takashi Abe and Toshiyuki Takeshita

*Department of Obstetrics and Gynecology, Nippon Medical School, Tokyo, Japan*

## 1. Introduction

Persistent ectopic pregnancy (PEP) is a condition that occurs due to incomplete removal of trophoblastic tissue during fallopian tube-preservation surgery for tubal pregnancy. According to several studies, the incidence has been reported to be approximately 3%-20%,<sup>1</sup> and the incidence appears to be rising due to the increase in treatment of tubal pregnancies via laparoscopic surgery.<sup>2-4</sup> If treatment for PEP is delayed, tubal rupture and intra-abdominal hemorrhage can occur and may be accompanied by significant morbidity and mortality. Therefore, prevention and early detection of PEP is of great importance.

Methotrexate (MTX), a cytostatic agent with proven anti-trophoblastic activity, has been used for the treatment of ectopic pregnancies, and has also been reported to be useful for treating PEPs.<sup>5-6</sup> Therefore, combined use of MTX following conservative tubal surgery may facilitate prevention of PEP.

Indeed, MTX has thus far been reported to significantly decrease the occurrence of PEP when systemically-administered in a single dose within 24 hours after laparoscopic linear salpingostomy.<sup>7</sup> However, systemic MTX administration has been reported to cause side effects and must be used with caution.<sup>8,9</sup> In contrast, local MTX administration into the tube, either laparoscopically<sup>10,11</sup> or through transvaginal ultrasonography<sup>12,13</sup>, has been associated with few side effects, and may be useful as a prophylactic for PEP. Therefore, local MTX administration after linear salpingostomy could prevent PEP without serious side effects.

In this chapter, we examined the efficacy of local MTX administration after linear salpingostomy for tubal pregnancies in preventing PEP, and evaluated the usefulness of postoperative serum human chorionic gonadotropin (hCG) decline (percentage of the preoperative hCG level) for early detection and ruling out of PEP.

## 2. Subjects and methods

### 2.1 Patients selection

Patients who underwent linear salpingostomies between January 1996 and December 2010 were enrolled in the study. A linear salpingostomy was indicated according to the following criteria: 1) stable circulatory dynamics; 2) desired future pregnancy; 3) no tubal rupture; 4) absence of marked tubal adhesions; 5) ectopic pregnancy diameter  $\leq 5$  cm; 6) absence of a

fetal heart beat; and 7) absence of a recurrent ectopic pregnancy in the ipsilateral fallopian tube. For patient selection, we did not limit the gestational age or pre-operative serum hCG level.

## 2.2 Surgical procedure

Following confirmation of indication criteria for laparoscopy, 5 IU of vasopressin was injected into the mesosalpinx. After making a linear incision on the distended portion of the fallopian tube with electrocautery, the products of conception were removed *en bloc* using forceps or by hydrodissection. Trophoblasts were macroscopically confirmed in water and sent for pathologic evaluation. The diagnosis of ectopic pregnancy was pathologically confirmed in all cases. Surgery was performed using an identical technique by several physicians under the guidance of a supervising physician.

## 2.3 Serum hCG measurement

Preoperative serum hCG levels were obtained  $\leq 24$  hours before surgery. Serum hCG levels during the first postoperative week were measured at 2-3 day intervals. The intervals between hCG measurements were determined by the attending physician based on clinical symptoms. Serum hCG levels were followed postoperatively until serum hCG levels  $< 5$  IU/ml or until the diagnosis of PEP.

Serum hCG levels were determined by an electrochemiluminescence immunoassay (ECLIA), which is based on a sandwich antibody principle (Elecsys 2010 Systems; Roche Tokyo, Japan). The inter-assay coefficient of variation was 5.8; the intra-assay coefficient of variation was 4.5.

## 2.4 Prevention of PEP

Patients were divided into two groups (prophylaxis and control groups). In the prophylaxis group, MTX (50 mg) was serially administered into the tubal wall near the lesion immediately after linear salpingostomy. Patients who underwent surgery without MTX administration were assigned to the control group. All patients gave informed consent to the procedures, and this study was approved by the Nippon Medical School Hospital Ethics Committee.

PEP was defined as an increase in the serum hCG level or a decline of  $< 20\%$  between measurements taken 3 days apart.<sup>14</sup>

The incidence of PEP between groups was analyzed using Fischer's exact test. In addition, statistical analysis for both groups used the Student's t-test or the Mann-Whitney test, as appropriate (STATMATE for Windows). Significance was defined as a  $P < 0.05$ .

## 2.5 Early detection of PEP

The 53 patients without prophylactic MTX injection were divided into two groups, as follows: patients with an increase in the serum hCG level or a decline in the serum hCG level  $< 20\%$  between measurements taken 3 days apart (PEP group); and successfully-treated patients with a marked decrease in hCG (control group). The clinical and laboratory characteristics of both groups were compared with respect to maternal age, parity, gestational age at enrollment, specimen diameter, and pre-operative serum hCG levels.

The postoperative course was divided into 4 periods, as follows: period A, days 1-2; period B, days 3-4; period C, days 5-6; and period D, days 7-8. The serum hCG declines during each period in the PEP and control groups were compared.

A cut-off value for serum hCG to rule out a PEP was established using receiver operating characteristic (ROC) curve analysis. The two groups were compared using the Student's t-test, and when appropriate, Fisher's exact test was used. Significance was defined as a  $P < 0.05$ .

3. Results

3.1 Prevention of PEP

One hundred two patients were enrolled in the present study. The prophylaxis and control groups consisted of 55 and 47 patients, respectively, with no intergroup differences in age, gestational age, or preoperative hCG levels. PEP were not noted in the prophylaxis group, but occurred in 8 patients (17.0%) in the control group ( $p < 0.05$ ; Table 1). The 8 patients in the control group who developed PEP received a single systemic administration of MTX (50 mg/m<sup>2</sup>) between postoperative days 7 and 10, the period during which the diagnosis was made. One patient had a poor decline in serum hCG and required an additional administration of MTX (50 mg/m<sup>2</sup>) 7 days later. In addition, another patient developed lower abdominal pain and a hemoperitoneum 4 days after MTX administration, and underwent laparoscopic salpingectomy. The remaining six patients had a steady decline in serum hCG levels. Patients in both groups who did not develop PEP reached undetectable serum hCG levels, and thus completed the recommended follow-up by post-operative day 28. In contrast, patients who developed PEP required a mean follow-up of 51.7±17.2 days ( $p < 0.05$ ; Table 2). No side effects attributable to MTX, such as dermatitis, alopecia, dyspepsia, and hepatic or bone marrow toxicity, were observed in the prophylaxis group.

3.2 Early detection of PEP

In 42 of the 53 patients, no postoperative symptoms of PEP were noted, and the serum hCG levels dropped to pre-pregnancy levels; the PEP was located in 11 patients. Table 3 presents the clinical characteristics of both groups. No statistically significant differences existed between the PEP and control groups with respect to age, parity, gravidity, gestational age, specimen diameter, or preoperative serum hCG levels.

	Prophylaxis Group (n = 55)	Control Group (n = 47)
Age (yr)	30.2 +/- 4.3	29.7 +/- 5.1
Gestational age (wk)	7.2 +/- 1.3	7.0 +/- 1.5
Preoperative hCG (mIU/ml)	3257 +/- 3380 (250 to 13012)	3118 +/- 3051 (198 to 12756)
Persistent ectopic pregnancy	0	8 *

Data are presented as mean +/- standard deviation with ranges in parentheses.

\* $P < 0.05$  compared with the prophylaxis group

Table 1. Patient characteristics and frequency of persistent ectopic pregnancy.

	Prophylaxis Group (n = 55)	Control Group (n = 39)	PEP Group (n = 8)
Length of follow up (days)	20.3 +/- 5.7	21.6 +/- 6.4	51.7 +/- 17.2*

Data are presented as mean +/- standard deviation.

\*P < 0.05 compared with the prophylaxis group and control group without persistent ectopic pregnancy (PEP).

Table 2. Duration of follow up.

	Total n = 53	Control n = 42	PEP n = 11	p value
Maternal age (y)	29.6 +/- 5.4	30.0 +/- 5.1	28.0 +/- 6.3	0.367
Parity	0.18 +/- 0.44	0.16 +/- 0.37	0.27 +/- 0.64	0.813
Gravidity	0.62 +/- 0.83	0.52 +/- 0.67	1.00 +/- 1.26	0.281
Gestational age at enrollment (w)	6.96 +/- 1.40	6.95 +/- 1.43	7.00 +/- 1.34	0.964
Diameter of tumor (cm)	2.90 +/- 1.55	3.08 +/- 1.61	2.30 +/- 1.30	0.339
hCG at diagnosis (IU/L)	3078.9 +/- 2915.1	3046.9 +/- 3208.9	3201.2 +/- 1396.4	0.160

Data are presented as mean +/- standard deviation or number (%).

Table 3. Clinical characteristics of subjects in the study of postoperative declines in serum human chorionic gonadotropin (hCG) levels and persistent ectopic pregnancy (PEP).

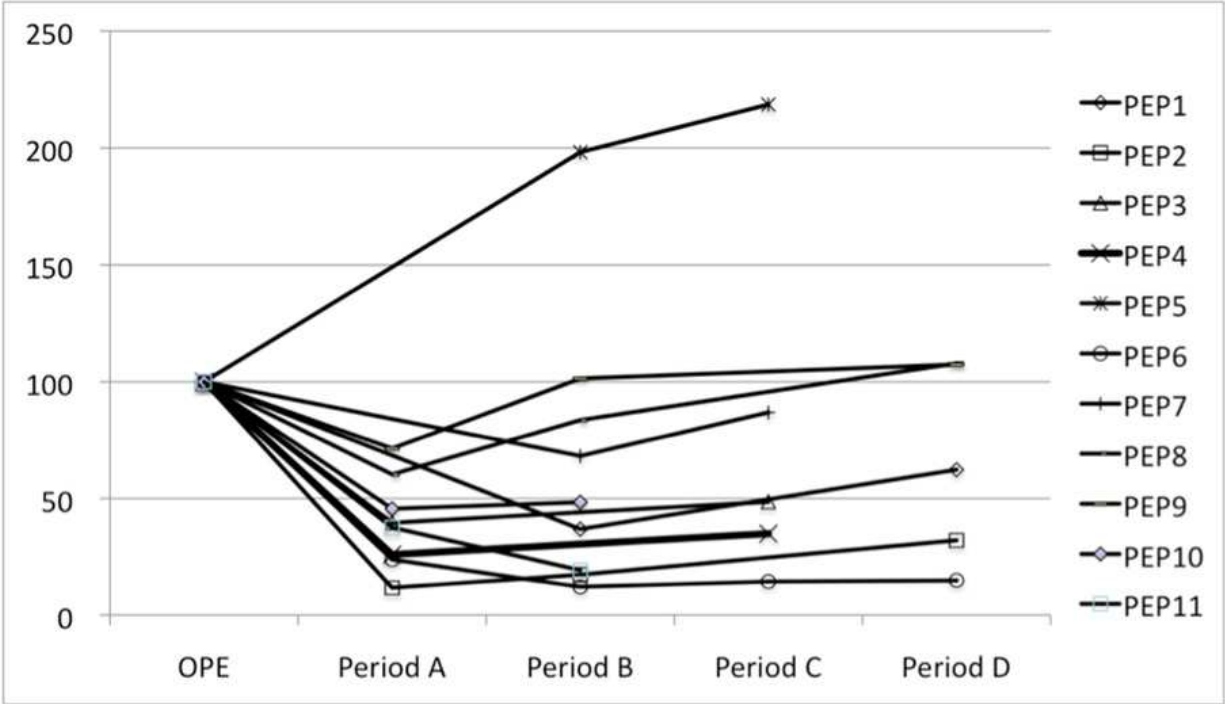


Fig. 1. Postoperative declines in serum human chorionic gonadotropin (hCG) levels (percentages of preoperative hCG levels) during the first week after laparoscopic salpingotomy in the persistent ectopic pregnancy patients.

Figure 1 shows the postoperative hCG declines in the PEP group. In one patient, the post-operative serum hCG levels steadily increased post-operatively, and in the other nine patients, the levels of serum hCG decreased transiently, then increased. After period C, the hCG levels of all patients in the PEP group increased and did not decrease until the second intervention. In these patients, systemic administration of one additional dose of MTX (50 mg/m<sup>2</sup>) was given.

Figure 2 compares the variance in the hCG decline for each study period between the control and PEP groups. After period B, the hCG decline was significantly less in the PEP group than the control group.

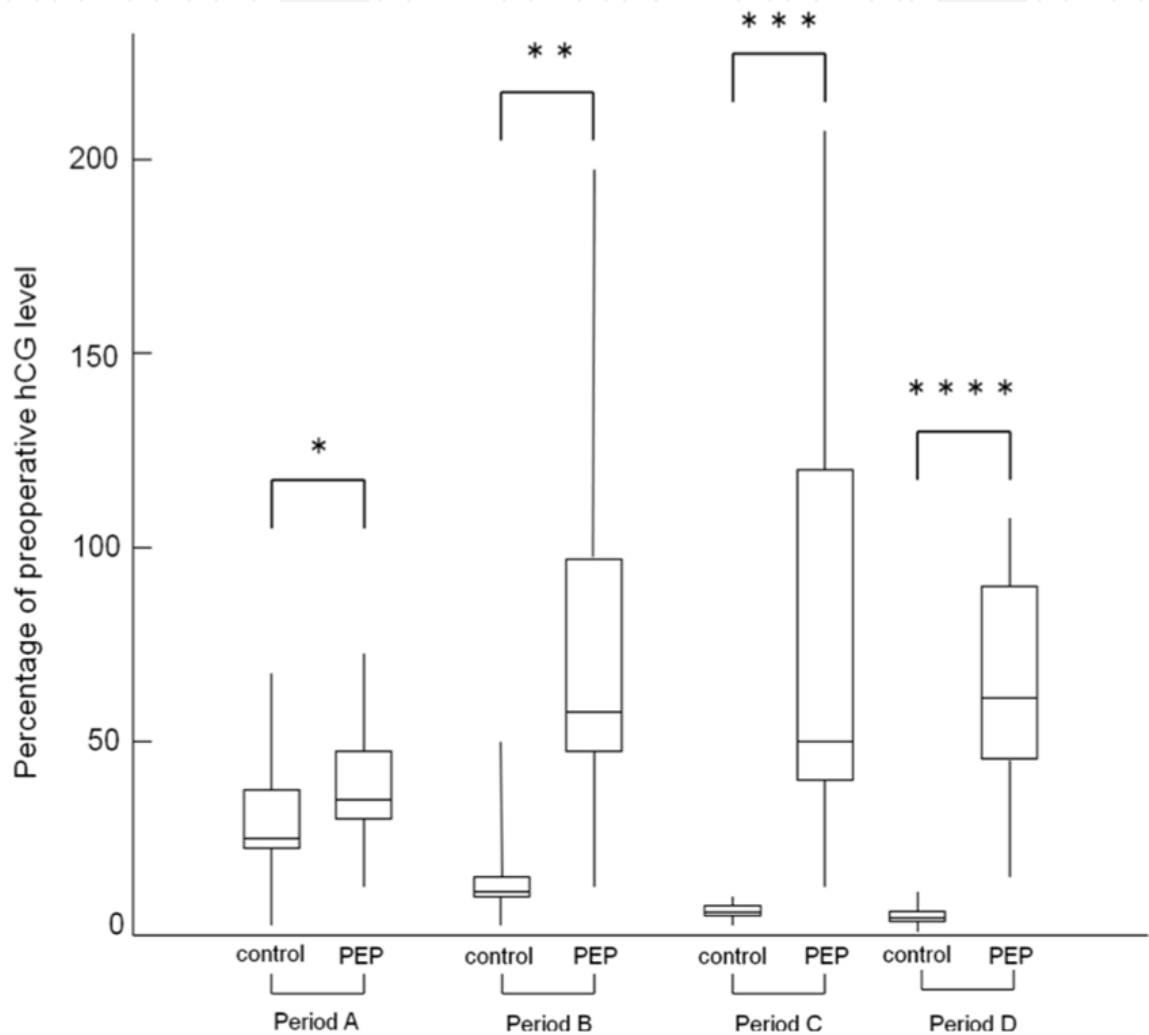


Fig. 2. Comparison of the variance in the serum human chorionic gonadotropin (hCG) decline for each period between the control and persistent ectopic pregnancy (PEP) groups. Data are presented as median value and interquartile ranges (IQR) in each period.

Figure 3 presents the 95% confidence interval (CI) of the hCG decline for 1 week after surgery in the control group, and the postoperative hCG decline in the PEP group. In the PEP group, the hCG decline after period C was outside the 95% CI of the control group. Analysis by ROC, sensitivity and specificity were calculated with optimal points in each period, and 14% of preoperative hCG valued in period C and D revealed that the specificity and sensitivity of the test were equal to 100% (Figure 4).

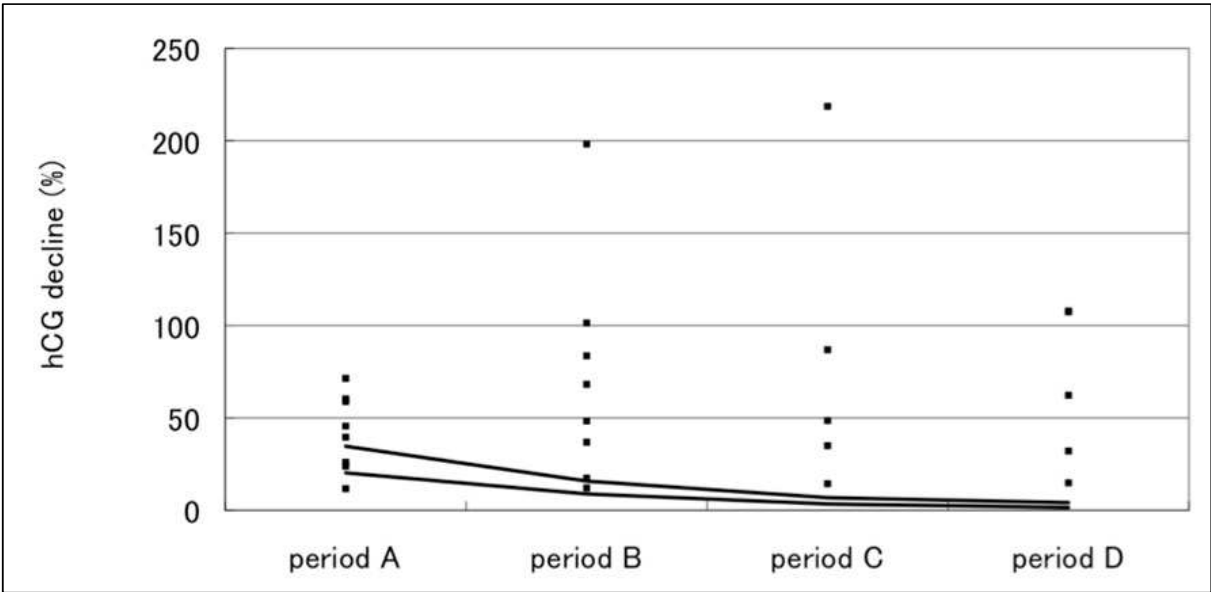


Fig. 3. Postoperative declines in serum human chorionic gonadotropin (hCG) levels during the first week after laparoscopic salpingotomy in the successfully treated patients (control group, black line [95% confidence interval]) an PEP patients (Black boxes [individual hCG declines]). Between the black lines is presented 95% confidential interval of the control group. Black boxes present individual preoperative hCG values.

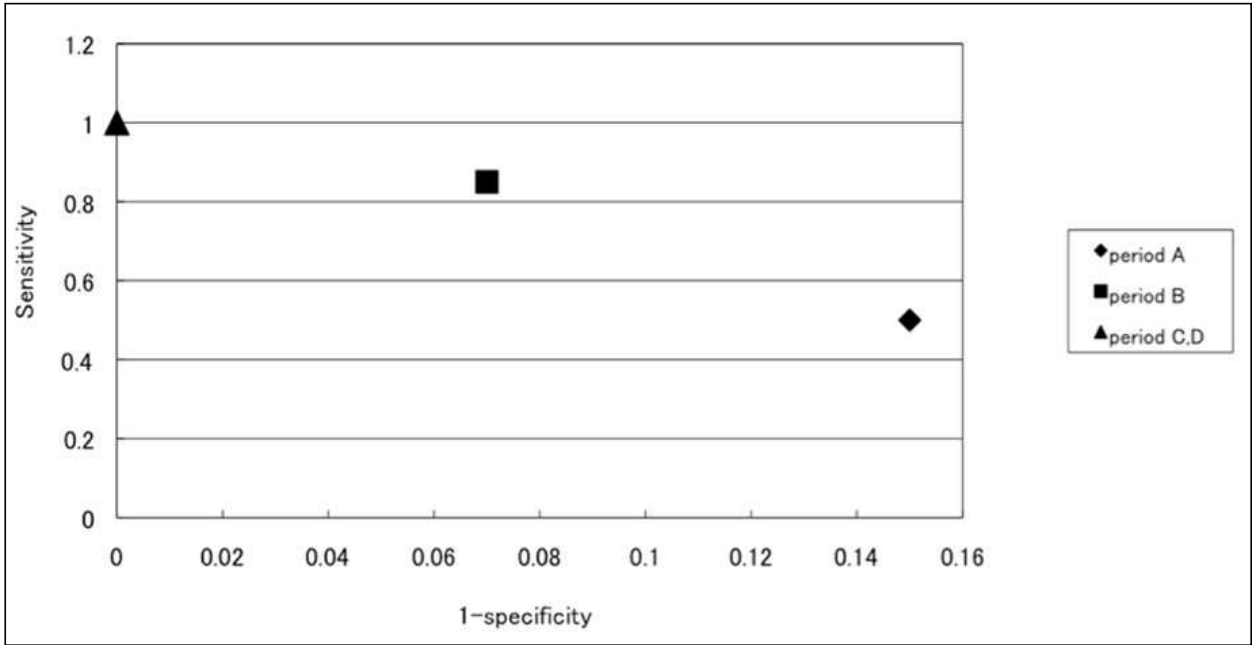


Fig. 4. Analysis by receiver operating characteristic curve correlating sensitivity of the test with the false-positive rate (1-specificity) for each postoperative period for the first week following laparoscopic salpingotomy. Sensitivity and specificity were calculated with optimal points in each period, and the excellent sensitivity and false positive rate (1-specificity) were plotted on this figure. A 14% of preoperative serum human chorionic gonadotropin (hCG) value in period C and D revealed that the specificity and sensitivity of the test were equal to 100%.



#### 4. Discussion

As indicated by the results of the present study, prophylactic local administration of MTX into the tubal wall immediately after linear salpingostomy is extremely effective in preventing post-operative PEP. In addition, even when systemic MTX administration was effective, patients who developed PEP required a significantly longer follow-up of hCG level than patients without PEP.

MTX has been shown to have no adverse effects on future pregnancies as long as pregnancy is avoided for a certain period of time,<sup>15</sup> and may thus be proactively used as prophylaxis following salpingostomy. Graczykowski et al.<sup>7</sup> reported that the incidence of PEP was reduced to 1.9% following a single systemic administration of prophylactic MTX (1 mg/kg) within 24 hours after salpingostomy. However, although generally mild, side effects related to systemic MTX administration have been reported in up to 24% of cases,<sup>8</sup> including some cases of serious side effects.<sup>9</sup> Therefore, the implementation of prophylactic systemic administration of MTX for all patients remains controversial. Importantly, local intratubal administration of MTX has been reported to enhance local anti-trophoblastic activity,<sup>16</sup> in addition to reducing side effects,<sup>17,18</sup> and may thus be a more effective and safer regimen for preventing PEP. This assumption is supported by the fact that no cases of PEP or side effects were observed in the MTX group in the present study, while PEP was observed in 1.9% of cases in a study involving single systemic administration of MTX.<sup>8</sup>

Regarding the toxicity to the tube of local administration of MTX (50 mg), no effects were reported in a histologic study of intratubal injection of MTX (100 mg).<sup>19</sup> Furthermore, subsequent fertility after local MTX injection was satisfactory.<sup>13,20</sup> Therefore, local administration of MTX (50 mg) was thought to have no toxicity in the tube.

Administration of prophylactic MTX to all patients remains a controversial issue. Prophylactic administration of MTX may be appropriate for patients at increased risk for developing PEP, such as patients with a short duration of amenorrhea, a small ectopic pregnancy (< 2 cm in size), and a preoperative hCG level  $\geq 2500$  IU/ml.<sup>21</sup> Considering that no side effects were reported after local MTX administration in the present study, and in light of the risk of salpingectomy and the need for long follow-up in cases of PEP, it may be appropriate to consider prophylactic local administration for all patients.

This study also showed that age, parity, gravity, gestational age, specimen diameter, and preoperative serum hCG levels are not predictive of a PEP following a laparoscopic salpingostomy. Several attempts have been made to predict a PEP; however, no effective predictive protocols for PEP currently exist.<sup>22</sup> Because our results were comparable and decreasing pattern of serum hCG has been reported to be helpful aid in avoiding further surgery,<sup>23</sup> serum hCG levels must be closely monitored in all patients who have had a salpingostomy before PEP is ruled out.

In the current study, no difference existed in the decline in serum hCG postoperatively between the PEP and control groups during period A; however, after period B, the decline in serum hCG in patients with PEP was significantly less than the control group. This finding indicates that a subsequent increase in the serum hCG level occurs during period B in the PEP group (approximately 3-4 days postoperatively).

Previous studies have used the decline in serum hCG to detect a PEP<sup>24-26</sup>; however, all of the studies have used a single early post-operative hCG measurement. We indicated that the future course of serum hCG cannot be predicted reliably from a single early postoperative measurement. In our study, during period B, the hCG decline in patients with PEP began to be less than the 95% CI of the control group, and from period C, the decline in PEP group was



completely outside the 95% CI of the control group. In addition, the subsequent increase in hCG was observed after period C in all PEP patients. Furthermore, once an increase in the serum hCG levels was observed, the serum hCG levels never decreased until the second intervention. Therefore, the decision to perform a second intervention, including MTX treatment, should be made by confirming a rise in the hCG levels from period A or B to period C. We also evaluated the appropriate duration of intensive hCG measurement to rule out a PEP. After period C, the hCG decline in all patients with PEP was completely outside the 95% CI of the control group. Furthermore, based on the results of the ROC analysis of the two groups, the specificity and sensitivity were equal to 100% from period C (Figure 4). These results indicate that intensive serum hCG monitoring after laparoscopic salpingostomy must be continued through period C; if the level of the hCG declines to < 14% of the preoperative level, PEP can be ruled out and the serum hCG monitoring interval can be extended.

5. Conclusions

We suggest that prophylactic intratubal injection of MTX after a linear salpingostomy for tubal pregnancy is a safe and effective regimen for preventing PEP, enhances the possibility of tubal preservation, and contributes to improvements in the postoperative QOL of patients. The decision-making for a second intervention to PEP should be made by confirming an increase of the serum hCG levels from period A or B to period C. Intensive hCG follow-up after laparoscopic salpingostomy for tubal pregnancy must continue through period C; if the serum hCG decline is < 14%, a PEP can be ruled out and the serum hCG monitoring interval can be extended. In view of these findings, serum hCG follow-up after laparoscopic salpingostomy can be as follows (Figure 5).

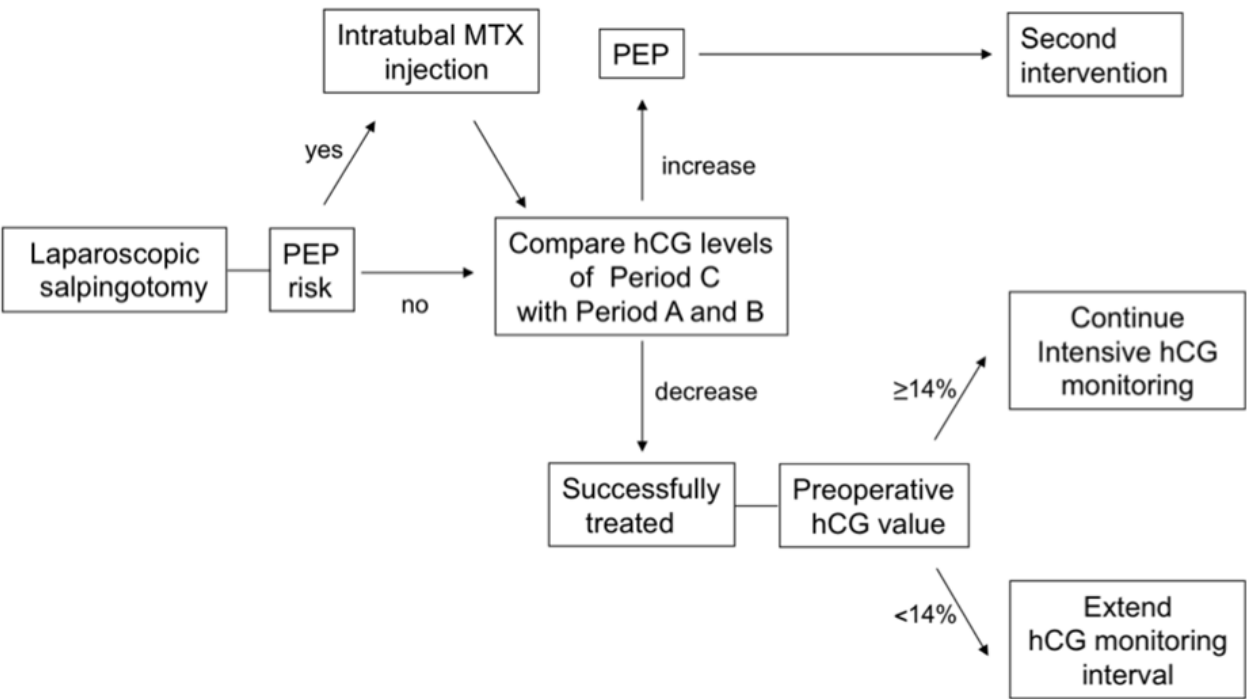



Fig. 5. Strategy for management of ectopic pregnancy after laparoscopic salpingotomy. hCG: human chorionic gonadotropin, MTX: methotrexate, PEP: persistent ectopic pregnancy.

Prophylactic local administration of MTX after laparoscopic salpingostomy may be appropriate for patients at increased risk for PEP<sup>20,27-29</sup>, specifically patients with a short duration of amenorrhea and a small ectopic pregnancy site. The hCG decline in periods A and B should be compared with period C and if a rise in serum hCG occurs, MTX should be administered. Conversely, if a continuous decline in serum hCG is confirmed and if the serum hCG decline is < 14% in period C, the measurement interval for serum hCG can be extended to once every 2 weeks until the level becomes undetectable.

## 6. References

- [1] Seifer DB, Diamond MP, Decherny AH: Persistent ectopic pregnancy. *Obstet Gynecol Clin North Am* 1991;18:153-159.
- [2] Vermesh M, Silva PD, Rosen GF, et al.: Management of unruptured ectopic gestation by linear salpingostomy: a prospective, randomized clinical trial of laparoscopy versus laparotomy. *Obstet Gynecol* 1989;73: 400-404.
- [3] Murphy AA, Nager CE, Wujek JJ, et al.: Operative laparoscopy versus laparotomy for the management of ectopic pregnancy: A prospective trial. *Fertil Steril* 1992;57:1180-1185.
- [4] Seifer DB, Gutmann JN, Grant WD, et al.: Comparison of persistent ectopic pregnancy after laparoscopic salpingostomy versus salpingostomy at laparotomy for ectopic pregnancy. *Obstet Gynecol* 1993;81:378-382.
- [5] Tanaka T, Hayashi H, Kutsuzawa T, et al.: Treatment of interstitial ectopic pregnancy with methotrexate: report of a successful case. *Fertil Steril* 1982;37:851-852.
- [6] Ory SJ, Villanueva AJ, Sand PK, et al.: Conservative treatment of ectopic pregnancy with methotrexate. *Am J Obstet Gynecol* 1986;154:1299-1306.
- [7] Graczykowski JW, Mishell DR: Methotrexate prophylaxis for persistent ectopic pregnancy after conservative treatment by salpingostomy. *Obstet Gynecol* 1997;89:118-122
- [8] Parker J, Bisits A, Proietto AM: A systematic review of single-dose intramuscular methotrexate for the treatment of ectopic pregnancy. *Aust N Z Obstet Gynecol* 1998; 38:145-150 *Z rnecol* 1998;38:145-150.
- [9] Isaacs JD Jr, McGehee RP, Cowan BD: Life-threatening neutropenia following methotrexate treatment of ectopic pregnancy: a report of two case. *Obstet Gynecol* 1996; 88:694-696.
- [10] Pansky M, Bukovsky I, Golan A, et al.: Local methotrexate injection : a nonsurgical treatment of ectopic pregnancy. *Am J Obstet Gynecol* 1989;161:393-396.
- [11] Akira S, Ishihara T, Yamanaka A, et al.: Laparoscopy with ultrasonographic guidance of intraamniotic methotrexate injection for ectopic pregnancy: a report of two cases. *J Reprod Med* 2000;45:844-846.
- [12] Menard A, Crequat J, Mandelbrot L, et al.: Treatment of unruptured tubal pregnancy by local injection of methotrexate under transvaginal sonographic control. *Fertil Steril* 1990;54:47-50.
- [13] Fernandez H, Benifla J-L, Lelaidier C, et al.: Methotrexate treatment of ectopic pregnancy: 100 cases treated by primary tranvaginal injection under sonographic control. *Fertil Steril* 1993;59:773-777.

- [14] Vermesh M, Silva PD, Sauer MV, et al.: Persistent tubal ectopic gestation: Patterns of circulating  $\beta$ -human chorionic gonadotropin and progesterone, and management options. *Fertil Steril* 1988;50:584-588.
- [15] Yao M, Tulandi T: Current status of surgical and nonsurgical management of ectopic pregnancy. *Fertil Steril* 1997;76: 421-433.
- [16] Sand PK, Stubblefield PA, Ory JS: Methotrexate inhibition of normal trophoblasts in vitro. *Am J Obstet Gynecol* 1986;155:324-329.
- [17] Haans LCF, vanKessel PH, Kock HCLV: Treatment of ectopic pregnancy with methotrexate. *Eur J Obstet Gynecol Reprod Biol* 1987;24:63-67.
- [18] Stovall TG, Ling FW, Buster JE: Outpatient chemotherapy of unruptured ectopic pregnancy. *Fertil Steril* 1989;51:435-438.
- [19] Kooi S, van Etten FHPM, Kock HCLV: Histopathology of five tubes after treatment with methotrexate for a tubal pregnancy. *Fertil Steril* 1992;57:341-345.
- [20] Stovall TG, Ling FM, Gray LA, et al: Methotrexate treatment of unruptured ectopic pregnancy: A report of 100 cases. *Obstet Gynecol* 1991; 77: 749-753.
- [21] Seifer DB, Gutmann JN, Doyle MB, et al.: Persistent ectopic pregnancy following laparoscopic linear salpingostomy. *Am J Obstet Gynecol* 1990;76:1121-1125.
- [22] Lund CO, Nilas L, Bangsgaard N, et al.: Persistent ectopic pregnancy after linear salpingostomy: a non-predictable complication to conservative surgery for tubal gestation. *Acta Obstet Gynecol Scand* 2002;81:1053-1059.
- [23] Kamrava MM, Taymor ML, Berger MJ, et al.: Disappearance of human chorionic gonadotropin following removal of ectopic pregnancy. *Obstet Gynecol* 1983;62:486-488.
- [24] Mock P, Chardonens D, Stamm P, et al.: The apparent late half-life of human chorionic gonadotropin (hCG) after surgical treatment for ectopic pregnancy. A new approach to diagnose persistent trophoblastic activity. *Eur J Obstet Gynecol Reprod Biol* 1998;78:99-102.
- [25] Spandorfer SD, Sawin SW, Benjamin I, et al.: Post-operative day 1 serum human chorionic gonadotropin level as a predictor of persistent ectopic pregnancy after conservative surgical management. *Fertil Steril* 1997;68:430-434.
- [26] Poppe W.A.J, Vandenbussche N. Postoperative day 3 serum human chorionic gonadotropin decline: a predictor of persistent ectopic pregnancy after linear salpingotomy. *Obstet Gynecol Reprod Biol* 2001; 99: 249-252.
- [27] Lundorff P, Hahlin M, Sjoblom P, Lindblom B. Persistent trophoblast after conservative treatment of tubal pregnancy: prediction and detection. *Obstet Gynecol* 1991; 77: 129-133.
- [28] Hagstrom HG, Hahlin M, Bennegard-Eden B, Sjoblom P, Thorburn J, Lindblom B. Prediction of persistent ectopic pregnancy after laparoscopic salpingostomy. *Obstet Gynecol* 1994; 84: 798-802.
- [29] Hoppe DE, Bekkar BE, Nager CW, et al.: Single-dose systemic methotrexate for the treatment of persistent ectopic pregnancy after conservative surgery. *Obstet Gynecol* ;1994: 83: 51-55.



## **Ectopic Pregnancy - Modern Diagnosis and Management**

Edited by Dr. Michael Kamrava

ISBN 978-953-307-648-5

Hard cover, 248 pages

**Publisher** InTech

**Published online** 26, October, 2011

**Published in print edition** October, 2011

Ectopic pregnancy is the second major cause of maternal mortality in the United States and a leading cause of maternal morbidity and mortality in the world. This book contains the practical methods to early diagnosis of various forms of ectopic pregnancies and their modern management. Ectopic Pregnancy - Modern Diagnosis and Management is a comprehensive book which guides the reader through all features of ectopic pregnancy, both practical and academic, covering all aspects of diagnosis and management of ectopic pregnancy in a clear, concise, and practical fashion. The book is organized so that it can either be read cover to cover for a comprehensive tutorial or be kept desk side as a reference to the ectopic pregnancies. Each chapter introduces a number of related ectopic pregnancy and its diagnosis, treatment and co-morbidities supported by examples. Included chapters bring together valuable materials in the form of extended clinical knowledge from practice to clinic features.

### **How to reference**

In order to correctly reference this scholarly work, feel free to copy and paste the following:

Shigeo Akira, Takashi Abe and Toshiyuki Takeshita (2011). Persistent Ectopic Pregnancy After Laparoscopic Linear Salpingostomy for Tubal Pregnancy: Prevention and Early Detection, Ectopic Pregnancy - Modern Diagnosis and Management, Dr. Michael Kamrava (Ed.), ISBN: 978-953-307-648-5, InTech, Available from: <http://www.intechopen.com/books/ectopic-pregnancy-modern-diagnosis-and-management/persistent-ectopic-pregnancy-after-laparoscopic-linear-salpingostomy-for-tubal-pregnancy-prevention->

**INTECH**  
open science | open minds

### **InTech Europe**

University Campus STeP Ri  
Slavka Krautzeka 83/A  
51000 Rijeka, Croatia  
Phone: +385 (51) 770 447  
Fax: +385 (51) 686 166  
[www.intechopen.com](http://www.intechopen.com)

### **InTech China**

Unit 405, Office Block, Hotel Equatorial Shanghai  
No.65, Yan An Road (West), Shanghai, 200040, China  
中国上海市延安西路65号上海国际贵都大饭店办公楼405单元  
Phone: +86-21-62489820  
Fax: +86-21-62489821

© 2011 The Author(s). Licensee IntechOpen. This is an open access article distributed under the terms of the [Creative Commons Attribution 3.0 License](https://creativecommons.org/licenses/by/3.0/), which permits unrestricted use, distribution, and reproduction in any medium, provided the original work is properly cited.

IntechOpen

IntechOpen