

We are IntechOpen, the world's leading publisher of Open Access books Built by scientists, for scientists

6,900

Open access books available

186,000

International authors and editors

200M

Downloads

Our authors are among the

154

Countries delivered to

TOP 1%

most cited scientists

12.2%

Contributors from top 500 universities



WEB OF SCIENCE™

Selection of our books indexed in the Book Citation Index
in Web of Science™ Core Collection (BKCI)

Interested in publishing with us?
Contact book.department@intechopen.com

Numbers displayed above are based on latest data collected.
For more information visit www.intechopen.com



Ectopic Pregnancy and Assisted Reproductive Technologies: A Systematic Review

Anastasia Velalopoulou et al.*

*Laboratory of Physiology, Faculty of Medicine,
University of Ioannina, Ioannina,
Greece*

1. Introduction

Ectopic pregnancy represents a rare pregnancy complication. In the last 20 years, with the use of IVF, heterotopic pregnancies have become more frequent, while this percentage differs between IVF programs. Many factors contribute to this, like the active management of hydrosalpinx or treatment of Chlamydia infection before starting a cycle. Although, *in vitro* fertilization is an expensive treatment, ectopic complication adds to this cost.

Not a lot of studies exist for ectopic pregnancy after IVF. Most of them are case reports. Not a standard way exists, for dealing with heterotopic pregnancies, even in the era of modern laparoscopy. Not a lot of research has been performed on molecules that involved. Studies have tried to associate certain techniques during IVF, with this entity, but with controversial results. There is no standard form for diagnosing, dealing and presenting heterotopic pregnancies. Most of them are diagnosed when ruptured. Because it is rare event, cost-effectiveness studies could not be performed and this complication is added to the overall IVF. Knowledge, on this field, is taken from the management of ectopic pregnancies in the general population, even if these present at a lower percentage.

The purpose of the study is to systematically evaluate studies on molecular aspects of ectopic pregnancy, the ART techniques that are associated with ectopic pregnancy, the diagnosis of this entity and finally present case reports of heterotopic pregnancies and their management. At the end, cost-effectiveness models from the general population will be presented in parallel with systematic examination of these studies. Finally, new research targets will be pointed.

* Dimitrios Peschos¹, Mynbaev Ospan², Eliseeva Marina², Ioannis Verginadis¹, Yannis Simos¹, Tsirkas Panagiotis³, Spyridon Karkabounas¹, Vicky Kalfakakou¹, Angelos Evangelou¹ and Ioannis P Kosmas^{1,3}

¹Laboratory of Physiology, Faculty of Medicine, University of Ioannina, Ioannina, Greece

²Centre of Obstetrics, Gynaecology & Perinatology, Moscow State University of Medicine & Dentistry, Moscow, Russia

³Department of Obstetrics and Gynecology, Ioannina State General Hospital G Chatzikosta, Ioannina, Greece

2. Methods

2.1 Identification and eligibility of relevant studies

Medline searches (up to March 2011) were performed using various combinations of terms: ectopic pregnancy, heterotopic pregnancy, *In Vitro* Fertilization, Intrauterine Insemination, pelvic inflammatory disease, Chlamydia trachomatis, heterotopic pregnancy, cervical pregnancy, cost-effectiveness.

The search was complemented with perusal of the bibliographies of retrieved papers and review articles. We included studies that evaluated the presence of an ectopic pregnancy after IVF in case reports, although in other chapters information was obtained from studies in the general population.

Number of tested samples was not an exclusion criterion. Only studies including human subjects were included.

2.2 Data extraction

For each study, information was obtained on authors, journal, year of publication, country and years of study enrollment, study design and study target, number of tested samples, tissue and disease tested, searched molecules and pathways involved, clinical outcome and whether biopsy was performed with the site.

Data extraction was performed independently by two investigators, and conflicts were resolved after discussion.

3. Main outcomes

3.1 Statistical methods

Frequencies of all important parameters were performed. Statistical analyses were performed in using the Statistical Package for Social Sciences (SPSS) version 12.0 (SPSS, Chicago, IL, USA).

3.2 Founding source

No sponsor was involved in the study design, report writing, or paper submission.

4. Results

4.1 Studies examining biological factors playing a role to ectopic pregnancy

A total of 42 abstracts were retrieved and further screened. Only studies that performed basic investigations were included in this part. Out of 20 included studies, 3 were performed in USA (15%), 2 in Germany (10%), Israel, Sweden and UK, and from one (5%) in Brazil, Canada, China, Croatia, Denmark, Finland, Hungary, India and Poland. 8 (40%) of them considered themselves clinical, 8 (40%) experimental, 1 (5%) prospective, 1 (5%) as pilot study, 1 (1%) as preliminary report, 1 (5%) as hypothesis testing. The type of study per country initiated can be seen in Fig 1.

All studies selected used human tissue. Five studies used fallopian tubes (25%). From the other studies 1 (5%) used fallopian tube and peripheral blood, 1 used deciduas, placenta, primary first trimester trophoblast cells and peripheral blood, 1 used decidual tissue, 2 endometrial tissue, 1 epithelial tissue and 1 mucosal tissue, 1 cervical specimen and

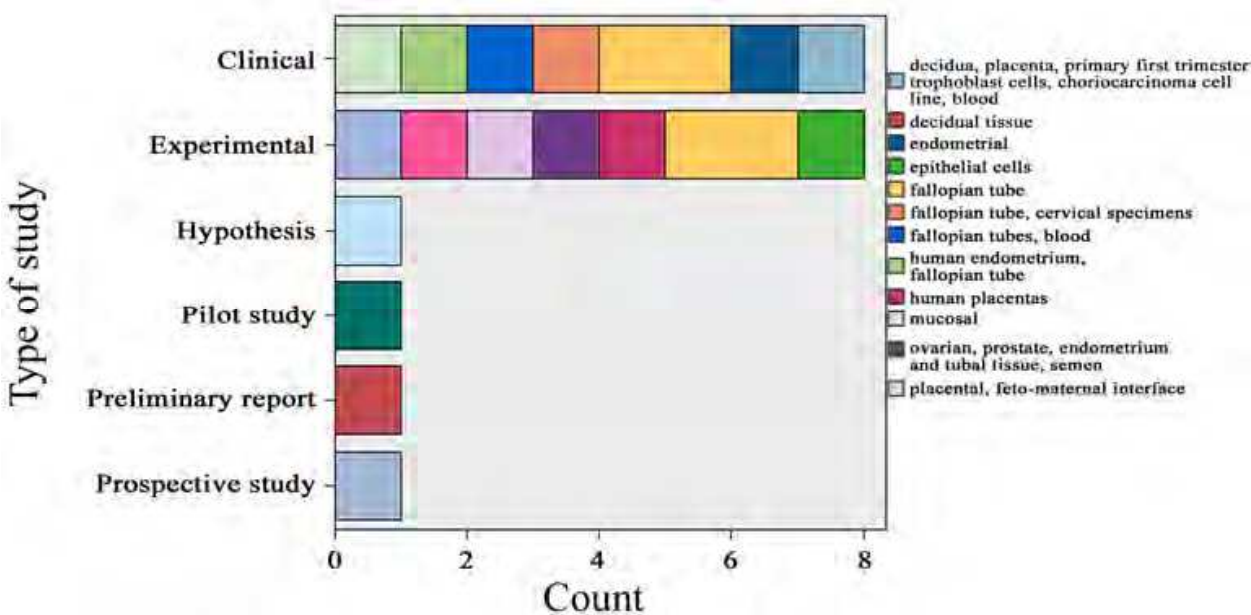


Fig. 2. Type of study per tissue used when examining biological factors in ectopic pregnancy fallopian tube samples, 1 used human endometrium and fallopian tube, 2 used human placental tissue, 1 used ovarian, prostate, endometrial, tubal and semen, 1 used trophoblast, 2 used serum samples, 1 used transervical specimens and one used stimulated cervical mononuclear cell supernatants. The type of study per tissue used can be seen in Fig 2.

4 (20%) of the studies were published in American Journal of Reproductive Immunology, 2 (10%) in Human Reproduction and from 1 (5%) in Molecular Human Reproduction, Reproduction, Reproductive Biology & Endocrinology, Reproductive Sciences, Biology of Reproduction, Cellular Microbiology, Clinical and Vaccine Immunology, European Journal of Obstetrics & Gynecology, Histochemistry & Cellular Biology, Infection and Immunity, The Journal of Immunology, The Journal of Infectious Diseases ,The Journal of Clinical Endocrinology & Metabolism, The Medical Hypothesis journal. The distribution of type of study per Journal is seen in Fig 3. Eight studies (40%) did not mentioned their controls, four studies (20%) used normal pregnant patients and intrauterine pregnancy, and from one study (5%) used women with no infection and without infertility problem, normal desidual tissue, normal endometrium and normal Fallopian tube, normal pregnant patient peripheral blood, spontaneous abortion,, tissue from women undergoing tubal ligation with segmental resection and women with viable and non-viable intrauterine pregnancy.

Samples size examined ranged from 3 (in each group) to 144. Disease distribution examined presented as: ectopic pregnancy (8/40%), spontaneous abortion and ectopic pregnancy (2/10%), Chlamydia infection (2/10%), Chlamydia infection in patients with no infertility compared with women with Chlamydia and tubal damage, ectopic pregnancy and decidualized endometrium, ectopic pregnancy and blighted ovum, ectopic pregnancy and Chlamydia infection, pelvic inflammatory disease and ectopic pregnancy, post IVF ectopic pregnancy, viable ectopic pregnancy while 1 (5%) did not mentioned disease. Funding source of each study per Journal published is seen on Fig 4.

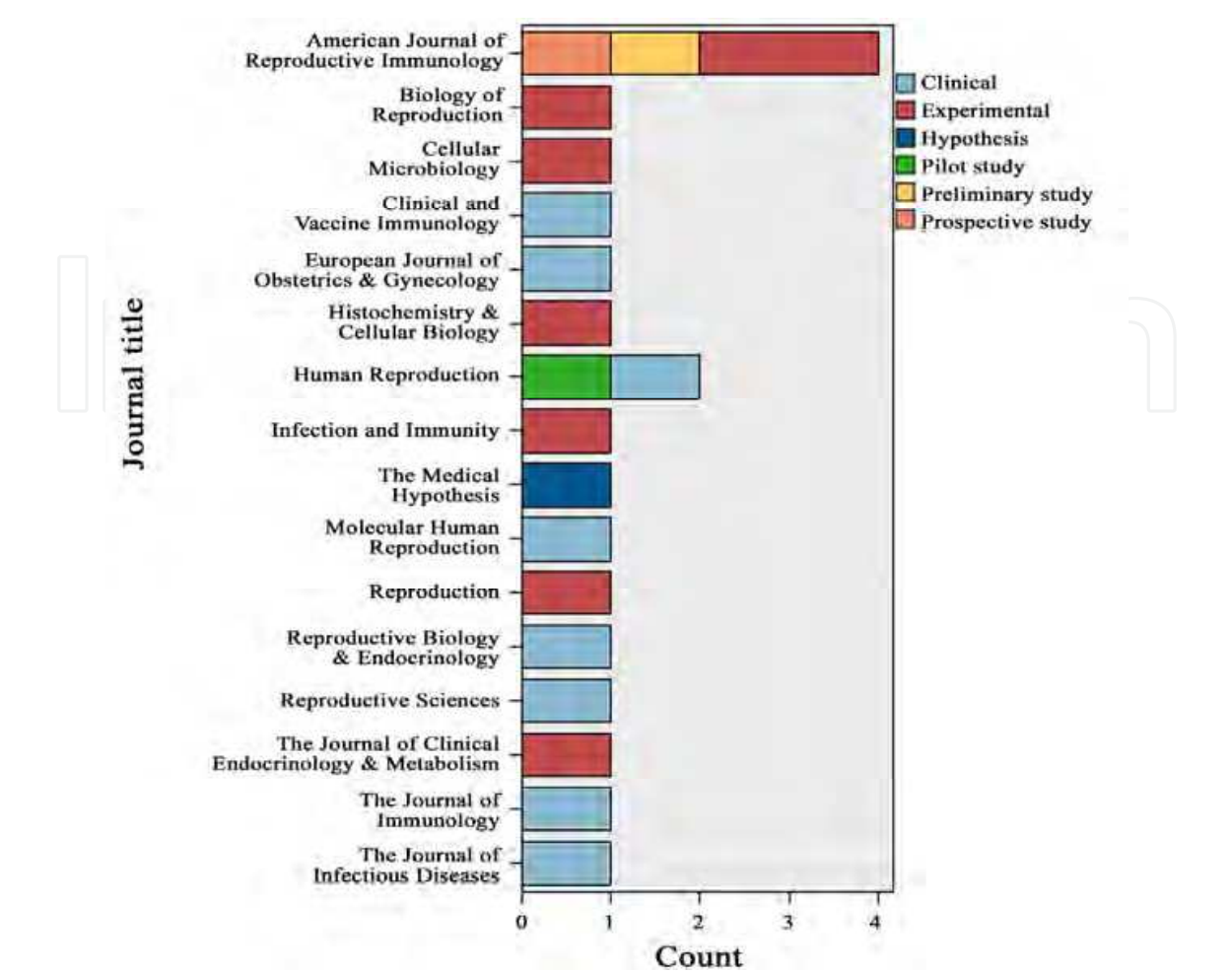


Fig. 3. The distribution of type of study per Journal when examining biological factors in ectopic pregnancy

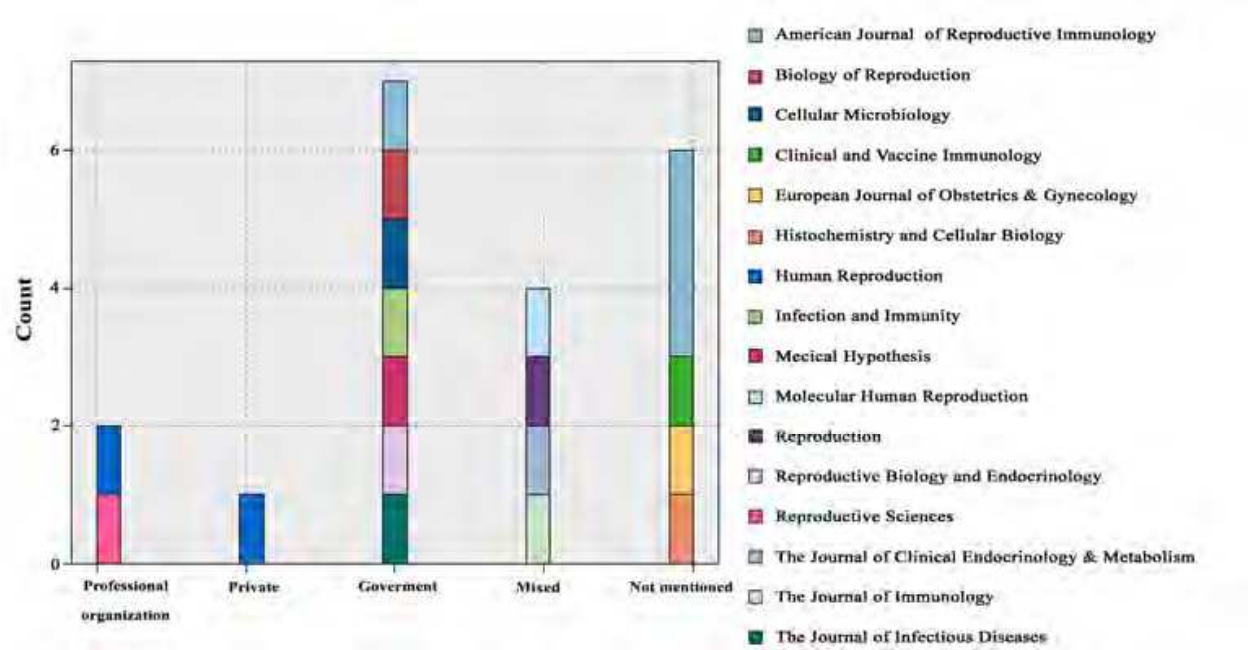


Fig. 4. Funding source of each study per Journal published

4.2 Outcomes

All studies except two (3/15%) mentioned the molecule studied. Two studies (10%) mentioned C Trachomatis DNA, one C Trachomatis serum antibodies, while from one study mentioned CD14B7H4, CHSP-60, E-Cadherin, estrogen receptor, IgG antibodies, IL-1, IL-8, Ki-67, MMP-2, PIGF, SLIT/ROBO proteins, Svcam-1, TAG-72, Treg. Ten studies (50%) did not mention a second molecule while the other studies mentioned CT antibodies (1/5%) chlamydial sarkosyl-soluble 57-kDa protein, cHSP 60, Cytokeratin 7, estrogen receptor, hCG, IL-1a, MMP-9, P38 and progesterone. 11 studies (55%) did not mention third outcome while the other ones mentioned Chsp 60 (2/10%), bhCG, cHSP 10 (1/5%), ERK, Fibronectin, FOXP 3, IL-10 and MMP-14. Thirteen studies (13/65%) did not mention a fourth outcome, while the other mentioned activin (1/5%) IFN- γ , Laminin, MAPK, neurophilin, p38 inhibitor and TIMP-1. Fifth molecule was mentioned in only 6 studies. Only four studies mentioned pathways involved: invasive pathway, p38 MAP-kinases pathway, ERK-MAPK pathway and SLIT/ROBO pathway. Only two studies (2/5%) mentioned intervention medication.

In terms of bio-analytic techniques, PCR techniques and immunohistochemistry was mainly used. For immunohistochemistry techniques, four studies (20%) did not mention it, seven studies (7%) mentioned as immunohistochemistry, 23 (15%) as immunofluorescence immunohistochemistry, and from one as electron microscopic immunohistochemistry, immunoblotting, immunoperoxidase staining (IP), immunosorbent assay, microimmunofluorescence, microimmunofluorescence-immunoblot. For PCR techniques, eleven studies (55%) did not mention PCR technique, 4 (20%) studies mention it as quantitative PCR, 2 (10%) studies mention it as PCR, two (10%) as RT-PCR, and 1 (5%) as N-PCR.

When ectopic pregnancy exists, Arias-Stella reaction is observed in endometrium. At that time, B7H4 positive macrophages is significantly lower when compared with secretory endometrium (Wicherek et al., 2009)

Chlamydia trachomatis are highly associated with ectopic pregnancy (Brunham et al., 1992). Chlamydia trachomatis antigens, exist in asymptomatic, culture negative men and women with chronic infection and may act as immunostimulants and re-activate Chlamydia (Toth et al., 2000). After first episode of ectopic pregnancy, antibody response to conserved epitope of cHSP-60 (Chlamydia heat shock protein) is associated with increased probability of adverse pregnancy outcome (Sziller et al., 2007). So this biomarker could be used for counseling women with first episode of ectopic pregnancy: if sensitized to this epitope, *in vitro* fertilization should be offered. Another indication for the significance of this biomarker is that in infertile women, when Chlamydia infected tissue is exposed to Chlamydia heat shock proteins (cHSP-60 and cHSP-10) increased release of IFN-gamma, IL-10 and TNF-alpha (Srivastava et al., 2008) affect mucosal immune function. From the other side, Ct-IgG and c-hsp6 antigens, were not found as an independent predictor of ectopic pregnancy (Bjartling et al., 2006).

In the fallopian tube of serologically positive patients for Chlamydia trachomatis that had ectopic pregnancy, there is an increase in the expression of activin β A subunit, type II receptors, follistatin and iNOS (Refaat et al., 2009).

In infected tubes from Chlamydia trachomatis infection, interleukin -1 production from epithelial cells initiates tissue destruction. By blocking IL-1 with IL-1RA receptor antagonist and/or IL-10, tissue destruction is eliminated. Chlamydia infected cells, also, produce IL-8 by ERK MAPK pathway (Buchholz et al., 2007).

Regulators T cells (Treg) express LH/CG receptor on their surface during pregnancy and are present at the fetal-maternal interface, attracted by high levels of human chorionic gonadotrophin. In ectopic pregnancies, regulatory T cells are not attracted to the same degree by the lower levels of hCG (Schumacher et al., 2009).

Another possible biomarker for ectopic pregnancy after IVF is E-cadherin, because it is highly expressed in cytotrophoblast cells of chorionic villi from these pregnancies, when compared with spontaneous ectopic pregnancy (Revel et al., 2008).

From micro-array studies, Savaris et al, by using the model of ectopic pregnancy, found that the transcriptome of the decidua is influenced by trophoblast products, in endocrine fashion (Savaris et al., 2008).

In close proximity of the tubal implantation site, MUC-1 and TAG-72 are present in the epithelial cells and might contribute to the deeper trophoblast invasion in the tubal wall (von Rango et al., 2003) while a significant reduction in NK-cell numbers at the tubal implantation site, could be seen, induced by local antigen-presenting cells in the presence of mucins (Laskarin et al., 2010).

Viable tubal pregnancies implant at the mesosalpingeal side of the tubal wall show a massively increased invasion of extravillous trophoblast cells (EVT) into the tubal wall, and the proliferation of trophoblast cells extends deeply into the invasive zone in the invasive pathway (Kemp et al., 1999). Tubal pregnancies that will undergo tubal abortion implant at the antimesometrial side which show shallow invasion and poor trophoblast proliferation (Kemp et al., 1999). In extrauterine pregnancy, expression of integrin subunit $\alpha 3$ is nearly exclusively restricted to the basal plasmalemma of the first layer of trophoblast cells while only the first proximal layer of EVT (in direct contact to the basement membrane) expresses integrin $\alpha 6$. The switch to the integrin subunits αv and $\alpha 5$ takes place already in the second layer of trophoblast cells, as soon as the latter detach from the basement membrane (Kemp et al., 2002).

In tubal pregnancies, MMP-9 and TIMP-1, -2 and -3 are produced by all types of extravillous cytotrophoblast (EVCT) cells, while MMP-2 and -14 mainly exist in distal column cytotrophoblast (CCT) cells and invasive EVCT cells (Bai et al., 2005). In parallel, MMP-14 and TIMP-1 and -2 are increased along the invasive pathway toward maternal interstitium. MMP-2, -9 and -14 and TIMP-1, -2 and -3 were all detected in the villous CT (VCT) cells (Bai et al., 2005).

Another promising technique for early detection of an ectopic pregnancy is that trophoblast cells can be reliably obtained and identified among cervical cells in the first trimester and labeled with antibody to HLA-G. The number of trophoblast cells per total cervical cells (trophoblast frequency) is significant lower in ectopic pregnancy when compared to intrauterine pregnancy but not to blighted ovum (Imudia et al., 2009). Using ROC curves the positive predictive value for abnormal pregnancy was 97% and the negative predictive value was 87%. From intrauterine tissue and sera, Horne et al, examined PIGF, localized to the cytotrophoblast cells (Horne et al, 2010). Expression of PIGF mRNA was significantly reduced in trophoblast cells, isolated from women with ectopic pregnancy compared with intrauterine pregnancies. Serum PIGF was undetectable in women with tubal ectopic pregnancies and reduced, or undetectable, in miscarriage compared with viable intrauterine pregnancies.

From the other side, it seems that SLT/ROBO pathway and protein expression in endometrium and fallopian tube, is not implicated in ectopic pregnancy because known factors that contribute to EP (e.g. smoking/cotinine or chlamydial infection) do not alter

protein expression (Duncan et al., 2010). Also serum VCAM-1 was found comparable between the three pregnancy types, normal, ectopic and failed thus making this marker not useful for the diagnosis of ectopic pregnancy (Daniel et al., 2000).

Also a role for ectopic pregnancy formation might exist from ovulation induction regimens. Clomiphene citrate, which used for anovulatory infertility, may indirectly contribute to ectopic pregnancy creation. Chronic treatment with clomiphene activates estrogen receptors, particularly in cilia, and inducing tubal apoptosis of isthmus epithelial cells while slowing oocyte cumulus complex passage from the fallopian tube (Shao et al., 2009). This may contribute to ectopic pregnancy formation.

5. Section 2

5.1 Ectopic pregnancy and IVF

A total of 56 abstracts were retrieved and further screened. Out of 40 included studies, 10 (25%) were performed in USA, 3 (7.5%) in England, India and in Netherlands, 2 (5%) in France, Greece, Israel, Italy and Nepal, while 1 (2.5%) in Australia, Canada, Germany, Japan, Jordan, Korea, Norway, Singapore, Taiwan, Thailand and between USA/Sweden. 17 (42.5%) of them considered themselves retrospective, 11 (27.5%) as case report, and from 1 (2.56%) as cohort study, prospective randomized double blinded cross over study, prospective cohort study, population based cost-effectiveness study, epidemiological study, economical analysis, cost effectiveness analysis, cost benefit analysis, cost analysis, while 3 (7.5%) do not mentioned the type of study. The type of study per country initiated can be seen in Fig 5.

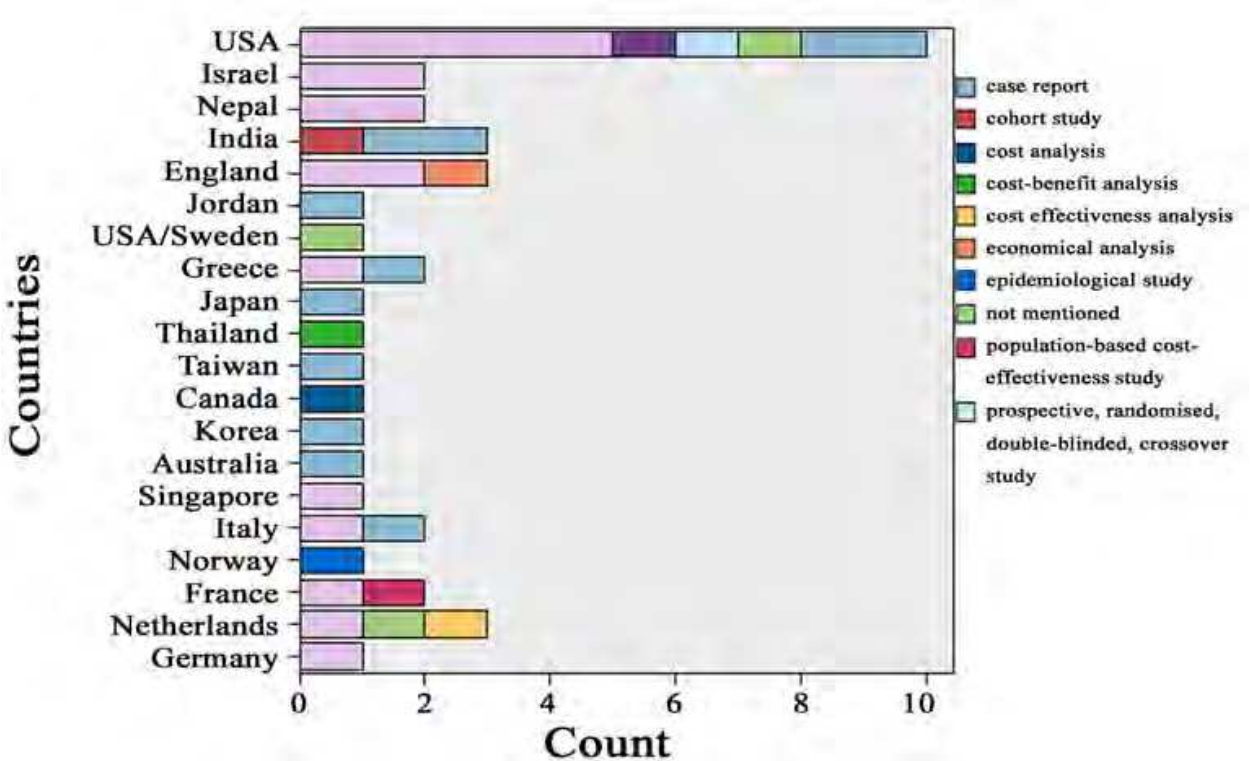


Fig. 5. The type of study per country initiated examining IVF and ectopic pregnancy

All studies selected used human tissue. Fourteen studies mentioned embryo (35%) as tissue examined plus 4 (10%) mentioned especially the blastocyst, 4(10%) used fallopian tube and

from 1 (2.5%) used embryos with thickened zona pellucida, fallopian tube ectopic pregnancy and sperm with abnormal characteristics, hydrosalpinx, ovarian tissue and trophoblastic tissue, while one tested newborns for congenital abnormalities after failed emergency contraception while 12 (30%) did not specified the tissue examined. The type of study per tissue used can be seen in Fig 6.

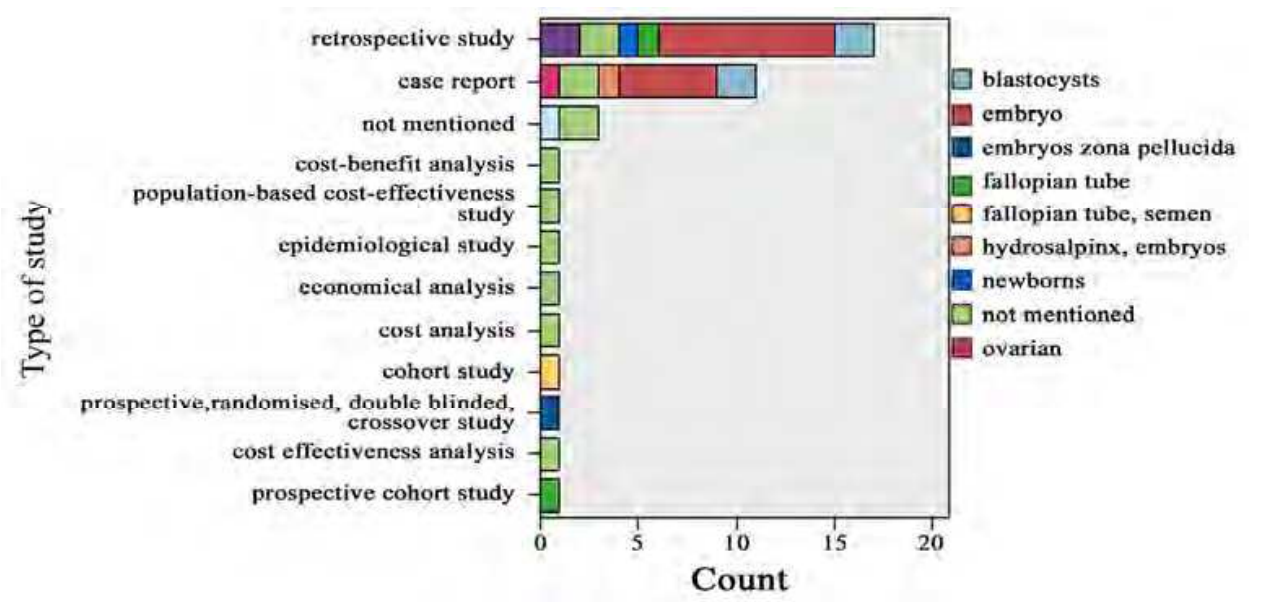


Fig. 6. The type of study per tissue used examining IVF and ectopic pregnancy

12 (30.0%) of the studies were published in Fertility & Sterility, 5 (12.5%) in Human Reproduction, 5 (12.5%) in the Journal of Assisted Reproduction & Genetics, and from 1 (2.5%) in Acta Obstetrica et Gynecologica Scandinavica, American Journal of Emergency Medicine, Annals Academy of Medicine, BMC Pregnancy & Childbirth, BMJ, British Journal of General Practice, British Journal of Obstetrics & Gynecology, Clinical Chemistry, Contraception, European Journal of Obstetrics, Gynecology & Reproductive Biology, International Federation of Gynecology & Obstetrics, International Journal of Gynecology & Obstetrics and Journal of Obstetrics & Gynecology, Kathamandu University Medical Journal, Nepal Medical College Journal, Obstetrics & Gynecology, Sex Transmission Infections and The Lancet. The distribution of type of study per Journal is seen in Fig 7. Samples size examined ranged from 1 (case reports) to 44. Disease distribution examined presented as: ectopic pregnancy (17/42.5%), and from 1 (2.5%) bilateral tubal ligation, chlamydial infection-tubal infertility-ectopic pregnancy, ectopic pregnancy on patients after IVF with abnormal sperm characteristics, ectopic pregnancy after oocyte donation in menopausal patients, ectopic pregnancy after donation surviving even with the absence of exogenous steroids, ectopic pregnancy after embryos with thickened zona pellucida, ectopic pregnancy after empty follicle syndrome, ectopic pregnancy after exposure to levonorgestrel, heterotopic abdominal pregnancy, heterotopic abdominal pregnancy, ectopic pregnancy after hydrosalpinx, menopause and oocyte donation, ovarian heterotopic pregnancy, ectopic pregnancy after pelvic inflammatory disease, pelvic inflammatory disease-ectopic pregnancy and neonatal complications, primary infertility, tubal factor infertility and bilateral ovarian pregnancy, tubal sterilization while 3 (7.5%) did not mentioned disease. Funding source of each study per Journal published is seen on Fig 8.

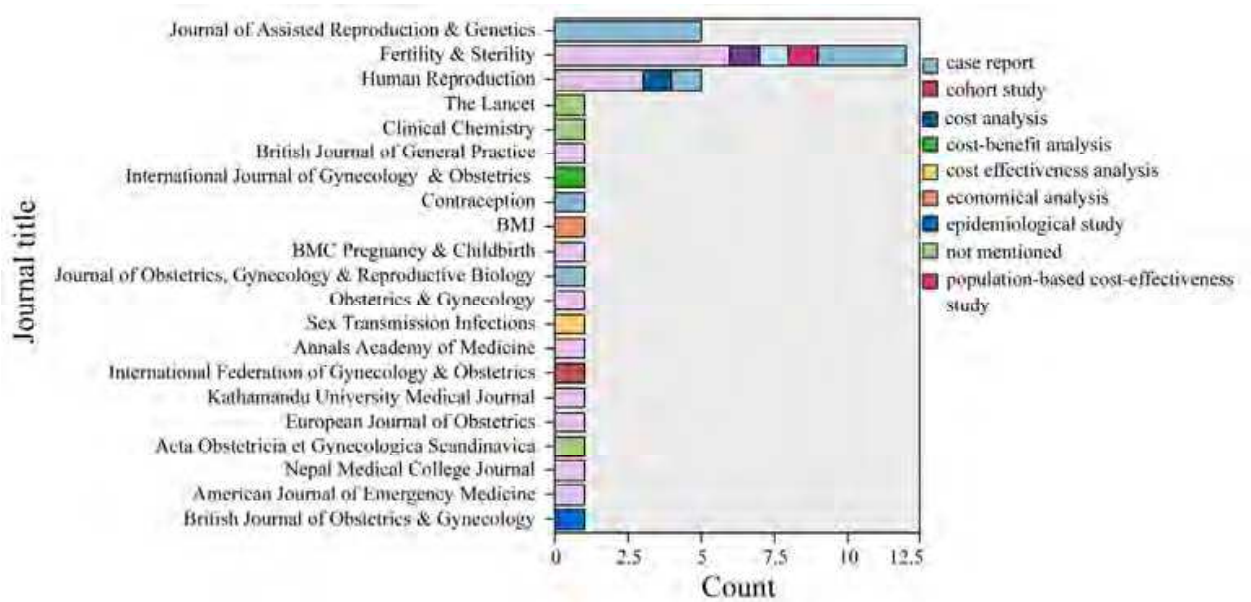


Fig. 7. The distribution of type of study per Journal examining IVF and ectopic pregnancy

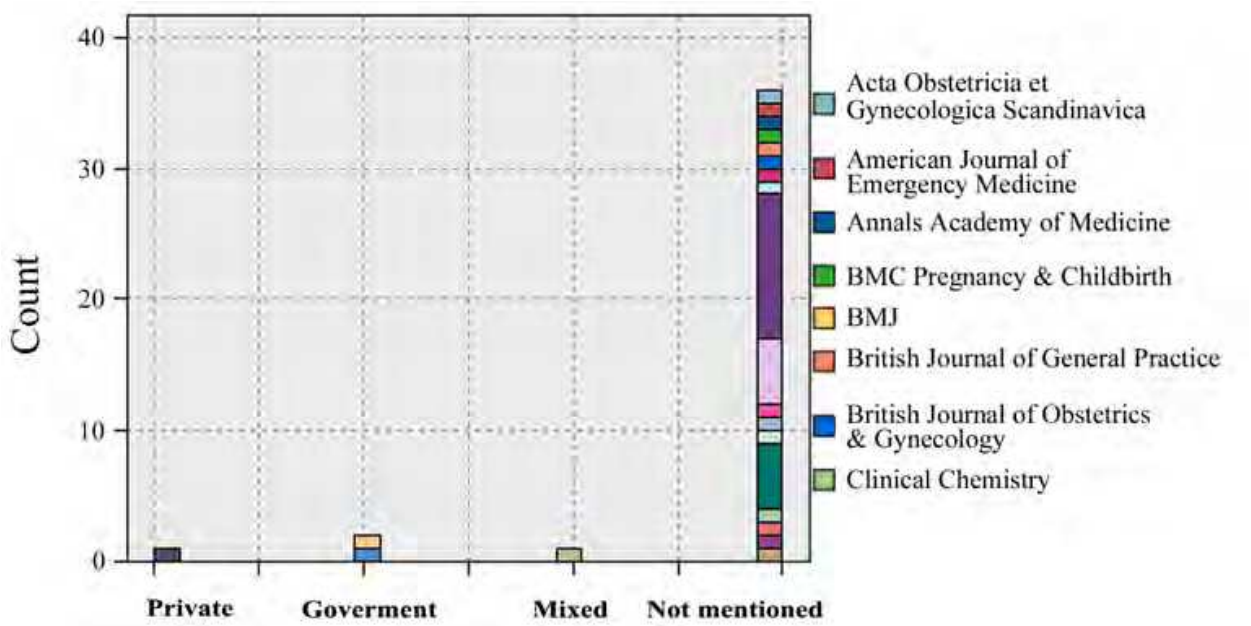


Fig. 8. Funding source of each study per Journal published examining IVF and ectopic pregnancy

5.2 Outcomes

5.2.1 Factors contributing to ectopic pregnancy after IVF

Pyrgiotis et al, retrospectively analyzed a large series of fresh (n=2812) and frozen embryo transfers (n=405) showing a 2.4% and 7.6% EP rate, respectively (Pyrgiotis et al., 1994). Tubal factor presented as 85.7% of all causes of ectopic pregnancies. In a previous study, an EP rate of 3.3% was found (26 patients) and the major contributing factor was a prior ectopic (Karande et al., 1991). Heterotopic pregnancy rates remained low in both studies while the majority of them were tubal. Also cervical pregnancies were low.

Clayton et al, in the largest series of 94,118 pregnancies found an EP rate of 2.2% in fresh non-donor cycles while ZIFT procedures EP rate was 3.6% (Clayton et al., 2006). Tubal factor with or without hydrosalpinx was the main factor of ectopic pregnancy while endometriosis, uterine factor and diminished ovarian reserve was some of the less but important factors. Although all other factors may be well understood, the last factor could be explained from the fact that when higher implantation embryo potential was present, EP rate was minimal. When two or less embryos transferred, then the EP rate was less than when three or more embryos transferred.

To the extent of the previous study, abnormal embryogenesis was a major factor for ectopic pregnancy. From this study it was found that DNA aneuploidy was associated with tubal implantation in 33% (Karikoski et al., 1993). Similar rates (24%) of abnormal amount of DNA content in tubal pregnancies was found also by Toikkanen et al., 1993.

In a recent study Chang et al, found that tubal factor infertility and endometriosis was the main factor (Chang et al., 2010). Tubal surgery and previous ectopic pregnancies was another important factor while risk for EP was seriously decreased with a previous live birth. Donor oocytes do not attribute to more ectopic pregnancies and this apply to higher embryo implantation potential, as mentioned above.

Contradictory to previous results, Bhattacharya et al, found that ectopic pregnancies in IVF are associated with significantly lower percentage of motile sperm (Bhattacharya et al., 2010).

A more detailed approach follows:

5.2.2 Heterotopic pregnancy

It is considered a rare entity of ectopic pregnancy (1/30000) and could be seen especially after IVF (<0.01) (Dimitry et al, 1990; Molloy et al., 1990). It has been presented in literature in various forms: 1) Triplet heterotopic pregnancy a) in a previous caesarian scar and intrauterine pregnancy b) a tubal singleton and two intrauterine pregnancies and an ovarian abscess c) bilateral tubal and intrauterine pregnancy 2) Cornual pregnancy a) recurrent cornual pregnancy b) cornual pregnancy and twin intrauterine pregnancy 3) heterotopic pregnancy with intrauterine dizygotic twins after blastocyst transfer 4) heterotopic cervical pregnancy a) intrauterine and twin cervical pregnancy b) cervico-istmic pregnancy 5) Heterotopic pregnancy in parallel with ovarian hyperstimulation syndrome 6) heterotopic pregnancy ruptured after spontaneous abortion.

Eventually the presence of an intrauterine gestation sac in a patient without symptoms should not exclude the diagnosis of a concomitant extrauterine pregnancy until the pelvis is carefully visualized (Rizk et al., 1991).

5.2.3 Differences in the prevalence in different countries of the world

EP complicates about 2% of all pregnancies. Although no studies exists that specifically describe the prevalence in different countries, especially after IVF treatment, certain studies present this, as a secondary outcome. In Nigeria (Okohue et al., 2010), prevalence for EP was 7.8% after IVF, while in general population in the same country, EP rate was 1.74% (Musa et al., 2009). The same percentage in Jordan was 0.005% (Obeidat et al., 2010). In Cameroon, this percentage is 0.72% (Leke et al., 2004). In a large follow up study, in Sweden, ectopic pregnancy rates were compared between women from different countries of birth, but small differences were found (Eggert et al., 2008). In New York, ectopic pregnancy rates in black women are 4.78% (Fang et al., 2000).

5.2.4 Contraception as a risk factor

Ghosh et al, described a right ampullary ruptured ectopic pregnancy after the failure of levonorgestrel as emergency contraception (Ghosh et al., 2009), while Fabunmi and Perks, reported a case of Caesarean section scar pregnancy after the same LNG failure (Fabunmi & Perks, 2002). From the other side, opposite to the numerous case reports, De Santis et al, in a retrospective observational cohort study found no association of LNG failure with ectopic pregnancy (De Santis et al., 2005).

5.2.5 Ectopic pregnancy rates in fresh vs. frozen cycles

Controversy exists in this issue. Jun et al, found no difference in ectopic pregnancy rates between fresh and frozen cycles while Yanaihara et al, found a significant difference in ectopic pregnancies when two frozen blastocysts were transferred, than one (Jun et al., 2007; Yanaihara et al., 2008). From the other side, Ishihara et al, in a large registry retrospective study, found that frozen-thawed single blastocyst transfer significantly reduce EP rates (Ishihara et al., 2010). Even when data were stratified for age, EP rates varied, but remained low.

5.2.6 Day 3 versus day 5

Milki et al, found no difference in ectopic pregnancy rates when blastocyst transfer compared with day 3 embryo transfer (Milki et al., 2003). In this study important confounding factors like tubal disease between the two groups, cryopreserved transfers but not number of embryos transferred were checked between the two groups and no significant difference was found.

5.2.7 Blastocyst (single vs. double blastocyst transfer)

Knopman et al, reported a heterotopic abdominal pregnancy after the transfer of two blastocysts (Knopman et al., 2006). Intrauterine pregnancy miscarried first while abdominal pregnancy ruptured two weeks later and ectopic removed by laparoscopy. Ectopic pregnancies are significant lower when single frozen-thawed blastocysts transferred compared with two blastocysts (Yanaihara et al., 2008).

5.2.8 Oocyte donation and ectopic pregnancy rates

Cohen et al, found that hydrosalpinx patients that undergo oocyte donation have higher ectopic pregnancy rates than patients in the same program with no hydrosalpinx (Cohen et al., 1999). Possible explanation for that is the chronic alteration of endometrium rather the direct embryotoxic effect of hydrosalpinx fluid. In case, after oocyte donation, an ectopic takes place, minimal monitoring may allow rupture of ectopic with significant complication (Ledger et al., 1992). Mantzavinos et al, reported three case of ovarian pregnancy after oocyte donation (Mantzavinos et al., 1994). Cases were resolved with laparoscopy and removal of ovarian pregnancy tissue. Pantos et al, in a large series of donation patients found only one ectopic pregnancy (Pantos et al., 1993). Rosman et al, in a large retrospective study (4186 non-donor IVF cycles vs. 884 donor ET cycles) found that there is no difference in ectopic pregnancy rates between donor and IVF cycles (Rosman et al., 2009). From the other side, donor patients showed significant lower incidence of tubal disease than standard IVF patients.

5.2.9 The ICSI role

In a large retrospective study, Clayton et al, found that use of ICSI was not associated with EP while male factor infertility was associated more with EP with all other races than white-non-Hispanic (Clayton et al., 2006).

5.2.10 Ultrasound guided embryo transfer

In a meta-analysis of clinical trials (on 5,968 ET cycles), comparing ultrasound guided ET vs. clinical touch ET (Abou-Setta et al., 2007), it was found that ectopic pregnancy rates were no different between the two groups. In a another meta-analysis on 17 studies, (Brown et al., 2010), it was found the same results, although it was stated that EP are relatively rare and study sample sizes limit the ability to detect such differences. Even when a single clinician performs all embryo transfers, (Kosmas et al., 2007), no difference in ectopic pregnancy rates was found.

5.2.11 Assisted hatching

Hagemann et al, found no difference in ectopic pregnancy rates in patients that their embryos had assisted hatching or not (Hagemann et al., 2008). From the other side Milki et al, in a large series of retrospectively examined patients saw that a significant higher ectopic pregnancy rate was found in cases where assisted hatching (AH) was performed when compared with cases that hatching was not preformed (Milki et al., 2004). Possible explanation for that is: 1) assisted hatching may accelerate embryo implantation, 2) a mechanism exists, that prevents embryos that reached fallopian tube to divert back to uterus and 3) the much higher embryo transfer volume that used in certain IVF programs.

5.2.12 Air bubble position after embryo transfer

No difference in ectopic pregnancy rates was observed with different distances of embryo deposition from the uterine fundus (10-15 mm or < 10 mm) (Pacchiarotti et al., 2007).

5.2.13 Reanastomosis

Patients with tubal infertility may undergo microsurgical reconstructive surgery of the fallopian tubes for adhesiolysis, anastomosis, fimbrioplasty, salpingostomy, and refertilization after former sterilization. These patients, if choose the microsurgical approach, show higher ectopic pregnancy rates after a single IVF trial (Schipper et al., 2009). From the other side, in a small series of patients, higher incidence of ectopic pregnancies was observed when previous tubal sterilization was reversed by laparoscopy than open microsurgical reversal (Tan et al, 2010). Even if suture less laparoscopic tubal re-anastomosis was performed (using a serosamuscular fixation/biological glue technique) an ectopic pregnancy rate of 3.9% was observed (Schepens et al., 2011). In a small series of robotic tubal reanastomosis (Dharia Patel et al., 2007) more ectopic pregnancies were observed when compared with open reanastomosis.

5.2.14 Other complications of ectopic pregnancies

Rh immunization could be observed in ruptured ectopic pregnancy.

6. Section 3

6.1 Diagnosis of an ectopic in IVF

Pregnancies of unknown location include viable pregnancies, ectopic pregnancies and miscarriages (Condous et al., 2005). Only a small portion of them are high risk pregnancies

(Condous et al., 2005) and there is difficulty in diagnosis and management. Serial measurements of hCG and progesterone should be performed on a wait and see approach, in parallel with TVS. Serum hCG increase over 48 h of more than 66% – that is, an hCG ratio of >1.66 – correlates well with a developing intrauterine pregnancy. The use of discriminatory zone technique (Condous et al., 2005), is currently evaluated for prediction of probability of ectopic pregnancy. By this technique, if an intra-uterine sac cannot be seen on ultrasound scan above the threshold value, then steps must be taken to determine whether the pregnancy is abnormal or ectopic. After that a D&C can be safely performed only when a non-viable pregnancy has been documented by either a serum progesterone level of 15.9 nM or the absence of a rise in serum hCG after 2 days; that is, an hCG ratio of <1.50 (Pisarska et al., 1998).

6.2 Transvaginal ultrasound and hCG levels for prediction

With the use of TVS, before 35 days a pregnancy could be considered as a pregnancy of unknown location, from 35 to 41 days a pregnancy of uncertain viability and from 42 days a viable intrauterine pregnancy (Bottomley et al., 2009). Time for diagnosis of ectopic pregnancy was 48 days. In case, previous ectopic pregnancies took place, then diagnosis could be made before this time. Viability scans should be deferred until 49 days of gestation with a minimal benefit delaying after that. The addition of abdominal pain and vaginal bleeding adds to ectopic pregnancy risk. Statistical models have been developed, based on the hCG ratio to predict the outcome of pregnancies of unknown location and especially ectopic pregnancies (Kirk et al., 2006), but this is not easily implemented in clinical practice.

6.3 Newer biomarkers for ectopic pregnancy

Daniel et al, tested for serum sVCAM-1, ectopic and normal pregnancies, but did not find any difference (Daniel et al., 2000).

C. trachomatis antigen and nucleic acid could be found at 33% among ectopic pregnancies tissue even if they are negative for cervical Chlamydia (Toth et al., 2000).

Activin A subunit, type II receptors, follistatin, and iNOS show increased expression within the fallopian tube of ectopic pregnancy patients tested serologically positive for C. trachomatis (Refaat et al., 2009). Especially for iNOS, elevated activity positively correlates with protection from hydrosalpinx formation and prevention of the systemic spread of C. trachomatis. In a clinical setting, Florio et al, found that Activin A levels were significantly lower in spontaneous abortions and intrauterine pregnancies than ectopic ones, and at the cutoff of 0.37ng/ml a sensitivity and a specificity of 100 and 99.6%, respectively, was achieved, for prediction of EP (Florio et al., 2007). From the other side, on a different approach, Kirk et al, found no more discriminatory capacity of Activin A and inhibin than serum hCG levels for ectopic pregnancy in case of a pregnancy of unknown location (Kirk et al., 2009).

7. Section 4

7.1 Management of specific ectopic pregnancies

In this section, a total of 26 abstracts were retrieved and further screened. Only studies that performed clinical interventions for ectopic pregnancy after IVF were included in this part. Out of 16 included studies, 5 (31.25%) were performed in Taiwan, 4 in USA (25%), 2 in Italy

(12.5%), 1 (6.25%) in France, 1 in Germany (6.25%), 1 (6.25%) in Netherlands, 1 in Turkey (6.25%), and one in Serbia and Montenegro. 15 (93.75%) of them considered themselves case report while 1 (6.25%) clinical. The type of study per country initiated can be seen in Fig 9.

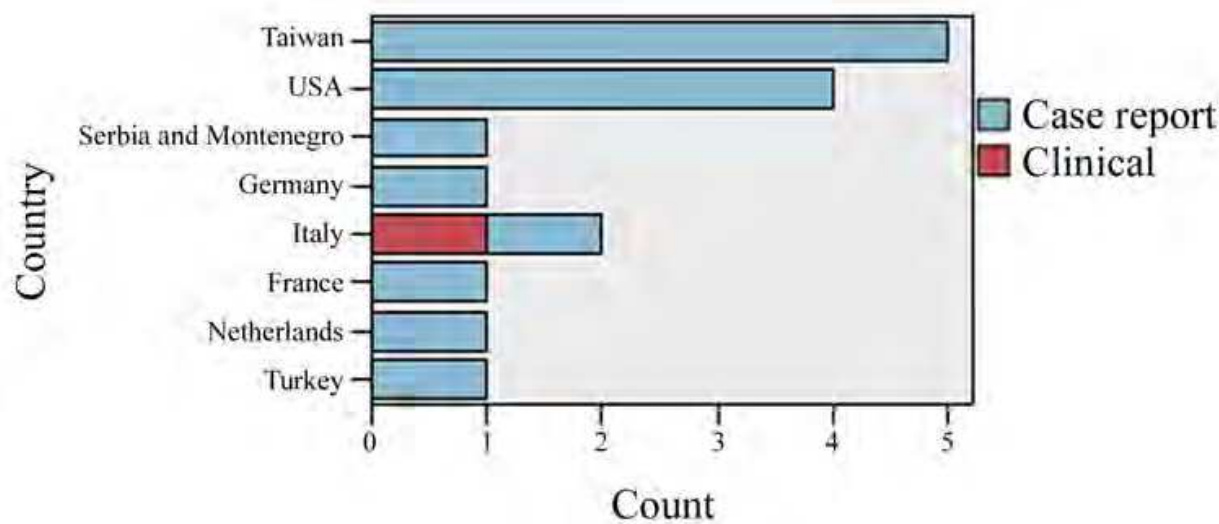


Fig. 9. The type of study per country initiated

All studies selected used human tissue. Thirteen studies did not mention anatomical tissue used (81.25%). From the other studies 1 (6.25%) used fallopian tissue, 1 used endometrium & fallopian tube, and one used cornual pregnancy. The type of study per tissue used can be seen in Fig 10.

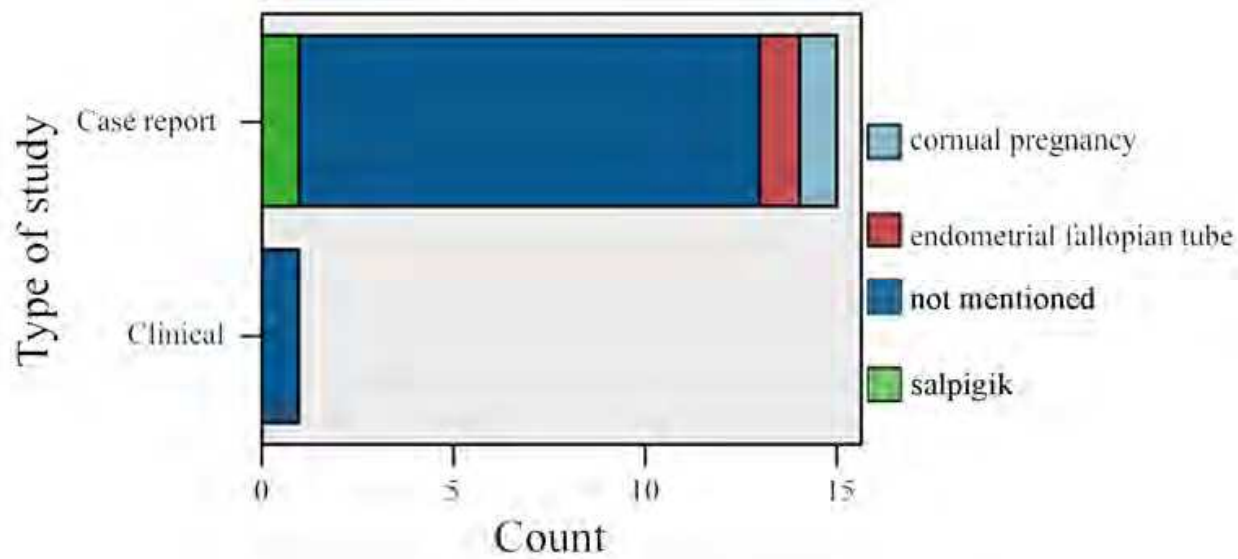


Fig. 10. The type of study per tissue used

10 (62.5%) of the studies were published in Fertility & Sterility, 2 (12.5%) in Human Reproduction and from 1 (6.25%) in Archives Gynecological & Obstetrics, Journal of Obstetrics & Gynecology, Journal of Assisted Reproduction & Genetics and Mayo Clinical Proceedings. The distribution of type of study per Journal is seen in Fig 11. All studies did not mention their controls.

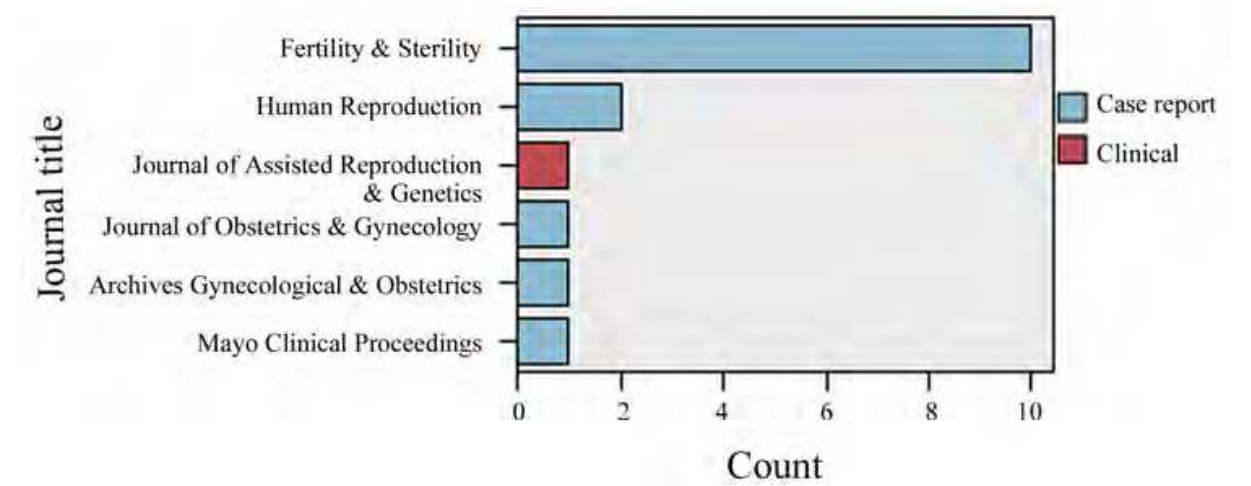


Fig. 11. Type of study per Journal published

Samples size examined ranged from 1 (case report) to 104. Disease distribution examined presented as: heterotopic cesarean scar pregnancy, (5/31.25%) (one study described ectopic twin pregnancy in a Cesarean section scar (1/6.,67%) and a second described a triplet heterotopic cesarean scar pregnancy), heterotopic cervical pregnancy (4/25%), cornual pregnancy (1/6.25%), heterotopic cornual pregnancy, heterotopic triplet pregnancy, Intersitial Heterotopic pregnancy, unilateral ectopic twin pregnancy while one study did not mentioned the type of ectopic pregnancy. Tissue used per disease is seen on Fig12.

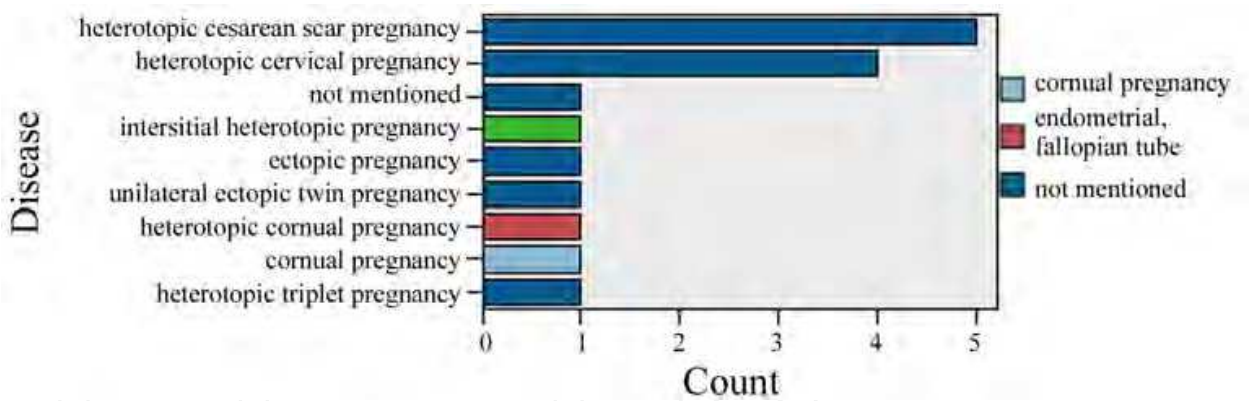


Fig. 12. The type of tissue used per disease

Funding source of each study per Journal published is seen on Fig 13.

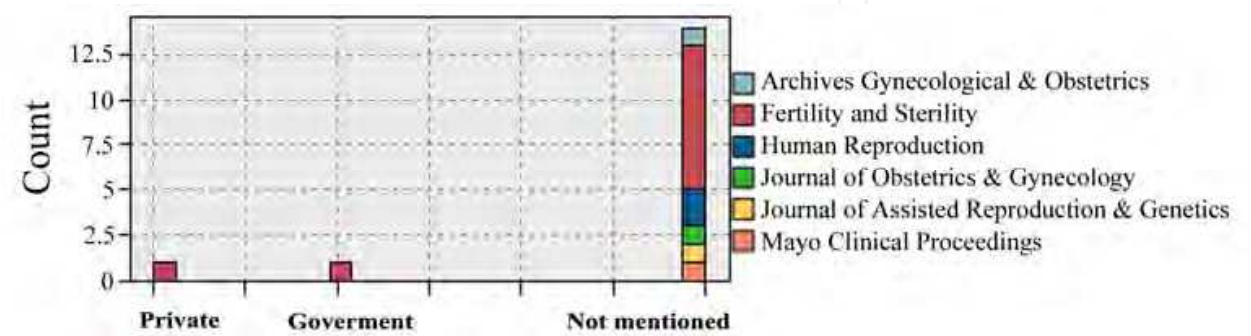


Fig. 13. Funding source of each study per Journal published

Five studies (31.25%) did not use any pharmacological interventions while the other 11 described it: two studies used potassium chloride, one study used sodium chloride, one used systemic methotrexate, one used vasopressin. The other six studies described the pharmacological interventions from IVF, previously performed.

7.2 Rare cases of ectopic pregnancies

Papers that report ectopic pregnancies after IVF and their clinical picture will be presented in this section. Case studies will be presented according to anatomical location and management.

7.2.1 Ovarian ectopic pregnancies

In a large series of patients, Raziel et al., found that ovarian ectopic pregnancy rate comprises 2.7% of all ectopic pregnancies, is highly associated with the use of intrauterine device and treated with laparoscopic wedge resection (Raziel et al., 2004). The use of ultrasound for diagnosis of hemoperitoneum makes culdocentesis not necessary.

Case reports presenting ovarian ectopic pregnancies present: 1) ovarian heterotopic pregnancy after IVF (Kamath et al., 2010), 2) bilateral ovarian pregnancy after IVF and previous tubal pregnancy after reanastomosis (Han et al., 2004), 3) left ovarian pregnancy after empty follicle syndrome in IVF treatment (Qublan et al., 2008), 4) ovarian pregnancy from cornual fistulae after bilateral salpingectomy and IVF treatment (Hsu et al., 2004).

7.2.2 Management of a late ectopic pregnancy

A case of a cervical intrauterine pregnancy has been reported by Fruscalzo et al., after IVF (Fruscalzo et al., 2007). At the 13th gestational week, a viable intrauterine pregnancy and a non viable cervical pregnancy were diagnosed. The cervical pregnancy was anteriorly confined near a thick cervical blood vessel with low resistance flow at Doppler ultrasound. Due to the proximity to the cervical venous vessel, there was increased hemorrhagic risks associated with a cervical pregnancy expulsion. After hospitalization and observation, cervical pregnancy was expelled at 15th gestational week + 6 days and hemorrhage was managed through cervical curettage and multiple cervical stitches under general anesthesia. Unfortunately, some hours later, intrauterine pregnancy expelled also, leading to a curettage.

Another case of heterotopic pregnancy at 16 wks gestation after IVF was presented by Hassiakos et al., 2002. It was ruptured and presented with intra-abdominal bleeding and hemorrhagic shock.

7.2.3 Maternal-embryo complications from use of Potassium chloride

A study by Gyamfi et al, described a cervical heterotopic pregnancy (one in the intrauterine cavity and the other in the upper portion of the cervix) treated with KCl (3 mL) injection and aspiration of the gestational sac contents (Gyamfi et al., 2004). A blood supply, separate from that of the remaining pregnancy was seen at 19 wks by color Doppler. Unfortunately remaining trophoblastic tissue did not resolve, leading to obstetric hemorrhage at 31 wks gestation and subsequently to emergency cesarean hysterectomy with a viable infant, while patient waited for an elective Cs at 32 wks. Another possible complication of this technique is that diffuse of KCL in the target amniotic sac, may lead to diffuse to adjacent sac, thus makes harm to the intrauterine embryo.

7.3 Rare ectopic pregnancies

7.3.1 Cervical pregnancies

A heterotopic cervical pregnancy treated with TVS-guided aspiration at day 34 after her embryo transfer, developed of uterine varices at the cervical site, bilateral hypogastric artery occlusion was used while a fundal classic cesarean section at 37 weeks gave birth to an infant (Shah et al., 2008). Uterine varices were diagnosed at 28 weeks gestation, as prominent vessels associated with the empty sac located anteriorly and posteriorly occupying a significant portion of the myometrium of the lower uterine segment and cervical stroma. Venous waveforms were observed on Doppler studies. Fundal C section was planned to avoid entry into the gestational tissue and vasculature that occupied the lower uterine segment. After delivery, the patient went for pelvic angiography and possible embolization to diminish the risk of bleeding.

Prorocic et al. described the treatment of a heterotopic cervical pregnancy with TVS-guided aspiration and instillation of hypertonic solution of sodium chloride and ligation of descending cervical branches of the uterine arteries (Prorocic et al., 2006). The latter took place before TVS guided aspiration. By vagina retraction, two DEXON sutures were placed bilaterally on the cervix, high below the fornix vaginae thus reducing hemorrhage, significantly. Twin pregnancy in the uterine cavity continue to grow till article publication (at 12th week of pregnancy).

A cervical twin ectopic pregnancy has been described by Aboufoutouh et al. (Aboufoutouh et al., 2011). Treatment consistent from transvaginal ultrasound-guided aspiration plus systemic single injection of methotrexate.

A 37-year-old woman after IVF developed severe ovarian hyperstimulation syndrome. Transvaginal ultrasound revealed two gestational sacs with one viable fetus located below the internal cervical os at 7 weeks' gestation while Doppler imaging demonstrated a cervical mass containing numerous tortuous and dilated blood vessels and vascular communication beds in the implantation site and established abundant peritrophoblastic arterial flows. 2 days later developed vaginal bleeding and Intracervical Foley catheter tamponade was performed. Persistently active gestational tissue and bleeding leads to hysteroscopic endocervical resection (12-degree resectoscope with an outer diameter of 8 mm) in combination with temporary balloon occlusion of bilateral common iliac arteries (CIA). After complete removal of gestational tissue, electrocoagulation was done using the rollerball for homeostasis. After that, a 24-Fr Foley balloon catheter was placed at the cervical canal to achieve homeostasis while methotrexate 50 mg im was injected on the following day, and the 24-Fr Foley balloon catheter was removed 3 days after surgery (Yang et al., 2010). Same method of treatment was used by Peleg et al. (Peleg et al., 1994).

A 45-year-old woman, diagnosed by ultrasound with a triplet gestation 7 weeks following IVF. Transvaginal ultrasound showed a triplet heterotopic pregnancy consisting of two gestational sacs in the cervix and one in the uterine cavity. Termination of pregnancy was decided for future fertility preservation with catheterization and methotrexate treatment. The right femoral artery was catheterized with catheter and the uterine arteries were cannulated. 42 mg of methotrexate were injected into the right and left uterine arteries (total dose of 84 mg (50 mg/m₂)). Pledgets of Gelfoam were then used to embolize the arteries. Follow-up ultrasound scan (after 48 hours) revealed an absence of cardiac activity in both embryos. A gradual shrinkage of the cervical and intrauterine sacs was seen later (Nitke et al., 2007).

A 37-year-old woman undergone ICSI, due to severe oligoasthenoteratospermia, diagnosed with transvaginal ultrasound two gestational sacs with embryonic heartbeats, one in the cervical region and the second intrauterine. Hysteroscopic removal of the cervical gestational sac was chosen, to preserve the intrauterine pregnancy. The gestational sac was observed on the left side of the endocervical canal 2 cm away from the internal cervical os. The tip of the resectoscope did not go beyond the internal cervical os during the operation, and the uterine cavity was not touched. By roller ball electrocautery was used for the conception products. Cautery settings were 100 W for cutting, and the coagulation current blend was 1. The entire procedure was performed under continuous ultrasound guidance with an abdominal probe (Jozwiak et al., 2003).

A viable intrauterine and cervical pregnancy was diagnosed in a 34-year-old woman in her 4 IVF attempts. With transabdominal scanning, needle was inserted transcervically and maneuvered into the embryo fetal heart that ceased. After that KCl injected. Then 3 cm³ of saline were injected for better visualization of the cervical fetus, and to confirm absence of heart beat. The intrauterine pregnancy delivered at 36.5 wks (Carreno et al., 2000).

A heterotopic cervical pregnancy diagnosed 25 days after ET because the patient reported some mild vaginal bleeding. Transvaginal ultrasound and Doppler vascular blood flow confirmed the suspected heterotopic cervical pregnancy that was treated with transvaginal ultrasound-guided aspiration and KCL injection in the heterotopic pregnancy cavity. Sixteen days after the procedure, and under epidural anesthesia, hemostatic synthetic absorbable sutures were placed high on the cervix at 1, 3, 9, and 10 o'clock, ultimately circumferentially tying the cervix. Cervical-stay sutures dissolved by the 18th–20th weeks of gestation while no cervical incompetence was observed. At 38 weeks of gestation, via cesarean section an infant was delivered. For safety precautions, during the procedure, interventional radiologists were on standby to perform uterine artery embolization if necessary (Chen et al., 2001).

7.3.2 Ectopic pregnancies developed in a scar

7.3.2.1 Previous myomectomy scar

Although pre-IVF myomectomy is not a necessity to achieve an ongoing pregnancy (Vimercati et al., 2007), other authors prefer to perform it, especially when repeated implantation failures take place (Margalioth et al., 2006) or uterine cavity involvement exists (Klatsky et al., 2007). In a retrospective study for laparoscopic myomectomy outcomes, Paul et al. mentioned a 5.2% EP rate (Paul et al., 2006). In the same year, Seracchioli et al., reported an EP rate of 2.6% (Seracchioli et al., 2006). From the other side Campo et al. found no ectopic in their series after laparoscopic myomectomy (Campo et al., 2003). None of the ectopic pregnancies developed in the scar of the previous myomectomy.

7.3.2.2 Previous Cesarean scar (CSP)

Cesarean scar pregnancy carries the high risk of uncontrollable bleeding requiring hysterectomy, so management has to include this risk in its treatment options.

Wang et al. described a heterotopic pregnancy combined with intrauterine pregnancy after IVF (Wang et al., 2007). Embryo reduction was performed with transvaginal ultrasound-guided KCL injection (0.2ml) at 10 wks gestation. A mass 3x3 cm remained till 32 wks gestation. A male was delivered at 35 weeks delivered by CS. Remaining gestational tissue leads to massive blood loss after CS, blood transfusion and bilateral internal iliac arteries ligation.

Another author (Wang et al., 2010) found a Cesarean Scar pregnancy (within the isthmic area of the lower anterior wall of the uterus) and an intrauterine pregnancy after IVF. At this time, management was performed by hysteroscopy evacuation at 7 wks gestation and coagulation of the implantation vessel site. Cervix was dilated to 11 mm, not beyond the endocervical canal and gestational sac was pulled out, under sonographic guidance. Suction curettage was used to clear the residual gestational tissue and a hysteroscopic rolling ball was used to stop the bleeding point. A healthy infant delivered by Cs at 39 wks gestation.

From the other side two different cases was presented by Chueh et al., 2008. Both cases were a twin cesarean scar pregnancy. Ectopic pregnancies were treated either by laparotomy excision of the scar twin pregnancy (first case) and hysteroscopic resection (second case) with resectoscopic coagulation of placenta bed vessels. In both cases, no fluid was seen in the cul-de-sac.

More pregnancies could be observed in cesarean scar. Litwicka et al, described a triplet heterotopic cesarean scar pregnancy after IVF, a twin pregnancy in the anterior isthmic wall close to the CS scar (separated from the bladder wall by a thin myometrial layer) and one intrauterine gestational sac (Litwicka et al., 2010). Caesarian scar gestation sacs have been diagnosed, one week later than the intrauterine sac. Transvaginal ultrasound-guided potassium chloride (2 ml) and methotrexate (15 mg) was injected in the ectopic gestational sacs while the intrauterine pregnancy continue to ongoing pregnancy.

In another case, described by Hsieh et al, a heterotopic triplet pregnancy was evident after IVF treatment, two intrauterine pregnancies and one cesarean scar pregnancy (Hsieh et al., 2004). Color Doppler sonography revealed proliferated peritrophoblastic vessels around the Caesarean scar pregnancy and the intrauterine twin pregnancy. CSP was treated with embryo aspiration under vaginal ultrasonography with preservation of intrauterine twin pregnancy. Due to preterm labour, two infants delivered at 32 wks gestation.

Rare CSP may exist at different forms after IVF treatments and previous CS. The management of these pregnancies may be performed with laparotomy or hysteroscopic resection of CS ectopic tissue after KCL lethal injection to embryo. Also MTX may be used for the second case. Complications of the second treatment include spontaneous abortion and congenital abnormality of MTX or diffuse of KCL in the target amniotic sac that may lead to diffuse to adjacent sac.

7.3.3 Live twin pregnancy in the same fallopian tube

A left fallopian tube twin pregnancy was presented by Atabekoğlu et al., an isthmic pregnancy and another ampullary sac in the same tube (Atabekoğlu et al., 2009). Both treated with a left laparoscopic salpingectomy.

7.3.4 Cul-de-sac pregnancy

A case of a cul-de-sac ectopic pregnancy after IVF, was described by Shih et al. (Shih et al., 2007). After 4 weeks from ET it was found an ectopic gestational sac with fetal heart beat in the left adnexa. It was revealed, by laparoscopy, an ectopic mass in the congenital blind pouch that was connected to the posterior cul-de-sac. Laparotomy was used for removal of conceptus and homeostasis.

7.3.5 Hepatic pregnancy

Although a lot of case reports exist for a hepatic pregnancy in the literature (Chin et al., 2010; Moores et al., 2010), none of them is reported after IVF, so they mentioned as primary

hepatic pregnancy. Chlamydia infections may involved also in this type of ectopic because adhesions between and liver the diaphragm (Fitz-Hugh-Curtis Syndrome) were demonstrated in 34% of those with EP (Picaud et al., 1991). Treatment of this type of pregnancy included direct methotrexate injection (Nichols et al., 1995), laparoscopic suctioning and homeostasis (Chin et al., 2010) or laparotomy. In case an advanced week's live pregnancy is diagnosed, then laparotomy with intact placenta may be performed (Shukla et al., 1995).

7.3.6 Intrauterine and twin bilateral tubal pregnancy

Pan et al, report a case of bilateral tubal pregnancy and intrauterine pregnancy (Pan et al., 2002). After right tubal embryo transfer (due to cervical stenosis) of four embryos, in 5th week, a laparotomy showed a ruptured right tubal pregnancy, hemoperitoneum and a dilated left tube. Bilateral salpingectomy was performed with preservation of intrauterine pregnancy and deliver of a male at term.

7.3.7 Intrauterine and interstitial heterotopic pregnancy after bilateral salpingectomy

Patient had two previous unsuccessful IVF cycles and removed both tubes for bilateral hydrosalpinges. After that she preformed a third IVF cycle. She developed an intrauterine pregnancy and an interstitial pregnancy that ruptured at the left salpingectomy site by its lateral position to the insertion of the ipsilateral round ligment. After laparotomy and left cornual resection, intrauterine pregnancy survived two more weeks and miscarried. Trisomy 21 was revealed, in aborted fetus (Dumesic et al., 2001).

7.3.8 Cornual pregnancy

Two studies exist that describe cornual pregnancy after IVF. First case was a heterotopic triplet pregnancy after in utero transfer of three embryos (Divry et al., 2006). Cornual pregnancy was treated with resection by laparotomy. A special technique was presented in this patient. A Vicryl string with a tight knot was inserted at the base of the implantation site of the corneal pregnancy and the base of the uterine wall above this string was sectioned. Cornual scar was closed with same stitches in X form while a base knot left in place. Intrauterine twin pregnancy continue uneventfully till 31 wks gestation, where the patient delivered two girls with Csection. The site of the corneal pregnancy was well vascularized and not ruptured.

The second case was a recurrent spontaneous cornual pregnancy 2 years after a heterotopic cornual pregnancy occurred after IVF cycle (van der Weiden et al., 2005). Previous cornual heterotopic pregnancy was treated with injection of 0.5 ml of 15% potassium chloride into the fetal heart while normal pregnancy was delivered at 39 weeks of gestation by elective caesarean section. Spontaneous cornual pregnancy was treated by injection of 40 mg methotrexate in the gestational sac and systemic methotrexate (1.0 mg/kg orally alternated with 15 mg folinic acid).

7.3.9 Interstitial pregnancy

Berkes et al., reported a unilateral triplet ectopic pregnancy, on a woman with a history of right salpingectomy (Berkes et al., 2008). After IVF, in the left fallopian tube, a triplet pregnancy was found (two pregnancies at interstitial and one at ampullary location). Color flow Doppler sonography revealed intensive perithrophoblastic blood flow around the two gestational sacs with live embryos while TVS showed three gestational sacs, in the left

interstitial area, in the isthmic part of the fallopian tube and in the ampullar part next to the left ovary. After multiple dose of methotrexate, hCG levels were lowered but pregnancies were ruptured, so a laparotomy was performed with the removal of the left tube and cornual part of the uterus. Another case of previous bilateral salpingectomy and IVF was reported by Chang et al. (Chang et al., 2003). An intrauterine monozygotic twin and an interstitial monozygotic twin pregnancy were reported. By laparotomy, interstitial pregnancy was removed and intrauterine pregnancy allowed delivering at 38 wks gestation. Another intrauterine monochorionic diamniotic twin pregnancy and an interstitial pregnancy were reported by Nikolaou et al. (Nikolaou et al., 2002). Also after bilateral salpingectomy and IVF, interstitial heterotopic pregnancy was developed that ruptured (Dumesic et al., 2001). A recurrent interstitial pregnancy in uterine horn was seen after IVF (Muzikova et al., 2003).

Laparoscopic loop ligature was used by Qin et al, for heterotopic interstitial pregnancy (Qin et al., 2008). Perez et al., reported medical therapy in two cases of interstitial pregnancy, one with transvaginal ultrasound guided injection of methotrexate and second with potassium chloride into the ectopic sac of the heterotopic twins (Perez et al., 1993).

Overall, interstitial pregnancies are always possible after tubal occlusion.

7.3.10 Rare cases of mild ovarian hyperstimulation and ectopic pregnancy

Korkontzelos et al., reported the co-existence of ovarian hyperstimulation with ascetic fluid accumulation, enlarged ovaries after IVF and a right tubal ectopic pregnancy (Korkontzelos et al., 2006). Right salpingectomy was performed. Same case was presented by Fujii et al., which ended in a bilateral salpingectomy and continuation of intrauterine pregnancy till 32 wks of gestation (Fujii et al., 1996).

7.3.11 Consecutive recurrent ectopic pregnancies

Three consecutive recurrent pregnancies have been reported in the same patient with pelvic inflammatory disease, two in the right fallopian tube and one in the left. Laparotomy was performed in all three cases, to preserve the tubes while removing conceptus (Adelusi et al., 2003). Another case of two consecutive ectopic pregnancies after IVF, was presented by Abu-Musa et al. (Abu-Musa et al., 2002). Three consecutive cases of ectopic pregnancy on the same patient was presented by Oki et al., 1998. The first involved simultaneous intrauterine and left tubal pregnancy, the second was a right tubal pregnancy, and the third was a right interstitial pregnancy. Another case of two ectopic pregnancies in consecutive menstrual cycles was presented by Irvine et al. (Irvine et al., 1999). Left distal ectopic pregnancy was seen and treated with left partial salpingectomy while in the next cycle a right distal ectopic pregnancy was observed which treated with right partial salpingectomy. Except the second case, the other two patients conceived by coitus, so cases are presented in this review because they are rare. Another report of recurrent cornual ectopic pregnancy has been presented (MacRae et al., 2009) but presentation is beyond the scope of this manuscript.

8. Section 5

8.1 Cost effectiveness

8.1.1 Chlamydia trachomatis -ectopic pregnancy-cost effectiveness

Eight studies described cost-effectiveness of Chlamydia screening for pregnancy complications, including ectopic pregnancy. For most of them, proactive screening of

Chlamydia is not cost-effective when tested in general population (Buhaug et al., 1989; Roberts et al., 2007; van Valkengoed et al., 2001) and that only when women aged 18 to 24 years old tested or prevalence of Chlamydia is over 3% (Postma et al., 2000) or 2% (Trachtenberg et al., 1988), cost-effectiveness exist for prevention of ectopic pregnancy. Hu et al, pointed out that annual screening for Chlamydia is indicated for women 15 to 29 years of age and selective targeting with semiannual screening of those women with a history of infection (Hu et al., 2004). Partner treatment should be provided (Postma et al., 1999) to avoid re-infection. Another author (Schjøtz et al., 1991) found that routine post-treatment control of non- systematic genital Chlamydia infection is not cost-beneficial.

8.1.2 Ultrasound for diagnosis of ectopic pregnancy-cost-effectiveness

In an emergency department, to rule out the possibility of ectopic pregnancy, the most cost effective strategy is to screen all patients with first trimester bleeding and lower abdominal cramping with ultrasound (Durstun et al., 1999), even if the scan is performed by an emergency doctor. Obviously this technique is not cost-effective in symptoms free women (Mol et al., 2002).

8.1.3 Laparoscopic treatment for Ectopic pregnancy-cost effectiveness

When laparoscopy is compared with methotrexate for its cost savings, methotrexate saves about 1000, Canadian dollars (Yao et al, 1996). In a decision and cost-effectiveness analysis, Seror et al., found that first line treatment with methotrexate is more cost-effective than conservative laparoscopy and radical laparoscopy in sub-acute ectopic pregnancy (Seror et al., 2006). Conservative laparoscopy was more cost-effective than radical laparoscopy in this group of patients, in terms of fertility preservation. Methotrexate treatment effectiveness was increased when diagnostic ultrasound accuracy is increased. If patient after an IVF ectopic pregnancy treated with methotrexate, then, in the next cycle, similar ovarian stimulation characteristics could be obtained (Orvieto et al., 2007).

9. Conclusion

In this systematic review we presented the most important studies dealing with ectopic pregnancy after *in vitro* fertilization. Also, important biological factors that play a role for EP has been presented. Case reports of ectopic pregnancies their position in the uterus, and the steps undertaken to preserve intrauterine pregnancy has been described. Complications of these treatments, where available, have been mentioned. Practices during *in vitro* fertilization treatment and their controversial role for this pregnancy complication have been described. Overall, cost-effectiveness studies in the ectopic pregnancy prediction and management has been described. New research directions have been pointed out.

Although ectopic pregnancies and more specific heterotopic pregnancies are rare, these increase due to infertility treatment. Active and aggressive management of hydrosalpinx has been proposed for heterotopic pregnancy minimization after IVF.

All combinations of heterotopic pregnancies have been described. The major complication was bleeding and rupture of pregnancy. Care was taken for intrauterine pregnancy continuation but many cases miscarried after some time. Laparoscopy and hysteroscopy were methods of choice but laparotomy was chosen when threat of major bleeding was expected. Another method of treatment was vaginal aspiration of embryo sac after a lethal injection with a pharmacological agent. Most cases have not recognized till rupture of ectopic pregnancy.

The majority of studies were case report and retrospective studies. Even if more studies exist in a specific issue (e. g. ectopic pregnancy rates in fresh and frozen IVF cycles) these are not, homogenously designed, and no data synthesis could be made. Also in the management of heterotopic pregnancies, a single methodology was not used, so no best practices outcome could be formed. Screening for ectopic pregnancy show better cost-effectiveness only when we expect increased prevalence of this entity (Roberts et al., 2007; van Valkengoed et al., 2001) or women age from 18 to 24 years old (Buhaug et al., 1990). Also general population screening program for C. Trachomatis, show that costs exceeds the benefits to avoid ectopic pregnancy. The method of choice for treatment is laparoscopy, because show similar cost-effectiveness but less invasiveness (Gray et al., 1995) than laparotomy. Combination therapies, like uterine artery embolization and laparoscopy has been used for complications like hemorrhage. Although these therapies are expensive, the rare cases do not allow a cost-effectiveness analysis to be performed.

Many heterotopic pregnancies were identified after EP rupture, thus leading to a laparoscopy or laparotomy and possible complications while an early identification may lead to MTX therapy, that is by far a more cost-effective treatment strategy. From the other side, close ultrasound monitoring has revealed heterotopic pregnancies developed in previous Caesarean scar pregnancy, cervical pregnancies etc. So for IVF patients, more intense ultrasound and b-hCG monitoring is required. It is not known yet whether this applies to all patients that had an ET or only in the subgroup of patients with risk factors for EP undergoing ET.

Many ectopic pregnancies remained unidentified with viable pregnancies till second trimester. It is important, for these cases, to improve our detection capabilities with new approaches. Heterotopic pregnancy may present with different combinations and uterine locations, at various gestational ages, even when the intrauterine pregnancy aborts. Eventually the presence of an intrauterine gestation sac in a patient without symptoms should not exclude the diagnosis of a concomitant extrauterine pregnancy until the pelvis is carefully visualized (Rizk et al., 1991). Currently, no biomarker could early identify an ectopic pregnancy, especially a heterotopic one. A promising non invasive marker could be developed from the use of cervical trophoblastic cells and special markers on them.

Regarding the IVF procedure, infertility medication should be used cautiously from non-specialists and ovulation induction has to be preformed always under close monitoring. In case of altered tubal motility, close monitoring of pregnancy as evolves, should be performed.

Chlamydia infections and tubal factor infertility still remain the major factor for EP after IVF. Active management for hydrosalpinx seems to lower EP rates, but still no minimal invasive test exists. No other IVF technique could be accounted for increased ectopic pregnancy rates except the transfer of multiple embryos, especially more than two. Where indications exist for increased EPs after specific techniques (e. g. assisted hatching), more clinical trials should be performed, controlled also for EP factors. Tubal transfer techniques (ZIFT) have been abandoned through years, so they could not account for EP in the modern era. Tubal reanastomosis also is not practiced in all IVF clinics, and only where it is practiced it has to be considered as a factor of tubal pregnancy.

Another issue that needs to be checked is the association of ectopic pregnancy and the abnormal embryogenesis. This is important for male factor infertility and increased age. It is not clear yet whether more intense pregnancy monitoring should apply in these patients.

As a general policy, individual IVF practices should evaluate their EP rate in an attempt to identify factors that may increase or decrease the rate compared to national statistics (Keegan et al., 2007).

It is not clear yet, whether a single biological pathway should account for ectopic pregnancy. Although TB implantation mechanism is different from normal uterine mechanism, tubal pregnancies should be used to study embryo implantation. Invasive pathway, as described in ectopic pregnancy seems to be important. Another pathway that may be involved is the NO pathway that is altered through the Chlamydia infection altered immune response.

Researchers performing RCTs in ectopic pregnancies need to consider certain issues in their design. Patients differ in age and the infertility factor. A trial has to control for the number of embryos transferred, the quality of them and patients demography because a common underlying risk factor might exist. A clear measure of complications has to be developed, especially for cost effectiveness studies. Because ectopic pregnancies after IVF always need intervention, no placebo trials could be performed. Length of follow up and follow up plan need to be decided before hand, so pregnant women need to have standardized care. Level of training for the providers of IVF services seems to be important.

Ruptured ectopic pregnancies may present with severe complications, due to hemorrhage. Currently, no single treatment plan is chosen and different groups perform different approaches. Although these treatments are life saving, they are not cost effective. It is important for hospitals with large IVF groups to undertake such studies, so knowledge to be transferred to smaller groups. In case of heterotopic pregnancy, it is important to know how to protect the intrauterine embryo (as valuable pregnancy), so research should direct to this also.

10. References

- Aboulfoutouh, I. I.; Youssef, M. A.; Zakaria, A. E.; Mady, A. A. & Khattab, S. M. (2011). Cervical twin ectopic pregnancy after *In Vitro* fertilization-Embryo transfer (IVF-ET): case report. *Gynecol Endocrinol*, (April 2011), [Epub ahead of print]
- Abou-Setta, A. M.; Mansour, R. T.; Al-Inany, H. G.; Aboulghar, M. M.; Aboulghar, M. A. & Serour, G. I. (2007). Among women undergoing embryo transfer, is the probability of pregnancy and live birth improved with ultrasound guidance over clinical touch alone? A systemic review and meta-analysis of prospective randomized trials. *Fertil Steril*, Vol. 88, No. 2, (August 2007), pp. 333-341, ISSN 1556-5653
- Abu-Musa, A.; Nassar, A.; Sakhel, K. & Usta, I. (2002). Two consecutive ectopic pregnancies after in-vitro fertilization and embryo transfer. Case report. *Clin Exp Obstet Gynecol*, Vol. 29, No. 4, (2002), pp. 302-303, ISSN 0390-6663
- Adelusi, B.; al-Meshari, A.; Akande, E. O. & Chowdhury, N. (1993). Three consecutive recurrent ectopic pregnancies. *East Afr Med J*, Vol. 70, No. 9 (September 1993), pp. 592-594, ISSN 0012-835X
- Atabekoğlu, C. S.; Gözükuçuk, M.; Ozkavukçu, S. & Sönmezer, M. (2009). Rare presentation of ectopic pregnancy following IVF-ET: live twin gestation in the same fallopian tube. *Hum Fertil (Camb)*, Vol. 12, No. 2, (June 2009), pp. 122-124, ISSN 1742-8149
- Bai, S. X.; Wang, Y. L.; Qin, L.; Xiao, Z. J.; Herva, R. & Piao, Y. S. (2005). Dynamic expression of matrix metalloproteinases (MMP-2, -9 and -14) and the tissue inhibitors of MMPs (TIMP-1, -2 and -3) at the implantation site during tubal pregnancy. *Reproduction*, Vol. 129, No. 1, (January 2005), pp. 103-113, ISSN 1741-7899

- Berkes, E.; Szendei, G.; Csabay, L.; Sipos, Z.; Joo, J. G. & Rigo, J. Jr. (2003). Unilateral triplet ectopic pregnancy after *in vitro* fertilization and embryo transfer. *Fertil Steril*, Vol. 90, No. 5, (November 2008), pp. 0003. e17-20, ISSN 1556-5653
- Bhattacharya, S. M. & Ghosh, M. (2010). Abnormal sperm characteristics and risk of ectopic pregnancy. *Int J Gynaecol Obstet*, Vol. 110, No. 2, (August 2010), pp. 161-162, ISSN 1879-3479
- Bjartling, C.; Osseer, S. & Persson, K. (2007). Deoxyribonucleic acid of Chlamydia trachomatis in fresh tissue from the Fallopian tubes of patients with ectopic pregnancy. *European Journal of Obstetrics & Gynecology and Reproductive Biology*, Vol. 134, No. 1, (September 2007), pp. 95-100, ISSN 1872-7654
- Bottomley, C.; Van Belle, V.; Mukri, F.; Kirk, E.; Van Huffel, S.; Timmerman, D. & Bourne, T. (2009). The optimal timing of an ultrasound scan to assess the location and viability of an early pregnancy. *Hum Reprod*, Vol. 24, No. 8, (August 2009), pp. 1811-1817, ISSN 1460-2350
- Brown, J.; Buckingham K.; Abou-Setta, A. M. & Buckett, W. (2010). Ultrasound versus 'clinical touch' for catheter guidance during embryo transfer in women. *Cochrane Database Syst Rev*, Vol. 20, No. 1, (January 2010), pp. CD006107, ISSN 1469-493X
- Brunham, R. C.; Peeling, R.; Maclean, I.; Kosseim, M. L. & Paraskevas, M. (1992). Chlamydia trachomatis-Associated Ectopic Pregnancy: Serologic and Histologic Correlates. *The Journal of Infectious Diseases*, Vol. 165, No. 6 (June 1992), pp. 1076-1081, ISSN 1537-6613
- Buchholz, K. R. & Stephens, R. S. (2007). The Extracellular Signal-Regulated Kinase/Mitogen-Activated Protein Kinase Pathway Induces the Inflammatory Factor Interleukin-8 following Chlamydia trachomatis Infection. *Infection and Immunity*, Vol. 75, No. 12, (December 2007), pp. 5924-5929, ISSN 1098-5522
- Buhaug, H.; Skjeldestad, F. E.; Backe, B. & Dalen, A. (1989). Cost effectiveness of testing for chlamydial infections in asymptomatic women. *Med Care*, Vol. 27, No. 8, (August 1989), pp. 833-841, ISSN 1537-1948
- Buhaug, H.; Skjeldestad, F. E.; Halvorsen, L. E. & Dalen, A. (1990). Should asymptomatic patients be tested for Chlamydia trachomatis in general practice? *Br J Gen Pract*. Vol. 40, No. 333, (April 1990), pp. 142-145, ISSN 1478-5242
- Campo, S.; Campo, V. & Gambadauro, P. (2003). Reproductive outcome before and after laparoscopic or abdominal myomectomy for subserous or intramural myomas. *Eur J Obstet Gynecol Reprod Biol*, Vol. 110, No. 2, (October 2003), pp. 215-219, ISSN 1872-7654
- Carreno, C. A.; King, M.; Johnson, M. P.; Yaron, Y.; Diamond, M. P.; Bush, D. & Evans, M. I. (2000). Treatment of heterotopic cervical and intrauterine pregnancy. *Fetal Diagn Ther*, Vol. 15, No. 1, (Jan-Feb 2000), pp. 1-3, ISSN 1421-9964
- Chang, H. J. & Suh, C. S., (2010). Ectopic pregnancy after assisted reproductive technology: what are the risk factors? *Curr Opin Obstet Gynecol*, Vol. 22, No. 3, (June 2010), pp. 202-207, ISSN 1473-656X
- Chang, Y.; Lee, J. N.; Yang, C. H.; Hsu, S. C. & Tsai, E. M. (2003). An unexpected quadruplet heterotopic pregnancy after bilateral salpingectomy and replacement of three embryos. *Fertil Steril*, Vol. 80, No. 1, (July 2003), pp. 218-220, ISSN 1556-5653

- Chen, D.; Kligman, I. & Rosenwaks, Z. (2001). Heterotopic cervical pregnancy successfully treated with transvaginal ultrasound-guided aspiration and cervical-stay sutures. *Fertil. Steril*, Vol. 75, No. 5, (May 2001), pp. 1030-1033, ISSN 1556-5653
- Chin, P. S.; Wee, H. Y. & Chern, B. S. (2010). Laparoscopic management of primary hepatic pregnancy. *Aust N Z J Obstet Gynaecol*, Vol. 50, No. 1, (February 2010), pp. 95-98, ISSN 1479-828X
- Chueh, H. Y.; Cheng, P. J.; Wang, C. W.; Shaw, S. W.; Lee, C. L. & Soong, Y. K. (2009). Ectopic twin pregnancy in cesarean scar after *in vitro* fertilization/embryo transfer: case report. *Fertil. Steril*, Vol. 90, No. 5, (November 2009), pp. 19-21, ISSN 1556-5653
- Clayton, H. B.; Schieve, L. A.; Peterson, H. B.; Jamieson, D. J.; Reynolds, M. A. & Wright, V. C. (2006). Ectopic pregnancy risk with assisted reproductive technology procedures. *Obstet Gynecol*, Vol. 107, No. 3, (March 2006), pp. 595-604, ISSN 1873-233X
- Cohen, M. A.; Lindheim, S. R. & Sauer, M. V. (1999). Hydrosalpinges adversely affect implantation in donor oocyte cycles. *Hum Reprod*, Vol. 14, No. 4, (April 1999), pp. 1087-1089, ISSN 1460-2350
- Condous, G.; Okaro, E. & Bourne, T. (2005). Pregnancies of unknown location: diagnostic dilemmas and management. *Curr Opin Obstet Gynecol*, Vol. 17, No. 6, (December 2005), pp. 568-573, ISSN 1473-656X
- Daniel, Y.; Geva, E.; Eshed-Englender, T.; Gamzu, R.; Lessing, B. J.; Bar-Am, A. & Amit, A. (2000). Vascular Cell Adhesion Molecule-1 in Normal, Failed, and Ectopic Pregnancy. *Am J Reprod Immunol*, Vol. 43, No. 2, (February 2000), pp. 92-97, ISSN 1600-0897
- De Santis, M.; Cavaliere, A. F.; Straface, G.; Carducci, B. & Caruso, A. (2005). Failure of the emergency contraceptive levonorgestrel and the risk of adverse effects in pregnancy and on fetal development: an observational cohort study. *Fertil Steril*, Vol. 84, No. 2, (August 2005), pp. 296-299, ISSN 1556-5653
- Dharia Patel, S. P.; Steinkampf, M. P.; Whitten, S. J. & Malizia, BA. (2007). Robotic tubal anastomosis: surgical technique and cost effectiveness. *Fertil Steril* Vol. 90, No. 4, (October 2008), pp. 1175-1179, ISSN 2008 1556-5653
- Dimitry, E. S.; Oskarsson, T.; Margara, R. & Winston, R. M. (1990). Heterotopic pregnancy associated with assisted reproductive technology. *Am J Obstet Gynecol*, Vol. 163, No. 1Pt1, (July 1990), pp. 244-245, ISSN 1097-6868
- Divry, V.; Hadj, S.; Bordes, A.; Genod, A. & Salle, B. (2007). Case of progressive intrauterine twin pregnancy after surgical treatment of cornual pregnancy. *Fertil. Steril*, Vol. 87, No. 1, (January 2007), pp. 190. e1-3, ISSN 1556-5653
- Dumesic, D. A.; Damario, M. A. & Session, D. R. (2001). Interstitial heterotopic pregnancy in a woman conceiving by *in vitro* fertilization after bilateral salpingectomy. *Mayo Clin Proc*, Vol. 76, No. 1, (January 2001), pp. 90-92, ISSN 1942-5546
- Duncan, W. C.; McDonald, S. E.; Dickinson, R. E.; Shaw, J. V. L.; Lourenco, P. C.; Wheelhouse, N.; Lee, K. F.; Critchley, H. O. D. & Horne, A. W. (2010). Expression of the repulsive SLIT/ROBO pathway in the human endometrium and Fallopian tube. *Molecular Human Reproduction*, Vol. 16, No. 12, (December 2010), pp. 950-959, ISSN 1460-2407
- Durston, W. E.; Carl, M. L.; Guerra, W.; Eaton, A. & Ackerson, L. M. (2000). Ultrasound availability in the evaluation of ectopic pregnancy in the ED: comparison of quality

- and cost-effectiveness with different approaches. *Am J Emerg Med*, Vol. 18, No. 4, (July 2000), pp. 408-417, ISSN 1532-8171
- Eggert, J.; Li, X. & Sundquist, K. (2008). Country of birth and hospitalization for pelvic inflammatory disease, ectopic pregnancy, endometriosis, and infertility: a nationwide study of 2 million women in Sweden. *Fertil Steril*, Vol. 90, No. 4, (October 2008), pp. 1019-1025, ISSN 1556-5653
- Fabunmi, L. & Perks, N. (2002). Caesarean section scar ectopic pregnancy following postcoital contraception. *J Fam Plann Reprod Health Care*, Vol. 28, No. 3, (July 2002), pp. 155-156, ISSN 1471-1893
- Fang, J.; Madhavan, S. & Alderman, M. H. (2000). Maternal mortality in New York City: excess mortality of black women. *J Urban Health*, Vol. 77, No. 4, (December 2000), pp. 735-744, ISSN 1468-2869
- Florio, P.; Severi, F. M.; Bocchi, C.; Luisi, S.; Mazzini, M.; Danero, S.; Torricelli, M. & Petraglia, F. (2007). Single serum activin a testing to predict ectopic pregnancy. *J Clin Endocrinol Metab*, Vol. 92, No. 5, (May 2007), pp. 1748-1753, ISSN 1945-7197
- Fruscalzo, A.; Mai, M.; Löbbeke, K.; Marchesoni, D. & Klockenbusch, W. (2008). A combined intrauterine and cervical pregnancy diagnosed in the 13th gestational week: which type of management is more feasible and successful? *Fertil. Steril*, Vol. 89, No. 2, (February 2008), pp. 456. e13-6, ISSN 1556-5653
- Fujii, M.; Mori, S.; Goto, T.; Kiya, T.; Yamamoto, H.; Ito, E. & Kudo, R. (1996). Simultaneous intra- and extra-uterine pregnancy with ovarian hyperstimulation syndrome after induction of ovulation: a case report. *J Obstet Gynaecol Res*, Vol. 22, No. 6, (December 1996), pp. 589-594, ISSN 1341-8076
- Ghosh, B.; Dadhwal, V.; Deka, D.; Ramesan, C. K. & Mittal, S. (2008). Ectopic pregnancy following levonorgestrel emergency contraception: a case report. *Contraception*, Vol. 79, No. 2, (February 2008), pp. 155-157, ISSN 1879-0518
- Gray, D. T.; Thorburn, J.; Lundorff, P.; Strandell, A. & Lindblom, B. (1995). A cost-effectiveness study of a randomised trial of laparoscopy versus laparotomy for ectopic pregnancy. *Lancet*, Vol. 345, No. 8958, (May 1995), pp. 1139-1143, ISSN 1474-547X
- Gyamfi, C.; Cohen, S.; Stone, J. L.; (2004). Maternal complication of cervical heterotopic pregnancy after successful potassium chloride fetal reduction. *Fertil. Steril*, Vol. 82, No. 4, (October 2004), pp. 940-943, ISSN 1556-5653
- Hagemann, A. R.; Lanzendorf, S. E.; Jungheim, E. S.; Chang, A. S.; Ratts, V. S. & Odem, RR. (2009). A prospective, randomized, double-blinded study of assisted hatching in women younger than 38 years undergoing *in vitro* fertilization. *Fertil Steril*, Vol. 93, No. 2, (February 2009), pp. 586-591, ISSN 1556-5653
- Han, M.; Kim, J.; Kim, H.; Je, G. & Hwang, T. (2004). Bilateral ovarian pregnancy after *in vitro* fertilization and embryo transfer in a patient with tubal factor infertility. *J Assist Reprod Genet*, Vol. 21, No. 5, (May 2004), pp. 181-183, ISSN 1573-7330
- Hassiakos, D.; Bakas, P.; Pistofidis, G. & Creatsas, G. (2002). Heterotopic pregnancy at 16 weeks of gestation after in-vitro fertilization and embryo transfer. *Arch Gynecol Obstet*, Vol. 266, No. 3, (July 2002), pp. 124-125, ISSN 1432-0711
- Horne, A. W.; Shaw, J. L. V.; Murdoch, A.; McDonald, S. E.; Williams, A. R.; Jabbour, H. N.; Duncan, W. C. & Critchley, H. O. D. (2011). Placental Growth Factor: A Promising

- Diagnostic Biomarker for Tubal Ectopic Pregnancy. *J Clin Endocrinol Metab*, Vol. 96, No. 1, (January 2011), pp. E104–E108, ISSN 1945-7197
- Hsieh, B. C.; Hwang, J. L.; Pan, H. S.; Huang, S. C.; Chen, C. Y. & Chen, P. H. (2004). Heterotopic Cesarean scar pregnancy combined with intrauterine pregnancy successfully treated with embryo aspiration for selective embryo reduction: case report. *Hum. Reprod*, Vol. 19, No. 2, (February 2004), pp. 285-287, ISSN 1460-2350
- Hsu, C. C.; Yang, T. T. & Hsu, C. T. (2005). Ovarian pregnancy resulting from cornual fistulae in a woman who had undergone bilateral salpingectomy. *Fertil Steril*, Vol. 83, No. 1, (January 2005), pp. 205-207, ISSN 1556-5653
- Hu, D.; Hook, E. W. & Goldie, S. J. (2004). Screening for Chlamydia trachomatis in women 15 to 29 years of age: a cost-effectiveness analysis. *Ann Intern Med*, Vol. 141, No. 7, (October 2004), pp. 501-513, ISSN 1539-3704
- Imudia, A. N.; Suzuki, Y.; Kilburn, B. A.; Yelian, F. D.; Diamond, M. P.; Romero, R. & Armant, D. R. (2009). Retrieval of trophoblast cells from the cervical canal for prediction of abnormal pregnancy: a pilot study. *Human Reproduction*, Vol. 24, No. 9, (September 2009), pp. 2086-2092, ISSN 1460-2350
- Irvine, L. M.; Evans, D. G. & Setchell, M. E. (1999). Ectopic pregnancies in two consecutive menstrual cycles. *J R Soc Med*, Vol. 92, No. 8, (August 1999), pp. 413-414, ISSN 1758-1095
- Ishihara, O.; Kuwahara, A. & Saitoh H. (2011). Frozen-thawed blastocyst transfer reduces ectopic pregnancy risk: an analysis of single embryo transfer cycles in Japan. *Fertil Steril*, Vol. 95, No. 6, (May 2011), pp. 1966-1969, ISSN 1556-5653
- Jozwiak, E. A.; Ulug, U.; Akman, M. A. & Bahceci, M. (2003). Successful resection of a heterotopic cervical pregnancy resulting from intracytoplasmic sperm injection. *Fertil Steril*, Vol. 79, No. 2, (February 2003), pp. 428-430, ISSN 1556-5653
- Jun, S. H. & Milki, A. A. (2007). Ectopic pregnancy rates with frozen compared with fresh blastocyst transfer. *Fertil Steril*, Vol. 88, No. 3, (September 2007), pp. 629-631, ISSN 1556-5653
- Kamath, M. S.; Aleyamma, T. K.; Muthukumar, K.; Kumar, R. M. & George, K. (2010). A rare case report: ovarian heterotopic pregnancy after *in vitro* fertilization. *Fertil Steril*, Vol. 94, No. 5, (October 2010), pp. 1910. e9-11, ISSN 1556-5653
- Karande, V. C.; Flood, J. T.; Heard, N.; Veeck, L. & Muasher, S. J. (1991). Analysis of ectopic pregnancies resulting from in-vitro fertilization and embryo transfer. *Hum Reprod*, Vol. 6, No. 3, (March 1991), pp. 446-449, ISSN 1460-2350
- Karikoski, R.; Aine, R. & Heinonen, P. K. (1993). Abnormal embryogenesis in the etiology of ectopic pregnancy. *Gynecol Obstet Invest*, Vol. 36, No. 3, (1993), pp. 158-162, ISSN 1423-002X
- Keegan, D. A.; Morelli, S. S.; Noyes, N.; Flisser, E. D.; Berkeley, A. S. & Grifo, J. A. (2007). Low ectopic pregnancy rates after *in vitro* fertilization: do practice habits matter? *Fertil Steril*, Vol. 88, No. 3, (September 2007), pp. 734-736, ISSN 1556-5653
- Kemp, B.; Kertschanska, S.; Handt, S.; Funk, A.; Kaufmann, P. & Rath, W. (1999). Different placentation patterns in viable compared with nonviable tubal pregnancy suggest a divergent clinical management. *Am J Obstet Gynecol*, Vol. 181, No. 3, (September 1999), pp. 615-620, ISSN 1097-6868
- Kemp, B.; Kertschanska, S.; Kadyrov, M.; Rath, W.; Kaufmann, P. & Huppertz, B. (2002). Invasive depth of extravillous trophoblast correlates with cellular phenotype: a

- comparison of intraand extrauterine implantation sites. *Histochem Cell Biol*, Vol. 117, No. 5, (May 2002), pp. 401-414, ISSN 1432-119X
- Kirk, E.; Condous, G.; Haider, Z.; Lu, C.; Van Huffel, S.; Timmerman, D. & Bourne, T. (2006). The practical application of a mathematical model to predict the outcome of pregnancies of unknown location. *Ultrasound Obstet Gynecol*, Vol. 27, No. 3, (March 2006), pp. 311-315, ISSN 1469-0705
- Kirk, E.; Papageorgiou A. T.; Van Calster, B.; Condous, G.; Cowans, N.; Van Huffel, S.; Timmerman, D.; Spencer, K. & Bourne, T. (2009). The use of serum inhibin A and activin A levels in predicting the outcome of 'pregnancies of unknown location'. *Hum Reprod*, Vol. 24, No. 10, (October 2009), pp. 2451-2456, ISSN 1460-2350
- Klatsky, P. C.; Lane, D. E.; Ryan, I. P. & Fujimoto, V. Y. (2007). The effect of fibroids without cavity involvement on ART outcomes independent of ovarian age. *Hum Reprod*, Vol. 22, No. 2, (February 2007), pp. 521-526, ISSN 1460-2350
- Knopman, J. M.; Talebian, S.; Keegan, D. A. & Grifo, J. A. (2007). Heterotopic abdominal pregnancy following two-blastocyst embryo transfer. *Fertil Steril*, Vol. 88, No. 5, (November 2007), pp. 1437. e13-5, ISSN 1556-5653
- Korkontzelos, I.; Tsirkas, P.; Antoniou, N.; Akrivis, C.; Tsirka, A. & Hadjopoulos, G. (2006). Mild ovarian hyperstimulation syndrome coexisting with ectopic pregnancy after *in vitro* fertilization. *Clin Exp Obstet Gynecol*, Vol. 33, No. 3, (2006), pp. 148-150, ISSN 0390-6663
- Kosmas, I. P.; Janssens, R.; De Munck, L.; Al Turki, H.; Van der Elst, J.; Tournaye, H. & Devroey, P. (2007). Ultrasound-guided embryo transfer does not offer any benefit in clinical outcome: a randomized controlled trial. *Hum Reprod*, Vol. 22, No. 5, (May 2007), pp. 1327-1334, ISSN 1460-2350
- Laskarin, G.; Redzovic, A.; Srsen Medancic, S. & Rukavina, D. (2010). Regulation of NK-cell functions by mucins via antigen-presenting cells. *Medical Hypotheses*, Vol. 75, No. 6, (December 2010), pp. 541-543, ISSN 1532-2777
- Ledger, W.; Clark, A.; Olesnick, G. & Norman, R. (1992). Life-threatening rupture of an interstitial ectopic pregnancy arising from oocyte donation: failure of early detection by quantitative human chorionic gonadotropin (hCG) and progesterone estimation. *J Assist Reprod Genet*, Vol. 9, No. 3, (June 1992), pp. 289-291, ISSN 1573-7330
- Leke, R. J.; Goyaux, N.; Matsuda, T. & Thonneau, P. F. (2004). Ectopic pregnancy in Africa: a population-based study. *Obstet Gynecol*, Vol. 103, No. 4, (April 2004), pp. 692-697, ISSN 1873-233X
- Litwicka, K.; Greco, E.; Prefumo, F.; Fratelli, N.; Scarselli, F.; Ferrero, S.; Iammarrone, E. & Frusca, T. (2011). Successful management of a triplet heterotopic caesarean scar pregnancy after *in vitro* fertilization-embryo transfer. *Fertil. Steril*, Vol. 95, No. 1, (January 2011), pp. 291. e1-3, ISSN 1556-5653
- MacRae, R.; Olowu, O.; Rizzuto, M. I. & Odejinmi, F. (2009). Diagnosis and laparoscopic management of 11 consecutive cases of cornual ectopic pregnancy. *Arch Gynecol Obstet*, Vol. 280, No. 1, (July 2009), pp. 59-64, ISSN 1432-0711
- Mantzavinos, T.; Kanakas, N. & Mavrelou, K. (1994). Ovarian pregnancies after oocyte donation in three menopausal patients treated by laparoscopy. *J Assist Reprod Genet*, Vol. 11, No. 6, (July 1994), pp. 319-320, ISSN 1573-7330


- Margalioth, E. J.; Ben-Chetrit, A.; Gal, M. & Eldar-Geva, T. (2006). Investigation and treatment of repeated implantation failure following IVF-ET. *Hum Reprod*, Vol. 21, No. 12, (December 2006), pp. 3036-3043, ISSN 1460-2350
- Milki, A. A. & Jun, S. H. (2003). Ectopic pregnancy rates with day 3 versus day 5 embryo transfer: a retrospective analysis. *BMC Pregnancy Childbirth*, Vol. 3, No. 1, (November 2003), pp. 7, ISSN 1471-2393
- Mol, B. W.; van der Veen, F. & Bossuyt, P. M. (2002). Symptom-free women at increased risk of ectopic pregnancy: should we screen? *Acta Obstet Gynecol Scand*, Vol. 81, No. 7, (July 2002), pp. 661-672, ISSN 1600-0412
- Molloy, D.; Deambrosis, W.; Keeping, D.; Hynes, J.; Harrison, K. & Hennessey, J. (1990). Multiple-sited (heterotopic) pregnancy after *in vitro* fertilization and gamete intrafallopian transfer. *Fertil Steril*, Vol. 53, No. 6, (June 1990), pp. 1068-1071, ISSN 1556-5653
- Moore, K. L.; Keriakos, R. H.; Anumba, D. O.; Connor, M. E., & Lashen, H. (2010). Management challenges of a live 12-week sub-hepatic intra-abdominal pregnancy Picaud. *BJOG*, Vol. 117, No. 3, (February 2010), pp. 365-368, ISSN 1471-0528
- Musa, J.; Daru, P. H.; Mutihir, J. T. & Ujah, I. A. (2009). Ectopic pregnancy in Jos Northern Nigeria: prevalence and impact on subsequent fertility. *Niger J Med*, Vol. 18, No. 1, (January-March 2009), pp. 35-38, ISSN 1115-2613
- Muzíková, D.; Visnová, H.; Ventruba, P. & Juránková, E. (2003). Recurrent interstitial pregnancy in uterine horn after IVF/ET. *Ceska Gynekol*, Vol. 68, No. 3, (May 2003), pp. 201-203, ISSN 1210-7832
- Nichols, C.; Koong, D.; Faulkner, K. & Thompson, G. (1995). A hepatic ectopic pregnancy treated with direct methotrexate injection. *Aust N Z J Obstet Gynaecol*, Vol. 35, No. 2, (May 1995), pp. 221-223, ISSN 1479-828X
- Nikolaou, D. S.; Lavery, S.; Bevan, R.; Margara, R. & Trew, G. (2002). Triplet heterotopic pregnancy with an intrauterine monochorionic diamniotic twin pregnancy and an interstitial pregnancy following *in vitro* fertilisation and transfer of two embryos. *J Obstet Gynaecol*, Vol. 22, No. 1, (January 2002), pp. 94-95, ISSN 1364-6893
- Nitke, S.; Horowitz, E.; Farhi, J.; Krissi, H. & Shalev, J. (2007). Combined intrauterine and twin cervical pregnancy managed by a new conservative modality. *Fertil Steril*, Vol. 88, No. 3, (September 2007), pp. 706. e1-3, ISSN 1556-5653
- Obeidat, B.; Zayed, F.; Amarin, Z.; Obeidat, N. & El-Jallad, M. F. (2010). Tubal ectopic pregnancy in the north of Jordan: presentation and management. *Clin Exp Obstet Gynecol*, Vol. 37, No. 2, (2010), pp. 138-140, ISSN 0390-6663
- Oki, T.; Douchi, T.; Nakamura, S.; Maruta, K.; Ijuin, H. & Nagata, Y. (1998). A woman with three ectopic pregnancies after in-vitro fertilization and embryo transfer. *Hum Reprod*, Vol. 13, No. 2, (February 1998), pp. 468-470, ISSN 1460-2350
- Okohue, J. E.; Ikimalo, J. I. & Omoregie, O. B. (2010). Ectopic pregnancy following *in vitro* fertilisation and embryo transfer. *West Afr J Med*, Vol. 29, No. 5, (September-October 2010), pp. 349-351, ISSN 0189-160X
- Orvieto, R.; Kruchkovich, J.; Zohav, E.; Rabinson, J.; Anteby, E. Y. & Meltzer, S. (2007). Does methotrexate treatment for ectopic pregnancy influence the patient's performance during a subsequent *in vitro* fertilization/embryo transfer cycle? *Fertil Steril*, Vol. 88, No. 6, (December 2007), pp. 1685-1686, ISSN 1556-5653

- Pacchiarotti, A.; Mohamed, M. A.; Micara, G.; Tranquilli, D.; Linari, A.; Espinola, S. M. & Aragona, C. (2007). The impact of the depth of embryo replacement on IVF outcome. *J. Assist. Reprod. Genet*, Vol. 24, No. 5, (May 2007), pp. 189-193, ISSN 1573-7330
- Pan, H. S.; Chuang, J.; Chiu, S. F.; Hsieh, B. C.; Lin, Y. H.; Tsai, Y. L.; Huang, S. C.; Hsieh, M. L.; Chen, C. Y. & Hwang, J. L. (2002). Heterotopic triplet pregnancy: report of a case with bilateral tubal pregnancy and an intrauterine pregnancy. *Hum. Reprod*, Vol. 17, No. 5, (May 2002), pp. 1363-1366, ISSN 1460-2350
- Pantos, K.; Meimetis-Damianaki, T.; Vaxevanoglou, T. & Kapetanakis, E. (1993). Oocyte donation in menopausal women aged over 40 years. *Hum Reprod*, Vol. 8, No. 3, (March 1993), pp. 488-491, ISSN 1460-2350
- Paul, P. G.; Koshy, A. K. & Thomas, T. (2006). Hum Reprod. Pregnancy outcomes following laparoscopic myomectomy and single-layer myometrial closure. Vol. 21, No. 12, (December 2006), pp. 3278-3781, ISSN 1460-2350
- Peleg, D.; Bar-Hava, I.; Neuman-Levin, M.; Ashkenazi, J. & Ben-Rafael, Z. (1994). Early diagnosis and successful nonsurgical treatment of viable combined intrauterine and cervical pregnancy. *Fertil Steril*, Vol. 62, No. 2, (August 1994), pp. 405-458, ISSN 1556-5653
- Pérez, J. A.; Sadek, M. M.; Savale, M.; Boyer, P. & Zorn, J. R. (1993). Local medical treatment of interstitial pregnancy after in-vitro fertilization and embryo transfer (IVF-ET): two case reports. *Hum Reprod*, Vol. 8, No. 4, (April 1993), pp. 631-634, ISSN 1460-2350
- Picaud, A.; Berthonneau, J. P.; Nlome-Nze, A. R.; Ogowet-Igumu, N.; Engongah-Beka, T. & Faye, A. (1991). Serology of Chlamydia and ectopic pregnancies. Incidence of Fitz-Hugh-Curtis syndrome. *J Gynecol Obstet Biol Reprod (Paris)*, Vol. 20, No. 2, (1991), pp. 209-215, ISSN 0150-9918
- Pisarska, M. D.; Casson, P. R.; Moise K. J. Jr.; DiMaio D. J.; Buster J. E. & Carson S. A., (1998). Heterotopic abdominal pregnancy treated at laparoscopy. *Fertil Steril*, Vol. 70, No. 1, (July 1998), pp. 159-160, ISSN 1556-5653
- Postma, M. J.; Bakker, A.; Welte, R.; van Bergen, J. E.; van den Hoek, J. A.; de Jong-van den Berg, L. T. & Jager, J. C. (2000). Screening for asymptomatic Chlamydia trachomatis infection in pregnancy; cost-effectiveness favorable at a minimum prevalence rate of 3% or more. *Ned Tijdschr Geneesk*, Vol. 144, No. 49, (December 2000), pp. 2350-2354, ISSN 1876-8784
- Postma, M. J.; Welte, R.; van den Hoek, J. A.; van Doornum, G. J.; Coutinho, R. A. & Jager, J. C. (1999). Opportunistic screening for genital infections with Chlamydia trachomatis in sexually active population of Amsterdam. II. Cost-effectiveness analysis of screening women. *Ned Tijdschr Geneesk*, Vol. 143, No. 13, (March 1999), pp. 677-681, ISSN 1876-8784
- Prorocic, M. & Vasiljevic, M. (2007). Treatment of heterotopic cervical pregnancy after *in vitro* fertilization-embryo transfer by using transvaginal ultrasound-guided aspiration and instillation of hypertonic solution of sodium chloride. *Fertil. Steril*, Vol. 88, No. 4, (October 2007), pp. 969. e3-5, ISSN 1556-5653
- Pyrgiotis, E.; Sultan, K. M.; Neal, G. S.; Liu, H. C.; Grifo, J. A. & Rosenwaks, Z. (1994). Ectopic pregnancies after *in vitro* fertilization and embryo transfer. *J Assist Reprod Genet*, Vol. 11, No. 2, (February 1994), pp. 79-84, ISSN 1573-7330

- Qin, L.; Li, S. & Tan, S. (2008). Laparoscopic loop ligature for selective therapy in heterotopic interstitial and intrauterine pregnancy following in-vitro fertilization and embryo transfer. *Int J Gynaecol Obstet*, Vol. 101, No. 1, (April 2008), pp. 80-81, ISSN 1879-3479
- Qublan, H.; Tahat, Y. & Al-Masri, A. (2008). Primary ovarian pregnancy after the empty follicle syndrome: a case report. *J Obstet Gynaecol Res*, Vol. 34, No. 3, (June 2008), pp. 422-424, ISSN 1341-8076
- Raziel, A.; Schachter, M.; Mordechai, E.; Friedler, S.; Panski, M. & Ron-El, R. (2004). Ovarian pregnancy-a 12-year experience of 19 cases in one institution. *Eur J Obstet Gynecol Reprod Biol*, Vol. 114, No. 1, (May 2004), pp. 92-96, ISSN 1872-7654
- Refaat, B.; Al-Azemi, M.; Geary, I.; Eley, A. & Ledger, W. (2009). Role of Activins and Inducible Nitric Oxide in the Pathogenesis of Ectopic Pregnancy in Patients with or without Chlamydia trachomatis Infection. *Clinical and Vaccine Immunology*, Vol. 16, No. 10, (October 2009), pp. 1493-1503, ISSN 1556-679X
- Revel, A.; Ophir, I.; Koler, M.; Achache, H. & Prus, D. (2008). Changing etiology of tubal pregnancy following IVF. *Hum Reprod*, Vol. 23, No. 6, (June 2008), pp. 1372-1376, ISSN 1460-2350
- Rizk, B.; Tan, S. L.; Morcos, S.; Riddle, A.; Brinsden, P.; Mason, B. A. & Edwards, R. G. (1991). Heterotopic pregnancies after *in vitro* fertilization and embryo transfer. *Am J Obstet Gynecol*, Vol. 164, No. 1 Pt 1, (January 1991), pp. 161-164, ISSN 1097-6868
- Roberts, T. E.; Robinson, S.; Barton, P. M.; Bryan, S.; McCarthy, A.; Macleod, J.; Egger, M. & Low, N. (2007). Cost effectiveness of home based population screening for Chlamydia trachomatis in the UK: economic evaluation of chlamydia screening studies (ClaSS) project. *BMJ*, Vol. 335, No. 7614, (August 2007), pp. 291, ISSN 1468-5833
- Rosman, ER.; Keegan, D. A.; Krey, L.; Liu, M.; Licciardi, F. & Grifo, J. A., (2009). Ectopic pregnancy rates after *in vitro* fertilization: a look at the donor egg population. *Fertil Steril*, Vol. 92, No. 5, (November 2009), pp. 1791-1793, ISSN 1556-5653
- Savaris, R. F.; Hamilton, A. E.; Lessey, B. A. & Giudice, L. C. (2008). Endometrial Gene Expression in Early Pregnancy: Lessons from Human Ectopic Pregnancy. *Reprod Sci*, Vol. 15, No. 8, (October 2008), pp. 797-816, ISSN 1933-7205
- Schepens, J. J.; Mol, B. W.; Wiegerinck, M. A.; Houterman, S. & Koks, C. A. (2010). Pregnancy outcomes and prognostic factors from tubal sterilization reversal by sutureless laparoscopic re-anastomosis: a retrospective cohort study. *Hum Reprod*, Vol. 26, No. 2, (February 2010), pp. 354-359, ISSN 1460-2350
- Schiøtz, H. A. & Csángó, P. A. (1991). Asymptomatic genital infection by Chlamydia trachomatis in women. A cost analysis of control check-ups. *Tidsskr Nor Laegeforen*, Vol. 111, No. 7, (March 1991), pp. 848-850, ISSN 0807-7096
- Schippert, C.; Bassler, C.; Soergel, P.; Hille, U.; Hollwitz, B. & Garcia-Rocha, G. J. (2010). Reconstructive, organ-preserving microsurgery in tubal infertility: still an alternative to *in vitro* fertilization. *Fertil Steril*, Vol. 93, No. 4, (March 2010), pp. 1359-1361, ISSN 1556-5653
- Schumacher, A.; Brachwitz, N.; Sohr, S.; Engeland, K.; Langwisch, S.; Dolaptchieva, M.; Alexander, T.; Taran, A.; Malfertheiner, S. F.; Dan Costa, S.; Zimmermann, G.; Nitschke, C.; Volk, H. D.; Alexander, H.; Gunzer, M. & Zenclussen, A. C. (2009). Human Chorionic Gonadotropin Attracts Regulatory T-Cells into the Fetal-

- Maternal Interface during Early Human Pregnancy. *J Immunol*, Vol. 182, No. 9, (May 2009), pp. 5488-5497, ISSN 1550-6606
- Seracchioli, R.; Manuzzi, L.; Vianello, F.; Gualerzi, B.; Savelli, L.; Paradisi, R. & Venturoli, S. (2006). Obstetric and delivery outcome of pregnancies achieved after laparoscopic myomectomy. *Fertil Steril*, Vol. 86, No. 1 (July 2006), pp. 159-165, ISSN 1556-5653
- Seror, V.; Gelfucci, F.; Gerbaud, L.; Pouly, J. L.; Fernandez, H.; Job-Spira, N.; Bouyer, J. & Coste, J. (2007). Care pathways for ectopic pregnancy: a population-based cost-effectiveness analysis. *Fertil Steril*, Vol. 87, No. 4, (April 2007), pp. 737-748, ISSN 1556-5653
- Shah, A. A.; Grotegut, C. A.; Likes, C. E.; Miller, M. J. & Walmer, D. K. (2009). Heterotopic cervical pregnancy treated with transvaginal ultrasound-guided aspiration resulting in cervical site varices within the myometrium. *Fertil Steril*, Vol. 91, No. 3, (March 2009), pp. 934. e19-22, ISSN 1556-5653
- Shao, R.; Nutu, M.; Weijdegard, B.; Egecioglu, E.; Fernandez-Rodriguez, J.; Karlsson-Lindah, L.; Gemzell-Danielsson, K.; Bergh, C. & Billig, H. (2009). Clomiphene Citrate Causes Aberrant Tubal Apoptosis and Estrogen Receptor Activation in Rat Fallopian Tube: Implications for Tubal Ectopic Pregnancy. *Biol Reprod*, Vol. 80, No. 6, (June 2009), pp. 1262-1271, ISSN 1529-7268
- Shih, C. C.; Lee, R. K. & Hwu, Y. M. (2007). Cul-de-sac pregnancy following *in vitro* fertilization and embryo transfer. *Taiwan J Obstet Gynecol*, Vol. 46, No. 2, (June 2007), pp. 171-173, ISSN 1875-6263
- Shukla, V. K.; Pandey, S.; Pandey, L. K.; Roy, S. K. & Vaidya, M. P. (1985). Primary hepatic pregnancy. *Postgrad Med J*, Vol. 61, No. 719, (September 1985), pp. 831-832, ISSN 1469-0756
- Srivastava, P.; Jha, R.; Bas, S.; Salhan S. & Mitta, A. (2008). In infertile women, cells from Chlamydia trachomatis infected site release higher levels of interferon-gamma, interleukin-10 and tumor necrosis factor-alpha upon heat shock protein stimulation than fertile women. *Reprod Biol Endocrinol*, Vol. 6, No. 20, (May 2008), ISSN 1477-7827
- Sziller, I.; Fedorcsak, P.; Csapo, Z.; Szirmai, K.; Linhares, I. M.; Papp, Z. & Witkin, S. S. (2008). Circulating Antibodies to a Conserved Epitope of the Chlamydia Trachomatis 60-kDa Heat Shock Protein is Associated with Decreased Spontaneous Fertility Rate in Ectopic Pregnant Women Treated by Salpingectomy. *Am J Reprod Immunol*, Vol. 59, No. 2, (February 2008), pp. 99-104, ISSN 1600-0897
- Tan, H. H. & Loh, S. F. (2010). Microsurgical reversal of sterilisation - is this still clinically relevant today? *Ann Acad Med Singapore*, Vol. 39, No. 1 (January 2010), pp. 22-26, ISSN 0304-4602
- Toikkanen, S., Joensuu, H. & Erkkola, R. (1993). DNA aneuploidy in ectopic pregnancy and spontaneous abortions. *Eur J Obstet Gynecol Reprod Biol*, Vol. 51, No. 1, (September 1993), pp. 9-13, ISSN 1872-7654
- Toth, M.; Patton, D. L.; Campbell, L. A.; Carretta, E. I.; Mouradian, J.; Toth, A.; Shevchuk, M.; Baergen, R. & Ledger, W. (2000). Detection of Chlamydial Antigenic Material in Ovarian, Prostatic, Ectopic Pregnancy and Semen Samples of Culture-Negative Subjects. *Am J Reprod Immunol*, Vol. 43, No. 4, (April 2000), pp. 218-222, ISSN 1600-0897

- Trachtenberg, A. I.; Washington, A. E. & Halldorson, S. (1988). A cost-based decision analysis for Chlamydia screening in California family planning clinics. *Obstet Gynecol*, Vol. 71, No. 1 (January 1988), pp. 101-108, ISSN 1873-233X
- van der Weiden, R. M. & Karsdorp, V. H. (2005). Recurrent cornual pregnancy after heterotopic cornual pregnancy successfully treated with systemic methotrexate. *Arch Gynecol Obstet*, Vol. 273, No. 3, (December 2005), pp. 180-181, ISSN 1432-0711
- van Valkengoed, I. G.; Postma, M. J.; Morré, S. A.; van den Brule, A. J.; Meijer, C. J.; Bouter, L. M. & Boeke, A. J. (2001). Cost effectiveness analysis of a population based screening programme for asymptomatic Chlamydia trachomatis infections in women by means of home obtained urine specimens. *Sex Transm Infect*, Vol. 77, No. 4, (August 2001), pp. 276-282, ISSN 1472-3263
- Vimercati, A.; Scioscia, M.; Lorusso, F.; Laera, A. F.; Lamanna, G.; Coluccia, A.; Bettocchi, S.; Selvaggi, L. & Depalo, R. (2007). Do uterine fibroids affect IVF outcomes? *Reprod Biomed Online*, Vol. 15, No. 6, (December 2007), pp. 686-691, ISSN 1472-6491
- von Rango, U.; Classen-Linke, I.; Raven, G.; Bocken, F. & Beier, H. M. (2003). Cytokine microenvironments in human first trimester decidua are dependent on trophoblast cells. *Fertil Steril*, Vol. 79, No. 5, (May 2003), pp. 1176-1186, ISSN 1556-5653
- Wang, C. J.; Tsai, F.; Chen, C. & Chao, A. (2010). Hysteroscopic management of heterotopic cesarean scar pregnancy. *Fertil Steril*, Vol. 94, No. 4, (September 2010), pp. 1529. e15-8, ISSN 1556-5653
- Wang, C. N.; Chen, C. K.; Wang, H. S.; Chiueh, H. Y. & Soong, Y. K. (2007). Successful management of heterotopic cesarean scar pregnancy combined with intrauterine pregnancy after *in vitro* fertilization-embryo transfer. *Fertil Steril*, Vol. 88, No. 3, (September 2007), pp. 706. e13-6, ISSN 1556-5653
- Wicherek, L.; Basta, P.; Pitynski, K.; Marianowski, P.; Kijowski, J.; Wiatr, J. & Majka, M. (2009). The Characterization of the Subpopulation of Suppressive B7H4⁺ Macrophages and the Subpopulation of CD25⁺ CD4⁺ and FOXP3⁺ Regulatory T-cells in Decidua during the Secretory Cycle Phase, Arias Stella Reaction, and Spontaneous Abortion – A Preliminary Report. *Am J Reprod Immunol*, Vol. 61, No. 4, (April 2009), pp. 303-312, ISSN 1600-0897
- Yanaihara, A.; Yorimitsu, T.; Motoyama, H.; Ohara, M. & Kawamura, T. (2008). Clinical outcome of frozen blastocyst transfer; single vs. double transfer. *J Assist Reprod Genet*, Vol. 25, No. 11-12, (November-December 2008), pp. 531-534, ISSN 1573-7330
- Yang, X. Y.; Yu, H.; Li, K. M.; Chu, Y. X. & Zheng, A. (2010). Uterine artery embolisation combined with local methotrexate for treatment of caesarean scar pregnancy. *BJOG*, Vol. 117, No. 8, (July 2010), pp. 990-996, ISSN 1471-0528
- Yao, M.; Tulandi, T.; Kaplow, M. & Smith, A. P. (1996). A comparison of methotrexate versus laparoscopic surgery for the treatment of ectopic pregnancy: a cost analysis. *Hum Reprod*, Vol. 11, No. 12, (December 1996), pp. 2762-2766, ISSN 1460-2350



Ectopic Pregnancy - Modern Diagnosis and Management

Edited by Dr. Michael Kamrava

ISBN 978-953-307-648-5

Hard cover, 248 pages

Publisher InTech

Published online 26, October, 2011

Published in print edition October, 2011

Ectopic pregnancy is the second major cause of maternal mortality in the United States and a leading cause of maternal morbidity and mortality in the world. This book contains the practical methods to early diagnosis of various forms of ectopic pregnancies and their modern management. Ectopic Pregnancy - Modern Diagnosis and Management is a comprehensive book which guides the reader through all features of ectopic pregnancy, both practical and academic, covering all aspects of diagnosis and management of ectopic pregnancy in a clear, concise, and practical fashion. The book is organized so that it can either be read cover to cover for a comprehensive tutorial or be kept desk side as a reference to the ectopic pregnancies. Each chapter introduces a number of related ectopic pregnancy and its diagnosis, treatment and co-morbidities supported by examples. Included chapters bring together valuable materials in the form of extended clinical knowledge from practice to clinic features.

How to reference

In order to correctly reference this scholarly work, feel free to copy and paste the following:

Anastasia Velalopoulou, Dimitrios Peschos, Mynbaev Ospan, Eliseeva Marina, Ioannis Verginadis, Yannis Simos, Tsirkas Panagiotis, Spyridon Karkabounas, Vicky Kalfakakou, Angelos Evangelou and Ioannis P. Kosmas (2011). Ectopic Pregnancy and Assisted Reproductive Technologies: A Systematic Review, Ectopic Pregnancy - Modern Diagnosis and Management, Dr. Michael Kamrava (Ed.), ISBN: 978-953-307-648-5, InTech, Available from: <http://www.intechopen.com/books/ectopic-pregnancy-modern-diagnosis-and-management/ectopic-pregnancy-and-assisted-reproductive-technologies-a-systematic-review>

INTeCH
open science | open minds

InTech Europe

University Campus STeP Ri
Slavka Krautzeka 83/A
51000 Rijeka, Croatia
Phone: +385 (51) 770 447
Fax: +385 (51) 686 166
www.intechopen.com

InTech China

Unit 405, Office Block, Hotel Equatorial Shanghai
No.65, Yan An Road (West), Shanghai, 200040, China
中国上海市延安西路65号上海国际贵都大饭店办公楼405单元
Phone: +86-21-62489820
Fax: +86-21-62489821

© 2011 The Author(s). Licensee IntechOpen. This is an open access article distributed under the terms of the [Creative Commons Attribution 3.0 License](https://creativecommons.org/licenses/by/3.0/), which permits unrestricted use, distribution, and reproduction in any medium, provided the original work is properly cited.

IntechOpen

IntechOpen