

# We are IntechOpen, the world's leading publisher of Open Access books Built by scientists, for scientists

6,900

Open access books available

185,000

International authors and editors

200M

Downloads

Our authors are among the

154

Countries delivered to

TOP 1%

most cited scientists

12.2%

Contributors from top 500 universities



WEB OF SCIENCE™

Selection of our books indexed in the Book Citation Index  
in Web of Science™ Core Collection (BKCI)

Interested in publishing with us?  
Contact [book.department@intechopen.com](mailto:book.department@intechopen.com)

Numbers displayed above are based on latest data collected.  
For more information visit [www.intechopen.com](http://www.intechopen.com)



# Myocarditis Presenting with Ventricular Arrhythmias: Role of Electroanatomical Mapping-Guided Endomyocardial Biopsy in Differential Diagnosis

Maurizio Pieroni, Costantino Smaldone and Fulvio Bellocchi  
*Cardiology Department, Catholic University of the Sacred Heart,  
 Rome,  
 Italy*

## 1. Introduction

Myocarditis is defined as a disease characterized by myocardial inflammation associated with myocyte necrosis. It can be caused by infections, autoimmune response primarily affecting the myocardium or by systemic autoimmune or inflammatory disorders (Aretz et al., 1986). Viral infections are the most frequent cause and account for the vast majority of cases in North America and Europe (Cooper, 2009).

Cardiac symptoms that develop during myocarditis may follow after a delay of days to weeks from the beginning of the pathological process; they are quite unspecific and include fatigue, dyspnoea, palpitations, malaise and atypical chest discomfort. Even the clinical cardiac signs may be vague in many patients and generally include cardiac murmurs, gallop rhythms and other signs of heart failure and sometimes pericardial rubs when the pericardium is also involved in the inflammatory process. Myocarditis is often associated with various types of ECG abnormalities (including bundle branch blocks, Q waves resembling those related to myocardial infarction, repolarization abnormalities and QRS prolongation) and rhythm disturbance such as atrio-ventricular blocks, supraventricular tachycardias and ventricular ectopies and tachycardias. Echocardiography may reveal overt systolic dysfunction or a reduction of peak systolic velocities at TDI; moreover, regional wall motion abnormalities and diastolic dysfunction may be found (Cooper, 2009; Feldman et al. 2000). Therefore, this disease should always be considered in patients who present with rapidly progressive cardiomyopathy, chest pain with ECG anomalies that mimic an acute coronary syndrome but with normal coronary arteries or idiopathic ventricular arrhythmias. Furthermore, in young people myocarditis may be frequently responsible for sudden cardiac death, particularly after strenuous physical exertion (Doolan et al., 2004; Corrado D et al. 2001). With this regard it should be highlighted that the recognition of myocarditis in patients presenting with aborted sudden death or major ventricular arrhythmias is actually challenging in everyday clinical practice, as the diagnosis may be difficult and may require the use of invasive procedures. Nevertheless, the detection of myocarditis in patients presenting with ventricular arrhythmias may have a pivotal importance, because the

identification of myocarditis as the substrate of arrhythmias is actually important for targeting therapies.

In the last decades the development of new diagnostic techniques, in particular cardiac magnetic resonance, has led to an increased recognition of myocarditis as a cause of ventricular arrhythmias. However endomyocardial biopsy still represents the gold standard for the diagnosis of myocarditis. The main criticism against a wider use of endomyocardial biopsy in the diagnostic approach to patients with ventricular arrhythmias is represented by the possible sampling error in the presence of a focal myocarditis. We recently demonstrated that three dimensional electroanatomical mapping (3D-EAM) may guide endomyocardial biopsy identifying the segments of ventricular wall presenting an abnormal voltage, thus reducing sampling error and increasing sensitivity of biopsy. The systematic association of endomyocardial biopsy with electroanatomical mapping represents a significant improvement of the diagnostic tools available to identify the substrate of ventricular arrhythmias.

In this chapter we describe the role of electroanatomical mapping-guided endomyocardial biopsy in the differential diagnosis of myocardial pathological substrates in patients with ventricular arrhythmias. We report the results of our group and other groups adopting this technique in different categories of patients, including subjects with a clinical diagnosis of arrhythmogenic right ventricular cardiomyopathy (ARVC), competitive athletes and patients with electrocardiographic diagnosis of Brugada syndrome.

## 2. Myocarditis and ventricular arrhythmias

Endomyocardial biopsy and autopsy findings have clearly demonstrated that myocarditis represents a frequent cause of life-threatening ventricular arrhythmias and sudden death. Post-mortem studies suggest that myocarditis is a major cause of sudden, unexpected death in adults less than 40 years of age (accounting for approximately 20% of cases - Fabre & Sheppard, 2006; Doolan et al., 2004). Indeed myocarditis may frequently cause ventricular arrhythmias associated with systolic dysfunction of left or right ventricle or both. In both its acute and chronic phase myocarditis may be associated with severe arrhythmias that can significantly affect the natural course of the disease, as they can further contribute to the deterioration of cardiac systolic and diastolic function and can be the ultimate cause of death in these patients (Magnani et al. 2006; Zeppenfeld et al. 2007; Graner et al, 2007). Mechanisms of arrhythmogenesis in the context of myocarditis include myocyte necrosis, replacement fibrosis (favoring re-entry mechanism), proarrhythmic effects of cytokines and inflammatory mediators possibly through a modulation of ion channel function.

In patients with chronic active myocarditis, the perpetuation of inflammation is often related to viral persistence or to autoimmune self-maintaining mechanisms, and replacement fibrosis seems to represent a major arrhythmogenic substrate in this case, together with the permanence of an inflammatory milieu surrounding myocardiocytes. Moreover it has been demonstrated that enteroviral persistence perpetrates myocardial damage even in the absence of overt myocardial inflammation, through the release of proteases capable of cleaving dystrophin (Andreoletti et al., 2007). This in turns causes cytoskeletal anomalies that can affect myocyte mechanical and even electric properties and finally lead to myocyte death, possibly contributing to arrhythmogenesis.

Myocarditis may be the cause of ventricular arrhythmias even in subjects with no previous symptoms or presenting with an apparently normal heart or minimal electrocardiographic

and cardiac structural abnormalities (Theleman et al., 2001; Friedman et al., 1994). Subtle abnormalities not detectable by first-line examinations such as echocardiography may be present in patients with myocarditis presenting with ventricular arrhythmias. Other imaging modalities such as cardiac magnetic resonance (CMR) and even ventricular angiography are generally needed to detect these abnormalities. In a study published in 2001 we found small aneurysms at ventricular angiography in patients with apparently idiopathic major ventricular arrhythmias; it should be underlined that all the patients enrolled in this study were also submitted to CMR that failed to detect microaneurysms in most patients (It is possible that currently used cine-sequences for functional analysis of both ventricles may enhance the diagnostic performance of CMR even in this setting). Histological examination of myocardial samples drawn from areas surrounding the aneurysms revealed the presence of active lymphocytic myocarditis with intense myocytolysis. Notably, no patient suffered from cardiac sudden death or malignant ventricular arrhythmias during a 1-year follow-up and sequential Holter recording showed progressive reduction of the arrhythmic burden. Furthermore neither heart failure episodes nor decrease of LV function were reported in the study population (Chimenti et al., 2001). Under this respect it should be noticed that inflammatory microaneurysms were also found in experimental animal models of myocarditis, namely in hamster and mice which survived to acute viral myocarditis, and they seem to cause electroanatomical abnormalities that are associated with development of severe ventricular arrhythmias; interestingly, in the inoculated animals the prognosis associated with the development of microaneurysms in the setting of experimental viral myocarditis was good with a survival similar to normal animals who had no aneurysms (Hoschino et al., 1984; Matsumori et al 1983).

Myocarditis may selectively affect the right ventricle causing structural abnormalities, including microaneurysms, and arrhythmic manifestations typical of arrhythmogenic right ventricular cardiomyopathy. In fact myocardial inflammatory infiltrates associated with myocyte necrosis and replacement fibrosis, may lead to functional and structural changes of right ventricular myocardium resembling those produced by fibrofatty replacement, and representing the substrate of abnormal voltage map and ventricular arrhythmias (Hoffmann et al, 1993; Pieroni et al., 2009). Namely, our group demonstrated that biopsy-proven myocarditis is present in up to 50% of patients fulfilling current diagnostic criteria of arrhythmogenic right ventricular cardiomyopathy at non-invasive evaluation (including cardiac magnetic resonance), moreover myocarditis was associated to the presence of low-voltage areas, as detected by 3D electro-anatomic mapping (Pieroni et al., 2009). Consistently it has been recently reported that also right ventricular sarcoidosis may mimic electroanatomic mapping features and arrhythmic presentation of arrhythmogenic right ventricular cardiomyopathy (Ott et al., 2003; Koplan et al. 2006; Vaisawala et al., 2009).

Myocarditis represents a frequent cause of ventricular arrhythmias also in competitive athletes and its recognition and differential diagnosis with other cardiomyopathies with different prognosis may have important implications for sport eligibility (Basso C et al., 2007). In fact, a recent study by our group demonstrated the presence of myocarditis, diagnosed by endomyocardial biopsy, in most elite athletes presenting with major arrhythmias and apparently normal heart. Moreover it should be emphasized that according to current diagnostic recommendations (the 2<sup>nd</sup> consensus document on Brugada Syndrome underlined the need to exclude other pathological conditions), the presence of a myocarditis should be always excluded in patients with electrocardiographic features leading to the diagnosis of Brugada syndrome. Among the pathologic conditions that can lead to a

Brugada-like phenotype, myocarditis of the right ventricle is one of the most frequently found when patients with Brugada syndrome are submitted to an extensive invasive and non-invasive evaluation (Frustaci et al., 2005; Okubo et al., 2010). In fact, a study on 18 patients with Brugada Syndrome (diagnosed according to the consensus criteria) presenting with sustained ventricular arrhythmias or syncope, revealed the presence of biopsy-proven myocarditis in most patients (Frustaci et al., 2005). The complex links between myocarditis and genetically determined arrhythmic disorders is further discussed below in this chapter. Various studies on experimental animal models contributed to demonstrate that both autoimmune and viral myocarditis may cause major ventricular arrhythmia. Studies on murine models of myocarditis demonstrated that persistence of inflammation after the acute phase is associated with electrical abnormalities associated with ventricular arrhythmias; interestingly, a close correlation between the location of inflammatory burden (associated with myocyte necrosis), the reported electric abnormalities and the site of origin of arrhythmias was found (Kishimoto et al., 1983; Hoshino et al., 1982;). The major mechanisms involved in the genesis of arrhythmias seems to be the formation of micro-reentry circuits, favored by myocyte injury and replacement fibrosis, and triggered activity mainly due to the pro-arrhythmic effects of cytokines. Moreover it was reported that the environment surrounding myocytes could influence the electrophysiological properties of the myocardium, this phenomenon is known as electrical remodeling. As previously pointed out the inflammatory process of the myocardium may itself be arrhythmogenic, nonetheless the change in the electrophysiological properties of the myocytes seems also play a role in causing the arrhythmias. Changes in expression of surface ion channels, as assessed by quantitative determination of mRNA expression, have been demonstrated in animal experimental models of both viral and autoimmune myocarditis; these changes, affecting mainly potassium and calcium channels, causes modification of the ventricular effective refractory period, which appear to be longer in myocarditis, an increase in monofasic action potential duration of the ventricular myocardium and an augment of ventricular vulnerability that ultimately favors the genesis of ventricular arrhythmias (Saito et al., 2006). Interestingly, some data suggests that these changes may be transient and can reverse after the healing of the inflammatory process. Altogether, these data further support the hypothesis that active inflammation represents a major substrate of ventricular arrhythmias and suggests that pro-arrhythmic changes of myocardial electrical properties caused by the inflammation might be, completely or partially, reversed after the healing of the inflammatory process.

## **2.1 Myocarditis and sudden arrhythmic death**

In the last decades myocarditis has emerged as an important cause of sudden arrhythmic death also in patients with a structurally and functionally normal heart. The most striking evidence that myocarditis may be the substrate of sudden arrhythmic death is represented by a study on Air Force recruits victims of cardiac sudden death in which myocarditis was recognized as the cause of death in 40% of cases (Phillips et al., 1986)

Although no data on cardiac function before death were available in the study, the percentage of cases in which myocarditis was observed at necropsy studies indicates the high arrhythmic risk related to myocarditis. In more recent studies the percentage of myocarditis detected at necropsy in subjects with sudden arrhythmic death and an apparently normal heart ranged from 5 to 12% (Doolan et al., 2004; Thelemann et al., 2001).



In a study performed in our Institution in 1994 seventeen young patients (10 males and 7 females, aged 14 to 38 years, mean 26.4) without overt organic heart disease, who had been resuscitated from sudden cardiac arrest were submitted to noninvasive (electrocardiography, 2D-echocardiography, and magnetic resonance imaging) and invasive (coronary angiography with ergonovine testing, electrophysiologic study and biventricular angiography and endomyocardial biopsy) cardiac studies. Six to 8 biopsy fragments per patient were processed for histology and electron microscopy and read by a pathologist blinded to clinical data. Two groups of patients were distinguished by invasive and noninvasive examinations: Group 1 consisted of 9 patients with entirely normal parameters; Group 2 consisted of 8 patients with structural, nonspecific cardiac abnormalities. In this latter group, mild to moderate dilatation and hypokinesia of the left ventricle were documented in 4 patients, concentric left ventricular hypertrophy was seen in three patients, and RV dysfunction was noted in 1 patient. Histologic examination was abnormal in all patients and revealed specific lesions in 65% of them; in particular an active myocarditis was diagnosed in 6 out of 9 patients in the Group 1. In these 6 patients immunosuppressive therapy (steroids plus azathioprine) administered on top of conventional antiarrhythmic treatment led to disappearance of ventricular arrhythmias and healing of myocardial inflammation at follow-up endomyocardial biopsies (Frustaci et al., 1994). Similarly in a study from the Padua group in a series of 273 sudden cardiac deaths victims, 76 cases (28%) presented a macroscopically normal heart: of these 60 (79%) had abnormal histology with a 36% of cases of active myocarditis (Corrado et al., 2001). These data suggest that myocarditis represents an important, frequently unrecognized and underestimated, cause of sudden arrhythmic death. Moreover these studies dramatically demonstrate that sudden arrhythmic death may represent the very first clinical manifestation of myocarditis. Accordingly the consensus document based on the two main registries on sudden arrhythmic death (the UCARE, Unexplained Cardiac Arrest Registry of Europe and the IVF-US, Idiopathic Ventricular Fibrillation Registry of United States) includes myocarditis among the subclinical disorders that may cause sudden death (UCARE, 1997).

It should be also emphasized that myocarditis is a cause of sudden arrhythmic death even in competitive athletes, more frequently exposed to viral infections of upper airways. With this regard it has been claimed but never conclusively demonstrated that exercise in the context of an active myocarditis may represent a further arrhythmic trigger.

### **2.1.1 Myocarditis and genetically determined arrhythmic syndromes**

In the last decades several studies suggested a role for myocardial inflammation in the pathogenesis of different genetically determined arrhythmic syndromes and cardiomyopathies. In the presence of gene mutations leading to abnormal structure and/or function of structural and functional proteins, myocardial inflammation may act as a mechanism of myocardial damage, amplifying the dysfunction related to the genetic abnormalities, or rather as trigger of specific clinical manifestations, such as arrhythmias, occurring later in the natural history of the disease. Myocardial inflammation has been observed in necropsy and endomyocardial biopsy studies in genetically determined myocardial disorders, including ARVC, Brugada syndrome and hypertrophic cardiomyopathy.

In ARVC myocardial inflammation may be seen in up to 75% of hearts at autopsy, and probably it plays a role in triggering ventricular tachyarrhythmias (Thiene et al., 2001). Nobody knows whether inflammation is a reactive phenomenon to cell death, or whether it

is the consequence of an infection or immune mechanism. Viruses have been detected in the myocardium of some ARVC patients and have been claimed to support an infective etiology of the disease (Bowles et al., 2002). Others say that the viruses are innocent bystanders or that spontaneous cell degeneration may serve as a milieu favoring viral settlement in the myocardium (Calabrese et al., 2006). In addition we and others demonstrated that myocarditis may present with clinical and arrhythmic features and structural right ventricular abnormalities resembling those observed in ARVC. (Chimenti et al., 2004; Pieroni et al., 2009).

With regard to Brugada syndrome we studied 18 consecutive patients with clinical phenotype of Brugada syndrome and normal cardiac structure and function on noninvasive examinations. Clinical presentation was ventricular fibrillation in 7 patients, sustained polymorphic ventricular tachycardia in 7, and syncope in 4. All patients underwent cardiac catheterization, coronary and ventricular angiography, biventricular endomyocardial biopsy, and DNA screening of the *SCN5A* gene. Biopsy samples were processed for histology, electron microscopy, and molecular screening for viral genomes. In 14 patients histology showed a prevalent or localized right ventricular myocarditis, arrhythmogenic right ventricular cardiomyopathy in 1 patient and cardiomyopathic changes in 3. In the latter 4 patients genetic studies identified *SCN5A* gene mutations causing in vitro abnormal function of mutant proteins. In these patients, myocyte cytoplasm degeneration and a significant increase of apoptotic myocytes in right and left ventricle versus normal controls were observed (Frustaci et al., 2005). This study highlighted the complexities between the clinical manifestations of Brugada syndrome, the presence of *SCN5A* mutations, and the presence of structural heart disease and provided striking new evidence implicating myocarditis in the transient development of Brugada-like ECG abnormalities and arrhythmias.

However it still remains unclear whether myocardial inflammation may be part of the structural changes following an abnormal ion channel function, or rather right ventricular myocarditis may mimic ECG and arrhythmic features of Brugada syndrome. Further studies combining genetic analysis and accurate pathology studies are needed to clarify the complex menage a trois between abnormal gene function (whether affecting desmosomal or ion channel proteins), myocardial inflammation and inherited arrhythmic syndromes.

Myocarditis has been also observed in patients with hypertrophic cardiomyopathy and severe arrhythmic manifestations, suggesting that inflammation may act as a trigger for life-threatening ventricular arrhythmias when affecting a myocardium already prone to electrical instability (Frustaci et al., 2007). Even in this context it is not clear whether myocardial inflammation was the result of a reactive process related to ischemic myocyte necrosis or rather a superimposed autoimmune or viral process.

### **3. The diagnosis of myocarditis in patients with ventricular arrhythmias**

Myocardial inflammation represents a potent pro-arrhythmic substrate, myocarditis should always be taken into account when facing with ventricular arrhythmias. Furthermore the detection of myocarditis as the pathological substrate underlying ventricular arrhythmias may be crucial as the identification of myocarditis as the etiology of the arrhythmias is actually important for targeting therapies and may have implications even for patients' relatives as discussed below in the chapter. In the last decades the development of new imaging techniques, in particular CMR, led to an increased recognition of myocarditis as a cause of ventricular arrhythmias.

### 3.1 Cardiac magnetic resonance

Cardiac Magnetic resonance offers a combination of clarity of anatomical visualization, interobserver consistency and quantitative accuracy, even when evaluating the right ventricle, which enables to overcome the major pitfalls of echocardiography. Furthermore it is characterized by the unique feature of providing some degree of tissue characterization, thus allowing to obtain non-invasively information about the presence of necrosis, fibrosis and edema. Nonetheless CMR has some limitations due to the technical difficulty in obtaining good images in patients with arrhythmias that cause high variability of cardiac cycle length and also due to safety issues related to the presence of cardiac rhythm devices. Recently a panel of international experts on CMR has published a white paper in which imaging protocols and diagnostic criteria are defined that should be used in the setting of myocarditis. According to this consensus (Friedrich et al., 2009), a diagnosis of myocarditis can be set when at least two of the following features are present: one area of non-ischemic (i.e. sparing of sub-endocardial layers of the myocardium and/or distribution of areas not consistent with coronary perfusion territories) late gadolinium enhancement (consistent with myocyte injury and scarring), global or regional signal increase in T2-weighted images (indicative of tissue oedema) and global early gadolinium enhancement (consistent with hyperemia) (Figure 1).

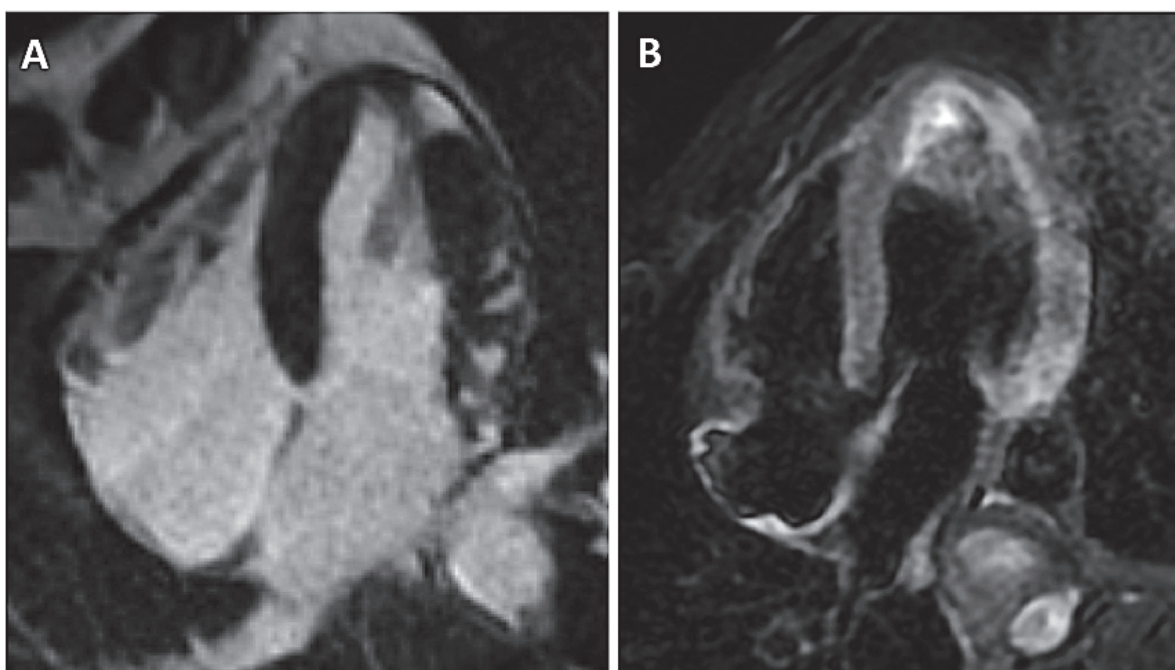


Fig. 1. Diagnosis of myocarditis through CMR in a patient with sustained ventricular arrhythmias. Evidence of spotty areas of sub-epicardial and midwall late enhancement (non-ischemic pattern) in the lateral wall (A), associated with areas of edema (high signal intensity on T2-weighted images) in the same location (B). The presence of both late enhancement and edema fulfils the criteria proposed by the consensus document.

In many studies CMR has demonstrated to be useful for the assessment of the presence of pathological substrates underlying ventricular arrhythmias. Its use allowed to detect the presence of structural cardiomyopathies including myocarditis (Ordovas et al. 2008) in up to 30% of patients. Clinical studies specifically addressing the diagnostic yield of CMR in the



setting of myocarditis presenting with either arrhythmia or heart failure reported a sensitivity and specificity of more than up to 90% (Mahrholdt et al., 2004). Moreover, CMR was able to differentiate active from healing inflammation in patients presenting with chronic myocarditis.

In particular, De Cobelli and colleagues studied patients presenting with chronic myocarditis assessed with EMB and CMR; they found areas of high signal intensity in T2-weighted images in 36% of patients with histological evidence of active myocarditis, but not in patients with borderline myocarditis. They also found areas of late gadolinium enhancement in 84% and 44% of patients with active and borderline myocarditis, respectively. A midwall pattern of late enhancement was a frequent finding in patients with both active myocarditis and borderline myocarditis, whereas a subepicardial pattern was only observed in patients with histological evidence of active myocarditis (De Cobelli et al., 2004). Taken together, these data support the need to include sequences for the detection of myocardial inflammation when CMR is performed in the non-invasive diagnostic work-up of patients presenting with ventricular arrhythmias (Figure 2). In addition CMR represents an important noninvasive tool in the follow-up of patients with a diagnosis of myocarditis.

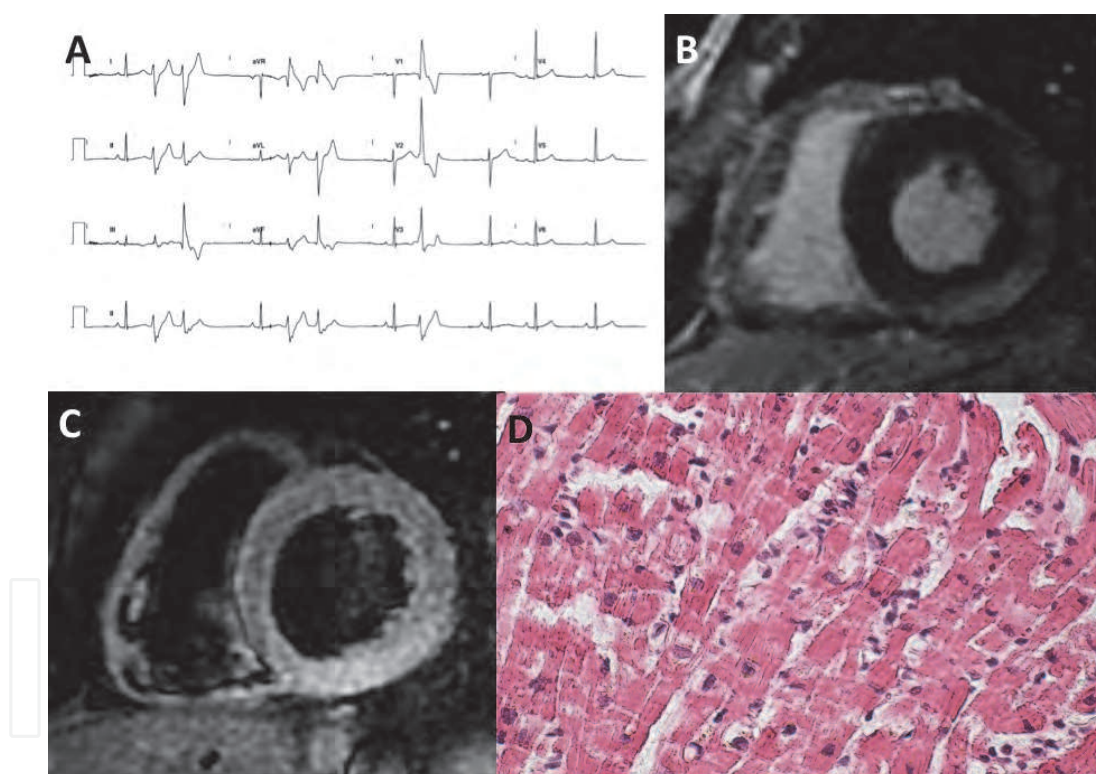


Fig. 2. CMR findings in a patient with chronic myocarditis presenting with ventricular arrhythmias. ECG shows repetitive polymorphic ventricular ectopic beats (A). CMR shows sub-epicardial late enhancement in the posterior and postero-lateral walls (B) and transmurular edema in the same location (C). Histology shows the presence of active myocarditis (D).

### 3.2 Endomyocardial biopsy

Despite the improvement of imaging techniques, endomyocardial biopsy still represents the gold standard for the diagnosis of myocarditis as allow the recognition and the

characterization of the myocardial inflammatory process, the assessment of myocyte necrosis and fibrosis as well as the possible detection of viral genomes.

A recent statement from AHA/ACC/ESC (Cooper et al., 2007) aimed to define the role of endomyocardial biopsy in the management of cardiovascular disease, identified 14 clinical scenarios in which the incremental diagnostic, prognostic and therapeutic value of endomyocardial biopsy could be estimated and compared with the procedural risks. According to this statement, in the absence of randomized clinical trials or multicenter studies, endomyocardial biopsy may be considered in the setting of unexplained ventricular arrhythmias (Clinical scenario 13) only in exceptional cases in which the perceived likelihood of meaningful prognostic and therapeutic benefit outweighs the procedural risks (Class of recommendation IIb, Level of evidence C).

Nevertheless there is growing evidence that endomyocardial biopsy may be crucial to clarify the pathological substrate and therefore the cause of otherwise unexplained ventricular arrhythmias, with a possible impact on both treatment and prognosis as detailed further in this chapter.

Accordingly a recent document from the Italian federation of Cardiology (Leone et al., 2009) suggested indications to endomyocardial biopsy different from the above-mentioned statement, in particular with regard to patients with ventricular arrhythmias. The authors graded clinical indications according to the following scheme:

- Grade 1: there are no alternative tools to obtain a definite diagnosis and the clinical implications of diagnosis are certain.
- Grade 2A: there are no alternative tools to obtain a definite diagnosis and the clinical implications of diagnosis are uncertain.
- Grade 2B: there are no alternative tools to obtain a definite diagnosis but the diagnosis has scientific but no clinical implications.
- Grade 3: there are alternative tools to obtain a definite diagnosis.

According to this grading, taking into account the potential diagnostic usefulness of endomyocardial biopsy in different myocardial disorders, the authors identified several clinical scenarios. In the presence of sustained and/or life-threatening ventricular arrhythmias, when a myocarditis is suspected or is a possible diagnosis, the grade of recommendation to perform endomyocardial biopsy is 1. Similarly in the presence of AV blocks associated with a clinical context consistent with a diagnosis of myocarditis, recommendations are Grade 2A and 2B in the presence or in the absence of left ventricular dysfunction respectively. Therefore the Italian Federation of Cardiology document seems to more adequately address the diagnostic and therapeutic issues that are frequently faced by cardiologists in everyday clinical practice when dealing with patients with severe ventricular arrhythmias or atrioventricular conduction disturbances and no evidence of ischemic heart disease or overt valvular or myocardial disease.

Both documents do also indicate how many samples are needed in different clinical conditions, how to handle and process myocardial samples, and which studies are necessary to obtain the desired diagnostic information. In the case of clinically suspected myocarditis 5 to 10 samples must be obtained to perform histology and immunohistochemistry studies and molecular biology studies to detect the presence of viral genomes. Samples for molecular biology must be flash-frozen in liquid nitrogen and stored at -80°C. Endomyocardial biopsy should better not be performed in patients with clinically suspected myocarditis, if immunohistochemistry and virology studies are not available.

The main criticism against a wider use of endomyocardial biopsy in the diagnostic approach to patients with ventricular arrhythmias is represented by the possible sampling error in the presence of a focal myocarditis. In fact, as previously mentioned, the myocardial inflammation in patients presenting with arrhythmias may present a patchy distribution and therefore myocardial samples drawn from a same conventional site (the right side of interventricular septum or the left ventricular apex) may not include myocardial tissue involved by the inflammatory process. Increasing the number of samples obtained or arbitrarily changing the site of biopsy can in part minimize sampling error, but these tricks may increase the risks of the procedure. To overcome the sampling error and increase the diagnostic sensitivity of endomyocardial biopsy, we recently demonstrated that in patients presenting with ventricular arrhythmias, electroanatomical mapping may guide the execution endomyocardial biopsy identifying the segments of ventricular wall presenting an abnormal voltage, suggesting an abnormal histological substrate (Pieroni et al, 2009; Casella & Dello Russo, 2009). This technique represents an important innovation in the field of endomyocardial biopsy as reduces sampling error and increases the sensitivity of biopsy, thus possibly reducing the number of samples needed for a complete study of myocardial tissue and therefore reducing the risks of the procedure.

### 3.3 Electroanatomic mapping

Electroanatomic mapping allows operators to record intracardiac electrical activation in relation to anatomic location in a cardiac chamber of interest, even during arrhythmia mapping. Several 3D-EAM systems are currently available that accomplish these tasks. When applied properly, such technology allows one to accurately determine the location of arrhythmia origin, define cardiac chamber geometry in three dimensions, delineate areas of anatomic interest, and allow catheter manipulation and positioning without fluoroscopic guidance. These systems often simplify mapping efforts and can enhance procedural success, particularly in cases in which complex arrhythmias and unusual cardiac anatomy are encountered.

The CARTO mapping system (Biosense, Diamond Bar, CA, USA) is a three-dimensional nonfluoroscopic mapping system that utilizes a low-level magnetic field ( $5 \times 10^{-6}$  to  $5 \times 10^{-5}$  Tesla) delivered from three separate coils in a locator pad beneath the patient. The magnetic field strength from each coil is detected by a location sensor embedded proximal to the tip of a specialized mapping catheter. The strength of each coil's magnetic field measured by the location sensor is inversely proportional to the distance between the sensor and coil. Hence, by integrating each coil's field strength and converting this measurement into a distance, the location sensor (and therefore, catheter tip location) can be triangulated in space. The mapping catheter has proximal and distal electrode pairs, and a tip electrode capable of radiofrequency energy delivery. This catheter can be moved along a chamber's surface to record local endocardial activation times for arrhythmia mapping, while simultaneously recording location points to generate 3D chamber geometry. Validation studies have shown CARTO to have substantial accuracy in navigating to single points, in returning to prior ablation sites, and in creating a desired length of ablation line. Electrograms recorded from the specialized mapping (NaviSTAR) catheter showed excellent correlation with recordings from standard EP catheters. Moreover human validation studies have shown a good level of spatial precision and accuracy, and realistic reconstruction of chamber geometry and electroanatomic activation during arrhythmia mapping. Nevertheless in our experience, the comparison between biplane right ventricular angiography and the 3D reconstruction

obtained by CARTO showed that small structures such as microaneurysms, can be missed by the mapping catheter and therefore are not properly visualized. These limitations would be partially overcome by importing CT and CMR images and merging them with 3D maps so that during mapping the catheter can be visualized inside the anatomical images. Similar to CARTO the NavX system is a mapping and 3D nonfluoroscopic intracardiac browsing system that can reconstruct in real time geometry as well as the electric activation of the heart chamber. NavX technology makes use of six surface patch electrodes that generate, once correctly positioned, an electric field. Within this electric field it is possible to locate in real time the position of every electrophysiology catheter employed during the procedure, including the cardiac biptome when electrically connected to the mapping system. We tested both systems in guiding endomyocardial biopsy execution. Although a comparison between the systems exceeds the scopes of this chapter, CARTO system probably offers a more detailed reconstruction of the ventricular chambers, while NavX system has the advantage of direct real time visulization of the biptome in the 3D map. In this chapter we will refer to the CARTO system as it was more frequently used in our and other studies.

High-density mapping must be obtained in sinus rhythm (reference channel: QRS complex) by sampling at least 100 points in each chamber, uniformly distributed. The voltage maps are then edited setting the point density (fill threshold) at 15 mm and manually eliminating intracavitary points. According to current literature “electroanatomic scar” is defined as an area including at least 3 adjacent points with bipolar signal amplitude <0.5 mV; the reference value for normal endocardium is usually set at 1,5 mV. In the CARTO system the color display to identify normal and abnormal voltage myocardium ranges from red (electroanatomic scar tissue; amplitude <0.5 mV), to purple (electroanatomic normal tissue; amplitude ≥1.5 mV). Intermediate colors represent the electroanatomic border zone (amplitude >0.5 and <1.5 mV) (Figure 3).

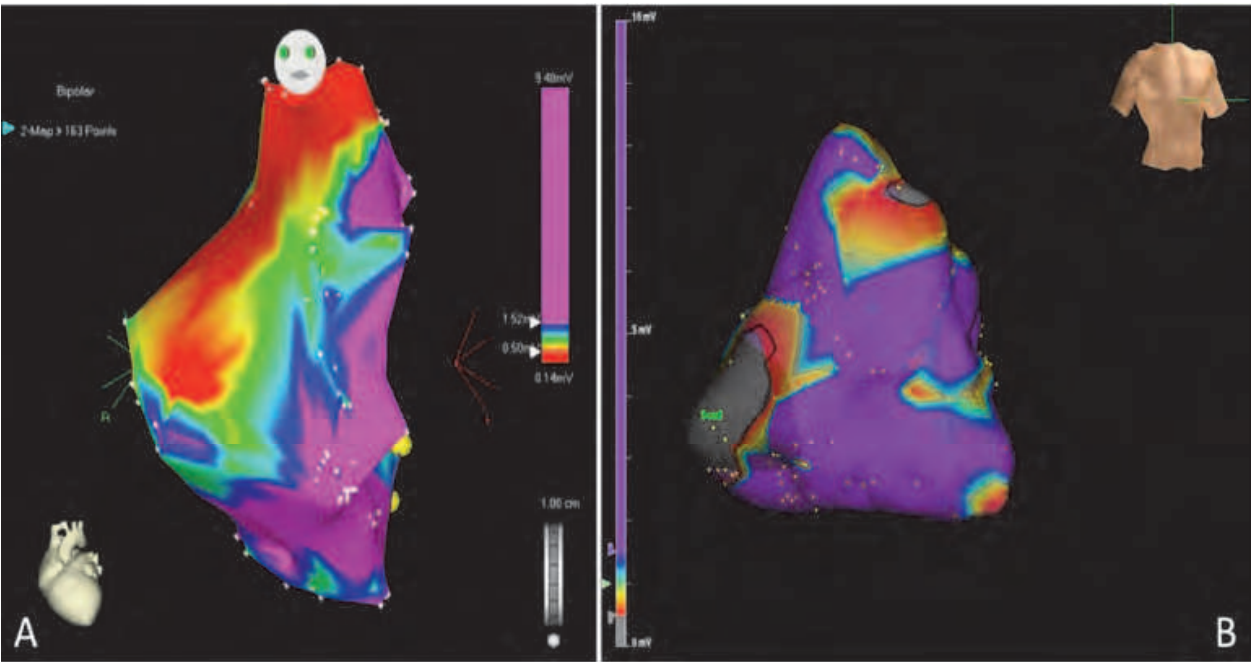


Fig. 3. Example of electroanatomic maps obtained with CARTO (A) and NavX (B) systems. For colours interpretation see text.



Adequate catheter contact should be confirmed by concordant catheter tip motion with the cardiac silhouettes on fluoroscopy and by adherence of voltage map to angiographic right ventricular shape. To avoid low voltage recordings due to poor contact, the following tools can be used: 1) the signal has to satisfy 3 stability criteria automatically detected by CARTO system in terms of cycle length, local activation time and beat-to-beat difference of the location of the catheter ( $<2\%$ ,  $<3$  ms, and  $<4$  mm, respectively); 2) both bipolar and unipolar signals are simultaneously acquired to confirm true catheter contact through the analysis of local electrogram (in particular the shape of the unipolar electrogram); 3) in the presence of a low voltage area, at least 3 additional points should be acquired in the same site to confirm the reproducibility of the voltage measurement. The anatomical distribution of the pathological areas is evaluated dividing the right ventricular voltage map into five segments: outflow tract, free (anterolateral) wall, inferior and posterior basal segments, apex, and interventricular septum.

### **3.4 Electroanatomic mapping-guided endomyocardial biopsy**

The main limitation of endomyocardial biopsy to provide a specific diagnosis in patients with ventricular arrhythmias caused by focal myocardial diseases, (i.e. myocarditis or initial forms of arrhythmogenic right ventricular cardiomyopathy), is represented by the sampling error due to the lack of an effective guide in selecting ventricular areas where to perform biopsies. In the last years, after the development of 3D-EAM systems, we introduced a new technique for the execution of endomyocardial biopsies in patients with ventricular arrhythmias (Pieroni et al., 2009).

#### **3.4.1 Technique**

The new approach is aimed to perform endomyocardial biopsies in the ventricular segments presenting electrical abnormalities at electroanatomical mapping. When using the CARTO system, once the electroanatomical map is completed, the mapping catheter is placed in a region of interest of the ventricular wall and the preformed sheath is positioned closed to the catheter tip (Figure 4). Endomyocardial biopsy is then performed in the area with abnormal electrical properties as showed by the map. As previously mentioned, another approach we tested requires the electrical connection of the biptome to the mapping system: the presence of the metallic jaws makes the biptome similar to a mapping catheter and it is therefore visualized in the 3D electroanatomical map of the ventricle. In this case, the site of biopsy can be chosen “live”, directly mapping the ventricular wall with the biptome (Figure 4). The latter technique can be adopted when using the NavX mapping system. With both systems we usually performed ventricular angiography before the execution of ventricular mapping, in order to improve the anatomical accuracy of the map, as angiography still represents the gold standard to detect wall motion abnormalities and small aneurysms of the right ventricle.

Although no data on specificity and sensitivity of 3D-EAM-guided vs. conventional technique are currently available in literature, it is reasonable that obtaining myocardial samples from areas of the ventricular wall presenting electrical abnormalities will probably reduce the sampling error and the need for multiple biopsies from the same patient (See below). Moreover the combination of 3D-EAM with other imaging tools such as cardiac MRI would further improve our ability to obtain samples from selected regions that present structural, functional and electrical abnormalities.

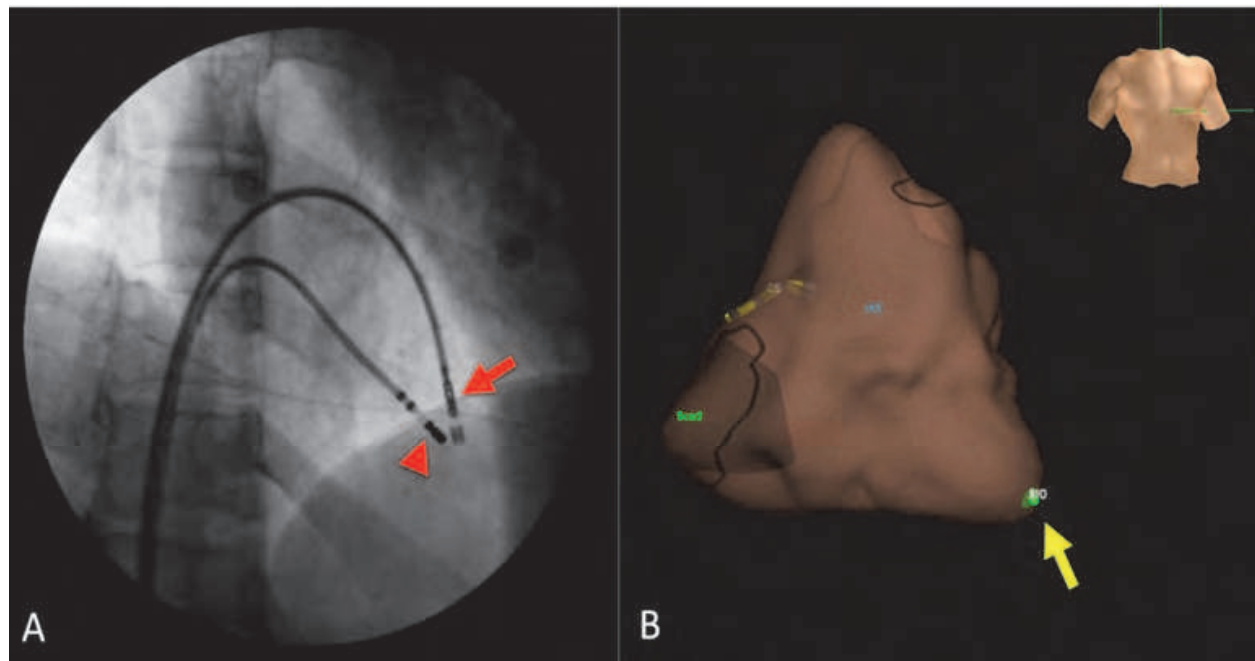


Fig. 4. 3D-EAM-guided EMB. With the CARTO system (A) the long sheath with the biptome inside (arrow) is positioned near to the mapping catheter (arrowhead). With the NavX system (B) the biptome tip (green point and arrow) can be directly visualized in the 3D ventricular map.

### 3.4.2 Safety

The execution of endomyocardial biopsies drawing myocardial samples from non conventional sites, including the right ventricular free-wall and outflow tract do not increase the risks of the procedure. Since 2006 we performed 3D-EAM-guided endomyocardial biopsy in more than sixty patients with about 400 samples obtained. In order to evaluate the safety of this new approach we prospectively analysed the rate of major and minor complications through continuous ECG monitoring during the procedure, ECG and 2D-echocardiography at the end the procedure and after 3 and 6 hours. Major complications included pericardial tamponade with need for pericardiocentesis, hemo- and pneumopericardium, permanent atrioventricular block requiring permanent pacemaker implantation, myocardial infarction, transient cerebral ischemic attack and stroke, severe valvular damage, and death, whereas minor complications included transient chest pain, transient ECG abnormalities, transient arrhythmias, transient hypotension, and small pericardial effusions. The major complication rate was 0% and the minor complication rate was 4.5%: minor complications were represented by small pericardial effusions in 2 patients and chest pain in 1. These rates are in line with those observed in a recent large two-centers study including 755 procedures (right, left and biventricular endomyocardial biopsy) and reporting a major and minor complication rate of 0.82% and 5.1% respectively for right ventricular endomyocardial biopsy (Yilmaz et al., 2010). In literature another study in which 3D-EAM-guided endomyocardial biopsy was performed in 22 patients, reported a higher rate of major complications (1.1%) and minor complications (5.7%), thus suggesting that the expertise of the operators besides the clinical condition and the underlying disorder may influence the safety of the procedure (Avella et al., 2008).

#### 4. Electroanatomic mapping-guided endomyocardial biopsy in patients with ventricular arrhythmias

There is growing evidence that 3D-EAM-guided endomyocardial biopsy represent a new important tool to improve the diagnosis and the treatment of patients with arrhythmias, as well as the knowledge of the pathological substrates and mechanisms underlying arrhythmic syndromes. Since 2006 we performed 66 3D-EAM-guided endomyocardial biopsy procedures. In all cases the biopsies were drawn from the right ventricle, with biventricular mapping and 3D-EAM-guided biopsy being performed in 10 patients. Although data on a direct comparison between 3D-EAM-guided and conventional technique are not yet available, the 3D-EAM-guided approach seems to significantly improve the diagnostic sensitivity and specificity of endomyocardial biopsy. In fact, when applying immunohistochemistry and molecular biology techniques, a definite histologic diagnosis was obtained in all cases. The new technique was firstly adopted in a series of 30 patients with a noninvasive diagnosis of ARVC according to current diagnostic criteria (Pieroni et al., 2009). Twenty-nine (97%) of 30 patients presented an abnormal voltage map. Histology and immunohistochemistry confirmed the diagnosis of ARVC in 15 patients, while showed an active myocarditis in the remaining 15 patients (Figure 5). Patients with ARVC were not distinguishable on the basis of clinical features, presence and severity of structural and functional right ventricular abnormalities and three-dimensional 3D-EAM findings.

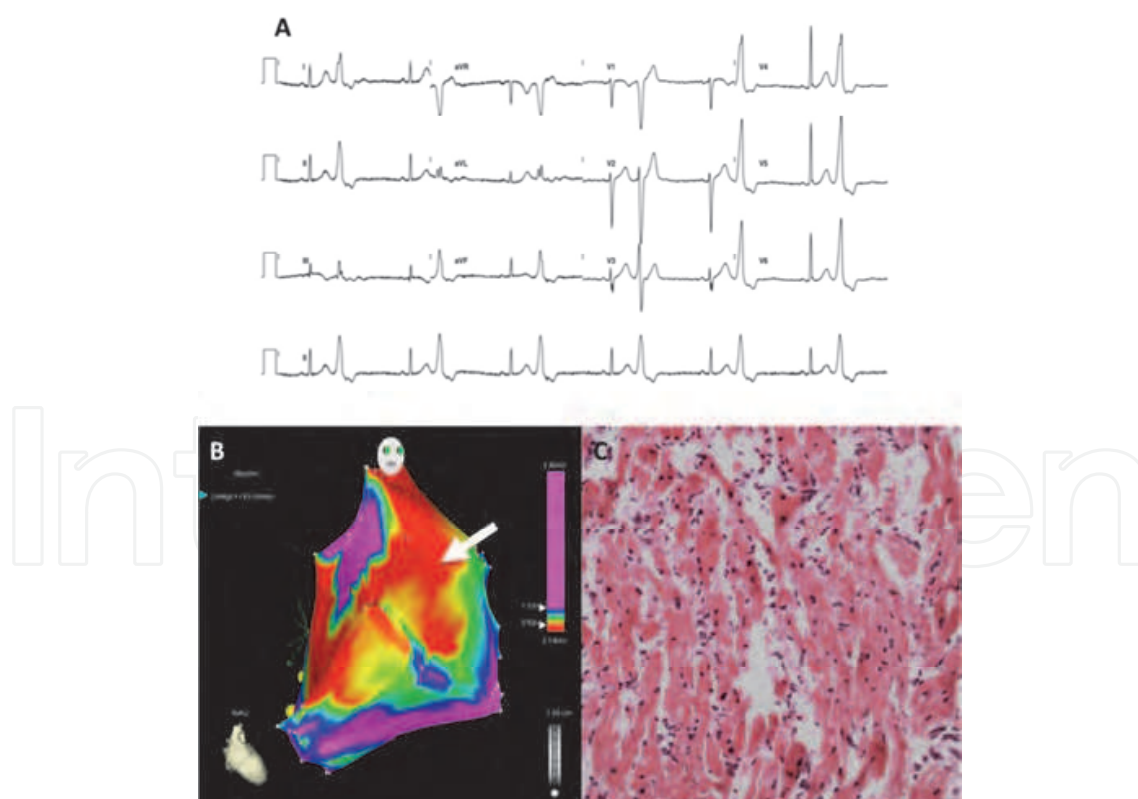


Fig. 5. 3D-EAM-guided EMB, in a patient with bigeminism due to ventricular ectopic beats with LBBB morphology and inferior axis (A). 3D-EAM shows low voltages in the outflow tract and free wall (B). Endomyocardial biopsies drawn from free wall (arrow) shows active myocarditis (C).

On the basis of clinical and histological features, a cardioverter defibrillator was implanted in 13 patients with biopsy-proven ARVC and in 1 patient only with myocarditis. At a mean follow-up of  $21\pm 8$  months, 7 (47%) patients with ARVC experienced recurrence of symptomatic sustained ventricular arrhythmias with appropriate defibrillator intervention in all cases. All patients with myocarditis remained asymptomatic and free from arrhythmic events. Our study was the first to demonstrate that 3D-EAM-guided EMB may allow obtaining a differential diagnosis in patients with otherwise undistinguishable clinical, arrhythmic and imaging features. In addition our study clearly showed that patients with similar arrhythmic presentation may have a dramatically different prognosis in terms of arrhythmias' recurrence according to the underlying disorders, as only 53% of biopsy-proven ARVC patients remained free from arrhythmias at a mean follow-up of  $21\pm 8$  months years, while no patients with biopsy-proven myocarditis experienced major arrhythmic events during the same time (Figure 6).

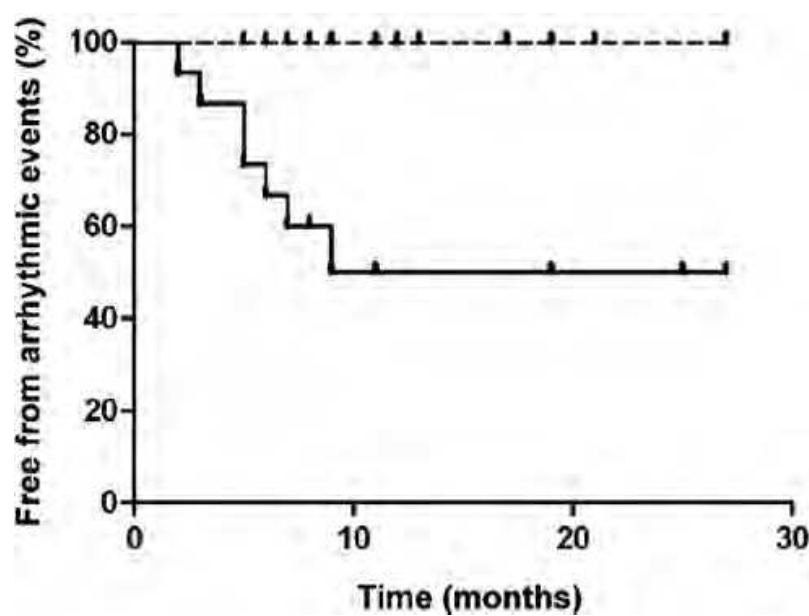


Fig. 6. Kaplan-Meier analysis of arrhythmic event-free survival depending on the histological findings (Modified from Pieroni et al. 2009).

In a more recent study (Pieroni et al unpublished data) we performed 3D-EAM-guided EMB in a series of elite competitive athletes presenting with sustained ventricular arrhythmias. We studied 13 consecutive competitive athletes with evidence of sustained ventricular arrhythmias within the previous six months on 12-lead ECG, 24-hour Holter ECG or ECG exercise testing and who were judged as having a structurally normal heart after a thorough non-invasive evaluation, including signal-averaged electrocardiogram, transthoracic echocardiogram and CMR. Depending on the presumed site of arrhythmias origin according to 12-lead ECG criteria, patients underwent right or left ventricular 3D-EAM and 3D-EAM-guided endomyocardial biopsy. Twelve (92%) patients presented at least 1 low-voltage region at 3D-EAM, while the histologic diagnosis was active myocarditis in 7 patients, and of arrhythmogenic RV cardiomyopathy in 5. In one patient the histological evidence of contraction-band necrosis allowed to unmask caffeine and ephedrine abuse. The identification of the underlying histological substrate in patients with ventricular arrhythmias may be relevant also when radiofrequency catheter ablation (RFCA) is



considered as a possible therapeutic strategy. In fact there is growing evidence that in patients with ARVC, RFCA is effective in abolishing ventricular tachycardias, but the rate or recurrence of arrhythmias with the same or a different morphology may be very high even when an epicardial approach is adopted (Dalal et al., 2007). On the contrary several reports have demonstrated that RFCA may be effective in eliminating ventricular arrhythmias in myocardial inflammatory disorders, including Chagas cardiomyopathy and sarcoidosis (Sosa et al., 1999; Sarabanda et al., 2005; Jefic et al., 2009; Henz et al., 2009). Recent reports and also our experience suggest that endocardial ablation cannot be sufficient in some patients and a combined endo-epicardial approach is required for definitive results. (See below, Clinical implications of myocarditis diagnosis)

## **5. Clinical implications of myocarditis diagnosis in patients with ventricular arrhythmias**

Despite the improvement of diagnostic techniques in defining the characteristics and the etiology of the inflammatory process and the more specific comprehension of the mechanisms leading to myocardial damage, a specific standardized treatment of myocarditis is not yet available. However in the last decades several studies and trials have clearly demonstrated that an etiologic definition of myocarditis based on the immunohistological evaluation of inflammation and proof of viral infection by PCR on biopsies is essential for targeting appropriate treatment strategies indicating that myocarditis patients may benefit from immunosuppression, provided that viral persistence is excluded, while patients with viral persistence fail to respond favourably or deteriorate by immunosuppression.

Several studies have demonstrated the negative prognostic role of viral persistence. In a recent study Kuhl and colleagues analyzed 172 patients with dilated cardiomyopathy and biopsy-proven viral infection in endomyocardial biopsies. The authors reported a high prevalence of enteroviral and parvovirus B19 infection (32.6% and 36.6%, respectively) and found that viral persistence was associated with a progressive impairment of left ventricular ejection fraction, whereas spontaneous viral elimination was associated with a significant improvement in left ventricular function (Kuhl et al., 2005).

Autoimmunity, on the other hand, may play an outstanding role in the progression of myocardial damage and persistence of symptoms, including ventricular arrhythmias. Notably, both acute viral infection and chronic viral persistence can induce autoimmunity by mechanisms not fully elucidated. Molecular mimicry has been suggested as one mechanism to explain chronic myocarditis (Caforio et al., 2002; Rose et al., 2006) and several cellular antigens have been identified to cross-react with viral antigens, thus providing possible targets in virus-induced myocarditis. Autoantibody production also may be caused by the initial myocyte damage by viral infection, releasing increased amounts of self-antigens into the circulation. Autoantibodies against adrenergic and acetylcholine receptors contractile structures, extracellular matrix proteins, proteins involved in energy metabolism, calcium receptors and homeostasis and antistress proteins have all been detected in patients with myocarditis (Neumann et al., 1994; Pankuweit et al., 1997). Furthermore, autoimmunity is considered the main pathogenetic mechanism underlying eosinophilic, giant-cell and granulomatous myocarditis (Cihakova et al., 2008), as well as myocarditis associated with connective tissue diseases, peripartum cardiomyopathy (Ansari et al., 2002) or heart transplant, in which immunosuppression has been proven effective.

Immunosuppression is clearly recommended essentially for the treatment of eosinophilic, granulomatous, giant-cell myocarditis and lymphocytic myocarditis associated with connective tissue diseases or with the rejection of a transplanted heart. With regard to idiopathic lymphocytic myocarditis, beyond acute phase where a spontaneous resolution has been reported in up to 40% of the cases, many patients with idiopathic myocarditis and chronic heart failure are likely to benefit from immunosuppression. An up-regulation of HLA antigens in the myocardial tissue of patients with lymphocytic myocarditis has been proposed as a marker of susceptibility to beneficial effects of immunosuppression (Wojnicz et al., 2001). Recently the data from a randomized double-blind, placebo-controlled study designed to evaluate the efficacy of immunosuppression in virus-negative inflammatory cardiomyopathy have been reported (Frustaci et al., 2009). Eighty-five patients with myocarditis and chronic (>6 months) heart failure unresponsive to conventional therapy and no evidence of myocardial viral genomes were randomized to receive either prednisone and azathioprine (43 patients, Group 1) or placebo (42 patients, Group 2) in addition to conventional therapy for heart failure. Primary outcome was the 6 months improvement in left-ventricular function. Group 1 showed a significant improvement of left-ventricular ejection fraction and a significant decrease in left-ventricular dimensions and volumes compared with baseline. None of Group 2 patients showed improvement of ejection fraction, that significantly worsened compared with baseline. No major adverse reaction was registered as a result of immunosuppression. These data confirmed the efficacy of immunosuppression in virus-negative inflammatory cardiomyopathy. Lack of response in 12% of cases suggested the presence of not screened viruses or mechanisms of damage and inflammation not susceptible to immunosuppression. Antiviral therapy is a logical strategy advocated for the treatment of myocarditis in patients with evidence of viral presence in myocardial tissue. In a small phase II study 22 patients with myocarditis and biopsy-proven viral persistence (15 enteroviral and 7 adenoviral) were treated with interferon-beta  $18 \times 10^6$  IU/week for 24 weeks. Interferon-b treatment resulted in complete elimination of both enteroviral and adenoviral genomes and hemodynamic improvement, as shown by improvement of EF and amelioration of heart failure symptoms. Importantly, treatment with interferon-beta was safe and well-tolerated, with no adverse cardiac effects, and flu-like side effects could be efficiently eliminated by non-steroidal anti-inflammatory drugs (Kuhl et al., 2003). After these encouraging results, a prospective placebo-controlled randomized multicenter study, the Betaferon® in Chronic Viral Cardiomyopathy (BICC) trial, was initiated in 2002 and presented at the 2008 American Heart Association scientific sessions. The primary endpoint was virus elimination or reduction of virus load. At 24-week follow-up, compared to placebo, virus elimination and/or viral load reduction were significantly higher in the interferon group. Moreover, interferon-beta showed a good safety profile and was associated with beneficial effects on clinical secondary endpoints, such as NYHA functional class and quality of life, as assessed by Minnesota questionnaire, although echocardiographic and hemodynamic parameters were not statistically significantly different. This interesting phase II study showed proof of concept for targeted therapy based on molecular diagnosis in inflammatory cardiomyopathy. Future directions in the field of antiviral therapy include preventing direct viral damage and inhibition of viral proliferation by preventing the interaction of viruses with their cellular receptor and their consequent signalling amplification systems, such as the tyrosine kinase p56lck, phosphatase CD45 and downstream ERK1/2 (Liu et al., 2000). Therefore, additional research is required to further understand the mechanisms of viral heart disease and consequently identify new potential targets for therapy.

No specific trial or data from single-center studies on the treatment of myocarditis presenting with ventricular arrhythmias are currently available in literature. In patients with acute myocarditis, therapy for arrhythmias is essentially supportive, since arrhythmias usually resolve after the acute phase of the disease, which can last several weeks, together with the resolution of the inflammatory process. Even in chronic myocarditis, management of ventricular arrhythmias is currently confined to antiarrhythmic drug therapy, with limited efficacy, and to implantable cardioverter-defibrillator for higher-risk patients, including those with hemodynamically unstable ventricular tachycardias (Zipes et al., 2006) and those with aborted sudden death. Radiofrequency catheter ablation has been demonstrated to be effective in reducing ventricular tachycardia occurrence in patients with Chagas cardiomyopathy and sarcoidosis. Regarding ventricular arrhythmias in patients with lymphocytic myocarditis, isolated reports suggest that RFCA may be effective, (Chauhan et al., 2008; Hama et al. 2009; Kettering et al., 2009; Zeppenfeld et al., 2007) but its safety and long-term efficacy in this setting is unclear. In our Institution we documented the safety and efficacy of RFCA in a series of consecutive patients with chronic active myocarditis presenting with drug-refractory ventricular tachycardias. We enrolled 20 pts with biopsy-proven myocarditis and drug-refractory ventricular tachycardia including 5 pts presenting with electrical storm. All patients underwent endocardial RFCA with an irrigation catheter, using contact electroanatomical mapping. Recurrence of sustained ventricular tachycardia after endocardial RFCA was treated with additional epicardial RFCA. Endocardial RFCA was acutely successful in 14 pts (70%), while in the remaining 6 pts (30%) clinical ventricular tachycardia was successfully ablated by epicardial RFCA thus demonstrating that in patients with myocarditis, RFCA of drug-refractory ventricular tachycardia is feasible, safe and effective and that epicardial RFCA should be considered as an important therapeutic option to increase success rate (Pieroni and colleagues in press).

## 6. Conclusion

Myocarditis represents a frequent but often underestimated cause of life-threatening ventricular arrhythmias and sudden arrhythmic death and therefore should be always suspected in these clinical settings. The recognition of myocarditis as the cause of ventricular arrhythmias may have dramatic implications on treatment and prognosis. Imaging techniques such as CMR have improved our ability to recognize myocardial inflammatory damage, and increased the awareness of the disease among physicians. Nevertheless EMB still represents the gold standard for the diagnosis of myocarditis as offers a immunohistological and virological characterization of the inflammatory process that may influence the treatment. Electroanatomic mapping-guided EMB represents a new important technique that allows increasing diagnostic sensitivity and minimizing the sampling error in patients with myocarditis presenting with arrhythmias. In the next future 3D-EAM-guided EMB will also represent an important research tool in the study of channelopathies and other genetically determined arrhythmic syndromes.

## 7. References

Andréoletti L, Ventéo L, Douche-Aourik F, et al. Active Coxsackieviral B infection is associated with disruption of dystrophin in endomyocardial tissue of patients who died suddenly of acute myocardial infarction. *J Am Coll Cardiol* 2007;50:2207-14.

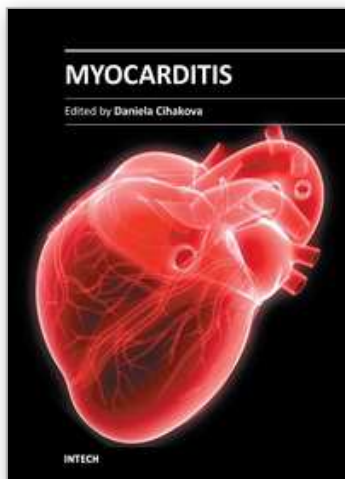
- Ansari AA, Fett JD, Carraway RE, et al. Autoimmune mechanisms as the basis for human peripartum cardiomyopathy. *Clin Rev Allergy Immunol* 2002; 23: 301-324.
- Aretz HT, Billingham ME, Edwards WD, et al. Myocarditis. A histopathologic definition and classification. *Am J Cardiovasc Pathol* 1987;1:3-14.
- Avella A, d'Amati G, Pappalardo A, et al. Diagnostic value of endomyocardial biopsy guided by electroanatomic voltage mapping in arrhythmogenic right ventricular cardiomyopathy/dysplasia. *J Cardiovasc Electrophysiol*. 2008;19:1127-34.
- Basso C, Carturan E, Corrado D, Thiene G. Myocarditis and dilated cardiomyopathy in athletes: diagnosis, management, and recommendations for sport activity. *Cardiol Clin*. 2007;25:423-9.
- Bowles NE, Ni J, Marcus F, Towbin JA. The detection of cardiotropic viruses in the myocardium of patients with arrhythmogenic right ventricular dysplasia/cardiomyopathy. *J Am Coll Cardiol*. 2002;39:892-895.
- Caforio AL, Mahon NJ, Tona F, McKenna WJ. Circulating cardiac autoantibodies in dilated cardiomyopathy and myocarditis: pathogenetic and clinical significance. *Eur J Heart Fail* 2002; 4: 411-417.
- Calabrese F, Basso C, Carturan E, Valente M, Thiene G. Arrhythmogenic right ventricular cardiomyopathy/dysplasia: is there a role for viruses? *Cardiovasc Pathol*. 2006;15:11-17.
- Casella M, Dello Russo A. (2008). *An atlas of radiosopic catheter placement for the electrophysiologist*. Springer-Verlag. ISBN:978-1-84800-226-5, London.
- Chauhan VS, Hameedullah I, Nanthakumar K, Downar E. Epicardial catheter ablation of incessant ventricular tachycardia in giant cell myocarditis. *J Cardiovasc Electrophysiol* 2008;19:1219.
- Chimenti C, Calabrese F, Thiene G, Pieroni M, Maseri A, Frustaci A. Inflammatory left ventricular microaneurysms as a cause of apparently idiopathic ventricular tachyarrhythmias. *Circulation* 2001;104:168-73.
- Chimenti C, Pieroni M, Maseri A, Frustaci A. Histologic findings in patients with clinical and instrumental diagnosis of sporadic arrhythmogenic right ventricular dysplasia. *J Am Coll Cardiol* 2004; 43: 2305 - 2313.
- Cihakova D; Rose NR. Pathogenesis of myocarditis and dilated cardiomyopathy. *Adv Immunol* 2008; 99: 95-114.
- Cooper LT, Baughman KL, Feldman AM et al. American Heart Association; American College of Cardiology; European Society of Cardiology. The role of endomyocardial biopsy in the management of cardiovascular disease: a scientific statement from the American Heart Association, the American College of Cardiology, and the European Society of Cardiology. *Circulation* 2007;116:2216-33.
- Cooper LT. Myocarditis. *N Engl J Med*. 2009;360:1526-38.
- Corrado D, Basso C, Thiene G. Sudden cardiac death in young people with apparently normal heart. *Cardiovasc Res* 2001;50:399-408.
- Dalal D, Jain R, Tandri H, Dong J, Eid SM, Prakasa K, et al. Long-term efficacy of catheter ablation of ventricular tachycardia in patients with arrhythmogenic right ventricular dysplasia/cardiomyopathy. *J Am Coll Cardiol* 2007;50:432-40.
- De Cobelli F, Pieroni M, Esposito A, et al. Delayed gadolinium-enhanced cardiac magnetic resonance in patients with chronic myocarditis presenting with heart failure or recurrent arrhythmias. *J Am Coll Cardiol* 2006;47:1649-54.
- Doolan A, Langlois N, Semsarian C. Causes of sudden cardiac death in young Australians. *Med J Aust* 2004;180:110-112.



- Fabre A, Sheppard MN. Sudden adult death syndrome and other non-ischaemic causes of sudden cardiac death. *Heart*. 2006 Mar;92(3):316-20.
- Fabre A, Sheppard MN. Sudden adult death syndrome and other non-ischaemic causes of sudden cardiac death. *Heart*. 2006;92:316-20.
- Feldman AM, McNamara D. Myocarditis. *N Engl J Med*. 2000;343:1388-98.
- Friedman RA, Kearney DL, Moak JP, Fenrich AL, Perry JC. Persistence of ventricular arrhythmia after resolution of occult myocarditis in children and young adults. *J Am Coll Cardiol* 1994;24:780-3.
- Friedrich MG, Sechtem U, Schulz-Menger J, Holmvang G, Alakija P, Cooper LT, White JA, Abdel-Aty H, Gutberlet M, Prasad S, Aletras A, Laissy JP, Paterson I, Filipchuk NG, Kumar A, Pauschinger M, Liu P; International Consensus Group on Cardiovascular Magnetic Resonance in Myocarditis. Cardiovascular magnetic resonance in myocarditis: A JACC White Paper. *J Am Coll Cardiol*. 2009;53:1475-87.
- Frustaci A, Bellocci F, Olsen EG. Results of biventricular endomyocardial biopsy in survivors of cardiac arrest with apparently normal hearts. *Am J Cardiol* 1994;74:890-5.
- Frustaci A, Priori SG, Pieroni M, et al. Cardiac histological substrate in patients with clinical phenotype of Brugada syndrome. *Circulation* 2005;112:3680 -7.
- Frustaci A, Russo MA, Chimenti C. Randomized study on the efficacy of immunosuppressive therapy in patients with virus-negative inflammatory cardiomyopathy: the TIMIC study. *Eur Heart J*. 2009;30:1995-2002.
- Frustaci A, Verardo R, Caldarulo M, Acconcia MC, Russo MA, Chimenti C. Myocarditis in hypertrophic cardiomyopathy patients presenting acute clinical deterioration. *Eur Heart J*. 2007;28:733-40.
- Granér M, Lommi J, Kupari M, Raisanen-Sokolowski A, Toivonen L. Multiple forms of sustained monomorphic ventricular tachycardia as common presentation in giant-cell myocarditis. *Heart* 2007;93:119-21.
- Hama Y, Funabashi N, Ueda M, et al. Right-sided heart wall thickening and delayed enhancement caused by chronic active myocarditis complicated by sustained monomorphic ventricular tachycardia. *Circulation* 2009;119:e200-3.
- Henz BD, do Nascimento TA, Dietrich Cde O, et al. Simultaneous epicardial and endocardial substrate mapping and radiofrequency catheter ablation as first-line treatment for ventricular tachycardia and frequent ICD shocks in chronic chagasic cardiomyopathy. *J Interv Card Electrophysiol* 2009;26:195-205.
- Hofmann R, Trappe HJ, Klein H, Kemnitz J. Chronic (or healed) myocarditis mimicking arrhythmogenic right ventricular dysplasia. *Eur Heart J* 1993;14:717-20.
- Hoshino T, Matsumori A, Kawai C, Imai J. Electrocardiographic abnormalities in Syrian golden hamsters with coxsackievirus B1 myocarditis. *Jpn Circ J* 1982;46:1305-12.
- Hoshino T, Matsumori A, Kawai C, Imai J. Ventricular aneurysms and ventricular arrhythmias complicating Coxsackie virus B1 myocarditis of Syrian golden hamsters. *Cardiovasc Res*. 1984;18:24-9.
- Jefic D, Joel B, Good E, Morady F, Rosman H, Knight B, Bogun F. Role of radiofrequency catheter ablation of ventricular tachycardia in cardiac sarcoidosis: report from a multicenter registry. *Heart Rhythm*. 2009;6:189-95.
- Kettering K, Kampmann C, Mollnau H, Kreitner KF, Munzel T, Weiss C. Catheter ablation of an incessant ventricular tachycardia originating from the left aortic sinus cusp in an adolescent with subacute myocarditis. *Clin Res Cardiol* 2009;98:66-70.

- Kishimoto C, Matsumori A, Kawai C. Electrocardiographic findings in experimental murine myocarditis--arrhythmias in the chronic stage. *Jpn Circ J.* 1983;47:1317-21.
- Koplan BA, Soejima K, Baughman K, et al. Refractory ventricular tachycardia secondary to cardiac sarcoid: electrophysiologic characteristics, mapping, and ablation. *Heart Rhythm* 2006;3:924 -9.
- Kuhl U, Pauschinger M, Schwimmbeck PL, et al. Interferon-beta treatment eliminates cardiotropic viruses and improves left ventricular function in patients with myocardial persistence of viral genomes and left ventricular dysfunction. *Circulation* 2003; 107: 2793-2798.
- Kuhl U, Pauschinger M, Seeberg B, et al. Viral persistence in the myocardium is associated with progressive cardiac dysfunction. *Circulation* 2005; 112: 1965-1970.
- Leone O, Rapezzi C, Sinagra G, Angelini A, Arbustini E, Bartoloni G, Basso C, Caforio AL, Calabrese F, Coccolo F, d'Amati G, Mariesi E, Milanese O, Nodari S, Oliva F, Perkan A, Prandstraller D, Pucci A, Ramondo A, Silvestri F, Valente M, Thiene G; Federazione Italiana di Cardiologia; Associazione per la Patologia Cardiovascolare Italiana. Consensus document on endomyocardial biopsy of the Associazione per la Patologia Cardiovascolare Italiana. *G Ital Cardiol.* 2009;10:3S-50S
- Liu, P, Aitken, K, Kong, YY, *et al.* The tyrosine kinase p56lck is essential in coxsackievirus B3-mediated heart disease. *Nat Med* 2000; 6: 429-434.
- Magnani JW, Danik HJ, Dec GW, Jr., DiSalvo TG. Survival in biopsy-proven myocarditis: a long-term retrospective analysis of the histopathologic, clinical, and hemodynamic predictors. *Am Heart J* 2006;151:463-70.
- Mahrholdt H, Goedecke H, Wagner A et al. Cardiovascular magnetic resonance assessment of human myocarditis: comparison to histology and molecular pathology. *Circulation* 2004;109:1250-8.
- Matsumori A, Kishimoto C, Kawai C, Sawada S. Right ventricular aneurysms complicating encephalomyocarditis virus myocarditis in mice. *Jpn Circ J.* 1983;47:1322-4.
- Muratore CA, Baranchuk A. Current and emerging therapeutic options for the treatment of chronic chagasic cardiomyopathy. *Vasc Health Risk Manag* 2010;6:593-601.
- Neumann DA, Rose NR, Ansari AA, Herskowitz A. Induction of multiple heart autoantibodies in mice with coxsackievirus B3- and cardiac myosin-induced autoimmune myocarditis. *J Immunol* 1994; 152: 343-350.
- Ohkubo K, Watanabe I, Okumuru Y et al. Right ventricular histological substrate and conduction delay in patients with Brugada Syndrome. *Int J Cardiol* 2010;51:17-23).
- Ordovas KG, Reddy GP, Higgins CB. MRI in nonischemic acquired heart disease. *J Magn Reson Imaging.* 2008;27:1195-213.
- Ott P, Marcus FI, Sobonya RE, Morady F, Knight BP, Fuenzalida CE. Cardiac sarcoidosis masquerading as right ventricular dysplasia. *Pacing Clin Electrophysiol.* 2003;26:1498-503.
- Pankuweit S, Portig I, Lottspeich F, Maisch B. Autoantibodies in sera of patients with myocarditis: characterization of the corresponding proteins by isoelectric focusing and N-terminal sequence analysis. *J Mol Cell Cardiol* 1997; 29: 77-84.
- Phillips MP, Robinowitz M, Higgins JR, et al. Sudden cardiac death in Air Force recruits. *JAMA* 1986;256:2696-2699.
- Pieroni M, Dello Russo A, Marzo F, et al. High prevalence of myocarditis mimicking arrhythmogenic right ventricular cardiomyopathy differential diagnosis by electroanatomic mapping-guided endomyocardial biopsy. *J Am Coll Cardiol* 2009;53:681-9.

- Rose NR. The significance of autoimmunity in myocarditis. Ernst Schering Res Found Workshop 2006: 141-154.
- Saito J, Niwano S, Niwano H, et al. Electrical remodeling of the ventricular myocardium in myocarditis: studies of rat experimental autoimmune myocarditis. *Circ J* 2002;66:97-103.
- Sarabanda AV, Sosa E, Simoes MV, Figueiredo GL, Pintya AO, Marin-Neto JA. Ventricular tachycardia in Chagas' disease: a comparison of clinical, angiographic, electrophysiologic and myocardial perfusion disturbances between patients presenting with either sustained or nonsustained forms. *Int J Cardiol* 2005;102:9-19.
- Sosa E, Scanavacca M, D'Avila A, Bellotti G, Pilleggi F. Radiofrequency catheter ablation of ventricular tachycardia guided by nonsurgical epicardial mapping in chronic Chagasic heart disease. *Pacing Clin Electrophysiol* 1999;22:128-30.
- Theleman KP, Kuiper JJ, Roberts WC. Acute myocarditis (predominately lymphocytic) causing sudden death without heart failure. *Am J Cardiol* 2001;88:1078-83.
- Thiene G, Basso C. Arrhythmogenic right ventricular cardiomyopathy: An update. *Cardiovasc Pathol*. 2001;10:109-117.
- UCARE, IVF-US. Survivors of out-of-hospital cardiac arrest with apparently normal heart. Need for definition and standardized clinical evaluation. Consensus Statement of the Joint Steering Committees of the Unexplained Cardiac Arrest Registry of Europe and of the Idiopathic Ventricular Fibrillation Registry of the United States. *Circulation* 1997;95:265-72.
- Vasaiwala SC, Finn C, Delpriore J, et al. Prospective Study of cardiac sarcoid mimicking arrhythmogenic right ventricular dysplasia. *J Cardiovasc Electrophysiol* 2008;19:2000-7.
- Wojnicz, R, Nowalany-Kozielska, E, Wojciechowska, C, *et al.* Randomized, placebo-controlled study for immunosuppressive treatment of inflammatory dilated cardiomyopathy: two-year follow-up results. *Circulation* 2001; 104: 39-45.
- Yilmaz A, Kindermann I, Kindermann M, Mahfoud F, Ukena C, Athanasiadis A, Hill S, Mahrholdt H, Voehringer M, Schießer M, Klingel K, Kandolf R, Böhm M, Sechtem U. Comparative evaluation of left and right ventricular endomyocardial biopsy: differences in complication rate and diagnostic performance. *Circulation*. 2010;122:900-9.
- Zeppenfeld K, Blom NA, Bootsma M, Schalij MJ. Incessant ventricular tachycardia in fulminant lymphocytic myocarditis: Evidence for origin in the Purkinje system and successful treatment with ablation. *Heart Rhythm* 2007;4:88-91.
- Zipes DP, Camm AJ, Borggrefe M, et al. ACC/AHA/ESC 2006 guidelines for management of patients with ventricular arrhythmias and the prevention of sudden cardiac death--executive summary: A report of the American College of Cardiology/American Heart Association Task Force and the European Society of Cardiology Committee for Practice Guidelines (Writing Committee to Develop Guidelines for Management of Patients with Ventricular Arrhythmias and the Prevention of Sudden Cardiac Death) Developed in collaboration with the European Heart Rhythm Association and the Heart Rhythm Society. *Eur Heart J* 2006;27:2099-140.



## **Myocarditis**

Edited by Dr. Daniela Cihakova

ISBN 978-953-307-289-0

Hard cover, 428 pages

**Publisher** InTech

**Published online** 19, October, 2011

**Published in print edition** October, 2011

Myocarditis, the inflammation of the heart muscle, could be in some cases serious and potentially fatal disease. This book is a comprehensive compilation of studies from leading international experts on various aspects of myocarditis. The first section of the book provides a clinical perspective on the disease. It contains comprehensive reviews of the causes of myocarditis, its classification, diagnosis, and treatment. It also includes reviews of Perimyocarditis; Chagas's™ chronic myocarditis, and myocarditis in HIV-positive patients. The second section of the book focuses on the pathogenesis of myocarditis, discussing pathways and mechanisms activated during viral infection and host immune response during myocarditis. The third, and final, section discusses new findings in the pathogenesis that may lead to new directions for clinical diagnosis, including use of new biomarkers, and new treatments of myocarditis.

### **How to reference**

In order to correctly reference this scholarly work, feel free to copy and paste the following:

Maurizio Pieroni, Costantino Smaldone and Fulvio Bellocchi (2011). Myocarditis Presenting with Ventricular Arrhythmias: Role of Electroanatomical Mapping-Guided Endomyocardial Biopsy in Differential Diagnosis, Myocarditis, Dr. Daniela Cihakova (Ed.), ISBN: 978-953-307-289-0, InTech, Available from: <http://www.intechopen.com/books/myocarditis/myocarditis-presenting-with-ventricular-arrhythmias-role-of-electroanatomical-mapping-guided-endomyo>

**INTech**  
open science | open minds

### **InTech Europe**

University Campus STeP Ri  
Slavka Krautzeka 83/A  
51000 Rijeka, Croatia  
Phone: +385 (51) 770 447  
Fax: +385 (51) 686 166  
[www.intechopen.com](http://www.intechopen.com)

### **InTech China**

Unit 405, Office Block, Hotel Equatorial Shanghai  
No.65, Yan An Road (West), Shanghai, 200040, China  
中国上海市延安西路65号上海国际贵都大饭店办公楼405单元  
Phone: +86-21-62489820  
Fax: +86-21-62489821



© 2011 The Author(s). Licensee IntechOpen. This is an open access article distributed under the terms of the [Creative Commons Attribution 3.0 License](https://creativecommons.org/licenses/by/3.0/), which permits unrestricted use, distribution, and reproduction in any medium, provided the original work is properly cited.

IntechOpen

IntechOpen