

# We are IntechOpen, the world's leading publisher of Open Access books Built by scientists, for scientists

6,900

Open access books available

185,000

International authors and editors

200M

Downloads

Our authors are among the

154

Countries delivered to

TOP 1%

most cited scientists

12.2%

Contributors from top 500 universities



WEB OF SCIENCE™

Selection of our books indexed in the Book Citation Index  
in Web of Science™ Core Collection (BKCI)

Interested in publishing with us?  
Contact [book.department@intechopen.com](mailto:book.department@intechopen.com)

Numbers displayed above are based on latest data collected.  
For more information visit [www.intechopen.com](http://www.intechopen.com)



## Endovascular Repair of Thoracic Aortic Emergencies

Lucas Ribé, Juan Luis Portero, Juan Vicente Solís, Rosario García-Pajares,  
María Vila and Luis Manuel Reparaz  
*General University Hospital "Gregorio Marañón". Madrid  
Spain*

### 1. Introduction

The thoracic aorta begins at the lower border of the fourth thoracic vertebra, descends from the aortic arch, and ends at the level of the lower border of the twelfth thoracic vertebra. After passing through the aortic hiatus, it becomes the abdominal aorta.

The volume and pressure of blood through the thoracic aorta are greater than those of all other vascular structures. Consequently, diseases and complications of the thoracic aorta are extremely problematic. Emergencies such as aortic dissection, trauma, ruptured thoracic aortic aneurysms, penetrating aortic ulcers, thoracic aortic tears, aortobronchial fistulas, and any other condition where the integrity of the thoracic aorta is disrupted can have fatal consequences.

One of the most difficult emergencies of the thoracic aorta is acute aortic syndrome, which encompasses classic aortic dissection, intramural hematoma, and penetrating aortic ulcers.

Emergency open repair of lesions in the thoracic aorta is associated with very high surgical risk. Even with the use of cardiopulmonary bypass, profound hypothermia, circulatory arrest, spinal cord protection, and intensive care unit support, operative mortality rates for open repair have been reported to range from 8% to 20% for elective cases and from 60% to 70% following aortic rupture or aortic emergencies (Saratzis et al., 2008; Cowley et al.; 1990). Some series report mortality rates to be as high as 40-50% for open surgical repair of the thoracic aorta in emergency situations (Kaya et al., 2009; Schermerhorn et al., 2008).

Other postoperative complications, such as cardiac conditions, paraplegia, pulmonary conditions, or renal failure are observed in 12% to 45% of patients undergoing open surgical repair (Kaya et al., 2009; Schermerhorn et al., 2008; Achneck et al., 2007; Bozinovski & Coselli, 2008; Rousseau et al., 2005; Buz et al., 2008; Demetriades et al., 2008).

Endovascular repair, on the other hand, is associated with lower morbidity and mortality (Schermerhorn et al., 2008). Moreover, patients considered unsuitable for surgery because of severe comorbid conditions may benefit from this less invasive technique.

In this chapter, we present our experience with endovascular approaches to a series of thoracic aortic emergencies: aortic dissection, ruptured thoracic aneurysms, aortobronchial fistula, aorto-esophageal fistula, subclavian symptomatic pseudoaneurysm, and blunt aortic disruption. We also review previous publications on this important vascular pathology.

2. Clinical cases

2.1 Material and methods

We present our experience with thoracic aortic emergencies. From May 2003 to September 2010, more than 200 patients were evaluated in our hospital for various emergencies affecting the entire aorta. Many patients required laparotomy or thoracotomy due to hemodynamic instability.

From January 2000 to September 2010, we treated 80 patients using endovascular stent grafting, both in elective and in emergency repair. Endovascular procedures were performed in 25 patients for emergency lesions between May 2003 and September 2010.

In this section, we describe the cases, procedures, and outcome.

At our institution, we divide aortic emergencies into 5 groups:

- Acute aortic syndrome: aortic dissection (5), penetrating aortic ulcer (2), intramural hematoma (2)
- Ruptured thoracic aneurysm (5)
- Symptomatic thoracic aortic pseudoaneurysm (3)
- Traumatic (blunt) aortic disruption (4)
- Aortobronchial fistula (1), aortoesophageal fistula (2)
- Subclavian symptomatic pseudoaneurysm (1)

The indications for treatment were aortic rupture in 5 patients (20%), persistent or recurrent pain in 8 patients (32%), hypotension or shock in 9 patients (36%), hemoptysis in 2 patients (8%), and acute renal failure in 1 patient (4%).

Baseline characteristics and cardiovascular risk factors of our patients are given in Table 1.

Age, years	60 (range, 26-80)
Gender (male: female)	21:4 (84%: 16%)
Hypertension	20 (80%)
Diabetes mellitus	7 (28%)
Dyslipidemia	9 (36%)
Smoking	16 (64%)
Coronary artery disease	4 (16%)
Previous cardiac surgery/coronary intervention	5 (20%)
Renal insufficiency	3 (12%)
Chronic obstructive pulmonary disease	5 (21%)
<b>Aortic disease</b>	
- Aortic dissection	5
- Penetrating aortic ulcer	2
- Intramural hematoma	2
- Ruptured thoracic aneurysm	5
- Symptomatic thoracic aortic pseudoaneurysm	3
- Traumatic (blunt) aortic disruption	4
- Aortobronchial fistula	1
- Aortoesophageal fistula	2
- Subclavian symptomatic pseudoaneurysm	1
	n=25

Table 1. Patient characteristics and comorbidities

Five patients (20%) had already undergone aortic surgery and five (20%) had undergone cardiac surgery. Two patients had undergone open repair of the abdominal aorta for abdominal aortic aneurysm.

The mean diameter of the thoracic aorta in patients with ruptured thoracic aortic aneurysms was  $79 \pm 18$  mm (range, 70-92 mm). Mean diameter including all patients with thoracic aortic aneurysms and pseudoaneurysms (11 patients) was 77 mm (range, 40-110 mm).

The median interval between onset of symptoms and the endovascular procedure was 0.7 days (range, 0- 6).

We used four commercially available thoracic stent-graft prostheses: Talent® (n=12, 48%), Valiant®, (Medtronic Vascular, Santa Rosa, California, USA) (n=6, 24%), Relay® (Bolton Medical, Florida, USA) (n=6, 24%), and AneuRx® (Medtronic AVE, Cupertino, California, USA) (n=1, 4%).

Each endoprosthesis consisted of a self-expanding nitinol stent, covered externally by a Dacron graft. The type of stent graft was selected depending on availability and surgeon preference.

Data were collected on case report forms and checked for inconsistencies by two of the authors (R.L, P. JL).

## 2.2 Preprocedural diagnosis

Sizing of the endoprosthesis was based on centerline diameter measurements from contrast enhanced computed tomography (CT) angiography and three-dimensional image reconstructions; 10-20% oversizing was applied when selecting the stent graft diameter.

Trans-esophageal echocardiography was used in all cases of acute aortic syndrome (Stanford type B acute aortic dissection, intramural hematoma, penetrating aortic ulcer) and in the patient with an aortobronchial fistula.

Intravascular ultrasound was used in 3 of the patients with aortic dissection and for deployment of the stent graft in the patient with aortobronchial fistula.

## 2.3 Procedures

All surgical procedures were performed under general anesthesia in an operating room with angiographic and fluoroscopic equipment. Each patient received a single dose of antibiotic therapy (cefazolin) and 5000 units of heparin (except in ruptured aneurysms or head injuries). Cerebrospinal fluid (CSF) was drained in 8 hemodynamically stable patients (n=8). CSF pressure was monitored and maintained at 10 mmHg. CSF drainage was continued for 48 hours after surgery unless complications occurred. Hypotension was induced before device deployment when patients were stable.

Intravascular access was by transfemoral insertion in one groin. An ultrastiff 0.035-inch Amplatz SuperStiff™ guidewire (Boston Scientific, Miami, Florida, USA) or Lunderquist ExtraStiff wire (Cook, Inc., Bloomington, Illinois, USA) was directed into the ascending aorta via a transverse arteriotomy. Using a percutaneous contralateral approach, a soft Terumo guidewire (Terumo Medical, Somerset, New Jersey, USA) and 6-F pigtail catheter (Cordis, Johnson and Johnson, Warren, New Jersey, USA) were directed into the ascending aorta. Intraoperative angiogram was then performed in a left anterior oblique view at 40°-60°. The stent graft delivery system was inserted through the access artery. After marking the left subclavian artery, the endoprosthesis was delivered and deployed. During deployment, systolic blood pressure was usually maintained below 80 mmHg.

A prosthetic conduit was used from the common iliac artery (2 cases) when the diameter of the femoral or iliac vessels was very small (under 7 mm) or the vessels were very calcified or tortuous.

Completion angiography was performed at the end of the procedure to assess accurate placement of the endoprosthesis and exclusion of pathology.

Table 2 shows the diagnosis, patient’s age and endovascular procedure details.

CASES	DIAGNOSIS	AGE (years)	PROCEDURE
1	DISSECTION	67	Thoracic endoprosthesis
2	DISSECTION	39	Thoracic endoprosthesis
3	DISSECTION	65	Thoracic endoprosthesis
4	DISSECTION	74	Thoracic endoprosthesis
5	DISSECTION	33	Thoracic endoprosthesis
6	PENETRATING AORTIC ULCER	61	Thoracic endoprosthesis
7	PENETRATING AORTIC ULCER	66	Thoracic endoprosthesis
8	INTRAMURAL HEMATOMA	64	Thoracic endoprosthesis
9	INTRAMURAL HEMATOMA	69	Thoracic endoprosthesis
10	RUPTURED TAA	80	Thoracic endoprosthesis
11	RUPTURED TAA	56	Thoracic endoprosthesis
12	RUPTURED TAA	69	Thoracic endoprosthesis
13	RUPTURED TAA	72	Thoracic endoprosthesis
14	RUPTURED TAA	76	Thoracic endoprosthesis
15	PSEUDOANEURYSM	74	Thoracic endoprosthesis
16	PSEUDOANEURYSM	44	Thoracic endoprosthesis
17	PSEUDOANEURYSM	46	Thoracic endoprosthesis
18	TRAUMATIC AORTIC DISRUPTION	64	Thoracic endoprosthesis
19	TRAUMATIC AORTIC DISRUPTION	55	Thoracic endoprosthesis
20	TRAUMATIC AORTIC DISRUPTION	30	Thoracic endoprosthesis
21	TRAUMATIC AORTIC DISRUPTION	26	Thoracic endoprosthesis
22	AORTOBRONCHIAL FISTULA	55	Thoracic endoprosthesis
23	AORTOESOPHAGEAL FISTULA	74	Thoracic endoprosthesis
24	AORTOESOPHAGEAL FISTULA	68	Thoracic endoprosthesis
25	SUBCLAVIAN PSEUDOANEURYSM	65	Thoracic endoprosthesis and Amplatzer plug

Table 2. Diagnosis, age and endovascular procedure details.

## 2.4 Cases

### 2.4.1 Cases 1-9. Acute aortic syndrome (9)

Five patients were treated during this period for symptomatic type B aortic dissection, 2 for symptomatic penetrating aortic ulcer and 2 for intramural hematoma. Median age was 60 years (range, 33- 74 years).

Seven patients were treated for persistent pain. One patient was treated for uncontrolled hypertension. One patient was treated for onset of acute renal failure (due to the dissection) and persistent pain.

One patient was a 33-year-old male with Marfan syndrome who was treated for a symptomatic huge growth of a distal thoracic aorta dissection (10 cm in diameter) with a postdissection thoracoabdominal aneurysm (Figure 1). He presented at the emergency department with interscapular pain. The patient underwent a hybrid surgical procedure in a 2-stage intervention involving placement of a thoracic endoprosthesis (34 x 34 x 200 mm Valiant-Medtronic®) followed 2 days later by open repair of his visceral aorta using an aorto-aortic bypass Dacron graft with reimplantation of the 4 visceral vessels. He was discharged 32 days after the second procedure.

Another patient was a 60-year-old male who presented with acute-onset intense thoracic interscapular pain and hypertension. CT scan revealed an intramural hematoma complicated with penetrating aortic ulcers (Figure 2). A 46 x 42 x 110-mm Talent® stent-graft was deployed. Four days later, CT scan revealed a type I proximal endoleak. A proximal stent graft (46 x 46 x 130-mm Talent) was successfully delivered and deployed. The patient was discharged 6 days later.

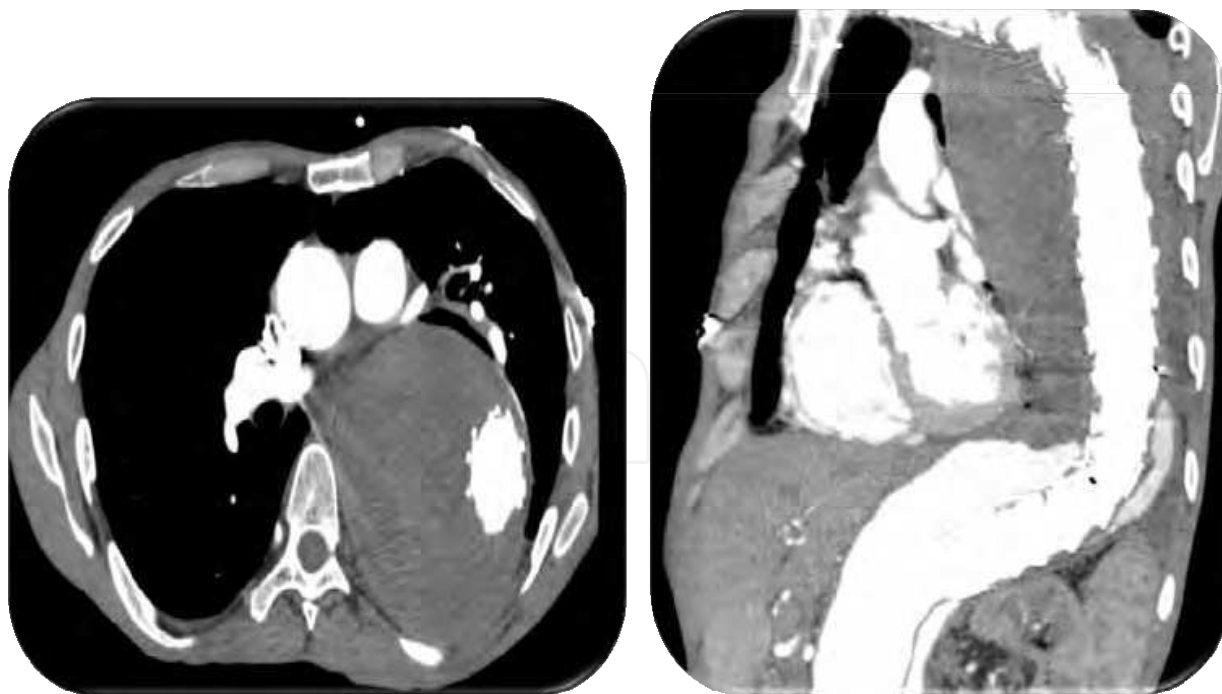


Fig. 1. Case 5. Left: Chest computed tomography scan showing sac growth (11 cm in diameter) in the descending thoracic aorta. Right: Dissection of the distal thoracic aorta and visceral aorta, with a huge thoracic postdissection sac.



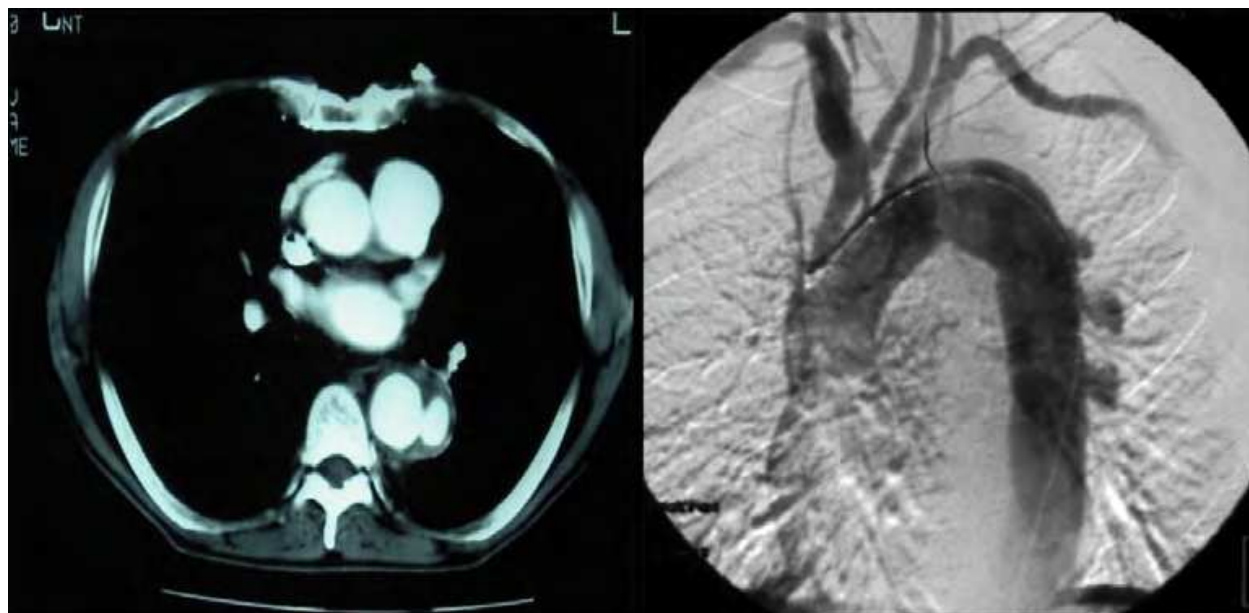


Fig. 2. Case 6. Left: Computed tomography scan revealing a 20 x 10-mm penetrating aortic ulcer with an intramural hematoma. Right: Aortography showing 3 penetrating ulcers in the descending thoracic aorta.

#### 2.4.2 Cases 10-17. Ruptured thoracic aneurysms and symptomatic pseudoaneurysms (8)

Five patients were treated during this period for ruptured thoracic aneurysms and 3 patients for symptomatic thoracic pseudoaneurysms. Median age (all 8 patients) was 65 years (range, 44-80 years). Mean thoracic aorta diameter in patients with ruptured thoracic aortic aneurysms was 79 mm (range, 70- 92 mm) (Figure 3). On admission, 7 patients were hemodynamically unstable. One patient presented with hemoptysis.

As an unusual presentation, we describe the case of a 46-year-old HIV-infected woman (stage B2) coinfecting with hepatitis C virus and tuberculosis. She presented with persistent hemoptysis (ongoing for 3 days), interscapular pain, and fever. CT scan revealed a 40-mm upper thoracic pseudoaneurysm in close contact with the left bronchus (Figure 4). The patient became hemodynamically unstable and went into cardiopulmonary arrest. After cardiopulmonary resuscitation and stabilization in the intensive care unit, she underwent successful exclusion of the lesion with a 26 x 26 x 155-mm Relay® endoprosthesis placed distal to the origin of the left common carotid artery and covering the ostium of the left subclavian artery. The postoperative period was uneventful and she was discharged 11 days after surgery.

Follow up was scheduled at 1, 3, 6, and 12 months. Her latest CT scan (36 months) showed patency of the endoprosthesis with no endoleaks. Her latest physical examination revealed no vascular abnormalities.

Mortality in this group was very high (3 of 8 patients). Three of the 5 patients who died during their stay were in this group.

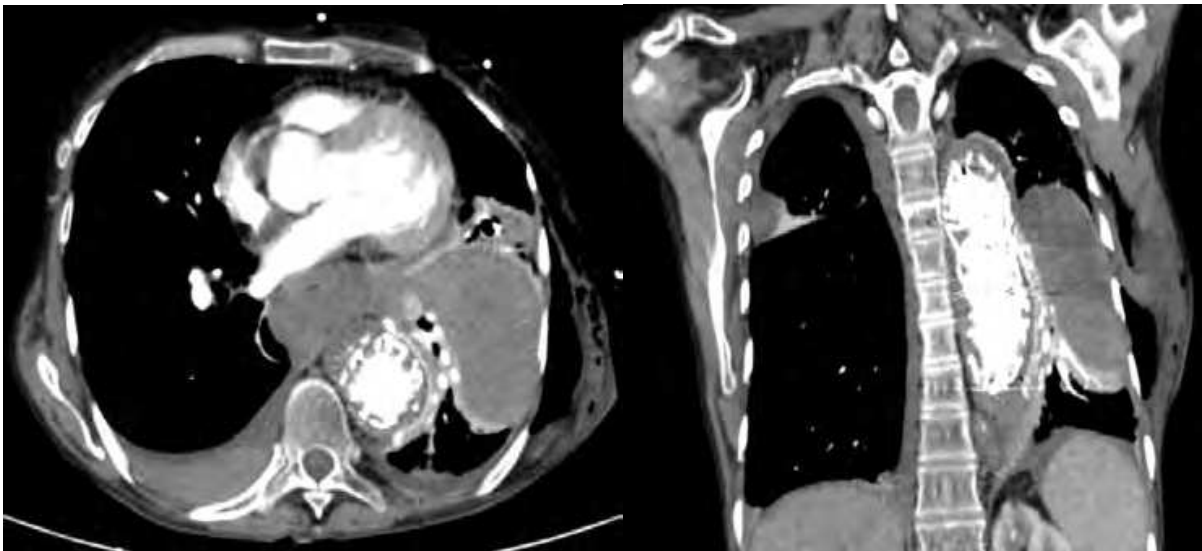


Fig. 3. Case 16. Chest computed tomography scan showing a ruptured (contained) pseudoaneurysm in the descending thoracic aorta at the site of a previous thoracic stent graft.

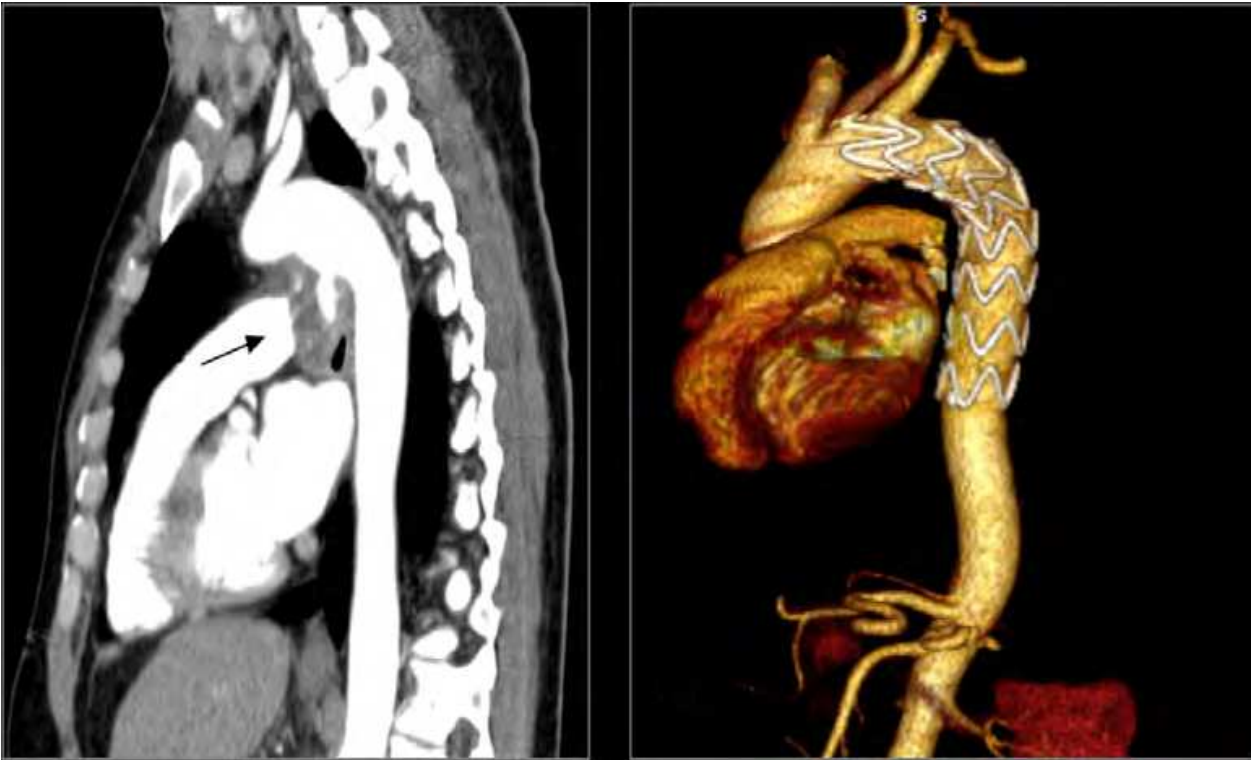


Fig. 4. Case 17. Left: Chest computed tomography scan showing a mycotic pseudoaneurysm (arrow) in the descending thoracic aorta. Right: Computed tomography scan demonstrating correct position of the stent graft.

**2.4.3 Cases 18-21. Traumatic (blunt) aortic disruption (4)**

In this group, all the patients were young (median age, 40 years [range, 26-58 years]) and were treated for hypotension or shock.



In all cases, the lesion was located at the aortic isthmus.

A 26-year-old woman was admitted after a fall from 15 meters. CT scan revealed a blunt aortic disruption at the level of the proximal thoracic aorta (aortic isthmus), slightly distal to the left subclavian artery. The patient was unstable and therefore immediately transferred to the operating room. She underwent successful endovascular stent grafting (22 x 22 x 150 mm Relay® endoprosthesis) of the ruptured thoracic aorta. The patient had multiple fractures, as well as hemothorax and liver contusion. She was discharged 54 days after surgery.

#### 2.4.4 Cases 22-24: Aortobronchial fistula (1) and aortoesophageal fistula (2)

The patient with the aortobronchial fistula presented with massive (>400 cc) hemoptysis and hypotension. The other 2 patients were evaluated for hematemesis, malaise, and sudden hypotension.

A 55-year-old male was referred to our hospital for evaluation of massive hemoptysis. CT with intravenous contrast revealed a ruptured para-anastomotic pseudo-aneurysm in the descending thoracic aorta. Intra-operative angiography confirmed the presence of an aortobronchial fistula at the site of the pseudo-aneurysm (Figure 5).

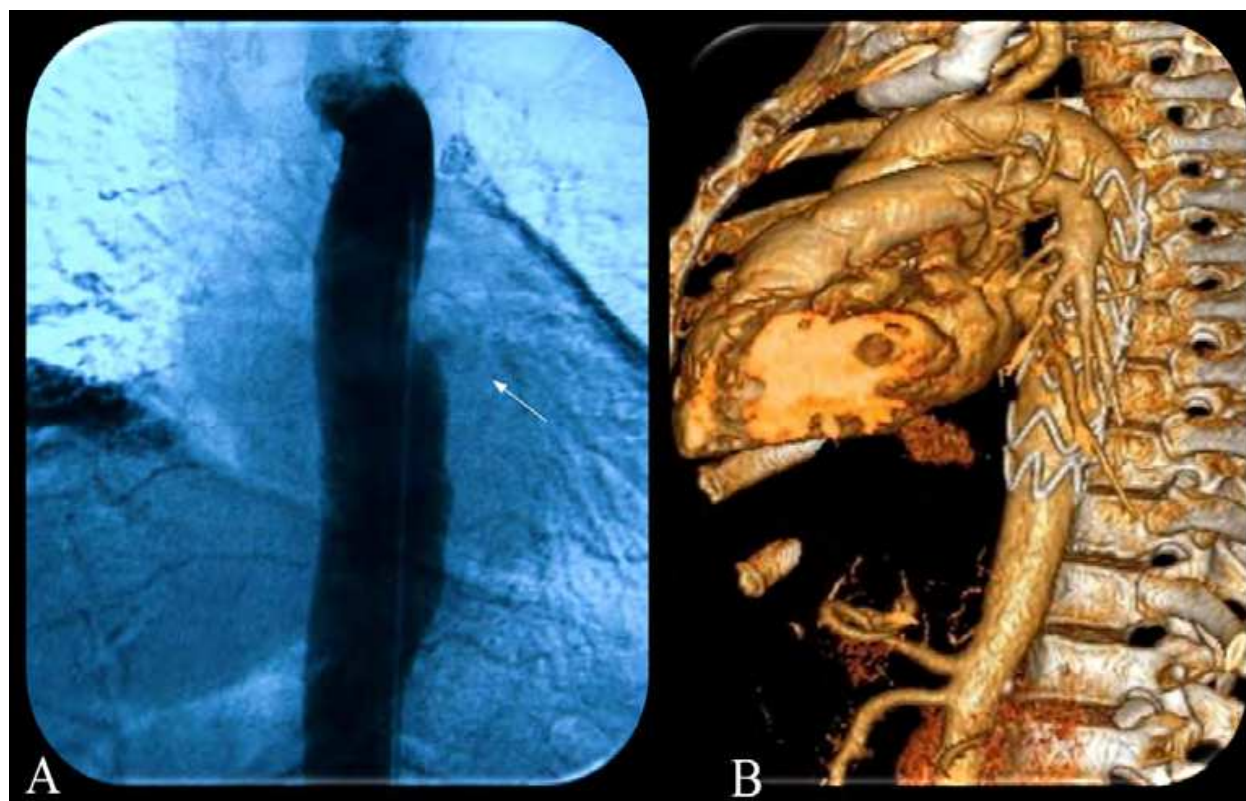


Fig. 5. Case 22. A, Aortography showing an aortobronchial fistula (arrow) at the site of a thoracic pseudoaneurysm. B, Computed tomography scan showing accurate placement of endoprosthesis with successful exclusion of the aortobronchial fistula (B).

A 74-year-old man was referred to our hospital for evaluation of massive hematemesis and hypotension. Preoperative assessment was with blood samples and chest X-ray. A CT scan revealed a descending thoracic aneurysm measuring 100 mm in diameter. This aneurysm was displacing the esophagus (Figures 6 and 7). In the emergency department, the patient

became hemodynamically unstable and was transferred to the operating room. He underwent successful endovascular stent grafting (36 x 36 x 200 and 36 x 36 x 145-mm Relay® endoprostheses). The patient died of a massive myocardial infarction on the third day after surgery.

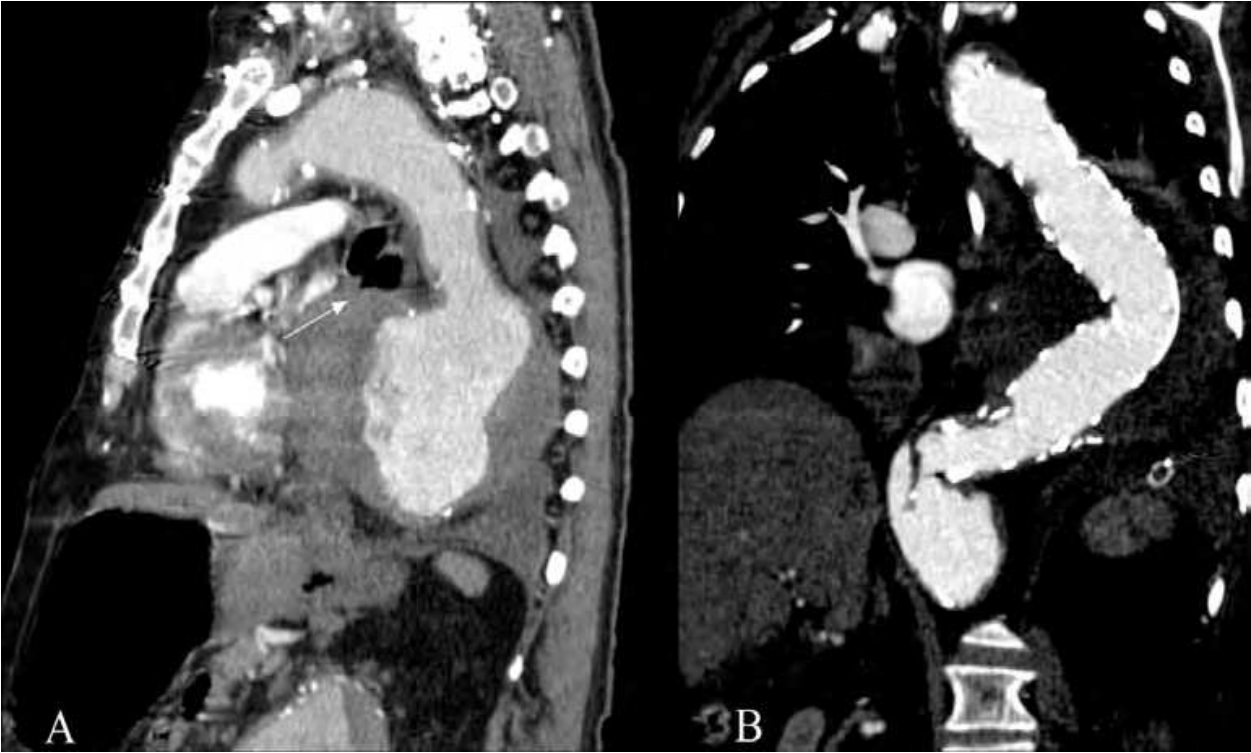

Fig. 6. Case 23. A, Chest computed tomography scan showing complete contact between a thoracic aortic aneurysm (10 cm in diameter) and the esophagus (arrow), causing an aortoesophageal fistula. B, Computed tomography scan showing accurate placement of endoprosthesis (postoperative day 2), with successful exclusion of the aortoesophageal fistula and aneurysm.

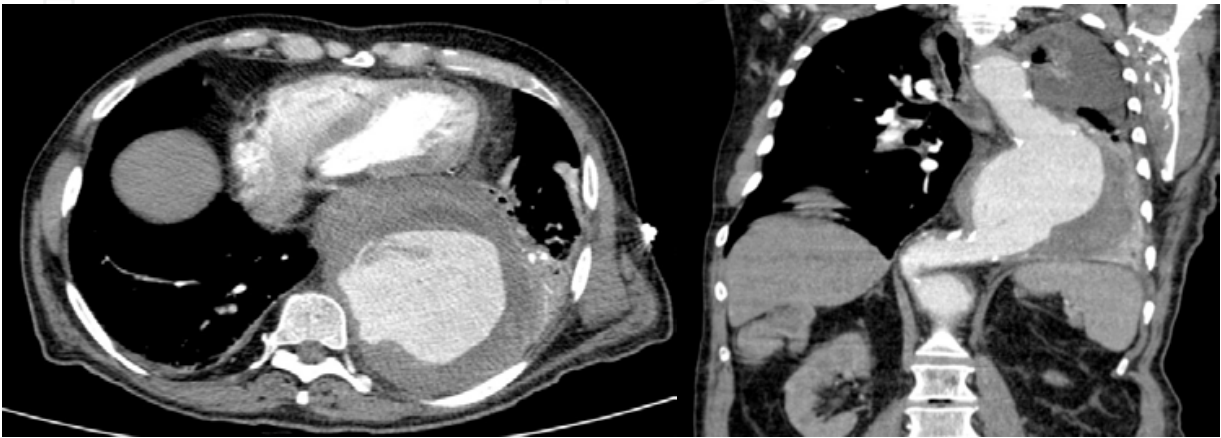


Fig. 7. Case 23. Upper: Chest computed tomography scan (transverse view) showing the thoracic aortic aneurysm measuring 10 cm in diameter. Lower: Computed tomography scan in a coronal view.

### 2.4.5 Case 25: Subclavian symptomatic pseudoaneurysm (1)

A 70-year-old Chinese man with a significant history of hypertension and smoking was referred to our hospital for evaluation of intermittent hemoptysis. On admission, he presented hemoptysis (>300 cc) and dyspnea. CT scan revealed a pseudoaneurysm measuring 30 mm x 20 mm at the origin of the left subclavian artery and in contact with the left pulmonary apex (Figure 8). The patient experienced 2 new episodes of massive hemoptysis with progressive anemia and was transferred immediately to the operating room. A Relay® covered self-expandable thoracic endoprosthesis (36 mm x 36 mm x 145-mm) was successfully placed distal to the origin of the left common carotid artery and covering the left subclavian artery. A 16-mm Amplatzer® vascular plug (AGA Medical Corporation, Plymouth, Minnesota, USA) was inserted through the left brachial artery to occlude the left subclavian artery without covering the left vertebral artery. Serology and culture studies were negative.

The patient was discharged 13 days after the endovascular procedure. Follow-up was scheduled at 1, 6, and 12 months, and yearly thereafter. His latest examination revealed the recovery of left brachial and distal pulses.

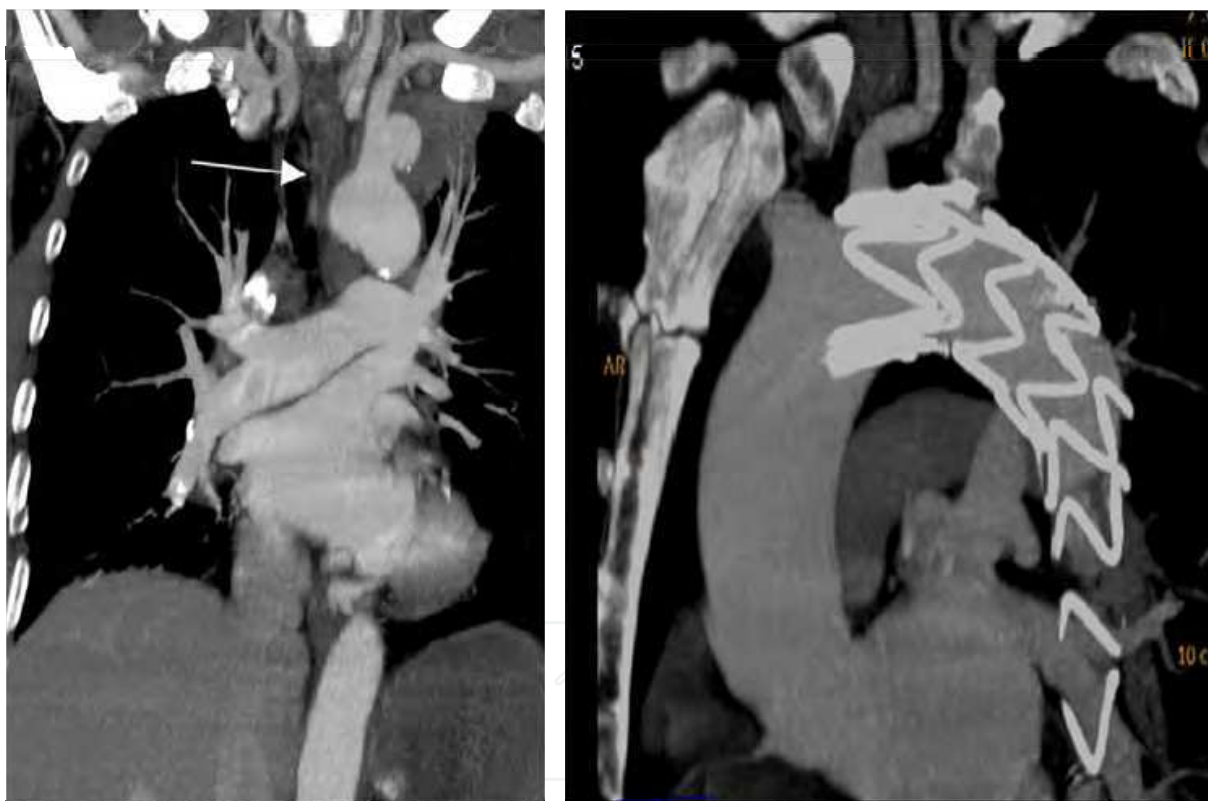

Fig. 8. Case 25. Left: Computed tomography scan revealing a pseudoaneurysm measuring 30 mm x 20 mm (arrow) at the origin of the left subclavian artery. Right: Computed tomography scan revealing accurate placement of endoprosthesis and 16-mm Amplatzer plug, with successful exclusion of the pseudoaneurysm (right).

## 3. Results

A total of 41 endografts were implanted. Median diameter and length were 36 mm (range, 22-46 mm) and 135 mm (range, 100-200 mm), respectively. The characteristics of the endografts and types of lesion are described in Table 3.



Lesions were excluded by 1 stent graft in 15 patients (60%, table 2), by 2 stent grafts in 4 patients (16%), and 3 stent grafts in 6 patients (24%).  
The stent grafts were all deployed at the intended position, which was predominantly in the distal aortic arch or proximal descending aorta, necessitating complete coverage of the ostium of the left subclavian artery in 6 of 25 patients (24%).

Case	Type of stent graft	Size (mm)	Length (mm)	No. of grafts	LSA coverage
1	TALENT	36 x 36	200	1	Yes
2	VALIANT	34 x 34	150	1	Yes
3	TALENT	36 and 34	112 and 115	2	No
4	TALENT	34, 38, and 42	115, 114, 113	3	No
5	VALIANT	30, 32, and 34	200, 150, 120	3	Yes
6	TALENT	46 x 42	110	1	No
7	TALENT	34 x 34	100	1	No
8	TALENT	46 and 42	113	2	No
9	TALENT	36, 38, and 38	115, 115, 115	3	Yes
10	VALIANT	38, 38, and 38	150, 100, 100	3	No
11	VALIANT	36 and 32	150 and 150	2	No
12	RELAY	38, 36, and 32	200, 130, 130	3	No
13	RELAY	34 x 34	200	1	No
14	VALIANT	38 x 38	200	1	No
15	TALENT	34 x 34	130	1	No
16	VALIANT	42, 44, and 46	150, 100, 100	3	No
17	RELAY	26 x 26	155	1	Yes
18	ANEURX	40 x 40	120	1	No
19	TALENT	28 x 24	113	1	No
20	RELAY	22 x 22	150	1	No
21	TALENT	24 x 24	113	1	No
22	TALENT	30 x 30	130	1	No
23	RELAY	36 and 36	200 and 145	2	No
24	TALENT	34 x 34	150	1	No
25	RELAY	36 x 36	145	1	Yes

Table 3. Stent graft and endovascular procedure

LSA: Left subclavian artery.

Technical success, defined as correct stent placement and accurate coverage of the affected site, was achieved in all 25 patients (100%).

One patient required a proximal extension for a proximal type I endoleak 4 days after the procedure. One patient with a traumatic (blunt) aortic disruption required a proximal extension 20 days after the endovascular procedure for a proximal type I endoleak.

Intraoperative mortality was 4% (1 patient who was in severe shock before surgery and died during stent graft implantation from a ruptured thoracic aneurysm).

There was no conversion to open thoracotomy and no incidence of paraplegia after surgery.

Median length of hospital stay was 18 days (range, 6-60 days).

### 3.1 Mortality

Overall hospital and 30-day mortality was 20% (n = 5). One patient (4%) died during surgery.

Two patients died during their hospital stay due to multiorgan failure (after 17 and 80 days, respectively). One patient died of cardiorespiratory failure (postoperative day 15). One patient (treated for an aorto-esophageal fistula) died on the third day after surgery of a massive myocardial infarction.

### 3.2 Follow-up

Follow-up was scheduled at 1, 6, and 12 months and yearly thereafter. Patients with endoleaks (type II) were followed closely at 3 to 6 months. Mean follow-up was 51 months (range, 4-96 months). Nineteen patients were followed up, 1 was lost to follow-up, and 5 died in hospital.

Two patients (8%) died after discharge from hospital.

One patient died of a cerebral hemorrhage after 8 months, the other died of an aorto-esophageal fistula 4 months after discharge.

Overall survival at 1 year was 72%. At the time of writing, 17 patients are still alive, with no evidence of new leaks, device migration, or other complications.

One patient treated for an acute type B dissection required a proximal stent graft extension for a type I endoleak after 12 months. One patient (previously treated for an acute type B dissection) required a left renal angioplasty and stent for renal stenosis and hypertension after 13 months. One patient (treated for an intramural hematoma) required a distal stent graft after 48 months to repair postdissection sac growth.

Although we had to cover the ostium of the left subclavian artery in 6 of 25 patients (24%), it was not necessary to revascularize the left subclavian artery, as no arm ischemia or vertebro-basilar ischemia was detected.

According to the definitions of Chaikof et al. (Chaikof et al, 2002), primary technical success was 80%.

Table 4 shows results in terms of mortality and follow up.

## 4. Discussion

Vascular lesions and injuries to the thoracic aorta are associated with very high morbidity and mortality. Many patients with severe injuries die at the scene of the accident before being diagnosed or are severely ill on arrival at the emergency department.



CASES	DIAGNOSIS	Intraoperative Mortality	30- day Mortality	FOLLOW UP (months)
1	DISSECTION	No	No	48
2	DISSECTION	No	No	72
3	DISSECTION	No	No	72
4	DISSECTION	No	No	72
5	DISSECTION	No	No	8
6	PENETRATING ULCER	No	No	84
7	PENETRATING ULCER	No	No	72
8	INTRAMURAL HEMATOMA	No	No	72
9	INTRAMURAL HEMATOMA	No	No	60
10	RUPTURED TAA	No	No	60
11	RUPTURED TAA	Yes	Yes	
12	RUPTURED TAA	No	No	4
13	RUPTURED TAA	No	No	12
14	RUPTURED TAA	No	Yes- Day 80	
15	PSEUDOANEURYSM	No	Yes- Day 17	
16	PSEUDOANEURYSM	No	No	36
17	PSEUDOANEURYSM	No	No	36
18	TRAUMATIC DISRUPTION	No	No	84
19	TRAUMATIC DISRUPTION	No	No	72
20	TRAUMATIC DISRUPTION	No	No	36
21	TRAUMATIC DISRUPTION	No	No	6
22	AORTOBRONCHIAL FISTULA	No	No	96
23	AORTOESOPHAGEAL FISTULA	No	Yes- Day 15	
24	AORTOESOPHAGEAL FISTULA	No	Yes- Day 3	
25	SUBCLAVIAN PSEUDOANEURYSM	No	No	20

Table 4. Intra- postoperative mortality and follow up.

Endovascular repair of a ruptured thoracic aorta was initiated in the mid-nineties. Dake et al. presented one of the first series of endovascular stent grafts for the treatment of descending thoracic aortic aneurysms in 1994 (Dake et al., 1994). Since then, several authors have reported successful endovascular treatment of both chronic and acute lesions of the thoracic aorta (Dake, 2001; Kato et al., 1997; Fujikawa et al., 2001; Lachat et al., 2002; Czermak et al., 2002; Amabile et al., 2004; Dunham et al., 2004; Hoornweg et al., 2006; Alsac et al., 2008; Kaya et al., 2009). Despite advances in surgical techniques, surgery for acute thoracic aortic rupture is associated with high morbidity and mortality rates (Doss et al., 2003; Dake et al., 1994). Open thoracic aortic repair carries the risk of severe complications affecting the heart, lungs, kidneys, and nervous system (spinal cord ischemia), with frequencies as high as 50%

(Lachat et al., 2002). Mortality rates for elective open surgical repair of descending thoracic aortic aneurysm have been reported at 3-12%. Most reports, however, are from high-volume centers of excellence and national referral centers; therefore, the results may not reflect the actual experience worldwide (Schermerhorn et al., 2008).

Ruptured descending thoracic aortic aneurysm (rDTAA) is a cardiovascular catastrophe, associated with high morbidity and mortality. The vast majority of patients who suffer from rDTAA die before they reach hospital (Johansson et al., 1995). rDTAA is less common than aortic dissection and traumatic aortic rupture, and the treatment of choice in most centers is thoracic endovascular aortic repair (TEVAR).

Open surgical repair of rDTAA presents very high mortality rates and is only feasible in referral centers. Mortality rates for open surgery vary from 30% to 60% depending on the series (Jonker et al., 2011).

Patients with rDTAA treated with TEVAR present lower mortality rates, although morbidity is also high. Recent reports present 30-day mortality rates of 15%-20%. Only highly specialized centers have reported mortality rates of between 25% and 30% after open repair of rDTAA (Jonker et al., 2010; Estrera et al., 2001). A recent comparative study by Patel and colleagues showed a 30-day mortality of 11.4% after TEVAR compared with 26.5% after open repair of ruptured thoracic aortic dissections and aneurysms (Patel et al., 2009). In endovascular repair of descending thoracic aortic aneurysms, the incidence rates of paraplegia and stroke usually range from 1% to 6% and from 2.5% to 5%, respectively. The risk of neurological complications may increase after endovascular repair of rDTAA, although it is still lower than that of open repair. The incidence of paraplegia and stroke after conventional surgical treatment of rDTAA may be as high as 12.5% and 25% (Jonker et al., 2011; Barbato et al., 2007), providing even greater support for endovascular treatment of rDTAA.

Although TEVAR is currently the most appropriate approach for the management of this often-fatal lesion, endovascular repair of rDTAA is still associated with considerable rates of neurological complications and procedure-related complications such as endoleak.

In our series, mortality for thoracic endovascular aortic repair in the ruptured thoracic aneurysm group was high (2 patients out of 5: 40%). Previous medical comorbidities and severe preoperative shock were determinant factors.

The prevalence of intramural hematoma in patients with acute aortic syndrome is 10%-20%, and approximately 10% of patients with symptomatic intramural hematoma develop aortic rupture. The signs of disease progression include aortic diameter  $\geq 40$  mm and thickening of the aortic wall  $\geq 10$  mm. Close surveillance in these patients is critical (Geisbüsch et al., 2008).

The prevalence of penetrating aortic ulcer among patients presenting with acute aortic syndrome is about 2%-8%. Although frequently causing the same symptoms, penetrating aortic ulcer and classic aortic dissection must be distinguished, as they differ in their natural course. The rupture rate in symptomatic penetrating aortic ulcer is reported to be as high as 40% compared to 4% in Stanford type B dissection. Therefore, urgent repair is required in symptomatic cases (Geisbüsch et al., 2008; Tittle et al., 2002; Coady et al., 1996; Ganaha et al., 2002). Signs of progression of this condition include aortic ulcer diameter  $> 20$  mm and ulcer depth  $> 10$  mm. Close surveillance is essential.

Early mortality after TEVAR in penetrating aortic ulcer is reported at 0%-11%. Medium-term outcomes have been published, with 1-, 3-, and 5- year survival rates of 85%, 75%, and 60%, respectively (Geisbüsch et al., 2008; Botta et al., 2008; Demers et al., 2004).

In 2007, Estrera et al. published their series of 159 patients treated for acute type B aortic dissection. They concluded that mortality associated with complicated dissection was 17%. In contrast, 53% of patients with uncomplicated dissection were managed medically, with a mortality rate of only 1.2% (Estrera et al., 2007).

TEVAR should now be considered the gold standard for complicated acute type B thoracic dissections and symptomatic penetrating ulcers.

In our series, the acute aortic syndrome group was quite homogeneous as regards age, initial presentation, postoperative period, and outcome. There was no in-hospital mortality, with 90% of patients alive during a mean follow-up of 62 months (range, 8-84 months).

Traumatic aortic injury is the second commonest cause of death in patients after blunt injury; autopsy reveals that 15%-30% of deaths from blunt trauma involve aortic transection (Thompson & Morgan., 2009; Shorr, 1987). Traumatic thoracic aortic rupture is a potentially lethal injury and leads to immediate death in 75%-90% of cases. Only about 10%-20% of victims reach the hospital alive.

The most common site of aortic injury is the isthmus, where the relatively mobile thoracic aorta joins the fixed arch. Aortic rupture occurs at this site in 80% of pathological series and in 90% of the clinical series (Thompson & Morgan., 2009).

Despite advances in surgical techniques, in emergency settings, open surgical repair of aortic rupture is still associated with a mortality rate of 18%-67% (Steingruber et al., 2007, Karmy-Jones et al. 2003; Richens et al., 2002; Williams et al., 1994).

Most series report the technical success of TEVAR to be 81.1-100%, with a paraplegia rate of 0%. These series present low mortality and morbidity rates, with accompanying injuries as primary causes of morbidity and mortality (Urgnani et al., 2009, Neuhauser et al., 2004; Rousseau et al., 2005).

Our results revealed considerable age differences between the traumatic (blunt) aortic rupture group and the other groups. This is due to the type of injury, which commonly occurs in young patients after high velocity trauma such as car accidents or falls from great heights. These patients commonly present multiple extremity and other fractures, vertebral or spinal cord injuries, and lung and visceral contusions, thus increasing the already high postoperative mortality.

In spite of the many benefits in the short and medium terms, the long-term results of endovascular repair of traumatic aortic rupture remain a major issue in these relatively young patients. In the future, we expect to see the development and use of stent grafts specifically designed to treat aortic trauma.

We present our experience with endovascular repair of thoracic aortic emergencies. Some of the cases we report are very unusual and therefore challenging, in terms of both diagnosis and treatment.

In several cases the presenting symptom was hemoptysis. In patients with massive hemoptysis, lesions in the intrathoracic large vessels, including the supra-aortic arteries, must be considered in the differential diagnosis. Moreover, in patients with previous aortic surgery and hemoptysis, the physician must have a high index of suspicion (Kopp et al., 2009).

Aortobronchial fistula and aortoesophageal fistula can be difficult to diagnose and extremely complex to treat. These conditions are often devastating, and the results of surgery are usually very poor. Endovascular repair provides an alternative to very complex open surgical repair. Very few series in the literature analyze endovascular repair of these complex lesions, and data are mostly from case reports or small series.

Open surgery entails high morbidity and mortality, and mortality rates range from 25% to 60% (Thompson et al., 2002; Piciche et al., 2003; Liu et al., 2004).

As regards endovascular repair of aortobronchial fistula, a review of the literature revealed less than 60 cases treated using endovascular repair. These were all from small series (Wheatley et al., 2007; Pirrelli et al., 2006; Ribé et al., 2010).

Initial results are encouraging, with 30-day mortality rates below 10%; however, larger series with longer-term follow-up are still required (Pirrelli et al., 2006).

Both our results and those published in the literature indicate that endovascular repair of thoracic aortic emergencies is a promising approach.

In some acute conditions, such as complicated type B thoracic dissections or ruptured thoracic aortic aneurysms, endovascular repair must be considered the treatment of choice. Larger series and longer follow-up are required for future assessment of these conditions.

## 5. Conclusion

Endovascular therapy may now be considered the first-line treatment for thoracic aortic emergencies, especially for ruptured thoracic aortic aneurysms and acute complicated dissections.

Endovascular procedures reduce morbidity and mortality in patients with acute thoracic aortic lesions, and must therefore be considered the gold standard in these situations.

## 6. References

- Achneck, HE.; Rizzo, JA.; Tranquilli, M. & Elefteriades, JA. Safety of thoracic aortic surgery in the present era. *The Annals of Thoracic Surgery*, Vol.84, (2007), pp. 1180-5.
- Alsac, JM.; Boura, B.; Desgranges, P.; Fabiani, JN.; Becquemin, JP. & Leseche, G. Immediate endovascular repair for acute traumatic injuries of the thoracic aorta: a multicenter analysis of 28 cases. *The Journal of Vascular Surgery*, Vol.48, No.6, (December 2006), pp. 1369-74.
- Amabile, P.; Collart, F.; Gariboldi, V.; Rollet, G.; Bartoli, JM. & Piquet, P. Surgical versus endovascular treatment of traumatic thoracic aortic rupture. *The Journal of Vascular Surgery*, Vol.40, (2004), pp. 873-9. ISSN 1555-7899.
- Barbato, JE.; Kim, JY.; Zenati, M.; bu-Hamad, G.; Rhee, RY.; Makaroun, MS. & Cho, JS. Contemporary results of open repair of ruptured descending thoracic and thoracoabdominal aortic aneurysms. *The Journal of Vascular Surgery*, Vol.45, (2007), pp. 667-676. ISSN 1739-8375.
- Botta, L.; Buttazzi, K.; Russo, V.; Parlapiano, M.; Gostoli, V.; Di Bartolomeo, R. et al. Endovascular repair for penetrating atherosclerotic ulcers of the descending thoracic aorta: early and mid-term results. *The Annals of Thoracic Surgery*, Vol.85, (2008), pp. 987-92. ISSN 1829-1184.
- Bozinovski, J. & Coselli, JS. Outcomes and survival in surgical treatment of descending thoracic aorta with acute dissection. *The Annals of Thoracic Surgery*, Vol.85, (2008), pp. 965- 71.
- Buz, S.; Zipfel, B.; Mulahasanovic, S.; Pasic, M.; Weng, Y. & Hetzer, R. Conventional surgical repair and endovascular treatment of acute traumatic aortic rupture. *European Journal of Cardiothoracic Surgery*, Vol.33, (2008), pp. 143- 151.



- Coady, MA.; Rizzo, JA.; Hammond, GL.; Pierce, JG.; Kopf, GS. & Elefteriades, JA. Penetrating ulcer of the thoracic aorta: what is it? How do we recognize it? How do we manage it? *The Journal of Vascular Surgery*, Vol.27, (1998), pp. 1006-15. ISSN 9652462.
- Cowley, RA.; Turney, SZ.; Hankins, JR.; Rodriguez, A.; Attar, S & Shankar, BS. Rupture of thoracic aorta caused by blunt trauma. A fifteen-year experience. *Journal of Thoracic and Cardiovascular Surgery*, Vol.100, (1990), pp. 652-660.
- Czermak, BV.; Waldenberger, P.; Perkmann, R.; Rieger, M.; Steingruber, IE.; Mallouhi, A. et al. Placement of endovascular stent grafts for emergency treatment of acute disease of the descending thoracic aorta. *AJR Am J Roentgenol*, Vol.179, (2002), pp. 337-45. ISSN 1213-0430.
- Dake, MD. Endovascular stent-graft management of thoracic aortic diseases. *European Journal of Radiology*, Vol.39, (2001), pp. 42-9. ISSN 1143-9230.
- Dake, MD.; Miller, DC.; Semba, CP.; Mitchell, RS.; Walker, PJ. & Liddell, RP. Transluminal placement of endovascular stent-grafts for the treatment of descending thoracic aortic aneurysms. *N Engl J Med*. Vol.331, No.26, (1994), pp. 1729-34. ISSN 798-4192.
- Demers, P.; Miller, DC.; Mitchell, RS.; Kee, ST.; Chagonjian, L. & Dake, MD. Stent-graft repair of penetrating atherosclerotic ulcers in the descending thoracic aorta: mid-term results. *The Annals of Thoracic Surgery*, Vol.77, (2004), pp. 81-6. ISSN 1472-6040.
- Demetriades, D.; Velmahos, GC.; Scalea, TM.; Jurkovich, GJ.; Karmy-Jones, R.; Teixeira, PG. et al. Operative repair or endovascular stent graft in blunt traumatic thoracic aortic injuries: results of an American Association for the Surgery of Trauma Multicenter study. *The Journal of Trauma*, Vol.64, (2008), pp. 561-71.
- Doss, M.; Balzer, J.; Martens, S.; Wood, JP.; Wimmer-Greinecker, G.; Fieguth, HG. & Moritz, A. Surgical versus endovascular treatment of acute thoracic aortic rupture: a single-center experience. *The Annals of Thoracic Surgery*, Vol.76, No.5, (November 2003), pp. 1465-9. ISSN 1460-2268.
- Dunham, MB.; Zygun, D.; Petrasek, P.; Kortbeek, JB.; Karmy-Jones, R. & Moore, RD. Endovascular stent grafts for acute blunt aortic injury. *The Journal of Trauma*, Vol.56 (2004), pp. 1173-8.
- Estrera, AL.; Miller, CC.; Goodrick, J.; Porat, EE.; Achouh, PE.; Dhareshwar, J.; Meada, R.; Azizzadeh, A. & Safi, HJ. Update on outcomes of acute type B aortic dissection. *The Annals of Thoracic Surgery*, Vol.83, No.2, (February 2007), pp. S842-5. ISSN 1725-7938.
- Estrera, AL.; Rubenstein, FS.; Miller, CC III.; Huynh, TT.; Letsou, GV. & Safi, HJ. Descending thoracic aortic aneurysm: surgical approach and treatment using the adjuncts cerebrospinal fluid drainage and distal aortic perfusion. *The Annals of Thoracic Surgery*, Vol.72, (2001), pp. 481-486. ISSN 1151-5886.
- Fujikawa, T.; Yukioka, T.; Ishimaru, S.; Kanai, M.; Muraoka, A.; Sasaki, H. et al. Endovascular stent grafting for the treatment of blunt thoracic aortic injury. *The Journal of Trauma*, Vol.205, (1997), pp. 657-62.
- Ganaha, F.; Miller, DC.; Sugimoto, K.; Do, YS.; Minamiguchi, H.; Saito, H. et al. Prognosis of aortic intramural hematoma with and without penetrating atherosclerotic ulcer: a clinical and radiological analysis. *Circulation*, Vol.106, (2002), pp. 342-8.




- Geisbüsch, P.; Kotelis, D.; Weber, TF.; Hyhlik-Dürr, A.; Kauczor, H. & Böckler, D. Early and midterm results after endovascular stent graft repair of penetrating aortic ulcers. *The Journal of Vascular Surgery*, Vol.48, No.6, (December 2008), pp. 1361-8. ISSN 1882-9235.
- Hoornweg, LL.; Dinkelmann, MK.; Goslings, JC.; Reekers, JA.; Verhagen, HJ.; Verhoeven, EL. et al. Endovascular management of traumatic ruptures of the thoracic aorta: a retrospective multicenter analysis of 28 cases in The Netherlands. *Journal of Vascular Surgery*, Vol.43 (2006), pp. 1096-102. ISSN 1676-5221.
- Johansson, G.; Markstrom, U. & Swedenborg, J. Ruptured thoracic aortic aneurysms: a study of incidence and mortality rates. *The Journal of Vascular Surgery*, Vol.21, (1995), pp. 985-958.
- Jonker, FH.; Verhagen, HJ.; Lin, PH.; Heijmen, RH.; Trimarchi, S.; Lee, WA.; Moll, FL. et al. Open surgery versus endovascular repair of ruptured thoracic aortic aneurysms. *The Journal of Vascular Surgery*, Vol.4, (Feb 2011). Epub ahead of print.
- Jonker, FH.; Verhagen, HJ.; Lin, PH.; Heijmen, RH.; Trimarchi, S.; Lee, WA.; Moll, FL. et al. Outcomes of endovascular repair of ruptured descending thoracic aortic aneurysms. *Circulation*, Vol.121, No. 25, (June 2010), pp. 2718-23. ISSN 2054-7930.
- Karmy-Jones, R.; Hoffer, E.; Meissner, MH.; Nicholls, S. & Mattos, M. Endovascular stent grafts and aortic rupture: a case series. *The Journal of Trauma*, Vol.55, (2003), pp. 805-10. ISSN 1460-8148.
- Kato, N.; Dake, MD.; Miller, DC.; Semba, CP.; Mitchell, RS.; Razavi, MK. et al. Traumatic thoracic aortic aneurysm: treatment with endovascular stent grafts. *Radiology*, Vol.50, (2001), pp. 223-9. ISSN 9393517.
- Kaya, A.; Heijmen, RH.; Rousseau, H.; Nienaber, CA.; Ehrlich, M. & Amabile, P. Emergency treatment of the thoracic aorta: results in 113 consecutive acute patients (the Talent Thoracic Retrospective Registry). *European Journal of Cardiothoracic Surgery*, Vol.35, No.2, (February 2009), pp. 276-81.
- Kopp, R.; Meimarakis, G.; Strauss, T.; Hatz, R.; Walter Jauch, K. & Wiggershauser, T. Combined supra-aortic extra-anatomic revascularization and endovascular hybrid procedure for recurrent hemoptysis caused by a symptomatic aneurysm of the right subclavian artery, *Vascular*. Vol.17, No.3, (May-June 2009), pp. 172-5.
- Lachat, M.; Pfammatter, T.; Witzke, H.; Bernard, E.; Wolfensberger, U.; Künzli, A. et al. Acute traumatic aortic rupture: early stent-graft repair. *European Journal of Cardiothoracic Surgery*, Vol.21, (2002), pp. 959-63.
- Liu, SF.; Chen, YC.; Lin, MC. & Kao, CL. Thoracic aortic aneurysm with aortobronchial fistula: a thirteen-year experience. *Heart & Lung*, Vol.33, No.2, (2004), pp. 119-23. ISSN 1502-4377.
- Neuhauser, B.; Czermak, B.; Jaschke, W.; Waldenberger, P.; Fraedrich, G. & Perkmann, R. Stent-graft repair for acute traumatic thoracic aortic rupture. *The American Surgeon*, Vol.70, (2004), pp. 1039-44. ISSN 1566-3041.
- Piciche, M.; DePaulis, R.; Fabbri, A. & Chiariello, L. Post-operative aortic fistulas into the airways: etiology, pathogenesis, presentation, diagnosis and management. *The Annals of Thoracic Surgery*, Vol.75, (2003), pp. 1998-2006. ISSN 1282-2663.

- Pirrelli, S.; Bozzani, A.; Arici, V. & Odero, A. Endovascular treatment of acute haemoptysis secondary to aortobronchial fistula. *European Journal of Vascular and Endovascular Surgery*, Vol.32, No.4, (2006), pp. 366-8.
- Ribé, L.; Río, J.; Portero, J.L. & Reparaz, L. Late survival after endovascular repair of an aortobronchial fistula. *European Journal of Vascular and Endovascular Surgery*, Vol.39, No.3, (March 2010), pp. 378. ISSN 1533-3167.
- Richens, D.; Field, M.; Neale, M. & Oakley, C. The mechanism of injury in blunt traumatic rupture of the aorta. *European Journal of Cardiothoracic Surgery*, Vol.21, No.2, (February 2002), pp. 288-93. ISSN 1182-5737.
- Rousseau, H.; Dambrin, C.; Marcheix, B.; Richeux, L.; Mazerolles, M.; Cron, C. et al. Acute traumatic aortic rupture: a comparison of surgical and stent-graft repair. *Journal of Thoracic and Cardiovascular Surgery*. Vol.129, (2005), pp. 1050-5. ISSN 15867779.
- Saratzis, N.; Melas, N.; Saratzis, A.; Lazaridis, J. & Kiskinis, D. Minimally invasive endovascular intervention in emergent and urgent thoracic aortic pathologies: single center experience. *Hellenic Journal of Cardiology*, Vol.49, No.5, (September-October 2008), pp. 312-319, ISSN 1884-6921.
- Schermerhorn, M.L.; Giles, K.A.; Hamdan, A.D.; Dahlberg, S.E.; Hagberg, R. & Pomposelli, F. Population-based outcomes of open descending thoracic aortic aneurysm repair. *The Journal of Vascular Surgery*, Vol.48, (2008), pp. 821- 7.
- Shorr, R.M.; Crittenden, M.; Indeck, M.; Hartunian, S.L. & Rodriguez, A. Blunt thoracic trauma. Analysis of 515 patients. *Annals of Surgery*. Vol.206, No.2, (August 1987), pp. 200-5.
- Steingruber, I.E.; Czermak, B.V.; Chemelli, A.; Glodny, B.; Bonatti, J. et al. Placement of endovascular stent-grafts for emergency repair of acute traumatic aortic rupture: a single-centre experience. *European Radiology*, Vol.17, No.7, (July 2007), pp. 1727-37. ISSN 1711-5167.
- Thompson, C.S.; Ramaiah, V.G.; Rodriguez-Lopez, J.A.; Vranic, M.; Ravi, R.; DiMugno, L. et al. Endoluminal stent-graft repair of aortobronchial fistulas. *The Journal of Vascular Surgery*, Vol.35, No.5, (2002), pp. 387-391. ISSN 1185-4740.
- Thompson, M. & Morgan, R. Thoracic and thoraco-abdominal aortic disease. *Vascular and endovascular surgery* (Fourth edition), Jonathan Beard & Peter Gaines, pp. 253-266, Saunders, London.
- Tittle, S.L.; Lynch, R.J.; Cole, P.E.; Singh, H.S.; Rizzo, J.A.; Kopf, G.S. et al. Midterm follow-up of penetrating ulcer and intramural hematoma of the aorta. *Journal of Thoracic and Cardiovascular Surgery*, Vol.123, No.6, (2002), pp. 1051-9. ISSN 1206-3450.
- Urgnani, F.; Lerut, P.; Da Rocha, M.; Adriani D.; Leon, F. & Rimbau, V. Endovascular treatment of acute traumatic thoracic aortic injuries: a retrospective analysis of 20 cases. *Journal of Thoracic and Cardiovascular Surgery*, Vol.138, No.5, (November 2009), pp. 1129-38. ISSN 1966-0375.
- Wheatley, G.H. 3<sup>rd</sup>; Nunez, A.; Preventza, O.; Ramaiah, V.G.; Rodriguez- Lopez, J.A.; Williams, J. et al. Have we gone too far? Endovascular stent-graft repair of aortobronchial fistulas. *Journal of Thoracic and Cardiovascular Surgery*, Vol.133, No.5, (2007), pp. 1277-85. ISSN 1746-7441.

Williams, JS.; Graff, JA.; Uku, JM. & Steinig, JP. Aortic injury in vehicular trauma. *The Annals of Thoracic Surgery*, Vol.57, No.3, (March 1994), pp. 726-30. ISSN 8147647.

IntechOpen

IntechOpen



## **Diagnosis and Treatment of Abdominal and Thoracic Aortic Aneurysms Including the Ascending Aorta and the Aortic Arch**

Edited by Prof. Reinhart Grundmann

ISBN 978-953-307-524-2

Hard cover, 208 pages

**Publisher** InTech

**Published online** 22, June, 2011

**Published in print edition** June, 2011

This book considers diagnosis and treatment of abdominal and thoracic aortic aneurysms. It addresses vascular and cardiothoracic surgeons and interventional radiologists, but also anyone engaged in vascular medicine. The book focuses amongst other things on operations in the ascending aorta and the aortic arch. Surgical procedures in this area have received increasing attention in the last few years and have been subjected to several modifications. Especially the development of interventional radiological endovascular techniques that reduce the invasive nature of surgery as well as complication rates led to rapid advancements. Thoracoabdominal aortic aneurysm (TAAA) repair still remains a challenging operation since it necessitates extended exposure of the aorta and reimplantation of the vital aortic branches. Among possible postoperative complications, spinal cord injury (SCI) seems one of the most formidable morbidities. Strategies for TAAA repair and the best and most reasonable approach to prevent SCI after TAAA repair are presented.

### **How to reference**

In order to correctly reference this scholarly work, feel free to copy and paste the following:

Lucas Ribé, Juan Luis Portero, Juan Vicente Sofis, Rosario García-Pajares, María Vila and Luis Manuel Reparaz (2011). Endovascular Repair of Thoracic Aortic Emergencies, *Diagnosis and Treatment of Abdominal and Thoracic Aortic Aneurysms Including the Ascending Aorta and the Aortic Arch*, Prof. Reinhart Grundmann (Ed.), ISBN: 978-953-307-524-2, InTech, Available from: <http://www.intechopen.com/books/diagnosis-and-treatment-of-abdominal-and-thoracic-aortic-aneurysms-including-the-ascending-aorta-and-the-aortic-arch/endovascular-repair-of-thoracic-aortic-emergencies>

**INTeCH**  
open science | open minds

### **InTech Europe**

University Campus STeP Ri  
Slavka Krautzeka 83/A  
51000 Rijeka, Croatia  
Phone: +385 (51) 770 447  
Fax: +385 (51) 686 166  
[www.intechopen.com](http://www.intechopen.com)

### **InTech China**

Unit 405, Office Block, Hotel Equatorial Shanghai  
No.65, Yan An Road (West), Shanghai, 200040, China  
中国上海市延安西路65号上海国际贵都大饭店办公楼405单元  
Phone: +86-21-62489820  
Fax: +86-21-62489821

© 2011 The Author(s). Licensee IntechOpen. This is an open access article distributed under the terms of the [Creative Commons Attribution 3.0 License](https://creativecommons.org/licenses/by/3.0/), which permits unrestricted use, distribution, and reproduction in any medium, provided the original work is properly cited.

IntechOpen

IntechOpen