

# We are IntechOpen, the world's leading publisher of Open Access books Built by scientists, for scientists

6,900

Open access books available

186,000

International authors and editors

200M

Downloads

Our authors are among the

154

Countries delivered to

TOP 1%

most cited scientists

12.2%

Contributors from top 500 universities



WEB OF SCIENCE™

Selection of our books indexed in the Book Citation Index  
in Web of Science™ Core Collection (BKCI)

Interested in publishing with us?  
Contact [book.department@intechopen.com](mailto:book.department@intechopen.com)

Numbers displayed above are based on latest data collected.  
For more information visit [www.intechopen.com](http://www.intechopen.com)



# Presentation of Abdominal Aortic Aneurysm in Clinical Practice, a Review

Simone Knaap<sup>1</sup> and Wayne Powell II<sup>2</sup>

<sup>1</sup>*Private practice, Borger,*

<sup>2</sup>*Private practice, Emmen  
The Netherlands*

## 1. Introduction

Patients with abdominal aortic aneurysms (AAA) may present with musculoskeletal pain patterns (Bassano, 2006). In approximately 7% to 8% of patients with low back pain (LBP), the cause is due to non-mechanical spinal conditions or visceral disease (Jarvik & Deyo, 2002). A contained retroperitoneal rupture of AAA is very rare, but may have a long history of less apparent clinical signs (Al-Koteesh et al., 2005). Approximately half of diagnosed AAAs are detected clinically; these are usually >5 cm in diameter (Beck et al., 2005). Accidental discovery is common when plain film radiographs are taken for evaluation of back pain. Ultrasonography of the abdomen is accurate and reliable in detecting AAAs (Fleming et al., 2005), but there needs to be a clinical reason before deciding to do these evaluations. This stresses the importance of a thorough history and physical examination.

## 2. Clinical history

It can be quite challenging to recognize the symptoms found in clinical history that support the need for a screening abdominal exam. Patients that do have an abdominal aortic aneurysm can present in three different categories. These categories consist of patients without significant symptoms, patients with symptoms due to a bulging AAA, and patients with symptoms due to a chronic contained ruptured AAA where the containment of the rupture keeps the leak slow enough as to not cause immediate death (Cates, 1997).

### 2.1 Aortic aneurysms without significant symptoms

The first category is obviously the most difficult to discover in clinical practice. Although most patients with AAA present with symptoms, 66%-75% of the cases of AAA are asymptomatic (Beck et al., 2005; Crawford et al., 2003, de Boer et al., 2010). What is even more disturbing is the fact that there is a considerable amount of patients with a chronic AAA rupture that have less than apparent clinical symptoms signifying the need for a screening for abdominal aortic aneurysms (Al-Koteesh et al, 2005). It is also unfortunate that most patients that have an asymptomatic AAA will remain asymptomatic until it finally ruptures. If they are fortunate, the size of the aneurysm draws the attention of the patient and physician prior to rupture (Crawford et al., 2003). Mass screening will benefit this group since this is the only way to detect these.

## 2.2 Symptomatic aortic aneurysm

In the second category, it is also difficult to discern between a patient that has an AAA and a patient that has another cause for the same complaint. Compared with non-inflammatory AAA, 65% to 90% of patients with inflammatory AAA are symptomatic (Ahlawat & Cuddihy, 2002). Some of these patients do present as patients having typical musculoskeletal problems and/or abdominal pain (Crawford et al, 2003). A feeling of fullness or heavy pulsations in the abdomen may be an early symptom (Crawford et al, 2003). Often, patients with this condition present with epigastric pain radiating into the flank/back region (Patel & Kettner, 2006). Sometimes patients with this sort of condition find it difficult to achieve a position which eases the pain (Mechelli et al, 2008). Other symptoms that a patient with AAA may have, include costovertebral angle pain, suprapubic pain, groin pain or leg pain (Hadida & Rajwani, 1998). Other patients may present with a dull constant aching pain paired with weight loss and occasional night sweats. These symptoms are generally considered “red flags” (Ahlawat & Cuddihy, 2002).

## 2.3 Chronic contained ruptured aneurysm

The third category is an emergency situation. Here again the symptoms are still the same, except there are added symptoms from the hypotension due to loss of blood. Depending on the rate of leaked blood from the rupture, the severity of the symptoms can differ. In general, the pain is severe in most patients, but atypical presentations are just as common. The symptoms can also vary depending on where the rupture is and what structures are compromised by the haematoma. For instance, a retroperitoneal haematoma that places stress on a iliopsoas muscle can very well cause irritation of the femoral nerve, making it appear a femoral neuropathy. This may imply that a patient presenting with a sensory deficit of the anterior thigh could be someone who is in need of an immediate medical referral (Ramasamy et al, 2001; Al-Koteesh et al, 2005). Symptoms can result from compression (e.g. ureter), erosion of vertebral bodies, or occlusion of blood supply (Hadida & Rajwani, 1998; Yokomuro et al, 2008).

These three categories demonstrate that in many cases the history alone gives no reliable information about a potential AAA. Many of these patients may very well end up presenting with low back pain and try various therapies to help lessen these conditions. It is also probable that there could be actual musculoskeletal symptoms at the same time as symptoms from an AAA. Other differential diagnoses include any abdominal pathology related to the structures compressed. It is suggested that the atherosclerotic plaques from someone with an AAA can increase risk of ischemia and thus lead also to disc degeneration (Al-Koteesh et al, 2005). This means that anyone presenting with degenerative disc disease symptoms could also have an underlying AAA that was the initial cause. Evaluating the risk factors in history is, therefore, very important.

## 3. Risk factors

In the clinical history, the presenting complaint gives information on the signs and symptoms. Since patients in primary contact practices do not necessarily present with symptoms that point directly to an abdominal aortic aneurysm (AAA), the review of systems and social history is of value in ‘case finding’. This is the consideration of unrelated or intercurrent illness in presenting patients due to the presence of the risk factors associated with, in this case, an abdominal aneurysm (Crawford, 2003).

Age, gender, smoking and family history are the most significant risk factors for developing an AAA (Brown & Powell, 1999; Lederle et al., 2000; Kuivaniemi et al., 2003). These alone are a reason to pay attention to abdominal palpation and auscultation in the physical examination (Mechelli et al., 2008). Apart from these risk factors, there are other characteristics that may be of significance, namely cardiovascular disease and its associated complicating factors like hypertension, hyperlipidemia and atherosclerosis (Patel & Kettner, 2006; Hadida & Rajwani, 1998; Mechelli et al., 2008). COPD, trauma, infectious and inflammatory conditions and autoimmune diseases causing cystic medial necrosis, have also been implicated (Van der Velde, 1998; Weston, 1995). Black race and diabetes have a negative association with AAA. (Lederle et al., 2000).

### 3.1 Age, gender and race

Most AAA deaths occur in men over 65 years of age (Mechelli et al., 2008; Fleming et al., 2005). AAA is considered uncommon under the age of 50 (Van der Velde, 1998). With aging, the aorta may be less able to withstand the force of the pulsatile blood flow, in which case dilatation can occur (Crawford et al., 2003). The prevalence increases with age. The prevalence rates in men range from 2-9.5% (Cates, 1997; Van der Velde, 1998). Lederle et al. (2000) found that the likelihood of discovering an AAA of 4 cm or larger increases for every 7 year interval of age (OR 1.71; 95% CI: 1.61-1.82).

There is a difference in age-related deaths between men and women. Whereas in men, it occurs mostly over the age of 65, in women this occurs on average around 10 years later (Scott 2002), with a peak approximately at the age of 80 (Mechelli et al., 2008). This may be because of the protective effect of oestrogen, which may delay the process leading to AAA until after the menopause (Van der Velde, 1998). Overall prevalence is 5 to 6 times greater in men than in women (Scott et al., 2002). The inflammatory variant of AAA has male-to-female ratios ranging from 30:1 to 6:1 (Ahlawat & Cuddihy, 2002). Aneurysms occur more often in Caucasian men (Karkos et al., 2000). Even though the prevalence is many times lower in women than in men, it is surprising to note that the risk of rupture is threefold higher in women than in men. This difference is independent of age, initial AAA diameter, and body mass index or height. The mean AAA diameter at rupture was 5 cm in women and 6 cm in men (Brown & Powell, 1999).

### 3.2 Smoking and lung function

Smoking is a primary risk factor for AAA: it increases AAA growth rates by 15% to 20% (Brady et al., 2004). A history of smoking in this context is defined as lifetime consumption of more than 100 cigarettes in a lifetime. Deaths associated with AAA have increased since the 1950s. Part of this can be explained by improved diagnostic methods, better surgical techniques and general aging of the population, but this does not explain the increase completely. The deaths parallel the increase of tobacco use in those decades (Crawford et al., 2003; Van der Velde, 1998). The excess prevalence associated with smoking accounts for approximately 75% of all AAA of 4.0 cm or greater (Lederle et al., 2000). There is a significant association between the amount of cigarettes currently smoked and the depth of inhalation and the risk of AAA. This risk increases with an increasing amount of cigarettes and deeper inhalation into the lungs (Franks et al., 1996). There is, however, no association for any blood marker of smoking.

Smoking is also the only modifiable factor in AAA. It increases the risk for AAA, but abstaining from smoking can slow the growth of the aneurysm (Brady et al., 2004).

Inflammatory AAA represents 3% to 10% of all AAAs. A significant percentage of patients with inflammatory AAA are active smokers, when compared to non-inflammatory AAA (Ahlawat & Cuddihy, 2002). There is an 8:1 preponderance of smokers compared to non-smokers (Cates, 1997).

Poor lung function and smoking go hand in hand; both influence the rate of rupture of an aneurysm. Smokers are considered to be less healthy in general than non-smokers: they exercise less and exercise reduces the risk for cardiovascular disease (Kawachi et al., 1993). Several studies have shown an association between poor lung function (lower mean FEV<sub>1</sub>) and AAA rupture (Brown & Powell, 1999; United Kingdom Small Aneurysm Trial Participants, 2002). Other studies report that after correction for number of years smoked, the connection between AAA rupture and COPD was lost and is not a risk factor (Lederle et al., 2000). Overall, patients that were former smokers after AAA surgery had a lower risk of death than those who reported that they were current smokers.

The mechanism by which smoking influences the development of an AAA is not known. It is thought that smoking influences the aortic elasticity negatively, which promotes AAA formation (Lederle et al., 2000). Increased amounts of the proteolytic enzymes collagenase and elastase have been observed in individuals that smoke as well as people with chronic obstructive pulmonary disease. This causes degradation of the aortic wall and atherosclerosis, thereby slowly weakening the aortic wall (Crawford et al., 2003; Lederle et al., 2000; Van der Velde, 1998; Cates, 1997).

### 3.3 Family history

Family history is an important issue. When considering patient history, special issues that require attention during a physical examination are easier to identify (Donahue, 1997). The probability of a patient having AAA is nearly twice that of someone without a (male) relative with a history of AAA (Lederle et al., 2000). It is found that a significantly higher percentage of patients with inflammatory AAA have a family history of AAA compared with patients with non-inflammatory AAA (Ahlawat & Cuddihy, 2002). Men who are first-degree relatives of a known aneurysm patient are especially at risk. Studies have reported prevalence rates of 12% to 33% in first-degree relatives (Crawford et al., 2003; Kuivaniemi et al., 2003; Van Vlijmen-van Keulen et al., 2002; Patel & Kettner, 2006).

The exact mode of inheritance is not known, but thought to be multifactorial with more than one environmental and genetic risk factor (Kuivaniemi et al., 2003). Defects are found in collagen type I and III or other components of the connective tissue matrix, elastin and fibrillin, the inflammatory cell-derived matrix metalloproteinase, their inhibitors, autoimmune components and components related to atherosclerosis. Some say there may be autosomal dominant inheritance; however, others say that the sex-chromosome linked susceptibility is thought to account for male predisposition (Van Vlijmen-van Keulen et al., 2002; Cates, 1997). Association of certain collagen diseases, such as Marfan's syndrome and Ehler-Danlos type IV syndrome do seem to suggest a gene defect (Van der Velde, 1998).

### 3.4 Other risk factors

Coexisting conditions like cardiovascular disease can have an influence on the elasticity of the arteries, thereby causing weakening of the aortic wall. In the case of inflammatory AAA, 10-47% of patients have been reported to have arterial occlusive disease (Ahlawat & Cuddihy, 2002). Several authors have reported the presence of cerebral arterial disease,



peripheral aneurysms or claudication as a sign in the clinical history demanding further questioning and examination. At least a third of patients with femoral or popliteal aneurysms will have an AAA (Karkos et al, 2000; Crawford et al., 2003; Patel & Kettner, 2006). Suspicion is raised when a patient comes in with low back pain and mentions a history of myocardial infarction (Crawford et al., 2003). A history of coronary artery disease also carries an increased risk (OR 1.52; 95% CI: 1.37 to 1.68)(Lederle et al., 2000). Hypertension and older age are more strongly associated with AAA than with coronary artery disease even though risk factors of coronary artery disease show overlap with those of AAA (Kishi et al., 1997). Hypertension is associated both with increased risk of rupture as well as increased prevalence of AAA. It is a continuing haemodynamic burden on the aortic wall, which may further weaken the aortic wall (Crawford et al., 2003; Brown & Powell, 1999). Higher systolic as well as diastolic blood pressure has been found in aneurysm patients. When combined with a history of smoking and a positive family history, the association becomes even stronger (Franks et al., 1996; Kishi et al., 1997). With uncomplicated hypertension, screening is generally not indicated, but in the case of low back pain, especially when no apparent cause is found, careful physical examination is indicated (Crawford et al., 2003). Since hypertension can be influenced, it is especially important to regulate blood pressure in patients with smaller AAAs. Hyperlipidemia and atherosclerosis generally increase the risk of complications within the cardiovascular system, and with this increases the risk of AAA (United Kingdom Small Aneurysm Trial Participants, 2002; Mechelli et al., 2008; Patel & Kettner, 2006). Medication is said to be necessary to reduce the rate of expansion of aneurysms, even though no medical treatment has shown to influence this rate over time (Thompson et al., 2009).

Diabetes actually decreases the risk for AAA, even though it increases the risk for atherosclerosis (Lederle et al., 2000; Brady et al., 2004). Its effect is not yet fully understood, but the release of proteolytic enzymes and cytokines is implicated and the inhibitory effect of diabetes on this process may be a factor in the pathogenesis of AAA (Golledge et al., 2008). Certain infectious and inflammatory conditions are known to weaken the aortic wall. Diseases like Takayasu's disease and Marfan's syndrome can cause cystic medial necrosis, also causing weakening of the aortic wall, which predisposes to aneurysms (Hadida & Rajwani, 1998).

#### 4. Signs in clinical examination

The usefulness of the clinical examination to detect AAA is limited. However, abdominal palpation and auscultation are important, especially when there is a suspicion of a non-mechanical or abdominal pathology for low back pain or when patients do not respond to the treatment. Most non-ruptured AAAs are asymptomatic, apart from a pulsating mass in the abdomen (Engel, 1996). There is a difference in chronic and acute rupture. Chronic is often misdiagnosed as back pain, spinal cord compression or more unusual presentations (Al-Koteesh et al, 2005). Acute rupture more often gives pain as described in the history findings.

Blood pressure in most cases will be either normal or high (Crawford et al., 2003; Hadida & Rajwani, 1998; Ahlawat & Cuddihy, 2002; Yokomuro et al, 2008; Cates, 1997). Pulse rate and rhythm are generally normal. In case of a ruptured aneurysm, there is often hypotension with a high pulse rate (Van der Velde, 1998).

On visual inspection, a pulsatile mass may be visible at or slightly above the umbilicus in the epigastrium (Patel & Kettner, 2006; Hadida & Rajwani, 1998). Ecchymosis may be present as an atypical finding. This may be somewhere over the abdomen, but can appear as low as the scrotum or popliteal fossa (Dargin & Lowenstein, 2008).

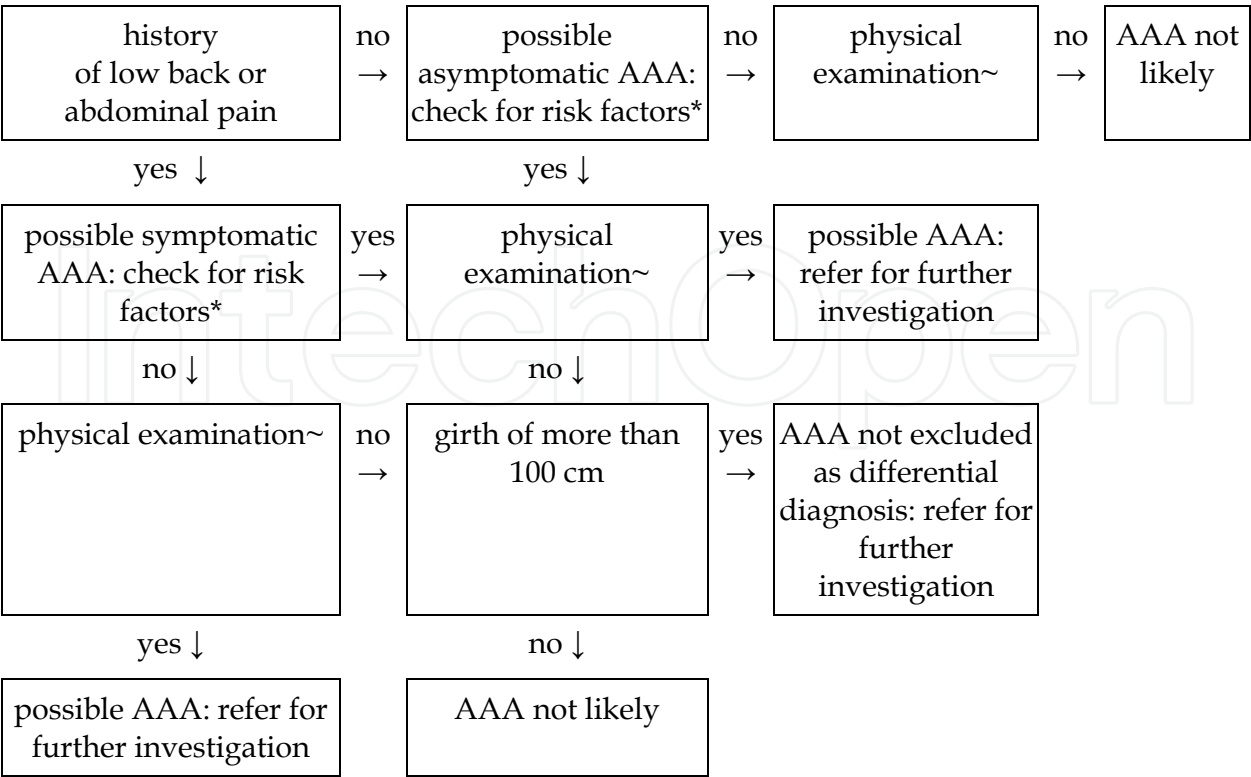
Palpation of the lower extremity pulses is also important, even though it is often unremarkable (Thorkeldsen, 1993; Yochum, 1994; Yokomuro et al, 2008; Donahue, 1997; Engel, 1996). Peripheral aneurysms increases suspicion of AAA; absent pulses may indicate atherosclerosis: another risk factor for AAA (Patel & Kettner, 2006; Pierce, 1998). The abdominal aorta can be palpated at or slightly above the umbilicus in the epigastrium in the supine position with the knees bent. In the case of AAA, a prominent and often nontender, mass with pulsations or thrills is felt in the coronal as well as the sagittal plane (Ahlawat & Cuddihy, 2002; Patel & Kettner, 2006; Hadida & Rajwani, 1998; Pierce, 1998). Pulsations of an AAA tend to push more laterally than anteriorly (Cates, 1997).

In thin people, an abdominal pulse can easily be felt. But the accuracy of detecting AAA is dependent upon the patient's girth as well as the size of the aneurysm. When the patient's girth is 100 cm or greater, very few AAAs are palpable. However, as aneurysm size increases, the chance of clinical detection increases. The sensitivity of detecting an AAA with a diameter greater than 5cm in a patient with an abdominal girth of less than 100cm is 100%, but this percentage decreases quickly with a smaller aneurysm (Fink et al., 2000). Karkos et al. (2000) found that physical examination missed more than a third of those detected radiologically, but they also say that clinical examination still plays a paramount role in the detection of AAAs. Physical examination cannot be relied upon to exclude AAA. If the history has enough signs and risk factors present, a referral for an ultrasound evaluation may be warranted (Lynch, 2004).

Another screening tool for AAA that is always mentioned is auscultation for an abdominal or femoral bruit. Lederle et al. found that it does not contribute to the diagnosis of AAA. It is, however, part of the routine in many case reports. A negative physical exam in a patient with a girth of more than 100 cm with risk factors of AAA present still warrants referral for ultrasound evaluation (Ahlawat & Cuddihy, 2002; Mechelli et al., 2008; Hadida & Rajwani, 1998; Pierce, 1998).

## **5. Implications for treatment of the accompanying musculoskeletal complaints**

The significance of AAA to the therapist treating the patient is the potential for rupture during treatment (Beck et al., 2005). In the case of a large AAA, lumbar spinal manipulative therapy is an absolute contra-indication. It is, however, likely that patients with smaller AAAs and mechanical low back pain are receiving spinal manipulative therapy. Knowing the prevalence of AAA, it seems reasonable to assume that many patients have been treated without detrimental effect. It is, however, important to modify the techniques for patients who are considered at high risk after history taking. It is advised to minimize torsional stress to the lumbar spine and use more graded mobilisation or manipulation during exhalation, to decrease the intra-abdominal pressure (Weston, 1995). In the clinical setting, management of patients with AAA is limited (Pierce, 1998). A delay in referral in order to offer a trial of spinal manipulative care is unacceptable (Crawford et al., 2003). Table 1 gives an outline of the steps to be taken in clinical practice.



~ physical examination includes: blood pressure, pulsating mass in abdomen, peripheral aneurysm  
\* risk factors include: age over 50, male gender, Caucasian, smoking, positive family history, co-existing cardiovascular disease

Table 1. Flow sheet Aortic Abdominal Aneurysm in clinical practice

6. Conclusion

Abdominal aortic aneurysms can be very difficult to identify. Careful history taking and case finding is important to decrease the chance of missing the diagnosis. Presentation can vary from totally asymptomatic to excruciating pain. Combining these with the risk factors gender, age, history of smoking and family history of AAA will furnish a good indication for the physical examination and possible referral for further screening.

7. Acknowledgement

We would like to acknowledge Mrs. Pam Powell for her proofreading and suggestions.

8. References


Ahlawat, S.K. & Cuddihy, M.T. (2002). 71-year-old woman with low back pain, *Mayo Clin Proc.* 77(8):849-52.



- Al-Koteesh, J., Masannat, Y., James, N.V.M. & Sharaf, U. (2005). Chronic Contained Rupture Of Abdominal Aortic Aneurysm Presenting With Longstanding Back Pain. *SMJ* 50(3): 122-123.
- Bassano JM. (2006). Abdominal calcifications and diagnostic imaging decision making: a topic review. *J Chiropr Med* 5(1):43-52.
- Beck, R.W., Holt, K.R., Fox, M.A. & Hurtgen-Grace, K.L. (2005). Radiographic anomalies that may alter chiropractic intervention strategies found in a New Zealand population. *J Manipulative Physiol Ther* 27(9):554-559.
- Brady, A.R., Thompson, S.G., Fowkes, F.G., Greenhalgh, R.M. & Powell, J.T., UK Small Aneurysm Trial Participants. (2004). Abdominal aortic aneurysm expansion: risk factors and time intervals for surveillance. *Circulation* 110(1):16-21.
- Brown, L.C. & Powell, J.T. (1999). Risk factors for aneurysm rupture in patients kept under ultrasound surveillance. UK Small Aneurysm Trial Participants. *Ann Surg* 230(3):289-96.
- Cates, J.R. (1997). Abdominal aortic aneurysms: clinical diagnosis and management. *J Manipulative Physiol Ther* 20(8):557-61.
- Crawford, C.M. (2003). Abdominal aortic aneurysm presenting as low back pain: a case report. *Chiropr J Aust* 33(3):83-8.
- Crawford, C.M., Hurtgen-Grace, K., Talarico, E. & Marley, J. (2003). Abdominal aortic aneurysm: an illustrated narrative review. *J Manipulative Physiol Ther* 26(3):184-95.
- Dargin, J.M. & Lowenstein, R.A. (2008). Ruptured Abdominal Aortic Aneurysm Presenting As Painless Testicular Ecchymosis: The Scrotal Sign of Bryant Revisited. *J Emerg Med* Jul 8. [Epub ahead of print]
- De Boer, N.J., Knaap, S.F.C. & De Zoete, A. (2010). Clinical detection of abdominal aortic aneurysm in a 74-year-old man in chiropractic practice. *J Chiropr Med* 9(1):38-41.
- Donahue, T.C. (1997). Low back pain that led to the discovery of an abdominal aneurysm. *J Sports Chiropr & Rehabil* 11(3):114-118.
- Engel, N. (1996). Abdominal Aortic Aneurysm and Low Back Pain. *Dynamic Chiropractic* 14(16).
- Fink, H.A., Lederle, F.A., Roth, C.S., Bowles, C.A., Nelson, D.B. & Haas, M.A. (2000). The accuracy of physical examination to detect abdominal aortic aneurysm. *Arch Intern Med* 160(6):833-6.
- Fleming, C., Whitlock, E.P., Beil, T.L., Lederle, F.A. (2005). Screening for abdominal aortic aneurysm: a best-evidence systematic review for the U.S. Preventive Services Task Force. *Ann Intern Med* 142(3):203-11.
- Franks, P.J., Edwards, R.J., Greenhalgh, R.M., Powell, J.T. (1996). Risk factors for abdominal aortic aneurysms in smokers. *Eur J Vasc Endovasc Surg* 11(4):487-92.
- Golledge, J., Karan, M., Moran, C.S., Muller, J., Clancy, P., Dear, A.E. & Norman, P.E. (2008). Reduced expansion rate of abdominal aortic aneurysms in patients with diabetes may be related to aberrant monocyte-matrix interactions. *Eur Heart J* 29(5):665-72.
- Hadida, C. & Rajwani, M. (1998). Abdominal aortic aneurysms: case report. *JCCA* 42(4):216-221.
- Jarvik, J.G. & Deyo, R.A. (2002). Diagnostic evaluation of low back pain with emphasis on imaging. *Ann Intern Med* 137(7):586-97.

- Karkos, C., Mukhopadhyay, U., Papakostas, I., Ghosh, J., Thomson, G. & Hughes, R. (2000) Abdominal aortic aneurysm: the role of clinical examination and opportunistic detection. *Eur J Vasc Endovasc Surg* 19(3):299-303.
- Kawachi, I., Colditz, G.A., Stampfer, M.J., Willett, W.C., Manson, J.E., Rosner, B., Hunter, D.J., Hennekens, C.H. & Speizer, F.E. (1993). Smoking cessation in relation to total mortality rates in women: a prospective cohort study. *Ann Intern Med* 119(10):992-1000.
- Kishi, K., Ito, S. & Hiasa, Y. (1997). Risk factors and incidence of coronary artery lesions in patients with abdominal aortic aneurysms. *Intern Med* 36(6):384-8.
- Kuivaniemi, H., Shibamura, H., Arthur, C., Berguer, R., Cole, C.W., Juvonen, T., Kline, R.A., Limet, R., Mackean, G., Norrgård, O., Pals, G., Powell, J.T., Rainio, P., Sakalihasan, N., van Vlijmen-van Keulen, C., Verloes, A. & Tromp, G. (2003). Familial abdominal aortic aneurysms: collection of 233 multiplex families. *J Vasc Surg* 37(2):340-5.
- Lederle, F.A., Johnson, G.R., Wilson, S.E., Chute, E.P., Hye, R.J., Makaroun, M.S., Barone, G.W., Bandyk, D., Moneta, G.L. & Makhoul, R.G. (2000). The aneurysm detection and management study screening program: validation cohort and final results. Aneurysm Detection and Management Veterans Affairs Cooperative Study Investigators. *Arch Intern Med* 160(10):1425-30.
- Lynch, R.M. (2004). Accuracy of abdominal examination in the diagnosis of non-ruptured abdominal aortic aneurysm. *Accid Emerg Nurs* 12(2):99-107.
- Mechelli, F., Preboski, Z. & Boissonnault, W.G. (2008). Differential diagnosis of a patient referred to physical therapy with low back pain: abdominal aortic aneurysm. *J Orthop Sports Phys Ther* 38(9):551-7.
- Patel, S.N. & Kettner, N.W. (2006). Abdominal aortic aneurysm presenting as back pain to a chiropractic clinic: a case report. *J Manipulative Physiol Ther* 29(5):409.e1-7.
- Pierce, S. (1998). Undisclosed medical history of a re-presenting patient: a case study. *BJC* 2(2):22-3.
- Ramasamy, P.R., Fox, D., Narendra, G., Carnie, L. & Watura, R. (2001). Chronic contained leak of abdominal aortic aneurysm presenting as lumbar neuropathy. *J R Coll Surg Edinb* 46(5):307-9.
- Scott, R.A., Bridgewater, S.G., Ashton, H.A. (2002) Randomized clinical trial of screening for abdominal aortic aneurysm in women. *Br J Surg* 89(3):283-5.
- Thompson, S.G., Ashton, H.A., Gao, L. & Scott, R.A.: Multicentre Aneurysm Screening Study Group. (2009). Screening men for abdominal aortic aneurysm: 10 year mortality and cost effectiveness results from the randomised Multicentre Aneurysm Screening Study. *BMJ* 338:b2307.
- Thorkelsen, A. (1993). Abdominal aneurysm: a case report. *Eur J Chir* 41:95-100.
- United Kingdom Small Aneurysm Trial Participants. (2002). Long-term outcomes of immediate repair compared with surveillance of small abdominal aortic aneurysms. *N Engl J Med* 346(19):1445-52.
- Van der Velde, G.M. (1998). Abdominal aortic aneurysm: two case reports and a brief review of its clinical characteristics. *JNMS* 6(2):76-83.

- Van Vlijmen-van Keulen, C.J., Pals, G. & Rauwerda, J.A. (2002). Familial abdominal aortic aneurysm: a systematic review of a genetic background. *Eur J Vasc Endovasc Surg* 24(2):105-16.
- Weston, J.P. (1995). Chiropractic management of abdominal aortic aneurysm: a case report. *JCCA* 39(2):75-79.
- Yochum, T.R. (1994). A case of life or death! *JNMS* 2(2):93-96.
- Yokomuro, H., Ichikawa, Y., Kajiwaru, H. (2005). Chronic Contained Rupture of Abdominal Aortic Aneurysm. *Asian Cardiovasc Thorac Ann* 16(6):e55-7.



## **Diagnosis and Treatment of Abdominal and Thoracic Aortic Aneurysms Including the Ascending Aorta and the Aortic Arch**

Edited by Prof. Reinhart Grundmann

ISBN 978-953-307-524-2

Hard cover, 208 pages

**Publisher** InTech

**Published online** 22, June, 2011

**Published in print edition** June, 2011

This book considers diagnosis and treatment of abdominal and thoracic aortic aneurysms. It addresses vascular and cardiothoracic surgeons and interventional radiologists, but also anyone engaged in vascular medicine. The book focuses amongst other things on operations in the ascending aorta and the aortic arch. Surgical procedures in this area have received increasing attention in the last few years and have been subjected to several modifications. Especially the development of interventional radiological endovascular techniques that reduce the invasive nature of surgery as well as complication rates led to rapid advancements. Thoracoabdominal aortic aneurysm (TAAA) repair still remains a challenging operation since it necessitates extended exposure of the aorta and reimplantation of the vital aortic branches. Among possible postoperative complications, spinal cord injury (SCI) seems one of the most formidable morbidities. Strategies for TAAA repair and the best and most reasonable approach to prevent SCI after TAAA repair are presented.

### **How to reference**

In order to correctly reference this scholarly work, feel free to copy and paste the following:

Simone Knaap and Wayne Powell II (2011). Presentation of Abdominal Aortic Aneurysm in Clinical Practice, a Review, Diagnosis and Treatment of Abdominal and Thoracic Aortic Aneurysms Including the Ascending Aorta and the Aortic Arch, Prof. Reinhart Grundmann (Ed.), ISBN: 978-953-307-524-2, InTech, Available from: <http://www.intechopen.com/books/diagnosis-and-treatment-of-abdominal-and-thoracic-aortic-aneurysms-including-the-ascending-aorta-and-the-aortic-arch/presentation-of-abdominal-aortic-aneurysm-in-clinical-practice-a-review>

**INTeCH**  
open science | open minds

### **InTech Europe**

University Campus STeP Ri  
Slavka Krautzeka 83/A  
51000 Rijeka, Croatia  
Phone: +385 (51) 770 447  
Fax: +385 (51) 686 166  
[www.intechopen.com](http://www.intechopen.com)

### **InTech China**

Unit 405, Office Block, Hotel Equatorial Shanghai  
No.65, Yan An Road (West), Shanghai, 200040, China  
中国上海市延安西路65号上海国际贵都大饭店办公楼405单元  
Phone: +86-21-62489820  
Fax: +86-21-62489821

© 2011 The Author(s). Licensee IntechOpen. This is an open access article distributed under the terms of the [Creative Commons Attribution 3.0 License](https://creativecommons.org/licenses/by/3.0/), which permits unrestricted use, distribution, and reproduction in any medium, provided the original work is properly cited.

IntechOpen

IntechOpen