

We are IntechOpen, the world's leading publisher of Open Access books Built by scientists, for scientists

6,900

Open access books available

186,000

International authors and editors

200M

Downloads

Our authors are among the

154

Countries delivered to

TOP 1%

most cited scientists

12.2%

Contributors from top 500 universities



WEB OF SCIENCE™

Selection of our books indexed in the Book Citation Index
in Web of Science™ Core Collection (BKCI)

Interested in publishing with us?
Contact book.department@intechopen.com

Numbers displayed above are based on latest data collected.
For more information visit www.intechopen.com



Audiovestibular Manifestations in Systemic Vasculitis: An Update

Juan Carlos Amor-Dorado¹ and Miguel Angel Gonzalez-Gay²

¹Otolaryngology Division, Hospital Lucus Augusti, Lugo,

²Rheumatology Division, Hospital Universitario Marques de Valdecilla, IFIMAV, Santander, Spain

1. Introduction

The term systemic vasculitis encompasses a group of diseases that were considered rare years ago. However, as knowledge of them has been expanded, there have become increasingly important in the differential diagnosis of patients with varied manifestations, not only rheumatological, but also with sensory and visceral affection in diverse locations, extent and severity.

This is a heterogeneous group of diseases that often overlap each other, with various etiologies and clinical manifestations. The common feature among them is the inflammation of the lining of blood vessels, which causes ischemic events and tissue necrosis, as well as the occlusion of the lumen of vessels and, consequently, impaired function of the affected organ [1].

Any blood vessel can be affected by the vasculitic phenomenon. Moreover, the extent and site of affection of the vessels varies depending on the type of vasculitis; in general, they tend to be irregular and segmental. In severe forms, lesions spread throughout the body. In mild forms, it can be located in a single region of the body; for example, limited to the skin in patients with cutaneous leukocytoclastic vasculitis. Others, however, cause lesions in several distant organs such as kidneys or lungs in patients with microscopic polyangiitis and Wegener's granulomatosis. Some types of vasculitis manifest with lesions in the same stage of development, as in the case of cutaneous lesions that appear with an outbreak of Henoch- Schönlein purpura. In others, such as polyarteritis nodosa, lesions that are at different stages of development in different organs. Some forms of vasculitis may have an acute course, mainly those with a predominantly skin involvement. In contrast, others such as Takayasu's arteritis have shown varying degrees of activity for over 20 years [1].

2. Audiovestibular manifestations in systemic vasculitis

The inner ear may be involved in organ-specific autoimmune diseases such as the autoimmune inner ear disease described by McCabe in 1979 and it may be the target organ in various non-organ specific systemic diseases. Among these, some are the result of direct autoimmune lesion and others of vascular damage which, in turn, can be primary or

secondary to infections or collagen diseases. The systemic vasculitis forms belong to the group of diseases that have vascular damage as the main pathogenic factor [2, 3].

Vasculitis	Audiovestibular manifestations
Primary vasculitis	
<i>Predominantly affecting large vessels</i>	
Giant cell arteritis	Partially reversible asymmetric sensorineural hearing loss Sudden hearing loss and tinnitus Partially reversible vestibular hypofunction in caloric testing (canal paresis) BPPV (PSC more frequent than HSC)
Takayasu’s arteritis	Sudden reversible hearing loss
<i>Predominantly affecting medium vessels</i>	
Classic Polyarteritis nodosa (PAN)	Sensorineural hearing loss or sudden hearing loss Vertigo, without vestibular function studies
Kawasaki disease	Reversible sensorineural hearing loss or conductive hearing loss
<i>Predominantly affecting medium and small vessels</i>	
Wegener’s granulomatosis	Otitis media with effusion or chronic otitis media with conductive hearing loss or sudden hearing loss or sensorineural hearing loss in audiometric test and tinnitus Central and peripheral nystagmus with vertigo
Churg-Strauss syndrome	Otitis media with effusion or suppurative otitis media due to tympanic perforation and sensorineural hearing loss in audiometric test
Microscopic polyangiitis	Sensorineural hearing loss or sudden hearing loss Vertigo, without vestibular function studies

Secondary vasculitis

Predominantly affecting medium and small vessels

Rheumatoid arthritis	Conductive hearing loss or sudden hearing loss with sensorineural hearing loss in audiogram
Scleroderma	Symmetrical and bilateral sensorineural hearing loss with a flat curve in the audiogram Middle ear dysfunction manifested by a flattened tracing in tympanometry BPPV (HSC more frequent than PSC). Abnormal head thrust test, head-shaking nystagmus and positional nystagmus
Systemic lupus erythematosus	Conductive hearing loss or sudden hearing loss
Sjögren’s syndrome	Conductive hearing loss or sudden sensorineural hearing loss
Ankylosing spondylitis	Symmetrical high frequency sensorineural hearing loss in audiogram Dysfunction of static postural control in CTSIB (conditions 5 and 6) Frequent BPPV and positional nystagmus
Behcet’s disease	Sensorineural hearing loss or sudden hearing loss Central and peripheral (mixed) vestibular syndrome

Other vasculitis

Cogan syndrome	Fluctuating sensorineural hearing loss with tinnitus and recurrent spontaneous vertigo
Relapsing polychondritis	Sensorineural hearing loss, tinnitus Peripheral vestibular syndrome

BPPV: benign paroxysmal positional vertigo; HSC: horizontal semicircular canal; PSC: posterior semicircular canal; PAN: panarteritis nodosa; CTSIB: Clinical Test for Sensory Interaction and Balance.

Table 1. Audiovestibular manifestations in systemic vasculitis

Interestingly, regardless of the etiology of the various diseases affecting the inner ear, pathological findings are identical. They include degeneration and destruction of the peripheral receptor; segmental and diffuse infiltration of lymphocytes, plasma cells, and

macrophages; proliferation of fibrous tissue, and varying degrees of ossification of the inner ear [4].

Next, we discuss the studies to date that have disclosed an association of vasculitis involvement with auditory and vestibular manifestations. Table 1 presents an update of the different audiovestibular manifestations described according to the classification of vasculitis.

3. Primary vasculitis

Giant cell arteritis (GCA) is a multisystemic vasculitis of elderly people. It mainly involves large and medium-sized blood vessels with predisposition to the cranial arteries. GCA constitutes the most common systemic vasculitis in Western countries. Some cranial ischemic manifestations, in particular permanent visual loss, have been widely described in patients with this vasculitis. However, audiovestibular manifestations in GCA patients, such as hearing loss, vertigo, or tinnitus, have been less commonly reported. It is also characterized by granulomatous affectation of the aorta and its major branches, with a predisposition towards the cranial area, both in the arterial branches arising from the external carotid (explaining the topical headaches) and the internal carotid artery, leading to the feared blindness, either by affectation of the posterior ciliary arteries or the central retinal artery. GCA is often present with temporoparietal pulsating headaches, different from the usual, which often accompanied by polymyalgia rheumatica and, to a lesser extent, jaw claudication, amaurosis fugax, blindness, or stroke predominantly in the vertebrobasilar territory [5-8]. The definitive diagnosis is obtained by a temporal artery biopsy demonstrating disruption of the internal elastic lamina with lymphocytic inflammatory infiltration and multinucleated giant cells in 50% of cases [9].

The last 4 decades have witnessed a significant increase in the number of diagnosed cases of GCA. This increase has not only been found in areas where GCA is common [10] but also here the incidence was low [11-13]. This fact can be explained by a greater awareness of the disease. In our population in Lugo of individuals older than 50, the incidence of GCA adjusted for age and gender is 10/100 000 inhabitants/year, but it reaches 23/100 000 inhabitants/year in the group of patients between 70 and 79 [14,15].

In a prospective study of 44 patients with GCA and 10 with isolated polymyalgia rheumatica from our Lugo population, in 39 (89%) of the 44 GCA patients only exhibited abnormalities in the vestibular tests when these were performed in the first four days at the onset of diagnosis and parenterally corticosteroid therapy. Our data suggest that the vestibule is very sensitive to the ischemic effects of the GCA. Also, they suggest that the vestibular damage may be reversible in some cases. With respect to this, only 13 (30%) of the 44 after 3 months of treatment and 1 patient after 6 months of follow-up had persistent vestibular impairment, coinciding with the start of treatment with steroids. The most significant vestibular finding observed at 3 months was parietic horizontal nystagmus in the head shaking nystagmus test. Moreover, although in our study a Dix-Hallpike test was found to be positive in 7% of the control population, this test yielded positive results in 21% of the biopsy-negative GCA and 33% of biopsy-positive GCA patients. This finding in GCA patients seems to be extremely high. It may suggest that in some cases the benign paroxysmal positional vertigo (BPPV) may be related to a vasculitic inflammatory disorder. Furthermore, we found a close relationship between GCA and benign paroxysmal positional vertigo of the posterior semicircular canal in our population [16,17].

In our series, the audiometric tests at the time of diagnosis showed a remarkable auditory dysfunction in GCA patients. Another point to be considered from our study was the presence of a frequent asymmetrical auditory dysfunction that it is in keeping with the asymmetrical cranial manifestations reported in many patients with GCA. During follow-up improvement in auditory function was observed within the first 3 months after the onset of therapy. However, such an improvement was only found in 27% of the cases. In addition, despite corticosteroid therapy, further deterioration in auditory function after 3 months of treatment was detected in 3 patients. Moreover, no additional improvement in hearing function was observed after another 3 months of treatment. These data suggest that the possible improvement in hearing function may be achieved generally early during the first months after the onset of therapy [16]. In summary, our results support the presence of both auditory and vestibular dysfunction closely related to the vasculitic process in GCA patients.

Polymyalgia rheumatica is characterized by pain in the scapulae and proximal aspects of the shoulders, pelvis and proximal aspects of the lower extremities and the cervical region, together with morning stiffness of more than 1 h; it may be present in about 40% of patients with GCA [5]. However, polymyalgia rheumatica may be a separate entity [6] or the initial form of a GCA that does not initially show cranial condition data or other ischemic symptoms suggesting a GCA [18]. Therefore, the presence of audiovestibular abnormalities in one of our patients who initially showed only clinical symptoms of polymyalgia rheumatica was of particular importance. The patient did not initially present the ischemic vascular disease typical of GCA, but at follow-up showed the typical manifestations attributable to it. The presence of vestibular dysfunction may be an alarm sign to consider the possibility of having a "silent and subclinical" GCA in those patients presenting with PMR symptoms. In this regard, the presence of vestibular dysfunction, probably related to ischemic manifestations, may be considered as an early and reversible sign in the course of the disease. Thus, the knowledge of these manifestations as alert signs for a possible underlying GCA is of main importance in elderly people as early corticosteroid treatment reduces significantly the risk of blindness due to GCA. This fact is even more important in GCA whose presenting manifestation is PMR only, as in these cases low dose prednisone does not prevent the development of blindness. The presence of abnormal vestibular tests in patients presenting with PMR without cranial manifestations of GCA may be considered as a red flag to raise the suspicion of an underlying GCA [16].

Takayasu's arteritis is a chronic vasculitis of unknown etiology that affects the aorta, its major branches, the pulmonary artery and the coronary arteries; it causes headache, absence of arterial pulses, heart failure, renovascular hypertension and ocular and cerebral ischemia. In contrast to GCA, Takayasu's arteritis primarily affects young people, especially women between 15 and 25, more commonly in Asian or Central-American populations [19]. In this vasculitis affecting large vessels, a patient has been described who presented sudden deafness and decreased pulse in the radial artery. The hearing condition worsened upon withdrawal of parenterally administered steroids and improved when they were reintroduced [20]. Histopathological studies of the temporal bone are of great interest in patients with systemic vasculitis. Among them, those published for patients diagnosed with **polyarteritis nodosa (PAN)** should be highlighted. In a patient whose first manifestation of the disease was sudden unilateral deafness and vertigo, the temporal bone histopathological study showed bilateral cochlear condition in the form of loss of the organ of Corti in various portions of the cochlea, the absence of the tectorial membrane and atrophy of the stria

vascularis, whereas no vestibular histopathological changes were observed [21]. In another patient with a diagnosis of PAN and unilateral profound hearing loss and vertigo, the histopathological study found vasculitis in the internal auditory artery, accompanied by ossification of the cochlea and the vestibular system as well as endolymphatic hydrops in the basal ramp of the cochlea [22]. The loss of sensory cells and neurons in the maculae of the semicircular canals, utricle and saccule has also been reported in PAN [23]. Most of the reported cases with a diagnosis of PAN met the criteria of the Chapel Hill Consensus Conference relative to microscopic polyangiitis. Recently, the possibility has been described of obtaining a recovery of hearing through a cochlear implant in a patient diagnosed with PAN by biopsy. This reinforces the impression that the lesion is located at the cochlear level. In this group of patients with PAN and profound bilateral hearing loss, this may be secondary to labyrinthine ischemia by a vascular phenomenon [24].

Kawasaki disease (KD) is a diffuse necrotizing vasculitis involving medium-sized vessels, with almost constant injury of the coronary arteries and large non-intraparenchymatous arteries. 85% of patients with KD are children under 5 in whom the disease occurs sporadically or in small outbreaks. It is predominant in males (1.5:1) and, although it is more frequent in Japan, the disease has been diagnosed in more than 40 countries [25]. In a study of 62 patients diagnosed with KD, sensorineural hearing loss was described in the acute phase of the disease in 30% and conductive hearing loss in 9%. On examination of auditory function after the acute phase, neurosensorial hearing loss persisted in 5.5% of patients, so the partially reversible character after treatment with steroids was confirmed [26].

Wegener's granulomatosis is defined as a granulomatous inflammation that affects the airways combined with necrotizing vasculitis of small and medium vessels together with glomerulonephritis and positive cANCA [27]. Furthermore to the known hearing loss secondary to obstruction of the Eustachian tube due to granulomas in the nasopharynx, a series of 21 patients described sudden hearing loss and tinnitus [28]. Bilateral sensorineural hearing loss was observed in 12 of 13 patients with auditory symptoms in a series of 19 patients diagnosed with Wegener's disease by biopsy [29]. Some patients also described vestibular manifestations such as vertigo and peripheral nystagmus [30].

Churg-Strauss allergic granulomatous vasculitis is characterized by granulomas in the upper airways, with eosinophilic infiltration and systemic vasculitis in medium and small vessels, along with a history of asthma, circulating eosinophilia and high concentrations of circulating IgE [27]. It has been described with otitis media with effusion, acute otitis media and progressive sensorineural hearing loss in 9.5% of patients, who improved or stabilized after administration of steroids and immunosuppressors [31].

Behcet's disease is a multisystemic, chronic and recurrent disease that almost always occurs with oral thrush and, in variable frequency, genital sores, uveitis, skin lesions and neurological, vascular and gastrointestinal manifestations with a pathological substrate of leukocytoclastic or lymphocytic vasculitis, preferably from capillaries and venules [32]. Auditory manifestations such as sudden deafness have been described, as well as vertigo during the course of the disease and in relapses [33,34]. Sensorineural hearing loss with a cochlear location was described in 30% of 62 patients diagnosed with Behcet's disease, and central vestibular syndrome in 40% [35].

Cogan's syndrome is characterized by fluctuating hearing loss, tinnitus, spontaneous sudden vertigo, and interstitial keratitis. A significant audiovestibular function has also been described. However, the reported damage is so severe that it does not seem to be the result of a true vasculitis, but rather of a primary labyrinthitis [36].

4. Secondary vasculitis

Rheumatoid arthritis is a chronic, multisystemic inflammatory disease characterised by persistent inflammatory synovitis, usually involving peripheral joints in a symmetrical manner, predominantly the wrists, the metacarpophalangeal and proximal interphalangeal joints of the hands, elbows and knees and metatarsal-phalangeal of feet. It is more common in women; although its etiology is unknown, there is a genetic predisposition, as shown by the tendency to familial aggregation, the high concordance with rheumatoid arthritis in monozygotic twins and the association with genes within the major histocompatibility complex, particularly with certain alleles that share a common sequence of amino acids within the hypervariable control region of the HLA-DRB1 chain, called shared epitope [37]. One study has described sudden hearing loss in patients with RA with an underlying vasculitic process affecting the eighth cranial nerve [38].

In the Lugo population, as in the Anglo-Saxon, an association of rheumatoid arthritis with HLA-DR4 alleles has been observed, in particular with HLA-DRB1*0401 and *0404. These alleles have also been shown as markers of vascular damage in patients with rheumatoid arthritis in Lugo, since patients with these alleles are at increased risk of endothelial vascular dysfunction [39] a marker of early stage of atherosclerosis and an increased risk of cardiovascular events [40].

Interestingly, in a series of 33 patients diagnosed with idiopathic sudden hearing loss in our Lugo population, we also observed an association of HLA-DR4 with increased susceptibility to the disease and a worse prognosis for recovery with steroid treatment [41]. Accordingly with this, an increased susceptibility to sensorineural hearing loss has been described in patients with rheumatoid arthritis with respect to a control group. Specifically, in a series of 194 patients diagnosed with rheumatoid arthritis, sensorineural hearing loss was also described in 39% [42]. The coincidence of findings involving HLA-DR4 alleles with increased severity of rheumatoid arthritis [37] and its association with increased risk of vascular damage in this disease [39,40] together with the finding of an increased risk of sudden deafness with worse functional outcome in people presenting HLA-DR4 may indicate that these alleles would be true markers of endothelial vascular damage regardless of the underlying disease [41].

Scleroderma or systemic sclerosis is included in the collagenosis group. Systemic sclerosis (SSc) is a disease characterized by excessive deposition of connective tissue and extracellular matrix proteins in different organs and tissues, and is more common in women. Its etiology is unknown, but it is known to involve disorders of collagen synthesis as well as vascular and immune system abnormalities. Two clinical forms have been established: the limited and the diffuse variants. The predominate features in the limited form are Raynaud's phenomenon, clinical data defined in the CREST syndrome (calcinosis, Raynaud's phenomenon, sclerodactyly, oesophageal disorders, and telangiectasia), increased risk of pulmonary hypertension and presence of positive antinuclear antibodies anticentromere B positive and distal skin condition in the extremities [43]. In the diffuse form, the predominate features are proximal skin condition and more intense injury to internal organs that leads to increased risk of pulmonary fibrosis and renal scleroderma crisis, typically associating with anti-SCL70 positive antibodies [43].

Recently, in the population of Lugo, we tried to assess the presence of audiovestibular damage in a homogenous cohort of patients with limited SSc and antibodies against CENB. We were able to observe abnormalities of audiometric and vestibular tests

supporting the presence of audiovestibular damage in limited forms of SSc. We also examined the influence of disease duration on the development of audiovestibular abnormalities; however, we found no association between disease duration and the development of abnormalities of audiometric, vestibular, or postural tests. Nevertheless, we found a significantly increased frequency of patients with abnormal hearing loss in the audiogram (77%). Of interest, a high frequency loss in the audiogram was common in our series; the typical pattern of hearing impairment in our patients with limited SSc was a bilateral and symmetrical sensorineural hearing loss with a flat curve in the audiogram. Vasculitis leading to focal striae atrophy or malfunction of the hair cells of the organ of Corti, or both, has been proposed as responsible for sensorineural hearing loss in SSc. Besides sensorineural damage, we also found middle ear dysfunction, manifested by a flattened tracing in tympanometry in 20% of the patients with limited SSc, due to myringosclerosis confirmed by otomicroscopic examination.

Furthermore, our results confirm that the vestibule is also involved in SSc, even in limited forms of the disease. Patients with limited SSc had a significantly increased frequency of abnormal oculo-cephalic response or head thrust test (29%) and head-shaking nystagmus (26%), and a higher frequency of 3 or more abnormal positions when positional nystagmus was assessed by means of videonystagmography and videonystagmoscopy goggles [44]. The static postural study also yielded a significantly increased frequency of abnormal clinical test of sensory interaction and balance (CTSIB) in limited and diffuse SSc patients (46%) compared with controls (12%). Interestingly, vestibular loss was the main pattern of abnormal CTSIB in our patients. All these findings support the presence of a peripheral vestibular lesion, probably due to vascular involvement in patients with SSc.

In our series, almost a fifth of the patients with limited and diffuse SSc showed a benign paroxysmal positioning vertigo (BPPV) that was generally caused by the involvement of the horizontal semicircular canal (HSC). Interestingly, we observed the presence of abnormal caloric test in 43% of SSc patients with associated BPPV. These observations indicate that abnormalities found in our patients with SSc are not the result of an injury in a single semicircular canal of the inner ear. They also suggest that vascular disease in the setting of this connective tissue disease may be responsible for these findings, supporting an ischemic cause as responsible for the functional damage. However, an alternative cause for BPPV could be related to a possible intralabyrinthine autoimmune process [45].

In summary, we have described hearing and vestibular dysfunctions, as well as an abnormal postural control of static balance in systemic sclerosis, both in limited and in diffuse forms. The etiology is probably vasculitic, although a direct autoimmune mechanism in the inner ear cannot be ruled out. In this patient group studied, we highlight symmetrical and bilateral sensorineural hearing loss, vestibular hypofunction on caloric testing and an abnormal response in head shaking nystagmus test and oculoccephalic maneuver (head thrust test), all these findings are typically related with peripheral vestibular dysfunction. Furthermore, we also describe a close association with benign paroxysmal positional vertigo (BPPV), predominantly of the horizontal canal [44,45].

Systemic lupus erythematosus (SLE) is the prototype of autoimmune disease, which primarily affects women between 15 and 50 and also causes secondary vasculitis [46]. Sensorineural hearing loss has been observed with relative frequency in this group of patients with SLE, and both autoimmune and vasculitic mechanisms have been involved in its pathogenesis [47].

Hearing loss and vertigo of probable ischemic origin have been described in **relapsing polychondritis**, an autoimmune disease that affects, unilaterally or bilaterally, the cartilage of the ear, nose and trachea. Its pathophysiology has been explained assuming the existence of a vasculitis of the labyrinthine artery and its branches [48].

Another disease involving audiovestibular manifestations and vasculitis is **Sjögren's syndrome**. This is a slowly progressing, chronic auto-immune disease, characterized by lymphocytic infiltration of exocrine glands, as well as hyper-reactivity and proliferation of B cells that end up producing xerostomia and dry eyes. It may be primary or secondary; in the latter case, it is accompanied by another auto-immune disease with systemic clinic, as occurs in 30% of patients. It mainly affects women between 40 and 50.

Like SLE, Sjögren's syndrome also causes secondary vasculitis [46]. Sensorineural hearing loss concomitant with cardiolipinic antibodies has been described in 14 of 30 patients with Sjögren's syndrome [49]. A sudden hearing loss has also been reported as initial and exceptional presentation in a case of Sjögren's syndrome [50].

Ankylosing spondylitis (AS) is a chronic inflammatory disease of unknown origin affecting up to 1% of the population. To further investigate hearing loss in AS we studied a series of 50 consecutive patients that fulfilled the modified New York diagnostic criteria for AS and 44 matched controls from the Lugo region of Northwest Spain. In this study, 29 (58%) of the patients with AS showed abnormal hearing loss in the audiogram compared to only 8 (18%) of the controls. Of interest, the audiogram shape disclosed a predominant pattern of symmetrical high frequency sensorineural hearing loss in AS patients (50%). In our study, individuals with severe extraspinal manifestations had an increased risk of having hypoacusia. Furthermore, the presence of hip involvement, anterior uveitis, and HLA-B27 in patients with AS appears to be a signal for sensorineural hearing loss (SNHL) that deserves further investigation. Besides sensorineural damage, in our series middle ear dysfunction, manifested by an abnormal tympanometry, was found in 8% of patients with a flattened tracing who was considered the most specific sign of abnormal tympanometry in AS patients. This finding could be explained by an increased rigidity of the tympanossicular system.

Furthermore, our results confirm that the vestibule is also involved in patients with AS. Patients with AS have a marginally increased frequency of abnormal head thrust test and a significantly increased frequency of abnormal head-shaking nystagmus in oculocephalic response study (vestibule-ocular reflex) and disclosed an abnormal vestibular function in caloric testing (canal paresis).

In our series from Lugo, we also founded a significantly increased frequency of abnormal CTSIB results in AS patients (36%). In this regard, increased frequency of abnormal postural control in CTSIB test was of vestibular origin, conditions 5 and 6 of the study, that correspond to a vestibular pattern of the study in patients with AS.

All our findings support the presence of a peripheral vestibular lesion in patients with AS. On the other hand, although the difference did not reach statistical significance, BPPV also was found more frequently in patients than in the controls. Therefore, these studies confirm the presence of inner ear compromise and audiovestibular dysfunction in patients with AS that may be the result of vascular involvement or due to a direct immune-mediated injury of the inner ear and it could provide justification for rheumatologists or physicians to screen for inner ear compromise in their AS population. [51,52].

5. Role of serological study

As for serological markers that could help diagnose diseases involving vascular damage, some studies suggest an etiopathogenic role of anti-endothelial cell antibodies (AECA). These could be regarded as markers of immune-mediated vascular damage in vasculitis, as well as sudden hearing loss, where some authors assign it a direct involvement in physiopathology [53,54]. However, in our population, we could not confirm the diagnostic or pathogenic role of AECA in patients diagnosed with GCA through temporal artery biopsy in whom vestibular dysfunction and sensorineural hearing loss had been confirmed [55].

As far as we know, there is no specific marker to support the diagnosis of immune-mediated inner ear disease. We must suspect it based on a combination of a compatible clinic together with the findings derived from conducting vestibular, hearing and laboratory tests for each disease.

6. Conclusions

The vasculitis forms are a heterogeneous group of diseases in which audiovestibular symptoms are relatively more common than was initially considered, both at the beginning of the vasculitis and in the evolution of the process. Studies confirm that the search for changes in auditory and vestibular tests shows both peripheral and central disorders. Furthermore, the audiovestibular dysfunction could be explained by an ischemic mechanism mediated by the inflammatory vasculitic phenomenon in primary vasculitis, but one cannot rule out the role of a direct autoimmune mechanism when the inner ear is involved in secondary vasculitis. In our population, BPPV was found more frequently when was studied in GCA, SS and AS. Moreover, patients with GCA showed more frequent findings of BPPV than SS and this more than AS. This finding may suggest that BPPV could be associated with more frequency when vasculitis was the main pathogenic factor mediated by ischemia. In SS and AS patients both autoimmune and vasculitic mechanisms could be involved in its pathogenesis.

7. References

- [1] Lie JT. Vasculitis, 1815 to 1991: classification and diagnostic specificity (Dunlop Dottridge lecture). *J Rheumatol*. 1991; 19:19:83-89.
- [2] McCabe BF. Autoimmune sensorineural hearing loss. *Ann Otol Rhinol Laryngol*. 1979;88:585-9.
- [3] Garcia Berrocal JR, Ramirez-Camacho R. Immuneresponse and immunopathology of the inner ear: an update. *J Laryngol Otol*. 2000;114:101-7.
- [4] Yoon TH, Paparella MM, Schachern PA. Systemic vasculitis: a temporal bone histopathologic study. *Laryngoscope*. 1989;99:600-609.
- [5] Gonzalez-Gay MA, Barros S, Lopez-Diaz MJ, Garcia-Porrúa C, Sanchez-Andrade A, Llorca J. Giant cell arteritis: disease patterns of clinical presentation in a series of 240 patients. *Medicine (Baltimore)*. 2005;84:269-76.
- [6] Gonzalez-Gay MA. Giant cell arteritis and polymyalgia rheumatica: two different but often overlapping conditions. *Semin Arthritis Rheum*. 2004;33:289-93.

- [7] Gonzalez-Gay MA, García-Porma C, Llorca J, Hajeer AH, Branas F, Dababneh, A, et al. Visual manifestations of giant cell arteritis. Trends and clinical spectrum in 161 patients. *Medicine (Baltimore)*. 2000;79:283-92.
- [8] Gonzalez-Gay MA, Garcia-Porrúa C, Vazquez-Caruncho M. Polymyalgia rheumatica in biopsy proven giant cell arteritis does not constitute a different subset but differs from isolated polymyalgia rheumatica. *J Rheumatol*. ;1998;25:1750-5.
- [9] Gonzalez-Gay MA, Garcia-Porrúa C, Llorca J, Gonzalez-Louzao C, Rodriguez-Ledo P. Biopsy-negative giant cell arteritis: clinical spectrum and predictive factors for positive temporal artery biopsy. *Semin Arthritis Rheum*. 2001;30:249-56.
- [10] Machado EB, Michet CJ, Ballard DJ, Hunder GG, Beard CM, Chu, CP, et al. Trends in incidence and clinical presentation of temporal arteritis in Olmsted County, Minnesota, 1950-1985. *Arthritis Rheum*. 1988;31:745-9.
- [11] Sonnenblick M, Neshet G, Friedlander Y, Rubinow A. Giant cell arteritis in Jerusalem: a 12-year epidemiological study. *Br J Rheumatol*. 1994;33:938-41.
- [12] Gonzalez-Gay MA, Blanco R, Sanchez-Andrade A, Vazquez- Caruncho M. Giant cell arteritis in Lugo (Spain): a more frequent disease with less fewer classic features. *J Rheumatol*. 1997;24:2166-70.
- [13] Gonzalez-Gay MA, Garcia-Porrúa C, Rivas MJ, Rodriguez-Ledo P, Llorca J. Epidemiology of biopsy proven giant cell arteritis in northwestern Spain: trend over an 18 year period. *Ann Rheum Dis*. 2001;60:367-71.
- [14] Gonzalez-Gay MA, Miranda-Fillooy JA, Lopez-Diaz MJ, Perez- Alvarez R, Gonzalez-Juanatey C, Sanchez-Andrade, A, et al. Giant cell arteritis in northwestern Spain: a 25-year epidemiologic study. *Medicine (Baltimore)*. 2007;86:61-8.
- [15] Gonzalez-Gay MA, Garcia-Porrúa C, Amor-Dorado JC. Arteritis de células gigantes y polimialgia reumática. In: Ramos Casals M, Garcia Carrasco M, Gomez de Salazar JR, Calvo Alen J, Font Franco J, editors. *Enfermedades autoinmunes sistémicas y reumatológicas*. Barcelona: Masson; 2005. p. 197-209.
- [16] Amor-Dorado JC, Llorca J, Garcia-Porrúa C, Costa C, Perez- Fernandez N, Gonzalez-Gay MA. Audiovestibular manifestations in giant cell arteritis: a prospective study. *Medicine (Baltimore)*. 2003;82:13-26.
- [17] Amor-Dorado JC, Llorca J, Costa-Ribas C, Garcia-Porrúa C, Gonzalez-Gay MA. Giant cell arteritis: a new association with benign paroxysmal positional vertigo. *Laryngoscope*. 2004;114: 1420-1425.
- [18] Gonzalez-Gay MA, Garcia-Porrúa C, Amor-Dorado JC, Llorca J. Giant cell arteritis without clinically evident vascular involvement in a defined population. *Arthritis Rheum*. 2004;51:274-7.
- [19] Hall S, Barr W, Lie JT, Stanson AW, Kazmier FL, Hunder GG. Takayasu's arteritis: A study of 32 North American patients. *Medicine (Baltimore)*. 1985;64:89-99.
- [20] Maruyoshi H, Toyama K, Kojima S, Kawano H, Ogata N, Miyamoto, S, et al. Sensorineural hearing loss combined with Takayasu's arteritis. *Intern Med*. 2005;44:124-8.
- [21] Jenkins HA, Pollak AM, Fisch U. Polyarteritis nodosa as a cause of sudden deafness. A human temporal bone study. *Am J Otolaryngol*. 1981;2:99-107.
- [22] Gussen P. Polyarteritis nodosa and deafness. A human temporal bone study. *Arch Otorhinolaryngol*. 1977;26:263-71.

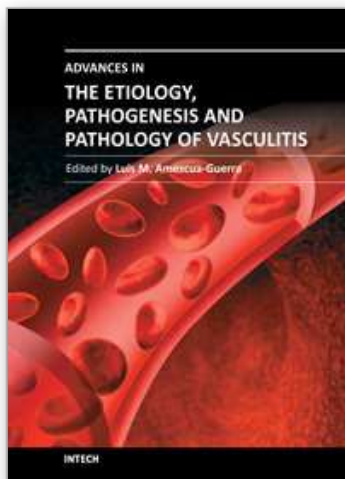
- [23] Adkins WY, Ward PH. Temporal bone showing polyarteritis nodosa, otosclerosis, and occult neuroma. *Laryngoscope*. 1986;96:645-52.
- [24] Psillas G, Kyriafinis G, Danizilidis J. Polyarteritis nodosa and cochlear implantation. *J Laryngol Otol*. 2007;121:196-9.
- [25] Dym L. Kawasaki disease. *Curr Opin Rheumatol*. 1993;5:41-5.
- [26] Knott PD, Orloff LA, Harris JP, Novak RE, Burns JC, Kawasaki Disease Multicenter Hearing Loss Study Group. Sensorineural hearing loss and Kawasaki disease: a prospective study. *Am J Otolaryngol*. 2001;22:343-8.
- [27] Gonzalez-Gay MA, Garcia-Porrúa C, Guerrero J, Rodriguez-Ledo P, Llorca J. The epidemiology of the primary systemic vasculitides in northwest Spain: implications of the Chapel Hill Consensus Conference definitions. *Arthritis Rheum*. 2003;49:388-393.
- [28] Llompart X, Aumaitre O, Kemeny JL, Mom T, Gilain L. Early otorhinolaryngological manifestations of Wegener's granulomatosis. Analysis of 21 patients. *Ann Otolaryngol Chir Cervicofac*. 2002;119:330-6.
- [29] Kempf HG. Ear involvement in Wegener's granulomatosis. *Clin Otolaryngol*. 1989;14:451-6.
- [30] Bennett RW, Staker LV. Wegener's granulomatosis presenting as vertigo. *West J Med*. 1987;146:359-61.
- [31] Bacciu A, Bacciu S, Mercante G, Ingegnoli F, Grasselli C, Vaglio, A, et al. Ear, nose and throat manifestations of Churg-Strauss syndrome. *Acta Otolaryngol*. 2006;126:503-9.
- [32] Gonzalez-Gay MA, Garcia-Porrúa C, Branas F, Lopez-Leizaro L, Olivieri I. Epidemiologic and clinical aspects of Behcet's disease in a defined area of Northwestern Spain, 1988-1997. *J Rheumatol*. 2000;27:703-
- [33] Belkahia A, Ben Ayed H, Ben H'Mida M, Hamza M. Auditory and vestibular lesions in Behcet's disease. *Ann Otolaryngol Chir Cervicofac*. 1982;99:469-76.
- [34] Narvaez J, Valverde-Garcia J, Alegre-Sancho JJ, Juanola X, Clavaguera MT, Roig-Escofet D. Sudden cochlear hearing loss in a patient with Behcet's disease. *Rev Rheum (Engl ed)*. 1998;65:63-4.
- [35] Kulahli I, Balci K, Koseoglu E, Yuce I, Cagli S, Senturk M. Audiovestibular disturbances in Behcet's patients: report of 62 cases. *Hear Res*. 2005;203:28-31.
- [36] Schuknecht HF, Nadol Jr JB. Temporal bone pathology in a case of Cogan's syndrome. *Laryngoscope*. 1994;104:1135-42.
- [37] Gonzalez-Gay MA, Garcia-Porrúa C, Hajeer AH. Influence of human leukocyte antigen-DRB1 on the susceptibility and severity of rheumatoid arthritis. *Semin Arthritis Rheum*. 2002;31:355-60.
- [38] Merrin PK, Macfarlane DG. Vestibulocochlear dysfunction in a patient with rheumatoid disease and vasculitis. *Ann Rheum Dis*. 1991;50:393-4.
- [39] Gonzalez-Juanatey C, Testa A, Garcia-Castelo A, Garcia-Porrúa C, Llorca J, Vidan, A, et al. HLA-DRB1 status affects endothelial function in treated patients with rheumatoid arthritis. *Am J Med*. 2003;114:647-52.
- [40] Gonzalez-Gay MA, Gonzalez-Juanatey C, Lopez-Diaz MJ, Pineiro A, Garcia-Porrúa C, Miranda-Fillooy, JA, et al. HLA-DRB1 and persistent chronic inflammation

- contribute to cardiovascular events and cardiovascular mortality in patients with rheumatoid arthritis. *Arthritis Rheum.* 2007;57:125-32.
- [41] Amor-Dorado JC, Paco L, Martin J, Lopez-Nevot MA, Gonzalez-Gay MA. Human leukocyte antigen-DQB1 and -DRB1 associations in patients with idiopathic sudden sensorineural hearing loss from a defined population of Northwest Spain. *Acta Otolaryngol.* 2005;125:1277-82.
- [42] García Callejo FJ, Conill Tobías N, Munoz Fernandez N, De Paula Vernetta C, Alonso Castaneira I, Marco Algarra J. Hearing impairment in patients with rheumatoid arthritis. *Acta Otorrinolaringol Esp.* 2007;58:232-8.
- [43] Arias-Nunez MC, Llorca J, Vazquez-Rodriguez TR, Gomez-Acebo I, Miranda-Fillooy JA, Martin, J, et al. Systemic sclerosis in northwestern Spain: a 19-year epidemiologic study. *Medicine (Baltimore).* 2008;87:272-80.
- [44] Amor-Dorado JC, Arias-Nuñez MC, Miranda-Fillooy JA, Gonzalez- Juanatey C, Llorca J, Gonzalez-Gay MA. Audiovestibular manifestations in patients with limited systemic sclerosis and centromere protein-B (CENP-B) antibodies. *Medicine (Baltimore).* 2008;87:131-41.
- [45] Amor-Dorado JC, Barreira-Fernandez MP, Arias-Nunez MC, Gomez-Acebo I, Llorca J, Gonzalez-Gay MA. Benign paroxysmal positional vertigo and clinical test of sensory interaction and balance in systemic sclerosis. *Otol Neurotol.* 2008;29: 1155-61.
- [46] Gonzalez-Gay MA, García-Porrúa C. Systemic vasculitis in adults in northwestern Spain, 1988-1997, Clinical and epidemiologic aspects. *Medicine (Baltimore).* 1999;78:292-308.
- [47] Andonopoulos AP, Naxakis S, Goumas P, Lygatsikas C. Sensorineural hearing disorders in systemic lupus erythematosus. A controlled study. *Clin Exp Rheumatol.* 1995;13:137-41.
- [48] Schuknecht HF. Ear pathology in autoimmune disease. *Adv Otorhinolaryngol.* 1991;46:50-70.
- [49] Tumiatì B, Casoli P, Parmeggiani A. Hearing loss in the Sjogren syndrome. *Ann Intern Med.* 1997;126:450-3.
- [50] García Berrocal JR, Arellano B, Vargas JA, Trinidad A, Ramírez Camacho R, Vergara J. Enfermedad inmunomediada del oído interno: Presentación de casos clínicos. *Acta Otorrinolaringol Esp.* 1997;48:565- 70.
- [51] Amor-Dorado JC, Barreira-Fernández MP, Vázquez-Rodríguez TR, Miranda-Fillooy JA, Llorca J, González-Gay MA. Benign paroxysmal positional vertigo and clinical test of sensory interaction and balance in ankylosing spondylitis. *Otol Neurotol.* 2011;32:278-83.
- [52] Amor-Dorado JC, Barreira-Fernandez MP, Vazquez-Rodriguez TR, Gomez-Acebo I, Miranda-Fillooy JA, Diaz de Teran T, Llorca J, Gonzalez-Gay MA. Audiovestibular manifestations in patients with ankylosing spondylitis. *Medicine (Baltimore).* 2011 ;90:99-109.
- [53] Cadoni G, Fetoni AR, Agostino S, De Santis A, Manna R, Ottaviani, F, et al. Autoimmunity in sudden sensorineural hearing loss: possible role of anti-endothelial cell autoantibodies. *Acta Otolaryngol Suppl.* 2002;548:30-3.

- [54] Ottaviani F, Cadoni G, Marinelli L, Fetoni AR, de Santis A, Romito, A, et al. Anti-endothelial autoantibodies in patients with sudden hearing loss. *Laryngoscope*. 1999;109:1084-7.
- [55] Amor-Dorado JC, Garcia-Porrúa C, Gonzalez-Gay MA. Antiendothelial cell antibodies and biopsy-proven temporal arteritis. *Lupus*. 2002;11:134.

IntechOpen

IntechOpen



Advances in the Etiology, Pathogenesis and Pathology of Vasculitis

Edited by Dr. Luis M Amezcua-Guerra

ISBN 978-953-307-651-5

Hard cover, 438 pages

Publisher InTech

Published online 17, October, 2011

Published in print edition October, 2011

This book represents the culmination of the efforts of a group of outstanding experts in vasculitis from all over the world, who have endeavored to devote their work to this book by keeping both the text and the accompanying figures and tables lucid and memorable. Here, you will find an amalgam between evidence-based medicine to one based on eminence, through an exciting combination of original contributions, structured reviews, overviews, state-of-the-art articles, and even the proposal of novel pathogenetic models of disease. The book contains contributions on the etiology and pathology of vasculitis, the potential role of endothelial cells and cytokines in vascular damage and repair as well as summaries of the latest information on several primary and secondary vasculitis syndromes. It also covers selected topics such as organ-specific vasculitic involvement and quality of life issues in vasculitis. The editor and each of the authors invite you to share this journey through one of the most exciting fields of the medicine, the world of Vasculitis.

How to reference

In order to correctly reference this scholarly work, feel free to copy and paste the following:

Juan Carlos Amor-Dorado and Miguel Angel Gonzalez-Gay (2011). Audiovestibular Manifestations in Systemic Vasculitis: An Update, *Advances in the Etiology, Pathogenesis and Pathology of Vasculitis*, Dr. Luis M Amezcua-Guerra (Ed.), ISBN: 978-953-307-651-5, InTech, Available from:
<http://www.intechopen.com/books/advances-in-the-etiology-pathogenesis-and-pathology-of-vasculitis/audiovestibular-manifestations-in-systemic-vasculitis-an-update>

INTECH
open science | open minds

InTech Europe

University Campus STeP Ri
Slavka Krautzeka 83/A
51000 Rijeka, Croatia
Phone: +385 (51) 770 447
Fax: +385 (51) 686 166
www.intechopen.com

InTech China

Unit 405, Office Block, Hotel Equatorial Shanghai
No.65, Yan An Road (West), Shanghai, 200040, China
中国上海市延安西路65号上海国际贵都大饭店办公楼405单元
Phone: +86-21-62489820
Fax: +86-21-62489821

© 2011 The Author(s). Licensee IntechOpen. This is an open access article distributed under the terms of the [Creative Commons Attribution 3.0 License](https://creativecommons.org/licenses/by/3.0/), which permits unrestricted use, distribution, and reproduction in any medium, provided the original work is properly cited.

IntechOpen

IntechOpen