

# We are IntechOpen, the world's leading publisher of Open Access books Built by scientists, for scientists

6,900

Open access books available

186,000

International authors and editors

200M

Downloads

Our authors are among the

154

Countries delivered to

TOP 1%

most cited scientists

12.2%

Contributors from top 500 universities



WEB OF SCIENCE™

Selection of our books indexed in the Book Citation Index  
in Web of Science™ Core Collection (BKCI)

Interested in publishing with us?  
Contact [book.department@intechopen.com](mailto:book.department@intechopen.com)

Numbers displayed above are based on latest data collected.  
For more information visit [www.intechopen.com](http://www.intechopen.com)



## Virtual Planning for Dental Implant Placement Using Guided Surgery

Vinicius Nery Viegas, Celso Gustavo Schwalm Lacroix,  
Rogério Miranda Pagnoncelli and Marília Gerhardt de Oliveira  
*Pontifícia Universidade Católica do Rio Grande do Sul  
Brazil*

### 1. Introduction

Technical and scientific advances in diagnostic and therapeutic methods in the biomedical field have substantially increased the predictability and longevity of the outcomes of restorative surgical procedures. In contemporary oral implantology, bioprototyping techniques based on computer-aided design and computer-aided manufacturing (CAD/CAM) technology have proven to be valuable aids in diagnosis, treatment planning, and surgical intervention. Among other aspects, use of these technologies improves preoperative planning, makes it easier for patients to understand proposed procedures, increases the predictability of treatment, and may reduce surgical morbidity.

The preliminary stages that precede dental implant surgery are as important as the actual operative intervention itself, or even more so. Inadequate placement of implants may injure important anatomical structures or lead to aesthetic or functional compromise of the prosthetic stage of oral rehabilitation.

Implant planning and placement can be based solely on computed tomography data and surgical guides fashioned after diagnostic models. However, direct three-dimensional visualization of the surgical site and real-model simulation of the intended surgical procedure can play a significant role in obtaining outcomes that are more consistent with the original treatment plan. Biomedical prototypes, or biomodels, provide faithful reproductions of the patient's bone condition, thus enabling this type of assessment.

Likewise, the surgery itself can be made safer and less invasive with use of individualized surgical guides for implant placement. The development of software programs for implant placement planning and the integration of these software packages with rapid prototyping methods have made fabrication of such guides possible.

The process of obtaining and reformatting computed tomography (CT) data, planning implant placement over a virtual model, fabricating a surgical guide with prototyping methods, and using this guide or template during dental implant surgery with specifically designed systems may be referred to as guided implant surgery.

### 2. Principles of guided surgery

Guided implant surgery is based on the combination of virtual surgical planning and prototyping techniques. Rapid prototyping can be defined as a set of technology-based

processes that enable fabrication of three-dimensional, concrete objects from a computer-aided design (CAD) project. The objective of rapid prototyping is to create a real model with the same geometric features of the virtual model, which can then undergo real-world manipulation for a variety of purposes (James et al., 1998; Peltola et al., 2008).

The greatest challenges in the surgical and prosthetic stages of dental implant surgery are due to diagnostic failure and poor case planning (Lal et al., 2006).

The American Academy of Oral and Maxillofacial Radiology (AAOMR) recommends that any evaluation of the available bony architecture for diagnosis and planning of extensive implant-based oral rehabilitation include CT imaging (Almog et al., 2006).

In this context, Jacobs et al. (1999) assessed the reliability of two-dimensional CT images for implant placement planning. The Jacobs study was performed on 100 partially or fully edentulous patients who underwent CT scanning and subsequent implant placement. Available bone height was measured below the maxillary sinus and nasal fossa and above the mandibular canal, and a 1.5 mm safety margin was respected. Planning took into account implant number, location, and size, available bone height, and possible anatomic complications, such as bony dehiscences and fenestrations, maxillary sinus perforation, absence of primary stability, and poor implant positioning in light of the required biomechanical and cosmetic outcome. The authors found that, in some cases, placement of implants according to plan was impossible, mostly due to intraoperative findings that had been missed or underestimated on CT images. Agreement between planned and intraoperative implant number and sites was satisfactory. Of the 416 planned implants, 395 were successfully placed. However, the authors found weak agreement between the size of the planned implant and that of the implant actually placed (44%). Implants were shorter or longer than planned in 110 and 74 of the 395 successful cases respectively.

According to the authors, CT images can be used for preoperative planning of the number of implants, as well as for choice of implant sites. However, CT scans are not sufficiently reliable for precise determination of implant size or for prevention of intraoperative anatomic complications, and can thus reduce the predictability of the implant placement procedure (Jacobs et al., 1999).

Thus, in light of the need for implementation of available treatment planning resources in implantology, virtual planning and rapid prototyping techniques have come to provide an excellent choice in the search for satisfactory outcomes with lower intra- and postoperative complication rates (Choi et al., 2002; Almog et al., 2006).

Biomedical prototypes and virtual evaluation provide the ability to visualize and manipulate the surgical sites, measure the patient's bony structures, and simulate the surgical intervention itself. These preoperative procedures increase predictability of the chosen technique, improve applicability of the surgical plan, and can shorten operative time (Choi et al., 2002; Sarment et al., 2003a; Sarment et al., 2003b; Meurer et al., 2008).

Erickson et al. (1999) surveyed the opinions of oral and maxillofacial surgeons about the use of stereolithographic models for diagnosis, treatment planning, preoperative surgical simulation, and construction of alloplastic implants for anatomical reconstruction. Seventy-six models were constructed in the study period. Prototypes were used by 69% of respondents as a diagnostic aid during the planning phase, and played a role in treatment planning in 92% of cases. Seventy-three percent of respondents used the models to instruct patients as to the planned procedure. Preoperative surgical simulation was employed in 38% of cases. Seventy-seven percent of surgeons reported reductions in operative time when

prototypes were used, 38% reported improvement in surgical access, and 46% noted that more complex procedures were made safer and more predictable by preoperative study of prototype models. Despite the wide applicability of biomodels (in 96% of treatment phases) only 15% of surgeons that responded to the survey believed that rapid prototyping had played an essential role in proper treatment. Nevertheless, the authors stressed the validity of prototypes as a tool for obtaining more predictable and lasting results.

In a similar study, Erben et al. (2002) interviewed 38 oral and maxillofacial surgeons to determine the main indications for biomodels and the key benefits provided by their use in preoperative planning. Models were used in planning placement of osseointegrated implants and other procedures. Surgeons noted that use of biomedical prototypes improved the quality of diagnosis, enabled preoperative simulation of planned interventions, made it easier for patients to understand the procedure and provided intraoperative guidance.

Wulf et al. (2003) published a study conducted between September 1999 and April 2002 in order to assess the relevance of biomedical prototypes in the preoperative, intraoperative, and postoperative stages of maxillofacial surgery. Fifty-four surgeons described their experiences on a total of 466 cases. This study corroborated the advantages of biomodel use described in the aforementioned investigations.

In dental implantology, bioprototyping techniques are not limited to model construction and analysis. With the advent of sophisticated data acquisition methods and image manipulation and virtual planning software, fabrication of rapid-prototyped surgical guides and templates have made it possible to achieve more reliable agreement between the planned and final position of dental implants. This improved predictability of implant and prosthesis positions is based on the concepts of guided surgery (Garg, 2006; Rosenfeld et al., 2006).

### 3. Guided surgery in dental implantology

Fabrication of a surgical guide that faithfully reproduces planned implant positions can play an essential role in the success of implant-based oral rehabilitation (Ganz, 2003).

Surgical templates fashioned using conventional methods have some drawbacks that can make successful aesthetic and functional outcomes more difficult to achieve. The diagnostic models on which these guides are based provide a rigid, non-functional representation of the soft tissues that cover the alveolar ridge, which prevents visualization of the underlying bone anatomy of the region of interest and consequently makes it impossible to decide on a definitive orientation for implants (Lal et al., 2006).

Guided surgery can be used in rehabilitation of fully or partially edentulous patients, or even for single teeth. Likewise, guides can be mucosa-supported (tissue-borne), tooth-supported (tooth-borne), or bone-supported (bone-borne).

In guided surgery for rehabilitation of fully edentulous arches, certain steps must be followed prior to implant position planning:

- a. placement of diagnostic models on a semi-adjustable articulator;
- b. diagnostic wax-up;
- c. duplicate of wax-up for fabrication of acrylic-resin CT guide;
- d. placement of at least six 1.5 to 2 mm-diameter holes on the vestibular region of the guide and filling with radiopaque material;

- e. interocclusal registration with addition or condensation silicone for guidance during CT scanning;
- f. occlusal CT view of guide and interocclusal record;
- g. isolated scan of guide (for flapless procedures) (Parel & Triplett, 2004; Balshi et al., 2006; Marchack, 2007; Sanna et al., 2007; Van Assche et al., 2007).

CT slices acquired in the DICOM file format must be converted with the aid of a specific software package prior to manipulation and reformatting into 3D images. During this process, the isolated radiographic guide scan is superimposed onto its occlusal view, using the radiopaque points as landmarks (Parel & Triplett, 2004; Balshi et al., 2006; Marchack, 2007; Sanna et al., 2007; Van Assche et al., 2007). The threshold for the case is also defined during this stage (Souza et al., 2003).

Files obtained during this step can then be opened in implant position planning software. These applications provide axial, panoramic, and three-dimensional reconstructions of CT slices (Marchack, 2007; Sanna et al., 2007; Van Assche et al., 2007). They also enable manipulation of the panoramic reconstruction curve on the axial plane, providing orthogonal slices for assessment of alveolar ridge thickness in the vestibulolingual or vestibulopalatal direction (Parel & Triplett, 2004; Sanna et al., 2007; Van Assche et al., 2007). Virtual planning gives implantologists the ability to choose the precise location, orientation, and dimensions of implants, abutments and other fixtures. Implant emergence and the relationship of the implant to the future prosthesis can also be visualized and adjusted as convenient. In short, virtual planning can overcome the limitations of conventional surgical guides (Lal et al., 2006).

Several virtual planning and guided surgery systems are available on the market. Each has its own particularities that should be taken into account by the implantologist, according to therapeutic indication, cost-benefit ratio, and learning curve for clinical use.

The final stage of planning consists of defining the sites for placement of two or more anchor pins for the surgical guide, which are inserted through the vestibular aspect of the guide, between the implants (Balshi et al., 2006; Marchack, 2007; Sanna et al., 2007).

After planning is complete, files are sent to a medical prototyping facility, where they will be converted into an appropriate format for prototype fabrication (Parel & Triplett, 2004; Marchack, 2007; Sanna et al., 2007; Van Assche et al., 2007).

With implant positions established, a surgical guide is designed on the basis of the virtual model and sent to the prototyping station, where it is then fabricated (Lal et al., 2006).

Three types of surgical guides or templates can be manufactured with rapid prototyping methods to improve the predictability of osseointegrated implant-based oral rehabilitation. Bone-supported (or bone-borne) guides are placed after the mucoperiosteal flap has been raised. Their advantages include positional stability during implant placement and the possibility of direct visualization of anatomical structures. The need for broader surgical exploration, however, may be regarded as a drawback of this type of guide, which is usually reserved for partially or fully edentulous arches (Tardieu et al., 2003; Garg, 2006; Lal et al., 2006).

In mucosa-supported (or tissue-borne) surgical guides, templates, anchor pins are placed transmucosally. The drilling sequence for implant placement begins with a tissue punch or extractor, with the guide in place (Parel & Triplett, 2004; Marchack, 2007; Sanna et al., 2007). These guides are indicated in fully edentulous patients. Use of the double-scan technique, in



which two independent scans of the radiographic guide—individually and in occlusion—are obtained, is mandatory in these cases. The key advantage of this method is the possibility of performing allows minimally invasive flapless procedures, which make for an easier intraoperative and postoperative period (Garg, 2006).

Tooth-supported (or tooth-borne) surgical guides, as the name implies, are supported by the patient’s remaining teeth. They are indicated in rehabilitation of single teeth or partially partially edentulous regions, and provide good outcomes when used for minimally invasive flapless surgery (Garg, 2006).

Once the prototyped guide is ready, implant placement may proceed as recommended for each system (Figures 1 and 2).

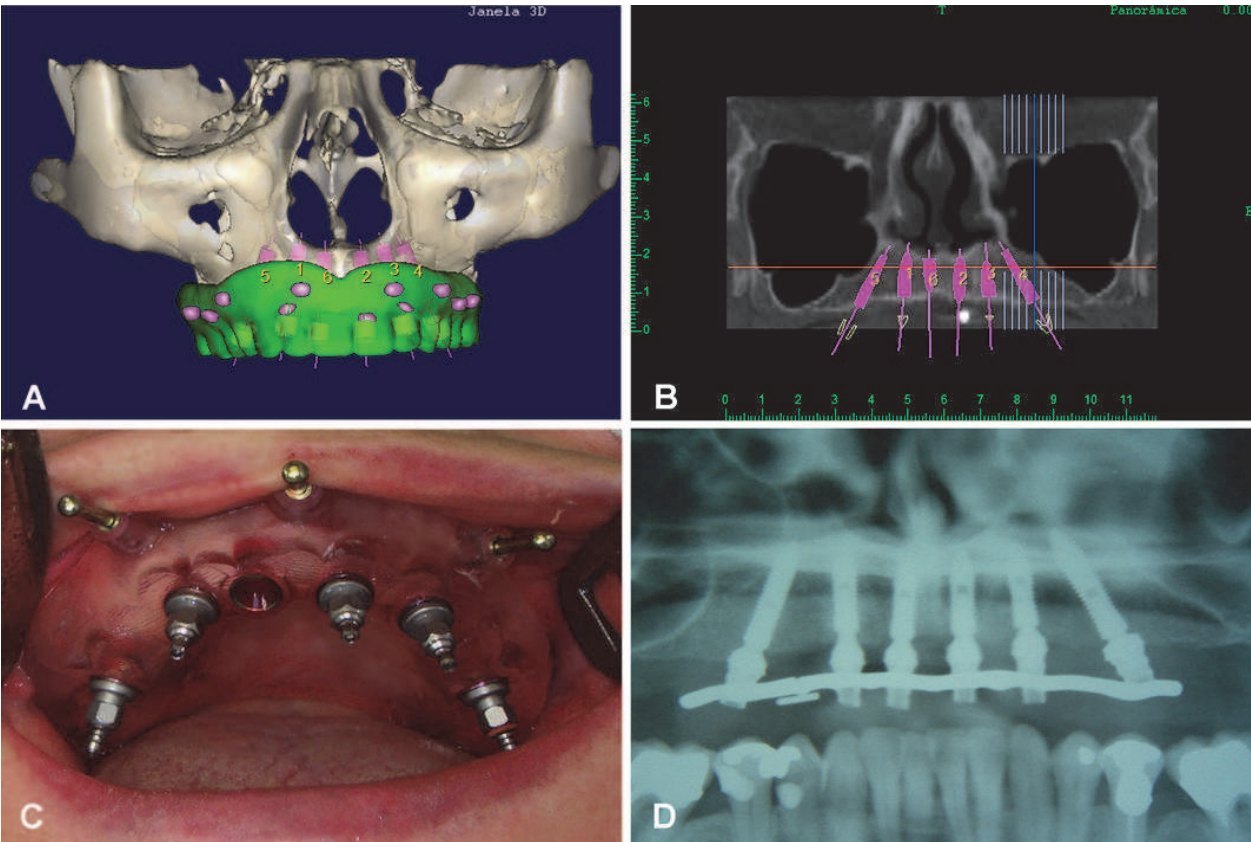


Fig. 1. Guided surgery for complete upper arch rehabilitation. a) Three-dimensional view of preoperative planning. Note radiopaque markers used to superimpose scans of the guide (isolated and in occlusion). Dentaslice® software package (Bioparts®, Brazil). b) Preoperative implant positioning. c) Five implants in place. Note insertion of anchor pins into stereolithographic guide. Neoguide® system (Neodent®, Brazil). d) Postoperative panoramic radiograph. Note similarity to virtual planning.

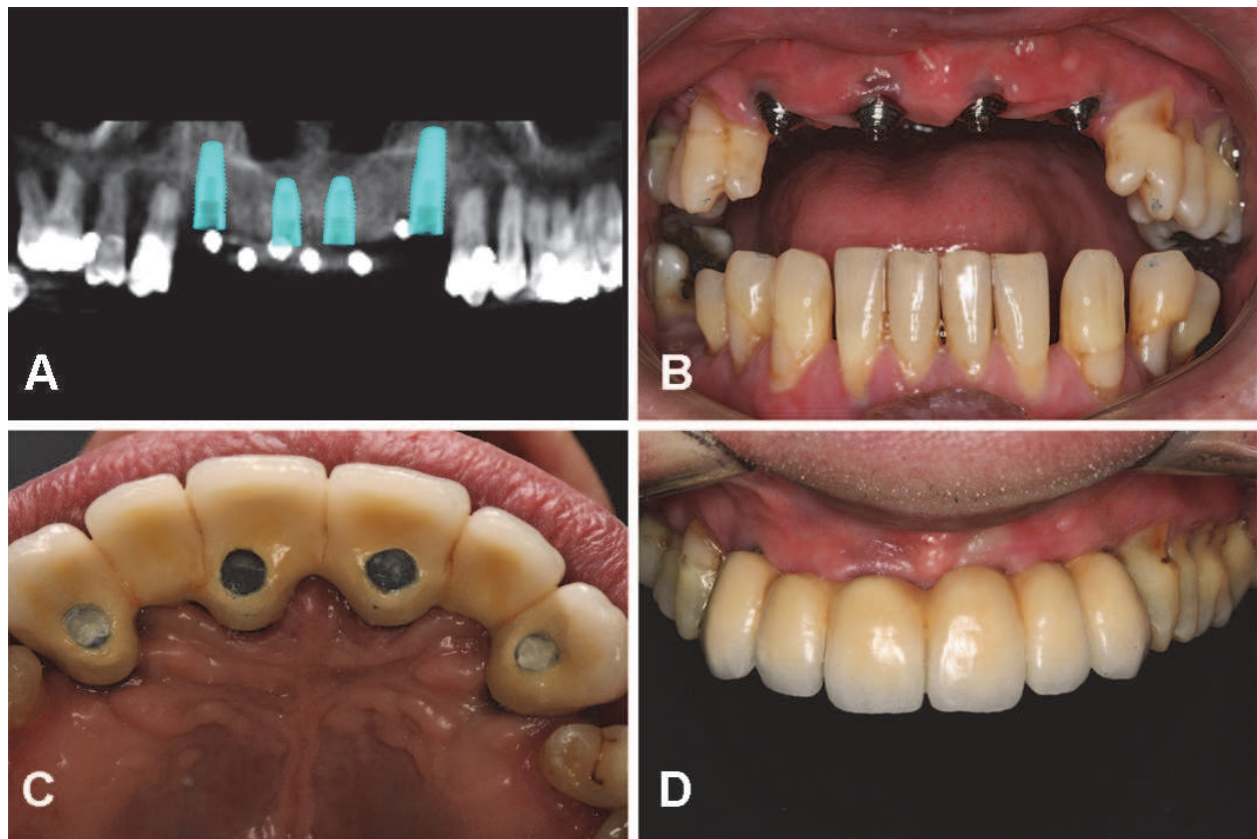


Fig. 2. Guided surgery for partial anterior-superior rehabilitation. a) Preoperative planning. Nobelguide® software system (Nobel Biocare®, Sweden) b) Implant position, immediately after surgery. c) Palatal emergence of implants, in accordance with virtual planning. d) Final result: porcelain-fused-to-metal restoration.

#### 4. Final remarks

Implant planning has always been a major challenge of dental practice. CT is often unable to provide precise definitions of implant size and will not always be useful in preventing anatomical complications during surgery. Loubele et al (2007) found that bony dimensions were underestimated on the basis of measurements taken from several CT scans. Likewise, Suomalainen et al. (2008) reported errors in measurement of bone dimensions on CT images. These setbacks are even more critical when planning implants for patients with little available bone tissue.

The advent of virtual planning and rapid prototyping techniques has led to a shift in this paradigm. Biomedical prototypes have made it possible for the implantologist to visualize and directly manipulate areas of interest, thus narrowing the gap between pre- and intraoperative findings (Choi et al., 2002; Sarment et al., 2003a; Meurer et al., 2008). Virtual planning permits three-dimensional analysis of implant position. Its clinical application—guided surgery—optimizes intra- and postoperative outcomes, as it can reduce surgical morbidity and improve the predictability of the proposed treatment plan.

Studies on guided surgery have gained prominence in the dentistry literature since the early 2000s. Gateno et al. (2003) studied the fit precision of stereolithographic surgical splints and that of conventional acrylic resin splints. Their results indicated that stereolithographic

splints had a high degree of accuracy of seating, thus enabling transfer of virtual treatment plans directly to the patient during surgery.

Van Assche et al. (2007) evaluated the precision of transfer of computer-based planning for implant placement in four partially edentulous human jaws with soft tissues present. All stages of guided surgery were performed on the anatomical specimens, from molding and diagnostic wax-up to placement of implants (a total of 12).

Postoperative cone-beam CT scans were obtained and superimposed onto preoperative scans in a virtual environment. Placed implants had a mean angular deviation of 2 degrees (range, 0.7 - 4 degrees) from the planned position, whereas mean linear deviation was 1 mm (0.3 - 2.3 mm) at the hex and 2 mm (0.7 - 2.4 mm) at the apical implant tip.

The authors conclude that cone-beam CT images can be used in computer-based implant planning for guided implant surgery with rapid-prototyped guides (Van Assche et al., 2007).

Viegas et al. (2010) conducted an experiment on 11 dry human mandibles to assess transfer of virtual implant position planning to surgery. Implant positions were standardized and simulated in an appropriate software package, using preoperative cone-beam CT scans as a basis. Models and surgical guides for each mandible were fabricated using stereolithography methods. Simulated surgeries, including implant placement and removal, were first performed on each prototype. Implants were then placed into the mandible replicas. Analysis of results was based on standardized postoperative CT scanning of prototypes and replicas for visualization of the implant beds. Superposition of pre- and post-operative three-dimensional models enabled assessment of the linear distance and angle between the long axes of planned and placed implants. Linear measurements made directly on models were used to assess the validity of prototype-simulated procedures as a tool for treatment planning in oral implantology. The variations in distance between the coronal, central, and apical regions of the 22 implants evaluated in this study were, on average, <0.41 mm. Mean deviation in angle was  $1.45 \pm 0.89$  degrees for implants placed on the right and  $0.70 \pm 0.30$  degrees for implants placed on the left. Comparison of samples by means of Student's *t* test, using a reference value of zero, showed statistically significant differences for all measurements ( $p < 0.05$ ). The correlation between implant bed positions in each mandible was fair to very good, depending on the distance analyzed and on the method used for interpretation of measurements. This study found that real-life deviation from planned dental implant positions determined by means of virtual planning and simulated surgery on a biomedical prototype were within a range that indicates the reliability of guided surgery as a method of dental implant placement.

In a clinical study, Nickenig and Eitner (2007) evaluated transfer of virtual implant plans to the operative field by means of the guided surgery technique. A total of 102 patients took part in the study (250 implants). Implants were placed into the posterior area of the mandible in 55.4% of cases. Eighteen cases (7.2%) involved rehabilitation of fully edentulous arches.

Computer-based virtual planning based on cone-beam CT scans was used in all cases. Flapless surgery was used for placement of 147 implants (58.8%) and all patients had uneventful intraoperative courses. In 98.4% of patients, there were no issues with surgical guide fit or instrumentation. Reduced interocclusal distance limited applicability of the technique in four patients.

Initial plans were changed in eight cases, when raising the mucoperiosteal flap revealed a need for modifications in manipulation of the available bone tissue and simultaneous



implant placement. Regarding predictability of implant size, only one implant had to be replaced with a smaller-diameter equivalent due to insufficient bone thickness.

Postoperative panoramic radiographs showed that anatomical structures such as the maxillary sinus, mandibular canal, mental foramen, and neighboring teeth were spared as planned. Comparison of postoperative radiographs and panoramic reconstructions created by the planning software revealed substantial differences in implant angle in nine cases.

The authors concluded that virtual plans based on cone-beam CT scans can be reproduced during implant placement surgery, and constitute a reliable method for defining implant position and size, preventing anatomical complications, and enabling wider use of flapless surgery (Nickenig & Eitner, 2007).

The minor variations between planned and actual implant placement in the aforementioned studies show that computer-based treatment plans can be reliably transferred to the operative environment by means of the guided surgery technique.

Furthermore, another key advantage of this procedure is the possibility of immediate loading of functional prostheses. Implant planning and positioning should not only take into account successful intraosseous implant placement, but also ensure that the future prosthesis is passively and securely seated on its fixtures. Prosthetic options for offsetting deviations in implant position vary according to the chosen guided surgery system. Even so, the current literature reveals a concern with the longevity of these implants.

Sanna, Molly, and Van Steenberghe (2007) evaluated the survival of 183 implants (30 patients) placed for rehabilitation of fully edentulous arches with the guided surgery technique, using cone-beam CT scanning, tissue-borne guides, and immediate loading. The results showed that guided placement of dental implants followed by immediate loading of fixed prostheses was associated with survival rates similar to those obtained with the same mode of rehabilitation on implants reopened after the osseointegration period.

Schneider et al. (2009) conducted a systematic review to assess the accuracy and clinical applications of guided implant surgery. A literature search yielded 3120 titles, eight of which met the inclusion criteria in terms of accuracy and 10 in terms of the clinical performance. Meta-regression analysis revealed a mean deviation of 1.07 mm at the entry point (95% CI, 0.76 – 1.22 mm) and 1.63 mm at the apex (95% CI, 1.26 – 2 mm). No significant differences between the studies were found regarding method of template production or template support and stabilization. Early surgical complications occurred in 9.1% of cases. Limited access for instrumentation and fracture of the surgical guide were the sole technique-related complications observed—all others were equally possible during conventional implant placement procedures. Early prosthetic complications occurred in 18.8% and late prosthetic complications in 12% of cases. Noteworthy prosthesis-related complications included misfit of abutment to bridge, extensive adjustments of the occlusion, and incomplete seating of the prosthesis. The most common delayed complications were screw loosening and prosthesis fracture.

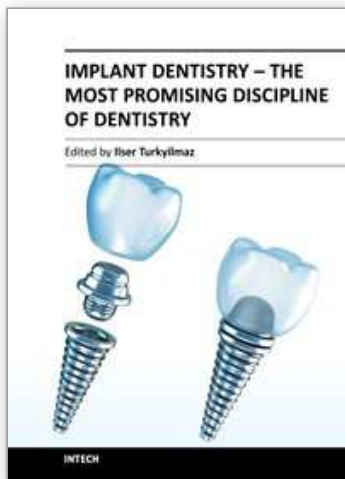
Implant survival rates, assessed in six clinical studies with a total of 537 implants—most loaded immediately after flapless implantation procedures—ranged between 91 and 100%.

Studies such as these related justify the relevance of investigations that seek improvement toward increasingly accurate and safe methods that are beneficial to patients and dentists alike, such as virtual planning and guided surgery.

## 5. References

- Almog, D. M., Benson, B. W., Wolfgang, L., Frederiksen, N. L. & Brooks, S. L. (2006). Computerized tomography-based imaging and surgical guidance in oral implantology. *J Oral Implantol*, Vol. 32, No. 1, pp. 14-18, ISSN 0160-6972
- Balshi, S. F., Wolfinger, G. J. & Balshi, T. J. (2006). Surgical planning and prosthesis construction using computed tomography, CAD/CAM technology, and the Internet for immediate loading of dental implants. *J Esthet Restor Dent*, Vol. 18, No. 6, pp. 312-323; discussion 324-315, ISSN 1496-4155
- Choi, J. Y., Choi, J. H., Kim, N. K., Kim, Y., Lee, J. K., Kim, M. K., Lee, J. H. & Kim, M. J. (2002). Analysis of errors in medical rapid prototyping models. *Int J Oral Maxillofac Surg*, Vol. 31, No. 1, (February 2002), pp. 23-32, ISSN 0901-5027
- Erben, C., Vitt, K. & Wulf, J. (2002). The Phidias validation study of reported benefits from use of stereolithographic models. *Phidias Newsletter*, Vol. [S.I.], No. 8, (March 2002), pp. 15-16, ISSN
- Erickson, D. M., Chance, D., Schmitt, S. & Mathis, J. (1999). An opinion survey of reported benefits from the use of stereolithographic models. *J Oral Maxillofac Surg*, Vol. 57, No. 9, (September), pp. 1040-1043, ISSN 0278-2391
- Ganz, S. D. (2003). Use of stereolithographic models as diagnostic and restorative aids for predictable immediate loading of implants. *Pract Proced Aesthet Dent*, Vol. 15, No. 10, (November-December 2003), pp. 763-771; quiz 772, ISSN 1534-6846
- Garg, A. K. (2006). Surgical templates in implant dentistry. *Dent Implantol Update*, Vol. 17, No. 6, (June 2006), pp. 41-44, ISSN 1062-0346
- Gateno, J., Xia, J., Teichgraber, J. F., Rosen, A., Hultgren, B. & Vadnais, T. (2003). The precision of computer-generated surgical splints. *J Oral Maxillofac Surg*, Vol. 61, No. 7, (July 2006), pp. 814-817, ISSN 0278-2391
- Jacobs, R., Adriansens, A., Naert, I., Quirynen, M., Hermans, R. & Van Steenberghe, D. (1999). Predictability of reformatted computed tomography for pre-operative planning of endosseous implants. *Dentomaxillofac Radiol*, Vol. 28, No. 1, (January 1999), pp. 37-41, ISSN 0250-832X
- James, W. J., Slabbekoorn, M. A., Edgin, W. A. & Hardin, C. K. (1998). Correction of congenital malar hypoplasia using stereolithography for presurgical planning. *J Oral Maxillofac Surg*, Vol. 56, No. 4, (April 1998), pp. 512-517, ISSN 0278-2391
- Lal, K., White, G. S., Morea, D. N. & Wright, R. F. (2006). Use of stereolithographic templates for surgical and prosthodontic implant planning and placement. Part I. The concept. *J Prosthodont*, Vol. 15, No. 1, (January-February 2006), pp. 51-58, ISSN 1059-941X
- Loubele, M., Guerrero, M. E., Jacobs, R., Suetens, P. & van Steenberghe, D. (2007). A comparison of jaw dimensional and quality assessments of bone characteristics with cone-beam CT, spiral tomography, and multi-slice spiral CT. *Int J Oral Maxillofac Implants*, Vol. 22, No. 3, (May-June 2007), pp. 446-454, ISSN 0882-2786
- Marchack, C. B. (2007). CAD/CAM-guided implant surgery and fabrication of an immediately loaded prosthesis for a partially edentulous patient. *J Prosthet Dent*, Vol. 97, No. 6, (June 2007), pp. 389-394, ISSN 0022-3913
- Meurer, M. I., Meurer, E., Silva, J. V. L. d., Bárbara, A. S., Nobre, L. F., Oliveira, M. G. d. & Silva, D. N. (2008). [Acquisition and manipulation of computed tomography images of the maxillofacial region for biomedical prototyping]. *Radiol. bras*, Vol. 41, No. 1, (January-February 2008), pp. 49-54, ISSN 0100-3984

- Nickenig, H. J. & Eitner, S. (2007). Reliability of implant placement after virtual planning of implant positions using cone beam CT data and surgical (guide) templates. *J Craniomaxillofac Surg*, Vol. 35, No. 4-5, (June-July 2007), pp. 207-211, ISSN 1010-5182
- Parel, S. M. & Triplett, R. G. (2004). Interactive imaging for implant planning, placement, and prosthesis construction. *J Oral Maxillofac Surg*, Vol. 62, No. 9 Suppl 2, (September 2004), pp. 41-47, ISSN 0278-2391
- Peltola, S. M., Melchels, F. P., Grijpma, D. W. & Kellomaki, M. (2008). A review of rapid prototyping techniques for tissue engineering purposes. *Ann Med*, Vol. 40, No. 4, pp. 268-280, ISSN 1365-2060
- Rosenfeld, A. L., Mandelaris, G. A. & Tardieu, P. B. (2006). Prosthetically directed implant placement using computer software to ensure precise placement and predictable prosthetic outcomes. Part 1: diagnostics, imaging, and collaborative accountability. *Int J Periodontics Restorative Dent*, Vol. 26, No. 3, (June 2006), pp. 215-221, ISSN 0198-7569
- Sanna, A. M., Molly, L. & van Steenberghe, D. (2007). Immediately loaded CAD-CAM manufactured fixed complete dentures using flapless implant placement procedures: a cohort study of consecutive patients. *J Prosthet Dent*, Vol. 97, No. 6, (June 2007), pp. 331-339, ISSN 0022-3913
- Sarment, D. P., Al-Shammari, K. & Kazor, C. E. (2003a). Stereolithographic surgical templates for placement of dental implants in complex cases. *Int J Periodontics Restorative Dent*, Vol. 23, No. 3, (June 2003), pp. 287-295, ISSN 0198-7569
- Sarment, D. P., Sukovic, P. & Clinthorne, N. (2003b). Accuracy of implant placement with a stereolithographic surgical guide. *Int J Oral Maxillofac Implants*, Vol. 18, No. 4, (July-August 2003), pp. 571-577, ISSN 0882-2786
- Schneider, D., Marquardt, P., Zwahlen, M. & Jung, R. E. (2009). A systematic review on the accuracy and the clinical outcome of computer-guided template-based implant dentistry. *Clin Oral Implants Res*, Vol. 20 No. Suppl 4, (September 2009), pp. 73-86, ISSN 1600-0501
- Souza, M. A. d., Centeno, T. M. & Pedrini, H. (2003). [Integrating 3D reconstruction of tomographic images and rapid prototyping for fabrication of medical models]. *Rev. bras. eng. biomed*, Vol. 19, No. 2, (August 2003), pp. 103-115, ISSN 1517-3151
- Suomalainen, A., Vehmas, T., Kortensniemi, M., Robinson, S. & Peltola, J. (2008). Accuracy of linear measurements using dental cone beam and conventional multislice computed tomography. *Dentomaxillofac Radiol*, Vol. 37, No. 1, (January 2008), pp. 10-17, ISSN 0250-832X
- Tardieu, P. B., Vrielinck, L. & Escolano, E. (2003). Computer-assisted implant placement. A case report: treatment of the mandible. *Int J Oral Maxillofac Implants*, Vol. 18, No. 4, (July-August 2003), pp. 599-604, ISSN 0882-2786
- Van Assche, N., van Steenberghe, D., Guerrero, M. E., Hirsch, E., Schutyser, F., Quirynen, M. & Jacobs, R. (2007). Accuracy of implant placement based on pre-surgical planning of three-dimensional cone-beam images: a pilot study. *J Clin Periodontol*, Vol. 34, No. 9, (September 2007), pp. 816-821, ISSN 0303-6979
- Viegas, V. N., Dutra, V., Pagnoncelli, R. M. & de Oliveira, M. G. (2010). Transference of virtual planning and planning over biomedical prototypes for dental implant placement using guided surgery. *Clin Oral Implants Res*, Vol. 21, No. 3, (March 2010), pp. 290-295, ISSN 1600-0501
- Wulf, J., Vitt, K. D., Erben, C. M., Bill, J. S. & Busch, L. C. (2003). Medical biomodelling in surgical applications: results of a multicentric European validation of 466 cases. *Stud Health Technol Inform*, Vol. 94, No. pp. 404-406, ISSN 0926-9630



## **Implant Dentistry - The Most Promising Discipline of Dentistry**

Edited by Prof. Ilser Turkyilmaz

ISBN 978-953-307-481-8

Hard cover, 476 pages

**Publisher** InTech

**Published online** 30, September, 2011

**Published in print edition** September, 2011

Since Dr. Branemark presented the osseointegration concept with dental implants, implant dentistry has changed and improved dramatically. The use of dental implants has skyrocketed in the past thirty years. As the benefits of therapy became apparent, implant treatment earned a widespread acceptance. The need for dental implants has resulted in a rapid expansion of the market worldwide. To date, general dentists and a variety of specialists offer implants as a solution to partial and complete edentulism. Implant dentistry continues to advance with the development of new surgical and prosthodontic techniques. The purpose of *Implant Dentistry - The Most Promising Discipline of Dentistry* is to present a contemporary resource for dentists who want to replace missing teeth with dental implants. It is a text that integrates common threads among basic science, clinical experience and future concepts. This book consists of twenty-one chapters divided into four sections.

### **How to reference**

In order to correctly reference this scholarly work, feel free to copy and paste the following:

Vinicius Nery Viegas, Celso Gustavo Schwalm Lacroix, Rogério Miranda Pagnoncelli and Marília Gerhardt de Oliveira (2011). Virtual Planning for Dental Implant Placement Using Guided Surgery, *Implant Dentistry - The Most Promising Discipline of Dentistry*, Prof. Ilser Turkyilmaz (Ed.), ISBN: 978-953-307-481-8, InTech, Available from: <http://www.intechopen.com/books/implant-dentistry-the-most-promising-discipline-of-dentistry/virtual-planning-for-dental-implant-placement-using-guided-surgery>

**INTECH**  
open science | open minds

### **InTech Europe**

University Campus STeP Ri  
Slavka Krautzeka 83/A  
51000 Rijeka, Croatia  
Phone: +385 (51) 770 447  
Fax: +385 (51) 686 166  
[www.intechopen.com](http://www.intechopen.com)

### **InTech China**

Unit 405, Office Block, Hotel Equatorial Shanghai  
No.65, Yan An Road (West), Shanghai, 200040, China  
中国上海市延安西路65号上海国际贵都大饭店办公楼405单元  
Phone: +86-21-62489820  
Fax: +86-21-62489821



© 2011 The Author(s). Licensee IntechOpen. This chapter is distributed under the terms of the [Creative Commons Attribution-NonCommercial-ShareAlike-3.0 License](https://creativecommons.org/licenses/by-nc-sa/3.0/), which permits use, distribution and reproduction for non-commercial purposes, provided the original is properly cited and derivative works building on this content are distributed under the same license.

IntechOpen

IntechOpen