

We are IntechOpen, the world's leading publisher of Open Access books Built by scientists, for scientists

6,900

Open access books available

185,000

International authors and editors

200M

Downloads

Our authors are among the

154

Countries delivered to

TOP 1%

most cited scientists

12.2%

Contributors from top 500 universities



WEB OF SCIENCE™

Selection of our books indexed in the Book Citation Index
in Web of Science™ Core Collection (BKCI)

Interested in publishing with us?
Contact book.department@intechopen.com

Numbers displayed above are based on latest data collected.
For more information visit www.intechopen.com



Bone Substitutes and Validation

Christopher Ogunsalu

Human Anatomy and Forensic Dentistry

Department of Basic Medical Sciences

Faculty of Medical Sciences, University of the West Indies, Mona Jamaica

*Caribbean Institute of Oral and Maxillofacial Implantology and Surgery
Jamaica*

1. Introduction

This chapter will focus on the review of the various bone grafting materials in the market for implant dentistry with much emphasis on the fact that they are all second-hand bones (bone substitutes) when compared with the autogeneous bone graft which is the gold standard to which all bone substitutes are compared.

Bone grafting implies to the application of autogenous bone or other bone substitute obtained from natural or synthetic source to an area of with boney defect. Bone grafting is a procedure and should not be confused with bone regeneration which is the actual formation of new bone in the grafted defect. Bone grafting does not necessarily lead to bone regeneration. It is so important that the clinician and the patient are aware of the difference in terminology because of the clinical, scientific and medicolegal implications.

The use of bone substitutes or bone replacement source has increased tremendously in implant dentistry today and will continue to be so because of the unavailability of autogenous bone from the intra-oral site in most situation and patients are becoming more and more tolerant to clinicians harvesting bone from the extra-oral site such as the iliac crest or the tibial tuberosity.

The mechanisms available for bone regeneration will be fully described and classification of bone substitutes under these mechanisms will be attempted so as to assist the surgeon make a decision regarding which bone substitute to be used for pre-implant, intra-implant surgery and post-implant bone grafting and regeneration.

Theses previously mentioned bone regeneration mechanisms are actually positive mechanisms (osteogenesis, osteoinduction and osteoconduction). The author will introduce a newly discovered mechanism called the osteo-obstructive mechanism as a negative bone regeneration mechanism. This osteoobstructive mechanism was accidentally discovered by the author on single photon emission computerized tomography (SPECT) with histologic correlation during animal experiment to validate bone grafting technique and substitutes in the Ogunsalu sandwich bone regeneration technique. This osteoobstructive mechanism has been histologically confirmed to be due to foreign body reaction.

In this chapter bone grafting will be mentioned distinctly from bone regeneration, similarly bone substitute (second -hand bone) will be distinctly separated from autogeneous bone graft.

The best GTR-membranes which will be preferably used with bone substitutes will be mentioned against the background of a new bone grafting technique called the Ogunsalu sandwich technique.

Finally the only available method for the qualitative and quantitative validation of bone substitutes and their comparison with one another will be described, in conjunction with histologic correlation. This method utilizes SPECT as a dynamic way for assessing osteoblastic activity after bone grafting and during bone regeneration.

1.1 Classification, types and source

This has been dealt with poorly in most standard textbook and as such I would attempt to adjust the existing classifications and sources. The source of bone graft could be autogenous or non autogenous with the autogenous bone source being the gold standard by which the non autogenous sources are to be compared for efficiency in effecting bone regeneration in the desired site. The autogenous bone can be derived from both intraoral or extra-oral sites. The intra-oral site includes the, chin, maxillary tuberosity, the body of the mandible, the ramus of the mandible, zygomatic buttress or even the exostosis including the oral tori (Fig. 1)

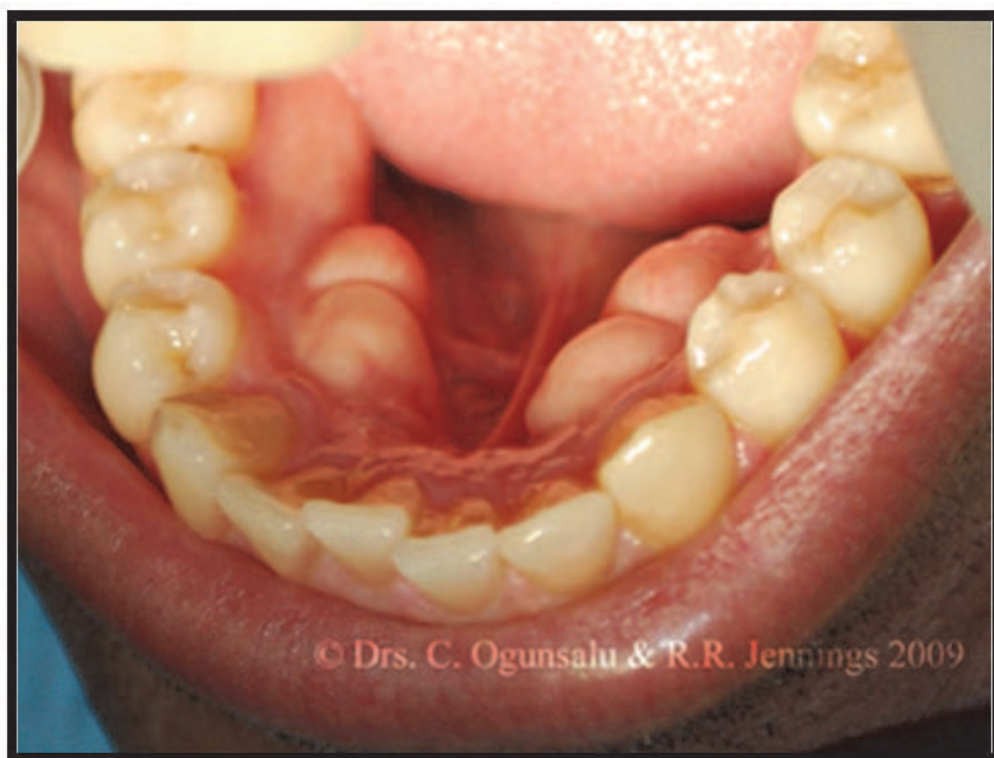

Fig. 1. Bilateral, multilobulated oral tori of the mandible.

The non-autogenous source are therefore second-hand in comparison to the autogenous source, for this reason I will call them the second-hand bones or bone grafting material (bone substitutes). Autogenous bone used for bone grafting should as such not be called bone grafting materials but rather a bone graft source.

The second hand bones are basically the allograft, alloplast of which the commercially available xenograft and the synthetic graft materials are generally considered a subgroup of the alloplastic bone grafting source.

The figure 2 shows the classification of bone grafting sources taken from the Glossary of implant dentistry II, published by the international congress of oral implantologists. I would however suggest that the classification shown in figure 3 be considered a reasonable variation of the former classification.

The origin of the bone graft will dictate the mechanism of its action with the understanding that none of them is osteogenic in action like the autogenous bone graft source, which is an organic bone source harvested from the patient. This autogenous bone also additionally forms bone by osteoinduction and osteoconduction, the two mechanisms ascribed to the second hand bones.

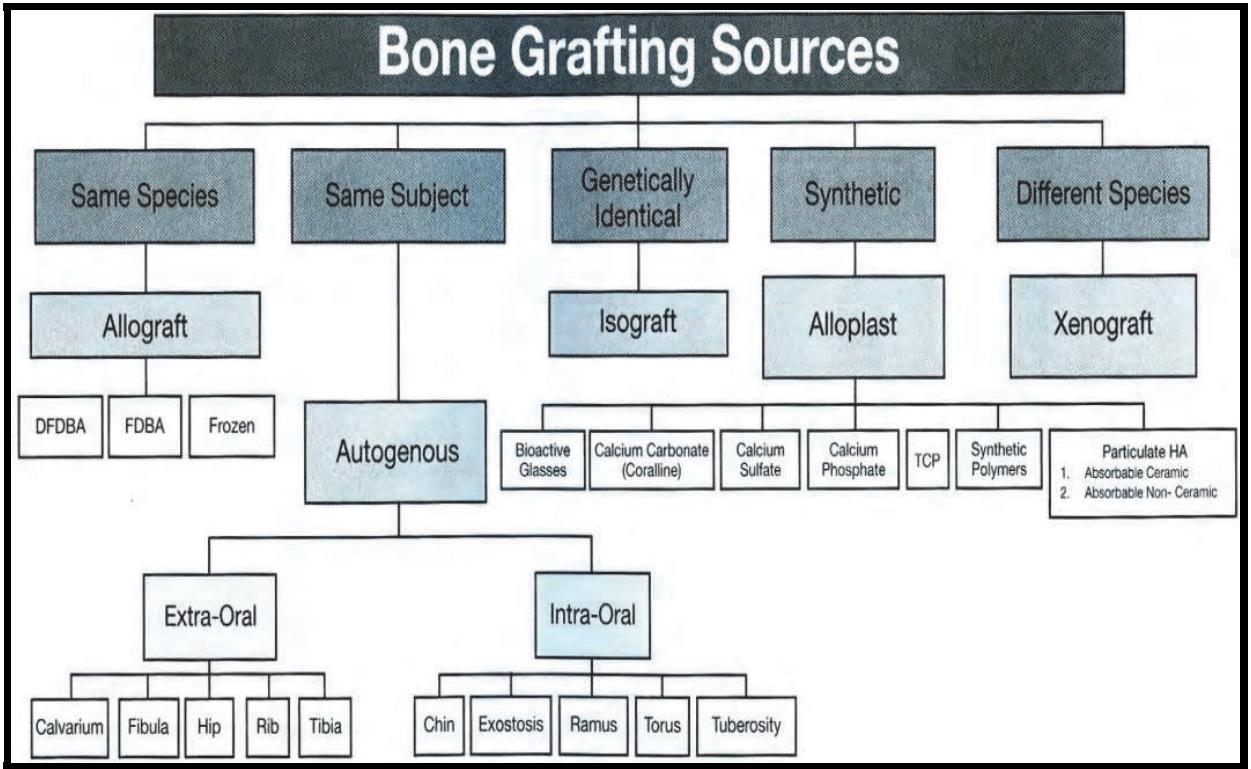


Fig. 2. Showing a reasonable classification of bone grafting source

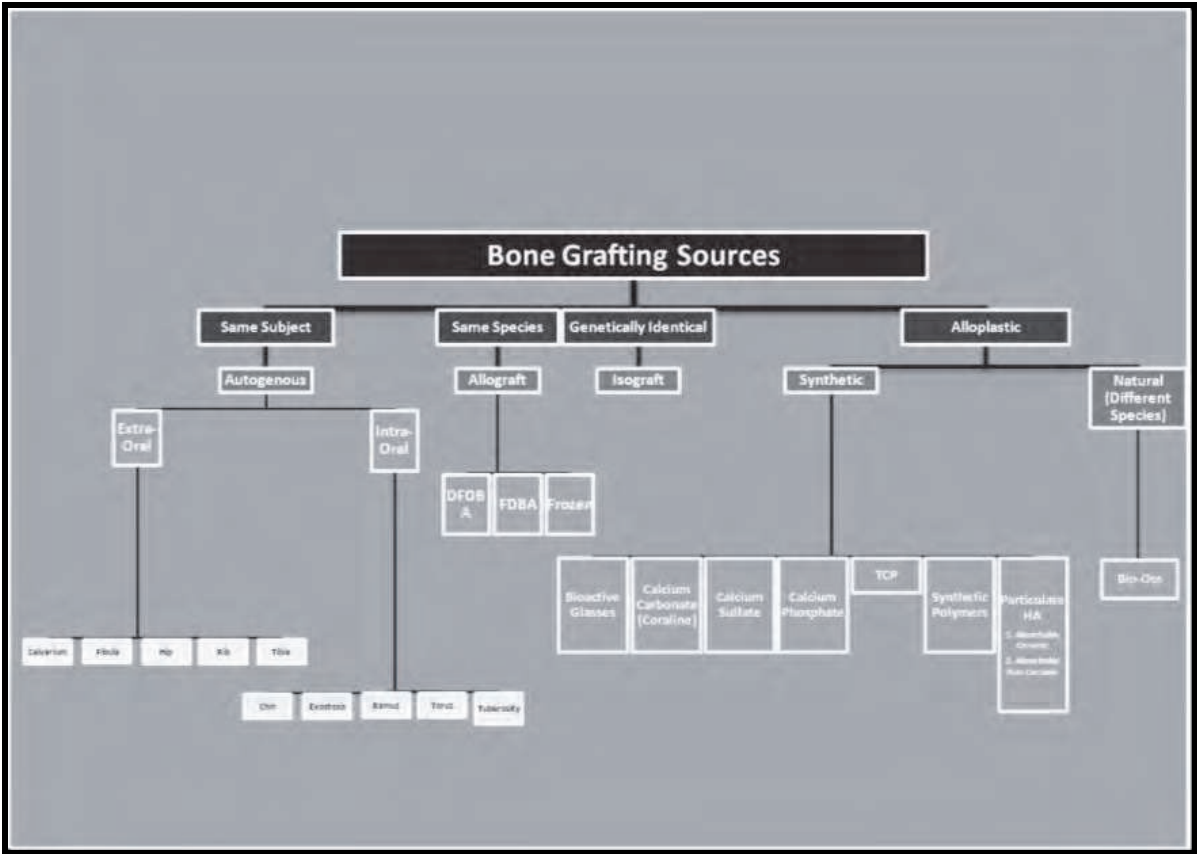


Fig. 3. Showing a much better classification of bone grafting source

1.2 Mechanism of action of bone substitutes

Bone grafts can effect bone replacement through three different mechanisms: osteogenesis, osteoinduction and osteoconduction (Misch and Dietsh 1993). Osteogenesis refers to organic material capable of forming bone directly from osteoblast (Misch and Dietsh 1993 and Marx and Saunders 1986). An osteogenic graft can therefore be said to be derived from or composed of tissues involved in the natural growth or repair of bone. It is for this reason that they can even encourage bone formation in soft tissues or activate more rapid bone growth in bone sites (Garg 2004, Wood and Moore 1988). Osteoinductive materials are capable of inducing the transformation of undifferentiated meseneymal cells into osteoblasts or chondroblast and enhance bone growth or even grow bone where it is not expected (Misch and Dietsh 1993). Urist (Urist 1980 and Urist 1965) recognized the mechanism as dependent upon many factors which includes specific proteins (e.g. bone morphogenic proteins [BMPs] located primarily in cortical bone. Osteoconduction is characteristic of a material (often organic) which permits bone apposition from existing bone and requires the presence of bone or differentiated mesenchymal cells (Rejda, Peelen and deGroot 1977 and Jarcho 1981). Osteoconduction provides a physical matrix or scaffolding suitable for the deposition of new bone. Osteoconductive graft are conductive to bone growth and allows bone apposition from existing bone, but do not produce bone formation themselves when placed within soft tissue (Garg 2004, Wood and Moore 1988). The healing of dental implants with a direct bone contact has been described as an osteoconductive process (Albrektsson 1985, 129-143).

Transplanted osteogenesis is another term for bone grafting. This term emphasizes that bone is dynamic and forms by cellular regeneration, which produces osteoid that becomes mineralized. A graft is not a solid bone block that heals into place (Garg 2004 and Marx and Garg 1998). Bone grafting is accomplished through osteogenesis, osteoinduction and osteoconduction (Lane 1995, Frame 1987, Pinholt, Bang and Haanaes 1991, and Lancet 1992). Osteogenesis refers to the formation and development of bone by osteocompetent cells. Osteogenic graft materials which are derived from or comprised of tissue involved in the natural growth and repair; it can encourage bone formation in soft tissues, and stimulates faster bone growth in bone implant site, whereas osteoinduction is the process of activating osteogenesis by recruiting cells from the surrounding natural bone that then differentiate into bone-forming cells. Osteoinductive grafts can enhance bone generation, sometimes even resulting in the extension or growth of bone where it is not normally found (Marx and Garg 1998). Osteoconductive grafts are those that act as nonviable scaffold on to and within which the patient’s own natural bone grows. They are conductive to bone growth and allow apposition from existing bone but do not produce or trigger bone formation themselves when placed in soft tissue.

The table below shows the properties of the various types of bone graft sources in terms of mechanism of action with regards to bone regeneration.

Properties of various types of bone graft source.			
	Osteoconductive	Osteoinductive	Osteogenic
Alloplast	+	-	-
Xenograft	+	-	-
Allograft	+	+/-	-
Autograft	+	+	+

Table 1. Showing the properties / mechanism of action for various bone source

It is important to note that all bone grafting materials have one or more of these three modes of action. Mixing of bone grafting substitutes can assist in bringing about a desired combination of modes of action for bone formation. For example Bio-Oss which is basically osteoconductive can be mixed with allograft as a deliberate or circumstantial cocktail to effect both osteoconductive and some osteoinductive properties. Because of making up the quantity of bone required in defects that definitely will benefit more from autogenous bone graft, any bone substitute can be mixed with autogenous bone graft to additionally effect all the mechanisms of action of bone regeneration attributed to autogenous bone graft.

Osteogenesis can form bone more rapidly and in conditions which have the least amount of bone. Autogenous bone is suggested even when additional operating time and surgical site preparation is required when limiting factors exist. Osteoconductive materials require the most ideal condition to grow bone, yet are the easiest material to obtain and manipulate. The amount of remaining host bone in the region and mode of action and physical characteristic of available graft materials must be considered prior to the selection of any one type or combination for use in implant dentistry (Misch and Dietsh 1993).

Osteogenesis, osteoinduction and osteoconduction are all positive mechanisms of bone regeneration with Osteogenesis being the fastest and most reliable. Bone substitute that regenerate bone via the osteoconductive mechanism are the least efficient.

In his classical experiment using animal model, Ogunsalu et al accidentally discovered the negative mechanism that will prevent bone regeneration (Ogunsalu 2009). This new mechanism called osteobstruction will be discussed in detail towards the end of the chapter.

2. Review of the literature on bone replacement source

The three primary types of bone graft material are autogenous bone, allograft and alloplast of which commercially available xenografts are generally considered a subgroup (Garg 2004). The mechanism by which these graft materials work normally depends on the origin and composition of the material (Misch and Dietsh 1993 and Lancet 1992). Autogenous bone, an organic material harvested from the patient, forms new bone by osteogenesis, osteoinduction and osteoconduction. Harvested from the cadavers, allografts which may be cortical or trabecular, have osteoconductive and possible osteoinductive properties (Garg 2004), but definitely they are not osteogenic. The alloplasts, which may be composed of natural or synthetic material, are typically only osteoconductive (Garg 2004).

In determining what type of graft material to use, the clinician must consider the characteristics of the bony defect to be restored (Misch and Dietsh 1993). In general, the larger the defect to be restored, the greater the amount of autogenous bone required. For small defects and for those with three to five bony walls still intact, alloplast may be used alone or with allografts. For relatively large defects or those with only one to three bony walls intact, autogenous bone must be added to any other type of graft material being considered. One of the complications during augmentation procedures with any grafting material is soft tissue ingrowths; it is for this reason that guided bone regeneration (GBR) using resorbable or non-resorbable membrane is to be employed (Schopper, Goriwoda, Moser, Spassova, Watzinger and Ewers 2001).

With regards to Maxillary sinus lift procedure, various materials including autogenous bone (Kent and Block 1989, Jensen, Simonsen and Sindet-Pederson 1990, Reghobar, Browne, Reintsena and Van Dort 1993, Adell R, Lekholm, Grondahl, Branemark, Lindstorm and Jacobsson 1990, Kahnberg, Nystrom and Bartholdsson 1989 and Nystrom, Kahnbourg and Gunne 1993), bone allograft (Misch and Dietsh 1993, Lane 1995, Lancet 1992, Wood and Moore 1988, Rummelhart, Mellonig, Gray and Towle 1989, Mellonig 1987, Tatum et al. 1993 and Tatum 1996) and alloplasts such as tricalcium phosphate (TCP), resorbable and non resorbable hydroxyapatite (Misch and Dietsh 1993, Rummelhart et al. 1989, Fetner, Hartigan and Low 1994, Schepers et al. 1993 and Smiler et al. 1992) bovine bone derivative (bovine-derived mineralized deproteinised bone) (McAllister et al. 1999) and bioactive glasses are used. It is important to note that an ideal graft is non-toxic, non-antigenic, non-carcinogenic, strong, resilient, easily fabricated, able to permit tissue attachment, resistant to infection, readily available and inexpensive (Wagner J 1989).

Autogenous bone which has long been considered the gold standards of grafting materials is currently the only osteogenic graft material available to clinical practitioners. When utilized for bone grafting autogenous bone heals into growing bone through all these modes of bone formation; these stages are not separate and distinct, but rather, overlap each other (Misch and Dietsh 1993). Autogenous bone can be harvested from extraoral sites such as the iliac crest or tibial plateau and intraoral sites such as the mandibular symphysis, maxillary tuberosity, ramus or exostosis (particularly the oral tori) (Misch and Dietsh 1993, Koole, Bosker, van der Dussen 1989 and Garg 1996).

It is well documented that less resorption is associated with the use of mandibular bone graft than with iliac crest grafts (Koole, Bosker, van der Dussen 1989). The use of expanded polytetrafluoroethylene (e-PTFE) membranes or slowly resorbable collagen membranes has been documented to enhance bone grafting (Buser, Dula, Hirt, Schenk et al. 1996). Furthermore, bone graft obtained intraorally would generally result in less morbidity; however intraoral bone sites provides a significantly smaller volume of bones than do extraoral sites such as the iliac crest or tibial plateau. The volume and type of regenerated bone needed for the site, will dictate the optimal donor site. The posterior iliac crest provides the greatest amount of bone (Koole, Bosker, van der Dussen 1989).

As previously stated, the autogenous bone graft is highly osteogenic and best fulfils the dental grafting requirement of providing a scaffold for bone regeneration (Hislop, Finlay and Moos 1993). Significant disadvantages associated with the use of autogenous bone include the need for a second operative site, resultant patient morbidity and in some cases the technical difficulties relating to obtaining a sufficient amount of graft material (this particular disadvantage relates to intraoral donor sites). In fact, it is these disadvantages and limitations that have lead to the development of less suitable alternatives such as allograft and alloplasts (Lane 1995, 36, Rummelhart, Mellonig, Gray and Towle 1989).

Autogenous bone graft forms the rigid scaffold which supports teeth and implants. It is composed of organic and inorganic structures. Resilience, toughness, and continuity are related to collagen, of the organic component. Stiffness, hardness and rigidity are characteristics of the inorganic aspect; a crystalline, ceramic-like material which is primarily hydroxyapatite (HA). This inorganic matrix contains organic components of osteocytes, osteoclasts, osteoblasts, osteogenic signaling proteins and various amount of mesenchymal tissue. Without any doubt, autogenous bone is the only osteogenic material (Misch and Dietsh 1993) and the various sites for harvesting autogeneous bone include intra-oral sites such as the chin, ramus, body of the mandible, maxillary tuberosity, oral tori and other exostosis, zygomatic buttress. The extra-oral sites are; tibial tuberosity, iliac crest (Misch and Dietsh 1993 and Garg 2004). Banked debris during implant osteotomy preparation is also another source of autogenous bone graft which is usually omitted by various authors (Misch and Dietsh 1993, Garg 2004, Koole, Bosker, van der Dussen 1989 and Garg 1996).

As shown in Figure. 4, grafted autogenous bone heals in three phases. During the first phase, the surviving cells are responsible for the formation of osteoid by osteogenesis. They are most active within the first four weeks after bone grafting (Marx and Saunders 1986, 347-428). The blood vessels from the host bone and the connecting tissue invade the graft. Bone cells from the host tissue follow the blood vessels and remodel the graft by a coupled resorption and formation phenomenon as reported by Roberts et al (Roberts et al. 1987). The BMP derived from the mineral matrix of the grafted bone through the resorbing action of osteoclast, acts as a mediator for the second phase (Urist 1980 and Urist 1965). The BMP and other proteins must be released prior to the osteoinduction cycle. Phase three occurs as the inorganic component of bone acts as a matrix and source of minerals during replacement of the matrix by the surrounding bone and resembles an osteoconductive mode of action. The three phases overlaps in the time sequence and are not separate phases of growing bone from the grafted autogenous material.

Grafted autogenous bone can be trabecular (cancellous), cortico-cancellous or cortical. The cancellous portion of grafts provides the cells for osteogenesis and survives best when a blood supply from the host bone is readily available. Cortico-cancellous block grafts permit

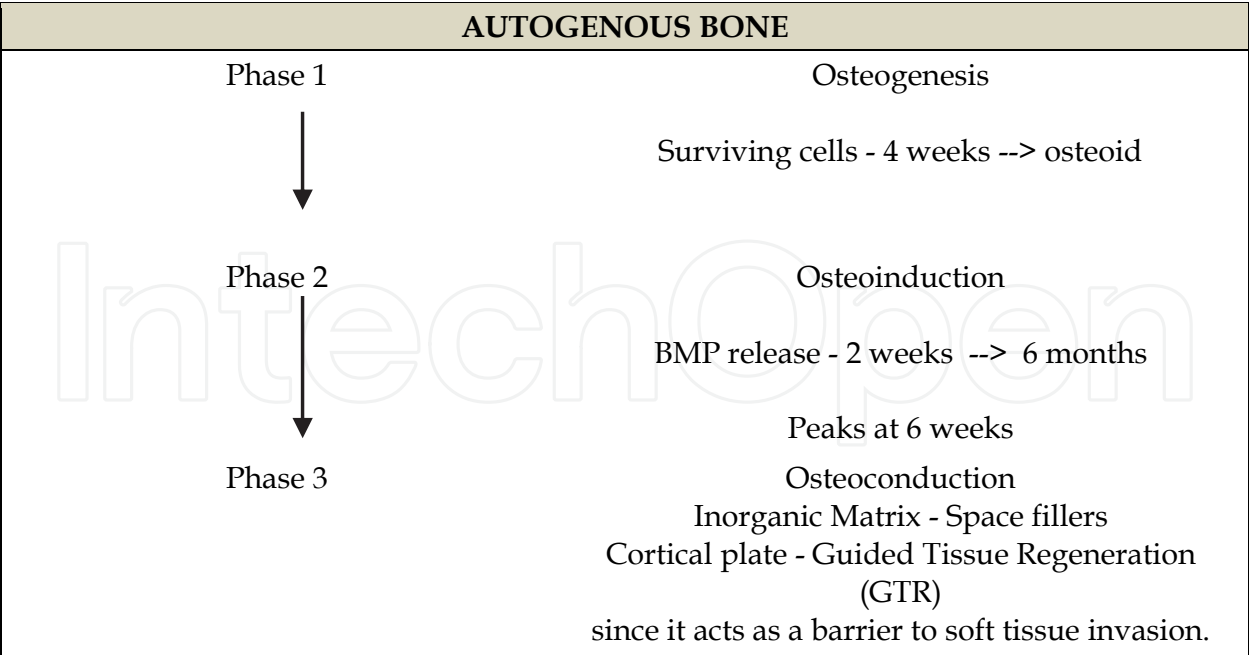


Fig. 4. Grafted autogenous bone healing, depicting the three phases of bone healing.

contouring and adaptation of the graft to the recipient bed anatomy. It is important however to quickly point out at this stage that the Ogunsalu sandwich bone regeneration technique (Ogunsalu 2009) will permit the cancellous portion of the autogeneous bone graft to be contoured and adapted to the recipients bed anatomy also. The trabecular portion is placed on the host bone and the cortical aspect is positioned on the surface of the graft. The cancellous portion is primarily responsible for the living bone cells and osteogenesis and therefore placed closest to the new blood vessels which arrive from the host bone and enter the graft at a rate of 0.5mm/day (Marx and Saunders 1986, 347- 428). The cortical graft supports osteogenesis only from the surviving cells (fewer than trabecular bone) and also provides more of the BMP compared with trabecular bone for the second osteoinductive phase (Longacre, Converse and Knize 1977). The cortical aspect also provides a more resistant scaffold for the third osteoconductive phase. In addition, it may act as a barrier to soft tissue invasion (thus excluding the need for a GTR membrane) and provide an extended period for blood vessels to enter the graft from the host bone (Misch and Dietsh 1993). Allografts are obtained from cadavers or from patients’ living relatives or non-relatives. Basically these bone grafts are of the same species but different genotypes. After processing, they are stored in bone banks. The advantages of allografts are availability, elimination of the donor site in the patient, decreased anesthetics and surgery time, decreased blood loss, and fewer complications. However, it is associated with some disadvantages which relate to bone tissues coming from another individual. Consequently the medical history must be thoroughly checked to eliminate donors with history of infection, malignant neoplasm’s, degenerative bone diseases, hepatitis B or C, sexually transmitted diseases, autoimmune disease and other problems which affects the quality of the bone and the health of the recipient (Fonseca et al. 1986). There are four main types of bone allografts: frozen, freeze-dried (lyophilized), demineralized freezed dried bone (DFDB), mineralized deproteinized and irradiated allograft. Fresh allografts are the most antigenic; freezing or freeze-drying the bone

significantly reduces its antigenicity (Lancet 1992). Allografts are not osteogenic and so, bone formation takes longer and results in less volume than can be achieved with autogenous grafts (Misch and Dietsh 1993). Allograft is said to form bone by osteoinductive effect on surrounding undifferentiated mesenchymal cells in the soft tissue over the graft as the blood vessels grow into the graft. It may also form bone by the osteoconduction phenomenon when the host bone resorbs the material and grows into its scaffold.

Freeze dried bone allograft (FDBA) can be used in either a mineralized or a demineralized (DFDBA) form. Demineralization removes the mineral phase of the graft material and possibly exposes the underlying bone collagen and growth factors such as the bone morphogenic proteins (BMPs) which has been implicated as a factor that increases the osteoconductive capabilities of allografts (Lane 1995, Acil et al. 2002 and Wikesjo et al. 2002). Freeze dried bone allograft hardens faster than DFBA because it is mineralized. Clinical studies have shown that grafting of the sinus with DFDBA alone results in the presence of dense connective tissue after six months whereas grafting with FDBA results in the presence of new bone formation (Meffert 1998). The clinical and histological study conducted by Feuille, Knapp, Brunsvold et al in 2003 showed that sites grafted with FDBA and subjected to GTR by coverage with an e-PTFE barrier can yield predictable result when augmenting alveolar ridges prior to placement of implants (Feuille et al 2003). MTF (Dentsply Friadent Ceramid, Lakewood Co.) and Puros (Zimmer dental, Carlsbond, CA) are examples of manufacturers' allografts. The MTF is an allogenic freeze-dried bone that is available in both mineralized and demineralized forms. The FDBA is more effective than DFDBA in the following situations: repair and restoration of fenestrations, minor ridge augmentation, fresh extraction site filler, sinus lift, bone grafting and in the repair of dehiscence's and failing implants. The Puros is an allogenic graft material that has been subjected to a well-tested processing method to reduce antigenicity and to minimize any cross infection with HIV or Hepatitis virus (Masullo 1995). Puros which is solvent-preserved (in comparison with the freeze-drying) to extract the water component has been demonstrated to osseointegrate as effectively as cryopreserved material and to be equally biotolerable (Gunther et al 1996). This material has been very promising with regards to good bone formation and repair (Sener et al. 1998, Becker et al. 1996, Dalkyz et al. 2000 and Alexopoulau et al 1998).

Moreover, because the water component is removed by solvents rather than by cryodehydration, which can alter the mineral as a result of volume expansion that occurs during the transition from the liquid to the solid phase, the mineral matrix is said to remain intact (Gunther et al 1996). This mineral also has both the mineral and collagen phases of allogenic tissues.

The use of DFDBA as a graft material continues to be questioned because of various reports showing that it is unpredictable in regenerating new bone. In one study in humans, for example, the DFDBA particles were found to be surrounded by uninflamed connective tissue (Brugnami et al. 1996). However, a more recent study (Feuille et al 2003) showed positive result with the use of DFDBA and a cell occlusive membrane. Incorporation of the DFDBA particles was observed in new bone that contained lacunae with osteocytes (Brugnami et al. 1996). The use of FDBA in this study instead of DFDBA might have yielded a more favorable outcome in terms of new bone regeneration. It is believed that BMPs and other non-collagenous protein in the expressed matrix are responsible for the osteoconductivity of DFDBA (Garg 2004). The osteoconductivity however, depends on the

quality and quantity of the bone matrix in the graft material (Zhang, Powers, and Wolfinbarger 1997). Furthermore, studies have shown that different samples from the same bone bank and also different samples from different bone banks of the DFDBA can display different osteoconductive activity (Schwartz et al 1996).

To date, there are no widely acceptable tests or guarantee to ensure that DFDBA materials meet any minimum standards for osteoinductive properties; it is for this reason that this graft material had been avoided by many surgeons when bone grafting is considered. *In vitro* and *in vivo* assays have been utilized to a limited extent to assess the osteoconductivity of DFDBA (Zhang, Powers, and Wolfinbarger 1997).

DFDBA can be combined with other materials that have the potential to enhance bone growth. For example, the use of tetracycline with a DFDBA allograft has been studied; however, no benefit was derived from reconstituting the DFDBA particles in tetracycline hydrochloride during grafting of osseous defects (Masters et al. 1996). Osteogenin, a bone-inductive protein isolated from human long bones has been combined with DFDBA and studied in the regeneration of intrabony periodontal defects. Although this combination generated new attachment apparatus and component tissues more positively, it did not have any additional positive effect on new bone regeneration (Bowers, Felton and Middleton 1991). In another study, which compared Osteofil (Regeneration Technologies, Alachula, FL) a DFDBA with Grafton (osteotech, Eatontown, NJ) another DFDBA which, forms bone via osteoconductivity, suggested that the graft processing methods could represent a greater source of variability than do differences among donors (Takikawa et al. 2003).

Irradiated cancellous bone (Rocky Mountain Tissue Bank, Denver, Co.) has also been used as a substitute graft material for autogenous bone (Tatum, Lebowitz, Tatum and Borgner 1993, Tatum 1996). This is trabecular allograft obtained from the spinal column and treated with between 2.5 and 3.8 megarads of radiation. It has been shown that among all available allograft, irradiated bone is most similar to autogenous bone in terms of demonstrating rapid replacement and consistent establishment of a reasonable ratio of new bone with less expense and morbidity than that associated with autogenous material (Tatum, Lebowitz, Tatum and Borgner 1993 and Tatum 1996). Unfortunately, because of lack of further work in this area, the use of this material is not recommended (Garg 2004).

Gendler (Gendler 1986) in 1986 demonstrated by experiments that perforated demineralized bone matrix was a new form of osteoinductive material. Osteoinduction which is defined as transformation of non osseous connective tissue cells into osteogenic and chondrogenic cell, is an important biological process whose contribution to the physiology of bone remodeling and fracture healing at that time had only began to be appreciated (Mckibbin 1978 and Peck 1981). In his unique experiment, Gendler demonstrated that subcutaneous implantation of perforated decalcified bone matrix (PDBM) induced multiple centers of endochondral osteogenesis with subsequent resorption of bone matrix and replacement by new bone. He therefore suggested that PDBM should be a useful research model to study osteoinduction and in the clinical management of orthopedic and reconstructive surgery for the filling of bone defects and stimulation of fracture healing (Gendler 1986).

Alloplast, xenografts and tissue-engineered materials are another group of bone graft substitutes. These include the deorganified bovine bone, synthetic calcium phosphate ceramics (e.g. hydroxyapatite, TCP) and calcium carbonate (e.g. Coralline). These ceramics form the new bone strictly by osteoconduction (Misch and Dietsh 1993 and Meffert et al. 1985) with the new bone formation taking place along their surface.

Basically alloplastic materials for bone growth are synthetic or deorganified biocompatible materials developed to cover a broad range of clinical applications for bone growth or soft tissue support. They come in a variety of textures, sizes and shapes and readily available and are mostly ceramics (Misch and Dietsh 1993).

Ceramic alloplasts may be bioinert or bioactive. Inert ceramics do not bond with the host bone. The relationship consists of an intimate mechanical contact which permits force transfer. They are rarely used as bone augmentation materials, but often are used as endosteal implants (e.g. aluminum oxide [Al_2O_3] and titanium oxide [TiO_2]) as previously mentioned; the mode of bone formation for these ceramics is osteoconduction. Sub categories of bioactive calcium phosphate ceramics includes synthetic TCP and dense HA and those derived of natural origin (corallin or deorganified bovine and human bone). A chemical contact between the host bone and grafted material may be developed as well as possible stimulus for bone activity (Le Geros 1988). These materials exhibit good compressive strength, but poor tensile strength (similar to bone) (Le Geros 1983). Additionally, particle size, porosity, chemical structure and composition of the bioactive ceramics greatly influence the resorption rate of the material and may be another method of describing bioactive materials (Misch and Dietsh 1993). The bioactive ceramics differ greatly in resorption properties. Although difference in the biologic response of implanted bone substitute occurs, all have been recommended for augmentation (Masters 1988 and Le Geros 1988). TCP can be used with osteogenic or osteoinductive materials to improve the handling characteristic of the graft during placement (Misch and Dietsh 1993). Both hydroxyapatite and TCP are safe and well tolerated.

Cerasorb (Curasan, Kleinostheim, Germany) is a beta-tricalcium phosphate (beta-TCP) material that has been certified for use in bone defect regeneration in the entire skeletal system. It is also certified in Europe as a synthetic carrier of the patient's own platelet rich plasma. This material is resorbed completely and is generally replaced by natural bone in three to twenty four month period, depending on the type of bone.

Hydroxyapatite (HA) is the principal inorganic component of the calcified tissues in the human body and has calcium to phosphorous ratio of 10:6. Its crystallographic similarity to the bone mineral apatite allows bone growth and contact when implanted in hard tissue (Misch and Dietsh 1993). Various types of HA can be distinguished according to physical or chemical characteristics. Physical properties are the surface area or form of the product (block, particle), porosity (dense, macroporous, microporous) and crystallinity (crystal or amorphous), chemical properties are related to the calcium-to-phosphorous ratio, elemental impurities (such as carbonate) ionic substitution in HA and the PH of the surrounding region (ToFe, Watson and Bowerman 1991). These properties all play a role in the rate of resorption and clinical application of HA material (ToFe, Watson and Bowerman 1991). The larger the particle size, the longer the material will remain at the augmentation size. Thus 75um particle will resorb more rapidly than 3000um particles. The porosity of the calcium phosphate also impacts on the resorption rate. ToFe et al (ToFe, Watson and Bowerman 1991) reported on the porosity of dense, macroporous and microporous HA. Dense HA may lack any macro or microporosity within the particles (Misch and Dietsh 1993). The longest resorption rate occurs with the dense HA type since osteoclasts may only attack the surface and cannot penetrate the dense material (Misch and Dietsh 1993). The greater the porosity, the more rapid the resorption of the graft material. The crystallinity of HA also affects the resorption rate of the material. The highly crystalline structure is harder for the body to alter and resorb. The crystalline form of HA has been found to be very stable over the long term

under normal conditions while the amorphous structures are more likely to exhibit resorption, The less crystalline the material, the faster its resorption rate (Le Geros 1983).

The purity of HA bone substitute may also affect the resorption rate. The resorption of this bone substitution requires living cells, similar to the modeling/ remodeling process of living bone with the coupled resorption/ formation process. A solution-mediated resorption permits the dissolution of the material by a chemical process. Impurities in bioactive ceramics, such as calcium carbonate, permits solution-mediated resorption which then increases the porosity of the bone substitute. It is said that corallin HA does not demonstrate micropores around the larger holes, the HA has carbonates incorporated within the material, which hastens the resorption process (ToFe, Watson and Bowerman 1991).

The pH in the region in which the bone substitute is placed also affects the rate of resorption of HA. As the pH decreases (e.g. from the infection in the bone), the HA components of living bone and phosphates resorbs by the solution-mediated process. Bone, dense HA, macroporous HA, microporous HA, crystalline HA or amorphorous HA may all resorbs within a two week period.

Physical properties should determine the type of HA selected for residual ridge augmentation. Dense, crystalline, large particle size HA can be used for ridge augmentation. Dense HA particles may also act as space filler or modifier of soft tissue contours under pontics of a fixed partial denture or around implants (Jarcho 1981). Dense crystalline HA cannot be easily cut and should not be placed in bone defects when the insertion of endosteal implants is planned in the future, in addition when an implant is in contact with dense crystalline HA, the material cannot grow into or attach itself to the implant surface. As a result, less percentage of inert bone implant bone implant contact occurs and compressive forces cannot be transmitted as well to the HA particle-implant interface. This factor will increase the amount of force generated to the remaining bone contacting the implant.

As the resorption rate of macroporous HA is generally greater than thirty six months, it is used where a more long-term matrix is desired (e.g. ridge augmentation or subantral augmentation). The resorption rate of microporous HA (six to twelve months) is compatible with applications where scaffold is needed within bone during the first several months of healing, but where living bone is desired in the near future.

Tricalcium phosphate (TCP) has calcium to phosphorous ratio of 3:2, and is intended to provide a scaffold for initial bony proliferation. TCP has been reported to act as short-term biologic filler which is resorbed over time by osteoclasts and replaced by living bone cells which grow directly in contact with the material without any encapsulation process (ToFe, Watson and Bowerman 1991 and Heimke and Griss 1983). The resorption of TCP and its replacement by new bone occurs through various mechanisms. The process seems to be very dependent upon the material characteristics, primarily chemical structures, porosity and particle size. These characteristics are closely related to manufacturing processes (Swart, Rejda and de Groot 1979).

TCP is prepared by sintering processes. It is very sensitive to heat and sterilization, which may change its chemical structure and alter its properties, including resorption rate (Le Geros 1988). It can be used in combination with osteogenic and or osteoinductive materials because it provides improved handling characteristics to the graft during placement. In addition to Cerosorb®, which is mentioned above as β -TCP, other commercially available TCP products are; Calciorsorb® (CeraVer Osteal, Paris, France), Synthograft (small size and dense) and Augmen (larger size and dense) (Miter, Warsaw).

Bovine-derived anorganic bone matrix materials (xenogenic alloplast) are utilized for bone grafting. An example of this is Bio-Oss (Osteohealth, Shirley, NY) which is anorganic bovine bone that has been chemically treated to remove its organic component.

After the Bio-Oss is sterilized, it can be used as a graft without causing a host immune response (Hislop, Finlay and Moos 1993). Bio-Oss is osteoconductive (Hislop, Finlay and Moos 1993 and Pinholt, Bang and Haanaes 1991) and over time, the graft undergoes physiologic remodeling and becomes incorporated into the surrounding bone. This type of bone graft can be used alone or in combination with barrier membrane in periodontal defects, dehiscences and fenestrations around implants and in small sinus osteotomies. In large alveolar ridge deficiencies, anorganic bone can be combined with autogenous bone for successful augmentation. Anorganic bone has been utilized in the treatment of intra bony defects, and for maxillary sinus augmentation and treatment of peri-implantitis (Garg 2004). Bovine bone substitutes are widely used for treating osseous defects, however, there is a risk of transmitting bovine spongiform encephalopathy to human (Will 1999, Scott et al. 1999 and Vedrager 1999). As these materials are routinely and successfully utilized in surgical dentistry and orthopedic surgery, careful risk assessment has to be done. Bio-Oss and osteograft are bovine derived bone substitute which are processed from veterinary certified cows from the USA, a country that is known to be free of BSE-cases. Consequently it is unlikely that the starting material for the manufacturing of Bio-Oss or osteograft contains prions. However, it has recently been questioned whether the U.S.A. can still be considered as a BSE-Free country.

(http://europa.eu.int/com/dgs/healthconsumer/library/press/press66_en.html)

The issue has become more urgent as many biomaterial scientists, dental and orthopedic surgeons are getting more concerned about the bio-safety of biomaterials from bovine origin. There is an increasing interest in the analysis of the risk of transmitting BSE through grafting materials derived from the bovine bone. The theoretical risk assessment has been done according to a model proposed by the German Health Authority (Bundesgesundheitsamt 1994 and Bundesgesundheitsamt 1996). This was done before for osteograft /N based on a model published in 1994 (Bundesgesundheitsamt 1994). Wenz *et al* in their publication of 2001 on the analysis of the risk of transmitting bovine spongiform encephalopathy (BSE) through bone grafts derived from bovine bone concluded that theoretical and experimental data indicate that the use of these materials does not carry a risk of transmitting BSE to patients (Wenz, Oesch and Horst 2001).

PepGen P-15 (Dentsply Friadent Ceramed) is another form of bovine-derived hydroxyapatite which is enhanced and contains an added synthetic short-chain peptide p-15. This component mimics the cell-binding domain of type I collagen which is responsible in natural bone for cell migration, differentiation and proliferation (Simler 2001). PepGen P-15 may provide the benefit of a synthetic graft containing an inorganic and an important organic component that together may mimic autogeneous bone in graft sites. This material has been reported to provide enhanced bone formation in a shorter time compared with the other bovine-derived hydroxyapatite plus DFDBA graft material traditionally used for sinus augmentation (Krauser, Rohrer and Wallace 2000). Another study indicated that enhanced bone formation and faster particle resorption can occur with Pep-Gen P-15 flow (PepGen p-15 particles suspended in biocompatible inert hydrogel consisting of sodium carboxymethyl-cellulose, glycerol and water) compared with the pep-Gen P-15 particles (Hahn, Rohrer and Tofe 2003).

Recently the bioactive glass ceramics have emerged as a bone grafting material. Bioglass (US Biomaterials, Jersey City, NJ) is composed of calcium salts and phosphate in a proportion similar to that found in bone and teeth, as well as sodium salts and silicon, which are essential for bone to mineralize. Bioglass is an amorphous material which is deliberately not manufactured in the crystalline form (to strengthen the material) because the developers foresaw that degradation of the material by tissue fluid and subsequent loss of the crystal could cause a loss of integrity. This material is not porous and as such, tissue and blood vessel in-growth is prevented. The biologic impact of this non-porous nature is not known, and only few studies support the use of this material in periodontal and maxillofacial procedures (Garg 2004).

Bioactive glass ceramics have two properties that contribute to the successful results observed with its use: (Misch and Dietsh 1993) a relatively quick rate of reaction with the host cell and (Marx and Saunders 1986, 347- 428) an ability to bond with the collagen found in connective tissue (Kirsh and Garg 1994). It has been documented that the high degree of bioactivity may stimulate the repair process and induces osteogenesis (Wilson 1993). Because the bioactivity index is high, reaction layers develop within minutes of implantation. As a result osteogenic cells in the implantation site may colonize the surface of the particles and produce collagen on these surfaces, osteoblast then lay down bone material on top of the collagen; an action which may supplement bone that grow by osteoconduction from the alveolus. In their seminal clinical trial and subsequent publication of 1993, Schepers *et al* (Schepers, Ducheyne, Barbier and Schepers 1993) reliably demonstrated that bioactive glass granules of narrow size range constitute a valuable material to aid in the repair of dental bone lesions.

The phenomenon of osteogenesis guided by bioactive glass particles with a narrow size range has been explained. The glass particles and the surrounding tissue fluids result in the formation of a silica gel, which is quickly covered by a calcium-phosphorous-rich layer. The particle size of the glass is such that the entire granule is transformed into silica gel (i.e. it is gelated). Phagocytosing cells penetrate the silica gel by means of small cracks in the outer calcium-phosphorous layer and partially resorbs the gel. This resorption leads to the formation of protective pouches in which primitive mesenchymal cells acquire phenotypic characteristics of osteoblasts. These osteoprogenitor cells adhere to the inner surface of the pouch. When the primitive cells are immobilized on this inner calcium-phosphorous-rich layer (a bone-like surface), differentiation of these cells into osteoblasts occurs. In this way islands of new bone tissue are formed without the need for osteoblastic proliferation from the preexisting bone (i.e. the cavity walls (Schepers, de Clercq, Ducheyne and Kempeneers 1991 and Schepers, Ducheyne, Barbier and Schepers 1993). The size range of bioglass particles must be narrow (300 to 360 μm for the glass composition selected) due to several critical considerations (Schepers, de Clercq, Ducheyne and Kempeneers 1991 and Schepers, Ducheyne, Barbier and Schepers 1993), the phenomenon of preferential resorption of the gel is restricted to this size range. Particles with a size exceeding this range do not corrode throughout and therefore are not resorbed into their centers. Hence recruitment of primitive cells exhibiting osteoblastic differentiation throughout the bone defect does not occur and healing is slow since it must proceed from the pre existing bone tissue walls. Particles with smaller diameter are fully resorbed and cannot act as a substrate for enhancement of mesenchymal cells. Glass granules preparations that contain the critical 300 to 360mm size range and also smaller particles are not active as described. Another critical aspect related to

small size range is the packing of the particles (Schepers, de Clercq, Ducheyne and Kempeneers 1991 and Schepers, Ducheyne, Barbier and Schepers 1993). When granules have uniform dimensions, dense packing will still leave space between the particles. With a wider size range, smaller particles fill up the spaces in between the larger particles. Such a granular mixture will extensively fill a defect space and leave very little room for tissue infiltration and regeneration (Fig. 5).

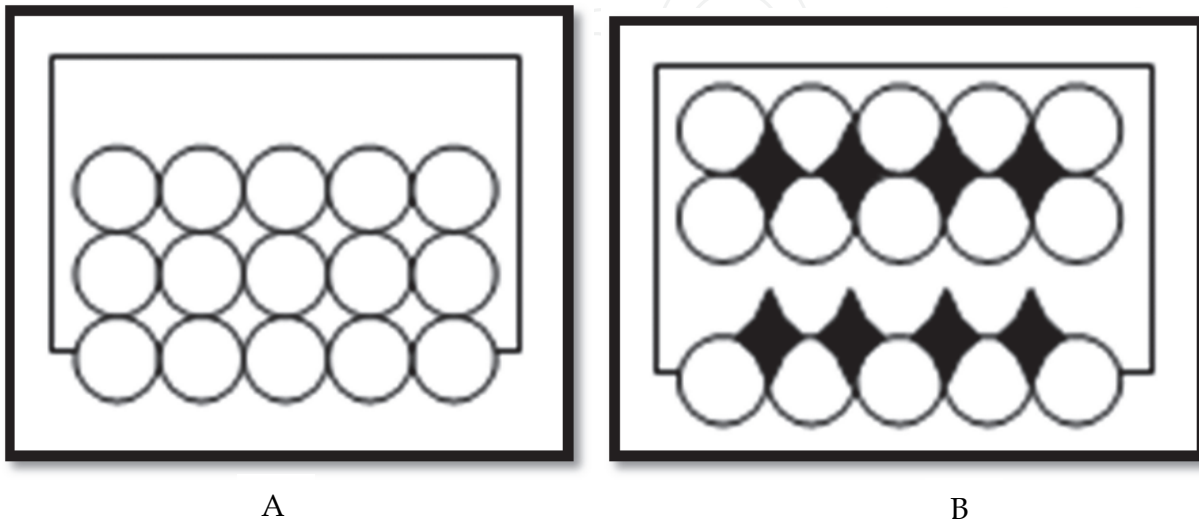


Fig. 5. Difference in packing when a limited size range of particles is used (A) as opposed to a larger size range (B)

The endosseous ridge maintenance implant (ERMI, US Biomaterials) is another Bioactive glass bone substitute. It is a cone-shaped device made of bioglass that is placed in the extraction site (Kirsh and Garg 1994). This bone implant system can be used for maxillary and mandibular premolars and anterior teeth. It can also be used for preserving the contour of the alveolar ridge following tooth removal. This bone implant acts under a time-dependant kinetic modification of its surface after placement within one hour of implantation; a chemical bond appears to form within the bone tissue (Kirsh and Garg 1994). Based on a study (Kirsh and Garg 1994), denture wearers showed a retention rate of approximately 90% for up to seven years when the Bioglass implants were used for alveolar ridge maintenance (Kirsh and Garg 1994).

Perioglass (Mova Bone, Alachu, FL) is a synthetic particulate form of Bioglass that bond to both bone and certain soft connective tissues (Wilson 1993). Perioglass is composed of calcium, phosphorous, silicon and sodium (Fetner, Hartigan and Low 1994). The quality and quantity of new bone deposition may increase with the use of perioglass particles compared with hydroxyapatite crystals (Oonishi 1994). Perioglass is indicated for the treatment of intrabony defects and the criteria for successful perioglass use includes pre-treatment planning, debridement of the defect, preservation of soft tissue vascularity and infection control (Quinones and Lovelace 1997).

Perioglass has demonstrated two favorable characteristics: ease of compactability and ability to promote hemostasis (Fetner, Hartigan and Low 1994). When well packed into osseous defects, it becomes strongly adherent and hardens into a solid mass incapable of being disturbed by a suction tip or hand piece. Fetner, *et al* concluded that by bonding to both bone and connective tissue, perioglass achieved improved grafting results (Fetner, Hartigan and Low 1994).

Biogran (3i, Implant Innovations, Palm Beach Gardens FL.) is another resorbable bioactive glass bone grafting material which have granules that are chemically identical to perioglass and are composed of calcium, phosphorous, silicon, and sodium. The difference between perioglass and biogran is the size range of the particles- 300 to 355 μm for biogran and 90 to 710 μm for perioglass. Biogran is hydrophilic and slightly homeostatic; it stays in place in the defect when bleeding occurs. Once in contact with the patient's blood, it forms a cohesive mass that is shaped into the defect (Garg 2004). Bone transformation and growth occurs within each granule. This osteogenesis which is guided by bioactive glass particles occurs at multiple sites, rapidly filling the osseous defects with new bone that continuously remodels in the normal physiologic manner (Rummelhart, Mellonig, Gray and Towle 1989, Schepers 1993 and Duchenyne et al 1992). This bioactivity permits material and bone transformation to occur simultaneously.

Biopant HTR Polymer (Biopant, Norwalk, CT) is a microporous composite with a calcium hydroxide graft surface (Ashman 1993 and Ashman 1984). This polymer resorbs slowly and is replaced by bone after approximately 4 to 5 years. This bone grafting material has been reported to be effective for ridge maintenance post extraction, ridge augmentation (immediate or delayed) and repair of periodontal and other bone defects. Boyne (Boyne 1995) concluded that in the HTR-implanted defects, bone tended to become lamellated (cortical) in the area of the particulate grafted implant particle over a long period of time. This lamellated bone structure suggests that such crestal regions should resist resorption in clinical areas. Porous bone material (Bio-Oss, Switzerland) that slowly resorbs and remodelled slowly also has been shown to confer a similar resistance to resorption on edentulous ridges in clinical situation (Boyne 1991). HTR is non-resorptive and may offer the same type of ridge support against resorption. The ability of HTR to produce an environment that resists resorption should be determined on a long-term basis by controlled clinical studies of conventional and root form implant supported prosthesis.

Garg (Garg 2004) argues that the use of autogenous bone, allografts and alloplasts or tissue engineered materials, alone or in combination should be based on the osteogenic potential of the recipient site. The decision should be based on the individual's systemic healing ability, considering among other things age, systemic illness affecting healing, (such as diabetes or autoimmune disorders like scleroderma and lupus), previous surgeries to the area, previous radiation treatment or chemotherapy, and irradiated tissue bed. Local osteogenic potential of the defects (e.g. defect size, ratio of host bone to graft material, number of walls of the defect, soft tissue bed, adjacent scar tissues, health of adjacent periosteum, stability of the graft material, soft tissue closure, use of interim restorative device over and around grafted site should also be considered. The osteogenic potential of the graft, the surgeon's skill and the time available for graft maturation are also critical to the decision.

It is as such important at this stage to indicate that the membrane sandwich technique allows us to enhance, combine, and maintain osteogenic potential at the required site.

3. Application of bone grafting materials and selection criteria

The application of bone grafting materials and selection criteria should be done against the background of the understanding that autogenous bone graft is the gold standard for utilization in any peri-implant or periodontal bony defect, because it forms bone by osteogenesis and additionally by osteoinduction and osteoconduction.

For the predictable long-term success of dental implants it is important to appreciate the available bone (Misch 1990). When available bone is inadequate, bone substitute represent a viable treatment modality. The extraction sockets, ridge defects and sites where bone volume is inadequate may be filled to maintain or improve ridge anatomy, improve esthetics and function, and/ or prepare the site for endosteal implants. Bone graft substitutes can also be found beneficial in the treatment of peri-implant defects which may occur after or during implant placement. It is important that the composition of the graft used to fill defects correspond to the mode of action of the graft material, and the number of walls of host bone remaining in contact with the graft (Misch 1993).

With regards to defects in the oral cavity that may require bone grafting, we have; five-wall defects, four-wall defects, two or three-wall defects and one-wall defects; each defect requires a particular type or combination of bone grafting substitute for optimum healing. It is for this reason that in this Section; I have dealt with bone grafting requirements per defect.

3.1 Five-wall defect (with one wall missing)

An extraction socket can be compared with a five-walled pocket (Fig. 6), similarly a cystic cavity is comparable to a five-walled pocket. This pocket is expected to fill with new bone by appositional growth. In order to maintain the width of the extracting socket and to improve the chance of success of future dental implants placement, an extraction socket can be filled with inexpensive resorbable calcium phosphate material to prevent the usually documented percent to 60% of the width of the ridge resorption which primarily occurs from the facial dimension (Khan et al 1981).

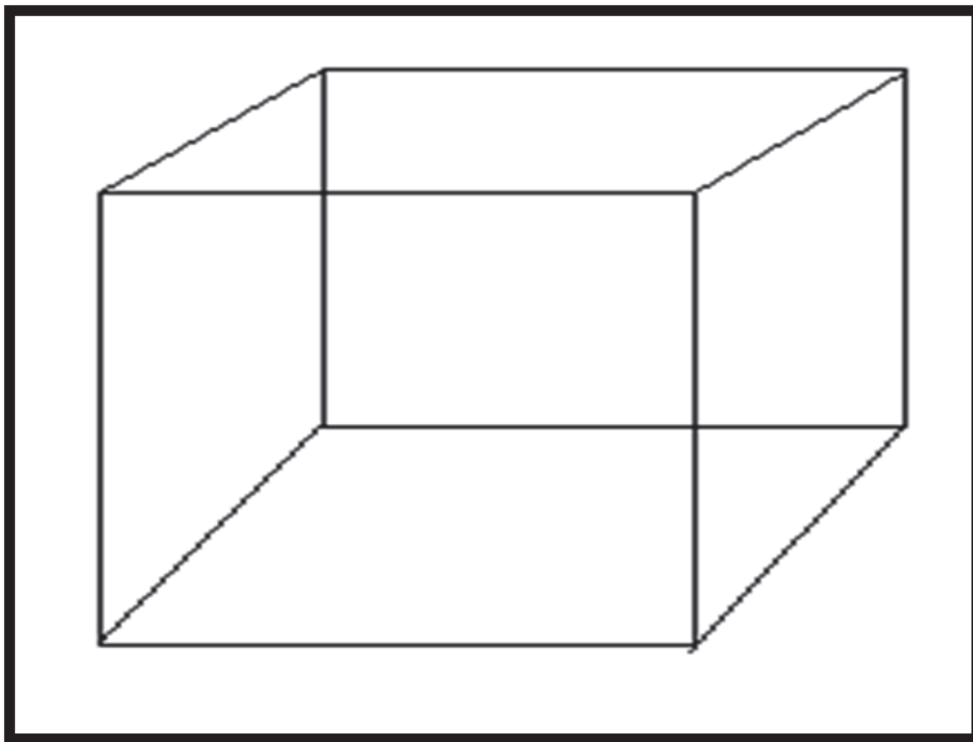


Fig. 6. Five-wall defects such as at tooth extraction socket or cystic cavities are filled with inexpensive resorbable calcium phosphate material to maintain ridge width. Autogenous bone is least indicated, but may always be used when readily available, since it is an osteogenic material and has no cost.

Autogenous bone may be used in any defect. It is often readily available without any cost to the clinician and forms bone by osteogenesis. When the harvesting site for bone is difficult to access, the five-wall defect may be grafted with any resorbable material, and then covered with a collagen or synthetic membrane to contain the resorbable material, particularly in situations where complete approximation of the soft tissue is not possible. With this procedure, it is advisable that 4 to 6 months elapse before re-entry and implant placement (Misch and Dietsh 1993).

3.2 Four-wall defect (defect with two walls missing)

If the host bone site has lost an additional wall of bone (usually the labial wall), it is called a four-wall defect. Additional active elements are beneficial in this graft since bone does not surround the defect. In such cases the addition of DFDB to the alloplastic calcium phosphate is recommended in order to compensate for the lack of labial bone and additional soft tissue in approximation to the graft (Roberts et al. 1987). It is suggested that the calcium phosphate be mixed with DFDB and over packed or contoured beyond the defect and this material is covered further with DFDB. This will allow the DFDB to be intact with the overlying soft tissue to modify the undifferentiated cells into osteoblast (Fig. 7).

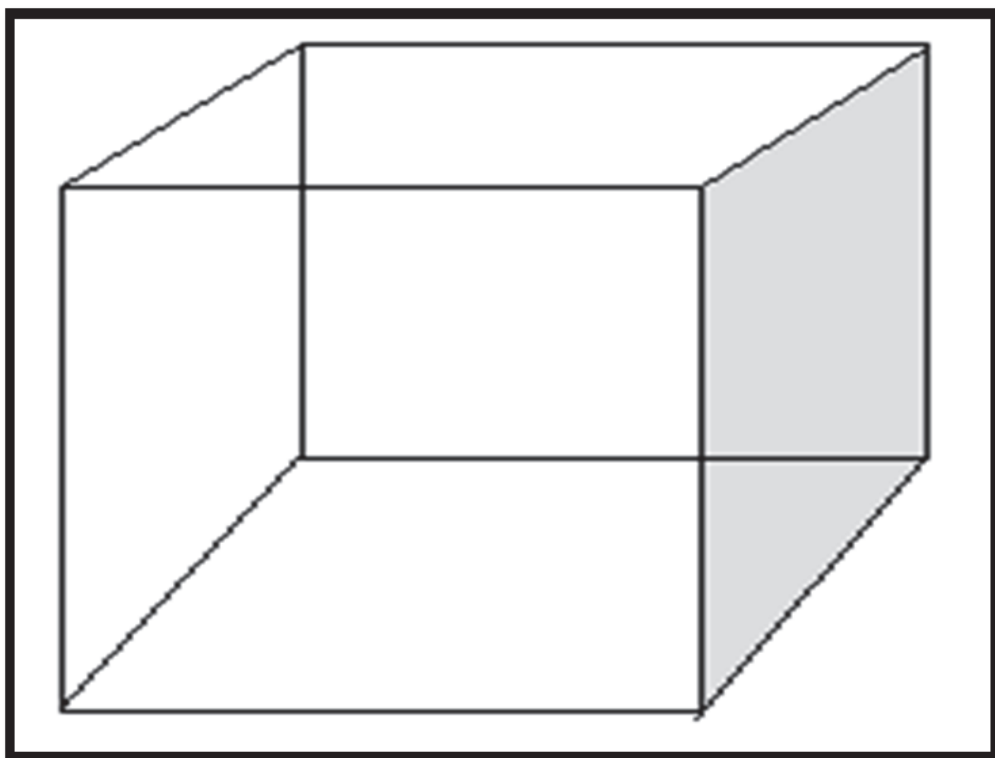


Fig. 7. With four remaining walls (usually labial and occlusal walls missing), calcium phosphate mixed with DFDB is placed over the host bone to retard soft tissue ingrowth. DFDB is placed on top of the calcium phosphate mixture so it is close to soft tissue for an osteoinductive effect.

The calcium phosphate acts similar to a barrier (due to its bulk) to retard the amount of soft tissue in growth within the graft and allows more bone formation in the region. DFDB when used alone in defects has not yielded much satisfactory results since it is eliminated too

rapidly to permit a predictable volume of bone formation in the defect with the four-wall defect as such a healing period of at least 6 months should elapse before implant placement (Misch and Dietsh 1993).

3.3 Two or three-wall defect (defects with 3 or 4 walls missing)

The loss of three or four bony walls will create a two or three wall defect. This type of defect requires the use of autogenous bone. The autogenous bone can be harvested intraorally from the maxillary tuberosity or with a trephine drill under the roots of the mandibular incisors and is positioned in the defect in contact with the host bone. Such placement allows for blood supply from bone to be established, to maintain trabecular cell survival. DFDB is laid over the autogenous bone chips to begin the osteoinduction process. Calcium phosphate and DFDB are added on top and the entire graft is covered with a membrane. A resorbable membrane is preferred to prevent the need for early re-entry and to reduce the risk of infection. Overall this approach allows guided tissue regeneration technique to impair epithelial in growth into the graft which would otherwise impair the healing process. Although the two-three wall defects are larger, the healing time is more rapid with the autogenous bone component. In approximately six months the implant can be inserted (Misch and Dietsh 1993) (Fig. 8).

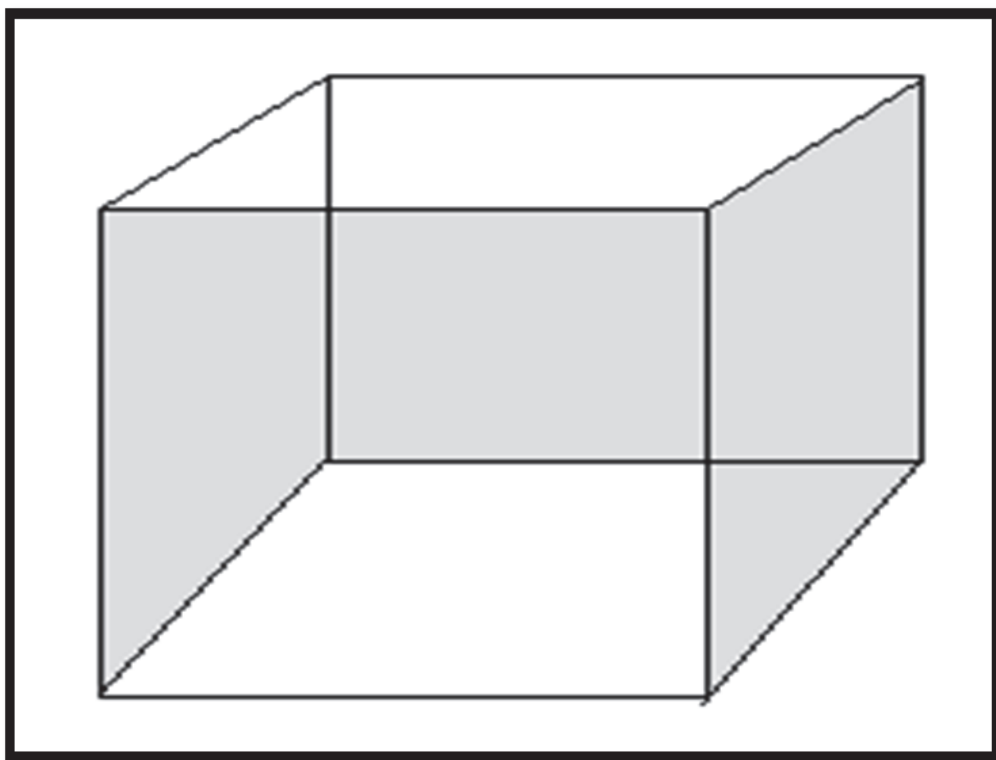


Fig. 8. The loss of three to four bony walls (a two or three wall defect) necessitates the use of autogenous bone

3.4 One-wall defect

Defects with five missing walls (one-wall defect) warrant the use of an autogenous corticotrabecular bone to regenerate a good volume of bone in the recipient site. A block graft is therefore the most preferable approach. The cortical aspect of the block is placed

superiorly to act as a barrier to the invagination of the soft tissue within the graft. A mixture of chips of autogenous bone, then DFDB and then calcium phosphate and DFDB can be used to fill any defects around the block of the bone (Fig. 9).

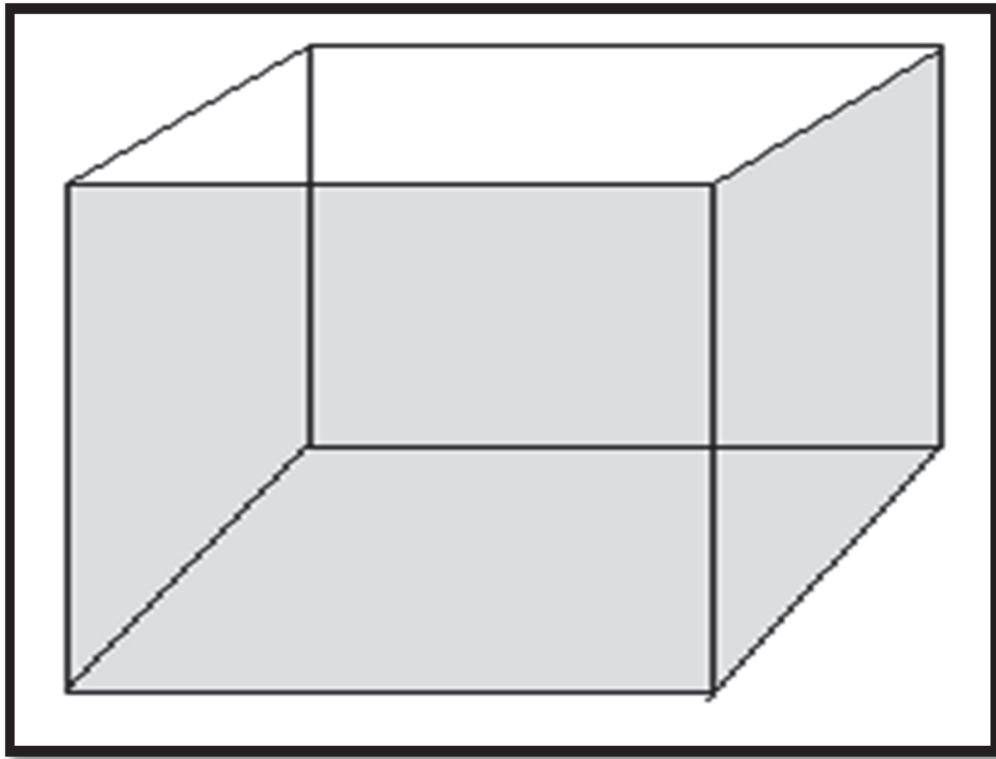


Fig. 9. Showing a one-wall defect

A healing period of four to six months is adequate to permit ridge reconstruction since autogenous bone is the major component of the graft (Misch and Dietsh 1993 and Misch 1993). If the cortical bone is present on the superior aspect of the autogenous graft, the area may be covered with a thin DFDB sheet or small pore membrane to prevent soft tissue ingrowth.

4. The indications for uses of bone substitutes

In implant dentistry the indications for use of bone substitutes can be divided into:

- a. Pre-implant bone grafting needs such as:
 - i. Ridge augmentation
 - ii. Maxillary sinus lift procedure
 - iii. Extraction socket for delayed implant placement
 - iv. Extraction socket for ridge preservation
 - v. Intrabony defect
 - vi. Furcation involvement of teeth adjacent to implant site
 - vii. Recession
 - viii. Pneumatized sinus
- b. Intra-implant surgery bone grafting needs such
 - i. Intra-operative per-implant placement (precautionary of mandatory)
 - ii. Extraction socket during immediate implant placement

- iii. Repair of cortical bone plate dehiscence
- iv. Alveolar or mental nerve protection
- v. Conventional maxillary sinus lift procedure
- vi. Osteotome technique for maxillary sinus lift and simultaneous implant placement
- vii. Ballooning technique for maxillary sinus lift and simultaneous implant placement
- viii. Intra-operative ridge preservation
- ix. Furcation involvement, recession and intrabony defect of teeth adjacent to the implant site.
- c. Post -implant bone grafting needs such as;
 - i. Implant failure
 - ii. Peri-implantitis

The repair of defects around previously inserted endosteal implants can also be performed with bone substitutes. At the time of uncovering, defects and bone resorption are best identified around the implant with a full-thickness reflection. The defect filled with soft tissue can be curetted and filled with autogenous bone. The defect is then covered with DFDB since such defects are similar to three or four wall defects (Misch and Dietsh 1993).

Subantral augmentation after sinus elevation in the posterior maxilla is the most predictable region of the oral cavity where the atrophic ridge can be augmented in height with the use of allografts and alloplastic material (Misch and Dietsh 1993). Autogenous bone is an excellent material for this procedure, but the quantity of bone necessary to fill the antrum often requires harvesting host bone from an extraoral site. The procedure has been further modified to permit the use of less autogenous bone and incorporation of both allografts and alloplastic materials. Results from structures show that the subantral region is similar to a three or four-wall defect and the graft should include autogenous bone, DFDB and TCP or microporous HA to combine osteogenic, osteoinductive and osteoconductive modes of bone regeneration (Misch and Dietsh 1993).

The fact that the last fifteen years have seen the introduction of several bone substitutes. Those materials can modify the bony structure of the patient prior to implant treatment, during implant treatment and after dental implant treatment. It is as such very important to understand the characteristics of the different materials in reference to crystallinity, porosity, particle size, chemical structure, and PH in order to be able to select the most appropriate type or combination to achieve a predictable result.

5. Validation of bone substitutes (second-hand bone)

Bone substitutes are best validated utilizing single photon emission computerized tomography (SPECT) to disclose in a dynamic way the osteoblastic activity and calculated index around the bone grafting site over a period of time. It is the intention of this section to explain SPECT and its various applications and then to describe the SPECT experiment to be used to compare second hand bone such as Bio-Oss with autogeneous bone (both of which are contained in the Ogunsalu sandwich unit).

5.1 Single Photon Emission Computerized Tomography (SPECT)

The literature is replete with the various applications of single photon emission computerized tomography (Khan et al. 1980, Ell et al. 1981, Flood and Russel 1998, Lima et al. 2004, Van der Wall and Fogelman 2007, Horger and Bares R. 2006, Schafers and Stegger 2008, Dasgeb Mulligan and Kim 2007, Sarikaya, Sarikaya and Holder 2001, Ozyurt et al.

2008, Kalita et al. 2008 Crespo et al. 2008, Massardo et al. 2008 and Ellis et al. 2008), however, there is a dearth of information on the applications of SPECT in relation to implant assessment and osseointegration. Reports in the medical literature on the radiologic evaluation of per-implant bone changes in the context of osseointegration are limited to one-dimensional quantifications of heights of the defects. Despite the fact that digitized radiography and computerized tomography can facilitate quantification of bone changes, these methods generally reflect morphologic changes but may fail to detect the dynamics of osteoblastic activity (Massardo et al. 2008, Ellis et al. 2008, Alberto 1998 and Galasko 1975).

Bone scintigraphy which is a well established imaging technique that accurately reflects osteoblastic activity (Ogunsalu et al. 2008) can be utilized to radiographically assess osseointegration. In most clinical situations, the data from planar or conventional radiographic views are usually sufficient for diagnosis, but accurate quantitative analysis may not always be possible because of interference by superimposed structures. The single photon emission computerized tomography (SPECT) provides an additional refinement to planar imaging, it allows accurate quantitation common to most tomographic techniques by removing regions not of clinical interest.

Although the SPECT technique is well established and successful in clinical application for the study of many organ systems, (including skeletal system) (Khan et al. 1980, Ell et al. 1981, Flood and Russel 1998, Lima et al. 2004, Van der Wall and Fogelman 2007, Horger and Bares R. 2006, Schafers and Stegger 2008, Dasgeb Mulligan and Kim 2007, Sarikaya, Sarikaya and Holder 2001, Ozyurt et al. 2008, and Kalita et al. 2008), its application by clinicians and manufacturers alike have been very much non-existent in the clinical or experimental assessment of osseointegration of bone grafts and implant systems. Recently however, Ogunsalu and co-workers have utilized SPECT to successfully assess osseointegration of a new bone grafting/ regeneration technique (Ogunsalu et al. 2008 and Ogunsalu et al 2008) and also for comparative assessment of osseointegration relating to implant systems (Ogunsalu et al. 2008 and Ell et al. 1982).

The underlying principles of SPECT are common to most tomographic imaging techniques. When a radiopharmaceutical agent containing a single gamma-photon emitting radionuclide such as technetium 99m is injected intravenously it is possible to obtain a three-dimensional representation of the distribution of radioactivity within an organ or an area of interest in which the radiopharmaceutical agent is localized by using radiation detectors and rotating gamma cameras which detects the emitted radioactivity as the camera is rotated around the clinical or experimental area of interest. The acquired data can then be processed by a computer which will initially provide a cross-sectional (trans-axial) representation of the distribution of radioactivity. The transaxial data can additionally be used to reconstruct sagittal and coronal images.

It is the ability for multiplane image reconstruction with SPECT which confers greater diagnostic accuracy to SPECT. Additionally, SPECT permits accurate volumetric measurement and it is thus possible, for quantitation of the distribution of radioactivity in terms of Mc_i per unit volume of tissue (Khan et al. 2000). This unique ability to quantitate physiologic events, by using a bone-seeking radiopharmaceutical sets SPECT apart from other tomographic techniques such as computerized tomography (Khan et al 2000). CT Scans (computerized tomography) is able to provide excellent morphological details but unlike SPECT, it is unable to provide functional data.

In a highly significant publication, Khan et al (Khan et al 2007 and Ogunsalu 2007) described SPECT as capable of accurate quantitation of bone changes, before and after titanium dental

implants in edentulous patients. “A novel approach that has the value in imaging bone changes dynamically and further offers an objective method for monitoring such dynamic changes before, during and after implantation” (Khan et al 2007).

6. Experiment

6.1 Materials and methods

Experimental Animals

Seven pigs 4 months old and weighing between 25 and 30 kg (Fig.10) were used. Pigs were used for this experiment because of the similar metabolism to human and the ease of ethical approval which should have been problem if dogs were used for obvious reasons. The pigs were all obtained from the same swineherd and, as far as possible, from the same litters. The pigs were housed at holding pens (Fig. 10) in the School of Veterinary Medicine for a of 2-3 week period of acclimatization prior to the surgery.

On the day of surgery, each pig was pre-anaesthetised with Azaperone (Stresnil,) and Butophanol at the dose rates of 6mg/kg and 0.2mg/kg respectively, induced with 5% Thiopentone at 10 mg/kg, intubated and maintained with isoflurane in oxygen. An Omicron Plus Multiparameter monitor was used to evaluate the vital parameters, including ECG, heart rate, pulse rate, invasive arterial blood pressure, respiratory rate, SpO₂, and end tidal CO₂. The anaesthetized pig was placed in dorsal recumbency and the mandibular area was prepared for surgery by clipping the hair, thorough washing with chlohexidine surgical scrub solution (Hibitane) followed by two alternating applications of povidone iodine and surgical (70%) alcohol.

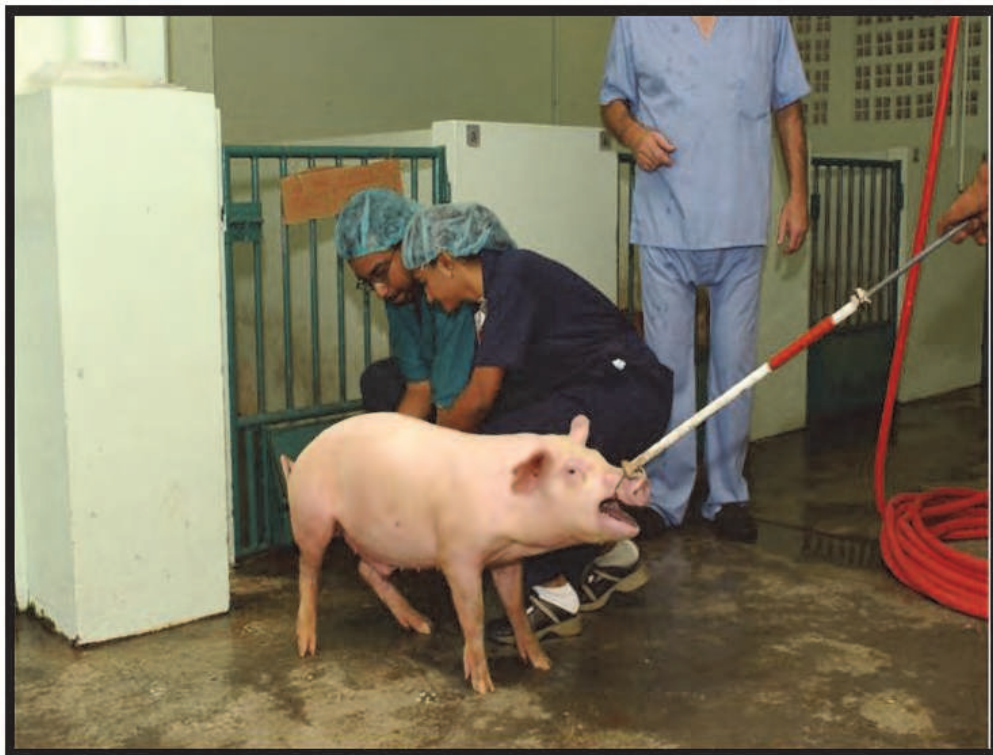

Fig. 10. Showing a 4 month old pig weighing approximately 30kg being cleaned and prepared for the operating room

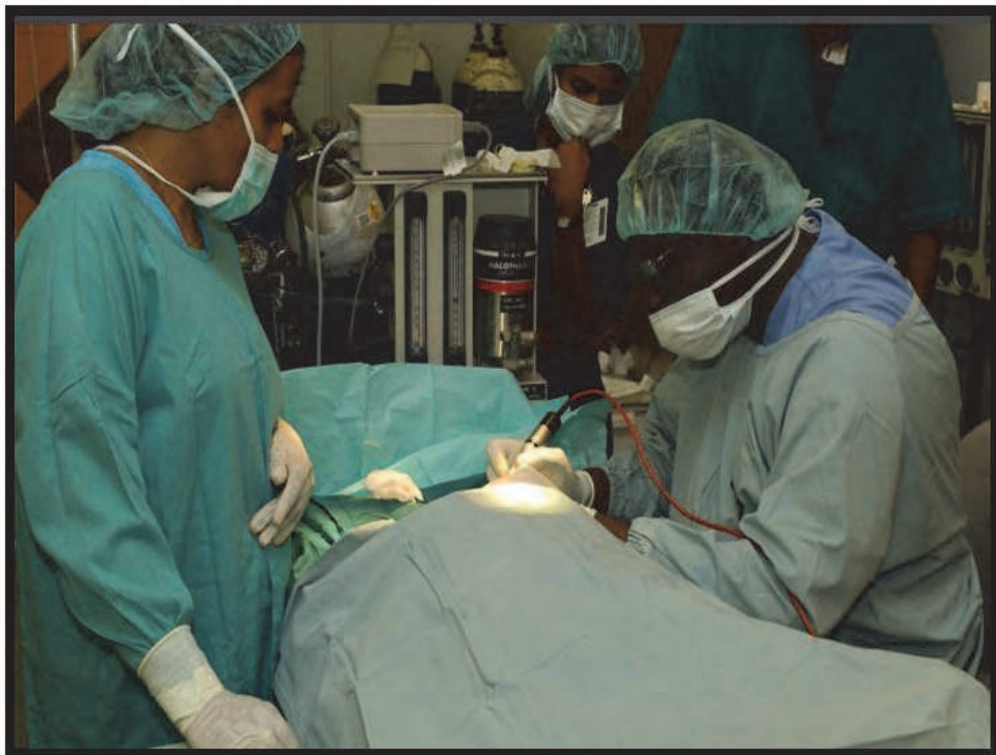

Fig. 11. Showing the operating room set-up and operator at work on the appropriately draped animal.

Surgical procedure

The animal was then draped as shown in Figure 11 prior to making an incision (approximately 6 cm long) along the ventro-lateral aspect of the mandible just cranial to the masseter muscle. The incision was extended to the subcuticular muscles to expose the mandible without damaging the facial artery. A self-retaining retractor was used to allow adequate exposure of the bone. An area measuring approximately 17 mm by 16 mm was marked on each mandible (left and right) using a template, and a block of bone measuring approximately 17 × 16 × 4 mm was removed from each mandible using an Elcomed implant surgical motor and a surgical fissure burr at a speed of 18000rpm (NI). The appropriate graft (with or without the sandwich) were placed in the appropriate mandibular defect. Subcutaneous tissue was then closed with Vicryl (0), and the skin closed with #3 Vetafil.

The Sandwich

The sandwich is prepared as shown in Figure 12 below. Two sheaths of restorable membrane (Bio-Gide) are utilized and tailored with a restorable suture material into a pillowcase before the particulate bone grafting material (Bio-Oss) is placed in it. The tailoring was completed by suturing the fourth side with the same suture material to produce a closed sandwich unit ready to be implanted in the surgical site.




Fig. 12. The creation of the sandwich unit with Bio-Gide, Bio-Oss and resorbable sutures.

Evaluation of bone regeneration and ossification

Bone regeneration and osseointegration were evaluated by (a) Computer Assisted Tomography scan (CT scan), (b) Single Photon Emission Computerized Tomography (SPECT), and (c) Histological and Histomorphometric techniques.

Single Photon Emission computerized tomography (SPECT):

SPECT studies focused primarily on evaluating the osteoblastic activities, especially the vascularization in and around the site of the graft or region of interest (ROI). At the end of each implantation period, the pig was anaesthetized and given an intravenous injection (into the ear vein) of 740MBq (20 mCi) technetium 99m -methylene diphosphate. The pig was subsequently euthanized two and half hours after the injection and then the mandible was removed. Tomographic images of the mandible in the region of interest (ROI) were acquired within 30 minutes of removal, using a Siemens Orbiter II rotating large field-of-view gamma camera equipped with a low energy high resolution Collimator (Siemens Medical System).

Inc, Erlangen, Germany). A total of 64 projections images (205/images) were acquired over 180 degrees in a 128 by 128 matrix with a dedicated nuclear medicine computer (Siemens ICON computer).



Fig. 13. The nuclear imaging team at work around the gamma camera and pigs mandible. From the left, Dr John Watkins, Mr Anthony Archibald and Dr Christopher Ogunsalu.

7. Results

7.1 Study I

SPECT Evaluation

The SPECT images demonstrated higher radioactivity on the right mandible compared to the left mandible, this indicates higher take-up of the radioactive material, which translate to higher osteoblastic activity. As such, on can conclude that the side with the autogenous graft (right side) has higher osteoblastic activity as shown in Figure 14. This result is presented graphically in Figure 15 which shows higher peak on the autogenous bone sandwich side compared with the xenograft sandwich side (left side). The average counts were 99.7 pixel and 78.1 pixels respectively (table 2) and a calculated relative activity ratio of 1:20.

SITE	COMPONENT OF SANDWICH UNIT	SIZE PIXEL	AVG COUNT	SUM
R	L			
1. Right mandible	a. Membrane – Bio-Gide ® b. Bone substitute – autograft	112	99.7	11167
2. Left Mandible	a. Membrane – Bio-Gide ® b. Bone substitute – xenograft (Bio-OSS®)	129	73.1	9425

Table 2. Showing the comparasim of the osteoblastic activity between the xenograft and autograft sandwich

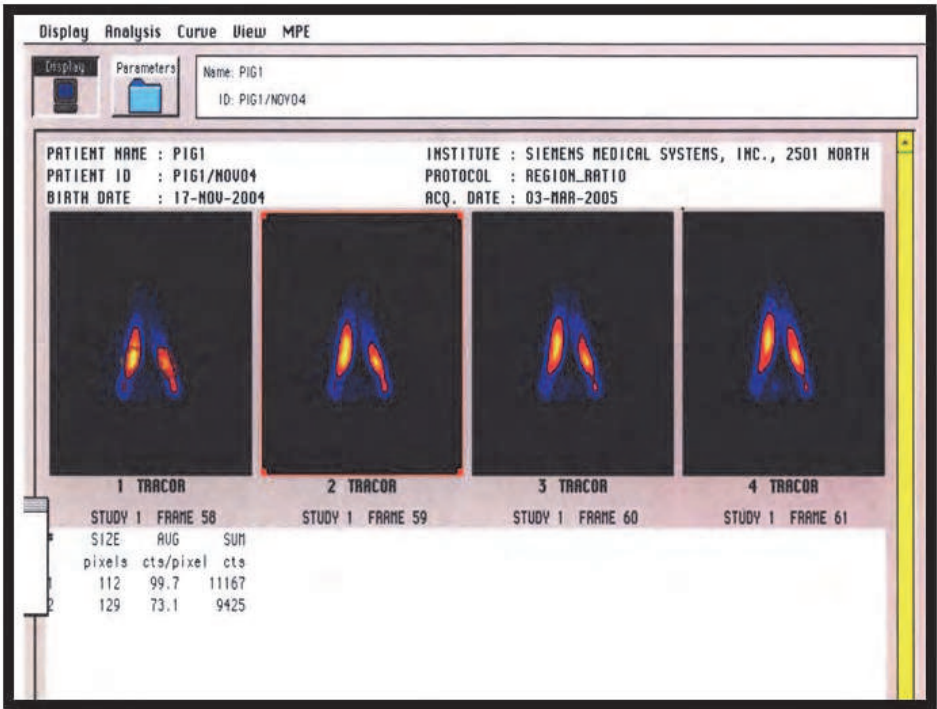
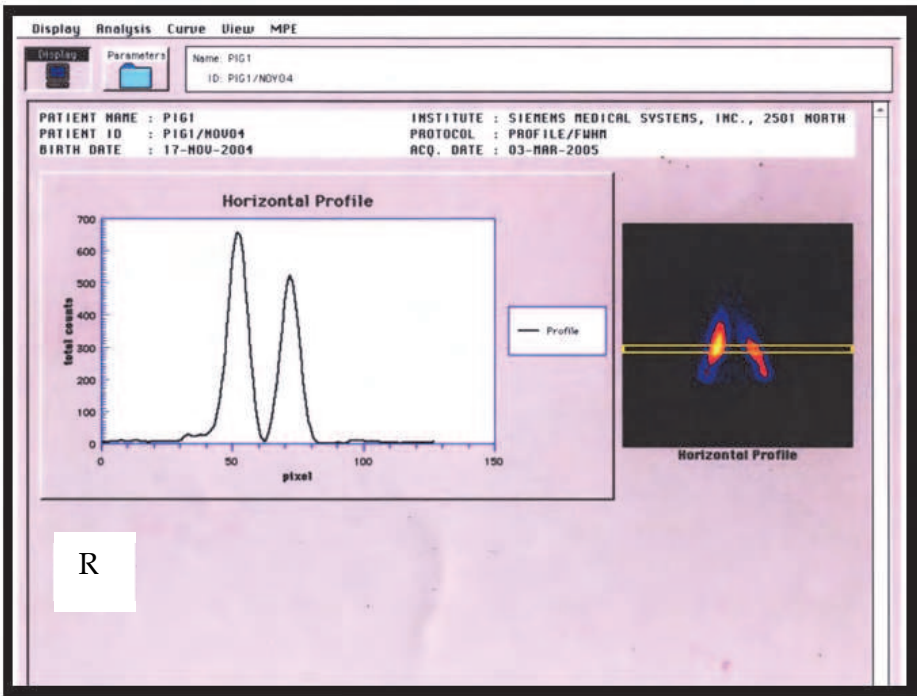


Fig. 14. Illustration of osteoblastic activity for Pig 1 at 14 weeks.



R = Right side

Fig. 15. Showing graphically the profile of osteoblastic activity of the autogenous sandwich side (right side) versus the Bio-Oss sandwich side (left side), together with the activity ratio. The autogenous sandwich side obviously has more activity than the Bio-Oss sandwich side (note that the actual left side of the pigs jaw is represented by the right side of the profile).

CT-Scan evaluation

The CT-scan evaluation also depicted the morphological state of the bone regeneration site with the side which utilized the autogenous bone with the sandwich side having much more bone formation with obliteration of the marrow space (Figure 16 a and b)

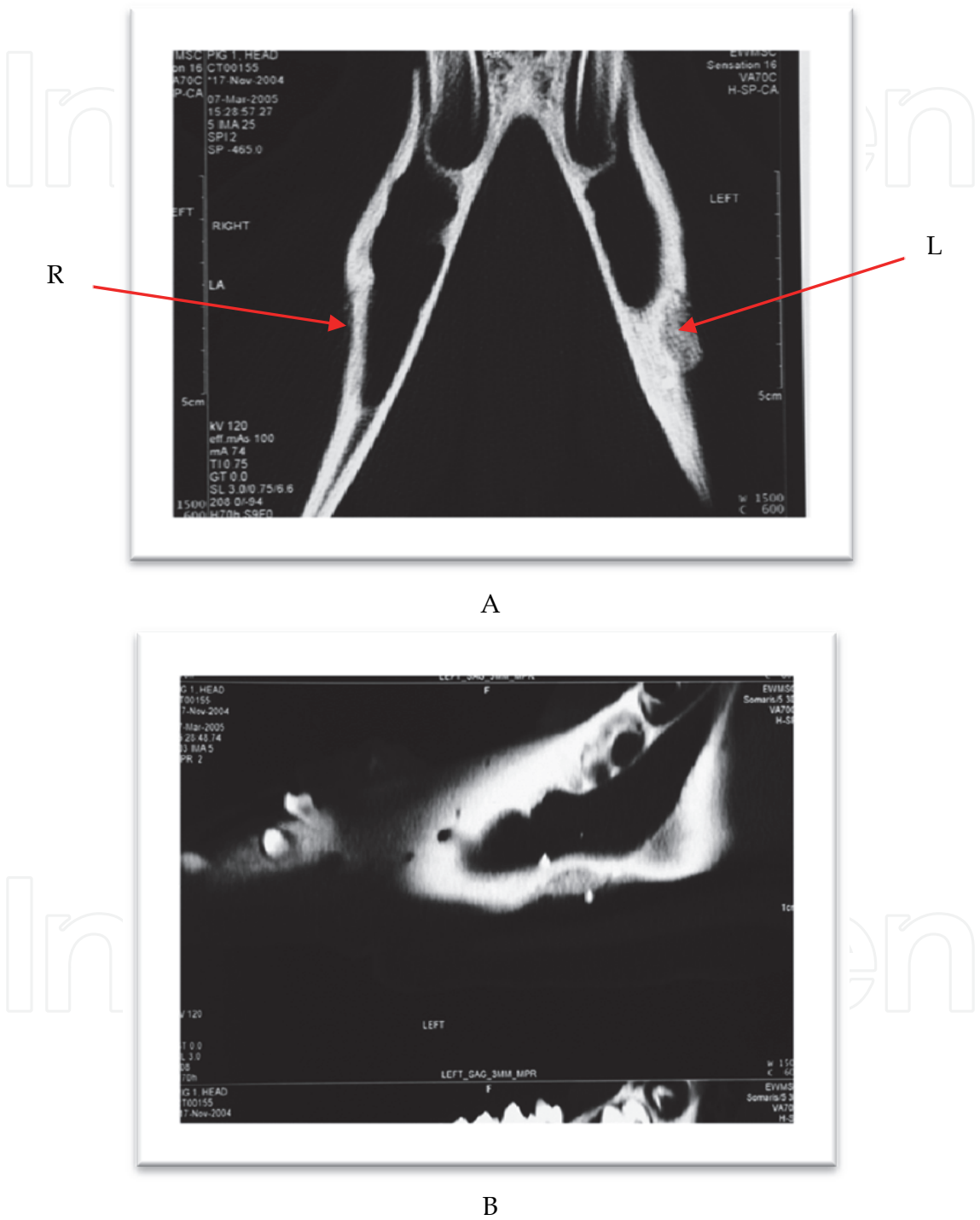

Fig. 16. (a- top and b- bottom): CT Scan showing the transverse saggital slices in the area of bone regeneration. Note the regular recortication on the side with autogenous sandwich (right side), compared with the side with Bio-Oss sandwich (left side), which shows less regular recortication with obliteration of the adjacent marrow space (see arrow).

8. The proper use of bone replacements

As mentioned earlier on in the chapter, bone replacement can be either autogenous in origin or non-autogenous and as such called second-hand bones or bone substitutes.

The proper use of the autogenous bone begins with its harvesting either as particulate, block or core graft to be placed in the site that requires bone to be regenerated. Recently the disposable bone scrappers became available in the market for the harvesting of particulate autogenous bone (Fig. 17). The attached CD will assist the clinician who is not knowledgeable with the use of the disposable bone scrapper to practice such utilizing a cadaver.

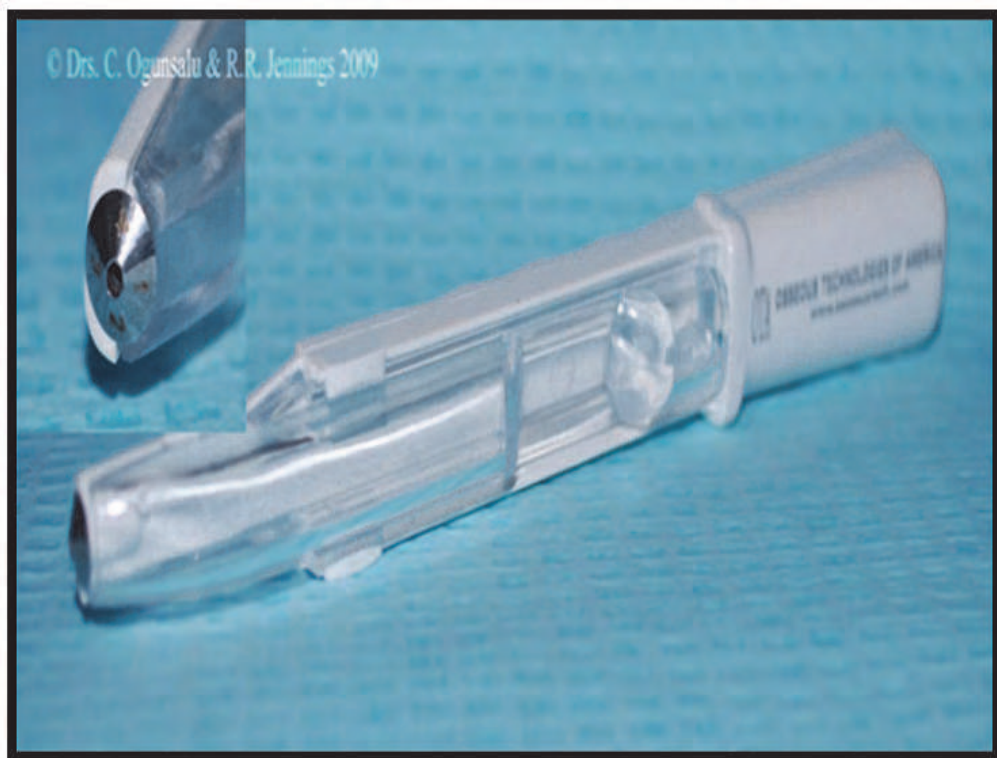

Fig. 17. Disposable bone scrapper for harvesting of particulate bone

Because of the technique sensitivity ascribed to the use of particulate bone substitute and the fact that it is the most common forms of bone substitute used in implant dentistry today, I will in stages describe the use of Bio-Oss (Osteohealth, Shirley, NY) particulate bone substitute in a furcation involvement in the mandibular molar region.

Bio-Oss (Fig. 18 and Fig. 19) is a xenogenic second hand bone obtained from bovine source and distributed in sterile packs and more important is the fact that it is sold only to practioners with current annual practicing license.

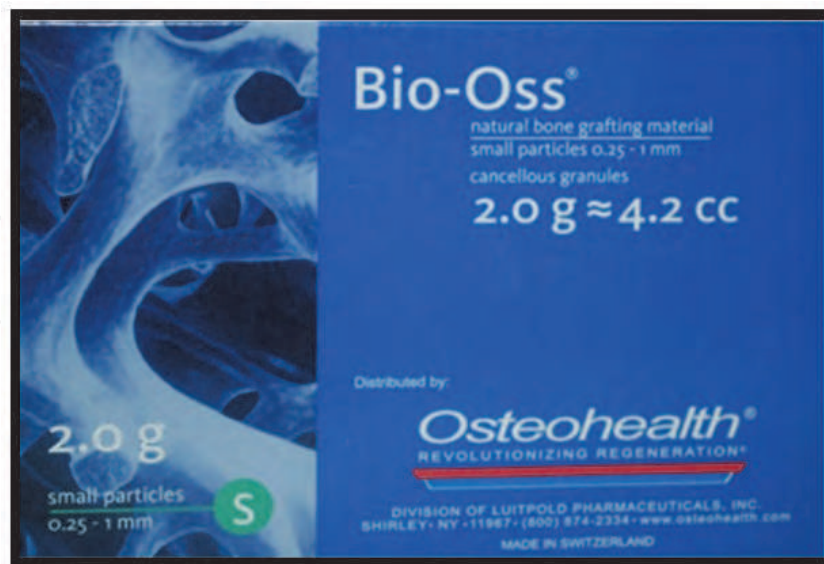

Fig. 18. Packing for Bio-Oss from Osteohealth



Fig. 19. Bottle of Bio-Oss particulate bone substitute(Xenograph)

In implant dentistry or in periodontal bone reconstruction or regeneration, it is best used with the resorbable membranes (Fig. 20 and 21)consistent with the guided tissue regeneration (GTR) technique.



Fig. 20. Bio-Gide resorbable membrane(smooth side)




Fig. 21. Bio-Gide resorbable membrane(rough side)

Once the surgical site has been exposed and all granulation tissue has been removed from the periodontal pathologic pockets and furcation area as shown in Figure 22 and 23.

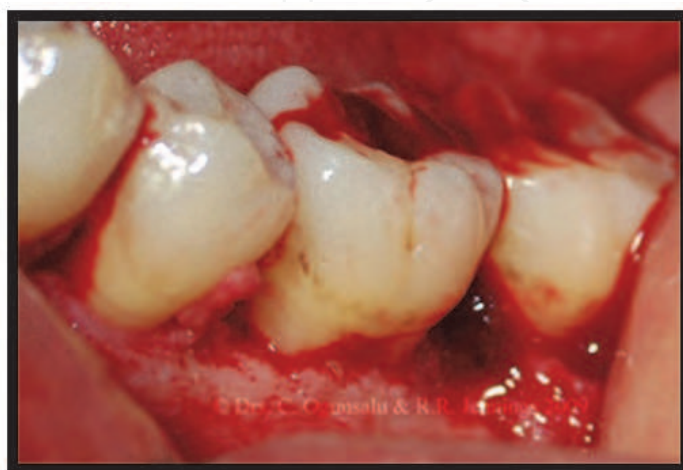

Fig. 22. Surgical site with some granulation tissue mesial to first molar tooth

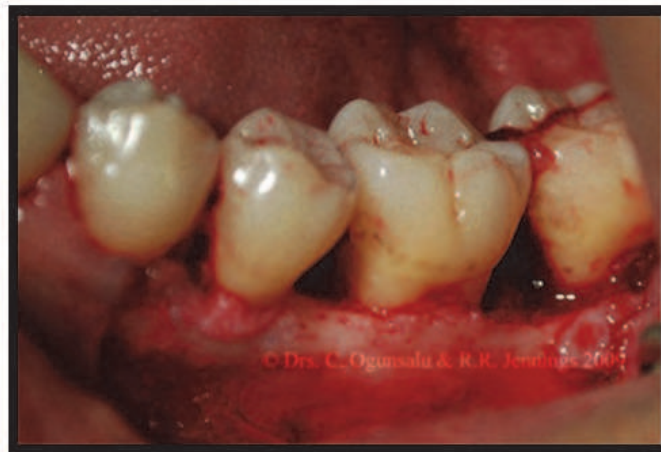

Fig. 23. Surgical site with all granulation tissue removed

The particulate bone which has been soaked with the patient's blood or sterile water is now condensed into the defect utilizing an amalgam plugger dedicated only for use in bone grafting (Fig. 24).

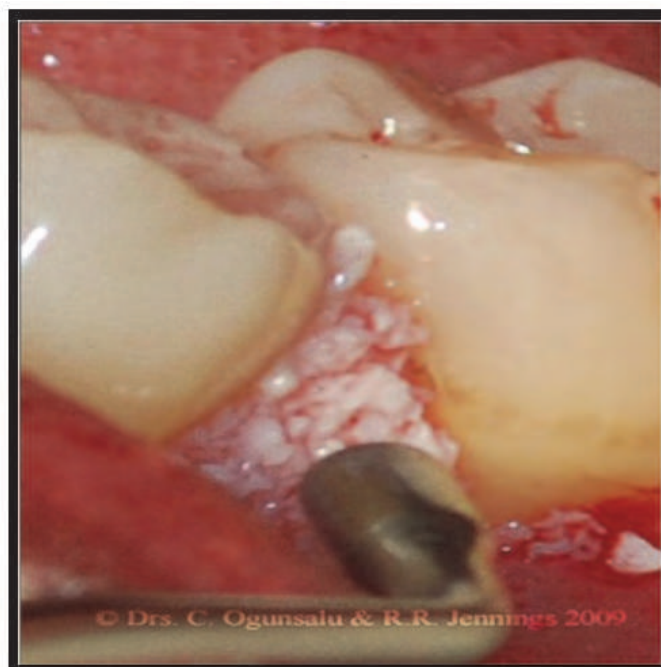


Fig. 24. Condensation of bone substitute with amalgam plugger

Once the particulate bone has been packed into the bony defect and appropriately condensed, the autotac pins and kit (Fig. 25) is now used to secure the GTR membrane which has been used to cover the grafted site (Fig. 26).




Fig. 25. Autotac kit with extra pins in sterile bottle

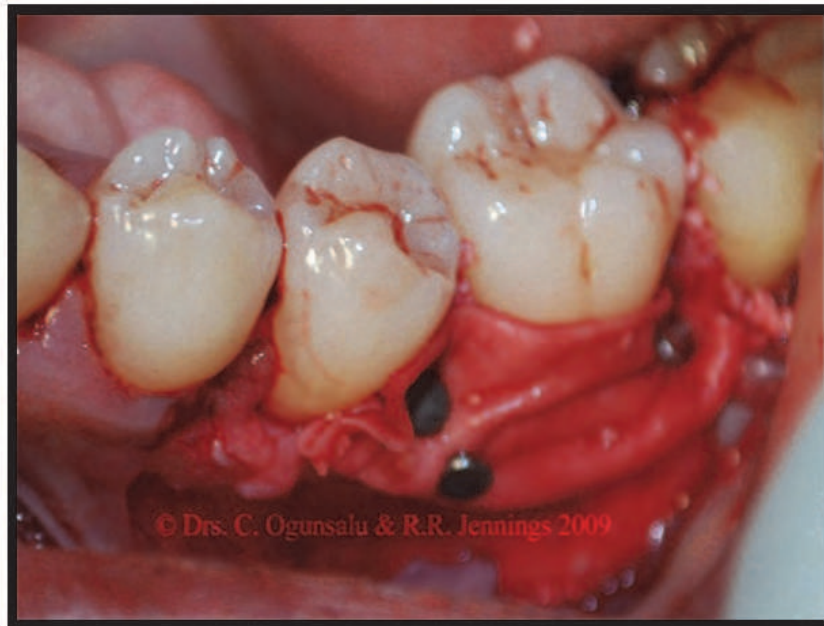


Fig. 26. Grafted site covered with resorbable membrane which is secured with stainless steel pins
The surgical procedure is then completed by suturing preferably with a non-resorbable suture material in such a manner that it is tension free (Fig. 27)

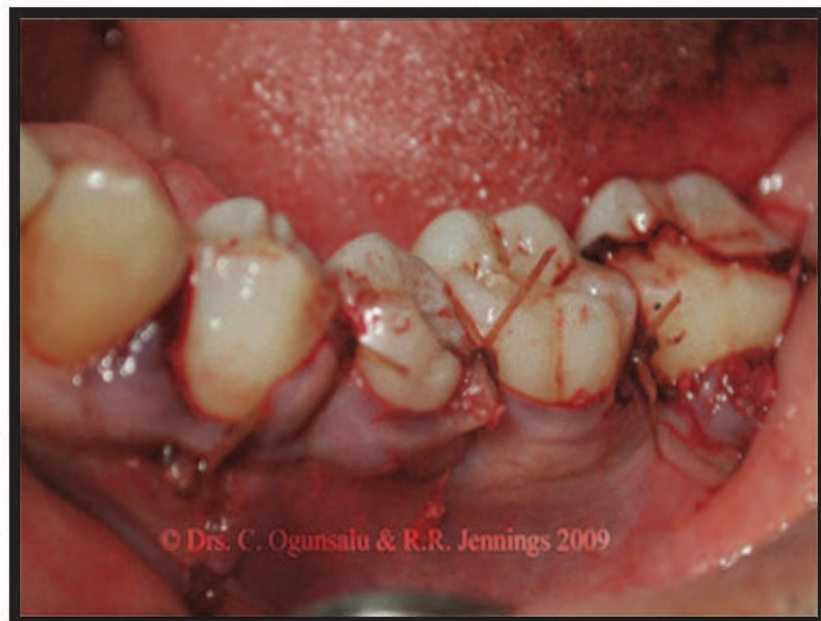

Fig. 27. Tension free suturing with resorbable suture

Most manufacturers of bone regenerative materials proudly explain the stage by stage use of their products in the appropriate section of their website. These information for use should be considered as very reliable and the clinician intending to use these products must adhere strictly to the suggested surgical sequence. For example Straumann, the manufacturers of a bone substitute, Emdogain proudly describe the use of this product which come in gel form variably by audiovisual on its website, www.straumann.us/index/..products-emdogain.htm.

Additionally they also mention the functional advantage, cellular process involved in bone regeneration when Emdogain is used . The various scientific research to back-up this product is also mentioned.

9. Osteobstruction and bone substitutes

The osteobstruction mechanism in bone regeneration was coincidentally discovered during a sequential SPECT, histological and histomorphometric analysis on animal model in the validation of the Ogunsalu Sandwich Bone Regeneration Technique (Ogunsalu 2009). This osteobstructive mechanism was demonstrated by episodes of overtaking and re-overtaking on SPECT following evaluation of osteoblastic activities in a sequential animal experiment to validate both the Ogunsalu Sandwich Bone Regeneration Technique (a double guided tissue technique; D-GTR) and the interceed membrane technique (a single guided tissue regeneration technique;-S-GTR) utilizing SPECT, histological and histomorphometric evaluation (Ogunsalu et al. 2008). This new phenomenon of overtaking and re-overtaking and the newly discovered osteobstructive phenomenon, in bone regeneration are integral finding of my experiment, of which much discussion will follow in the next paragraph which will focus primarily on discussing the findings of sequential histological and histomorphometric findings, against the background of the SPECT findings at 8, 14,11,17,13 and 24 weeks. The implications of this sequential finding will also be discussed. During the 8th week the total bone area was slightly more in the interceed side than the sandwich side and both side had vital bone with no non-vital bone. Also the marrow and fibrous tissue was more on the interceed side. This is in keeping with the superior osteoblastic activity on the interceed side on SPECT when compared with the sandwich side (Fig. 28)

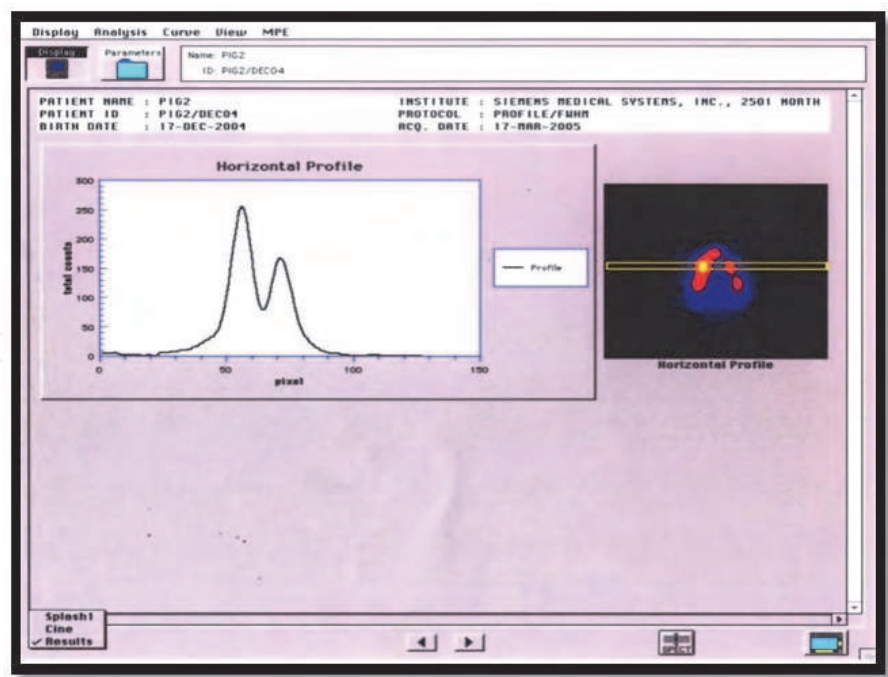


Fig. 28. Showing graphically the profile of osteoblastic activity of the sandwich side (SS) versus the interceed side (IS), together with the activity ratio. The IS obviously has more activity than the SS at 8 weeks. Note that the actual left side of the pig is represented by the right side of the profile.

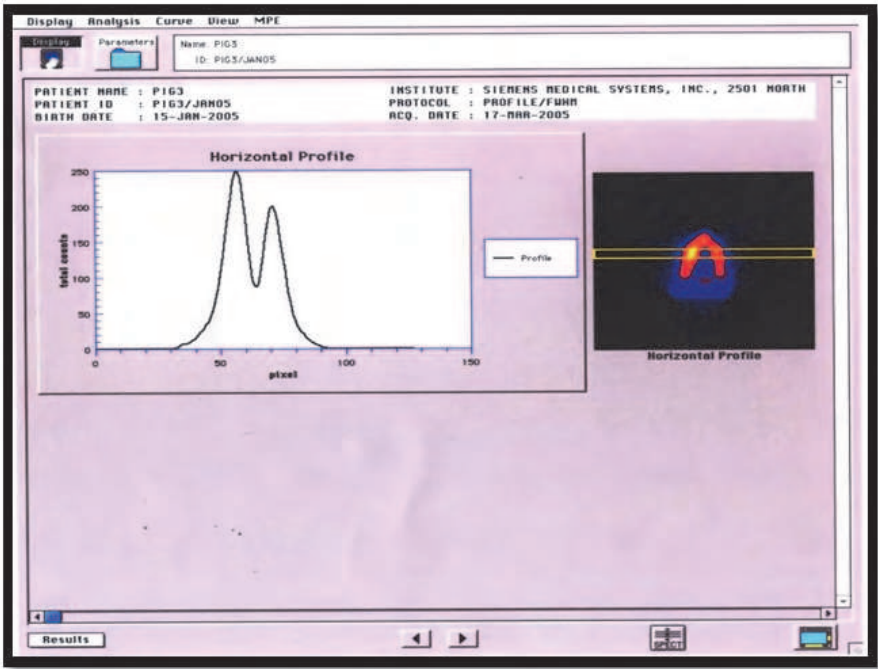


Fig. 29. Showing graphically the profile of osteoblastic activity of the sandwich side (SS) versus the interceed (IS) together with the activity ratio at 11 weeks. The interceed side still leads the SS at Fig 29: 11 weeks. Note that the actual left side of the pigs jaw is represented by the right side of the profile. The osteoblastic activity is still superior on the interceed side.

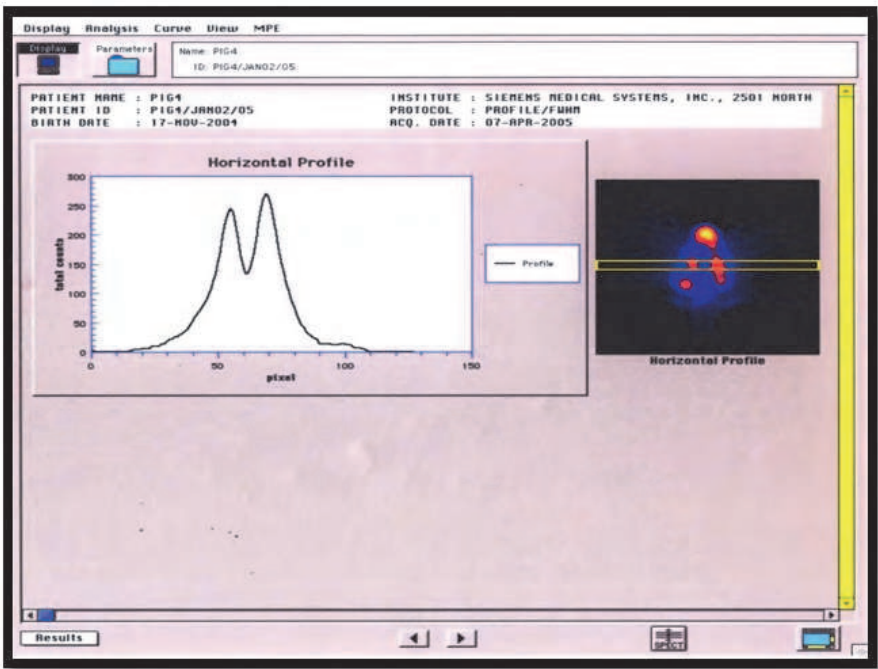


Fig. 30. Showing graphically the profile of osteoblastic activity of the sandwich side (SS) versus the interceed side (IS) together with the activity ratio at 13 weeks. The osteoblastic activity in the sandwich side has now overtaken the interceed side (slightly) at 13 weeks. Note that the actual left side of the pigs jaw is represented by the right side of the profile.

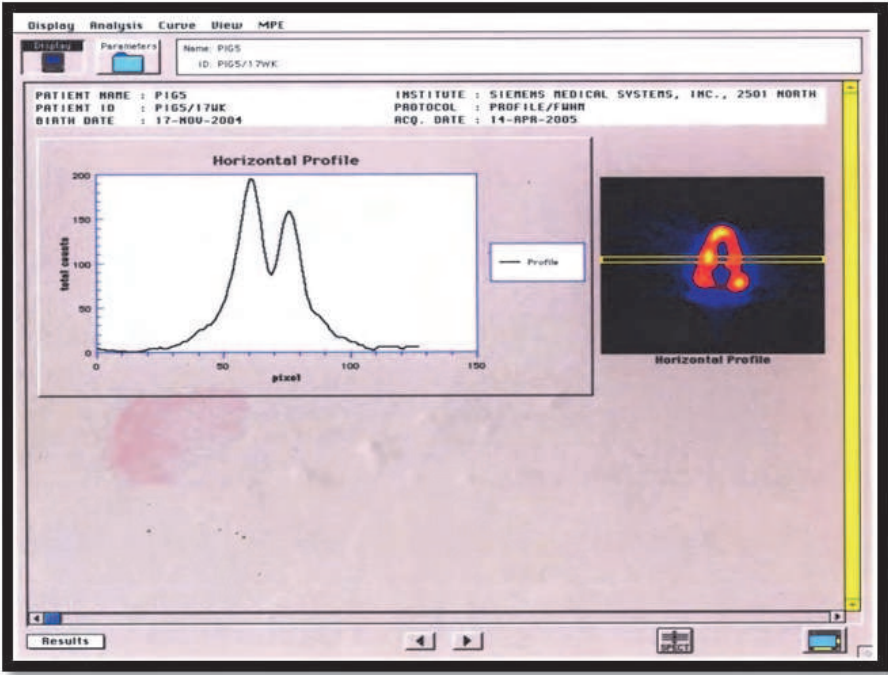


Fig. 31. Showing graphically the profile of osteoblastic activity of Sandwich side (SS) versus interceed side (IS) together with the activity ratio. The IS still leads the SS in terms of osteoblastic activity at 17 weeks as a result of an overtake. Note that the actual left side of the pigs jaw is represented by the right side of the profile

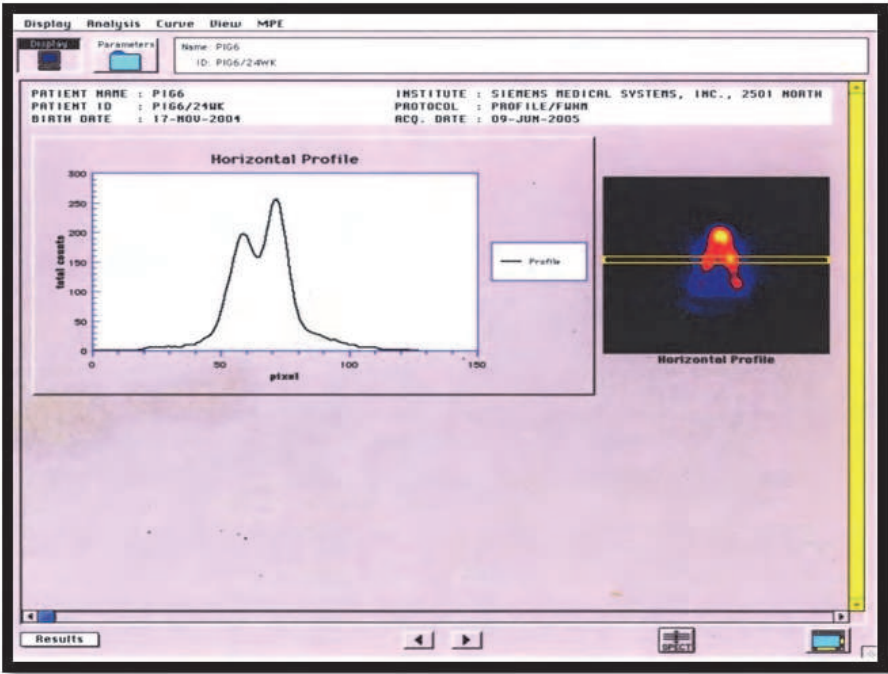
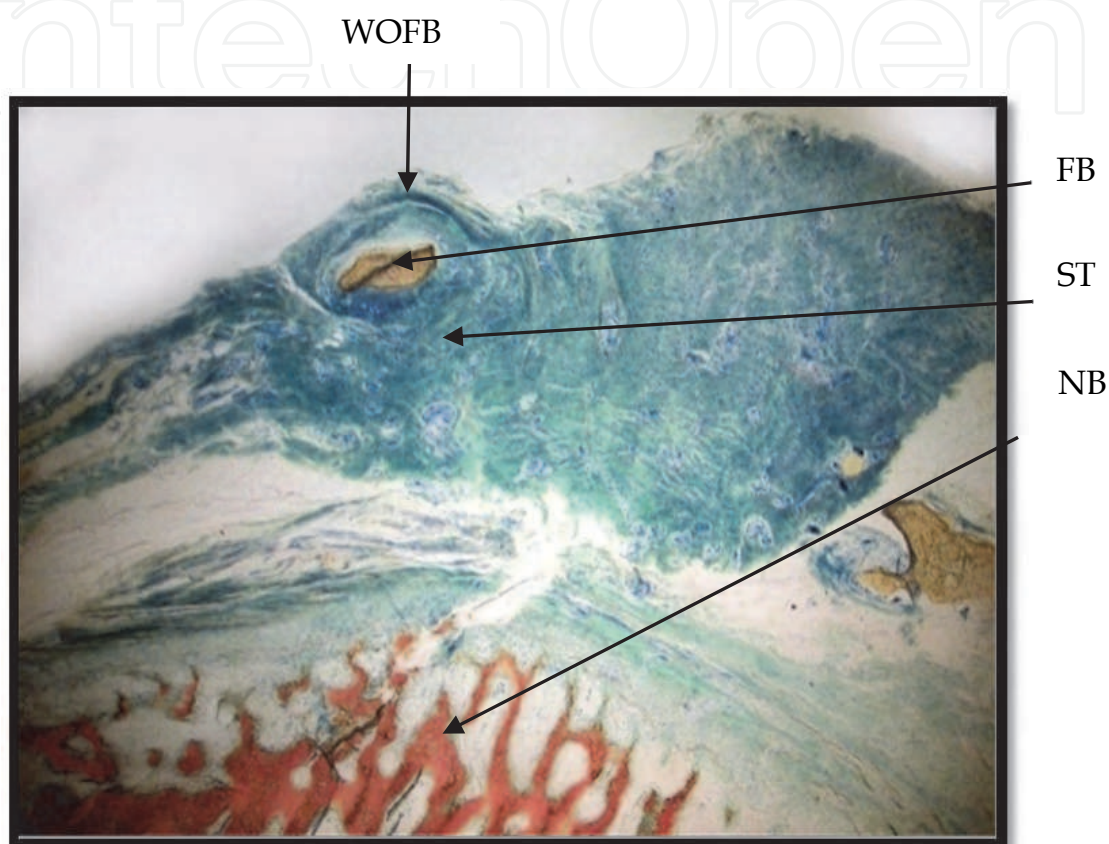


Fig. 32. Showing graphically the profile of osteoblastic activity of the sandwich side (SS) versus interceed side (IS), together with the activity ratio at 24 weeks. The sandwich side has finally exceeded the interceed side at 24 weeks.

The superiority of the interceed side was short lived at week 13 due to an overtake by the sandwich side (Fig. 29 to Fig. 32). This overtake as we found was due to the presence of foreign body reaction on the interceed side at week 11 as shown in Figure 33. The foreign body reaction is what can cause osteobstruction during bone regeneration. We as such include this as part of the mechanism of bone regeneration despite it being a negative mechanism when compared with osteogenesis, osteoinduction and osteoconduction which are all positive mechanisms.



NB = New Bone, ST = Soft Tissue, FB = Foreign Body, WOFB = Walling off of foreign body

Fig. 33. Medium power photomicrograph showing Bio-Oss in soft tissue representative of foreign body reaction. (Slide 22-06-49M; Stevenel's blue and van Gieson's picro fuchsin)

10. Conclusion

Various bone grafting substitutes continue to emerge into the market to assist with bone regeneration prior to, during and after implant therapy. These bone grafting substitutes preferably called second hand bones should be classified as shown in Figure 3. They can only be validated quantitatively and qualitatively by the monitoring of the triggered osteoblastic activity over a time period utilizing single photon emission computerized tomography(SPECT) as demonstrated in the work of Ogunsalu and co-workers. It is this validation that will inform the clinician which bone substitute performs better in terms of bone regeneration and osteoblastic activity/ index. Further more, the osteo-obstructive phenomenon in bone regeneration discovered by the above mentioned workers is new and warrants more investigation.

11. References

- [1] Misch CE, Dietsh F. 1993. "Bone-grafting materials in implant dentistry." *Implant Dent.* 2(3):158-67.
- [2] Marx RE, Saunders TR. 1986. "Reconstruction and rehabilitation of cancer patients." In *Reconstructive preprosthetic oral and maxillofacial surgery* edited by Fonseca RJ and Davis WH, 347-28. Philadelphia: WB Saunders.
- [3] Garg AK. 2004. Bone: biology, harvesting, grafting for dental implants. Chicago, IL: Quintessence Publishing.
- [4] Urist MR. 1980. "Bone transplants and implants." In *Fundamental and clinical bone physiology*, edited by Urist MR. 331- 368. Philadelphia: JB Lippincott.
- [5] Urist MR. 1965. "Bone: formation by autoinduction." *Science.* 150: 893-99.
- [6] Rejda BV, Peelen JGJ, deGroot K. 1977. "Tricalcium phosphate as a bone substitute." *J. Bioeng.* 1: 93-97.
- [7] Jarcho M. 1981. "Calcium phosphate ceramics as hard tissue prosthetics." *Clinical Orthop.* 157: 259 -78.
- [8] Albrektsson T. 1985. "Bone tissue response." In *Tissue-integrated prostheses. Osseointegration in clinical dentistry* edited by Branemark P-I, Zarb GA, Albrektsson T. 129-143. Chicago, IL: Quintessence Publishing.
- [9] Garg AK, 2004, Bone: biology, harvesting, grafting for dental implants. Chicago, IL: Quintessence Publishing.
- [10] Marx RE, Garg AK. 1998. "Bone structure, metabolism and physiology; its impact on dental implantology." *Implant Dent.* 7: 267-76.
- [11] Lane JM. 1995 "Bone graft substitutes." *West J Med.* 163: 565-66.
- [12] Frame JW. 1987 "Hydroxyapatite as a biomaterial for alveolar ridge augmentation." *Int J Oral Maxillofac Surg.* 16: 642-55.
- [13] Pinholt EM, Bang G, Haanaes HR. 1991, "Alveolar ridge augmentation in rats by combined hydroxyapatite and osteoinductive material." *Scand J Dent Res.* 99: 64-74.
- [14] Second-hand bones? *Lancet* 1992; 340: 1443.
- [15] Schopper C, Goriwoda W, Moser D, Spassova E, Watzinger F, Ewers R. 2001. "Long-term results after guided bone regeneration with resorbable and microporous titanium membranes." *Oral Maxillofac Clin North Am.* 13: 449-58.
- [16] Kent JN, Block MS. 1989. "Simultaneous maxillary floor bone grafting and placement of hydroxyapatite-coated implants." *J Oral Maxillofac Surg.* 47: 238-42.
- [17] Jensen J, Simonsen EK, Sindet- Pederson S. 1990. "Reconstruction of severely resorbed maxilla with bone grafting and osseointegrated implants: a preliminary report." *J Oral Maxillofac. Surg.* 48: 27-32.
- [18] Reghobar GM, Browne TJ, Reintsena H, Van Dort RP. 1993, "Augmentation of the maxillary sinus floor with autogenous bone for placement of endosseous implants: a preliminary report." *J Oral Maxillofac Surg.*; 51: 1198-203.
- [19] Adell R, Lekholm U, Grondahl K, Branemark P-I, Lindstorm J, Jacobsson M. 1990. "Reconstruction of severely resorbed edentulous maxillae using osseointegrated fixtures in immediate autogenous bone grafts." *Int J Oral Maxillofac Implants.* 5: 233-46.
- [20] Kahnberg KE, Nystrom E, Bartholdsson L. 1989. "Combined use of bone grafts and Branemark fixtures in the treatment of severely resorbed maxillae." *Int J Oral Maxillofac Implants.* 4: 297-304.
- [21] Nystrom E, Kahnbourg KE, Gunne J. 1993. "Bone grafts and Branemark implant in the treatment of the severely resorbed maxilla." *Int J Oral Maxillofac Implants.* 8:45-53.

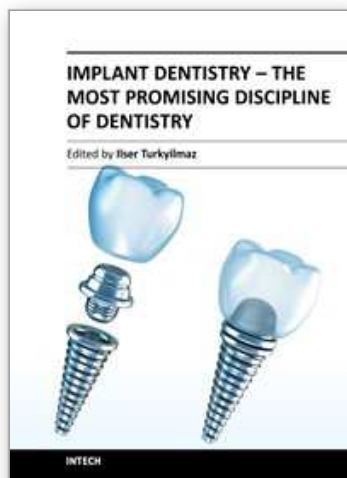
- [22] Wood RM, Moore DL. 1988. "Grafting of the maxillary sinus with intraorally harvested autogenous bone prior to implant placement." *Int J Oral Maxillofac Implants*. 3: 209 – 14.
- [23] Rummelhart JM, Mellonig JT, Gray JL, Towle HJ. 1989. "A comparison of freeze-dried bone allograft and demineralized freeze-dried bone allograft in human periodontal osseous defects." *J Periodontol*. 60: 655-63.
- [24] Mellonig JT. 1984. "Decalcified freeze- dried bone allograft as an implant material in human periodontal defects." *Int J Periodontics Restorative Dent*. 4:40-55.
- [25] Tatum OH Jr, Lebowitz MS, Tatum CA, Borgner RA. 1993. "Sinus augmentation: rationale, development, long term results." *NY state Dent J*. 59: 43 -8.
- [26] Tatum OH Jr. 1996. "Osseous grafts in intraoral sites." *J Oral Implantol*. 22:51-2.
- [27] Fetner AE, Hartigan MS, Low SB. 1994. "Periodontal repair using Perioglass in nonhuman primates: clinical and histologic observations." *Compendium*. 15: 932, 935-38.
- [28] Schepers E, de Clercq M, Ducheyne P, Kempeneers R. 1991. "Bioactive glass particulate materials as filler for bone lesions." *J Oral Rehabil*. 18: 439-52.
- [29] Schepers E, Ducheyne P, Barbier H, Schepers S. 1993. "Bioactive glass particles of narrow size range: A new material for the repair of bone defects." *Implant Dent*. 2: 151-56.
- [30] Smiler DG, Johnson PW, Lozada JL, Misch C, Rosenlicht JL, Tatum OH Jr et al. Sinus lift grafts and endosseous implants. Treatment of the atrophic posterior maxilla. *Dent Clin North Am*. 1992; 36: 151-86.
- [31] McAllister BS, Margolin MD, Cogan AG, Buck D, Hollinger JO, Lynch SE. 1999. "Eighteen-month radiographic and histologic evaluation of sinus grafting with anorganic bone in the chimpanzee." *Int J Oral Maxillofac Implants*. 14: 361-68.
- [32] Wagner J. 1989. "Clinical and histological case study using resorbable hydroxylapatite for the repair of osseous defects prior to endosseous implant surgery." *J Oral Implantol*. 15: 186-92.
- [33] Koole R, Bosker H, van der Dussen FN. 1989. "Late secondary autogenous bone grafting in cleft patients comparing mandibular (ectomesenchymal) and iliac crest (mesenchymal) grafts." *J Craniomaxillofac Surg*. 17 Suppl 1: 28-30.
- [34] Garg AK. 1996. Practical implant dentistry. Houston, TX: Taylor Publishing Company.
- [35] Buser D, Dula K, Hirt HP, Schenk RK. 1996. "Lateral ridge augmentation using autografts and barrier membranes. A clinical study with 40 partially edentulous patients." *J Oral Maxillofac Surg*. 54: 420-32.
- [36] Hislop WS, Finlay PM, Moos KF. 1993. "A preliminary study into the uses of anorganic bone in oral and maxillofac surgery." *Br J Oral Maxillofac Surg*. 31: 149-53.
- [37] Roberts WE, Turley PK, Brezniak N, Fielder PJ. 1987. "Implants. Bone physiology and metabolism." *Calif Dent Assoc J*. 15: 54-61.
- [38] Longacre JJ, Converse JM, Knize DM. 1977. "Transplantation of bone. In: Converse JM, editors. Reconstructive plastic surgery: principles and procedure in correction, reconstruction and transplantation. 2nd ed." Philadelphia: WB Saunders. 313-39.
- [39] Fonseca RJ, Frost D, Zeitler D, Stoelinga PJW. 1986. "Osseous reconstruction of edentulous bone loss." In *Reconstructive preprosthetic oral and maxillofacial surgery*, edited by Fonseca RJ, Davis WH. 117-65. Philadelphia: WB Saunders.
- [40] Acil Y, Springer IN, Broek V, Terheyden H, Jepsen S. 2002. "Effect of bone morphogenic proteins-7 stimulation on osteoblasts cultured on different biomaterials." *J Cell Biochem*. 86: 90-8.
- [41] Wikesjo UM, Sorensen RG, Kinoshita A, Wozney JM. 2002. "Rh BMP- 2/ alpha-BSM induce significant vertical alveolar ridge augmentation and dental implant osseointegration." *Clin Implant Dent Res*. 4: 173-81.

- [42] Meffert RA. 1998. "Current usage of bone fill as an adjunct in implant dentistry." *Dent Implantol Update*. 9:9-12.
- [43] Feuille F, Knapp CI, Brunsvold MA, Mellonig JT. 2003 "Clinical and histologic evaluation of bone-replacement grafts in the treatment of localized alveolar ridge defects. Part I: Mineralized freeze-dried bone allograft." *Int J Periodontics Restorative Dent*. 23: 29-35.
- [44] Masullo C. 1995. "Estimate of the theoretical risk of transmission of Creutzfeldt Jakob disease by human dura mater grafts manufactured by the Tutoplast process: a commissioned report for Bio-dynamics International." Rowe, Italy: Institute of Neurology, Catholic University.
- [45] Gunther KP, Scharf HP, Pesch HJ, Puhl W. 1996. "Osteointegration of solvent - preserved bone transplants in an animal model." *Osteology*. 5: 4-12.
- [46] Sener BC, Tasar F, Akkocaoglu M, Ozgen S, Kasapoglu O. 1998. "Use of allogenic bone grafts in onlay and sandwich augmentation technique." Paper presented at the XIV Congress of the European Association for Cranio- Maxillofacial Surgery in Helsinki, Finland, Sep 1-5.
- [47] Becker W, Urist M, Becker BE, Jackson W, Parry DA, Bartold M, et al. 1996. "Clinical and histologic observations of sites implanted with intraoral autologous bone grafts or allografts. 15 human case reports." *J Periodontol*. 67: 1025-33.
- [48] Dalkyz M, Ozcan A, Yapar M, Gokay N, Yuncu M. 2000. "Evaluation of the effects of different biomaterials on bone defects." *Implant Dent*. 9:226-35.
- [49] Alexopoulau M, Semergidis T, Sereti M. 1998. "Allogenic bone grafting of small and medium defects of the jaws." Paper presented at the XIV Congress of the European Association for Cranio- Maxillofacial Surgery in Helsinki, Finland, Sep 1-5.
- [50] Brugnami F, Then PR, Moroi H, Leone CW. 1996. "Histologic evaluation of human extraction sockets treated with demineralized freeze-dried bone allograft (DFDBA) and cell occlusive membrane." *J Periodontol*. 67: 821-5.
- [51] Zhang M, Powers RM Jr, Wolfenbarger L Jr. 1997. "A Quantitative assessment of osteoinductivity of human demineralized bone matrix." *J Periodontol*. 68: 1076-84.
- [52] Schwartz Z, Mellonig JT, Carnes DL, de la Fontaine J. 1996. "Ability of Commercial demineralized freeze-dried bone allograft to induce new bone formation." *J Periodontol*. 67: 918-26.
- [53] Masters LB, Mellonig JT, Brunsvold MA, Nummikoski PV. 1996. "A Clinical evaluation of demineralized freeze-dried bone allograft in combination with tetracycline in the treatment of periodontal osseous defects." *J Periodontol*. 67:770-81.
- [54] Bowers G, Felton F, Middleton C. 1991. "Histologic comparison of regeneration in human intrabony defects when osteogenin is combined with demineralized freeze-dried bone allograft and with purified bone collagen." *J Periodontol*. 62: 690-702.
- [55] Takikawa S, Bauer TW, Kambic H, Togawa D. 2003. "Comparative evaluation of the osteoinductivity of two formulations of human demineralized bone matrix." *J Biomed Mater Res*. 65A: 37-42.
- [56] Gendler E. 1986. "Perforated demineralized bone matrix: a new form of osteoinductive biomaterial." *J Biomed Mater Research*. 20: 687-97.
- [57] Mckibbin B. 1978. "The biology of fracture healing in long bones." *J Bone Joint Surg Br*. 60B:150-62.
- [58] Peck WA. 1981. "Osteoporosis as a disturbance in the local regulation of bone cell activity." In *Osteoporosis*, edited by J Menczel, G.C. Robin, M. Makin and R Steinberg. 191-94. New York: John Wiley.

- [59] Meffert RM, Thomas JR, Hamilton KM, Brownstein CN. 1985. "Hydroxylapatite as an alloplastic graft in the treatment of human periodontal osseous defects." *J Periodontol.* 56: 63-73.
- [60] Le Geros RZ. 1988. "Calcium phosphate materials in restorative dentistry: a review." *Adv Dent Res.* 2: 164-80.
- [61] Le Geros RZ. 1983. "Properties of commercial bone grafts compared to human bone and new synthetic bone. Biomaterials." In *Program and abstracts of the 9th annual meeting of the Society for Biomaterials*. Abstract 86. Birmingham AL.
- [62] Masters DH. 1988. "Bone, bone substitute." *Calif Dent Assoc J.* 16: 56-65.
- [63] ToFe AJ, Watson BA, Bowerman MA. 1991. "Solution and cell mediated resorption of grafting materials." *J Oral Implantol.* 17: 345 abstract.
- [64] Jarcho M. 1981. "Calcium phosphate ceramics as hard tissue prosthetics." *Clin Orthop Relat Res.* 157: 259-78.
- [65] Heimke G, Griss P. 1983. "Tissue reactions to bone replacement materials." In *Bioceramics of calcium phosphate*, edited by de Groot K. 79-94. Boca Raton, FL: CRC Press.
- [66] Swart JGN, Rejda BV, de Groot K. 1979. "Porous calcium phosphate as alveolar bone implant." *J Dent Res.* 58 (Spec. Issue D): 2267, abstract 73.
- [67] Pinholt EM, Bang G, 1991. "Haanaes HR. Alveolar ridge augmentation in rats by Bio-Oss." *Scand J Dent Res.* 99: 154-61.
- [68] Will RG. 1999. "The transmission of prions to humans." *Acta Paediatr Suppl.* 88 (433):28-32.Review.
- [69] Scott MR, Will R, Ironside J, Nguyen H-OB, Tremblay P, De Armond SJ, Prusiner SB. 1999. "Compelling transgenic evidence for transmission of bovine spongiform encephalopathy prions to humans." *Proc Natl Acad Sci USA.* 96:15137-42.
- [70] Vedrager J. 1999. "Risk of transmission of BSE via drugs of bovine origin." *Lancet* 354: 1304-5.
- [71] Bundesgesundheitsamt. 1994. "Bekanntmachung der Sicherheits- anforderungen an Arzermittel aus Körperbestandteilen Von Rind, Schaf oder Ziege Zur Vemeidung des Risikos einer Übertragung Von BSE bzw. Scrapis." *Bundesanzeiger.* 40: 1851-55.
- [72] Bundesgesundheitsamt. 1996. "Bekanntmachung über die Zulassung and Registrierung Von Arzneimitteln." *Bundesauzeiger.* 67: 4158-62.
- [73] Wenz B, Oesch B, Horst M. 2001. "Analysis of the risk of transmitting bovine spongiform encephalopathy through bone graft derived from bovine bone." *Biomaterials.* 22: 1599-606.
- [74] Similer DG. 2001. "Comparison of an organic bovine mineral with and without synthetic peptide in a sinus elevation: a case study." *Implant Dent.* 10: 139-42.
- [75] Krauser JT, Rohrer MD, Wallace SS. 2000. "Human histologic and histomorphometric analysis comparing OsteoGraft/N with Pep Gen P-15 in the maxillary sinus elevation procedures: a case report." *Implant Dent.* 9: 298-302.
- [76] Hahn J, Rohrer MD, Tofe AJ. 2003. "Clinical, radiographic, histologic and histomorphometric comparison of PepGen P-15 particulate and PepGen P-15 flow in extraction sockets: a same-month case study." *Implant Dent.* 12: 170-74.
- [77] Kirsh ER, Garg AK. 1994. "Postextraction ridge maintenance using the endosseous ridge maintenance implant (ERMI)." *Compendium.* 15: 234-38.
- [78] Wilson J, Clark AE, Hall M, Hench LL. 1993. "Tissue response to Bioglass endosseous ridge maintenance implants." *J Oral Implantol.* 19: 295-302.
- [79] Oonishi H, Kushitani S, Yasukawa E et al. 1994. "Bone growth into spaces between 45S5 bioglass granules." In *Bioceramics, Vol 7: Proceedings of the 7th International Symposium on Ceramics in Medicine July 28-30, Turku, Finland*, edited by Andersson OH, Yi-urpo A. 139-44. Oxford: Butterworth-Heinemann

- [80] Quinones CR, Lovelace TB. 1997. "Utilization of bio-active synthetic particulate for periodontal therapy and bone augmentation techniques." *Pract Periodont Aesthet Dent*. 9:1-7.
- [81] Duchenyne P, Bianco P, Radin S, Schepers E. 1992. "Bioactive materials: mechanisms and bioengineering considerations." In *Bone Bonding*, edited by Ducheyne P, Kokubo T, Van Blitterwijk CA. 1-12 Sutton: Reed Healthcare Publications.
- [82] Ashman A. 1993. "Clinical applications of synthetic bone in dentistry, Part II: Periodontal and bony defects in conjunction with dental implants." *Gen Dent*. 41: 37-44.
- [83] Ashman A. 1984. "The use of synthetic bone materials in dentistry." *Compendium Contin Educ Dent*. 13: 1020-34.
- [84] Boyne PJ. 1995. "Study of the use of HTR in tooth extraction socket to maintain alveolar ridge height and increase concentration of alveolar bone matrix." *Gen Dent*. 43: 470-3.
- [85] Boyne PJ. 1991. "Comparison of Bio-Oss and other implant materials in the maintenance of the alveolar ridge of mandible in man." In *International Symposium on Modern Trends in Bone Substitutes 1990 May Lucerne, Switzerland*, edited by Huggler AH, Kuner EH. 98-103. Hefte Zur Unfallheilkunde, Heft 216, Hrsg. Springer-Verlag.
- [86] Misch CE. 1990. "Divisions of available bone in implant dentistry." *Int J Oral Implantol*. 7: 9-17.
- [87] Misch CE. 1993. "Edentulous alveolar ridge augmentation and restorative grafting: residual ridge augmentation." In *Contemporary Implant Dentistry*, edited by Misch CE. 422-431. St. Louis: CV. Mosby.
- [88] Khan O, Ell PJ, Jarritt PH, Cullum ID, Williams ES. 1981. "Comparism between emission and transmission computed tomography of the liver." *Clin Res Ed*. 283: 1212-4.
- [89] Khan O, Ell PJ, Jarrit PH, Cullum ID. 1980. "Radio Iso-tope Section Scanning." *Cancer Res*. 40:3059-64.
- [90] Ell PJ, Khan O, Jarrit PH, Callum ID. 1981. "Radionuclide section scanning." *Semin Nucl Med*. 1: 50-60
- [91] Flood TR, Russel K. 1998. "Reconstruction of nasal defects with implant on retained nasal prosthesis." *Br J Oral Maxillofac Surg*. 36:341-5.
- [92] Lima RS, De Lorenzo A, Pantoja MR, Siqueira A. 2004. "Incremental prognostic value of myocardial perfusion 99m-technetium-sestamibi SPECT in the elderly." *Int J Cardiol*. 93:137-43.
- [93] Van der Wall H, Fogelman I. 2007. "Scintigraphy of benign bone disease." *Semin Musculoskelet Radiol*. 11: 281-300.
- [94] Horger M, Bares R. 2006. "The role of single-photon emission computerized tomography/ computed tomography in benign and malignant bone diseases." *Semin Nuci Med*. 36: 286-94.
- [95] Schafers KP, Stegger L. 2008. "Combined imaging of molecular function and morphology with PET/CT and SPECT/CT: image fusion and motion correction." *Basic Res Cardiol*. Mar 103: 191-9.
- [96] Dasgeb B, Mulligan MH, Kim CK. 2007. "The current status of bone scintigraphy in malignant disease." *Semin Musculoskelet Radiol*. 11: 301-11.
- [97] Sarikaya I, Sarikaya A, Holder LE. 2001. "The role of single photon emission computerized tomography in bone imaging." *Semin Nuci Med*. 31: 3-16.
- [98] Ozyurt G, Kaya FN, Kahveci F, Alper E. 2008. "Comparison of SPECT findings and neuropsychological sequele in carbon monoxide and organophosphate poisoning." *Clin Toxicol (Phila)*. 46: 218-21.

- [99] Kalita J, Misra UK, Ranjan P, Pradhar PK. 2008. "Pattern of cerebella perfusion on single emission computed tomography in sub cortical hematoma: a clinical and computed tomography correlation." *Neurol India*. 56: 17-21.
- [100] Crespo C, Gallego J, Cot A, Falcon C, Bullich S, Pareto D, Aguiar O et al. 2008. "Quantification of dopaminergic neurotransmission SPECT studies with 123I-labelled radioligands: a comparison between different imaging system and data acquisition protocol using Monte Carlo Simulation." *Eur J Nucl Med Imaging*. 35: 1334-42.
- [101] Massardo T, Lavados H, Jaimovich R, Herrera E, Quevedo L, Alfaro L et al. 2008. "Interobserver correlation in the interpretation of 99m Tc sestamibi SPECT in reperfused acute myocardial infarction." *Rev Esp Med Nuci*. 27: 83-9.
- [102] Ellis RJ, Zhon EH, Fu P, Kaminsky DA, Sodee DB, Faulhaber PF, et al. 2008. "Single photon emission computerized tomography with c apromab pendetide plus computed tomography image set co-registration independently predicts biochemical failure." *J Urol*. 179: 1768-73.
- [103] Alberto PL. 1998. "Implant reconstruction of the jaws and craniofacial skeleton." *Mt Sinai J Med*. 65: 316-21.
- [104] Galasko CS. 1975. "The pathologic basis for skeletal scintigraphy." *J Bone Joint Surg Br*. 57: 353-9.
- [105] Ogunsalu et al. 2008. "Single photon emission computerized tomography and histological evaluation in the validation of a new technique for the closure of oro-antral communication: an experimental study in pigs." *West Indian Med J*. Mar; 57(2):166-72.
- [106] Ogunsalu C, Ezeokoli C, Daisley H, Adogwa A, Watkins J, Archibald A et al. 2008. "Single photon emission computerized tomography in the evaluation of the osteoblastic activities of a new bone regeneration technique: analysis of 12 mandibular sites in six experimental pigs." *West Indian Med J*. 57(5): 500-7.
- [107] Ogunsalu C, Archibald A, Watkins J, Stoian C, Ezeokoli C, Daisley H, et al. 2008. "Comparative study of the osteoblastic activity of two implant systems (Endopore versus Integra) utilizing Single Photon Emission Computerized Tomography (SPECT): Experimental study in pigs model." Paper presented at the 16th General Meeting and Biennial Conference of the Caribbean Academy of Science, Grande Anse, Grenada, Oct 11-13.
- [108] C. Ogunsalu, C, Ezeokoli, A Archibald, J Watkins, C Stoian, H. Daisley et al. 2008. "Comparative study of osteoblastic activity of same implant (Endopore) in immediate extraction site utilizing single photon emission computerized tomography: Peri-implant autogenous bone grafting with GTR versus no peri-implant bone grafting- Experimental study in pig model" Paper presented at the 16th General Meeting and Biennial Conference of the Caribbean Academy of Science, Grande Anse, Grenada, Oct 11-13.
- [109] Ell PJ, Khan O, Jarrit PJ, Callum ID. Radionuclide section scanning; an atlas of clinical cases. Chapter 3, Clinical results. London: Chapman and Hall; 1982. p. 45-60.
- [110] Khan O, Archibald A, Thompson E, Maharaj P. 2000. "The role of quantitative single photon emission computerized tomography (SPECT) in the osseous integration process of dental implants." *Oral Surg Oral Med Oral Pathol Oral Radiol Endod*. 90: 228-30.
- [111] Ogunsalu C. 2009. "Double-Guided Bone Regeneration using the Ogunsalu sandwich regeneration technique: single photon emission computerized Tomography, Histology, and Histomorphometric analysis." PhD thesis, The University of the West Indies St. Augustine.



Implant Dentistry - The Most Promising Discipline of Dentistry

Edited by Prof. Ilser Turkyilmaz

ISBN 978-953-307-481-8

Hard cover, 476 pages

Publisher InTech

Published online 30, September, 2011

Published in print edition September, 2011

Since Dr. Branemark presented the osseointegration concept with dental implants, implant dentistry has changed and improved dramatically. The use of dental implants has skyrocketed in the past thirty years. As the benefits of therapy became apparent, implant treatment earned a widespread acceptance. The need for dental implants has resulted in a rapid expansion of the market worldwide. To date, general dentists and a variety of specialists offer implants as a solution to partial and complete edentulism. Implant dentistry continues to advance with the development of new surgical and prosthodontic techniques. The purpose of *Implant Dentistry - The Most Promising Discipline of Dentistry* is to present a contemporary resource for dentists who want to replace missing teeth with dental implants. It is a text that integrates common threads among basic science, clinical experience and future concepts. This book consists of twenty-one chapters divided into four sections.

How to reference

In order to correctly reference this scholarly work, feel free to copy and paste the following:

Christopher Ogunsalu (2011). Bone Substitutes and Validation, *Implant Dentistry - The Most Promising Discipline of Dentistry*, Prof. Ilser Turkyilmaz (Ed.), ISBN: 978-953-307-481-8, InTech, Available from: <http://www.intechopen.com/books/implant-dentistry-the-most-promising-discipline-of-dentistry/bone-substitutes-and-validation>

INTech
open science | open minds

InTech Europe

University Campus STeP Ri
Slavka Krautzeka 83/A
51000 Rijeka, Croatia
Phone: +385 (51) 770 447
Fax: +385 (51) 686 166
www.intechopen.com

InTech China

Unit 405, Office Block, Hotel Equatorial Shanghai
No.65, Yan An Road (West), Shanghai, 200040, China
中国上海市延安西路65号上海国际贵都大饭店办公楼405单元
Phone: +86-21-62489820
Fax: +86-21-62489821

© 2011 The Author(s). Licensee IntechOpen. This chapter is distributed under the terms of the [Creative Commons Attribution-NonCommercial-ShareAlike-3.0 License](https://creativecommons.org/licenses/by-nc-sa/3.0/), which permits use, distribution and reproduction for non-commercial purposes, provided the original is properly cited and derivative works building on this content are distributed under the same license.

IntechOpen

IntechOpen