

We are IntechOpen, the world's leading publisher of Open Access books Built by scientists, for scientists

6,900

Open access books available

186,000

International authors and editors

200M

Downloads

Our authors are among the

154

Countries delivered to

TOP 1%

most cited scientists

12.2%

Contributors from top 500 universities



WEB OF SCIENCE™

Selection of our books indexed in the Book Citation Index
in Web of Science™ Core Collection (BKCI)

Interested in publishing with us?
Contact book.department@intechopen.com

Numbers displayed above are based on latest data collected.
For more information visit www.intechopen.com



Epilepsy and Oral Health

Taskin Gurbuz

*Department of Pedodontics, Faculty of Dentistry,
Atatürk University, Erzurum
Turkey*

1. Introduction

Epilepsy is the most common chronic neurologic disorder in paediatric neurology and the predominant aetiologies are birth injury and congenital abnormalities. Epilepsy has a tendency to recurrent seizures. Most of these will have primary or idiopathic epilepsy (i.e., no underlying cause will be evident), but some will have secondary epilepsy due to a cause such as head injury, meningitis, or birth asphyxia. The international classification of epileptic seizures divides the epilepsies into those that are generalized, where the whole brain is involved, and the partial seizures, where the aberrant activity involves only a part of the brain (Koch & Poulsen, 2009). In infants, birth injuries and congenital defects are the primary causes of epilepsy. Birth injuries, genetic factors, infections, and trauma are major contributing factors in children and adolescents from 2 to 20 years of age. For individuals between 20 and 30 years of age, brain tumors and other structural lesions are the foremost contributing causes. In those older than 50 years of age, cerebral vascular accidents and metastatic tumors are significant causes of seizure activity (Aragon & Burneo, 2007).

Epilepsy is the most common neurological problem of childhood, and its incidence is the highest in the first decade of life, a period during which children begin and complete a critical part of their social and educational development. Epilepsy is a common chronic neurologic disorder that affects 1-3% of the population, and almost 10% of the population will have one or more seizures at some time in their lives (Hauser et al., 1996). The epilepsies form an array of more or less discrete epilepsy syndromes, characterized by age of onset, hereditary factors, seizure types, electroencephalogram (EEG) abnormalities, and prognosis (Roger, 2005).

A seizure is classified as "partial" when the electrical discharge causing it to occur in a specific area of the brain or "generalized" when the discharge affects the entire brain cortex. When there is loss of awareness, seizures are termed complex. The classification of epilepsy is similar. Epilepsy can be partial or generalized. Based on the cause, it can be symptomatic (caused by a developmental malformation), idiopathic (when a genetic condition is responsible) or cryptogenic (when the cause is unknown) (Aragon & Burneo, 2007). Epilepsy is the most common disorder in paediatric neurology and the predominant aetiologies are birth injury and congenital abnormalities.

2. Classification of seizures

There are five types of epilepsy, they are:

Grand mal seizures

Petit mal seizures
Psychomotor seizures
Focal seizure (Jacksonian seizures)
Self induced seizures (Rao, 2008).

2.1 Grand mal seizures

Onset is rapid and preceded by momentary aura. Associated with tonic and clonic phases of muscular spasm, patient losses consciousness and becomes pale. Pupils dilate, eyeballs roll upwards or to one side, the face becomes distorted and there is often rapid contraction of the jaw muscles. Micturition and defecation may occur.

Patient may experience cyanosis during the tonic phase (continuous tension or contraction) lasting for 20-40 seconds. Clonic phase (alternating series of contractions and partial relaxation) may last for several minutes. Patient wakes up from seizure with severe headache and in a general state of confusion. A patient who experiences a grand mal seizure in the dental office should be handled conservatively and be put in a position in which he cannot harm himself possibly on the floor away from the dental equipment. If the seizure is prolonged, administration of oxygen may be necessary. A rubber or plastic mouth prop has to be inserted to prevent the patient from biting his tongue. A tongue blade wrapped with gauze and adhesive may be utilized. It is usually sufficient that the dentist wait until the seizure stops and then evaluate him. If the seizure is prolonged, administration of oxygen may be necessary. Recovery may be quick or patient may be irritable.

2.2 Petit mal seizures

It appears between 3 years of age and puberty. More common in girls. It consists of transient loss of consciousness. It may occur once or twice a month or very frequently at less intervals and lasting for less than 30 seconds. Other features are upward rolling of eyes, moving of the lids, drooling or rhythmic nodding of the head or slight quivering of the trunk and limb muscles. They may also go unnoticed.

2.3 Psychomotor seizures

They are difficult to recognize and control. Slight aura is manifested as a shrill of cry or an attempt to run for help. Child is often drowsy or sleeps for a short time after the spell. Seizure consists of loss of postural tone. 1-5 minutes of unconsciousness is followed by normal sleep or activity. No tonic or clonic movements present.

2.4 Focal seizure (Jacksonian seizures)

It is produced by injury to the brain. Seizures are clonic in nature. Muscles involved are the ones most specialized for voluntary movements in the hand, face and tongue.

2.5 Self induced seizures

It is possible for some children to induce petit mal or grand mal seizures by over breathing, watching a blinking light or by performing some other form of learned behavior. In such cases drug therapy alone is usually unsatisfactory. Patient by doing so tries to draw attention to himself and is usually associated with complex family problems and psychiatric consultation is indicated.

3. Diagnosis and treatment

3.1 Diagnosis

The diagnosis of epilepsy requires the presence of recurrent, unprovoked seizures. Patients presenting with seizures should have a general and neurologic examination, looking for other causes of loss of consciousness (eg, cardiac abnormalities, evidence of infection), contributing factors or secondary causes of epilepsy, and focal neurologic signs. Some of the important clinical findings include alterations in consciousness, sensation, motor abilities, and reflexes. Detailed accounts of the seizures from either the patient or eyewitnesses can be important in making a correct diagnosis.

Diagnostic tools, such as electroencephalography (EEG) and magnetic resonance imaging (MRI), are required to classify epilepsy. EEG records waves generated by the brain cortex. These waves have characteristics that allow the differentiation of normal from abnormal electrical discharges and provide information about localization. EEG amplifies the waves and transfers them to a computer for interpretation (Aragon & Burneo, 2007).

When diagnosing epilepsy, the underlying disease must be identified. The signs and symptoms of the patient before, during, and after the seizure are vital for determining the cause. The patient and any witnesses should be questioned, and a physical examination for trauma, infections, and other conditions should be completed. Electroencephalography studies will often reveal an abnormality, especially when additional stimuli are recorded, such as flashing lights, music or rhythmic sounds, sleep deprivation, or hyperventilation. The use of blood tests, magnetic resonance imaging, or computed tomography may also yield helpful information leading to a diagnosis. Primary epilepsy is often diagnosed by exclusion of all other causes (Hupp, 2001).

3.2 Treatment

Seizure disorders are generally more severe in people who have mental retardation. Patients who have developmental disabilities and epilepsy are treated for their seizure type or types and syndrome just like any other person who has epilepsy. Several options exist for the treatment of epileptic seizures, including antiseizure medications, vagal nerve stimulation, ketogenic diet, and surgery. These options are may be used concurrently in the same individual if needed (Robbins, 2009). The choice of medication is related to the type of seizure (Table). In some cases, a trial of anti-seizure medication may be used in a patient with strong evidence of more than one seizure, whereas a patient with a single seizure is usually monitored but not given medication. Long-term therapy using one anticonvulsant medication is most desirable, although some patients need a combination to achieve efficacy with limited toxicity (Hupp, 2001). The most common oral side effect of antiepileptic drugs seen in the dental office is gingival hyperplasia (Fig. 1). Gingival hyperplasia is characterized by unusual growth of the gingival subepithelial connective tissue and epithelium, for unknown reasons; it is reversed once the drug is discontinued. Anticonvulsant drugs such as phenytoin, carbamazepine, valproic acid, and others have been used individually and in combinations. They act to reduce the frequency of seizures, elevate the seizure threshold of the motor cortex, and limit the spread of the excitation from the focus of the seizure (Hupp, 2001). In an epilepsy program, the objective is to find out whether the patient is a surgical candidate by using special tests, such as prolonged monitoring video-electroencephalography (VEEG) and structural MRI. VEEG allows confirmation of epilepsy syndrome and location of the epileptogenic focus. The behavioural

changes captured by video and the focal epileptiform abnormalities in the EEG are the most important pieces of information in the presurgical evaluation.

Drug	Type of seizure	Most common oral side effects and dental considerations
Phenytoin	GTCS, partial	Gingival hyperplasia, delayed healing, gingival bleeding, osteoporosis
Carbamazepine	GTCS, partial	Agranulocytosis, aplastic anemia, xerostomia, delayed healing, gingival bleeding (thrombocytopenia), osteoporosis
Valproic acid	Absence, any type	Excessive bleeding, decreased platelet aggregation, delayed healing, osteoporosis, xerostomia, stomatitis, gingivitis, drug interactions with aspirin and nonsteroidal anti-inflammatory drugs
Phenobarbital	Any type	Drowsiness, drug interactions, xerostomia, stomatitis, osteoporosis
Ethosuximide	Absence	Leukopenia, Stevens-Johnson syndrome, orofacial edema, dysgeusia
Primidone	Partial (psychomotor)	Ataxia, vertigo, stomatitis, osteoporosis
Gabapentin	Partial	Xerostomia, stomatitis, gingivitis, glossitis, orofacial edema, dysgeusia

Table 1. Adverse effects of antiepileptic drugs commonly used in children.

Temporal lobectomy is perhaps the most common type of surgery for epilepsy. In the only randomized controlled trial of surgery versus medical treatment, the success rate was 64%. However, patients can experience a significant decline in verbal memory (McKhann et al., 2002). Which can be partly predicted through a detailed neuropsychologic evaluation (Loring, 1997).

4. Treating dental patients with epilepsy

4.1 General situation

The medical literature contains little information on the influence of epilepsy in dental care. Most existing studies focus on phenytoin-induced gingival hyperplasia. These individuals often have worse oral health status than the general population. They tend to have a higher incidence of dental caries and difficulty in accessing dental care (Chikte et al., 1991). The main reason for higher prevalence of dental caries in disabled individuals is the inadequate plaque removal. Visually impaired cannot visualize the plaque on the teeth surfaces so even

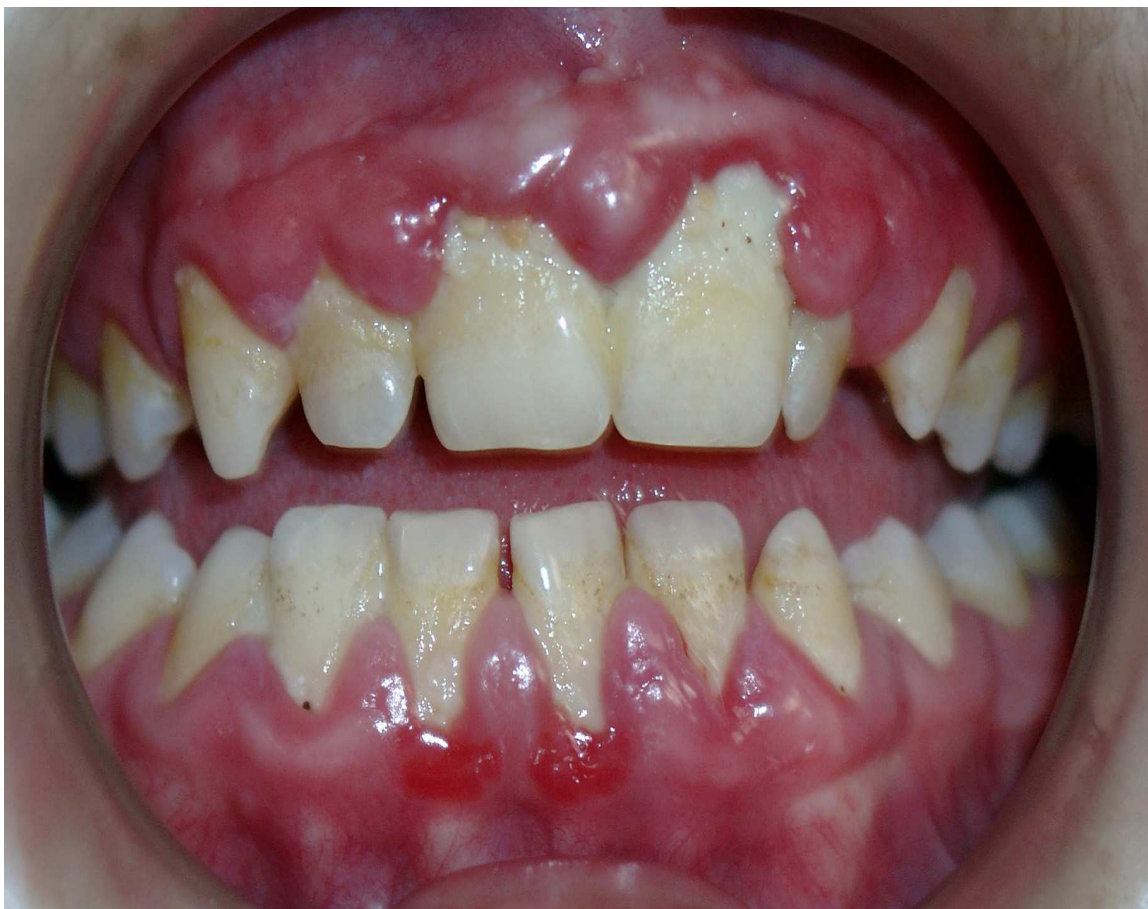

Fig. 1. Severe gingival enlargement in a child with epilepsy.

understanding the importance of oral hygiene is difficult for them, which results in the progression of dental caries as well as inflammatory disease of the periodontium (Mann et al., 1984). Patients living with epilepsy have special needs during dental treatment. In almost all aspects of oral health and dental status, the condition of patients with epilepsy is significantly worse than age-matched groups in the general (nonepileptic) population (Karolyhazy et al., 2003). Furthermore, patients who have poorly controlled epilepsy and experience frequent generalized tonic-clonic seizures exhibit worse oral health in comparison with patients who are better controlled or only have seizures that do not involve the masticatory apparatus (Karolyhazy, et al., 2003).

The number of decayed and missing teeth, the degree of abrasion and periodontal indexes are significantly worse in patients with epilepsy. Those with epilepsy also have significantly fewer restored and replaced teeth than the general population (Karolyhazy et al., 2005).

4.2 Dental status and oral health

4.2.1 Trauma

Dentofacial trauma occurring during seizures has been reported to include injuries to the tongue, buccal mucosa, facial fractures, avulsion, luxation or fractures of teeth, and subluxation of the temporomandibular joint (Ogunbodede et al., 1998).

Generalized tonic-clonic seizures often cause minor oral injuries, such as tongue biting, (Pick & Bauer, 2001) but also frequently lead to tooth injuries (Buck et al., 1997), and in some cases to maxillofacial trauma (Aragon et al., 2001).

Gurbuz et al. (Gurbuz & Tan, 2010) found a traumatic anterior dental injury rate of 68.8% in children with epilepsy in Erzurum, Turkey. This probably resulted from insufficient seizure control or from placing hard objects between the teeth of patients during seizures. According to O'Sullivan, the prevalence of traumatic anterior dental injury was 11–30% in children without epilepsy (Curzon, 2001). Generalized tonic-clonic seizures often cause minor oral injuries, such as tongue biting, but also frequently lead to tooth injuries (Buck, et al., 1997) and in some cases to maxillofacial trauma (Aragon, et al., 2001).

Patients with epilepsy can be at increased risk of fracture because enzyme-inducing antiepileptic drugs (e.g., phenytoin, phenobarbital, carbamazepine) alter the metabolism and clearance of vitamin D and have been associated with osteopenia and osteomalacia. Of interest, increased fracture risk has also been associated with the use of benzodiazepines, antidepressants and antipsychotics, suggesting that underlying brain disease or adverse effects of the medication are responsible for falls and injuries (Mattson & Gidal, 2004).

Fractures can have catastrophic effects on the lives of patients with epilepsy, and measures are available to minimize the risk of fractures, such as ensuring adequate calcium and vitamin D supplementation (a minimum of 1,000 mg and 400 IU daily, respectively) especially in patients taking phenobarbital, phenytoin or primidone (Sato et al., 2001).

4.2.2 Periodontal problems

Children younger than 15 years constitute a large group among epileptic individuals, and a considerable proportion of them also have mental and motor deficits (Bourgeois, 1995; Brodie & Dichter, 1996). These patients are at risk for oral health due to their poor self-care and the side-effects of anticonvulsant treatment: in particular, the use of phenytoin and phenobarbital can be associated with gingival enlargement (Delasnerie-Laupretre & Turpin, 1991; Thomason et al., 1992). Patients with epilepsy can be at increased risk of fracture because enzyme-inducing anti-epileptic drugs (AED; e.g., phenytoin, phenobarbital, carbamazepine) alter the metabolism and clearance of vitamin D and have been associated with osteopenia and osteomalacia (Mattson & Gidal, 2004). The association of phenytoin with gingival enlargement was first described by Kimball in 1939 (Kimball, 1939); subsequently, many articles have reported on its incidence or severity in different populations. The literature reveals a wide variation in its incidence, ranging from 3 to 93%. The variability is primarily due to differences in criteria for assessing the severity of the hyperplasia, the different sizes and ages of studied groups, and variations in the duration and dosage of phenytoin treatment. However, it is now widely accepted that clinically significant hyperplasia is seen in about 50% of patients taking phenytoin (Majola et al., 2000; Ogunbodede, et al., 1998; Perlik et al., 1995; Thomason, et al., 1992).

The logical approach in drug-induced gingival enlargement is a reduction of the dose or replacement with another drug (Dahllof et al., 1991; Lundstrom et al., 1982; R. A. Seymour et al., 1985).

Because gingival enlargement has not been reported with carbamazepine so far and appears to be extremely rare with valproate, these drugs have been proposed as alternatives in the treatment of patients who develop or are at risk of phenytoin-induced gingival enlargement (R. A. Seymour, et al., 1985).

Gingival enlargement as a complication of phenytoin use has been well studied (Angelopoulos, 1975a, 1975b). About 50% of patients taking this medication will develop gingival hyperplasia within 12–24 months of initiation of treatment. Despite the existence of

newer medications that are equally effective and have fewer side effects, phenytoin remains one of the most commonly used drugs. Evidence regarding best treatment for gingival hyperplasia is lacking. Some clinicians advocate the use of chlorhexidine, folic acid rinses or both, but excellent oral hygiene will probably prevent or significantly decrease the severity of the condition. In severe cases, surgical reduction is needed (Stoopler et al., 2003).

The newer antiepileptic drugs produce oral manifestations only infrequently. Xerostomia and stomatitis have been reported rarely as side effects of carbamazepine, (Ogunbodede, et al., 1998) and rash that may involve the oral cavity has been associated with lamotrigine and can be exacerbated by the concomitant use of valproic acid (Li et al., 1996).

Although phenytoin-induced gingival enlargement has been better studied, its pathogenesis is still unclear. Several mechanisms related to an interaction between phenytoin and the gingival fibroblasts have been hypothesized. Phenytoin decreases cellular folate uptake possibly by inhibiting cation currents, leading to local folate deficiency. This results in insufficient synthesis of collagenase activator proteins, which play a role in connective tissue catabolism. As connective tissue catabolism is limited, gingival enlargement develops (Brown et al., 1991). The sensitivity of gingival fibroblasts to phenytoin is different in each individual and is genetically determined. This might, in some degree, explain why not all phenytoin-treated individuals develop gingival enlargement. Recently, several reports revealed that the pathogenesis of phenytoin-induced gingival enlargement might be related to certain cytokines, including interleukin-1, -6, and -8; platelet-derived growth factor BB; and basic fibroblast growth factor (Hong & Trackman, 2002; Modeer et al., 2000; Sasaki & Maita, 1998). Whether similar mechanisms play a role in valproate-induced gingival enlargement is unclear.

Valproic acid can cause direct bone marrow suppression, which can impair wound healing and increase post-operative bleeding and infections. Decreased platelet count is the most common and best-recognized hematologic effect of valproic acid; the incidence varies from 5% to 40%. Clinically significant bleeding is uncommon because the thrombocytopenia is usually not severe. For elective surgery, laboratory evaluation – including bleeding time, fibrinogen level, prothrombin time, partial thromboplastin time and von Willebrand factor level – is needed to assess the risk of peri- and postoperative bleeding. Bleeding as a potential side effect should be discussed with patients and their families in preparation for surgery (Acharya & Bussel, 2000).

According to Tan et al., VPA can be associated with side-effects in gingival tissue in children by a mechanism attributable to the drug rather than oral hygiene or inflammation (Tan et al., 2004).

Those findings are consistent with the present results. Seymour reported that the most important determinant of phenytoin-induced gingival enlargement was poor oral hygiene (R.A. Seymour, 1992).

The pathogenesis of phenytoin-induced gingival enlargement is still not well known but several mechanisms, all related to an interaction between phenytoin and the gingival fibroblast, have been hypothesized. Valproic acid can cause direct bone marrow suppression, which can impair wound healing and increase postoperative bleeding and infections (Aragon & Burneo, 2007). The reaction begins as a diffuse swelling of the interdental papillae, which enlarge and coalesce. Clinically significant overgrowth occurs in approximately 50% of patients (Cameron & Widmer, 2008). The incidence and severity of overgrowth are the greatest on the labial surfaces on maxillary and mandibular anterior teeth (Fig. 1).

4.2.3 Prosthodontic problems

Epilepsy is a chronic disease that can affect oral health and prosthodontic status in different ways. However, epilepsy is a condition of various etiologies and seizure types, and different patients may have differing needs in prosthodontic care (Károlyhazy, et al., 2005).

In a recent analysis of the prosthodontic status of patients with epilepsy, it was found out that compared with age-matched controls, patients with epilepsy have a tendency to become edentulous earlier. It was also found that prosthodontic treatment is suboptimal, as significantly fewer teeth are replaced, despite the fact that epileptic patients tend to have more missing teeth. Based on these findings, the authors suggested a classification for patients with epilepsy according to dental risk factors and dental manageability and provided recommendations for dental treatment (Aragon & Burneo, 2007).

Friedlander and Cummings (Friedlander & Cummings, 1989) mentioned that in patients with epilepsy replacement of missing teeth is important to prevent the tongue from being caught in the edentulous spaces during seizures.

Specific guidelines were also provided, such as discouragement of incisal restorations, use of fixed rather than removable prostheses and inclusion of additional abutments if fixed partial dentures are to be used (Károlyhazy, et al., 2005). In addition, the use of metal base for complete dentures and telescopic retention with denture bases made of metal or reinforced with metal for nearly edentulous patients was recommended for those with frequent partial seizures involving the masticatory apparatus, frequent generalized tonic-clonic seizures and other seizures associated with falls. Patients with epilepsy have an increased risk for losing teeth, and the prosthodontic status of epilepsy patients is not optimal. This may unfavorably affect quality of life.

4.2.4 Orthodontic problems

Anti-epileptic drugs related to oral findings include recurrent aphthous-like ulcerations, gingival bleeding, hypercementosis, root shortening, anomalous tooth development, delayed eruption, and cervical lymphadenopathy (Johnstone et al., 1999).

Of particular interest to the orthodontist is a recent report of facial and body asymmetries affecting 41% of patients with partial seizures in the population studied; asymmetries included both hemihypertrophy and atrophy (Fong et al., 2003).

Gingival enlargement may cause delays in permanent teeth eruption and malocclusions in children with mixed dentition (Fig. 2). The hypertonicity of the oral musculature has caused the protrusion of the anterior teeth and the orthopaedic compression of the maxilla.

5. Dental management

Understanding of epilepsy and seizures raises awareness of the disorder's impact on patients' general medical and psychological health. Dental treatment of patients with epilepsy and seizures should be carried out by dentists who are knowledgeable about these disorders (Aragon & Burneo, 2007). The medical literature contains little information on the influence of epilepsy in dental care.

Patients who have epilepsy have been shown to have significantly worse dental condition than the general population (Károlyhazy, et al., 2003). The disease may affect the dental status and oral health of patients in several ways. Patients who have seizure disorders tend to have less than ideal oral health, with higher numbers of decayed and missing teeth. They tend to receive less dental treatment, with significantly fewer restored and replaced teeth

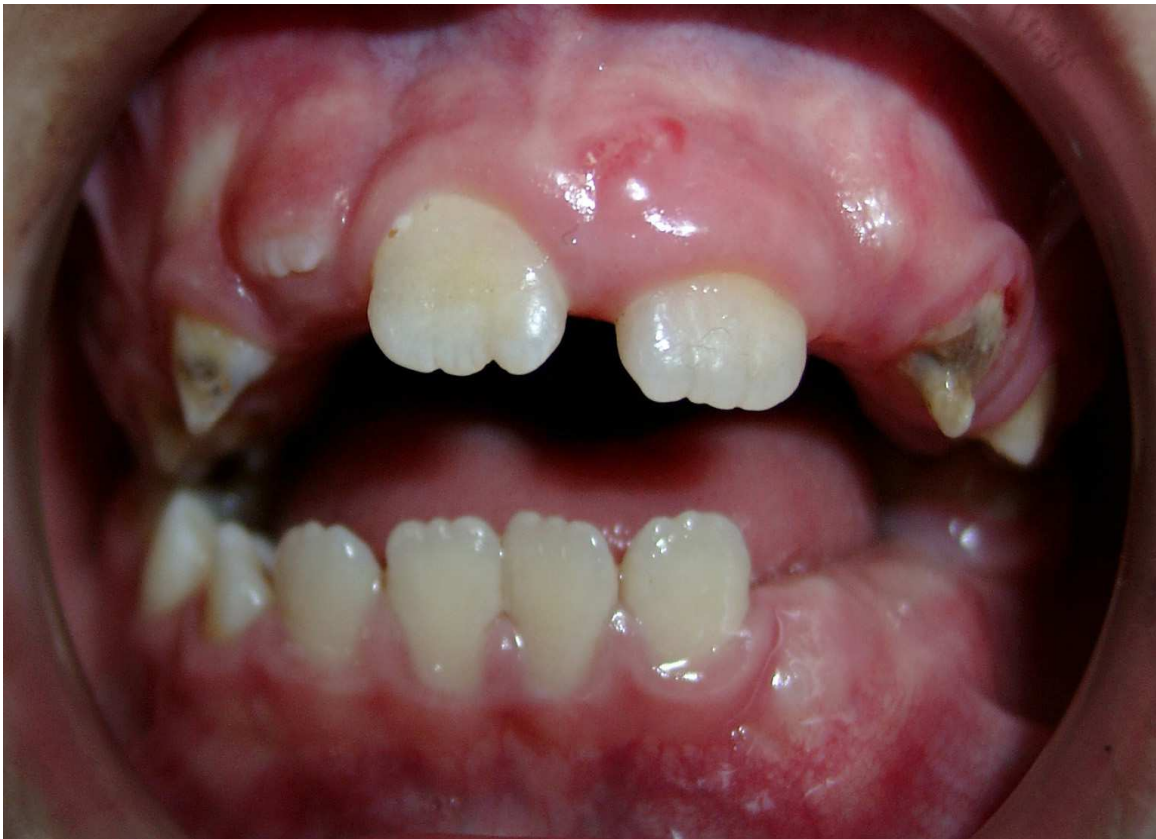

Fig. 2. Tooth eruption problem in a child with epilepsy.

than the general population. This situation can be especially true in patients who have development disabilities, who may have trouble accessing dental care anyway. The seizures themselves can cause injuries to the teeth and dental prostheses. Some of the drugs can cause periodontal disease. Specific considerations for epileptic patients include the treatment of oral soft tissue side effects of medications and damage to the hard and soft tissue of the orofacial region secondary to seizure trauma, especially in patients who suffer from poorly controlled generalized tonic-clonic seizures (Robbins, 2009).

Dentists with a thorough knowledge of seizure disorders and the medications used to treat them can provide necessary dental and oral health care for those patients. Patients with seizure disorders may report a history of fainting or dizzy spells, seizures, or epilepsy, as well as medications to treat the seizures. A thorough evaluation of a patient's seizure disorder is necessary before initiation of any dental treatment. Important aspects to evaluate include the type of seizures, any known cause, frequency, duration, known triggers such as stress or bright lights, presence of aura before seizure activity, and history of injuries related to effects or drug interactions noted. The drug history can give some indication as to the degree of seizure control. Drug history should be carefully reviewed and updated at each visit, and any potential drug side effects or severity or control (Robbins, 2009). The general goal of dental management is the avoidance of a seizure. It is important to know the type of epilepsy and any precipitating factors, medications and dosage, compliance and degree of seizure control before commencing treatment. In addition, drug interactions with anticonvulsants are common and their half-life and blood levels can be increased substantially. Consultation with the child's neurologist is essential before commencement of treatment (Cameron & Widmer, 2008). Unfortunately, even if the patient has been compliant with the

medication, breakthrough seizures can occur. These may be related to fatigue or lack of sleep, menstrual cycle, decreased overall health, a missed meal, alcohol use, physical or emotional stress, or pain. If the patient typically has an aura, it should be noted so that the dentist or staff members can notice any changes and move to protect the patient (Hupp, 2001).

Other conditions can lead to seizures in the dental office. The most common nonepileptic cause is an overdose of local anesthetic. In addition, hypoglycaemia or insulin overdose, hypoxia secondary to syncope, cerebrovascular accident or transient ischemic attack, and hyperventilation can occur in the dental office. If a patient has a convulsive seizure while undergoing dental treatment, stop the procedure and protect the patient from injury. This may involve removing any sharp objects from the area, such as handpieces, placing a soft mouth-prop, and cushioning the patient's head. It may also be necessary to control or gently restrain their arms and legs, keep them from falling out of the dental chair, and loosen any tight clothing. As the patient progresses to the postictal phase, maintain the airway because the muscles may become flaccid. Check for level of awareness, reassure them, and determine whether medical assistance is needed. Patients with partial or absence seizures usually are not at significant risk of loss of consciousness; nevertheless, they must be protected from injury. In some patients, the dental staff may be unaware that an episode has even occurred. Status epilepticus of a convulsive seizure must be treated urgently. Intravenous administration of diazepam or midazolam is needed before permanent brain injury occurs. Either drug should be titrated to the point at which seizure activity ceases. Basic life support (ie, airway, breathing, circulation) should be performed as required, and fluid in the mouth should be suctioned from the buccal aspect of the clenched teeth. Nothing should be forced between the teeth at any time, because temporomandibular joint injury or fractured teeth could result. Notification of emergency medical personnel is needed (Hupp, 2001).

It is advisable to check that the patient has taken his/her routine medications, has eaten normally, is not excessively tired, and has not been recently ill before starting dental treatment. Stress and fatigue are factors that can trigger a seizure. If the patient is not feeling well or is overly tired, it may be prudent to reschedule the appointment. Appointments should be scheduled during a time of day when seizures are less likely to occur, if predictable, and stress and anxiety should be minimized. Explaining the dental procedures to the patient before starting, and offering assurance during the procedure may be helpful. The use of nitrous oxide or conscious sedation may be necessary to provide dental care safely and effectively. In patients whose seizure disorder is poorly controlled and whose developmental disabilities make the delivery of dental care difficult, general anesthesia may need to be considered. General anaesthesia is preferable in children with poor seizure control as the abnormal neural activity is completely ablated during the procedure. Dental trauma is an obvious consequence in the child with frequent, poorly controlled seizures. Removable appliances are contraindicated in an epileptic child due to potential airway obstruction (Cameron & Widmer, 2008). Light can be a trigger in inducing an epileptic seizure. Dark glasses used as eye protection and careful positioning of the dental light so that it is directed into the mouth and not flashed in the patient's eyes can minimize any problems (Robbins, 2009).

It is well known that phenytoin causes gingival hyperplasia in a majority of patients. Studies have reported that the drug induces fibroblasts and osteoblasts, that there is an excessive deposition of extracellular matrix, and that normal tissue turnover and wound healing are altered. The most common sites for hyperplasia are the labial aspects of the maxillary and mandibular ridges. The tissue has normal color and surface texture, with lobular shape of

the interdental papillae and a firm, resilient feel, often without inflammation. Local irritants make the response more exuberant in some patients, with the typical erythema, edema, and easy bleeding of common gingivitis. If significant hyperplasia leads to discomfort, inability to function, or esthetic concerns, surgical reduction is necessary. The anterior labial surfaces of the maxillary and mandibular gingiva are the most commonly affected (Fig. 1) and it is strongly correlated with poor plaque control. It is believed that excellent oral hygiene will prevent or reduce the gingival response to phenytoin.

Most convulsive disorders are controlled through medication and pose few problems in dental treatment. It should be made sure that the child has taken the daily dose of medicines. Since anxiety is a frequent precipitation factor, premedication with minor tranquilizers will be effective. These children often arrive at the dental office in a slightly sedated state due to the CNS depressed activity of anticonvulsant medications. Use of mouth props is mandatory during treatment because once the seizure begins; it is difficult to insert any device to prevent intraoral injury due to clenching of the jaws. If appliances are indicated for tooth movement or tooth replacement purposes, fixed appliance is preferred because there is less chance of dislodgement (Rao, 2008). Generalized tonic-clonic seizures often cause minor oral injuries such as tongue biting and tooth injuries. Traumatic injury to anterior teeth should be evaluated in the standard way. Fractures of the anterior teeth can be repaired with composite restorations. A chest radiograph may be indicated if a tooth is avulsed and cannot be accounted for. Soft tissue wounds should be explored for tooth fragments when incisal fractures occur. Patients who have epilepsy can also be at increased risk for maxillofacial fractures caused by drugs-induced osteoporosis (Turner & Glickman, 2005).

The coarsening of facial features in patients on phenytoin is related to the increased activity of osteoblasts. Other intraoral side effects are seen with anticonvulsant medications, especially in the first few weeks of therapy. A rash or erythema multiforme may develop that can manifest in the mouth as erosions and ulcerations. Phenytoin has been associated with aphthous ulcers. Some of the medications (ie, carbamazepine, phenytoin, phenobarbital) affect bone marrow function, which can lead to altered immune response, thrombocytopenia, and bleeding. Valproic acid inhibits platelet aggregation. Others affect liver function (ethosuximide, carbamazepine), which impairs coagulation. If signs of petechial hemorrhage or abnormal bleeding are noted, hemostasis should be evaluated before surgical treatment. Drug interactions should also be considered for patients on anticonvulsants. A patient taking barbiturates (eg, primidone, phenobarbital) should avoid any other central nervous system depressants such as narcotics or nitrous oxide. Anti-epileptic drugs can cause xerostomia, which can put patients at increased risk for developing caries, especially in the cervical region and candidiasis. In children, increased dental caries can also be seen if drugs are delivered in a syrup form. Carbamazepine can cause ulcerations, xerostomia, glossitis, and stomatitis. The frequency of dental check-ups and prophylaxis appointments should be based on the patient's needs. The recall and hygiene interval may be more frequent for epileptic patients because of increased risk for gingival hyperplasia secondary to use of an anti-epileptic drug. Patients who are xerostomic should be put on supplemental topical fluoride to prevent dental decay and monitored regularly for candidal infections. The importance of good oral hygiene should be stressed to the patient and caregivers (if appropriate) (Robbins, 2009). Aspirin carbamazepine increase liver microsomal enzyme activity, decreasing the activity of concurrent, nonsteroidal anti-inflammatory medications, and the antifungal fluconazole will increase the blood level of

phenytoin and add to the platelet effects of valproic acid. Propoxyphene and erythromycin interfere with the metabolism of carbamazepine, which can lead to toxic levels of the anticonvulsant (Hupp, 2001). Thereafter, patients on VPA should be educated on oral hygiene and their oral health should carefully be followed. Gingivectomy is the treatment of choice in case of gingival hyperplasia that usually occurs with phenytoin therapy. They usually tend to recur. Hence the drug or the dose can be modified upon consultation with the paediatrician.

The presence of a seizure disorder can influence prosthodontic treatment decisions. Missing teeth should be replaced to prevent the tongue from being caught in the edentulous space and injured. Treatment planning considerations must consider fabrication of dental prostheses designed to minimize the risk for displacement of teeth or further damage. Fixed prostheses or implants are preferable to removable appliances because the latter can dislodge during a seizure and cause oral injury or airway obstruction. Large posterior restorations are prone to fracture in someone who may have jaw spasms during a tonic-clonic seizure. All-metal units should be considered whenever aesthetically possible, to minimize the chance of porcelain fracture. In the anterior, metal crowns with acrylic or composite facings can be used to facilitate repair as needed. For fixed partial dentures, the use of additional abutments may be advisable for more stability. If removable partial prostheses are unavoidable, they should be constructed with metallic palates and bases instead of acrylic and metal backings to anterior denture teeth (Robbins, 2009).

The danger of injury to the teeth and prostheses during this type of seizure is the highest and should be considered when designing dental prostheses. For occlusal restorations, the use of ceramic inlays is best avoided; complete metal-ceramic crowns are recommended instead. Generally, fixed rather than removable prostheses are preferred. For fixed partial dentures, the use of additional abutments may be advisable for more stability. If removable partial dentures are unavoidable, the dentures should be designed with a large metal base. As more teeth are lost, telescopic retention may be advised with a base made of metal or reinforced with metal. The base of complete dentures should also be metal or reinforced with metal, because an acrylic base may fracture, increasing the risk of aspiration or dislodgement into the esophagus. A small number of patients with epilepsy, primarily those where the disease is associated with inborn or perinatal encephalopathy, have a severe mental handicap that precludes cooperation. In these patients, general anesthesia is usually necessary to perform dental treatment, and prosthodontic rehabilitation is usually not performed. Seizure-related injuries to prostheses are also an issue, but only for those who are refractory to treatment and suffer from frequent generalized tonic-clonic seizures. Therefore, the large majority of patients can and should receive prosthodontic treatment without restrictions. In a smaller portion of patients, however, certain restrictions apply to prevent potentially dangerous seizure-related complications (Károlyhazy, et al., 2005).

Patients with epilepsy and a malocclusion should have a comprehensive orthodontic evaluation. It is important for the orthodontist to be alert to dental or facial trauma that may have previously occurred during seizures. The level of orthodontic intervention must take into account the type of seizure disorder and efficacy of control. History related by the patient should be confirmed during a discussion with the patient's physician. Adverse side effects of drugs and past dental trauma should be researched by the orthodontist and reviewed as part of patient informed consent. Mechanical challenges such as closing interdental spaces in the presence of gingival hypertrophy should be considered when estimating treatment time. One patient did have a tonic-clonic seizure during fixed

orthodontic treatment and suffered laceration of the lip mucosa and luxation of maxillary incisors; the patient's mother believed that the orthodontic appliance prevented incisor avulsion during the seizure. Accepting such risks should be decision of the patient and/or the guardian after careful discussion with the orthodontist. The metal in a fixed orthodontic appliance may distort images obtained by magnetic resonance imaging (MRI). Any metal portions of the orthodontic appliance close to the area being scanned decreases MRI quality. In some patients, an acceptable MRI may be obtained if arch wires and other removable components are removed before the scan; others will require the removal of the entire orthodontic appliance. This author treated one patient who required yearly MRI brain imaging. The patient's orthodontic treatment was impacted in the following way: fixed appliances were placed the day after MRI scan; 12 months into treatment, all appliances were removed; the MRI was obtained, and appliances were replaced. The fixed appliance was removed after 23 months of therapy, just before the next scheduled MRI scan (Sheller, 2004).

5.1 Management of the epileptic patient in the dental office

It is the responsibility of every dentist to have emergency procedures planned and rehearsed with their office staff on a regular basis. The dentist should reduce stress of the child by behavioral management and conscious sedation techniques. Reduce direct overhead lighting, particularly for the photosensitive form of epilepsy. Avoid seizure-promoting medications such as CNS stimulants and local anaesthetics containing adrenaline (epinephrine). Emergency drugs such as oxygen, intravenous or rectal diazepam (Valium) and intravenous phenobarbital sodium should be readily available. Take a complete health history and a complete seizure history. List all medications, including side effects and potential drug interactions (Gingival hyperplasia and bleeding tendencies in patients taking drug). Minimize risk for damaging or displacing restorations or prostheses during seizure.

The dentist should be careful while positioning of dental light and avoid of known precipitating factors. Consider use of mouth prop at the beginning of procedure. If a seizure occurs while a patient is in the dental chair. Firstly, clear all instruments away from the patient. Place the dental chair in a supported, supine position as near to the floor as possible. Place the patient on his or her side (to decrease the chance of aspiration of secretions or dental materials in the patient's mouth). If possible, remove any foreign material from mouth. If possible, turn patient onto his/her side. Passively restrain only to prevent patient from falling out of chair or hitting nearby objects. After the seizure, it is better to discontinue the therapy. If a cavity is already prepared, either temporize or complete the final restoration. Time the seizure (the duration of the event may seem longer than it actually is). After seizure, turn patient to the side to avoid aspiration and examine for traumatic injuries. If seizure last more than 3 minutes or patient become cyanotic. Administer oxygen at a rate of 6–8 L/minute. If the seizure lasts longer than 1 minute or for repeated seizures, administer a 10-mg dose of diazepam intramuscularly (IM) or intravenously (IV), or 2 mg of ativan, IV or IM, or 5 mg of midazolam, IM or IV. Be aware of the possibility of compromised airway or uncontrollable seizure. Also, contact the patient's family, if he or she is alone (Aragon & Burneo, 2007; Rao, 2008; Robbins, 2009).

6. Conclusion

The oral conditions observed demonstrate the need for dentists to follow up and treat these children. In addition, there is an ongoing need to improve the oral hygiene of these


individuals to prevent the development of periodontal and dental disease in later life. Advances in diagnostic technology, pharmacotherapy and understanding of neurologic processes allow dentists to understand and manage patients with epilepsy better. People with epilepsy can be safely treated in a general dental practice. A thorough medical history should be taken and updated at each visit. Seizure history must be taken into account when planning treatment. Dentists with a comprehension of seizure disorders can provide an invaluable service to their patients, providing not only oral health, but also maintaining and promoting the systemic health of these patients. Patients who have developmental disabilities and epilepsy can be safely treated in a general dental practice. Most patients who have epilepsy can and should receive functionally and esthetically adequate dental care.

7. References

- Acharya, S. & Bussel, J. B. (2000). *Hematologic toxicity of sodium valproate*. Journal Of Pediatric Hematology/Oncology: Official Journal Of The American Society Of Pediatric Hematology/Oncology, Vol.22, No.1, pp.62-65.
- Angelopoulos, A. P. (1975a). *A clinicopathological review. Diphenylhydantoin gingival hyperplasia: 2. Aetiology, pathogenesis, differential diagnosis and treatment*. Dental Journal, Vol.41, No.5, pp.275-277, 283.
- Angelopoulos, A. P. (1975b). *Diphenylhydantoin gingival hyperplasia. A clinicopathological review. 1. Incidence, clinical features and histopathology*. Dental Journal, Vol.41, No.2, pp.103-106.
- Aragon, C. E.; Burneo, J. G. & Helman, J. (2001). *Occult maxillofacial trauma in epilepsy*. The Journal Of Contemporary Dental Practice, Vol.2, No.4, pp.26-32.
- Aragon, C. E. & Burneo, J. G. (2007). *Understanding the patient with epilepsy and seizures in the dental practice*. J Can Dent Assoc, Vol.73, No.1, pp.71-76.
- Bourgeois, B. F. (1995). *Antiepileptic drugs in pediatric practice*. Epilepsia, Vol.36 Suppl 2, pp.S34-45.
- Brodie, M. J. & Dichter, M. A. (1996). *Antiepileptic drugs*. N Engl J Med, Vol.334, No.3, pp.168-175.
- Brown, R. S.; Beaver, W. T. & Bottomley, W. K. (1991). *On the mechanism of drug-induced gingival hyperplasia*. J Oral Pathol Med, Vol.20, No.5, pp.201-209.
- Buck, D.; Baker, G. A.; Jacoby, A.; Smith, D. F. & Chadwick, D. W. (1997). *Patients' experiences of injury as a result of epilepsy*. Epilepsia, Vol.38, No.4, pp.439-444.
- Cameron, A. C. & Widmer, R. P. (2008). *Handbook of pediatric dentistry*, Mosby/Elsevier, 0-7234-3452-2, Edinburgh ; New York.
- Chikte, U. M.; Pochee, E.; Rudolph, M. J. & Reinach, S. G. (1991). *Evaluation of stannous fluoride and chlorhexidine sprays on plaque and gingivitis in handicapped children*. Journal Of Clinical Periodontology, Vol.18, No.5, pp.281-286.
- Curzon, M. E. J. (2001). *Injuries to the primary dentition: diagnosis and treatment modalities*. In: *Handbook of dental trauma : a practical guide to the treatment of trauma to the teeth* (E. A. O'Sullivan (Ed.), pp.1100-1121). Butterworth-Heinemann, 0-7236-1741-4, Oxford.
- Dahllof, G.; Axio, E. & Modeer, T. (1991). *Regression of phenytoin-induced gingival overgrowth after withdrawal of medication*. Swedish Dental Journal, Vol.15, No.3, pp.139-143.

- Delasnerie-Laupretre, N. & Turpin, J. C. (1991). *[Evaluation of the prevalence of side effects of phenobarbital in patients in the Champagne-Ardenne region]*. *Pathol Biol (Paris)*, Vol.39, No.8, pp.780-784.
- Fong, G. C.; Mak, Y. F.; Swartz, B. E.; Walsh, G. O. & Delgado-Escueta, A. V. (2003). *Body part asymmetry in partial seizure*. *Seizure*, Vol.12, No.8, pp.606-612.
- Friedlander, A. H. & Cummings, J. L. (1989). *Temporal lobe epilepsy: its association with psychiatric impairment and appropriate dental management*. *Oral Surgery, Oral Medicine, And Oral Pathology*, Vol.68, No.3, pp.288-292.
- Gurbuz, T. & Tan, H. (2010). *Oral health status in epileptic children*. *Pediatrics International: Official Journal Of The Japan Pediatric Society*, Vol.52, No.2, pp.279-283.
- Hauser, W. A.; Annegers, J. F. & Rocca, W. A. (1996). *Descriptive epidemiology of epilepsy: contributions of population-based studies from Rochester, Minnesota*. *Mayo Clinic Proceedings Mayo Clinic*, Vol.71, No.6, pp.576-586.
- Hong, H. H. & Trackman, P. C. (2002). *Cytokine regulation of gingival fibroblast lysyl oxidase, collagen, and elastin*. *Journal Of Periodontology*, Vol.73, No.2, pp.145-152.
- Hupp, W. S. (2001). *Seizure disorders*. *Oral Surg Oral Med Oral Pathol Oral Radiol Endod*, Vol.92, No.6, pp.593-596.
- Johnstone, S. C.; Barnard, K. M. & Harrison, V. E. (1999). *Recognizing and caring for the medically compromised child: 4. Children with other chronic medical conditions*. *Dent Update*, Vol.26, No.1, pp.21-26.
- Karolyhazy, K.; Kovacs, E.; Kivovics, P.; Fejerdy, P. & Aranyi, Z. (2003). *Dental status and oral health of patients with epilepsy: an epidemiologic study*. *Epilepsia*, Vol.44, No.8, pp.1103-1108.
- Karolyhazy, K.; Kivovics, P.; Fejerdy, P. & Aranyi, Z. (2005). *Prosthodontic status and recommended care of patients with epilepsy*. *J Prosthet Dent*, Vol.93, No.2, pp.177-182.
- Kimball, O. P. (1939). *The Treatment of Epilepsy by Sodium Diphenylhydantoinate*. *JAMA*, No.112, pp.1244-1241.
- Koch, G. & Poulsen, S. (2009). *Children with chronic health conditions: implications for oral health*. In: *Pediatric dentistry : a clinical approach* (M. L. Dadllof Göran (Ed.), pp.315-330). Wiley-Blackwell, 1-4051-6100-0, Chichester, UK ; Ames, Iowa
- Li, L. M.; Russo, M.; O'Donoghue, M. F.; Duncan, J. S. & Sander, J. W. (1996). *Allergic skin rash with lamotrigine and concomitant valproate therapy: evidence for an increased risk*. *Arquivos De Neuro-Psiquiatria*, Vol.54, No.1, pp.47-49.
- Loring, D. W. (1997). *Neuropsychological evaluation in epilepsy surgery*. *Epilepsia*, Vol.38 Suppl 4, pp.S18-23.
- Lundstrom, A.; Eegolofsson, O. & Hamp, S. E. (1982). *Effects of Anti-Epileptic Drug-Treatment with Carbamazepine or Phenytoin on the Oral State of Children and Adolescents*. *Journal Of Clinical Periodontology*, Vol.9, No.6, pp.482-488.
- Majola, M. P.; McFadyen, M. L.; Connolly, C.; Nair, Y. P.; Govender, M. & Laher, M. H. (2000). *Factors influencing phenytoin-induced gingival enlargement*. *Journal Of Clinical Periodontology*, Vol.27, No.7, pp.506-512.
- Mann, J.; Wolnerman, J. S.; Lavie, G.; Carlin, Y. & Garfunkel, A. A. (1984). *Periodontal treatment needs and oral hygiene for institutionalized individuals with handicapping conditions*. *Spec Care Dentist*, Vol.4, No.4, pp.173-176.

- Mattson, R. H. & Gidal, B. E. (2004). *Fractures, epilepsy, and antiepileptic drugs*. Epilepsy & Behavior: E&B, Vol.5 Suppl 2, pp.S36-40.
- McKhann, G. M., 2nd; Bourgeois, B. F. & Goodman, R. R. (2002). *Epilepsy surgery: indications, approaches, and results*. Seminars In Neurology, Vol.22, No.3, pp.269-278.
- Modeer, T.; Domeij, H.; Anduren, I.; Mustafa, M. & Brunius, G. (2000). *Effect of phenytoin on the production of interleukin-6 and interleukin-8 in human gingival fibroblasts*. Journal Of Oral Pathology & Medicine: Official Publication Of The International Association Of Oral Pathologists And The American Academy Of Oral Pathology, Vol.29, No.10, pp.491-499.
- Ogunbodede, E. O.; Adamolekun, B. & Akintomide, A. O. (1998). *Oral health and dental treatment needs in Nigerian patients with epilepsy*. Epilepsia, Vol.39, No.6, pp.590-594.
- Perlik, F.; Kolinova, M.; Zvarova, J. & Patzelova, V. (1995). *Phenytoin as a risk factor in gingival hyperplasia*. Therapeutic Drug Monitoring, Vol.17, No.5, pp.445-448.
- Pick, L. & Bauer, J. (2001). [Dentistry and epilepsy]. Der Nervenarzt, Vol.72, No.12, pp.946-949.
- Rao, A. (2008). Dental Management of Handicapped Children. In: *Principles and practice of pedodontics* (pp.348-350). Jaypee Brothers Medical Publishers, 8184483457, New Delhi.
- Robbins, M. R. (2009). *Dental management of special needs patients who have epilepsy*. Dental Clinics Of North America, Vol.53, No.2, pp.295-309, ix.
- Roger, J. (2005). Epileptic Syndromes, In: *Infancy, Childhood And Adolescence* (3 ed.), 0-86196-320-2, John Libbey Eurotext Ltd, 2005.
- Sasaki, T. & Maita, E. (1998). *Increased bFGF level in the serum of patients with phenytoin-induced gingival overgrowth*. Journal Of Clinical Periodontology, Vol.25, No.1, pp.42-47.
- Sato, Y.; Kondo, I.; Ishida, S.; Motooka, H.; Takayama, K.; Tomita, Y., et al. (2001). *Decreased bone mass and increased bone turnover with valproate therapy in adults with epilepsy*. Neurology, Vol.57, No.3, pp.445-449.
- Seymour, R. A.; Smith, D. G. & Turnbull, D. N. (1985). *The effects of phenytoin and sodium valproate on the periodontal health of adult epileptic patients*. Journal Of Clinical Periodontology, Vol.12, No.6, pp.413-419.
- Seymour, R. A. (1992). Selected side effects: 7. Phenytoin and gingival overgrowth. Prescr. J., No.32, pp.124-126.
- Sheller, B. (2004). *Orthodontic Management of Patients with Seizure Disorders*. Semin Orthod, Vol.10, pp.247-251.
- Stoopler, E. T.; Sollecito, T. P. & Greenberg, M. S. (2003). *Seizure disorders: update of medical and dental considerations*. General Dentistry, Vol.51, No.4, pp.361-366; quiz 367.
- Tan, H.; Gurbuz, T. & Dagsuyu, I. M. (2004). *Gingival enlargement in children treated with antiepileptics*. J Child Neurol, Vol.19, No.12, pp.958-963.
- Thomason, J. M.; Seymour, R. A. & Rawlins, M. D. (1992). *Incidence and severity of phenytoin-induced gingival overgrowth in epileptic patients in general medical practice*. Community Dentistry And Oral Epidemiology, Vol.20, No.5, pp.288-291.
- Turner, M. D. & Glickman, R. S. (2005). *Epilepsy in the oral and maxillofacial patient: current therapy*. J Oral Maxillofac Surg, Vol.63, No.7, pp.996-1005.



Novel Aspects on Epilepsy

Edited by Prof. Humberto Foyaca-Sibat

ISBN 978-953-307-678-2

Hard cover, 338 pages

Publisher InTech

Published online 12, October, 2011

Published in print edition October, 2011

This book covers novel aspects of epilepsy without ignoring its foundation and therefore, apart from the classic issues that cannot be missing in any book about epilepsy, we introduced novel aspects related with epilepsy and neurocysticercosis as a leading cause of epilepsy in developing countries. We are looking forward with confidence and pride in the vital role that this book has to play for a new vision and mission. Therefore, we introduce novel aspects of epilepsy related to its impact on reproductive functions, oral health and epilepsy secondary to tuberous sclerosis, mitochondrial disorders and lisosomal storage disorders.

How to reference

In order to correctly reference this scholarly work, feel free to copy and paste the following:

Taskin Gurbuz (2011). Epilepsy and Oral Health, Novel Aspects on Epilepsy, Prof. Humberto Foyaca-Sibat (Ed.), ISBN: 978-953-307-678-2, InTech, Available from: <http://www.intechopen.com/books/novel-aspects-on-epilepsy/epilepsy-and-oral-health>

INTECH
open science | open minds

InTech Europe

University Campus STeP Ri
Slavka Krautzeka 83/A
51000 Rijeka, Croatia
Phone: +385 (51) 770 447
Fax: +385 (51) 686 166
www.intechopen.com

InTech China

Unit 405, Office Block, Hotel Equatorial Shanghai
No.65, Yan An Road (West), Shanghai, 200040, China
中国上海市延安西路65号上海国际贵都大饭店办公楼405单元
Phone: +86-21-62489820
Fax: +86-21-62489821

© 2011 The Author(s). Licensee IntechOpen. This is an open access article distributed under the terms of the [Creative Commons Attribution 3.0 License](https://creativecommons.org/licenses/by/3.0/), which permits unrestricted use, distribution, and reproduction in any medium, provided the original work is properly cited.

IntechOpen

IntechOpen