

We are IntechOpen, the world's leading publisher of Open Access books Built by scientists, for scientists

6,900

Open access books available

186,000

International authors and editors

200M

Downloads

Our authors are among the

154

Countries delivered to

TOP 1%

most cited scientists

12.2%

Contributors from top 500 universities



WEB OF SCIENCE™

Selection of our books indexed in the Book Citation Index
in Web of Science™ Core Collection (BKCI)

Interested in publishing with us?
Contact book.department@intechopen.com

Numbers displayed above are based on latest data collected.
For more information visit www.intechopen.com



Causes and Prevention of Functional Disturbances Following Low Anterior Resection for Rectal Cancer

Eberhard Gross
*Asklepios Medical School Hamburg
 Germany*

1. Introduction

Surgical therapy of a colon carcinoma does not usually affect the patient's quality of life in the medium or long term, if the tumor does not involve adjacent organs and there are no post-operative complications. In rectal cancer, however, dysfunctions such as anal continence disorders occur in quite a few patients following anterior resection, and particularly low anterior resection (LAR) with total mesorectal excision (TME), as a result of the total or almost total loss of the rectum, and disorders of the bladder and sexual function can occur because the autonomic nerves, which regulate bladder and sexual function as well as anal continence, are often damaged due to their anatomical proximity. Not only have healing rates improved with the introduction and more general use of total mesorectal excision, the local recurrence rates have fallen below 10 %, in part below 5 %, with TME and neoadjuvant radiotherapy or radio chemotherapy, so that disorders which affect quality of life naturally take on more importance for the individual patient, especially if he has been healed, but are also considered to be increasingly important by the surgeon. In the past decade anal continence disturbance has become quantitatively more significant, since the majority of patients with a rectal tumor undergo anterior resection. Hence 70 - 90% of rectal tumors can currently be operated with sphincter-preserving surgery without violating oncological principles. Rectal cancer surgery thus aims both at preventing a local recurrence and at preserving anal continence and bladder and sexual function. The risk of injury to the autonomic nerves is naturally greater when the tumor is more advanced, when the surgery is more extensive and the cancer itself is closer to the autonomic nerves, as is the case when the tumor is localized in the lower or middle third of the ventral circumference of the rectum, so that bladder and sexual dysfunction occur most frequently in this tumor site or after abdomino-perineal excision (APE). Further risk factors for dysfunction are age, local postoperative complications and radio- or radio-chemotherapy, in particular adjuvant therapy.

If the appropriate surgical technique is applied, dysfunction can generally be avoided if the tumor is not so advanced that parts of the bladder, the prostate or the posterior vaginal wall and autonomic nerves also have to be resected. In such cases a preparation technique which causes no mechanical or thermal damage to the autonomic nerves is important.

With ever increasing knowledge of the complex function of anal continence and the causes of postoperative disorders, surgical techniques and post-operative measures have been

adopted which do not completely rule out continence disorders, but with which they can be largely avoided, or at least reduced, so that they do not significantly affect quality of life.

2. Anal continence disorders

2.1 Anterior resection syndrome, diagnostics

Anal continence is a complex function and is made possible by different continence factors with their specific anatomical and physiological substrates (Tab. 1), including the visceral and somatic muscles, the rectum with its reservoir function and the extremely sensitive anoderm, which is capable of discrimination. The continence organ is controlled neurologically at the local spinal and cerebral level. Continence is affected if one of the continence factors, such as discrimination is deficient or the compliance of the remaining rectum or the replacement rectum is deminished. Depending on the cause, anal continence dysfunction, in addition to incontinence in the true sense, can manifest itself in various ways, including in evacuation disorders. This clinical picture is now known as anterior resection syndrome and includes the following symptoms: repetitive imperative urge to defecate post defecation, increased stool frequency, shortened warning period, incomplete bowel movements, fragmented defecation, increased stool frequency due to errors in diet, decreased stool consistency, nocturnal bowel movements, no formed stool, the need for increased abdominal pressure, and incontinence of varying degrees of severity (Tab2 (156). Continence disorders can be objectified with the different continence scores, although the most common ones, such as the Cleveland Clinic Continence Score and the Fecal Index Severity Score (Tab.3), only cover incontinence as such. Scores which also ask about other symptoms, such as discrimination, help to determine both the severity of the incontinence and to localize the causes of the continence disorders or the anterior resection syndrome. A proctologic examination is obligatory for diagnosing continence disorders. Whether further examinations, such as anal sonography, defecation radiography or a dynamic MRT of the pelvis are necessary, will depend on whether the findings have therapeutic consequences.

rectal distension	stretching receptors in the pelvic floor musculature and (?) lateral pelvic wall
sensory discrimination	free ending nerve fibers und org.nerve cells in the anoderm und transitional zone
anal high pressure zone	internal sphincter (70-80%) external sphincter (20 %) hemorrhoids (15 %)
sampling	rectoanal inhibitory reflex
reservoir function	compliance: 4-14 ml/cm H ₂ O,sensory volume: 10-70 ml maximal tolerable volume: 300 ml
voluntary contraction) (squeeze)	external sphincter
Reflectory increase of anal pressure	puborectal reflex, muscle spindles in external sphincter

Table 1. Factors of continence and their anatomical und physiological substrates

Fragmentationof stool
Frequent bowel movement
Repetitive urge to defecate
Shortened warning period
Disturbed discrimination
Incontinence of various degree of severity
Incomplete evacuation
Nocturnal bowel movement
Decreased stool consistency
Frequent bowel movement due to error in diet
Need for abdominal pressure

Table 2. Symptoms of the anterior rectum resection syndrome

	2 or more times a day	Once a day	2 or more times a week	Once a week	1 or 3 times a month	never
gas	O	O	O	O	O	O
mucus	O	O	O	O	O	O
liquid stool	O	O	O	O	O	O
solid stool	O	O	O	O	O	O

Table 3. Fecal Incontinence Severity Index (FISI)

3. Causes of anterior resection syndrome

3.1 Diminished reservoir function

Retrospective studies show that more than half the patients with straight coloanal anastomosis (26,27,73,127,162,163) and about 30 to 50 % of patients with straight low colorectal anastomosis (12,14,106,107,137) suffer from continence disorders after low anterior resection. The inevitable extensive or complete loss of the rectum after LAR and TME results in reduced compliance and a decrease in maximal tolerable volume (MTV) and sensory volume (SV). The reservoir function of the remaining rectum or the rectal replacement can be quantified with these parameters. A post-operative reduction in these parameters could be measured in patients compared with pre-operatively (5,25,89,115,123,161), as well as in patients compared with healthy controls (25,39,154,158). Compliance is also influenced by the height of the anastomosis and the length of the rectal stump. Anastomotic leakages (44,115) with consecutive scarring of the wall of the replacement rectum or the remaining rectum and late radiation reactions following adjuvant radio chemotherapy with the formation of a rigid wall in the neorectum naturally also result in reduced compliance, and thus to deterioration in the reservoir function

3.2 Reduction in resting anal pressure (RP) due to stretching trauma

Many manometric studies before and after low anterior resection have shown a reduction in resting anal pressure up to one year post-operatively compared with pre-operatively, regardless of whether the reconstruction had been made with a colon pouch or with a straight coloanal or colorectal anastomosis (5,25,30,37,66,69,72,74,89,158,161). As might be

expected, these findings were also seen following intersphincteric resection (80,106,145). Several studies show that resting anal pressure in patients is significantly reduced for up to one year after surgery compared with healthy controls (161). Several studies have also shown that stretching trauma plays a significant role in reducing resting anal pressure: in a randomized (55) significantly reduced resting anal pressure was found after LAR with stapled anastomosis compared with the group with hand-sewn anastomosis from the abdomen according to HAR. The lesion on the internal sphincter caused by the stapler could also be verified endosonographically six months after the operation (38), and up to 2 years postoperatively (28). Intra-operative measurement of resting anal pressure at each step of the operation during a LAR, from the beginning of anesthesia through to anastomosis, showed that resting anal pressure levels decreased significantly only after stapler anastomosis (61). Intersphincteric resection is associated with considerable stretching trauma. Hence a significantly shorter functional length of anal canal was found measuring resting anal pressure in the group with intersphincteric resection compared with LAR with TME, LAR with PME and with HAR (53). With regard to the role of stretching trauma as the reason for reduced resting anal pressure, as expected no difference was found between patients with and without a pouch system (10,37,40), or between groups with different anastomotic heights (66,90,105).

3.3 Disorders of sphincter function due to lesions of the autonomic nervous system

The autonomic nerves at the pelvic plane of inlet and in the pelvis (Fig1.) can be damaged at various points in their course during anterior resection, particularly during LAR with TME. The inferior mesenteric plexus is formed at the level of the inferior mesenteric artery by taking up fibers from the sympathetic chain. After running the aorta the nerve fibers fuse at the level of the bifurcation and the promontory to the superior hypogastric plexus, a flat, plate-like structure, which branches below the promontory into the hypogastric nerves. These consist mainly of preganglionic sympathetic fibers from T8 to L2 and fuse with parasympathetic splanchnic nerves from S2 to S4, occasionally also from S5 (108) to the inferior hypogastric plexus. This is also a flat structure, which in women is more triangular with a posterior base. The plexus receives irregular afferents from the sacral sympathetic ganglia (108). It lies on the fascia pelvis parietalis interna and the pelvic wall. The postganglionic fibers then lead from the plexus in bundles of nerve fibers to the pelvic organs, the seminal vesicles and the prostate, the bladder and the anorectum and the internal sphincter. The cavernous nerve is formed periprostatic, passes through the pelvic floor and reaches the corpora cavernosa. Six nerve fiber bundles leading to the organs were identified in female corpses (109). Afferent fibers also lead from the pelvic organs into the inferior hypogastric plexus.

The external sphincter is supplied via the pudendal nerve, which is formed from the roots of S2 -S4, leaves the pelvis through the piriform foramen and, after emerging from the alcock's canal, runs along the outer side of the levator to the fascia pelvis parietalis externa. The pudendal nerve also consist of sensitive fibers. The levator muscle itself is supplied by the levator nerve, which are also formed from S2 to S4 and run under the fascia pelvis parietalis interna on the inside of the levator muscle. They also supply a portion of the external anal sphincter (150)

The aganglionic internal sphincter tone is generated by myogenic pacemakers, relaxation is regulated by nonadrenergic and noncholinergic fibers (NANC) which release NO ,VIP or

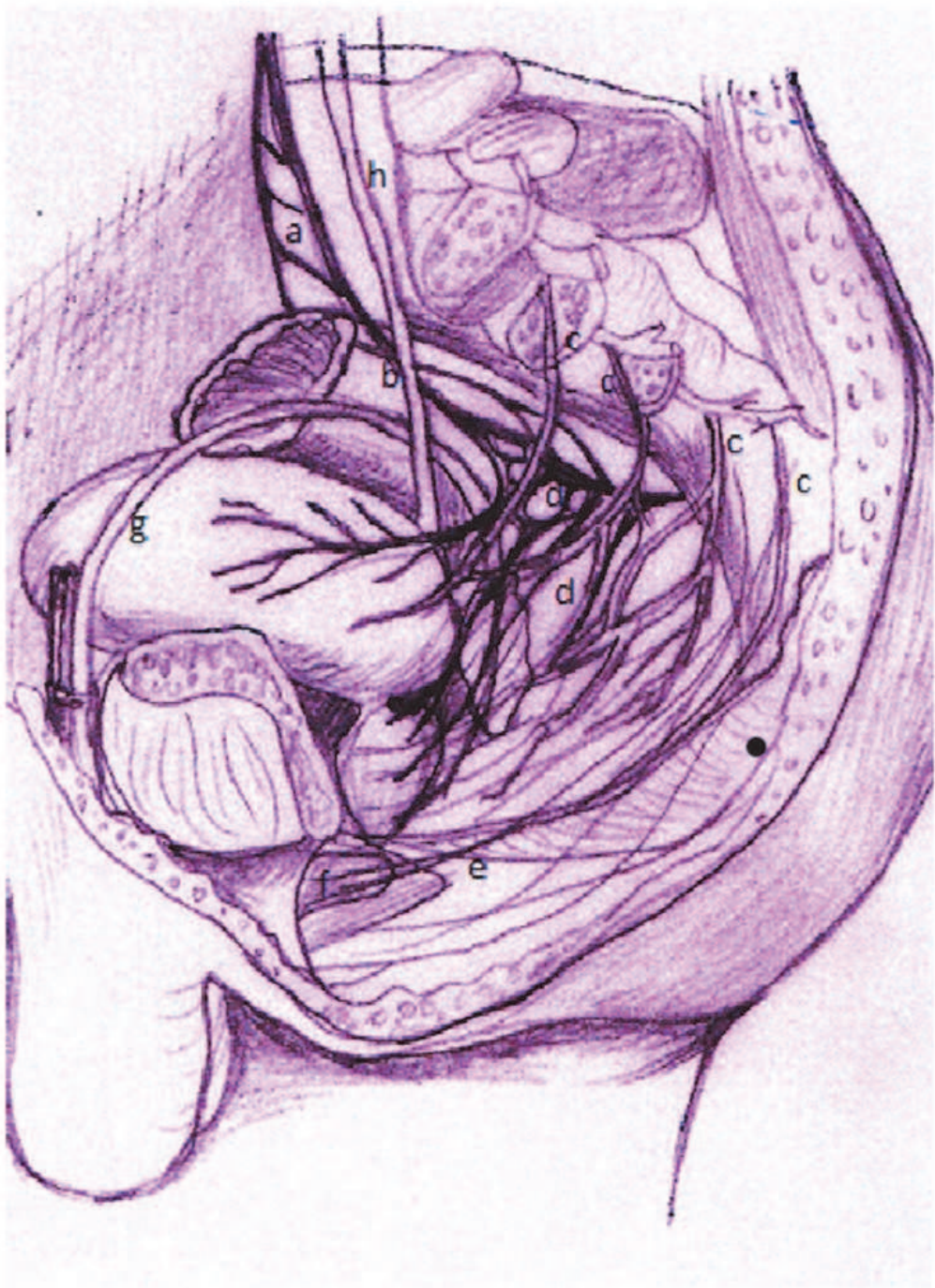


Fig. 1. Pelvic autonomic nerves left lateral aspect. a.superior hypogastric plexus b. splanchnic nerves (parasympathetic) c. hypogastric nerve d. inferior hypogastric plexus e. cavernous nerve f. corpora cavernosa g. deferens duct h. ureter

ATP (120). The internal sphincter is controlled by the intrinsic and extrinsic nervous systems with their sympathetic and parasympathetic fibers, whereby stimulation of the sympathicus has an excitatory effect. Hence it was possible to trigger a contraction of the internal sphincter by stimulating the hypogastric nerve electrically during rectal resection (19). Blocking the sympathicus with high spinal anesthesia led to a significant reduction in resting anal pressure compared with a parasympathetic blockade using low spinal

anesthesia (31). The activity of the internal sphincter is controlled predominantly by the alpha adrenergic mechanism, as has been shown in in vitro studies using preparations from different species and from humans (34,104), as well as in in vivo studies (4).

The pelvic floor and the external and internal sphincters (164)) are controlled by special motor neurons, the Onuf nucleus, which lies between the spinal cord segments S2 and S3, medial to the ganglion cells in the anterior horn.

Long-term studies of anal continence disorders in the Dutch rectal cancer study patient collective showed that 41.4 % suffered from anal continence disorders preoperatively and 48.7% five years after surgery, and that in 38.8% anal incontinence had newly developed as a result of the treatment. Risk factors were preoperative continence disorders and radiotherapy (159). The greatest risk of injury to the autonomic nerves is at the level of the so-called "rectal stalk" or "rectal pillar", where the splanchnic nerves which are attached to the inferior hypogastric plexus are found. The rectal stalk is formed when the mesorectum is detached dorsally. If these are not detached from the fascia recti they will be unavoidably severed. A further risk of injury occurs if the rectal stalk is stretched and detached from the inferior hypogastric plexus as a result of strong contralateral tension on the mesorectum. The risk for a nerve damage, particularly to cause an erectile dysfunction (ED) may be also very high if the Denonvilliers` fascia is resected. It lies posterior to the prostate and the seminal vesicles and anterior to the thin rectal fascia. The Denonvilliers` fascia in men is regularly a leathery membrane. Immediately to the anterior lateral border of the fascia nerves run to supply the corpora cavernosa and govern the erectile function. When the tumour involves the anterior rectal quadrant, the dissection should be conducted on the Denonvilliers fascia for oncological reason. Though the risk for a nerve damage is high with the special dissection technique these nerves can be preserved and the risk can be diminished. Damage may also be caused to the levator nerves (LAN) which supply the levator ani muscle (see above) and sometimes also parts of the external sphincter: The fascia recti and the endopelvic fascia fuse about 2- 3 cm cranially to the pelvic floor. The endopelvic fascia must be clearly severed in order to further detach the mesorectum, in order to reach the pelvic floor along which the LAN run.

Damage to the autonomic nerves during TME has been recently described as a cause of anal continence disorders (79). The sphincter function in patients where the autonomic nerves (AN) were completely preserved was significantly better than in patients where there was some damage. To date, scant attention has been paid to the connection between damage to the AN and anal continence disorders compared with disorders of the bladder and sexual function; since anal incontinence may be due to other factors, a connection can be more difficult to establish. According to electromyographic (78) and manometric investigations of the internal sphincter on animals (4,34,53) and on humans (19) during an anterior resection while the AN is subjected to electro-stimulation, it can be assumed that lesions on the AN play a not insignificant role as a cause of anal incontinence. This is also supported by findings such as spontaneous relaxation of the internal sphincter (140) and high amplitude pressure oscillations in the anal canal, with a spontaneous marked drop in incontinent patients following coloanal reconstruction (46) and ileoanal pouch procedure (153).

3.4 Low anastomosis

Many studies show that the height of the anastomosis affects continence (105,111,116,141). High rates of incontinence have been described both for an anastomosis height below 6 cm (73) and below 4 cm (89,90,127), and after pouch anal anastomosis compared with pouch

rectal anastomosis. According to Lewis (91), the height of anastomosis and the anal resting anal pressure are the continence-determining parameters. As with the influence of compliance on continence and the connection between compliance and remaining rectum, there is also a connection between the height of anastomosis and continence disorders. The fact that preservation of the distal rectum generally results in better continence, although it is only about 3 - 4 cm in length, is probably due to the particularly dense covering of rectospinal afferents, as has been seen in animals (117)

3.5 Disorders of the rectoanal inhibitory reflex

The rectoanal inhibitory reflex is important for fine continence based on the discrimination. Transient stretching of the rectum causes relaxation of the internal sphincter which triggers an involuntary decrease in resting anal pressure, whereby the amplitude and duration of relaxation until basal resting anal pressure is reached depend on the volume by which the rectum is distended. Bowel contents enter the upper anal canal while the rectum is filling as a result of this reflex, and can be perceived in the highly sensitive transitional zone and the upper anoderm. The reflex is communicated via the intrinsic nervous system, and is not triggered in patients with Hirschsprung disease as a result of the dysfunction of the intrinsic innervation. The reflex can also not be triggered initially after LAR (61,66,128), but is restored within a period of one year after the operation (25,26,83,89,121,124,141). In our own study the reflex was seen only in 40 % of patients at the first follow-up examination, and in 75 % six months later (26). An animal study has shown that restitution of the reflex is due to nerve growth which bridges the anastomosis (62).

3.6 Continence disorders following intersphincteric resection (ISR)

The entire rectum is resected during intersphincteric resection, including the mesorectum-free cloacogenic segment, to which a special sensory function is attributed (117,149). Different-sized portions of the internal sphincter are also removed during this process. In principle the ISR can also be performed from the pelvis. In our peranal approach the anoderm or the mucosa is incised circularly with the internal sphincter. After closing the rectum with a pursestring suture on the margin of the mucosa and internal sphincter to avoid contamination, the actual dissection is performed in the intersphincteric plane to the level of the dissection in the pelvis. The intersphincteric resection is usually associated with poorer continence performance than LAR with colorectal anastomosis (9,12,13,14,53). In addition to the loss of the cloacogenic segment and the transitional zone with its sensory function, including the hemorrhoids with their contribution to continence, more frequent incontinence is due to the partial loss of the internal sphincter and to the greater stretching trauma involved in peranal access compared with stapler anastomosis.

3.7 Continence disorders and manometric findings

According to several studies, altered anorectal manometry parameters were detected in patients with continence disorders following LAR: a significant reduction in anal resting pressure in incontinent patients compared with continent patients (91,110,137) and an inverse correlation between functional anal canal length and stool frequency (57,) or degree of incontinence (53), significantly lower values of the volumetric parameters MTV, SV and of compliance in incontinent patients compared with continent patients (26,91,105,137), and

a loss of the des recto-inhibitory reflex (26,64) or greater distension pressure to trigger the reflex (110). Saigusa(141) ascertained a deficient reflex in patients with nocturnal incontinence and an ileoanal pouch.

4. Restoration with colon pouch to improve continence

4.1 Colon J pouch (CJP)

Building on successful experience with the ileoanal pouch in familial adenomatous polyposis and ulcerative colitis following proctocolectomy, the colonic J pouch was introduced by Lazorthes and Parc (26,125)

The clinical results and manometric data have been compared with straight colorectal and coloanal anastomosis in controlled studies, including numerous randomized trials (29,33,41,54,56,63,88,100,122,123,143,146). According to a meta-analysis (49), the CJP has unique advantages compared with straight coloanal anastomosis: Bowel movement was significantly less up to 2 years after surgery, significantly fewer patients suffered from an imperative urge to defecate up to one year post-operatively and significantly fewer patients had to take antidiarrheals. According to the recent Cochrane review (15) in two out of six studies, or in two out of seven which examined the continence score, significantly fewer incontinent patients were found in the early post-operative phase (< 8 months post-operative) or in a period up to 18 months. In numerous controlled studies volumetric parameters of reservoir function, such as MTV, SV and compliance, were examined. In 13 out of 16 studies a significantly higher MTV was measured in the pouch group compared with the group without a pouch (5,32,43,52,54,64,69,82,86,102,118,122,123,160,162). In most studies the patients were examined one year post-operatively. In a randomized trial comparing 5cm and 10 cm long pouches, a significantly lower MTV was established with the smaller pouch, so that it can be assumed that the MTV is dependent on pouch volume (50). In 11 out of 12 controlled studies (5,40,43,52,54,64,49,102,143,160,162), compliance was higher in the pouch group than in the group with straight colorectal or coloanal anastomosis, in 9 studies significantly so. In 8 studies (32,50,64,82,88,123,160,162) SV was lower in the group without pouch, the majority significantly so compared with the pouch group. The studies on volumetric parameters confirm the better reservoir function of the pouch compared with straight coloanal or colorectal anastomosis.

4.2 Coloplasty v colon J pouch

The transverse coloplasty (165) consists of a plastic extension of the colon lumen about 4 cm proximal to the resection margin and similar to a pyloroplasty. It is easier to make and can be located in the pelvic floor even when there is a lot of fatty tissue in the mesocolon. In randomized studies (29,33,58,131 comparing coloplasty with the colon J pouch, no difference was found in the frequency of bowel movement in the early post-operative phase up to eight months, and the same result was seen in three studies up to 18 and 24 months respectively after surgery. In one of the studies (58) an advantage was seen with the colon J pouch with regard to imperative urge to defecate up to eight months post-operatively, however not after a longer period (29,33,131). In the studies the continence scores and use of antidiarrheals did not differ in the early post-operative period (29,33,58,131), nor in two studies covering a longer period after surgery (29,33,131). In a meta-analysis no differences were found in the SF or in the manometric and volumetric parameters (93).

4.3 Side to end anastomosis v colon J pouch

In 3 randomized studies side to end anastomosis was compared with the colon J pouch. One study showed a significantly lower SF in the colon J pouch group in the early phase after the operation (60), in two studies SF was the same in the period up to 18 months post-operatively and longer. In three studies no difference was found between the two methods with regard to imperative urge to defecate and continence score in the early post-operative phase (60,67,100), or in the medium and long term in two studies (67,101)

4.4 Von Flüe pouch

The interposition of an ileo ascending segment is more complex than the other pouch procedures and is not routine, especially as no advantages in terms of function could be shown in a randomized study compared with the CJP. It is an alternative procedure when the descending colon is missing, where the blood supply does not permit anastomosis with the left colon, or a left side nephrectomy has been performed, resulting in pronounced adhesions of the mesocolon transversum and descending colon

4.5 Clinical long-term results

90 % the 102 patients with a colon J pouch were continent in a study with a medium-term follow-up of 2.6 years (3). In a controlled study (10) comparing coloanal anastomosis and the colon J pouch no difference was found in the SF after a mean follow-up period of 10 years.

One study with a follow up period of 5 years showed a significantly less SF and imperative urge to defecate in the pouch group compared with straight colorectal anastomosis (52). In a retrospective study (45) with a follow-up of 5 years, imperative urge to defecate was less frequent in the pouch group compared with patients without a pouch. In a controlled study with a follow-up period of at least 3 years, the patients with a pouch showed significantly better results regarding SF, taking antidiarrheals and dietary restrictions (24).

5. Evacuation disorders

Evacuation disorders manifest with various symptoms: as a sensation of incomplete evacuation, as prolonged defecation time, fragmented stools, use of laxative suppositories or enemas. The first symptom is the one most frequently mentioned, as did 79% of patients after LAR with and without pouch (156). There are many reasons for evacuation disorders, and different factors may aggravate the problem.

5.1 Length of pouch

One reason for impaired evacuation following construction of a colon J-pouch is that the pouch is too long. Evacuation disturbances were observed in up to 60 % of patients when the colon J pouch was first introduced into clinical practice (11,43,54,113,125,130), and this increased the more time passed after the operation (88)

The evacuation disorders were attributed to an overlong pouch, since such disorders occurred in particularly high numbers when the pouch was longer than 8 cm (11,41,113,125,130). Randomized trials with different lengths of pouch then showed a tendency to, or a significantly higher rate of evacuation disorders when the pouch was 10 cm long (30,87). Large pouches also have a tendency to dilate. In addition secondary changes which resulted in outlet obstruction, such as rectocele (51) and angulations have been described. In animal experiments

it was not possible to pharmacologically stimulate the large pouch with cerelutid (142). In view of these studies, a pouch length of 5 - 6 cm is currently recommended.

5.2 Other reasons for evacuation disorders

Evacuation disorders also occur with a pouch length of 5 - 6 cm, as well as in patients without a pouch, so that the hypothesis that evacuation disorders are a side effect of the pouch, and particularly of the colon J-pouch, is not borne out. According to a meta-analysis (139), evacuation dysfunction also occurs after straight coloanal or colorectal anastomosis (SCA) and transverse colectomy (TCP), which have indeed been recommended just in order to avoid this. According to one of the meta-analyses (139) evacuation disorders such as sensation of incomplete evacuation and fragmentation occur in the early post-operative phase in the SCA group more frequently than in patients with colon J-pouch. In the mid and long-term post-operative phase, 14.8 % and 7.7 % of patients with colon J-pouch suffer much less from either complaint than patients without pouch (29.5 % and 28.9 %). If randomized studies only are considered, significantly fewer patients suffered from prolonged defecation time. When compared with the colon J-pouch, the typical disorders do not occur less often with TCP and Side to end anastomosis in the early and medium term in the post-operative period. However, fragmentation is a problem in TCP when compared with the colon J-pouch.

The fact that evacuation dysfunction can occur as frequently after straight coloanal anastomosis as it can with a pouch shows that the reconstruction procedure is only one of several factors which cause these disorders. Damage to the internal sphincter and the autonomic nerves and interruption to the intrinsic nervous system also play a part.

6. Anastomotic leaks with a pouch and with straight coloanal anastomosis (SCA)

According to the recent the Cochrane review (15) anastomotic leaks do not occur more frequently after SCA than with the colon J-pouch and according to a recent meta-analysis which includes six randomized studies (93), there is no difference in leakage rate between the colon J-pouch and the TCP. Leakage rate in side to end anastomosis does not differ with the CLP.

7. Voiding disorders after LAR

The consequences of damage to the autonomic nerves which supply the bladder are well known from the process of lateral lymph node dissection in low advanced rectal cancer, which is sometimes performed in Japan. Extensive bilateral resection of the inferior hypogastric plexus leads to a neurogenic bladder in 78 % of patients in the third post-operative week, in 58% of patients spontaneous voluntary evacuation was not restored after 2 months (59). After unilateral resection the majority of patients can urinate spontaneously again only after 2 months. (59,99). Vesicourethral dysfunction occurs after LAR and APE in the early post-operative phase in 30 -70 % of patients if the autonomic nerves are not specifically preserved or cannot be correctly identified in an effort to preserve the nerves (1,76,77) Obstructive disorders after surgery attract more attention as they have to be treated acutely, although continence disorders are also common. A retrospective study (166) showed an increase of 19 % in imperative need to urinate post-operatively compared with 4% pre-operatively, from 9% to 26 % in pollakiuria and from 46.4% to 63% in nocturia, from

1.8% to 7.6 % in stress incontinence grade 2 and from 0.7% to 5.8 % in grade 3, complete incontinence. If they are not preexistent and if the autonomic nerves are not damaged bilaterally obstructive disorders are transient. According to a prospective study (151), 24 % of patients suffered from a voiding dysfunction which required treatment until the 14th day post-operatively, and only 8 % after two months.

7.1 Evaluating vesicourethral function

The IPSS covers 7 symptoms (75). The score allows a semi-quantitative assessment of the dysfunction. However, the IPSS should be augmented by a survey on urge incontinence and stress incontinence. The additional determination of residual urine volume is diagnostically meaningful in assessing dysfunction.

7.2 Physiology and innervation of the bladder

The external voluntary urethral sphincter is controlled by the pudendal nerve. The pudendal nerve also contains afferents which pass on bladder filling and wall tension. The smooth-musled internal sphincter is contracted during the storage phase of the bladder. This muscle is controlled by the N. sympathicus. During the storage phase, the smooth-musled detrusor is also inhibited by the N. sympathicus. When the bladder is emptying the external and internal sphincters relax, while the detrusor, which is subject to parasympathetic innervation, contracts. The storage phase is regulated by the spinal urine storage reflex: Contraction of the internal sphincter increases as the bladder becomes fuller. Micturition is initiated via the pontine micturation reflex: The increasing filling of the bladder activates the pontine micturation center which is responsible for inhibiting the urine storage reflex, resulting in activation of the detrusor and relaxation of the internal sphincter. The urethra-bladder reflex – during micturation the flow of urine affects detrusor contraction – serves to ensure the bladder is completely emptied.

7.3 Voiding dysfunction (VD) in preserving autonomic nerve procedure (PANP)

The fact that bladder dysfunction is caused by injury to the autonomic nerves has been established in a prospective study (70): where the autonomic nerves were completely identified during the LAR only 5.6 % of patients developed a VD compared with 38.5 % when identification was not possible. The connection between preservation of the nerves and preservation of bladder function could be demonstrated by intra-operative neuro-monitoring (77). In patients with an positive test regarding an adequate increase in bladder pressure, the IPSS items weak stream, incomplete emptying and frequency of micturition varied significantly from those with negative test result.

According to various studies, if the autonomic nerves are identified the VD rate can be expected to fall significantly to between 0 and 23 %, whereby generally rates of about 10 % and lower are given and some of the patients had a pre-existing VD (2,6,35,46,70,75,77,99,114,133). Risk factors for VD are pre-existing disorders, tumor size over 5 cm (75), deep-seated tumor and APE (155,157), blood loss (84), age > 65 years (155).

8. Sexual dysfunction

Sexual dysfunction occurs in 10 - 80 % of men after surgery for rectal cancer (8,21,22,27,36,47,60,151,157,167). When evaluating post-operative sexual function, the not

infrequent pre-existing disorders and non-somatic causes must first be identified. Post-operative sexual dysfunction is predominantly caused by nerve lesions. A lesion of the hypogastric nerve or the superior hypogastric plexus (SHP) causes retrograde ejaculation. A lesion of the parasympathetic fibers (n. erigentes) causes erectile dysfunction (ED). The extent of nerve injury correlates with the degree of dysfunction. 76% of patients suffered from severe ED after ilio-pelvic lymphadenectomy (59); 48% (103) and 61 % (152) of patients experienced ED where the autonomic nerve was preserved unilaterally, and 70 % when the lesion was more extensive. The incidence is particularly high in APE because damage to the nerves is difficult to avoid in this case due to the proximity of the nerves, which supply the corpora cavernosa. It has been recognized as a risk factor in several studies (46,47,114,155). Advanced tumors, prior surgery in the pelvis (70,147) and age > 60 years (75) have been described as further risk factors. In contrast to voiding dysfunction, sexual dysfunction is normally permanent. As with voiding dysfunction, the rate of sexual dysfunction can be clearly reduced – to between 5 and 33 %, if the autonomic nerves are identified: (6,46,75,77,99,114,147).

8.1 Dissection techniques and outcome

During dissection it is important on the one hand to identify the autonomic nerves (AN), and on the other to avoid lesions as a result of the technique applied. Of the different procedures, such as dissection with monopolar or bipolar current, with ultrasonic instruments, the so-called bloody dissection with scissors or with a capillary high-pressure water jet (hydrojet) (Fig2), the latter two do not cause thermal lesions. According to the few studies in which the rate of identification of the AN has been examined, hydrojet dissection is the technique with which the nerves can always be represented (6,35), whereas the success rate is less successful with other techniques. Although the hypogastric nerves can almost always be identified with every technique, this is not the case with the splanchnic nerves, the IHP or the nerve fibers which emanate from them. 72 % of the AN (70) and 51 % (114) of the N. erigentes could be identified using the conventional technique. However, the success rate can be significantly improved with neuro-monitoring (23,77)

The only controlled study, a matched pair analysis also showed hydrojet dissection to be superior to the conventional technique with regard to complete loss of function (7.1% v 42.9%) as well as to the IIEF-5 (International Index of erectile function) (13.5 v 7.2), (6). However, the proportion of our own patients with ED, 26.1 % when the IIEF - 5 score was not taken into account, did not differ from the other studies (75,77,99,114,147)

8.2 Sexual dysfunction after laparoscopic surgery

The results with regard to sexual function after laparoscopic surgery for rectal cancer in men are contradictory. In the controlled studies, an advantage for the laparoscopic operation with an ED of 5 % (laparoscopic) v 29 % (open) (7) has been established, as well as a disadvantage with 41% (laparoscopic) compared with 4.5 % (open) (136). In the Classic trial (65) there was a trend to a higher rate of ED after the laparoscopic operation. After laparoscopic proctocolectomy with ileoanal pouch (85), a significantly higher rate of orgasm dysfunction was found in men compared with open surgery. In two further studies (119,148) no difference could be established between open and laparoscopic surgery. In the non-controlled studies, the rates of complete functional failure and of ED are not insignificant at 23% (144), 21.9% (92) and 31.1% (112). In the two first studies (92,144) an ED was found in 41 % and 15.9 % respectively. In a further study (68) based on extensive

experience in laparoscopic colorectal surgery, only 6 % ED was reported. The different results may be due to different dissection techniques, which were not described. For instance ultrasonic instruments and dissection using monopolar or bipolar current can cause thermal lesions. These techniques are used laparoscopically.

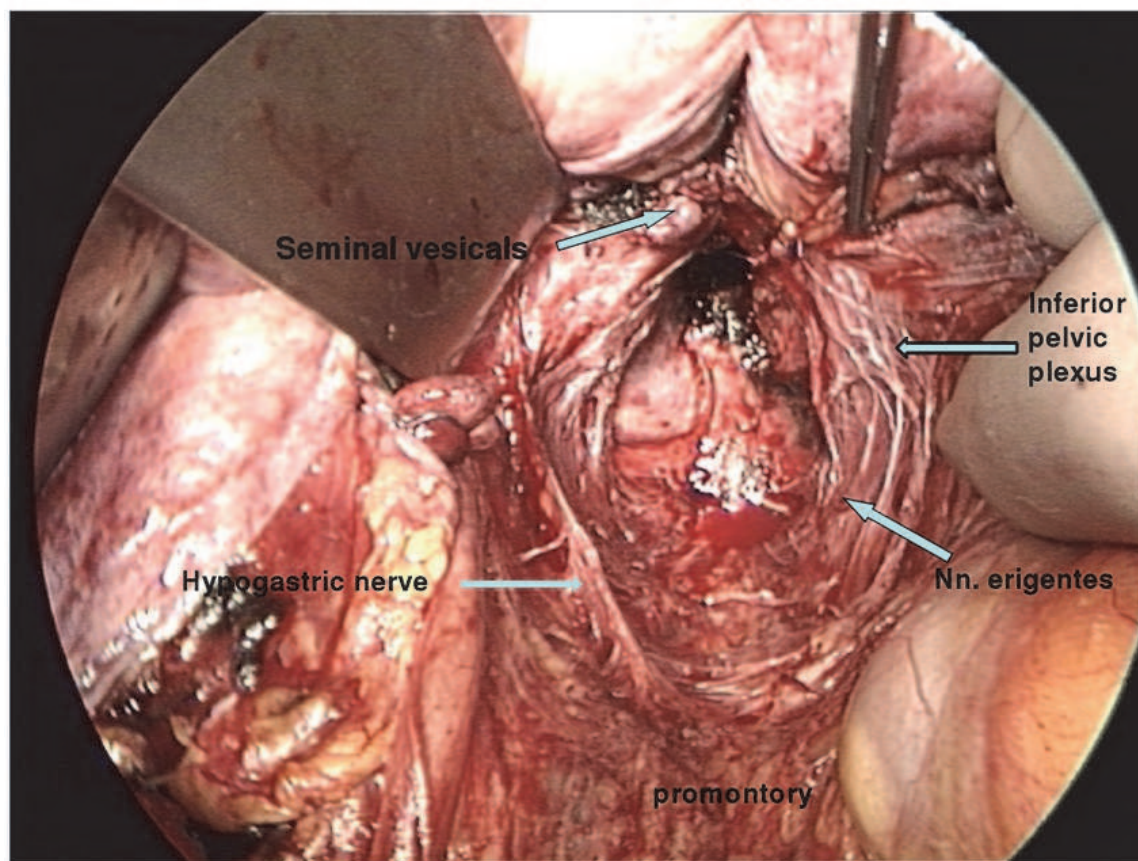


Fig. 2. Pelvic autonomic nerve identified by hydrojet dissection .View from the head of the patient. The rectum is removed.

9. Anastomotic leakage and anal continence

An anastomotic fistula always leaves scarring after healing. The extent of scarring depends on the size of the abscess, and may also cause symptomatic stenosis. As two studies have shown, these changes usually also result in decreased anal continence: patients with anastomotic leakage suffered more than patients without leakage from increased stool frequency, imperative urge to defecate and evacuation problems (44,115). A correspondingly lower compliance of the neorectum in this patient group was also measured. Not only clinically apparent leakages, but also inapparent ones can affect continence (95).

10. Adjuvant and neoadjuvant radio- and radio-chemotherapy and dysfunction

Neoadjuvant radio- and radio-chemotherapy and adjuvant radio-chemotherapy are risk factors for anal continence disorders, whereby post-operative treatment naturally presents the greater risk, because, in contrast to pre-operative therapy, a late radiation reaction can

always occur in the neorectum. Several trials established significantly worse continence in patients who underwent adjuvant radiotherapy compared with patients without radiotherapy (81,97). Poorer continence manifested itself as more frequent bowel movement, more frequent urge and soiling. Both neorectal compliance and capacity were significantly diminished in patients who underwent adjuvant radio-chemotherapy. In a non-controlled study (98) 39% had poor continence after a mean follow-up time of 10 years. Several studies also found significantly worse continence after neoadjuvant radiotherapy and radio-chemotherapy compared with patients who had not been pre-treated (18,126,129,134). In two non-controlled studies (20,135) only 14 % and 25% of patients had normal continence. Radio-chemotherapy on its own can trigger anal dysfunction, regardless of surgery (94).

As with anal dysfunction, both neoadjuvant radiotherapy and radio-chemotherapy and adjuvant radio-chemotherapy are risk factors for sexual dysfunction: Male patients who underwent adjuvant radio-chemotherapy showed a significant deterioration in sexual function eight months after treatment (48). In the Norwegian cancer register a significant deterioration in sexual function was also seen 4.5 years after treatment in male patients who underwent adjuvant radio-chemotherapy or neoadjuvant radiotherapy (17) compared with patients who did not undergo such therapy. After neoadjuvant radio-chemotherapy sexual function in men was significantly worse compared with patients who did not receive neoadjuvant treatment (126,135,167). In contrast, in women sexual function is not affected to the same extent by radiation therapy (16,126,132).

Low anterior resection is the operation of choice in rectal cancer and is always possible without violating oncological principles if the sphincter is not tumor-involved. If the circumferential margin is not affected the autonomic nerves can be identified in TME using suitable dissection techniques, such as hydrojet dissection or sharp dissection, and thus preserved. The risk of thermal lesions to the nerves is always present when ultrasonic instruments are used, or in dissection with mono- or bipolar current. This is probably the reason why some higher rates of sexual dysfunction have been observed in laparoscopic LAR and TME. Damage to nerves not only causes sexual dysfunction, which is generally persistent, but also vesicourethral dysfunction, which is only permanent if the nerve lesions are extensive. Damage to the pelvic autonomic nerves and to the N. levator also contribute to disorders of anal continence. Stretching trauma to the anal sphincter is unavoidable if a perianal anastomosis is performed, particularly during inter-sphincteral resection. Stretching trauma caused by the circular stapler or by the double stapling technique can be avoided by using the inverse technique, in which the pressure plate is introduced anally and the stapler in the open limb of the colon J-pouch, or side to end anastomosis. The open limb is then closed with a linear stapler. It is not possible to use the inverse technique in coloplasty. Continence is significantly improved with the construction of a pouch. The different types of pouch, including side to end anastomosis, are all comparable in regard to continence and complication rates.

Anastomosis complications involve poor continence. It follows from this that a protective ileostomy or colostomy should be a routine in TME in order to avoid the clinical consequences of a leakage, and hence a long-term disturbance in anal function. Although the side-effects of radiotherapy have been largely reduced as a result of new techniques, the risk of anal continence dysfunction, which is not inconsiderable with adjuvant therapy, remains. Neoadjuvant therapy should always be preferred over adjuvant therapy because of

the lesser risk. Radiotherapy, whether adjuvant or neoadjuvant, frequently causes sexual dysfunction in men. The general indication of neoadjuvant radio-chemotherapy in patients with infiltration of the mesorectum (T3) is probably excessive (71) if the circumferential resection margin is not affected and an exact TME is performed. Over-treatment can be avoided with an MRT-based indication for neoadjuvant radio-chemotherapy.

11. References

- [1] Aagaard J, Thomas C, Gerstenberg TC, Knudsen JJT. Urodynamic investigation predicts bladder dysfunction at an early stage after abdominoperineal resection of the rectum for cancer. *Surgery* 1986; 90: 564-568
- [2] Ameda K, Kakizaki H, Koyangi T, Hirakawa K, Kusumi T, Hosokawa M. The long-term voiding function and sexual function after pelvic nerve-sparing radical surgery for rectal cancer. *Int J Urol* 2005;12:256-63
- [3] Amin AI, Hallböök O, Lee AJ, Sexton R, Moran BJ, Heald RJ. A 5 cm J pouch coloanal reconstruction following anterior resection for low rectal cancer results in acceptable evacuation and continence in the long term. *Colorectal Dis* 2003;5:33-37
- [4] Andersen IS, Buntzen S, Rijkhoff NJ, Dalmose AL, Djurhuus JC, Laurberg S. Anorectal motility responses to pelvic hypogastric and pudendal nerve stimulation in the Göttingen minipig. *Neurogastroenterol Motil* 2006;18:153-161
- [5] Araki Y, Isomoto H, Tsuzi J, Matsumoto A, Yasunaga M, Yamauchi K, Hayashi K, Kodama T. Functional results of colonic j-pouch anastomosis for rectal cancer. *Surg Today* 1999 ;29:597-600
- [6] Arndt A. Urogenitale Dysfunktionen nach Rektumresektion mit TME unter Anwendung der Nerven schonenden Wasserstrahldissektion. Dissertation 2010 ; Universitätskrankenhaus Eppendorf Hamburg
- [7] Asoglu O, Matlim T, Karanlik H, Atar M, Muslumanoglu M, Kapran Y; Igci A, Ömen V, Kecer M, Parlak M. Impact of laparoscopic surgery on bladder and sexual function after total mesorectal excision for rectal cancer. *Surg Endosc* 2009;23:296-302
- [8] Balsev I. , Harling H. Sexual dysfunction following operation for carcinoma of the rectum. *Dis Colon Rectum* 1983; 26: 785-788
- [9] Barisic G, Markovic V, Popovic M, Dimitrijevic I, Gavrilovic P, Krivokapic Z. Function after intersphincteric resection for low rectal cancer and its influence on quality of life. *Colorectal Dis* 2011;13:638-641
- [10] Barrier A, Martel P, Gallot D, Dugue L, Sezeur A, Malfosse M. Long-term functional results of colonic j pouch versus straight coloanal anastomosis. *Br J Surg* 1999;86:1179-1186
- [11] Berger A, Tiret E, Parc R, Frileux P, Hannoun L, Nordlinger B, Ratelle R, Simon R. Excision of the rectum with colonic j pouch-anal anastomosis for adenocarcinoma of the low and midrectum. *World J Surg* 1992;16:470-477
- [12] Bernoist S, Panis Y, Boleslawski E, Hautefeuille P, Valleur P. Functional outcome after coloanal versus low colorectal anastomosis for rectal carcinoma *J Am Coll Surg* 1997;185:114-119

- [13] Bittdorf B, Stadelmeier U, Gohl J, Hohenberger W, Matzel KE. Functional outcome after intersphincteric resection of the rectum with coloanal anastomosis in low rectal cancer. *Eur J Surg Oncol* 2004 ;30:260-265
- [14] Bretagnol F, Rullier E, Laurent C, Zerbib F, Gontier R, Saric J. Comparison of functional results and quality of life between intersphincteric resection and conventional coloanal anastomosis for rectal cancer. *Dis Colon Rectum* 2004;47: 832-838
- [15] Brown CJ, Fenech D, McLeod RS. Reconstructive techniques after rectal resection for rectal cancer *The Cochrane Library* 2009 issue 4.
- [16] Bruheim K, Tveit KM, Skovlund E, Balteskard L, Carlsen E, Fossa SD, Guren MG. Sexual function in females after radiotherapy for rectal cancer. *Acta Oncol* 2010, 49:826-832
- [17] Bruheim K, Guren MG, Dahl AA, Skovlund E, Balteskard L, Carlsen E, Fossa SD, Tveit KM. Sexual function in males after radiotherapy for rectal cancer. *Int J Radiat Oncol Biol Phys* 2010 ;76:1012-1027
- [18] Canda AE, Terzi C, Gorken IB, Oztup I, Sokmen S, Fuzun M. Effects of preoperative chemoradiotherapy on anal sphincter functions and quality of life in rectal cancer patients. *Int J Colorectal Dis* 2010;25:197-204
- [19] Carlstedt A, Nordgren S, Fasth S, Appelgren L, Hulten L. Sympathetic nervous influence on the internal anal sphincter and rectum in man. *Int Colorectal Dis* 1988 ;3:90-95
- [20] Coco C, Valentini V, Manno A, Rizzo G, Gambacorta MA, Mattana C, Verbo A, Picciocchi A. Functional results after radiochemotherapy and total mesorectal excision for rectal cancer. *Int J Colorectal Dis* 2007;22:903-910
- [21] Cunsolo A, Bragaglia RB, Manara G, Poggioli G, Gozzetti G. Urogenital dysfunction after abdominoperineal resection for carcinoma of the rectum. *Dis Colon Rectum* 1990; 33: 918-922
- [22] Danzi M, Ferulano GP, Abate S, Califano G. Male sexual function after abdominoperineal resection for rectal cancer. *Dis Colon Rectum* 1983; 26: 665-668
- [23] Da Silva GM, Zmora O, Börjesson L, Mizhari N, Daniel N, Khnándwala F, Efron J, Weiss EG, Nogueras JJ, Vernava AM, Wexner SD. The efficacy of a nerve stimulator (Cavermap) to enhance autonomic nerve identification and confirm nerve preservation during total mesorectal excision. *Dis Colon Rectum* 2005;47:2032-2038
- [24] Dehni N, Schlegel D, Tiret E, Singland JD, Giguët M, Parc R. Effects of aging on the functional outcome of coloanal anastomosis with colonic j-pouch. *Am J Surg* 1998;175:209-212
- [25] van Duijvendijk P, Slors F, Taat C, Heisterkamp SH, Obertop H, Boeckxstaens GEE. A prospective evaluation of anorectal function after total mesorectal excision in patients with a rectal carcinoma. *Surgery* 2003;133:56-65
- [26] Eigler FW, Gross E. Kontinenzleistung nach totaler und subtotaler Rektumresektion mit perianaler Anastomosierung. In *Postoperative Fagezustände* S. 399, (ed). R. Häring Überreuter Verlag Wien 1988
- [27] Enker WE, Stearns MW, Janov AJ. Perianal coloanal anastomosis following low anterior resection for rectal cancer. *Dis Colon Rectum* 1985; 28:576-581

- [28] Farouk R, Duthie GS, Lee PW, Monson JR. Endosonographic evidence of injury to the internal anal sphincter after low anterior resection: long-term follow up. *Dis Colon Rectum* 1998;41:888-891
- [29] Fazio VW, Zutshi M, Remzi F, Parc Y, Ruppert R, Fürst A, Celebrezze J, Galanduk S, Orangio G, Hyman N, Bokey L, Tietze M, Kirchdorfer B, Medich D, Tietze M, Hull T, Hammel J. A randomized multicentre trial to compare long-term functional outcome, quality of life and complications of surgical procedures for low rectal cancer. *Ann Surg* 2007;246:481-490
- [30] Flühe v. d MO, Degen LP, Beglinger C, Hellwig AC, Rothenbühler JM, Harder FH. Ileocecal reconstruction with physiologic function after total mesorectal cancer excision. *Ann Surg* 1996;224:204-212
- [31] Frenckner B, Ihre T. Influence of autonomic nerves on the internal anal sphincter in man. *Gut* 1976;17:306 - 312
- [32] Fürst A, Burghofer K, Hutzler J, Jauch KW. Neorectal reservoir is not the functional principle of the colonic j-pouch: the volume of a short colonic j-pouch does not differ from a straight coloanal anastomosis. *Dis Colon Rectum* 2002;45:660-667
- [33] Fürst A, Suttner S, Ayman A, Beham A, Jauch KW. Colonic j-pouch vs coloplasty following resection of distal rectal cancer *Dis Colon Rectum* 2003;46:1161-1166
- [34] Garrett JR, Howard ER, Jones W. The internal sphincter in cat: a study of nervous mechanism affecting tone and reflex activity. *J Physiol* 1974;243. 153-166
- [35] Geers P, Moesta KT; Yildirim C, Thon WF, Köckerling F. Urodynamic outcome of waterjet-assisted total mesorectal excision. *Br J Surg* 2007;94:1543-1547
- [36] Gerstenberg TC, Nielsen ML, Clausen S, Blaabjerg J, Lindenberg J. Bladder function after abdominoperineal resection of the rectum for anorectal cancer. Urodynamic investigation before and after operation in a consecutive series. *Ann Surg* 1980; 191: 81-86
- [37] Götzinger P, Wamser P, Herbst F. Coloanale Anastomose :Verbesserung der funktionellen Frühergebnisse durch Rekonstruktion mit Colonpouch. *Chirurg* 2001 ;72:49-53
- [38] Gosselink MP, West RL, Kuipers EJ, Hansen BE, Schouten WR. Integrity of the anal sphincters after pouch-anal anastomosis: evaluation with the three-dimensional endoanal ultrasonography. *Dis Colon Rectum* 2005 ;48:1728-35
- [39] Gross E, Beersiek F, Eigler FW. Sphinkterfunktion nach perianalen Anastomosen. *Langenbecks Arch Surg* 1980;353:207-216
- [40] Gross E, Amir-Kabirian H. Koloanaler Pouch nach totaler Rektumresektion. *Zentralbl Chir*; 1994;119:878-885
- [41] Hallböök O, Pahlmann L, Krog M, Wexner St, Sjö Dahl R. Randomized comparison of straight and colonic j-pouch anastomosis after low anterior resection. *Ann Surg* 1996;224:58-65
- [42] Hallböök O, Nyström P-O, Sjö Dahl R. Physiological characteristics of straight and colonic j-pouch anastomosis after rectal excision for cancer. *Dis Colon Rectum* 1997;40:332-338
- [43] Hallböök O, Sjö Dahl R. Comparison between the colonic j -pouch-anal anastomosis and healthy rectum: clinical and physiological function. *Br J Surg* 1997; 84:1437-1441

- [44] Hallböök O, Sjö Dahl R. Anastomotic leakage and functional outcome after anterior resection of the rectum *Br J Surg* 1996 ;83:60-62
- [45] Harris GJC, Lavery IC, Fazio VW. Function of colonic pouch continues to improve with time. *Br J Surg* 2001;88:1623-1627
- [46] Havenga K, Enker WE, McDermott K, Cohen AM, Minsky BD, Guillem J. Male and female sexual and urinary function after total mesorectal excision with autonomic nerve preservation for carcinoma of the rectum. *J Am Coll Surg* 1996; 182: 495-502
- [47] Hendren SK, O'Connor BI, Liu M, Asano T, Cohen Z, Swallow CJ, Mc Rae HM, Gryfe R, McLeod R. Prevalence of male and female sexual dysfunctions high following surgery for rectal cancer. *Ann Surg* 2005;242:212-223
- [48] Heriot A G, Tekkis PP, Fazio VW, Neary P, Lavery JC. Adjuvant radiotherapy is associated with increased sexual dysfunction in male patients undergoing resection for rectal cancer. *Ann Surg* 2005;242:502 -511
- [49] Heriot A G, Tekkis PP, Constantinidis V, Paraskevas P, Nicholls R J, Darzi A, Fazio V. Meta-analysis of colonic reservoirs versus straight coloanal anastomosis after anterior resection. *Br J Surg* 2006;93:19-32
- [50] Hida J, Yatsunami M, Fujimoto K, et al. Functional outcome after low anterior resection with low anastomosis for rectal cancer using the colonic j-pouch: prospective randomized study for determination of optimum pouch size. *Dis Colon Rectum* 1996;39:986-981
- [51] Hida J, Yasutomi M, Maruyama T, Yoshifuji T, Tokoro T, wakano T, Uchida T, Ueda K. Detection of a rectocele-like prolapse in the colonic-j pouch using pouchography: cause or effect of evacuation difficulties. *Surg Today* 1999;29:1237-1242
- [52] Hida J, Yoshifuji T, Tokoro T, Inoue K, MatzuzakibT, Okuno K, Shiozaki H, Yasutomi M. Comparison of long-term functional results of colonic j-pouch and straight anastomosis after low anterior resection for rectal cancer. A five year follow- up, *Dis Colon Rectum* 2004;47:1578-1585
- [53] Hirano A, Koda K, Kosugi C, Yamazaki M, Yasuda H. Damage to the anal sphincter/levator ani muscles caused by operative procedure sphincter-preserving operation for rectal cancer. *Am J surg* 2011;201:508-513
- [54] Ho YH, Tan M, Seow -Cheon F. Prospective randomized trial controlled study of clinical function and anorectal physiology after low anterior resection : comparison of straight and colonic j pouch anastomosis. *Br J Surg* 1996;83:978-980
- [55] Ho YH, Tan M, Leong A, Eu, KW, Nyram D, Seow-Cheon F. Anal pressures impaired by stapler insertion during colorectal anastomosis. *Dis Colon Rectum* 1999;42:89-95
- [56] Ho YH, Seow-Choen F, Tan M. Colonic j-pouch function at six months versus straight coloanal anastomosis at two years :randomized controlled trial. *World J Surg* 2001 ;26:876-81
- [57] Ho YH, Tan, M, Leong AFPK, Seow-Choen F. Ambulatory manometry inpatients with colon-J pouch and straight coloanal anastomosis. *Dis Colon Rectum* 2000;43:793-799
- [58] Ho YH, Brown S, Heah SM, Tsang C, Seow Chon. Comparison of j-pouch and coloplasty pouch for low rectal cancer : an randomized, controlled trial

- investigating functional results and comparative anastomotic leak rates. *Ann Surg* 2002;236:49-55
- [59] Hojo K, Sawada T, Morya Y. An analysis of survival and voiding, sexual function after wide iliopelvic lymphadenectomy in patients with carcinoma of the rectum compared with conventional lymphadenectomy. *Dis Colon Rectum* 1989;32:128-133
- [60] Hojo K, Vernava AM III, Sugihara K, Katumata K. Preservation of urine voiding and sexual function after rectal cancer surgery. *Dis Colon Rectum* 1991; 34: 532-53
- [61] Horgan PG, O'Connell PR, Shinkwin CA, Kirwan WO. Effect of anterior resection on anal sphincter function *Br J Surg* 1989;76:783-786
- [62] Horgan AF, Molloy RG, Cpulter J, Sheehan M, Kirwan WO. Nerve regeneration across colorectal anastomoses after low anterior resection in a canine model. *Int J Colorectal Dis* 1993;8:167 -169
- [63] Huber FT, Herter B, Siewert JR. Colonic pouch vs side -to -end anastomosis in low anterior resection. *Dis Colon Rectum* 1999 ;42:896-902
- [64] Ikeuchi H, Kusunoki M, Shoji Y, Yamamura T, Utsonomiya J. Functional results after high coloanal anastomosis and "low" coloanal anastomosis with a colonic j-pouch for rectal carcinoma. *Surg Today* 1997;27:702-705
- [65] Jayne DG, Brown JM, Thorpe H, Walker J. Quirke P, Guillou PJ, Bladder and sexual function following resection for rectal cancer in a randomized clinical trial of laparoscopic versus open technique. *Br J Surg* 2005; 92:1124-1132
- [66] Jehle EC, Haehnel T, Starlinger MJ, Becker HD. Level of anastomosis does not influence functional outcome after anterior resection for rectal cancer. *Am J Surg* 1995;169:147-153
- [67] Jiang L-K, Yang S-H, Lin J-K. Transabdominal anastomosis after low anterior resection :a prospective randomized, controlled trial comparing long term results between side- to-end anastomosis and colonic j- pouch. *Dis Colon Rectum* 2005;48:2100-2110
- [68] Jones OM, Stevenson AR, Stitz RW, Lumley JW. Preservation of sexual and bladder function after laparoscopic rectal surgery. *Colorectal Dis* 2009;11:489-495
- [69] Joo JS, Latulippe JF, Alabaz O Weiss EG, Nogueras JJ, Wexner SD. Long-term functional evaluation of straight coloanal anastomosis and colonic j-pouch :is functional superiority of colonic j-pouch sustained? *Dis Colon Rectum* 1998;41:740-741
- [70] Junginger T, Kneist W, Heintz A,. influence of identification and preservation of pelvic autonomic nerves in rectal cancer surgery on bladder dysfunction after total mesorectal excision. *Dis Colon Rectum* 2003;46:621-628
- [71] JungingerT, Hermanek P, Oberholzer K, Schmidberger H. Rectal carcinoma:Is too much neoadjuvant therapy performed? Proposals for a more selective MRI based indication. *Zentralbl Chir* 2006, 1311:275-231
- [72] Kakodkar R, Gupta S, Nundy S. Low anterior resection with total mesorectal excision for rectal cancer : functional assessment and factors affecting outcome. *Colorectal Dis* 2006;8:650-656
- [73] Karania ND, Schache DJ, Heald RJ. Function of the distal rectum after low anterior resection for carcinoma. *Br J Surg* 1992;79:114-116

- [74] Kienle P, Stern J, Herfarth Ch. Restaurative Proktrektomie. Vergleich direkter coloanaler und colonpouchanaler Anastomosen zur Kontinuitätswiederherstellun. Chirurg 1997;68:630-63
- [75] Kim NK, Aahn TW, Park JK, Lee KY, Lee WH, Sohn SK, Min JS. Assessment of sexual and voiding function after total mesorectal excision with pelvic autonomic nerve preservation in males with rectal cancer. Dis Colon Rectum 2002; 45: 1178-1185
- [76] Kinn AC, Ohman U. Bladder and sexual function after surgery for rectal cancer. Dis Colon Rectum 1986;29:43-48
- [77] Kneist W, Junginger T. Male urogenital function after confirmed nerve sparing total mesorectal excision with dissection in front of Denonvillier's fascia. World J Surg 2007;31:1321-1328
- [78] Kneist W, Knauff D W, Roman K, Rahimi N, Rink AD, Heimann A, Somerlik K, Koch KP, Doerge T, Lang H. Intraoperative pelvic nerve stimulation performed under continous electromyography of the internal anal sphincter. Int J Colorectal Dis 2010;25:1325-1331
- [79] Kneist W, Kuhn E, Berger S, Knabe J, Ekkert B, Junginger T. Kontinenz nach Chirurgie des Rektumkarzinoms – Bedeutung des Nervenerhaltes und Wertigkeit der intraoperativen Neurostimulation:in Deutsche Kontinenz Gesellschaft(eds). Inkontinenz –eine soziale Herausforderung. Stuttgart Thieme 2006 p71
- [80] Köhler A, Athanasiadis S, Ommer A, Psarakis E. Long-term results of low anterior resection with intersphincteric anastomosis in carcinoma of the lower third of the rectum:analysis of 31 patients. Dis Colon Rectum 2000 ;43:843-850
- [81] Kollmorgen CF, Meagher AP, Wolff BG, Pemberton JH, Martenson JA, Ilstrup DM. The long-term effect of adjuvant postoperative chemoradiotherapy for rectal carcinoma on bowel function. Ann Surg 1994;220:576-682
- [82] Kusunoki M, Shoji Y, Yanagi H, Hatada T, Fujita S, Sakanoue T, Yamamura T, Utsunomiya J. Function after anoabdominal rectal resection and colonic J pouch-anal anastomosis. Br J Surg 1991 ;78:1434 -1438
- [83] Lane RH, Parks AG. Function of the anal sphincters following colo-anal anastomosis. Br J Surg 1977; 64:596-599
- [84] Lange MM, Maas CP, Marijnen CA, Wiggers T, Rutten HJ, Kranenberg EK, van der Welde CJ, Cooperative clinical investigation of the dutch total mesorectal trial. Urinary function after rectal cancer treatment is mainly caused by surgery. Br J Surg 2008;95:1020-1028
- [85] Larson DW, Davies MM, Dozois EF, Cima RR, Piotrowicz K, Anderson K, Barnes SA, Harmsen WS, Young-Fadok TM, Wolff BG, PembertonJH. Sexual function, body image and quality of life after laparoscopic and open pouch –anal anastomosis Dis Colon Rectum 2008;51:392-396
- [86] Lazorthes F, Fages P, Chiotasso P, et al : Resection of the rectum with construction of a colonic reservoir and coloanal anastomosis for carcinoma of the rectum. Br J Surg 1986;73:136-38
- [87] Lazorthes F, Gamagami R, Chiotasso P, et al. Prospective radomized study comparing clinical results between small and large colonic j-pouch following coloanal anastomosis. Dis Colon Rectum 1997;40:1409- 1413

- [88] Lazorthes F, Chiotasso P, Gamagami RA, Istvan G, Chevreau P. Late clinical outcome in a randomized prospective comparison of colonic j-pouch and straight coloanal anastomosis. *Br J Surg* 1997;84:1449-1451
- [89] Lee SJ, Park YS. Serial evaluation of anorectal function following low anterior resection of the rectum. *Int J Colorectal Dis* 1998;13:241-246
- [90] Lewis WG, Holdsworth PJ, Stephenson BM, Finan PJ, Johnston D. Role of the rectum in the physiological and clinical results of coloanal and colorectal anastomosis after anterior resection for rectal carcinoma *Br J Surg* 1992;79:1082 -1088
- [91] Lewis WG, Martin IG, Williamson ME et al. Why do some patients experience poor functional results after anterior resection of the rectum for carcinoma. *Dis Colon Rectum* 1995;38:259-263
- [92] Liang JT, Hong SL, Lee PH. Laparoscopic pelvic autonomic nerve-preserving surgery for patients with lower rectal cancer after chemoradiation therapy. *Ann Surg Oncol* 2007;14:1285-1287
- [93] Liao C, Cao F, Cao Y, Tan A, Li X, Wu D. Meta-analysis of the colo-J pouch vs transversoplasty pouch after anterior resection for rectal cancer. *Colorectal Dis* 2010, 12:624-631
- [94] Lim Jf, Tiandra JJ, Hiscock R, Chao MW, Gibbs P. Preoperative chemoradiation for rectal cancer causes prolonged pudendal nerve terminal motor latency. *Dis Colon Rectum* 2006;49:12 -19
- [95] Lim M, Akhtar S, Sasapu K, Keith H, Burke d, Sagar P, Finan P. Clinical and subclinical leaks after low colorectal anastomosis:a clinical and radiological study. *Dis Colon Rectum* 2006;49:1611-1619
- [96] Lubowski DZ, Nicholls RJ, Swash M, Jordan MJ. Neural control of internal anal sphincter function. *Br J Surg* 1987 ;74:668-670
- [97] Lundby L, Krogh K, Jensen VJ, Gandrup P, Qvist N, Overgaard J, Laurberg S. Long-term anorectal dysfunction after postoperative radiotherapy for rectal cancer. *Dis Colon Rectum* 2005;48:1343-1349
- [98] Lupatelli M, Mascioni F, Bellavita R, Draghini L, Tarducci R, Castagnoli P, Russo G, Aristei C. Long term anorectal function after preoperative chemoradiotherapy in high -risk rectal cancer patients. *Tumori* 2010; 96:34-41
- [99] Maas CP, Moriya Y, Steup WH, Kiebert GM, Kranenberg WMK, van de Velde CJH. Radical and nerve-preserving surgery for rectal cancer in the Netherlands: a prospective study on morbidity and functional outcome. *Br J Surg* 1998; 85: 92-97.
- [100] Machado M, Nygren J, Goldman S, Ljungqvist O. Similar outcome after colonic j - pouch and side-to -end anastomosis in low anterior resection for rectal cancer:a prospective randomized trial. *Ann Surg* 2003;238:214-220
- [101] Machado M, Nygren J, GoldmannS, Ljungqvist O. Functional and physiologic assessment of the colonic reservoir or side-to end anastomosis after low anterior resection for rectal cancer: a two year follow up. *Dis Colon Rectum* 2005;48:29-36
- [102] Manthayh CR, Hull TL, Fazio VW. Coloplasty in low colorectal anastomosis :manometric and functional comparison with straight and colonic j pouch anastomosis. *Dis Colon Rectum*, 2001;44:37-42

- [103] Masui H, Ike H, Yamaguchi S, Oki S, Shimada H. Male sexual function after autonomic nerve-preserving operation for rectal cancer. *Dis Colon Rectum* 1996; 39: 1140-1145
- [104] Matsufuji H, Yokoyama J. Neural control of the internal anal sphincter motility. *J Smooth Muscle Res* 2003;39:11 -20
- [105] Matzel KE, Stadelmeier U, Muehldorfer S, Hohenberger W. Continence after colorectal reconstruction following resection: impact of level of anastomosis. *Int J Colorectal Dis* 1997;12:82-87
- [106] Matzel, KE, Bittendorf B, Günther K, Stadelmaier U, Hohenberger W. Rectal resection with low anastomosis: functional outcome. *Colorectal Disease* 2003 ;5:458-464
- [107] Mc Anena OJ, Heald RJ, Lockhart-Mummery HE. Operative and functional results of total rectal excision with ultra-low anterior resection in the management of carcinoma of the lower one third of the rectum. *Surg Gyn Obstet* 1990;170:517-521
- [108] Mauroy B, Demondion X, Bizet B, Claret A, Mestdagh P, Hurt C. The female inferior hypogastric (pelvic) plexus: anatomical and radiological description of the plexus and its afferences – applications to pelvic surgery. *Surg Radiol Anat* 2007;29:55-66
- [109] Mauroy B, Demondion X, Drizenko A, Goullet E, Bonnal J. -I, Biserte J, Abbou C. The inferior hypogastric plexus (pelvic plexus): its importance in neural preservation techniques. *Surg Radiol Anat* 2003;25: 6-15
- [110] Miller AS, Lewis WG, Williamson ME et al. Factors that influence functional outcome after coloanal anastomosis for carcinoma of the rectum. *Br J Surg* 1995;82:1327-1330
- [111] Montesani C, Pronio A, Santella S, Boschetto A, Aguzzi D, Pirozzi R, D'Amato A, Vestri A. Rectal cancer surgery with sphincter preservation: functional results related to the level of anastomosis. Clinical and instrumental study. *Hepatogastroenterology* 2004;51:718-721
- [112] Morino M, Parini U, Allaix ME, Monasterolo G, Contul RB, Garrone C. Male sexual and urinary function after laparoscopic total mesorectal excision. *Surg Endosc* 2009;23:1233-1240
- [113] Mortensen NJ, Ramirez JM, Takeuchi N, Humphreys MM: Colonic j pouch -anal anastomosis after rectal excision for carcinoma: functional outcome. *Br J Surg* 1995;82:611-613
- [114] Nesbakken, A, Nygaard K, Bull-Njaa T, Carlsen E, Eri LM. Bladder and sexual dysfunction after mesorectal excision for rectal cancer. *Br J Surg* 2000; 87: 206-210
- [115] Nesbakken A, Nygaard K, Linde OC. Outcome and late functional results after anastomotic leakage following mesorectal excision for rectal cancer. *Br J Surg* 2001;88:400-404
- [116] Nesbakken A, Nygard K, Lunde O. Mesorectal excision for rectal cancer :functional outcome after low anterior resection and colorectal anastomosis without reservoir. *Colorectal Dis* 2002 ;4:172-176
- [117] Neuhuber WL, Appelt M, Pollak JM. Rectospinal neurons. *Neuroscience* 1993;56:367-378
- [118] Nicholls RJ, Lubowski DZ, Donaldson DR. , Comparison of colonic reservoir and straight coloanal reconstruction after rectal excision. *Br J Surg* 1988;75:318-320


- [119] Nitori N, Hasegawa H, Ishij Y, Endo T, Kitajima M, Ktagawa Y. Sexual function in men with rectal and rectosigmoid cancer after laparoscopic and open surgery. *Hepatogastroenterology* 2008;55:1304-1307
- [120] O'Kelly T J, Davies J R, Brarding A F. Distribution of nitroxid synthase containing neurons in the rectal myenteric plexus and anal canal. *Dis Colon Rectum* 1994;37:350
- [121] O'Riordan MG, Molloy RG, Gillen P, Horgan A, Kirwan WO. Rectoanal reflex following low stapled anterior resection of the rectum. *Dis Colon Rectum* 1992;35:874-878
- [122] Ortiz H, De Miguel M, Armendariz P, Rodriguez J, Chocarro C. Coloanal anastomosis: Are functional results better with a pouch ? *Dis Colon Rectum* 1995;38:375-377
- [123] Oya M, Komatsu J, Tkase Y, Nakamura T, Ishikawa H: Comparison of defacatory function after colonic-j pouch anastomosis and straight anastomosis for stapled low anterior resection: results of a prospective randomized trial. *Surg Today* 2002;32:104-110
- [124] Pappalardo G, Toccaceli S, Dionisio P, Castrinis G, Ravo B. Preoperative and postoperative evaluation by manometric study of the anal sphincter after coloanal anastomosis for carcinoma. *Dis Colon Rectum* 1988;31:119-122
- [125] Parc R, Tiret E, Frileux P, et al. Resection and coloanal anastomosis with colonic reservoir for rectal carcinoma. *Br J Surg* 1986;73:139-141
- [126] Parc Y, Zutshi M, Zalinski S, ruppert R, Fürst A, Fazio VW. Preoperative radiotherapy is associated with worse functional results after coloanal anastomosis for rectal cancer. *Dis Colon rectum* 2009;52:2004-2015
- [127] Parks AG, Pecz JP. Rectal carcinoma ;restorative resection using a sutured colo-anal anastomosis. *Int Surg* 1983;68:7-11
- [128] Pedersen IK, Hint K, Olsen J. Christiansen J, Jensen P, Mortensen PE. Anorectal function after low anterior resection for carcinoma. *Ann Surg* 1986;204:133-135
- [129] Peeters KCMJ, van de welde CJH, Leer JWH, Mrtijn H, Junggebur JMC, Klein E, Kranenberg WH, Steup WH, Wiggers T, Rutten HJ, Marijnen CAM. late bsideeffects of short course preoperative radiotherapy combined with total mesorectal excision for rectal cancer. Increased bowel dysfunction in irradiated patients. - a dutch colorectal cancer group study. *J Clin Oncol* 2005;23:6199-6206
- [130] Pelissier EP Blum D, Bachour A, Bosset JF. Functional results of coloanal anastomosis with reservoir. *Dis Colon Rectum* 1992;35:843-846
- [131] Pimentel JM, Duarte A, Gregorio C, Souto P, Patricio J. Transverse coloplasty pouch and colonic j-pouch for rectal cancer: a comparative study. *Colorectal Dis* 2003;5:465-470
- [132] Platell CF, Thompson PJ, Makin GB. Sexual health in women following pelvic surgery for rectal cancer. *Br J Surg* 2004;91:465-468
- [133] Pocard M, Zinzindohone F, Haab F, Caplin S, Parc R, Tiret E. A prospective study of sexual and urinary function after total mesorectal excision with autonomic nerves preservation for rectal cancer. *Surgery* 2002; 131: 368-372

- [134] Pollack J, Holm T, Cedermark B, Altman D, Holmström B, Glimelius B, Mellgren A. Late adverse effect of short –course preoperative radiotherapy in rectal cancer. *Br J Surg* 2006;93:1519-1525
- [135] Puciarelli S, Del Bianco P, Efficace F, Serpentine S, Capirci C, De Paoli A, Amato A, Cuicchi D, Nitti D. Patient – reported outcomes after neoadjuvant chemoradiotherapy for rectal cancer. A multicentre prospective observational study. *Ann Surg* 2011; 253:71-77
- [136] Quah HM, Jayne DG, Eu KW, Seow-Choen F. Bladder and sexual dysfunction following laparoscopically assisted and conventional open mesorectal resection for cancer. *Br J Surg* 2002; 89: 1551-1556
- [137] Rasmussen OO, Petersen IK, Christiansen J: Anorectal function following low anterior resection. *Colorectal Dis* 2003;5:258-261
- [138] Rink AD, Haaf F, Knupper N, Vestweber KH. Prospective randomized trial comparing ileocaecal interposition and colon j-pouch as rectal replacement after total mesorectal excision. *Int J Colorectal Dis* 2007;22:153-60
- [139] Rink AD, Sgourakis G, Sotiropoulos GC, Lang H, Vestweber KH. The colon J-pouch as a cause of evacuation disorders after rectal resection: myth or fact. *Langenbecks Arch Surg* 2009;394:79-91
- [140] Romanos J, Stebbing JF, Humphreys MM et al. Ambulatory manometric examination in patients with colonic j-pouch and in normal controls. *Br J Surg* 1996;83:1744-1746
- [141] Saigusa N, Belin BM, Choi HJ, Efron JE, Weiss EG, Nogueras JJ, Wexner SD. Recovery of the rectoanal inhibitory reflex after restorative proctocolectomy : does it correlate with nocturnal continence? *Dis Colon Rectum* 2003 ;46:168-172
- [142] Sailer M, Debus ES, Fuchs KH, Fein M, Beyerlein J, Thiede A. Comparison of different J-pouches vs straight and side-to- end coloanal anastomoses: experimental study in pigs. *Dis Colon Rectum* 1999;42:590-595.
- [143] Sailer M, Fuchs KH, Fein M, Thiede A. Randomized clinical trial comparing quality of life after straight and pouch coloanal reconstruction. *Br J Surg* 2002;89:1108-1117
- [144] Sartori CA, Sartori A, Vigna S, Occhipinti R, Biaocchi GL. Urinary and sexual disorders after laparoscopic TME for rectal cancer. *J Gastrointest Surg* 2011;15:637-643
- [145] Schiessl R, Karner -Hanusch J, Herbst F, Teleky B, Wunderlich M. Intersphincteric resection for low rectal tumors *Br J Surg* 1994;81:1376-1378
- [146] Seow-Choen F, Goh HS. Prospective randomized trial comparing pouch anal anastomosis and straight coloanal reconstruction. *Br J Surg* 1995 ;82:608- 610
- [147] Shirouzu K, Ogata Y, Araki Y. Oncologic and functional results of total mesorectal excision and autonomic nerve-preserving operation for advanced lower rectal cancer. *Dis Colon Rectum* 2004;47:1442-1447
- [148] Stamopoulos P, Theodoropoulos GE, Papailiou J, Savidis D, Golemati C, Bramis K, Panoussopoulos SCE. Prospective evaluation of sexual function after open and laparoscopic surgery for rectal cancer. *Surg Endosc* 2009;May 23 epub

- [149] Stelzner F, Biersack H, von Mallek D. Unteres, kloakogenes Rektumviertel. Anatomie und chirurgische Bedeutung für Mastdarmvorfall, Inkontinenz, Rektozele und Radikaloperation beim Rektumkarzinom. *Chirurg* 2006;77:273-280
- [150] Stelzner F. Die Nervenversorgung des anorektalen Kontinenzorgans In: Chirurgie an viszeralen Abschlußsystemen. Thieme Verlag Stuttgart 1998 pp. 131
- [151] Sterk P, Shekarritz B, Günter S, Nolde J, Keller R, Bruch HP, Shekarritz H. Voiding and sexual dysfunction after deep rectal resection and total mesorectal excision. *Int J Colorectal Dis* 2005;20:223 – 227
- [152] Sugihara K, Morya Y, Fujita S. Pelvic autonomic nerve preservation for patients with rectal carcinoma: oncological and functional outcome. *Cancer* 1996 ;78:1871-1880
- [153] Sun WM, Read NW, Katsinelos P, Donnelly TC, Shorthaus AJ. Anorectal function after restorative proctocolectomy and low anterior resection with coloanal anastomosis. *Br J Surg* 1994;81:280-284
- [154] Suzuki H, Matsumoto K, Amano S, Fujioka M, Honzumi M. Anorectal pressure and rectal compliance after low anterior resection. *Br J Surg* 1980;67:655-657
- [155] Tekkis PP, Cornish JA, ; Remzi FH, Tilney HS, Strong SA, Church JM, Lavery IC, Fazio VW. Measuring sexual and urinary outcomes in women after rectal cancer excision. *Dis Colon rectum* 2009;52:46 -54.
- [156] Temple LK, Bacik J, Savatta SG, Gottesman L, Paty PB, Weiser MR, Guillem JG, Minsky BD, Kalman M, Thaler HT, Schrag D, Wong WD. The development of a validated instrument to evaluate bowel function after sphincter-preserving surgery for rectal cancer. *Dis Colon Rectum* 2005;48:1353-1365
- [157] Varpe P, Huhtinen H, Rantala A, Salminen P, Rautava P, Hurme S, Grönroos J. Quality of life after surgery for rectal cancer with special reference to pelvic floor dysfunction. *Colorectal Dis* 2011;13. 399-405
- [158] Vassilakis JS, Pechlivanides G, Vrachasotakis N, Chrysos E, Tzovaras G, Xynos E. Anorectal function after low anterior resection of the rectum. *Int J Colorectal Dis* 1993;10:101-106
- [159] Wallner C, Lange MM, Bonsing BA, Maas CP, Wallace CN, Dabohoiwla NF, Rutten HJ, Lamers WH; De Ruiter MC, van de Welde CJH. Causes of fecal and urinary incontinence after total mesorectal excision for rectal cancer based on cadaveric surgery: study from the cooperative clinical investigators of the dutch total mesorectal excision trial. *J Clin Oncol* 2008;26. 4466-4472
- [160] Wang JW, You YT; Chen HH, Chiang JM, Yeh CY, Tang R. Stapled colonic j-pouch anal anastomosis without diverting colostomy for rectal carcinoma. *Dis Colon Rectum* 1997;40:30-34
- [161] Williamson ME, Lewis WG, Finan PJ, Miller AS, Holdsworth PJ, Johnston D. Recovery of physiologic and clinical function after low anterior resection of the rectum for carcinoma: myth or reality? *Dis Colon Rectum* 1995;38:411-418
- [162] Willis S, Kasperk R, Braun J, Schumpelick V. Comparison of colonic j-pouch reconstruction and straight coloanal anastomosis after intersphincteric rectal resection. *Langenbecks Arch Surg* 2001;386:193- 199
- [163] Wunderlich M, Teleki B, Schiessel R. Sphincter function following coloanal anastomosis. *Langenbecks Arch Chir* 1986;367:259-269

- [164] Yamamoto G, Satoni H, Ise H. Sacral spinal innervation of the rectal and vesical smooth muscles and sphincter striated muscles. *Neuroscience* 1978;7:41 -47
- [165] Z`graggen K, Maurer CA, Birrer S, Giachino D, Kern B, Büchler MW. A new surgical concept for rectal replacement after low anterior resection :the transverse colooplasty pouch. *Ann Surg* 2001; 234:780-787
- [166] Zugor V, Miskovic I, Matzel K, Hohenberger W, Neuhuber W, Labanaris A, Schott GE. Harnblasenentleer ungsstörungen nach Rektumoperationen. *Chirurg* 2010;81;56-60
- [167] Zugor V, Miskovic I, Lausen B, Matzel K, Hohenberger W, Schreiber M,, Labanaris A, Neuhuber W Witt J, Schott GE. Sexual dysfunction after rectal surgery :a retrospective study of men without disease recurrence. *J Sex Med* 2010;7:3199-31205

IntechOpen



Rectal Cancer - A Multidisciplinary Approach to Management

Edited by Dr. Giulio A. Santoro

ISBN 978-953-307-758-1

Hard cover, 410 pages

Publisher InTech

Published online 10, October, 2011

Published in print edition October, 2011

Dramatic improvements in medicine over the last few years have resulted in more reliable and accessible diagnostics and treatment of rectal cancer. Given the complex physiopathology of this tumor, the approach should not be limited to a single specialty but should involve a number of specialties (surgery, gastroenterology, radiology, biology, oncology, radiotherapy, nuclear medicine, physiotherapy) in an integrated fashion. The subtitle of this book "A Multidisciplinary Approach to Management" encompasses this concept. We have endeavored, with the help of an international group of contributors, to provide an up-to-date and authoritative account of the management of rectal tumor.

How to reference

In order to correctly reference this scholarly work, feel free to copy and paste the following:

Eberhard Gross (2011). Causes and Prevention of Functional Disturbances Following Low Anterior Resection for Rectal Cancer, Rectal Cancer - A Multidisciplinary Approach to Management, Dr. Giulio A. Santoro (Ed.), ISBN: 978-953-307-758-1, InTech, Available from: <http://www.intechopen.com/books/rectal-cancer-a-multidisciplinary-approach-to-management/causes-and-prevention-of-functional-disturbances-following-low-anterior-resection-for-rectal-cancer>

INTech
open science | open minds

InTech Europe

University Campus STeP Ri
Slavka Krautzeka 83/A
51000 Rijeka, Croatia
Phone: +385 (51) 770 447
Fax: +385 (51) 686 166
www.intechopen.com

InTech China

Unit 405, Office Block, Hotel Equatorial Shanghai
No.65, Yan An Road (West), Shanghai, 200040, China
中国上海市延安西路65号上海国际贵都大饭店办公楼405单元
Phone: +86-21-62489820
Fax: +86-21-62489821

© 2011 The Author(s). Licensee IntechOpen. This is an open access article distributed under the terms of the [Creative Commons Attribution 3.0 License](https://creativecommons.org/licenses/by/3.0/), which permits unrestricted use, distribution, and reproduction in any medium, provided the original work is properly cited.

IntechOpen

IntechOpen