

We are IntechOpen, the world's leading publisher of Open Access books Built by scientists, for scientists

6,900

Open access books available

186,000

International authors and editors

200M

Downloads

Our authors are among the

154

Countries delivered to

TOP 1%

most cited scientists

12.2%

Contributors from top 500 universities



WEB OF SCIENCE™

Selection of our books indexed in the Book Citation Index
in Web of Science™ Core Collection (BKCI)

Interested in publishing with us?
Contact book.department@intechopen.com

Numbers displayed above are based on latest data collected.
For more information visit www.intechopen.com



Pancreatogenous Hypoglycemic Syndrome - Insulinoma or Non-Insulinoma Origin (NIPHS)

Chen-Hsen Lee, Justin Ging-Shing Won and Hsiao-Shan Tseng
*Departments of Surgery, Internal Medicine and Radiology
 National Yang-Ming University and Taipei
 Veterans General Hospital, Taipei,
 Taiwan*

1. Introduction

Pancreatogenous hypoglycemic syndrome (PHS) is a heterogeneous disorder that occurs as a consequence of inappropriate and unregulated secretion of insulin by pancreatic β -cell tumors (insulinomas) or by nesidioblastic β -cells presenting as non-insulinoma pancreatogenous hypoglycemic syndrome (NIPHS). NIPHS, formerly termed adult nesidioblastosis, is characterized by postprandial hypoglycemia and negative prolonged fasts, and yields negative perioperative localization studies for insulinoma but positive intra-arterial calcium stimulation (IACS) tests as well as nesidioblastosis in the gradient-guided resected pancreas (Service et al., 1999a; Won et al., 2006). NIPHS is an increasingly recognized entity and appears to develop much more frequently in patients who have undergone either a Billroth II operation for peptic ulcer diseases or a Roux-en-Y gastric bypass procedure for medically complicated obesity (Service et al., 2005; Patti et al., 2005). Even though the histology of the resected pancreatic tissues from those patients resemble some of the histologic features observed in patients of congenital hyperinsulinism (CHI), in which genetic mutations in the 2 subunits (Kir6.2 and SUR 1) of the pancreatic β -cell ATP-sensitive potassium channel (K_{ATP}) are observed (Kapoor et al., 2006), screening for similar mutations in those patients has proven unsuccessful (Service et al., 1999; Patti et al., 2005). Although the existence of post-gastric bypass NIPHS as a discrete entity has been strongly questioned (Meier et al., 2006), several lines of evidence—the neuroglycopenic nature of spells, the usual unresponsiveness to dietary modification, and the very high recurrence rate (up to 87%) after gradient-guided pancreatectomy (Vanderveen et al., 2010)—suggest functional as well as structural abnormalities of the disorder.

Traditionally, PHS in adults is most commonly caused by circumscribed solitary or multiple insulinomas, while in 0.5-5% of patients, localized or diffuse proliferation of islet cells budding from pancreatic ducts (nesidioblastosis) has been defined (Fajans & Vinik 1989). With increasing utilization of IACS test, however, evidence shows that NIPHS has been found to account for 40-50% of all the patients with PHS (Starke et al., 2006; Thompson 2007). In our hospital, we routinely performed IACS tests for patients with documented hyperinsulinemic hypoglycemia, and during the past 15 years we found roughly an equal

incidence of insulinoma and NIPHS (Won et al., 2006), among the latter one-third had had gastric bypass surgery that was not bariatric-related.

2. Clinical presentations

The hypoglycemic symptoms are usually divided into adrenergic and neuroglycopenic symptoms. The sympathetic adrenergic symptoms include tachycardia, palpitations, sweating, tremor, and anxiety. The glucose deprivation of central nervous system (CNS) results in neuroglycopenic symptoms including behavioral changes, confusion, weakness, fatigue, loss of consciousness, amnesia, dizziness, blurry vision, diplopia, paresthesia, seizures, and coma (Fajans & Vinik 1989). These symptoms can occur during fasting, after exercise, or postprandially (3-5 hours after meal). Although the adrenergic symptoms are not unique to hypoglycemia, the possibility of neuroglycopenia should always be suspected in patients whose adrenergic symptoms are followed by spells of disturbed CNS functions, patients whose symptoms occur in the setting of a documented absolute hypoglycemia (plasma glucose ≤ 45 mg/dl; 2.8 mmol/l), and patients whose symptoms are relieved by glucose administration. A detailed history to ascertain the type of symptoms, the frequency of spells and its relationship to meals, and history of gastric bypass surgery should be obtained. Furthermore, clinical evidence of neuroglycopenia should be highly suggestive of organic hyperinsulinism, such as PHS, and warrants meticulous attentiveness and further testing until proven otherwise (Dizon et al., 1999). Approximately one-fourth of patients with insulinoma develop only neuroglycopenic symptoms (Fajans & Vinik 1989; Dizon et al., 1999).

Insulinoma is typically associated with fasting hypoglycemia, but may occur during both fasting and in postprandial states or even exclusively postprandially (Placzkowski et al., 2009). In contrast, NIPHS is often manifested as postprandial hypoglycemia, although fasting hypoglycemia can also occur. In a few of our NIPHS patients, persistent hypoglycemia during both fasting and postprandial periods requiring continuous infusion of dextrose to prevent neuroglycopenia was observed.

3. Diagnosis

The diagnosis of PHS requires biochemical confirmation of inappropriately elevated plasma insulin concentrations in the settings of absolute hypoglycemia, which may occur spontaneously or can be provoked (Service 1999). The diagnostic criteria for hyperinsulinemia consist of a plasma insulin level ≥ 6 μ U/ml (36 pmol/l), a plasma C-peptide ≥ 0.6 ng/ml (200 pmol/l), or a plasma proinsulin ≥ 5 pmol/l, and a plasma β -hydroxybutyrate ≤ 2.7 mmol/l at the time of hypoglycemia (plasma glucose ≤ 45 mg/dl or less) (Service 1999b). Nevertheless, with the development of the more sensitive and highly specific assay for insulin, the immunochemiluminometric assay (ICMA), an insulin level of ≥ 3 μ U/ml (18 pmol/l) has been suggested as the criterion for hyperinsulinemia (Service 1999b). It is therefore crucial to measure, in addition to insulin, the concentrations of plasma C-peptide (a marker of endogenous insulin production), proinsulin, and ketone body (an indicator of insulin action) concurrently during a symptomatic hypoglycemia, as occasional insulinoma cases have reported persistent low serum insulin levels as determined by ICMA, despite the elevated C-peptide and/or proinsulin concentrations (Chia & Saudek 2003; Coelho et al., 2009). Also, it is prudent to measure the level of insulin secretagogues (i.e.,

sulfonylureas and glinides), if available, to differentiate the factitious hypoglycemia; and insulin autoantibody to identify and exclude the insulin autoimmune syndrome, a rare disorder reported to occur primarily among persons of Japanese ancestry (Comi 1993). Our experience shows that, during hypoglycemic spells, the insulin levels tend to be higher in patients with insulinoma than in patients with NIPHS, in whom the detected insulin concentration may be a little higher than the aforementioned diagnostic criteria.

4. Laboratory tests

4.1 72 h fast

The 72 h supervised fast remains the gold standard for the diagnosis of insulinoma as the test enables the clinical demonstration of Whipple's triad: symptoms and signs consistent with hypoglycemia, a concomitant plasma glucose level of 45 mg/dl or less, and reversibility of symptoms with administration of glucose (Service & Natt 2000). In addition, the test provides biochemical confirmation of unsuppressed insulin secretion in the settings of hypoglycemia by measuring plasma insulin, C-peptide, proinsulin, and β -hydroxybutyrate concentrations simultaneously, as aforementioned. In most reports, one-third of patients with insulinoma develop symptoms within 12 hours, two-thirds within 24 hours, 95% in 48 hours, and 99% in 72 hours (Service & Natt 2000). A recent study suggests that a 48-h fast may be an alternative, with a sensitivity rate of 95% (Hirshberg et al., 2000). In our hospital, we routinely perform the 48-h prolonged fast. As expected, most patients with NIPHS, by definition, do not develop hypoglycemia during a 72 h prolonged fast.

4.2 The 5-hour oral glucose tolerance test (OGTT)

In contrast to the 72 h fast testing, the OGTT test may offer biochemical evidence of postprandial hypoglycemia associated with clinical symptoms and signs of neuroglycopenia, which may be missed in the supervised 72 h fast, though an abnormal OGTT is not helpful in the diagnosis or differential diagnosis of organic hyperinsulinism (Service 1999a). Interestingly, very few cases of insulinoma show signs of glucose-induced hypoglycemia alone (Wiesli et al., 2002; Kar et al., 2006).

4.3 Insulin/glucose (I/G) ratio or amended I/G ratio

These measurements are no longer applied to the diagnosis of organic hyperinsulinism as currently most insulin assays have been replaced by the more specific ICMA technique worldwide.

5. Image studies

Because of the small size (90% tumors usually less than 2 cm in size), potential multiplicity, and possible throughout the whole pancreas, preoperative localization of tumors is very important and essential in determining prognosis and appropriate surgical intervention. There are a variety of preoperative imaging modalities for the detection of insulinomas. However, no single one imaging examination could localize tumors in all patients. Most experienced endocrine surgeons obtain one or more localization tests before treatment is performed. In choosing the localization technique, specific tumor characteristics need to be considered.

- a. Most insulinomas are vascular and visualized in arterial phase imaging.
- b. Most tumors are intrapancreatic.
- c. 80 – 90% are solitary and 80% less than 2 cm in diameter.
- d. Distributed equally within the head, body and tail of the pancreas.
- e. Multiple tumors are found in only 8% of patients associated with MEN-1.

5.1 Preoperative transabdominal ultrasound

Just like other abdominal diseases, transabdominal ultrasound is the most convenient imaging modality to examine the pancreatic insulinomas. It is noninvasive, radiation free, and readily available. However, the pancreas is deeply located in the abdomen and most patients with insulinoma are obese due to frequent snacking to resolve hypoglycemic symptoms. To fully investigate the whole pancreas demands meticulous technique. Besides the usual supine position, placing the patient in recumbent or upright oblique position may be necessary. Using the fluid-filled stomach or the spleen as acoustic window is also useful to examine the body and tail of pancreas (Galiber et al., 1988; Gorman et al., 1986).

Usually, insulinoma is detected as a solitary, rounded, well-defined, hypoechoic mass with smooth outlines (Galiber et al., 1988). Gorman and colleagues reported 10% insulinoma either isoechoic or hyperechoic to surrounding parenchyma that may be due to normal pancreatic parenchyma. It is less echogenic in younger patients than in older ones (Gorman et al., 1986).

The ultrasound is operator dependent; thus, different detection rates were reported. Guettier and colleagues reported only a 14% accurate localization rate, a 72% false negative and a 14% false positive rates (Guettier et al., 1986). Grant reported their Mayo Clinic experience from July 1982 through October 2004 with a 65% sensitivity and a 91% positive predictive value (Grant, 2005). Not surprisingly, the bigger the tumor, the easier it is to be detected. Böttger and colleagues reported a sensitivity of 43% for tumors less than 1 cm in diameter, 67% for tumors between 1 and 1.5 cm, and 80% for tumors larger than 1.5 cm (Böttger et al., 1990). Kuzin and colleagues reported rates of 10%, 21.4% and 53.8% for tumors less than 1 cm, 1 to 2 cm and larger than 2 cm, respectively (Kuzin et al., 1998). They also found tumor location may affect the sensitivity of this test, with a 50% detection rate for tumor at pancreatic body, 16.7% for head and 23% for tail (Kuzin et al., 1998).

5.2 Endoscopic ultrasound (EUS)

Compared with transabdominal ultrasound, EUS is close to pancreas and can use high-frequency probe that improves the image resolution and increases the detection rate of insulinoma. The appearance of insulinomas in EUS is similar to that in transabdominal ultrasound. Most published series reported high sensitivity. Rösch and colleagues described a sensitivity of 82% (Rösch et al., 1992). Nikfarjam and colleagues reported 92% (Nikfarjam et al., 2008). But Druce and colleagues reported only 65.4% (Druce et al., 2010). This discrepancy implies the importance of expertise to carry out the procedure. Tumor location is another important factor. To detect an insulinoma in the pancreatic head portion is easier than one in the tail. Schumacher et al. had a 83% sensitivity for tumors at the head and 37% at the tail (Schumacher et al., 1996).

5.3 Computed tomography (CT)

CT is widely used to scan the pancreatic insulinoma. The reported sensitivity rate varied with different techniques. The conventional CT scan had low sensitivity with a range of 16 – 72% (Chatziioannou et al., 2001). There are at least two reasons to account for the low

detection rate. First, most insulinomas are small that conventional CT may skip the tumors. Second, small insulinomas appear similar density as normal parenchyma in pre-contrast and post-contrast delayed scan of conventional CT. With modern multidetector CT with dynamic contrast study, the above mentioned problems can be solved. After taking non-contrast study with thick slices (5–8 mm), biphasic images are taken after intravenous injection of 120–150 ml non-ionic contrast medium at the rate of 3–5 ml/sec with power injector. The arterial phase is taken about 30 seconds after injection and venous phase at 70 seconds. Thin slices and reformatted images may help to demonstrate smaller lesions (Chung et al., 1997). Nikfarjam and colleagues found the sensitivity rate increased from 24% before 1997 to 80% between 1994 and 2007 (Nikfarjam et al., 2008). Most insulinomas show isodensity nodule in pre-contrast scan and high density in the arterial phase images. Atypical CT appearances of insulinomas include a high density mass in pre-contrast CT scan, low density mass in post contrast scan, cystic or calcified mass (Chatziioannou et al., 2001).

5.4 Magnetic resonance imaging (MRI)

Modern MRI provides a high sensitive test in the localization of insulinoma. High field (1.5 T or 3 T) magnet combined with torso phased-array coil is used. Antiperistaltic agents may be used to decrease artifact caused by bowel movement. The protocol includes axial T1 and spin echo image with and without fat suppression, and spoiled gradient-echo (GRE) image before and after intravenous administration of gadolinium (Thoeni et al., 2000). Insulinomas usually show a low signal intensity in T1-weighted image and high in T2-weighted image, and marked enhancement after intravenous gadolinium administration. With modern MRI, the detection rates of 70% (Nikfarjam et al., 2008), 75% (Druce et al., 2010), and 85% (Thoeni et al., 2000) had been reported. The MRI technique is in constant evolution. Recently, the diffusion weighted image technique is applied to examine the abdomen. It may improve the detection of pancreatic insulinomas (Lee et al., 2008).

5.5 Angiography

Though angiography was considered also sensitive to localize insulinomas, it was rarely performed alone today in this hospital, and usually was combined with hepatic venous sampling. To perform angiography, a catheter is advanced through femoral artery and selected into the arteries that supplying the pancreas, including the celiac, superior mesenteric, splenic and gastroduodenal arteries. Modern angiographic suite is armamentarium with digital subtraction technique that will improve the sensitivity of this test. However, antiperistaltic agents may be necessary to suppress bowel movement which causes motion artifact (Jackson, 2005). Besides, different projections are mandatory to avoid overlapping with other organ, such as the spleen, that may interfere with the blush of insulinoma. Classical angiographic picture of an insulinoma is a well defined blushing appearing in early arterial phase and persist to venous phase. But hypovascular insulinomas are not uncommon because of their small sizes. Fulton and colleagues reported 9 of 24 insulinomas were hypovascular (Fulton et al., 1975). The reported detection rate of angiography ranged from 35% (Doherty et al., 1991) to 100% (Geoghegan et al., 1994).

5.6 Percutaneous transhepatic portal venous sampling (PTPVS)

The concept of PTPVS is that insulinomas secrete insulin which would be drained into adjacent venous system. The closer to the insulinoma, the higher the concentration of insulin

would be detected. After puncturing the branch of right portal vein, a catheter with side-hole at tip was advanced into the splenic vein and superior mesenteric vein. Venography was taken first as a map. Then, samplings were taken along the splenic, superior and inferior mesenteric veins as well as the portal trunk at 1 to 1.5 cm intervals. Pancreatic veins were also sampled when possible (Cho et al., 1982). PTPVS was highly accurate and considered to be the gold standard for this purpose (Nikfarjam et al., 2008; Vinik et al., 1991). However, severe complications, which mainly related to catheterizing the portal vein, are not infrequent. Miller and colleagues reported a rate of 6% severe complications (Miller et al., 1992). For this reason and the development of other less invasive modality, i.e. selective intra-arterial calcium stimulation with hepatic venous sampling, PTPVS is rarely performed nowadays.

5.7 Selective intra-arterial calcium stimulation (IACS) with hepatic venous sampling

In 1987, Imamura and colleagues described a novel method of intra-arterial injection of secretin and then sampling blood from hepatic vein to localize gastrinoma in patients with Zollinger-Ellison Syndrome (Imamura et al., 1987). In 1991, Doppman and colleagues adopted the concept but using calcium as secretagogue to localize insulinoma in four cases (Doppman et al. 1991). To perform IACS, a catheter with side-hole at the tip is threaded through femoral vein into right hepatic vein. After selective angiography, 10% calcium gluconate diluted with saline to equivalent to 0.0125 mmol/kg (0.025 mEq/kg) is injected as quickly as possible but not spilled into adjacent vessels to avoid bias. In obese patients, the dose is adjusted to 0.005mmol/kg. Blood samples are obtained from the right hepatic vein before and 30, 60, 90, 120, and 180 seconds after injection of calcium. All the arteries supplying pancreas should be studied that including superior mesenteric, gastroduodenal, and splenic arteries. Sometimes, dorsal pancreatic artery is also studied if it is large enough to be catheterized safely. A two-fold or greater increase of insulin above baseline indicates a positive result. A positive result in superior mesenteric artery or gastroduodenal artery means the lesion at pancreatic head or uncinate process, while in splenic artery means pancreatic body or tail. To further differentiate tumor location in body or tail, two sets of splenic artery samplings are collected. One is at proximal injection, another is distal to the pancreatic magna artery. If both are positive, the lesion is at pancreatic tail. If only proximal one is positive, the lesion is at pancreatic body. Besides the above mentioned arteries, proper hepatic artery is also studied to search the possibility of liver metastasis. The time between two calcium injections should be at least 5 minutes apart to allow the possible stimulated elevation of insulin level to return to its baseline (Jackson, 2005). Since its development, IACS is considered the most reliable preoperative localization modality for insulinoma. In most reported series, successful rates were more than 90% (Jackson, 2005). Diazoxide that is used to treat hyperinsulinemia should be suspended before IACS test as it may affect the result of the test (Doppman et al., 1991).

Besides insulinomas, beta-cell hyperfunction, the so-called nesidioblastosis, is another important cause of PHS. Since most nesidioblastosis did not form discrete nodule, the non-invasive image studies are usually negative (Raffel et al., 2007; Service et al., 1999a; Starke et al., 2006). But the IACS test always shows positive result and is an important clue to the diagnosis of nesidioblastosis. Meanwhile, if surgical treatment is to be performed, the gradient-guided resection according to the results of IACS test is mandatory (Thompson et al., 2000; Tseng et al., 2007).

5.8 Somatostatin receptor scintigraphy (SRS)

The somatostatin receptor scintigraphy (Octreoscan™), which uses Indium-111 pentetreotide as a traceable somatostatin analog that predominantly binds to receptor subtypes, sst2 and sst5 (Bertherat et al., 2003), serves as a functional imaging modality for neuroendocrine tumors and some non-neuroendocrine tumors which contain somatostatin receptors.

The diagnostic accuracy of the SRS is affected by the size and presence of different receptor subtypes of the tumors. The sensitivity of SRS in detecting insulinoma is reported to be as low as 50-60% (Balon et al., 2001; Mirallie et al., 2002), but the positive predictive value is high (Proye et al., 1998).

The SRS serves as a complementary role in the localization of an insulinoma when the diagnosis is established but undetectable or equivocal on CT or MRI.

6. Treatment

6.1 Medical treatment

For the insulinoma patients surgery is not amenable or is contraindicated, and for those with unresectable disease, medical treatment with diazoxide, a β -cell K_{ATP} channel agonist to inhibit insulin secretion, can be used with a reported effective rate of 97% (Gill et al., 1997). The usual dosage range is 150 to 450 mg daily, given orally twice or thrice a day. Side effects include nausea, hypertrichosis, and sodium retention. The addition of a benzothiadiazine diuretics, such as chlorothiazide, can combat the edema and potentiate the hyperglycemic effect of diazoxide (Fajans & Vinik 1989). Octreotide, a long-acting somatostatin analog that acts mainly via the somatostatin receptor subtype 2, is sometimes effective (Vezzosi et al., 2005).

Once the diagnosis of NIPHS in the patient is confirmed by IACS, medical treatment with diazoxide should be tried first. Our limited experience found that almost all the patients, with or without a previous gastric bypass surgery, responded satisfactorily, with alleviation of neuroglycopenic episodes presumably in those with intact function of β -cell K_{ATP} channel, which the action of diazoxide requires (Won et al., 2006). Whether octreotide or the newer analog, pasireotide (SOM230), is effective in patients with NIPHS is unclear and requires further study.

6.2 Surgical treatment

Surgical resection remains the treatment of choice for insulinomas. Usually, the successful rate of surgical treatment is over 90% in experienced hands. However, over resection of the pancreas may lead to diabetes which causes another problem affecting the patients' quality of life. With the advancement in imaging technology, increase in knowledge as well as improvement in surgical technique, blind resection for an unlocalized insulinoma is no more acceptable. Various modalities of resection are available for the surgical treatment of insulinomas. Enucleation is usually employed for an insulinoma superficially located and away from the main pancreatic duct either in the head or body portion of the pancreas. The postoperative occurrence rate of pancreatic fistula varied from 18 to 57%. Enucleation of the pancreatic tail insulinomas is also feasible in selective conditions such as a pedunculated or a small bulging tumor from pancreatic surface; or a clearly visible image of 2 to 3 mm distance between the tumor and main pancreatic duct. In the author's opinion, enucleation is

always first considered and evaluated before a resection of pancreas. If feasible, it causes less damage, avoids sacrificing islets in the pancreatic tail and saves time for operation. A distal pancreatectomy (40% distal pancreas resection) is done for multiple or big insulinomas ; or the tumor is attached to the pancreatic duct. The spleen should be preserved as possible; A Whipple's operation is rarely necessary for pancreatic head insulinoma unless it is big, deep or located near the main duct; Subtotal pancreatectomy (60~85% distal pancreatctomy) with enucleation of tumors in the head was advised for MEN-1 associated insulinomas because of its multiple and diffuse lesions before the IACS test was popular (Thompson 1995). Our recent experiences showed that a solitary insulinoma disease may exist in MEN-1 patients, and distal pancreatectomy achieved euglycemia for more than 10 years. Individualized judgment according to the IACS insulin gradients is mandatory to avoid over resections and ensuing sequellae, although in the published large series (Tonelli et al., 2005; Bartsch et al., 2005; Norton et al., 2006) most patients needed an extended distal pancreatectomy and enucleation of tumors in the head.

With repeated emphasis on the management of hypoglycemia in medical education as well as increased alertness of physicians at emergency department, more and more patients had diagnosis of spontaneous pancreatogenous hypoglycemia at its early presentation. It is our recommendation that image studies are done to localize the lesion instead of screening for diagnosis. However, despite the advancement in imaging technology, up to 25% of insulinomas remain occult preoperatively (Norton 1989). An occult insulinoma is defined as biochemically proven tumor with indeterminate anatomical site before operation. It should not prohibit the physicians from referring to surgery because intraoperative ultrasonography (IOUS) and palpation (96~100% sensitivity) by experienced surgeon may help to find out the tumor. A preoperative IACS test is helpful to indicate the region the tumor is located. It is especially useful in re-do operations or in patients with previous episodes of pancreatitis. In both situations dense peripancreatic adhesion usually exists and causes difficulties in dissection. Following the guidance of IACS test, a limited regional exploration may help to save operation time and prevent post-operative pancreatitis due to over manipulation (Tseng et al., 2007).

In case, IOUS and palpation failed to find the lesion, we recommend a regional resection of pancreatic tail (40%) or tail and body (80-85%) as suggested by the insulin gradients in the splenic artery alone or plus SMA. This is different from a blind resection and is helpful in the surgical treatment of adult NIPHS. Our previous report has shown its advantage over a subtotal pancreatectomy in terms of post-operative diabetes (Lee et al., 2002). However, long-term follow up is needed to observe any recurrence.

In summary, the goal of surgical treatment for PHS should aim at post-operative euglycemia and long term recurrence free. A blind distal pancreatectomy or an improper extensive subtotal pancreatectomy should not be performed. The IACS test plus IOUS is a good resection guide in the treatment of PHS. Surgical intervention for NIPHS is reserved for those refractory to medical treatment.

7. Conclusion

Spontaneous pancreatogenous hypoglycemic syndrome is a rare disease. With typical clinical presentation and compatible laboratory tests, it is not difficult for early diagnosis.

With pre-operative localization and intra-operative palpation as well as the use of intraoperative ultrasonography, blind resection of the distal pancreas is no more accepted. The cure rate of surgical treatment for insulinomas is usually more than 90%. Medical treatment is for those with high operation risk, previous failure of pre-operative and intra-operative localization or diffuse islet cell hyperplasia as indicated in the selective intra-arterial calcium stimulation test.

8. References

- Balon, H.R.; Goldsmith, S.J.; Siegel, B.A.; Silberstein, E.B.; Krenning, E.P.; Lang, O. & Donohoe, K.J. (2001). Procedure Guideline for Somatostatin Receptor Scintigraphy with ¹¹¹In-Pentetreotide. *The Journal of Nuclear Medicine*, Vol.42, No.7, (July), pp. 1134-1138.
- Bartsch, D. K.; Fendrich, V.; Langer, P. Celik I;Kann P.H. & Rothmund M., (2005). Outcome of Duodenopancreatic Resections in Patients with Multiple Endocrine Neoplasia Type 1. *Annals of Surgery*, Vol.242, No.6, (December), pp. 757-766.
- Bertherat, J.; Tenenbaum, F.; Perlemoine, K.; Videau, C.; Alberini, J.L.; Richard, B.; Dousset, B.; Bertagna, X. & Epelbaum, J. (2003). Somatostatin Receptors 2 and 5 are the Major Somatostatin Receptors in Insulinomas: an in Vivo and in Vitro Study. *The Journal of Clinical Endocrinology & Metabolism*, Vol.88, No.11, (November), PP. 5353-5360.
- Böttger, T.C.; Weber, W.; Beyer, J. & Jungineger, T. (1990). Value of Tumor Localizaton in Patients with Insulinoma. *World Journal of Surgery*, Vol.14, No.1, (January-February), pp. 107-114, ISSN 0364-2313.
- Chatziioannou, A.; Kehagias, D.; Mourikis, D.; Antoniou, A.; Limouris, G.; Kaponis, A.; Kavatzas, N.; Tseleni, S. & Vlachos, L. (2001). Imagining and Localization of Pancreatic Insulinomas. *Clinical Imaging*, Vol.25, No.4, (July-August), pp. 275-283.
- Chia, C. W. & Saudek, C. D. (2003). The Diagnosis of Fasting Hypoglycemia Due To an Islet-Cell Tumor Obscured by a Highly Specific Insulin Assay. *The Journal of Clinical Endocrinology & Metabolism*, Vol.88, No.4, (April), pp. 1464-1467.
- Cho, K.J.; Vinik, A.I.; Thompson N.W.; Porter D.J.; Brady, T.M.; Cadavid, G. & Fajans, S.S. (1982). Localzation of the Source of Hyperinsulinism: Percutaneous Transhepatic Portal and Pancreatic Vein Catheterization with Hormone Assay. *American Journal of Roentgenology*, Vol.139, No.2, (August), pp. 237-245.
- Chung, M.J.; Choi, B.I.; Han, J.K.; Chung, J.W.; Han, M.C. & Bae, S.H. (1997). Functioning Islet Cell Tumor of the Pancreas. Localization with Dynamic Spiral CT. *Acta Radiologica*, Vol.38, No.1, (January), pp. 135-138, ISSN 0284-1851.
- Coelho, C.; Druce, M. R. & Grossman, A. B. (2009). Diagnosis of Insulinoma in a Patient with Hypoglycemia without Obvious Hyperinsulinemia. *Nature Review of Endocrinology* Vol.5, No.11, (November), pp. 628-631.
- Comi, R. J. (1993). Approach to Acute Hypoglycemia. *Endocrinology and Metabolism Clinics of North America*, Vol. 22, No 2, (June), pp. 247-262.

- Dizon, A. M.; Kowalyk, S. & Hoogwerf, B. J. (1999). Neuroglycopenic and Other Symptoms in Patients with Insulinomas. *The American Journal of Medicine*, Vol.106, No.3, (March), pp. 307-310.
- Doherty, G.M.; Doppman, J.L.; Shawker, T.H.; Miller, D.L.; Eastman, R.C.; Gorden, P. & Norton, J.A. (1991). Results of a Prospective Strategy to Diagnose, Localize, and Resect Insulinomas. *Surgery*, Vol.110, No.6, (December), pp. 989-997.
- Doppman, J.L.; Miller, D.L.; Chang, R.; Shawker, T.H.; Gorden, P. & Norton, J.A. (1991). Insulinomas: Localization with Selective Intra-arterial Injection of Calcium. *Radiology*, Vol.178, No.1, (January), pp. 237-241.
- Druce, M.R.; Muthuppalaniappan, V.M.; O'Leary, B.; Chew, S.L.; Drake, W.M.; Monson, J.P.; Akker, S.A.; Besser, M.; Sahdev, A.; Rockall, A.; Vyas, S.; Bhattacharya, S.; Matson, M.; Berney, D. & Grossman, A.B. (2010). Diagnosis and Localization of Insulinoma: the Value of Modern Magnetic Resonance Imaging in Conjunction with Calcium Stimulation Catheterization. *European Journal of Endocrinology*, Vol.162, No.5, (May), pp. 971-978.
- Fajans, S. S. & Vinik, A. I. (1989). Insulin-producing Islet Cell Tumors. *Endocrinology and Metabolism Clinics of North America*, Vol.18, No.1, (March), pp. 45-74.
- Fulton, R.E.; Sheedy, P.F.; McIlrath, D.C. & Ferris, D.O. (1975). Preoperative Angiographic Localization of Insulin-producing Tumors of the Pancreas. *American Journal of Roentgenology*, Vol. 123, No.2, (February), pp. 367-377.
- Galiber, A.K.; Reading, C.C.; Charboneau J.W.; James, E.M.; Gorman, B.; Grant, C.S.; van Heerden, J.A. & Telander, R.L. (1988). Localization of Pancreatic Insulinoma: Comparison of Pre- and Intraoperative US with CT and Angiography. *Radiology*, Vol.166, No.2, (February), pp. 405-408.
- Geoghegan, J.G.; Jackson, J.E.; Lewis, M.P.N.; Owen, E.R.T.C.; Bloom, S.R.; Lynn, J.A. & Williamson, R.C.N. (1994). Localization and Surgical Management of Insulinoma. *British Journal of Surgery*, Vol.81, No.7, (July), pp. 1025-1028.
- Gill, G. V.; Rauf, O. & MacFarlane, I. A. (1997). Diazoxide Treatment for Insulinomas: A national UK survey. *Postgraduate Medical Journal*, Vol.73, No.864, (October), pp. 640-641.
- Gorman, B.; Charboneau J.W.; James, E.M.; Reading, C.C.; Galiber, A.K.; Grant, C.S.; van Heerden, J.A.; Telander, R.L. & Service F.J. (1986). Benign Pancreatic Insulinoma: Preoperative and Intraoperative Sonographic Localization. *American Journal of Roentgenology*, Vol.147, No.5, (November), pp. 929-934.
- Grant, C.S. (2005). Insulinoma. *Best Practice & Research Clinical Gastroenterology*, Vol.19, No.5, (October 2005), pp. 783-798.
- Guettier, J.M.; Kam, A.; Chang, R.; Skarulis, M.C.; Skarulis, M.C.; Cochran, C.; Alexander, H.R.; Libutti, S.K.; Pingpank, J.F. & Gorden, P. (2009). Localization of Insulinomas to Regions of Pancreas by Intraarterial Calcium Stimulation: The NIH Experience. *The Journal of Clinical Endocrinology & Metabolism*, Vol.94, pp.1074-1080.
- Hirshberg, B.; Livi, A.; Bartlett, D. L.; Libutti, S. K.; Alexander, H. R.; Doppman, J.L., Skarulis, M. C. & Gorden, P. (2000). Forty-Eight-Hour Fast: the Diagnostic Test for Insulinoma. *The Journal of Clinical Endocrinology & Metabolism*, Vol.85, No.9, (September), pp. 3222-3226.

- Imamura, M.; Takahashi, K.; Adachi, H.; Minematsu, S.; Shimada, Y.; Naito, M.; Suzuki, T.; Tobe, T. & Azuma, T. (1987). Usefulness of Selective Arterial Secretin Injection Test for Localization of Gastrinoma in the Zollinger-Ellison Syndrome. *Annals of Surgery*, Vol.205, No.3, (March), pp. 230-239.
- Jackson, J.E. (2005). Angiography and Arterial Stimulation Venous Sampling in the Localization of Pancreatic Neuroendocrine Tumours. *Best Practice & Research Clinical Endocrinology & Metabolism*, Vol.19, No.2, (June), pp. 229-239.
- Kapoor, R. R.; James, C. & Hussain, K. (2009). Advances in the Diagnosis and Management of Hyperinsulinemic Hypoglycemia. *Nature Clinical Practice of Endocrinology & Metabolism*, Vol.5, No.2, (February), pp. 101-112.
- Kar, P.; Price, P.; Sawers, S.; Bhattacharya, S.; Reznick, R. H. & Grossman, A. B. (2006). Insulinomas May Present with Normoglycemia after Prolonged Fasting but Glucose-stimulated Hypoglycemia. *The Journal of Clinical Endocrinology & Metabolism*, Vol.91, No.12, (December), pp. 4733-4736.
- Kuzin, N.M.; Egorov, A.V.; Kondrashin, S.A.; Lotov, A.N.; Kuznetsov, N.S. & Majorova, J.B. (1998). Preoperative and Intraoperative Topographic Diagnosis of Insulinomas. *World Journal of Surgery*, Vol.22, No.6, (June), pp. 593-597, ISSN 0364-2313.
- Lee, C.H.; Wong, J.G. & Chiang, J.H. (2002). Benign Diffuse Islet Cell Disease in Adults: A comparison of the results from distal and arterial stimulated venous sampling – guided pancreatectomies. *Chinese Medical Journal(Taipei)*. Vol.65, No.1, pp. 111-118.
- Lee, S.S.; Byun, J.H.; Park, B.J.; Park, S.H.; Kim, N.; Park, B.; Kim, J.K. & Lee, M. (2008). Quantitative Analysis of Diffusion-Weighted Magnetic Resonance Imaging of The Pancreas: Usefulness in Characterizing Solid Pancreatic Masses. *Journal of Magnetic Resonance Imaging*, Vol.28, No.4, (October), pp. 928-936.
- Meier, J. J.; Nauck, M. A. & Butler, P. C. (2006). Comment to: Patti ME, McMahon G, Mun EC et al. (2005) Severe Hypoglycaemia Post-gastric Bypass Requiring Partial Pancreatectomy: evidence for inappropriate insulin secretion and pancreatic islet hyperplasia. *Diabetologia* Vol.48, pp. 2236-2240. *Diabetologia*, Vol.49, No.3, (March), pp. 607-608.
- Miller, D.L.; Doppman, J.L.; Metz, D.C.; Maton, P.N.; Norton, J.A. & Jensen, R.T. (1992). Zollinger-Ellison Syndrome: Technique, Results, and Complications of Portal Venous Sampling. *Radiology*, Vol.182, No.1, (January), pp. 235-241.
- Mirallie, E.; Pattou, F.; Malvaux, P.; Filoche, B.; Godchaux, J.M.; Maunoury, V.; Palazzo, L.; Lefebvre, J.; Huglo, D.; Paris J.C.; Carnaille, B. & Proye, C. (2002). Value of Endoscopic Ultrasonography and Somatostatin Receptor Scintigraphy in the Preoperative Localization of Insulinomas and Gastrinomas. Experience of 54 cases. *Gastroenterologie clinique et biologique*, Vol.26, No.4, (April), pp. 360-366.
- Nikfarjam, M.; Warshaw A.L.; Axelrod, L.; Deshpande, V.; Thayer, S.P.; Ferrone, C.R. & Castillo, C.F. (2008). Improved Contemporary Surgical Management of Insulinomas. A 25-year Experience at the Massachusetts General Hospital. *Annals of Surgery*, Vol.247, No.1, (January), pp. 165-172, ISSN 0003-4932/08/24701-0165.

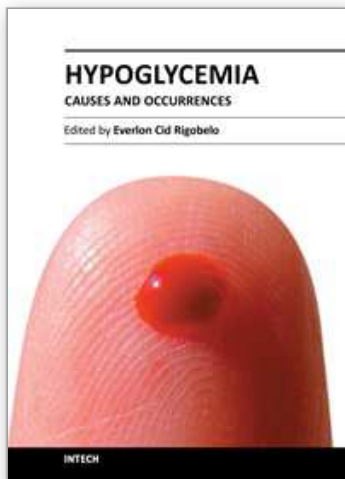
- Norton, J. A.; Cromack D. T. ; Shawker T. H.; Doppman J.L.; Comi R.; Gorden P.; Maton P.N.; Gardner J.D. & Jensen R.T. (1988). Intraoperative ultrasonographic localization of islet cell tumors. A prospective Comparison to Palpation. *Annals of Surgery*, Vol.207, No.2, (February), pp. 160-168.
- Norton, J. A.; Fang, T. D. & Jensen, R. T. (2006). Surgery for Gastrinoma and Insulinoma in Multiple Endocrine Neoplasia Type 1. *The Journal of the National Comprehensive Cancer Network*, Vol.4, pp. 148-153.
- Patti, M. E.; McMahon, G.; Mun, E. C.; Bitton, A.; Holst, J. J.; Goldsmith, J.; Hanto, D. W.; Callery, M.; Arky, R.; Nose, V.; Bonner-Weir, S. & Goldfine, A. B. (2005). Severe Hypoglycaemia Post-gastric Bypass Requiring Partial Pancreatectomy: Evidence for inappropriate insulin secretion and pancreatic islet hyperplasia. *Diabetologia*, Vol.48, No.11, (November), pp. 2236-2240.
- Placzkowski, K. A.; Vella, A.; Thompson, G. B.; Grant, C. S.; Reading, C. C.; Charboneau, J. W.; Andrews, J. C.; Lloyd, R. V. & Service, F. J. (2009). Secular Trends in the Presentation and Management of Functioning Insulinoma at the Mayo Clinic, 1987-2007. *The Journal of Clinical Endocrinology & Metabolism*, Vol.94, No.4, (April), pp. 1069-1073.
- Proye, C.; Malvaux, P.; Pattou, F.; Filoche, B.; Godchaux, J.M.; Maunoury, V.; Palazzo, L.; Huglo, Damien.; Lefebvre, J. & Paris, J.C. (1998). Noninvasive Imaging of Insulinomas and Gastrinomas with Endoscopic Ultrasonography and Somatostatin Receptor Scintigraphy. *Surgery*, Vol.124, No.6, (December), pp. 1134-1144.
- Raffel, A.; Krausch, M.; Anlauf, M.; Wieben, D.; Braunstein, S.; Klöppel, G.; Röher, H. & Knoefel, W.T. (2007). Diffuse Nesidioblastosis as a Cause of Hyperinsulinemic Hypoglycemia in Adults: a Diagnosis and Therapeutic Challenge. *Surgery*, Vol.141, No.2, (February), pp. 179-184.
- Rösch, T.; Lightdale, C.J.; Botet, J.F.; Boyce, G.A.; Sivak, M.V.; Yasuda, K.; Heyder, N.; Palazzo, L.; Dancygier, H.; Schusdziarra, V. & Classen, M. (1992). Localization of Pancreatic Neuroendocrine Tumours by Endoscopic Ultrasonography. *The New England Journal of Medicine*, Vol.326, No.26, (June), pp. 1721-1726.
- Schumacher, B.; Lübke, H.J.; Frieling T.; Strohmeyer, G. & Starke A.A.R. (1996). Prospective Study on the Detection of Insulinomas by Endoscopic Ultrasonography. *Endoscopy*, Vol.28, No.3, (March), pp. 273-276.
- Service, F.J.; Natt, N.; Thompson, G.B.; Grant, C.S.; van Heerden, J.A.; Andrews, J.C.; Lorenz, E.; Terzic, A. & Lloyd, R.V. (1999a). Noninsulinoma Pancreatogenous Hypoglycemia: a Novel Syndrome of Hyperinsulinemic Hypoglycemia in Adults Independent of Mutations in Kir6.2 and SUR1 Genes. *The Journal of Clinical Endocrinology & Metabolism*, Vol.84, No.5, (May), pp. 1582-1589.
- Service, F.J. (1999b). Diagnostic Approach to Adults with Hypoglycemic Disorders. *Endocrinology and Metabolism Clinics of North America*, Vol.28, No.3, (September), pp. 519-532.
- Service, F.J. & Natt, N. (2000). The Prolonged Fast. *The Journal of Clinical Endocrinology & Metabolism*, Vol.85, No.11, (November), pp. 3973-3974.

- Service, G. J.; Thompson, G. B. & Service, F. J.; Andrews, J.C; Collazo-Clavell, M. L & Lloyd, R.V. (2005). Hyperinsulinemic Hypoglycemia with Nesidioblastosis after Gastric-bypass Surgery. *The New England Journal of Medicine*, Vol.353, No.3, (July), pp. 249-254.
- Starke, A.; Saddig, C.; Kirch, B.; Tschahargane, C. & Goretzki, P. (2006). Islet Hyperplasia in Adults: Challenge to Preoperatively Diagnose Non-Insulinoma Pancreatogenic Hypoglycemia Syndrome. *World Journal of Surgery*, Vol.30, No.5, (May), pp. 670-679, ISSN 0364-2313.
- Thoeni, R.F.; Mueller-Lisse, U.G.; Chan, R.; Do, N.K. & Shyn, P.B. (2000). Detection of Small, Functional Islet Cell Tumors in the Pancreas: Selection of MR Imaging Sequences for Optimal Sensitivity. *Radiology*, Vol.214, No.2, (February 2000), pp. 483-490.
- Thompson, G. B. (2007). Invited commentary: On Diffuse Nesidioblastosis As a Cause of Hyperinsulinemic Hypoglycemia in Adults: A diagnostic and therapeutic challenge. *Surgery*, Vol.141, No.2, (February), pp. 185-186.
- Thompson, G.B.; Service F.J.; Andrews, J.C.; Lloyd, R.V.; Natt, N.; von Heerden J.A. & Grant C.S. (2000). Noninsulinoma Pancreatogenous Hypoglycemia Syndrome: an Update in 10 Surgically Treated Patients. *Surgery*, Vol.128, No.6, (December), pp. 937-945.
- Thompson, N. W.(1995). The Surgical Management of Hyperparathyroidism and Endocrine Diseases of the Pancreas in the Multiple Endocrine Neoplasia Type 1 Patient. *Journal of Internal Medicine*, Vol.238, No.3, (August), pp269-280.
- Tonelli, F. ; Fratini, G.; Falchetti, A., Nesi G. & Brandi M.L., (2004). Surgery for Gastroenteropancreatic Tumours in Multiple Endocrine Neoplasia Type 1: Review and personal experience. *Journal of Internal Medicine*, Vol.257, No.1, (December), pp38-49.
- Tseng, L.M.; Chen, J.Y.; Won, J.G.; Tseng, H.S.; Yan, A.H.; Wang, S.E. & Lee, C.H. (2007). The Role of Intra-Arterial Calcium Stimulation Test with Hepatic Venous Smapling (IACS) in the Management of Occult Insulinomas. *Annals of Surgical Oncology*, Vol.14, No.7, (July), pp. 2121-2127.
- Vanderveen, K. A.; Grant, C. S.; Thompson, G. B.; Farley, D. R.; Richards, M. L.; Vella, A.; Vollrath, B. & Service, F. J. (2010). Outcomes and Quality of Life after Partial Pancreatectomy for Noninsulinoma Pancreatogenous Hypoglycemia from Diffuse Islet Cell Disease. *Surgery*, Vol.148, No.6, (December), pp. 1237-1246.
- Vezzosi, D.; Bennet, A.; Rochaix, P.; Courbon, F.; Selves, J.; Pradere, B.; Buscail, L; Susini, C. & Caron, P. (2005). Octreotide in Insulinoma Patients: Efficacy on hypoglycemia, relationships with Octreoscanscintigraphy and immunostaining with anti-sst2A and anti-sst5 antibodies. *European Journal of Endocrinology*, Vol.152, No.5, (May), pp. 757-767.
- Vinik, A.I.; Delbridge, L.; Moattari, R.; Cho, K. & Thompson, N. (1991). Transhepatic Portal Vein Catheterization for Localization of Insulinomas: a Ten-Year Experience. *Surgery*, Vol.109, No.1, (January), pp. 1-11.
- Wiesli, P.; Spinas, G. A.; Pfammatter, T.; Krahenbuhl, L. & Schmid, C. (2002). Glucose-Induced Hypoglycaemia. *The Lancet*, Vol.360, No.9344, (November), pp. 1476.

Won, J. G. S.; Tseng, H. S.; Yang, A. H.; Tang, K. T.; Jap, T. S.; Lee, C. H.; Lin, H.D.; Burcus, N.; Pittenger, G. & Vinik, A. (2006). Clinical Features and Morphological Characterization of 10 Patients with Noninsulinoma Pancreatogenous Hypoglycaemia syndrome (NIPHS). *Clinical Endocrinology*, Vol.65, No.5, (November), pp. 566-578.

IntechOpen

IntechOpen



Hypoglycemia - Causes and Occurrences

Edited by Prof. Everlon Rigobelo

ISBN 978-953-307-657-7

Hard cover, 238 pages

Publisher InTech

Published online 10, October, 2011

Published in print edition October, 2011

Glucose is an essential metabolic substrate of all mammalian cells being the major carbohydrate presented to the cell for energy production and also many other anabolic requirements. Hypoglycemia is a disorder where the glucose serum concentration is usually low. The organism usually keeps the glucose serum concentration in a range of 70 to 110 mL/dL of blood. In hypoglycemia the glucose concentration normally remains lower than 50 mL/dL of blood. This book provides an abundance of information for all who need them in order to help many people worldwide.

How to reference

In order to correctly reference this scholarly work, feel free to copy and paste the following:

Chen-Hsen Lee, Justin Ging-Shing Won and Hsiao-Shan Tseng (2011). Pancreatogenous Hypoglycemic Syndrome - Insulinoma or Non-Insulinoma Origin (NIPHS), Hypoglycemia - Causes and Occurrences, Prof. Everlon Rigobelo (Ed.), ISBN: 978-953-307-657-7, InTech, Available from:
<http://www.intechopen.com/books/hypoglycemia-causes-and-occurrences/pancreatogenous-hypoglycemic-syndrome-insulinoma-or-non-insulinoma-origin-niphs->

INTECH
open science | open minds

InTech Europe

University Campus STeP Ri
Slavka Krautzeka 83/A
51000 Rijeka, Croatia
Phone: +385 (51) 770 447
Fax: +385 (51) 686 166
www.intechopen.com

InTech China

Unit 405, Office Block, Hotel Equatorial Shanghai
No.65, Yan An Road (West), Shanghai, 200040, China
中国上海市延安西路65号上海国际贵都大饭店办公楼405单元
Phone: +86-21-62489820
Fax: +86-21-62489821

© 2011 The Author(s). Licensee IntechOpen. This is an open access article distributed under the terms of the [Creative Commons Attribution 3.0 License](https://creativecommons.org/licenses/by/3.0/), which permits unrestricted use, distribution, and reproduction in any medium, provided the original work is properly cited.

IntechOpen

IntechOpen