

We are IntechOpen, the world's leading publisher of Open Access books Built by scientists, for scientists

6,900

Open access books available

185,000

International authors and editors

200M

Downloads

Our authors are among the

154

Countries delivered to

TOP 1%

most cited scientists

12.2%

Contributors from top 500 universities



WEB OF SCIENCE™

Selection of our books indexed in the Book Citation Index
in Web of Science™ Core Collection (BKCI)

Interested in publishing with us?
Contact book.department@intechopen.com

Numbers displayed above are based on latest data collected.
For more information visit www.intechopen.com



Reversal of Liver Fibrosis: A Review

Mona H. Ismail

*College of Medicine, University of Dammam, Department of Internal Medicine,
Division of Gastroenterology, King Fahad Hospital of the University,
Saudi Arabia*

1. Introduction

Liver fibrosis is the final pathway for most chronic liver disease and is the main reason for increased mortality in affected patients. The extent of liver fibrosis displays great individual variation, even after controlling for age (at infection), gender & exogenous factors. Thus, host genetic factors are likely to play an important role in the process of liver scarring. (Weber et al., 2008). Inflammation is strongly associated with chronic liver injury, and fibrosis is part of the liver's wound-healing response. Inflammation represents the driving force for the progressive accumulation of extracellular matrix (ECM) components, eventually leading to liver cirrhosis and hepatic failure. Although even acute injury will activate mechanisms of fibrogenesis, the sustained signals of inflammation associated with chronic liver disease caused by infection, drugs, metabolic disorders, or immune attacks are required for significant fibrosis to accumulate. Cirrhosis is the result of many liver diseases and consists of fibrosis and regenerating nodules. Clinical presentations vary from asymptomatic to advanced end stage liver diseases with complications. In addition, a significant need exists for developing safe and accurate noninvasive technique for detecting progression or regression of hepatic fibrosis in patients with chronic liver disease (Fallowfield JA et al., 2006).

The past few years have seen remarkable progress in the field of liver fibrosis, including understanding the crosstalk between innate immunity and inflammatory cells & pathways regulating fibrosis regression. This article will review recent advances in this field as well as imaging and diagnostic test of liver fibrosis.

2. Advances in the mechanisms of fibrogenesis

Liver fibrogenesis is characterized by cellular activation of hepatic stellate cells (HSCs) and its mediators. HSCs have dominated studies exploring mechanisms of liver fibrosis over the last two decades. HSCs are resident vitamin A-storing cells in the perisinusoidal space of Disse between the sinusoidal endothelium and hepatocytes. Following hepatic injury, HSCs become activated into a myofibroblast-like phenotype that is contractile, proliferative and fibrogenic. Collagen and other ECM components are deposited which result in a fibrous scar eventually leading to cirrhosis and liver failure (Lee & Friedman, 2011). Liver fibrosis is a dynamic process, resulting from the equilibrium between fibrogenesis and altered matrix degradation, and may be reversible prior to the establishment of advanced architectural

changes to the liver. HSC represent the final common pathway of the wound-healing response of the liver. Activation consists of two major phases, initiation (also called a 'preinflammatory stage') and perpetuation, followed by a resolution phase if the injury subsides (Friedman, 1993). Following alcohol consumption, cholestasis and iron overload, reactive oxygen species (ROS) and lipid peroxidation products are generated in large amounts leading to Kupffer cell activation. Activated Kupffer cells, infiltrating circulating monocytes, activated and aggregated platelets, and damaged hepatocytes are sources of platelet-derived growth factor (PDGF) and transforming growth factor- β 1 (TGF- β 1), which both trigger the initiation of intracellular signaling cascades after binding to HSC surface receptors. Activated HSC lose vitamin A droplets and increase expression of cytoskeletal proteins such as desmin and α -smooth muscle actin, which are associated with augmented contractile activity, as well as generate ECM, which includes type I and III collagen (Kawada, 2011). In addition, augmented production of the tissue inhibitor of matrix metalloproteinases (TIMP) hampers the degradation of ECM and conversely stimulates their accumulation in the inflamed liver. Activated HSC, also known as myofibroblasts (MFB), are contractile and their capacity to generate contractile force mediates the liver's injury response through modulation of sinusoidal blood flow and scar contracture.

Metalloproteinases-1 (MMP-1) is a key collagenase that metabolizes type I collagen; however, MMP activity also strictly regulates its binding partner, TIMP. Because HSC are able to generate both TIMP-1 and -2, a local balance between MMP and TIMP plays an important role in fostering the resolution of the fibrotic process (Benyon & Arthur, 2001). The liver's response to injury is an angiogenic one, with evidence of new blood vessel formation, sinusoidal remodeling, and HSC expansion (Lee et al., 2007). Neo-angiogenesis is stimulated in hepatic tissue by the progressive increase of tissue hypoxia. PDGF, vascular endothelial growth factor (VEGF), and their receptors as well as vasoactive mediators including nitric oxide and carbon monoxide are upregulated during liver fibrosis. This mechanism is strictly linked to the anatomical alterations following the establishment of periportal fibrosis with an increased contribution of the hepatic artery to the formation of sinusoidal blood. Accordingly, sinusoidal blood flow becomes increasingly arterialized with hepatocytes adjusting to an abnormally high oxygen concentration. Subsequently, the progressive capillarization of sinusoids leads to an impairment of oxygen diffusion from the sinusoids to hepatocytes with the consequent up-regulation of pro-angiogenic pathways (Pinzani et al., 2011). For example, increased VEGF concentrations may contribute to the accelerated progression of fibrosis in smokers who have hepatitis C (Dev et al., 2006).

The excess deposition of ECM proteins disrupts the normal architecture of the liver, which alters the normal function of the organ, ultimately leading to portal hypertension (PH) which is the earliest and most important consequence of cirrhosis and underlies most of the clinical complications of the disease. PH results from an increased intrahepatic resistance combined with increased portal (and hepatic arterial) blood flow.

Leptin, a key adipokine, has been implicated in fibrogenesis through a number of pathways. Leptin, a circulating adipogenic hormone, promotes stellate cell fibrogenesis and enhances TIMP-1 expression, which is associated with increased leptin signaling (Leclercq et al., 2002). Recent investigations have revealed the participation of mesenchymal cells, which originate from bone marrow, in liver fibrosis by using rodent models and damaged human livers (Forbes et al., 2004; Kisseleva et al., 2006). Similarly, fibrocytes in circulation and portal fibroblasts are acknowledged as fibrotic players (Dranoff & Wells, 2010). Furthermore, an

epithelial-mesenchymal transition (EMT) may be involved in the fibrotic process in the liver as well as in the kidney and lung (Zeisberg et al., 2007).

Perpetuation of the hepatic fibrotic process is supported by the activation of HSC and the presence of MFB, which are continuously stimulated by growth factors, cytokines and oxidative stress derived from nearby cells. Damaged hepatocytes are a source of lipid peroxides and ROS generated from hepatocytic mitochondria (Jiang et al., 2010). Macrophage chemotactic protein-1 (MCP-1) and osteopontin derived from activated Kupffer cells are involved in the infiltration of inflammatory cells into the liver (Syn et al., 2011).

Liver fibrosis is the final common pathway of the wound-healing response of the liver which can progress to liver fibrosis and eventually cirrhosis. At the cellular and molecular level, this progressive process is characterized by cellular activation of HSCs and aberrant activity of TGF- β with its downstream cellular mediators.

3. Reversibility of liver fibrosis and cirrhosis

Regression of fibrosis and cirrhosis in humans is not a novel concept. Anecdotal reports published more than forty years ago recorded an improvement in patients with cirrhosis treated for hemochromatosis and Wilson disease (Powell & Ker, 1970; Falkmer et al., 1970). Advanced fibrosis and cirrhosis has recently been described with respect to matrix turnover in trials of antiviral therapy for chronic viral hepatitis (Poynard et al., 2002). The issue of regression/reversibility of cirrhosis originates from evidence obtained in animal models upon the discontinuation of the cause of liver damage or following treatment with antifibrotic agent. In chronic liver injury, activated HSC are major source of fibrillar ECM as well as of the TIMPs which inhibit collagen degradation (Bataller & Brenner, 2005). HSC survival and apoptosis are regulated by growth factors expressed during fibrotic liver injury. Thus, HSC apoptosis plays a critical role in the recovery from biliary as well as toxic-induced liver fibrosis (Iredale et al., 1998). Moreover, the very striking improvement in the histological appearance in these reports suggests that the number of activated HSCs is reduced as well. By definition, the resolution of an injury with a return to normal histology must involve the loss or phenotypic reversal to quiescence of activated HSCs (Iredale, 2001). On the other hand, activated HSC produce the fibrolytic MMPs resulting in extracellular degradation and scar remodelling. Similarly, kuffer cells/macrophages appear instrumental in the reversal of established fibrosis when the fibrogenic stimulus is absent; while they can fuel fibrogenesis when the trigger is present (Duffield et al., 2005). Clearly, at some point (probably coinciding with the onset of the clinical symptoms of cirrhosis), fibrosis becomes irreversible. Animal models suggest that this event coincides with a significant collagen cross-linking by tissue transglutaminase, leading to the production of an insoluble matrix (Issa et al., 2004).

These observations have enhanced our understanding of the pathogenesis of liver fibrosis and defined our approach to its treatment. When hepatocyte necrosis occurs, the remaining hepatocytes undergo proliferation, leading to repair of the local environment. These processes are stimulated by growth factors derived from HSC, such as HGF, epidermal growth factor, epimorphin and pleiotrophin (Sawitza et al., 2009). It is difficult to say when cirrhosis becomes irreversible. Fibrotic deposition related to recent disease and characterized by the presence of thin reticulin fibers, often in the presence of a diffuse inflammatory infiltrate, is likely fully reversible. However, longstanding fibrosis, branded

by extensive collagen cross-linking, dense acellular/paucicellular ECM and decreased expression and/or activity of specific metalloproteinases, is likely irreversible (Issa et al., 2004; Pinzani & Rombouts, 2004). For example, cirrhosis following withdrawal of an injurious stimulus can undergo remodeling of dense micronodular cirrhosis to a more attenuated, macronodular pattern. However, some septa will persist, likely representing those laid down early in the injury, and are therefore the most “mature” (i.e., cross-linked) (Friedman, 2003).

Evidence of fibrotic regression has now been documented in chronic liver diseases, including autoimmune hepatitis, biliary obstruction, iron overload, Non-alcoholic steatohepatitis, and viral hepatitis B and C (Ismail & Pinzani, 2009). Poynard *et al.*, 2002 examined liver biopsy specimens taken before and after therapy from 153 patients with HCV-related cirrhosis treated with different pegylated interferon and ribavirin regimens. Using the METAVIR scoring system, they found that the extent of liver fibrosis had improved in 75 (49%) Stage-4 patients: to Stage 3 in 23 patients, to Stage 2 in 26 patients, to Stage 1 in 23 patients, and to a virtually normal histological appearance in three patients. No such improvements were recorded in the control group of patients treated with interferon monotherapy. Reversal of cirrhosis was more common among younger patients.

4. Evaluation of liver fibrosis

The accurate and early diagnosis of liver fibrosis is crucial for long-term prognosis (Castera & Pinzani, 2010). The complete evaluation of a patient with diffuse liver diseases requires clinical evaluation, laboratory tests and pathological examination. Standard liver tests (ALT, AST, Bilirubin...etc) are of limited value in assessing the degree of fibrosis. Currently, histological examination of a liver biopsy specimen is the reference standard for the diagnosis, staging, and monitoring of liver fibrosis (Bravo et al., 2001; Campbell & Reddy, 2004). Three staging systems are commonly used to classify liver fibrosis: the Knodell, METAVIR and Ishak scores (Knodell et al., 1981; Desmet et al., 1994; Anthony et al., 1978). Knodell and METAVIR score fibrosis from Stages 0 to 4, with Stage 4 as cirrhosis, whereas Ishak scores fibrosis from Stages 0 to 6, with 5 as incomplete or early cirrhosis and 6 as established cirrhosis. There are several situations in which the role of liver biopsy (LB) is being challenged. These methods are semi-quantitative which make it a poor choice when considering assessment of liver fibrosis progression or regression. Furthermore, there is the issue of sampling error, defined as variable levels of fibrosis throughout the liver, with biopsy only examining a small portion of the liver (around 1/50000th of liver mass is obtained) (Bedossa et al., 2003). In addition, histological examination is prone to intraobserver and interobserver variation, which may occur even when widely validated systems are used to assess liver damage (Regev et al., 2002). Finally, liver biopsy is an invasive procedure with associated morbidity: pain occurs in 20% of patients and major complications (such as bleeding or hemobilia) in 0.5% of patients (Huang et al., 2007; Rockey et al., 2009).

5. Noninvasive markers of fibrosis

Over the past years, several non-invasive tests have become available for clinicians to use to assess liver fibrosis and determine the best course of management for their patients,

especially those with chronic hepatitis C (Afdhal, 2003; Kotlyar et al., 2008). Initial studies of noninvasive markers largely consisted of single components, but the field has evolved into combining these single components into panel markers. Several laboratory tests, scores, and indices have been proposed for noninvasive prediction of hepatic fibrosis in patients with chronic hepatitis C. Among these is the aspartate aminotransferase (AST)/alanine aminotransferase (ALT) ratio (AAR) (Saadeh et al., 2001; Giannini et al., 2003; Williams & Hoofnagle, 1988). A ratio >1 has been proposed as a test for cirrhosis. However, the test is disadvantaged by both poor sensitivity (53.2%) and a negative predictive value (80.7%). Forns fibrosis index (FFI) (Forns, 2002) was developed as a model to predict fibrosis in patients with HCV based on age, gamma glutamyl transferase (gGT), cholesterol and platelet count. The score derived from this was validated against liver histology using the METAVIR scoring system for hepatic fibrosis, and it was found to have a sensitivity of 94% & specificity of 51% for a cut-off value of >4.2 (for absence of fibrosis) and a sensitivity of 30% & specificity of 95% for a cut-off value of >6.9 (for presence of fibrosis). Low platelet count *per se* (Ono et al., 1999) can predict advanced fibrosis. The AST-to-platelet ratio index (APRI) (Wai et al., 2003) is formulated by dividing the AST by the upper limit of normal AST divided by the platelet count and multiplied by 100. In the initial study in patients with HCV, the APRI was derived from a training set of 192 patients undergoing liver biopsy. The area under the curve (AUC) for predicting significant fibrosis (Ishak fibrosis score ≥ 3) and cirrhosis were 0.82 and 0.92, respectively, in the training set, and 0.80 and 0.89, respectively, in the validation set for 78 patients. Using optimized cut-off values, this test predicted significant fibrosis in 51% and cirrhosis in 81% of patients. Other similar scoring systems that have been applied include the cirrhosis discriminant score (Bonacini et al., 1997), age-platelet index (Poynard et al., 1997) and Pohl score (Pohl et al., 2007). These tests were compared in a study comparing AAR, CDS, AP index, Pohl score and APRI (Lackner et al., 2005). In this study of 194 patients, AUC analysis revealed similar diagnostic accuracy for CDS, AP index, APRI and platelet count for the prediction of significant fibrosis (Ishak score ≥ 3) (AUCs of 0.71, 0.74, 0.80 and 0.71, respectively) and cirrhosis (AUCs of 0.91, 0.91, 0.90 and 0.89, respectively). FIB-4 (Vallet-Pichard et al., 2007) is a recently described marker of fibrosis derived from a formula utilizing AST, ALT, age and platelets. In a series of 847 biopsies from HCV monoinfected patients comparing FIB-4 values to liver biopsy and FibroTest values, FIB-4 values <1.45 or >3.25 (64.6% cases) were concordant with FibroTest results in 92.1% and 76% of cases, respectively. Using the METAVIR scoring system to record fibrosis, this test had an AUC of 0.85 (95% CI 0.82–0.89) for prediction of severe fibrosis (F3–4) and 0.91 (95% CI 0.86–0.93) for prediction of cirrhosis. The FibroIndex was derived from an estimation set of 240 patients and validated in 120 subsequent patients. The test was derived from platelet count, AST and gamma globulin. Using this method, the AUC for the detection of significant fibrosis using the METAVIR histological classification of fibrosis ($\geq F2$) was 0.83 in the estimation set and 0.82 in the validation set. Although it was calculated using best cut-offs for PPV, only 35% of patients avoided LB.

FibroTest-ActiTest (FT-AT), from BioPredictive, Paris, France, is a noninvasive blood test that combines the quantitative results of six serum biochemical markers [α 2-macroglobulin, haptoglobin, gamma glutamyl transpeptidase, total bilirubin, apolipoprotein A1 and ALT] with patients' age and gender in a patented algorithm to generate a measure of fibrosis and necroinflammatory activity in the liver (Imbert-Bismut et al., 2001; Poynard et

Biomarker (Ref.)	Parameters	Patients	F2-3-4 (%)	AUC	Se (%)	Sp (%)	PPV/NPV (%)
Forns Fibrosis Index 2002 (Kotlyar et al., 2008)	Age, platelet count, GGTP and cholesterol.	HCV	26%	t =0.86, v =0.81	91	51	66/96
APRI Index 2003 (Giannini et al., 2003)	AST /Platelet Ratio	HCV	50	t =0.80, v =0.90	89	75	91/90
Fibrotest 2001 (Poynard et al., 1997)	α 2-macroglobulin, hepatoglobulin, lipoprotein A1, bilirubin and δ - glubulin.	HCV	80	t =0.84, v =87	75	85	>90/100

Abbreviations used: GGT: g-glutamyl-transpeptidase; AST: aspartate transaminase; chronic hepatitis C: HCV; Se: sensitivity; Sp: specificity; AUC: area under the receiver operator characteristic curve; t: Training group; v: Validation group. An AUC of 1.0 is characteristic of an ideal test, where as an AUC of 0.5 or less indicates a test of no diagnostic value.

Table 1. Diagnostic performance of common non-invasive tests of liver fibrosis.

al., 2002). FT-AT provides an accurate measurement of bridging fibrosis and/or moderate necroinflammatory activity with the area under the receiver operating curve (AUROC) predictive value, between 0.70 and 0.80, when compared to liver biopsy (Sporea et al., 2008) (Table 1 summarized the diagnostic performance of noninvasive tests of liver fibrosis).

6. Limitations of serum biomarkers

One limitation of biomarkers is that none is liver-specific and they may be influenced by changes in their clearance and excretion. The inter-laboratory reproducibility of scores such as FibroTest has been shown to be satisfactory for use in clinical practice (Cales et al., 2008). Careful interpretation of each test is required e.g., when using FibroTest, the existence of haemolysis or Gilbert syndrome can lead to false-positive results (by a decrease haptoglobin or an increase in bilirubin, respectively)(Castera et al., 2011).

7. Imaging methods

Imaging techniques are an attractive way of evaluating fibrosis because they are noninvasive and have the ability to detect structural changes, which serological-based tests of fibrosis and inflammation are unable to do. Using the modalities of ultrasound, computed tomography or magnetic resonance imaging (MRI), it is possible to diagnose features of advanced chronic liver disease by recognizing surrogate markers of portal hypertension (e.g. splenomegaly, ascites.etc) with a high degree of sensitivity and specificity. However, these techniques do not reliably detect lesser degrees of fibrosis. Even diagnosis of cirrhosis is often based only on signs of advanced liver cirrhosis, e.g., signs of portal hypertension, a shrunken right liver lobe with enlargement of the caudate lobe, resulting in a high specificity but lower sensitivity of the methods (Honda et al., 1990). Ultrasound studies combining several ultrasound parameters and Doppler measurements achieved accuracies for the diagnosis of cirrhosis up to a maximum of 88% (Aubé et al., 1999). Commonly used imaging methods are discussed in the next section.

7.1 Transient elastography or fibroscan

Transient elastography (TE), or FibroScan (Echosens, Paris, France), is a novel technology for measuring liver stiffness (Ziol et al., 2005). The scan was developed on the principle that livers with increasing degrees of scarring or fibrosis have decreasing elasticity and that a shear wave propagating through stiffer material would progress faster than in a more elastic material. Thus, the stiffer the liver, the faster the shear waves propagate. The ultrasound transducer probe is mounted on the axis of a vibrator. Pulse-echo ultrasound waves then measure the velocity of the shear wave in the liver tissue at a distance of 2.5–6.5 cm under the skin level, which corresponds to a measured distance of 4 cm in the liver tissue. TE is rapid (less than 5 minutes), highly reproducible and can easily be performed bedside or in the outpatient clinic with immediate results. Liver stiffness corresponds to the median value of ten validated measurements that range from 2.5 to 75 kPa, with normal values around 5.5 kPa (Castera et al., 2008).

TE provides clinicians with a noninvasive, accurate, and reproducible tool to estimate liver fibrosis. Numerous studies have shown that this technique is an excellent tool for the

detection of advanced fibrosis or cirrhosis, but the results for the prediction of different stages of moderate fibrosis are less conclusive. Due to its noninvasive nature, simple training and ease of use, TE can be used repeatedly on patients and is optimal for large-scale studies, in which healthy patients with no indication for liver biopsy can also be included. This technique has the advantage of being safe, reproducible, and rapid. However, falsely high liver stiffness measurements might also occur during acute hepatitis, extrahepatic cholestasis, congestive heart failure, and amyloidosis (Castera et al., 2010). Failed acquisition was commonly due to obesity, particularly increased waist circumference, and limited operator experience. However, development of S and XL probes might overcome this limitation. A meta-analysis of nine studies (Talwalkar et al., 2007) showed that TE has a sensitivity of 87% (95% CI 84%–90%) and a specificity of 91% (95% CI 89%–92%) for diagnosing cirrhosis. In seven of the nine studies, Stage 2 to 4 fibrosis was diagnosed with 70% sensitivity (95% CI 67%–73%) and 84% specificity (95% CI 80%–88%). Foucher et al. reported that, in 144 chronic hepatitis C patients with fibrosis at stage 3 or 4, the cut-off values of liver stiffness measured by TE were 27.5, 49.1, 53.7 and 62.7 kPa for the appearance of esophageal varices (Stage 2/3), ascites, HCC and rupture of esophageal varices (Castéra et al., 2010).

7.2 Magnetic resonance elastography

Few studies that focus on MRI detection and quantification of liver fibrosis currently exist. More recently, a liver stiffness evaluation (LSE) by MR elastography (MRE) has been demonstrated to provide high accuracy for the noninvasive diagnosis of liver fibrosis (Talwalkar et al., 2008; Huwart et al., 2008). The technique used is similar to that used in ultrasound elastography in that it uses a vibration device to induce a shear wave in the liver. Liver elasticity is evaluated using an external probe at the back of the patient and sending low frequency vibrations (60 Hz) through the liver and measuring the MRI spin-echo sequence. With this technique, shear elasticity and viscosity maps are obtained, and a color-coded image is generated that depicts the wave velocity, and thus the stiffness, throughout the organ. A study comparing the MRE of thirty healthy volunteers and fifty patients with chronic liver disease with liver histology showed a sensitivity of 86% and a specificity of 85% for discrimination between patients with moderate and severe fibrosis (Metavir F2–F4) and those with mild fibrosis (Yin et al., 2007). However, MRE is expensive, and cost may limit its use. Thus, it may not be readily available at all hospitals.

7.3 Acoustic radiation force impulse

Acoustic radiation force impulse (ARFI) is a new technology for LSE which uses an add-on module to the standard ultrasound imaging device. It involves targeting an anatomic region for interrogation of the elastic properties with the use of a region of interest cursor while performing real-time B-mode imaging. An initial ultrasonic pulse is transmitted at diagnostic intensity levels to obtain a baseline signal for later comparison. A short-duration (approximately 0.3 s), high-intensity acoustic ‘pushing pulse’ is then transmitted by the same transducer and is followed by a series of diagnostic intensity pulses, which are used to track the displacement of the tissue caused by the pushing pulse (Palmeri et al., 2005). By measuring the time-to-peak displacement at each lateral location, one can reproduce the shear-wave speed of the tissue. The shear-wave propagation velocity is proportional to the

square root of tissue elasticity. Results are expressed in meters per second (m/s) (range, 0.5–4.4 m/sec; $\pm 20\%$ accuracy over the range). In a study performed by Friedrich-Rust et al., 2009; ARFI was compared to LB and blood markers of liver fibrosis in 86 patients with chronic hepatitis (B or C). The Spearman correlation coefficients between the histological fibrosis stage and ARFI, TE, FibroTest and APRI scores indicated significant correlations: 0.71, 0.73, 0.66 and 0.45, respectively ($p < 0.001$).

Newer imaging estimation of hepatic fibrosis appears promising. TE & ARFI appear to be excellent tools for early detection of cirrhosis with likely prognostic value in this setting.

8. Combination of serum markers and imaging methods

The use of sequential or combined serum tests and imaging to provide better prediction for significant fibrosis (METAVIR stages F2–F4) or cirrhosis, and thus a reduction in the need for biopsy in patients with chronic hepatitis C (CHC), is gaining support. Certainly, the stepwise concept of using a highly sensitive test to first rule out significant disease and then using a more specific test to confirm the diagnosis if the test results are positive is advantageous. One recent approach integrated a biopsy into a clinical decision algorithm by targeting patients with indeterminate or misclassified values with marker panels. The Sequential Algorithms for Fibrosis Evaluation (SAFE) biopsy study (Sebastiani et al., 2009) evaluated the APRI followed by FT-AT in 2035 CHC patients from nine clinical centers in the United States and Europe. Using this sequential approach, the number of biopsies saved at baseline was 47 and 82% with an overall accuracy of 90% for Stages F2–F4 and cirrhosis, respectively. Another study (Paggi et al., 2008) noted that the combination of APRI and a simple ultrasound assessment of the presence of liver surface nodularity could predict stages F3–F4 in 54% of CHC patients.

These techniques certainly appear to be valid approaches for reducing the need for biopsy in CHC patients. The combined use of TE and biochemical markers seems to be the most promising noninvasive techniques which can help the clinician decide whether a liver biopsy is necessary in some patients, and accordingly decide who to treat.

9. Conclusions

Our understanding of the mechanism of liver fibrosis has changed dramatically over the last decade and is no longer viewed as permanent but rather as a dynamic process. The HSC play a critical role in fibrogenesis. Reversal of fibrosis is accompanied by clearance of HSC and treatment of the primary cause of injury can allow complete resolution of fibrosis. Liver biopsy is the current reference test for the assessment of hepatic fibrosis, but because of its limitations, noninvasive markers of liver fibrosis have been developed. Although none of the currently available noninvasive marker of fibrosis are an ideal test to accurately differentiate between disease stages, the combination of serum markers, and imaging appear to have good predictive values in excluding patients with cirrhosis.

10. References

Afdhal NH (2003). Diagnosing fibrosis in hepatitis C: is the pendulum swinging from biopsy to blood tests? *Hepatology* 2003 May; 37: 972-4.

- Anthony PP, Ishak KG, Nayak NC, Poulsen HE, Scheuer PJ & Sobin LH (1978). The morphology of cirrhosis. Working group sponsored by the World Health Organization. *J Clin Pathol* 1978 May; 31: 395-414.
- Aubé C, Oberti F, Korali N, Namour MA, Loisel D, Tanguy JY, et al (1999). Ultrasonographic diagnosis of hepatic fibrosis or cirrhosis. *J Hepatol* 1999 Mar; 30: 472-8.
- Bataller R & Brenner DA (2005). Liver fibrosis. *J Clin Invest* 2005 Feb; 115: 209-18.
- Bedossa P, Dargere D & Paradis V (2003). Sampling variability of liver fibrosis in chronic hepatitis C. *Hepatology* 2003 Dec;38:1449-57.
- Benyon RC & Arthur MJ (2001). Extracellular matrix degradation and the role of hepatic stellate cells. *Semin Liver Dis* 2001 Aug;21:373-84.
- Bonacini M, Hadi G, Govindarajan S & Lindsay KL (1997). Utility of a discriminant score for diagnosing advanced fibrosis or cirrhosis in patients with chronic hepatitis C virus infection. *Am J Gastroenterol* 1997 Aug;92:1302-4.
- Bravo AA, Sheth SG & Chopra S (2001). Liver biopsy. *N Engl J Med* 2001 Feb; 344: 495-500.
- Cales P, Veillon P, Konate A, Mathieu E, Ternisien C, Chevaller A, et al (2008). Reproducibility of blood tests of liver fibrosis in clinical practice. *Clin Biochem* 2008 Jan; 41(1-2):10-8.
- Campbell MS & Reddy KR (2004). Review article: the evolving role of liver biopsy. *Aliment Pharmacol Ther* 2004 Aug; 20:249-59.
- Castera L, Forms X & Alberti A (2008). Non-invasive evaluation of liver fibrosis using transient elastography. *J Hepatol* 2008 May; 48: 835-47.
- Castera L, Foucher J, Bernard PH, Carvalho F, Allaix D, Merrouche W, et al (2010). Pitfalls of liver stiffness measurement: a 5-year prospective study of 13,369 examinations. *Hepatology* 2010 Mar; 51:828-35.
- Castera L & Pinzani M (2010). Biopsy and non-invasive methods for the diagnosis of liver fibrosis: does it take two to tango? *Gut* 2010 Jul; 59: 861-6.
- Castera L (2011). Invasive and non-invasive methods for the assessment of fibrosis and disease progression in chronic liver disease. *Best Practice & Research Clinical Gastroenterology* 2011 Apr; 25(2): 291-303.
- Desmet VJ, Gerber M, Hoofnagle JH, Manns M & Scheuer PJ (1994). Classification of chronic hepatitis: diagnosis, grading and staging. *Hepatology* 1994 Jun; 19: 1513-20.
- Dev A, Patel K, Conrad A, Blatt LM & McHutchison JG (2006). Relationship of smoking and fibrosis in patients with chronic hepatitis C. *Clin Gastroenterol Hepatol* 2006 Jun; 4: 797-801.
- Dranoff JA & Wells RG (2010). Portal fibroblasts: underappreciated mediators of biliary fibrosis. *Hepatology* 2010 Apr; 51: 1438-44.
- Duffield J, Forbes S, Constandinou C, Clay S, Partolina M, Vuthoori S, et al (2005). Selective depletion of macrophages reveals distinct, opposing roles during liver injury and repair. *J Clin Invest* 2005 Jan; 115(1):56.
- Falkmer S, Samuelson G & Sjolín S (1970). Penicillamine-induced normalization of clinical signs and liver morphology and histochemistry in a case of Wilson's disease. *Pediatrics* 1970 Feb; 45 :260-8.
- Fallowfield JA, Kendall TJ & Iredale JP (2006). Reversal of Fibrosis: No Longer a Pipe Dream? *Clin Liver Dis* 2006 Aug; 10: 481-97.

- Forbes SJ, Russo FP, Rey V, Burra P, Rugge M, Wright NA, et al (2004). A significant proportion of myofibroblasts are of bone marrow origin in human liver fibrosis. *Gastroenterology* 2004 Apr; 126: 955-63.
- Forns X, Ampurdanes S, Llovet JM, Aponte J, Quinto L, Martinez- Bauer E, et al (2002). Identification of chronic hepatitis C patients without hepatic fibrosis by a simple predictive model. *Hepatology* 2002 Oct; 36: 986-92.
- Friedman SL (2003). Liver fibrosis – from bench to bedside. *J Hepatol* 2003; 38: S38-53.
- Friedman SL (1993). The cellular basis of hepatic fibrosis: Mechanisms and treatment strategies. *N Engl J Med* 1993 Jun; 328: 1828-35.
- Friedrich-Rust M, Wunder K, Kriener S, Sotoudeh F, Richter S, Bojunga J, et al (2009). Liver Fibrosis in Viral Hepatitis: Noninvasive Assessment with Acoustic Radiation Force Impulse Imaging versus Transient Elastography. *Radiology* 2009 Aug; 252 :595-604.
- Giannini E, Risso D, Botta F, Chiarbonello B, Fasoli A, Malfatti F, et al (2003). Validity and clinical utility of the aspartate aminotransferase-alanine aminotransferase ratio in assessing disease severity and prognosis in patient with hepatitis C virus-related chronic liver disease. *Arch Intern Med* 2003 Jan; 163: 218-24.
- Honda H, Onitsuka H, Masuda K, Nishitani H, Nakata H & Watanabe K (1990). Chronic liver disease, value of volumetry of liver and spleen with computed tomography. *Radiat Med* 1990 Nov-Dec; 8: 222-6.
- Huang JF, Hsieh MY, Dai CY, Hou NJ, Lee LP, Lin ZY, et al (2007). The incidence and risks of liver biopsy in non-cirrhotic patients: An evaluation of 3806 biopsies. *Gut* 2007 May; 56: 736-7.
- Huwart L, Sempoux C, Vicaud E, Salameh N, Annet L, Danse E, et al (2008). Magnetic resonance elastography for the noninvasive staging of liver fibrosis. *Gastroenterology* 2008 Jul; 135: 32-40.
- Imbert-Bismut F, Ratziu V, Pieroni L, Charlotte F, Benhamou Y, Poynard T, et al (2001). Biochemical markers of liver fibrosis in patients with hepatitis C virus infection: a prospective study. *Lancet* 2001 Apr; 357: 1069-75.
- Iredale JP, Benyon RC, Pickering J, McCullen M, Northrop M, Pawley S, et al (1998). Mechanisms of spontaneous resolution of rat liver fibrosis. Hepatic stellate cell apoptosis and reduced hepatic expression of metalloproteinase inhibitors. *J Clin Invest*. Aug 1 1998 Aug;102(3):538-49.
- Iredale JP (2001). Hepatic stellate cell behavior during resolution of liver injury. *Semin Liver Dis* 2001 Aug;21(3):427-36.
- Ismail MH & Pinzani M (2009). Reversal of liver fibrosis. *Saudi J Gastroenterol* 2009 Jan; 15: 72-9.
- Issa R, Zhou X, Constandinou CM, Fallowfield J, Millward-Sadler H, Gaca MD, et al (2004). Spontaneous recovery from micronodular cirrhosis: evidence for incomplete resolution associated with matrix cross-linking. *Gastroenterology* Jun 2004; 126(7): 1795-1808.
- Jiang JX, Venugopal S, Serizawa N, Chen X, Scott F, Li Y, Adamson R, et al (2010). Reduced nicotinamide adenine dinucleotide phosphate oxidase 2 plays a key role in stellate cell activation and liver fibrogenesis in vivo. *Gastroenterology* 2010 Oct; 139: 1375-84.

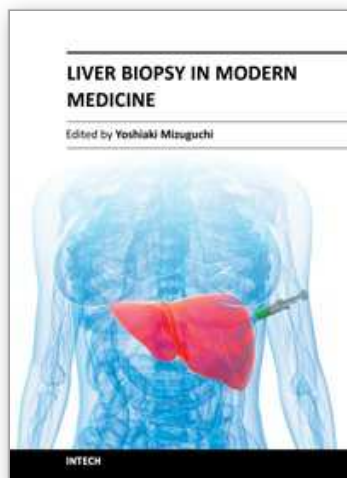
- Kawada N (2011). Evolution of hepatic fibrosis research. *Hepatol Res* 2011 Mar; 41: 199–208.
- Kisseleva T, Uchinami H, Feirt N, Quintana-Bustamante O, Segovia JC, Schwabe RF, et al (2006). Bone marrow derived fibrocytes participate in pathogenesis of liver fibrosis. *J Hepatol* 2006 Sep; 45: 429–38.
- Knodell RG, Ishak KG, Black WC, Chen TS, Craig R, Kaplowitz N, et al (1981). Formulation and application of a numerical scoring system for assessing histological activity in asymptomatic chronic active hepatitis. *Hepatology* 1981 Sep-Oct; 1: 431–5.
- Kotlyar D, Blonski W & Rustgi V (2008). Noninvasive Monitoring of Hepatitis C Fibrosis Progression. *Clin Liver Dis* 2008 Aug; 12(3): 557–71.
- Lackner C, Struber G, Liegl B, Leibl S, Ofner P, Bankuti C, et al (2005). Comparison and validation of simple noninvasive tests for prediction of fibrosis in chronic hepatitis C. *Hepatology* 2005 Jun; 41: 1376–82.
- Leclercq IA, Farrell GC, Schriemer R & Robertson GR (2002). Leptin is essential for the hepatic fibrogenic response to chronic liver injury. *J Hepatol* 2002 Aug; 37: 206–13.
- Lee JS, Semela D, Iredale J & Shah VH (2007). Sinusoidal remodeling and angiogenesis: a new function for the liver-specific pericyte? *Hepatology* 2007 Mar; 45: 817–25.
- Lee UE & Friedman SL (2011). Mechanisms of hepatic fibrogenesis. *Best Practice & Research Clinical Gastroenterology* 2011 Apr; 25(2): 195–206.
- Ono E, Shiratori Y, Okudaira T, Imamura M, Teratani T, Kanai F, et al (1999). Platelet count reflects stage of chronic hepatitis C. *Hepatol Res* 1999 Aug; 15: 192–200.
- Paggi S, Colli A, Fraquelli M, Viganò M, Del Poggio P, Facciotto C, et al (2008). A noninvasive algorithm accurately predicts advanced fibrosis in hepatitis C: a comparison using histology with internal-external validation. *J Hepatol* 2008 Oct; 49 :564–71.
- Palmeri ML, Frinkley KD, Zhai L, Gottfried M, Bentley RC, Ludwig K, et al (2005). Acoustic radiation force impulse (ARFI) imaging of the gastrointestinal tract. *Ultrason Imaging* 2005 Apr; 27: 75–88.
- Pinzani M & Rombouts K (2004). Liver fibrosis: from the bench to clinical targets. *Dig Liver Dis* 2004 Apr; 36: 231–42.
- Pinzani M, Rosselli M & Zuckermann M (2011). Liver cirrhosis. *Best Practice & Research Clinical Gastroenterology* 2011; 25(2): 281–90.
- Pohl A, Behling C, Oliver D, Kilani M, Monson P & Hassanein T (2001). Serum aminotransferase levels and platelet counts as predictors of degree of fibrosis in chronic hepatitis C virus infection. *Am J Gastroenterol* 2001 Nov; 96: 3142–6.
- Powell LW & Ker JF (1970). Reversal of “cirrhosis” in idiopathic hemochromatosis following long-term intensive venesection therapy. *Australas Ann Med* 1970 Feb; 2: 54–7.
- Poynard T, Bedossa P, METAVIR and CLINIVIR cooperative study groups (1997). Age and platelet count: a simple index for predicting the presence of histological lesions in patients with antibodies to hepatitis C virus. *J Viral Hepat* 1997 May; 4: 199–208.
- Poynard T, Imbert-Bismut F, Ratziu V, Chevret S, Jardel C, Moussalli J, et al (2002). Biochemical markers of liver fibrosis in patients infected by hepatitis C

- virus: longitudinal validation in a randomized trial. *J Viral Hepat* 2002 Mar; 9: 128-33.
- Poynard T, McHutchison J, Manns M, Trepo C, Lindsay K, Goodman Z, et al (2002). Impact of pegylated interferon alfa-2b and ribavirin on liver fibrosis in patients with chronic hepatitis C. *Gastroenterology* 2002 May; 122: 1303-13.
- Regev A, Berho M, Jeffers LT, Milikowski C, Molina EG, Pyrsopoulos T, et al (2002). Sampling error and intraobserver variability in liver biopsy in patients with chronic HCV infection. *Am J Gastroenterol* 2002 Oct; 15: 945-51.
- Rockey DC, Caldwell SH, Goodman ZD, Nelson RC & Smith AD (2009). American Association for the Study of Liver Diseases. Liver biopsy. *Hepatology* 2009 Mar; 49:1017-44.
- Saadeh S, Cammell G, Carey WD, Younossi Z, Barnes D & Easley K (2001). The role of liver biopsy in chronic hepatitis C. *Hepatology* 2001; 33: 196-200.
- Sawitzka I, Kordes C, Reister S & Häussinger D (2009). The niche of stellate cells within rat liver. *Hepatology* 2009 Nov; 50: 1617-24.
- Sebastiani G, Halfon P, Castera L, Pol S, Thomas DL, Mangia A, et al (2009). SAFE biopsy: a validated method for large-scale staging of liver fibrosis in chronic hepatitis C. *Hepatology* 2009 Jun; 49: 1821-7.
- Sporea I, Popescu A & Sirli R (2008). Why, who and how should perform liver biopsy in chronic liver diseases. *World J Gastroenterol* 2008 Jun; 14 (21):3396-402.
- Syn WK, Choi SS, Liaskou E, Karaca GF, Agboola KM, Oo YH, et al (2011). Osteopontin is induced by hedgehog pathway activation and promotes fibrosis progression in nonalcoholic steatohepatitis. *Hepatology* 2011 Jan; 53: 106-15.
- Talwalkar JA, Gross JB, Venkatesh SK, Yin M, Glockner J, Takahashi N, et al (2008). Magnetic resonance elastography for the detection of moderate to severe hepatic fibrosis. *Hepatology* 2008; 48 (Suppl 1):1110A.
- Talwalkar JA, Kurtz DM, Schoenleber SJ, West CP, Montori VM (2007). Ultrasound-based transient elastography for the detection of hepatic fibrosis: systematic review and meta-analysis. *Clin Gastroenterol Hepatol* 2007 Oct; 5:1214-20.
- Vallet-Pichard A, Mallet V, Nalpas B, Verkarre V, Nalpas A, Dhalluin-Venier V, et al (2007). FIB-4: an inexpensive and accurate marker of fibrosis in HCV infection. comparison with liver biopsy and fibrotest. *Hepatology* 2007 Jul; 46: 32-6.
- Wai CT, Greenson JK, Fontana RJ, Kalbfleisch JD, Marrero JA, Conjeevaram HS, et al (2003). A simple noninvasive index can predict both significant fibrosis and cirrhosis in patients with chronic hepatitis C. *Hepatology* 2003 Aug; 38: 518-26.
- Weber S, Gressner OA, Hall R, Grünhage F & Lammert F (2008). Genetic Determinants in Hepatic Fibrosis: From Experimental Models to Fibrogenic Gene Signatures in Humans. *Clinics in liver disease* 2008 Nov; 12(4):747-57.
- Williams AL & Hoofnagle JH (1988). Ratio of serum aspartate to alanine aminotransferase in chronic hepatitis. Relationship to cirrhosis. *Gastroenterology* 1988 Sep; 95 :734-9.
- Yin M, Talwalkar JA, Glaser KJ, Manduca A, Grimm RC, Rossman PJ, et al (2007). Assessment of hepatic fibrosis with magnetic resonance elastography. *Clin Gastroenterol Hepatol* 2007 Oct; 5:1207-13.
- Zeisberg M, Yang C, Martino M, Duncan MB, Rieder F, Tanjore H, et al (2007). Fibroblasts derive from hepatocytes in liver fibrosis via epithelial to mesenchymal transition. *J Biol Chem* 2007 Aug; 282:23337-47.

Ziol M, Handra-Luca A, Kettaneh A, Christidis C, Mal F, Kazemi F, et al (2005). Noninvasive assessment of liver fibrosis by measurement of stiffness in patients with chronic hepatitis C. *Hepatology* 2005 Jan; 41: 48-54.

IntechOpen

IntechOpen



Liver Biopsy in Modern Medicine

Edited by Dr. Yoshiaki Mizuguchi

ISBN 978-953-307-883-0

Hard cover, 378 pages

Publisher InTech

Published online 10, October, 2011

Published in print edition October, 2011

Liver biopsy, first performed by Paul Ehrlich in 1883, remains an important diagnostic procedure for the management of hepatobiliary disorders and the candidate/donated organ for transplantation. The book "Liver biopsy in Modern Medicine" comprises 21 chapters covering the various aspects of the biopsy procedure in detail and provides an up-to-date insightful coverage to the recent advances in the management of the various disorders with liver biopsy. This book will keep up with cutting edge understanding of liver biopsy to many clinicians, physicians, scientists, pharmaceuticals, engineers and other experts in a wide variety of different disciplines.

How to reference

In order to correctly reference this scholarly work, feel free to copy and paste the following:

Mona H. Ismail (2011). Reversal of Liver Fibrosis: A Review, Liver Biopsy in Modern Medicine, Dr. Yoshiaki Mizuguchi (Ed.), ISBN: 978-953-307-883-0, InTech, Available from: <http://www.intechopen.com/books/liver-biopsy-in-modern-medicine/reversal-of-liver-fibrosis-a-review>

INTech
open science | open minds

InTech Europe

University Campus STeP Ri
Slavka Krautzeka 83/A
51000 Rijeka, Croatia
Phone: +385 (51) 770 447
Fax: +385 (51) 686 166
www.intechopen.com

InTech China

Unit 405, Office Block, Hotel Equatorial Shanghai
No.65, Yan An Road (West), Shanghai, 200040, China
中国上海市延安西路65号上海国际贵都大饭店办公楼405单元
Phone: +86-21-62489820
Fax: +86-21-62489821

© 2011 The Author(s). Licensee IntechOpen. This is an open access article distributed under the terms of the [Creative Commons Attribution 3.0 License](https://creativecommons.org/licenses/by/3.0/), which permits unrestricted use, distribution, and reproduction in any medium, provided the original work is properly cited.

IntechOpen

IntechOpen