

We are IntechOpen, the world's leading publisher of Open Access books Built by scientists, for scientists

6,900

Open access books available

186,000

International authors and editors

200M

Downloads

Our authors are among the

154

Countries delivered to

TOP 1%

most cited scientists

12.2%

Contributors from top 500 universities



WEB OF SCIENCE™

Selection of our books indexed in the Book Citation Index
in Web of Science™ Core Collection (BKCI)

Interested in publishing with us?
Contact book.department@intechopen.com

Numbers displayed above are based on latest data collected.
For more information visit www.intechopen.com



Promising Experimental Therapies for Metastatic Melanoma

Bao Lam, Patrick A. Ott and Anna C. Pavlick
*New York University School of Medicine
 USA*

1. Introduction

Advanced melanoma has the highest per-death loss of years of potential life expectancy second only to adult leukemia. The incidence of melanoma continues to rise worldwide at approximately 3% per year, and in 2009 there were an estimated 68,720 new cases in the United States and 8650 deaths (Balch et al. 2009). According to Surveillance Epidemiology and End Results (SEER) data, roughly 4% of melanomas are metastatic at time of diagnosis. Locally advanced or recurrent unresectable, and disseminated melanoma is notoriously unresponsive to standard treatment, and is associated with a dismal prognosis. Patients with metastatic melanoma have a median survival of 8 months and 2-year survival rates of 10% to 15%. (Tsao et al. 2004). Until March of 2011, only 2 drugs were approved by the Food and Drug Administration (FDA) in the United States (US) for metastatic melanoma: interleukin 2 (IL-2) and dacarbazine (ipilimumab was approved in March of 2011 and will be discussed in this chapter). Dacarbazine is an alkylating agent that in 1975 became the first chemotherapeutic drug approved by the US FDA for metastatic melanoma. Response rates for this regimen were 20% in a 30-year overview (Serrone et al. 2000), whereas more recent studies showed response rates in the 10-14% range (Bedikian et al. 2006; Chapman et al. 1999; Middleton et al. 2000). Temozolomide, an orally available congener of dacarbazine, was shown to be non-inferior in efficacy in comparison to dacarbazine in a randomized phase III trial (Middleton et al. 2000). Temozolomide had a similar objective response rate and overall survival compared to dacarbazine, and a significantly longer disease free survival. IL-2 was approved by the US FDA in 1998 for the treatment of metastatic melanoma. Single agent IL-2, when given in high dose intravenous boluses, leads to objective responses in 16% of patients, with complete responses in 6% and partial responses in 10%. Many patients maintained a complete response even after 7 years follow-up (Atkins et al. 2000). The toxicities of high dose IL-2 are substantial, including constitutional symptoms (fevers, chills, fatigue), hypotension, renal insufficiency, emesis, diarrhea and thrombocytopenia, and up to 2% of mortality is directly related to the treatment (Atkins et al. 2000). A systemic review of 41 randomized clinical trials including patients receiving various treatment schedules including biochemotherapy did not show improved progression-free survival (PFS) or overall survival (OS) (Eigentler et al. 2003). More recently, another meta-analysis of 18 trials involving nearly 2,500 patients with metastatic melanoma suggested an increase in response rate to biochemotherapy, but overall survival was not improved (Ives et al. 2007). Until today, biochemotherapy and combination chemotherapy built upon IL-2 and dacarbazine or temozolomide has not shown statistically

significant improvement in overall survival and cannot be regarded as standard therapeutic options for metastatic melanoma. Thus, more effective treatment modalities are urgently needed.

2. Agents targeting the immune system

2.1 CTLA-4

Increasing knowledge of T-cell regulation has uncovered potential immunologic targets for the treatment of melanoma. The interaction between antigen-presenting cells (APC) and T lymphocytes is crucial for inducing melanoma-specific T-cell responses. In addition to the antigen specific interaction between the HLA peptide complex on the APC and the T-cell receptor (TCR), several different co-stimulatory and co-inhibitory molecules modulate the T cell response. For instance, the T-cell surface molecule CD28 interacts with the B7 receptor on the APC to mediate a co-stimulatory signal (which is necessary in addition to the HLA-peptide-TCR interaction for efficient priming of the T cell), whereas the T-cell cytotoxic T-lymphocyte antigen (CTLA)-4 interacts with B7 to downregulate T-cell activation, acting as a natural “checkpoint” on the T-cell mediated immunologic response. Blocking interaction between CTLA-4 and B7 can overcome this checkpoint and enhance T-cell-mediated antitumor activity. This can be achieved by an anti-CTLA-4 monoclonal antibody (mAb). To date, two fully human anti-CTLA-4 mAb's have been developed for metastatic melanoma: tremelimumab (CP-675,206; Pfizer Inc., New York) and ipilimumab (MDX-010; Bristol-Myers, New Jersey).

In the initial phase I study, tremelimumab was relatively well tolerated and demonstrated encouraging clinical activity including several complete responses. However, in a randomized phase III study comparing single-agent tremelimumab with either dacarbazine or temozolomide in patients with advanced melanoma, tremelimumab failed to demonstrate a significant improvement in OS in comparison to standard chemotherapy (Ribas 2008). On the other hand, ipilimumab, in a randomized phase III clinical trial comparing ipilimumab alone versus gp100 vaccine alone to the combination of ipilimumab and gp100 vaccine, resulted in improved OS of nearly four months (median survival duration of 10.1 and 10.0 months in the ipilimumab arm and the combined arm, respectively, in comparison to 6.4 months in the vaccination alone (HR 0.66; 95% CI = 0.51-0.87; $p = .033$ and HR 0.68; 95% CI = 0.55-0.85; $p < .001$, respectively). A total of 676 HLA-A*0201-positive patients with unresectable stage III or IV melanoma, whose disease had progressed after one or more of the following therapeutic regimens: dacarbazine, temozolomide, fotemustine, carboplatin, or interleukin-2, were included in this study. This was the first randomized clinical trial that showed a statistically significant improvement in OS for metastatic melanoma (Hodi et al. 2010). This agent has now received FDA approval for use in metastatic melanoma.

The activity and side-effect profile of anti-CTLA-4 antibodies have several characteristics that reflect their immune-mediated mechanism of action. Objective responses observed in patients with metastatic melanoma with either tremelimumab or ipilimumab were seen in approximately 7-10% of patients. Remarkably, as much as 70% of responses were durable (Hodi et al. 2010; Ribas 2008). The unique pattern of response to CTLA-4 mAbs such as initial apparent progression of disease, even with emergence of new lesions, followed by regression and responses over the course of several months to years, has been seen with these agents (Hamid 2007). The recognition of this unusual kinetics of response has led to a

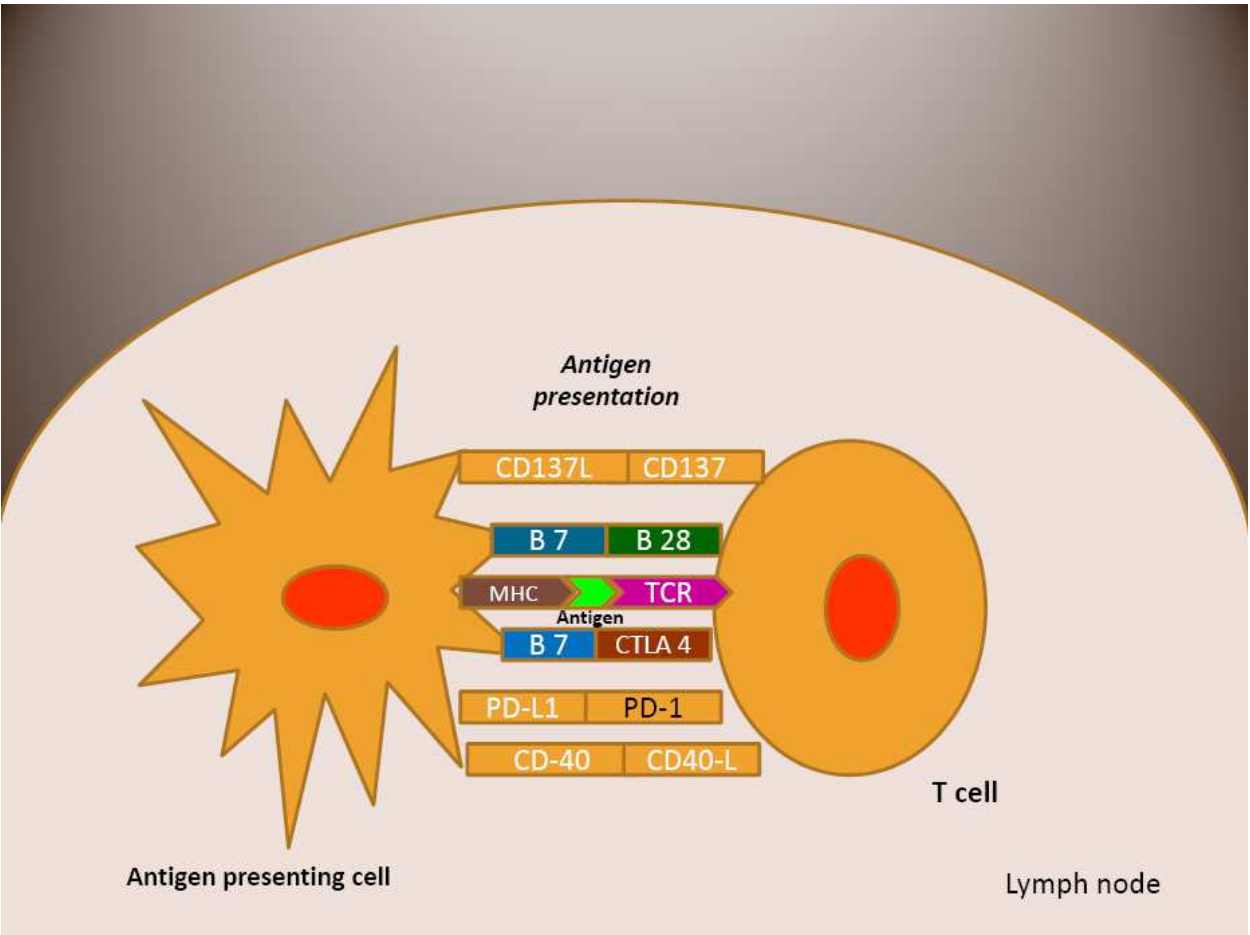


Fig. 1. T-cell response in melanoma: co-stimulatory and co-inhibitory signals. B7 proteins on antigen-presenting cells serve as ligands for both CD28 receptors and CTLA-4 inhibitory molecules on T cells. Upon T-cell receptor binding to antigen presented on MHCs, B7 proteins expressed on APCs can bind to CD28 or CTLA-4 receptors on T cells depending upon the precise expression patterns of the receptors and ligands and on the state of activation of the respective cells. Ligation of B7 to the CTLA-4 receptor results in inhibitory signals for T-cell activation and proliferation. Conversely, ligation of CD28 provides stimulatory signals to T cells leading to their activation. Interaction between PD-1 and PD-L1 results in inhibitory signals, whereas interaction between CD40 and CD40-L leads to T cell activation. Ag: antigen; CTLA-4: cytotoxic T-lymphocyte antigen 4; PD-1: programmed death 1; TCR: T-cell receptor.

proposal of immune-related response criteria (irRC) when evaluating treatment responses to anti-CTLA-4 mAb's (Wolchok JD 2009) (table 1). Immune related response criteria should replace currently accepted Response Evaluation Criteria in Solid Tumors (RECIST) for the evaluation of melanoma patients treated with immunotherapy. Indeed, it is possible that clinical efficacy of tremelimumab may have been missed in the phase III clinical trial owing to the failure to recognize that immune response criteria are needed for adequate response assessment.

The growing clinical experience with anti-CTLA-4 mAbs also identifies a constellation of autoimmune side effects, which have been designated "immune-related adverse events" or irAEs (Di Giacomo et al. 2010). These irAEs, including rash, autoimmune colitis, hepatitis,

	RECIST	irRC
New, measurable lesions (i.e., $\geq 5 \times 5$ mm)	Always represent PD	Incorporated into tumor burden
New, nonmeasurable lesions (i.e., $< 5 \times 5$ mm)	Always represent PD	Do not define progression (but preclude irCR)
Non-index lesions	Changes contribute to defining BOR of CR, PR, SD, and PD	Contribute to defining irCR (complete disappearance required)
CR	Disappearance of all lesions in two consecutive observations not less than 4 wk apart	Disappearance of all lesions in two consecutive observations not less than 4 wk apart
PR	$\geq 50\%$ decrease in SPD of all index lesions compared with baseline in two observations at least 4 wk apart, in absence of new lesions or unequivocal progression of non-index lesions	$\geq 50\%$ decrease in tumor burden compared with baseline in two observations at least 4 wk apart
SD	50% decrease in SPD compared with baseline cannot be established nor 25% increase compared with nadir, in absence of new lesions or unequivocal progression of non-index lesions	50% decrease in tumor burden compared with baseline cannot be established nor 25% increase compared with nadir
PD	At least 25% increase in SPD compared with nadir and/or unequivocal progression of non-index lesions and/or appearance of new lesions (at any single time point)	At least 25% increase in tumor burden compared with nadir (at any single time point) in two consecutive observations at least 4 wk apart

Table 1. Comparison between RECIST criteria and the irRC. BOR: best overall response; irCR: immune-related complete response; PD: progressive disease; PR: partial response; SD: stable disease; SPD: sum of the products of the two largest perpendicular diameters.

and less frequently hypophysitis and uveitis tend to be not harmful provided the clinician is aware of these unusual side effects, monitors the symptoms adequately, and knows when to intervene. IrAEs are thought to be a result of non-specific or cross-reactive tissue damage caused by activated T-cells. The most commonly reported rash is a macular and papular exanthema affecting trunk and extremities, which has been reported in 47–68 % of patients (O'Day et al. 2010; Weber et al. 2009; Wolchok et al. 2010). These dermatologic irAEs are generally mild and symptomatic relief is provided by antihistamines, while grade 3/4 autoimmune dermatitis is successfully treated with slowly tapered corticosteroids. At our institution, we reported the unique occurrence of hair depigmentation following therapy with CTLA-4 monoclonal antibody that correlated with durable clinical responses (figure 2). Six of 43 patients developed sudden hair depigmentation starting with the eyebrows, and continued to have either complete depigmentation of all body hair or the development of diffuse vitiligo. The median time to depigmentation was 10 months. All of these patients achieved partial response or complete response that sustained during the follow-up period of 24–36 months (Pavlick 2010).

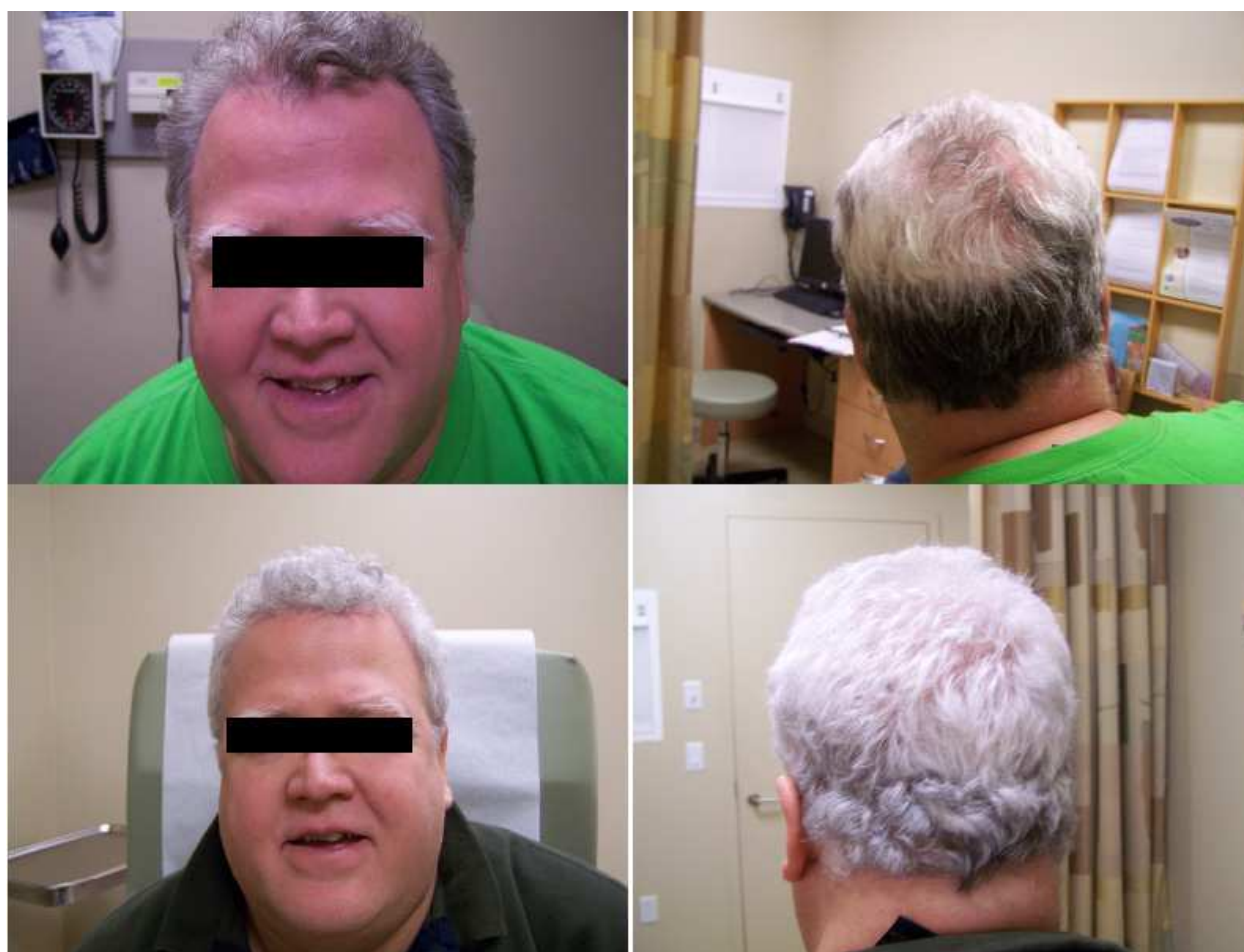

Fig. 2. Progressive hair depigmentation due to ipilimumab over 3-month period. These photographs are published with patient's permission.

Diarrhea due to immune-mediated colitis is the most frequent gastrointestinal irAE; if untreated, it may lead to serious complications such as intestinal perforation (<1%) (Beck et al. 2006). Although grade 3–4 diarrhea is generally reversible with standard anti-

inflammatory therapies, experience suggests that patients with colitis treated with high-dose corticosteroids combined with mesalamine, and with seeming resolution of the adverse effects, can have an early recrudescence of the symptoms requiring either prolonged corticosteroid administration, tumor necrosis factor (TNF) blockade with infliximab, or prolonged bowel rest with total parenteral hyperalimentation (Yang et al. 2007). Other irAEs such as hepatitis, iridocyclitis and endocrinopathies including hypophysitis, hypothyroidism and adrenal insufficiency are uncommon but worth mentioning. Hepatitis generally presents as asymptomatic rise in the levels of alanine aminotransferase (ALT) and aspartate aminotransferase (AST). In most cases, a delayed schedule of anti-CTLA 4 mAb leads to normalization of these levels. However, unlike other irAEs, hypophysitis, which occurs in 1.5% of patients treated with ipilimumab (Hodi et al. 2010) often does not improve with high-dose corticosteroids, and permanent hormone replacement therapy is required. Similarly the frequency of hypothyroidism and adrenal insufficiency is 1.5% each (Hodi et al. 2010). Interestingly, development and increasing severity of irAEs generally associate with tumor regression and with a prolonged time to relapse; nevertheless, this association is not absolute and patients without evidence of irAEs have also experienced significant clinical responses (Downey et al. 2007; Kahler and Hauschild 2010).

Melanoma is notorious for its propensity to metastasize to the brain. Up to 75% of patients develop this complication in autopsy series (de la Monte et al. 1983; Patel et al. 1978), and at least one third to one half of patients in clinical practice are found to have one or more brain metastases during the clinical course of their metastatic disease (Amer et al. 1978; Sampson et al. 1998). Brain metastasis portends a grave prognosis. The currently available treatment options for brain metastasis from melanoma include surgical and radiation therapies which may improve the outcome of selected patients with brain metastasis. The most favorable outcomes have been reported in patients who are candidates for stereotactic radiosurgery (Fife et al. 2004). Even though systemic treatment using cytotoxic agents, such as temozolomide in the US, often is employed in the setting of brain metastasis by virtue of the ability of temozolomide to cross the blood-brain barrier, its impact on overall survival remains unproven (Agarwala et al. 2004; Antonadou et al. 2002; Hwu et al. 2005). Up to date, no single treatment modality has been systematically tested in a randomized clinical trial to demonstrate an impact on disease-specific survival. Encouragingly, treatment with CTLA-4 mAb has resulted in durable control of brain metastases (Hodi et al. 2008b; Margolin et al. 2010; Schartz et al. 2010). While the phase III trials with ipilimumab excluded patients with prior or current brain metastasis, a parallel expanded access trial of ipilimumab enrolled patients who were later found to have small brain metastases that had not been treated with radiation. Among those patients, several were noted to have tumor regression in the brain. This unexpected observation led to a clinical trial initiated by the Cytokine Working Group specifically designed for melanoma patients with one or more brain metastases that did not require immediate surgery or radiotherapy. In this trial, patients were candidates for ipilimumab therapy if they had no systemic disease, untreated disease, or were no longer responding to a prior regimen for systemic disease. Brain metastases and extracranial disease were assessed separately, using standard criteria for tumor assessment based on the World Health Organization system and a composite global response status. The results of this trial, reported at the 2010 ASCO meeting, were encouraging. At week 12, for brain alone, the disease control rate was 21.5% (5 of 51 patients

achieved partial response, and 6 of 51 patients achieved stable disease); the duration of brain disease control ranged from 3 to 15 months (Lawrence 2010).

2.2 PD-1

The programmed death 1 (PD-1) receptor is a negative regulator of antigen-activated T cells (Fourcade et al. 2009). It bears homology to CTLA-4 but provides distinct co-inhibitory signals. The cytoplasmic domain of PD-1 contains 2 tyrosine signaling motifs that can attenuate the TCR/CD28 signal (Parry et al. 2005). There are two known ligands for PD-1: B7-H1/PD-L1 (hereafter PD-L1), the predominant mediator of PD-1-dependent immunosuppression, and B7-DC/PD-L2. PD-L1 is expressed by many tumors including melanoma, and its interaction with PD-1 resulted in tumor escape in experimental models (Iwai et al. 2002). Blockade of the PD-1: PD-L1 pathway in combination with prolonged antigen stimulation with melanoma cells augments the number of cytokine-producing, proliferating, and total NY-ESO-1-specific CD8⁺ T cells. In murine tumor models, the inhibition of PD-1: PD-L1 interactions was shown to reverse the generation of functional anergy and exhaustion in CD8⁺ T cells (Chikuma et al. 2009), and to restore a considerable proportion of the effector activity of CD8⁺ T cells (Blank et al. 2004), which can reinstate their antitumor effects (Blank et al. 2004; Iwai et al. 2002; Strome et al. 2003). Current data indicate that there is a correlation between the degree of PD-L1 expression and the vertical growth of primary tumors in melanoma (Hino et al. 2010). Multivariate analysis demonstrated that PD-L1 expression is an independent prognostic factor for melanoma (Hino et al. 2010). Therefore, blockade of PD-1: PD-L1 interaction represents a rational strategy for cancer immunotherapy.

MDX-1106 (BMS-936558/ONO-4538) is a fully human immunoglobulin G4 (IgG4) mAb specific for PD-1. The drug binds PD-1 with high affinity and blocks its interaction with both PD-L1 and PD-L2. A phase I study of single agent MDX-1106 in refractory solid tumors was conducted in 39 patients with advanced metastatic non-small cell lung carcinoma (NSCLC), melanoma, castrate-resistant prostate cancer, renal cell carcinoma (RCC), or colorectal carcinoma (CRC). Although efficacy was not the primary endpoint of this phase I study, of the 39 treated patients, 1 durable complete response (CRC) and 2 partial responses (melanoma, RCC) were seen. Two additional patients (melanoma, NSCLC) had significant lesional tumor regressions, which did not meet criteria for PR. This study suggested a more benign immune-related toxicity profile for anti-PD-1 mAb than one seen associated with anti-CTLA-4 mAb. Only 1 patient with metastatic ocular melanoma developed grade 3 inflammatory colitis following five doses (1 mg/kg) administered over 8 months, which responded to steroids and infliximab, while grade 2 immune related adverse events occurred in 3 patients presenting with polyarticular arthropathies requiring oral steroids and hypothyroidism requiring hormone replacement. (Brahmer et al. 2010). Another phase I trial was conducted on 16 patients with metastatic disease including melanoma. Objective responses were documented in 37.5% of patients lasting 3-13+ months; half of the patients had melanoma and there were few irAEs (Sznol 2010).

2.3 Adoptive cell therapy

The transfer of tumor specific T cells has emerged as a promising therapeutic strategy for melanoma. Adoptive cell therapy (ACT) was pioneered at the Surgery Branch of the National Cancer Institute (NCI; Bethesda, MD), and to date, has shown some of the most

impressive response rates (up to 72%) in patients with metastatic melanoma. The most developed approach is based on the *ex vivo* selection of highly reactive, tumor-infiltrating lymphocytes (TIL), their activation and numerical expansion before reinfusion to the autologous tumor-bearing host (Dudley et al. 2005). Adoptive transfer after a nonmyeloablative conditioning regimen was shown to result in the persistent clonal repopulation of T-cells in patients with metastatic melanoma, with the transferred cells proliferating *in vivo*, displaying functional activity, and trafficking to tumor sites (Dudley et al. 2002).

By eliminating competition for endogenous serum cytokines, lymphodepletion may affect survival and proliferation of the adoptively transferred TIL. Data from animal models suggested that increased levels of lymphodepletion could improve ACT efficacy. In murine models, lymphodepletion seemed to enhance the antitumor effects of transferred T cells *in vivo* by several mechanisms including the elimination of suppressive CD4+, CD25+ T-regulatory lymphocytes, the elimination of cellular “sinks” for homeostatic cytokines such as IL-7 and IL-15, and the engagement of toll-like receptors on antigen-presenting cells after damage to the integrity of the gut epithelial lining (Antony et al. 2005; Gattinoni et al. 2005; Paulos et al. 2007). Cyclophosphamide and fludarabine have been employed for nonmyeloablative lymphodepletion. In a series of 35 patients, Dudley et al. showed that adoptive transfer of autologous TIL after nonmyeloablative but lymphodepleting chemotherapy with cyclophosphamide and fludarabine followed by high dose IL-2 resulted in objective responses in 51% of heavily pretreated patients with metastatic melanoma (Dudley et al. 2005). Further increasing intensity of host preparative lymphodepletion by adding total-body irradiation (TBI) of either 2 or 12 Gy prior to cell transfer in cyclophosphamide and fludarabine lymphodepleted patients was shown to generate response rates up to 52% and 72%, respectively. Of the 25 patients studied in the 12 Gy TBI arm, there were 4 complete responders and at least 2 substantial partial responders (Dudley et al. 2008).

The caveat of adoptive cell therapy is its complexity of several critical preparative steps that are both labor intensive and costly which may be the major obstacle to the widespread application of this approach. Up to 4 to 6 weeks of cell culture are required to obtain adequate numbers of reactive lymphocytes for adoptive transfer. Additionally, much akin to the limitation of high dose IL-2, only patients with an excellent functional status are able to withstand the intensity of adoptive cell therapy which may also involve TBI in addition to IL-2. On the other hand, as the data from the NCI suggest, such potent therapy in highly selected patients does have the potential to induce durable responses and a potential cure. To date, however, only small phase II clinical trials have been completed and no phase III study has been initiated. Meanwhile, further innovations beyond current TIL technology are underway. Current strategies seek to improve the yield of TIL cultures, to use vaccines to stimulate the transferred T cells *in vivo*, and to employ gene therapy using genetically engineered lymphocytes that express highly reactive T-cell receptors (TCRs) with specific anti-melanoma differentiation antigen activity (gp-100 or MART-1), produce IL-2 or other molecules promoting an effective immune response. The gene therapy approach is of particular interest because the anti-tumor effector T cells could be rapidly expanded for adoptive transfer. Furthermore, it could be of tremendous benefit to patients who do not have autologous reactive TIL available and would otherwise be ineligible for adoptive immunotherapy (Johnson et al. 2009; Yang et al. 2010). The objective response rates in trials employing gene therapy have been reported to be 20% to 45%, and durable tumor

regression at all disease sites including the brain has also been observed (Johnson et al. 2009; Morgan et al. 2006; Robbins et al. 2011).

3. Agents targeting oncogenic signaling pathways

The MAPK pathway (figure 3) has been of keen interest in melanoma in particular since Davies et al. first reported that 66% of melanomas harbor activating somatic missense mutations in the BRAF gene (V600E), leading to constitutive activation of this pathway (Davies et al. 2002; Meier et al. 2005). The RAF/MEK/ERK pathway is an important regulator of growth, survival and migration and it is constitutively activated in many human cancers (Fecher et al. 2008). Physiologically, the RAF/MEK/ERK signaling pathway is activated upon binding of extracellular ligands to growth factor receptors with intrinsic tyrosine kinase activity such as epidermal growth factor receptor (EGFR), c-Kit, platelet-derived growth factor receptor (PDGFR), vascular endothelial growth factor receptor

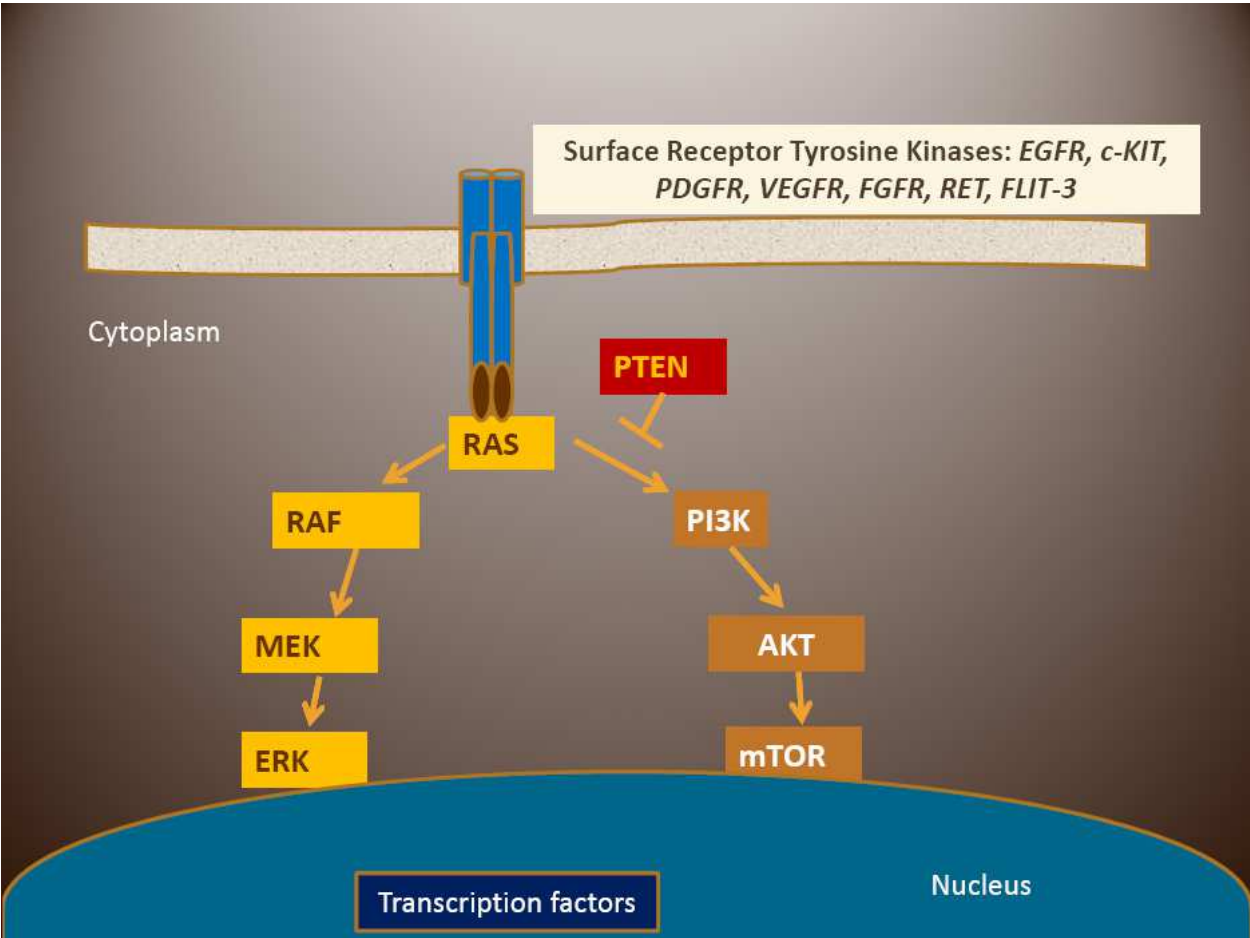


Fig. 3. Molecular targets in melanoma: the MAPK and PI3K pathways. Binding of growth factors to cell surface receptors induces their dimerization and activation of the MAPK tyrosine kinase cascade, which includes RAS RAF, MEK and ERK. Activated (phosphorylated) ERK translocates into the nucleus, and phosphorylates transcription factors for genes involved in cell growth and proliferation. This pathway is constitutively activated in many human melanomas. An alternate pathway via PI3K, AKT, and mTOR is also activated in some melanomas.

(VEGFR), and fibroblast growth factor receptor (FGFR). Signaling through the RAF/MEK/ERK pathway eventually leads to the transcription of hundreds if not thousands of genes related to cellular proliferation, survival, apoptosis, tumor invasion, and motility (Fecher et al. 2008; Shields et al. 2007). Another kinase signaling pathway involves PI3K/AKT activating mTOR which promotes signaling to the nucleus and activates genes involved in cell growth and proliferation (Stahl et al. 2004). Studies have shown that a high proportion of melanomas carry alterations in the PI3K/AKT pathway (PTEN deletion or AKT amplification) independent of the BRAF^{V600E} mutation (Haluska et al. 2007; Vivanco and Sawyers 2002). These findings reveal a complex, interlinked network of cellular signaling pathways that contain several potentially synergistic therapeutic targets for metastatic melanoma.

3.1 RAF

Sorafenib (Bay 43-9006) was the first RAF inhibitor to enter early clinical trials. It is a small-molecule, multi-targeted tyrosine kinase inhibitor that blocks EGFR, c-Kit, Flt-3, PDGF and VEGF in addition to BRAF (Adnane et al. 2006; Wilhelm et al. 2004). Although Sorafenib does not have meaningful activity in melanoma as a single agent (Eisen et al. 2006; Ott et al. 2010), its use in combination with dacarbazine or temozolomide led to superior objective responses and progression-free survival compared to historical response rates to these agents (Amaravadi et al. 2009). However, in a phase III randomized trial (E2603) comparing carboplatin, paclitaxel and sorafenib versus carboplatin, paclitaxel and placebo in chemotherapy-naïve patients, the futility analysis demonstrated no benefit of the three drug combination compared to the two drug chemotherapy combination. In the PRISM study, the addition of Sorafenib to the combination of carboplatin and paclitaxel as second-line treatment after chemotherapy with dacarbazine or temozolomide failed to improve progression-free survival, response rate and time-to-disease progression in metastatic melanoma patients (Hauschild et al. 2009).

Since then, second generation selective RAF inhibitors have been developed and are actively tested in various clinical trials. RG7204 (Roche Pharmaceuticals, formerly PLX4032, Plexxikon) is an oral, highly selective inhibitor of the oncogenic V600E mutant BRAF kinase, which showed promising results in early clinical studies. In a dose-finding phase I trial, 11/16 (68%) of patients with mutant BRAF metastatic melanoma achieved PR and four patients had minor responses leading to a PFS of 8-9 months (Flaherty 2009). A dose extension phase I trial with 32 patients demonstrated an objective response rate of 81% (2 CRs, 24 PRs) (Flaherty et al. 2010). The median PFS among these patients was more than 7 months. RG7204 is generally well tolerated with rash, photosensitivity, arthralgia and nausea. Of note, 31% of patients developed grade 3 squamous cell carcinoma (SCC), keratoacanthoma (KA) type. The median time to the appearance of a cutaneous squamous cell carcinoma was 8 weeks with no reported involvement of other organs. Treatment with RG7204 was not interrupted by the appearance of these skin lesions and the majority of them were resected (Flaherty et al. 2010). On the basis of these promising results, a phase II trial (BRIM 2) is now fully accrued and a phase III trial (BRIM 3) met its primary end points with RG7204 improving both PFS and OS (Chapman, PB, N Engl J Med. 2011 Jun 30;364(26):2507-16. Epub 2011 Jun 5) comparing RG7204 to dacarbazine in untreated patients with BRAF V600E mutant metastatic melanoma.

GSK 2118436 is another oral, highly potent and selective inhibitor of the V600E/K/D mutant BRAF. In a phase I/II study, treatment with GSK 2118436 led to a decrease in FDG-PET metabolic uptake with 11/14 (79%) of melanoma patients showing a decrease from baseline (range -5 to -100%), and 18/30 (60%) patients demonstrated a > 20% tumor decrease by RECIST at first restaging (8-9 wks). GSK 2118436 showed good tolerability and low grade nausea, vomiting, fatigue, headaches and skin changes (including low grade SCC) were the main adverse effects (Kefford 2010). A phase II study of GSK2118436 as salvage therapy (NCT01153763), and a phase III study of GSK2118436 versus dacarbazine (NCT01227889) as front line therapy for mutant BRAF metastatic melanoma patients are underway.

Judging from the data available to date and the experience in our center, selective RAF inhibitors are relatively well tolerated, high grade adverse events are uncommon. Unique side effects associated with these novel drugs are the emergence of KA and SCC. These lesions can appear as early as 2 weeks after the initiation of therapy and are reported in 15-30% of the patients (Arnault et al. 2009; Flaherty et al. 2010). Histologically, KA is almost indistinguishable from a well differentiated SCC. In contrast to KA, SCC is a malignant lesion that does not regress spontaneously and has the potential for metastasis. The biologic mechanism and natural history of these lesions in the context of RAF inhibitors, in comparison to their spontaneous counterparts, are currently unknown (Arnault et al. 2009; Robert et al. 2010).

3.2 MEK

The serine/threonine tyrosine kinase MEK acts downstream from RAF in the RAF/MEK/ERK pathway; its inhibition is an attractive anticancer strategy as it has the potential to block upregulated signal transduction through this pathway, regardless of the upstream position of the oncogenic aberration. AZD6244 (ARRY-142886, Array BioPharma, AstraZeneca) is a selective MEK1/2 inhibitor that has shown preclinical activity (Yeh et al. 2007) and demonstrated clinical activity in a phase I study with a relatively benign toxicity profile (Adjei et al. 2008). These results led to a randomized phase II trial comparing AZD6244 versus temozolomide in chemotherapy naïve advanced melanoma patients (Dummer 2008). A total of 200 patients were enrolled with 104 and 96 patients randomized to AZD6244 and temozolomide, respectively; those who progressed on temozolomide could crossover to AZD6244. Results showed a trend toward OS in patients with BRAF mutations in the AZD6244 arm (Dummer 2008). At the 2010 ASCO annual meeting, the early results of a phase I study with AZD6244 in combination with docetaxel, dacarbazine or temsirolimus suggests the presence of BRAF mutation was significantly associated with clinical responses and increased time to progression. (Patel 2010). Several phase II studies of AZD6244 are underway for advanced melanoma patients with BRAF mutations as front line therapy: for treatment-naïve patients versus temozolomide (NCT00338130), in combination with dacarbazine versus dacarbazine alone (NCT00936221), as well as salvage therapy (NCT00866177). GSK1120212 is another potent and selective inhibitor of the MEK1/2 enzymes with promising anti-tumor activity in a phase I clinical trial, resulting in response rate > 70% in advanced melanoma patients with known BRAF mutations, including one patient who was previously treated with PLX4032 (Infante 2010). This drug is currently investigated in phase II and III clinical trials for advanced BRAF mutant melanoma patients who were either previously treated with a BRAF inhibitor or not. (NCT01245062, NCT01037127).

Although targeting the MAPK pathway is a promising new therapeutic approach for the treatment of melanoma, and treatment with selective BRAF and MEK inhibitors can induce high response rates, the limited duration of these responses in most patients, most likely because of emerging resistance to these inhibitors represents a significant clinical challenge. Molecular redundancy, in part due to the existence of RAF isoforms and signaling through alternative oncogenic pathways, such as PI3K/AKT/mTOR pathway (Jiang et al. 2011; Paraiso et al. 2010), receptor tyrosine kinase (PDGFR β)-dependent pathway (Nazarian et al. 2010) and COT (MAP3K8) (Johannessen et al. 2010), may provide the melanoma cells' escape mechanisms to specific pathway inhibitors and underscore their ability to adapt to pharmacological challenges (Jiang et al. 2011; Paraiso et al. 2010). In preclinical models, it has been reported that acquired resistance of melanoma cells to the BRAF inhibitors was associated with rebound activation of the RAF/MEK/ERK pathway (Paraiso et al. 2010). In line with this finding, activating signals to downstream MEK/ERK has been shown to switch to ARAF (Villanueva et al. 2010) or CRAF (Montagut et al. 2008; Villanueva et al. 2010) via N-RAS upregulation (Nazarian et al. 2010) to overcome the effect of BRAF inhibition. Moreover, the majority of melanoma cells harboring the BRAF V600E mutation retained the wild-type BRAF allele which could be rescued from the effects of BRAF knock-down by extracellular growth factors such as basic fibroblast growth factor, hepatocyte growth factor or endothelin-1 (Christensen and Guldberg 2005).

3.3 C-Kit

Imatinib is a selective tyrosine kinase inhibitor with multiple targets, including c-Kit and PDGR receptors, and has shown to be highly efficacious in chronic myelogenous leukemia and GIST tumors (Heinrich et al. 2000). Initial phase II trials with this agent in melanoma were disappointing with no objective responses (Ugurel et al. 2005; Wyman et al. 2006). However, gain of function mutations, gene amplifications and over-expression of c-kit were subsequently reported in 30-40% of mucosal, acral and cutaneous melanomas with chronic sun damage (Curtin et al. 2006). Impressive tumor regression was documented in a patient with mucosal melanoma who carried a mutation in the juxtamembranous domain of c-Kit (exon 11) in response to single agent imatinib (Hodi et al. 2008a). Moreover, preclinical studies showed sensitivity of c-Kit mutant mucosal melanoma, providing a rationale for the use of imatinib in this melanoma type. Preliminary results of a phase II trial evaluating the effect of imatinib in patients with metastatic melanoma with c-kit aberrations were presented at ASCO 2009. Over 30% of patients achieved a response (complete and partial response), whereas 50% had disease stability (Carvajal 2009). Another phase I/II study to define safety and efficacy of imatinib in combination with temozolomide in patients with unresectable, stage III/IV melanoma is currently underway. After the data on c-kit alterations became available when the trial was already in progress, patients with mucosal, acral and chronic sun damage melanomas were preferentially enrolled in the phase II part of the study. Early results of the trial were presented at ASCO 2008 (Fecher 2008). Of the 23 patients treated, 16 had been enrolled in phase I and 7 in phase II. The combination was well tolerated and demonstrated anti-tumor activity in melanoma. Of the 7 patients treated in the phase II trial, 1 patient had a CR and 6 had PRs (Fecher 2008). Phase II studies with a second generation c-kit inhibitor (nilotinib) in first or second line therapies for advanced melanoma with c-Kit mutation or amplification are ongoing (NCT01168050, NCT01099514). In addition, the multi-targeted receptor tyrosine kinase inhibitor sunitinib has shown potential efficacy in patients with c-kit mutated melanoma in an early phase clinical trial (Minor 2010).

3.4 MTOR

Resistance of mutant BRAF melanoma cells to RAF/MEK inhibition may also be due to activation of other survival signaling pathways such as the PI3K/AKT/mTOR pathway (figure 3) resulting in melanoma development and progression (Shao and Aplin 2010; Stahl et al. 2004; Villanueva et al. 2010). Recent reports suggested a significant correlation of increased PI3K-AKT activity with resistance to RAF/MEK inhibitors in melanoma (Gopal et al. 2010; Villanueva et al. 2010) and that inhibition of the PI3K/AKT/mTOR pathway could suppress MEK inhibitor-induced activation of AKT and resulted in synergistic cell killing with a MEK inhibitor (AZD6244) (Gopal et al. 2010). This provides a rationale for combinatorial therapy leading to dual inhibition of both RAF/MEK/ERK and PI3K/AKT/mTOR pathways. A phase II trial of the mTOR inhibitor temsirolimus (CCI-779) combined with the MEK inhibitor AZD6244 is currently recruiting treatment-naïve patients with BRAF mutant advanced melanoma (NCT01166126). In addition, inhibition of the PI3K/AKT/mTOR signaling pathway was found to sensitize melanoma cells to chemotherapeutic agents such as cisplatin and temozolomide *in vitro* as evidenced by enhanced apoptosis and suppressed invasive tumor growth (Sinnberg et al. 2009). A Phase II study of the mTOR inhibitor everolimus in combination with paclitaxel and carboplatin in patients with metastatic melanoma is in progress (NCT01014351).

4. Other targeted drugs currently in clinical development

4.1 PARP Inhibitors

Poly-ADP ribose polymerase (PARP) is a key enzyme in DNA repair. ADP-ribosylation is involved in DNA excision repair and inhibition of the enzyme enhances the cytotoxicity of DNA damaging agents (Durkacz et al. 1980). PARP inhibition in BRCA-deficient breast cancers has shown a favorable therapeutic index. In a phase II trial, olaparib, a novel poly-ADP ribose polymerase (PARP) inhibitor, achieved an objective response rate of 41% in women with BRCA1 or BRCA2 mutations and advanced breast cancer (Tutt et al. 2010). In melanoma, PARP-1 expression has been shown to correlate with tumor thickness (Staibano et al. 2005), a poor prognostic factor for melanoma, and over-expression of PARP-1 is correlated with recurrence and/or progression of the disease (Csete et al. 2009), suggesting that it potentially is as a promising new therapeutic target. AG014699 is the first PARP inhibitor to enter a clinical trial and was studied in combination with temozolomide in a phase II study with 40 chemotherapy-naïve metastatic melanoma patients. Of the 20 evaluable patients, there were 4 confirmed PRs and 4 SDs (Plummer 2006).

4.2 Antibody-drug conjugate

Glycoprotein NMB (GPNMB) is over-expressed in a variety of cancers including melanoma. CR011-vcMMAE is an antibody-drug conjugate comprised of a fully-human monoclonal antibody directed at the extracellular domain of GPNMB linked to a potent tubulin destabilizing agent, monomethyl auristatin E (MMAE). The enzyme-sensitive linker is designed to be stable in the bloodstream and to release MMAE inside tumor cells, resulting in cancer cell death. A phase I/II study of CR011-vcMMAE in patients with advanced, pretreated melanoma has completed accrual (NCT00412828). At the ASCO annual meeting in 2010, CR-vcMMAE at 1.88mg/kg, when given every three weeks, was reported to produce an objective response rate of 15% (Hamid 2010).

4.3 Antibodies against integrins

Integrins of the α_v family, such as $\alpha_v\beta_3$ and $\alpha_v\beta_5$, are implicated in tumor-induced angiogenesis and are thought to play a role in tumor growth. CNTO 95 is a fully human monoclonal antibody directed against α_v Integrins, which has demonstrated anti-tumor and anti-angiogenic activities in animal models (Tripathi et al. 2004). Results of a phase I study to assess safety and pharmacokinetics of CNTO 95 in patients with advanced refractory solid tumors demonstrated good tolerability (Jayson 2004). A phase I/II multicenter, randomized and double-blind study to assess the safety and efficacy of CNTO 95, alone and in combination with dacarbazine, in stage IV melanoma patients has been completed and result pending publication (NCT00246012). Another phase I trial of CNTO 95 in patients with metastatic melanoma and angiosarcoma recently demonstrated a manageable toxicity profile, and encouragingly, 2 of 18 patients with melanoma, who had failed several therapeutic regimens, sustained stable disease 5 and 7 months, respectively (O'Day et al. 2011).

5. Conclusion

Understanding the molecular biology of melanoma and unraveling of several signaling pathways over the last few years, as well as advances in immunology have led to the development of a number of promising novel therapeutic treatment options for metastatic melanoma. Immune-checkpoint blockade with ipilimumab has demonstrated increased overall survival in a randomized phase III clinical study (Hodi et al. 2010). Other immune-related approaches, such as anti-PD1/PD-L1 and adoptive cell therapy, are on the horizon. The identification of the BRAF V600E mutation led to the development of new agents that specifically block the MAPK pathway. Improved PFS and OS as a result of treatment with the V600E mutant BRAF kinase inhibitor RG7204 in BRIM 3 have been reported. Encouraging response rates with imatinib therapy in patients with mucosal, acral, and sun-damaged skin melanomas that harbor mutations or amplification in the c-kit gene have also been documented. These results herald the era of individualized therapies based on specific tumor genotypes, of which scientifically thoughtful combinations will usher in a new standard of care for metastatic melanoma in the near future.

6. References

- Adjei, A. A., Cohen, R. B., Franklin, W., Morris, C., Wilson, D., Molina, J. R., Hanson, L. J., Gore, L., Chow, L., Leong, S., Maloney, L., Gordon, G., Simmons, H., Marlow, A., Litwiler, K., Brown, S., Poch, G., Kane, K., Haney, J., and Eckhardt, S. G. (2008). Phase I pharmacokinetic and pharmacodynamic study of the oral, small-molecule mitogen-activated protein kinase kinase 1/2 inhibitor AZD6244 (ARRY-142886) in patients with advanced cancers. *J Clin Oncol*, 26(13), 2139-2146
- Adnane, L., Trail, P. A., Taylor, I., and Wilhelm, S. M. (2006). Sorafenib (BAY 43-9006, Nexavar), a dual-action inhibitor that targets RAF/MEK/ERK pathway in tumor cells and tyrosine kinases VEGFR/PDGFR in tumor vasculature. *Methods Enzymol*, 407, 597-612
- Agarwala, S. S., Kirkwood, J. M., Gore, M., Dreno, B., Thatcher, N., Czarnetski, B., Atkins, M., Buzaid, A., Skarlos, D., and Rankin, E. M. (2004). Temozolomide for the

- treatment of brain metastases associated with metastatic melanoma: a phase II study. *J Clin Oncol*, 22(11), 2101-2107
- Amaravadi, R. K., Schuchter, L. M., McDermott, D. F., Kramer, A., Giles, L., Gramlich, K., Carberry, M., Troxel, A. B., Letrero, R., Nathanson, K. L., Atkins, M. B., O'Dwyer, P. J., and Flaherty, K. T. (2009). Phase II Trial of Temozolomide and Sorafenib in Advanced Melanoma Patients with or without Brain Metastases. *Clin Cancer Res*, 15(24), 7711-7718
- Amer, M. H., Al-Sarraf, M., Baker, L. H., and Vaitkevicius, V. K. (1978). Malignant melanoma and central nervous system metastases: incidence, diagnosis, treatment and survival. *Cancer*, 42(2), 660-668
- Antonadou, D., Paraskevaidis, M., Sarris, G., Coliarakis, N., Economou, I., Karageorgis, P., and Throuvalas, N. (2002). Phase II randomized trial of temozolomide and concurrent radiotherapy in patients with brain metastases. *J Clin Oncol*, 20(17), 3644-3650
- Antony, P. A., Piccirillo, C. A., Akpınarlı, A., Finkelstein, S. E., Speiss, P. J., Surman, D. R., Palmer, D. C., Chan, C. C., Klebanoff, C. A., Overwijk, W. W., Rosenberg, S. A., and Restifo, N. P. (2005). CD8+ T cell immunity against a tumor/self-antigen is augmented by CD4+ T helper cells and hindered by naturally occurring T regulatory cells. *J Immunol*, 174(5), 2591-2601
- Arnault, J. P., Wechsler, J., Escudier, B., Spatz, A., Tomasic, G., Sibaud, V., Aractingi, S., Grange, J. D., Poirier-Colame, V., Malka, D., Soria, J. C., Mateus, C., and Robert, C. (2009). Keratoacanthomas and squamous cell carcinomas in patients receiving sorafenib. *J Clin Oncol*, 27(23), 59-61
- Atkins, M. B., Kunkel, L., Sznol, M., and Rosenberg, S. A. (2000). High-dose recombinant interleukin-2 therapy in patients with metastatic melanoma: long-term survival update. *Cancer J Sci Am*, 6 Suppl 1, 11-14
- Balch, C. M., Gershenwald, J. E., Soong, S. J., Thompson, J. F., Atkins, M. B., Byrd, D. R., Buzaid, A. C., Cochran, A. J., Coit, D. G., Ding, S., Eggermont, A. M., Flaherty, K. T., Gimotty, P. A., Kirkwood, J. M., McMasters, K. M., Mihm, M. C., Jr., Morton, D. L., Ross, M. I., Sober, A. J., and Sondak, V. K. (2009). Final version of 2009 AJCC melanoma staging and classification. *J Clin Oncol*, 27(36), 6199-6206
- Beck, K. E., Blansfield, J. A., Tran, K. Q., Feldman, A. L., Hughes, M. S., Royal, R. E., Kammula, U. S., Topalian, S. L., Sherry, R. M., Kleiner, D., Quezado, M., Lowy, I., Yellin, M., Rosenberg, S. A., and Yang, J. C. (2006). Enterocolitis in patients with cancer after antibody blockade of cytotoxic T-lymphocyte-associated antigen 4. *J Clin Oncol*, 24(15), 2283-2289
- Bedikian, A. Y., Millward, M., Pehamberger, H., Conry, R., Gore, M., Trefzer, U., Pavlick, A. C., DeConti, R., Hersh, E. M., Hersey, P., Kirkwood, J. M., and Haluska, F. G. (2006). Bcl-2 antisense (oblimersen sodium) plus dacarbazine in patients with advanced melanoma: the Oblimersen Melanoma Study Group. *J Clin Oncol*, 24(29), 4738-4745
- Blank, C., Brown, I., Peterson, A. C., Spiotto, M., Iwai, Y., Honjo, T., and Gajewski, T. F. (2004). PD-L1/B7H-1 inhibits the effector phase of tumor rejection by T cell receptor (TCR) transgenic CD8+ T cells. *Cancer Res*, 64(3), 1140-1145
- Brahmer, J. R., Drake, C. G., Wollner, I., Powderly, J. D., Picus, J., Sharfman, W. H., Stankevich, E., Pons, A., Salay, T. M., McMiller, T. L., Gilson, M. M., Wang, C., Selby, M., Taube, J. M., Anders, R., Chen, L., Korman, A. J., Pardoll, D. M., Lowy, I.,

- and Topalian, S. L. (2010). Phase I study of single-agent anti-programmed death-1 (MDX-1106) in refractory solid tumors: safety, clinical activity, pharmacodynamics, and immunologic correlates. *J Clin Oncol*, 28(19), 3167-3175
- Carvajal, R. D., Chapman, P.B, Wolchok, J.D., Cane, L., Teitcher, J.B., Lutzky, J., Pavlick, A.C., Bastian, B.C., Antonescu, C.R., Schwartz, G.K. (2009). A phase II study of imatinib mesylate (IM) for patients with advanced melanoma harboring somatic alterations of KIT. *J Clin Oncol*, 27, ASCO Annual Meeting, Abstr 9001
- Chapman, P. B., Einhorn, L. H., Meyers, M. L., Saxman, S., Destro, A. N., Panageas, K. S., Begg, C. B., Agarwala, S. S., Schuchter, L. M., Ernstoff, M. S., Houghton, A. N., and Kirkwood, J. M. (1999). Phase III multicenter randomized trial of the Dartmouth regimen versus dacarbazine in patients with metastatic melanoma. *J Clin Oncol*, 17(9), 2745-2751
- Chikuma, S., Terawaki, S., Hayashi, T., Nabeshima, R., Yoshida, T., Shibayama, S., Okazaki, T., and Honjo, T. (2009). PD-1-mediated suppression of IL-2 production induces CD8+ T cell anergy in vivo. *J Immunol*, 182(11), 6682-6689
- Christensen, C., and Guldberg, P. (2005). Growth factors rescue cutaneous melanoma cells from apoptosis induced by knockdown of mutated (V 600 E) B-RAF. *Oncogene*, 24(41), 6292-6302
- Csete, B., Lengyel, Z., Kadar, Z., and Battyani, Z. (2009). Poly(adenosine diphosphate-ribose) polymerase-1 expression in cutaneous malignant melanomas as a new molecular marker of aggressive tumor. *Pathol Oncol Res*, 15(1), 47-53
- Curtin, J. A., Busam, K., Pinkel, D., and Bastian, B. C. (2006). Somatic activation of KIT in distinct subtypes of melanoma. *J Clin Oncol*, 24(26), 4340-4346
- Davies, H., Bignell, G. R., Cox, C., Stephens, P., Edkins, S., Clegg, S., Teague, J., Woffendin, H., Garnett, M. J., Bottomley, W., Davis, N., Dicks, E., Ewing, R., Floyd, Y., Gray, K., Hall, S., Hawes, R., Hughes, J., Kosmidou, V., Menzies, A., Mould, C., Parker, A., Stevens, C., Watt, S., Hooper, S., Wilson, R., Jayatilake, H., Gusterson, B. A., Cooper, C., Shipley, J., Hargrave, D., Pritchard-Jones, K., Maitland, N., Chenevix-Trench, G., Riggins, G. J., Bigner, D. D., Palmieri, G., Cossu, A., Flanagan, A., Nicholson, A., Ho, J. W., Leung, S. Y., Yuen, S. T., Weber, B. L., Seigler, H. F., Darrow, T. L., Paterson, H., Marais, R., Marshall, C. J., Wooster, R., Stratton, M. R., and Futreal, P. A. (2002). Mutations of the BRAF gene in human cancer. *Nature*, 417(6892), 949-954
- de la Monte, S. M., Moore, G. W., and Hutchins, G. M. (1983). Patterned distribution of metastases from malignant melanoma in humans. *Cancer Res*, 43(7), 3427-3433
- Di Giacomo, A. M., Biagioli, M., and Maio, M. (2010). The emerging toxicity profiles of anti-CTLA-4 antibodies across clinical indications. *Semin Oncol*, 37(5), 499-507
- Downey, S. G., Klapper, J. A., Smith, F. O., Yang, J. C., Sherry, R. M., Royal, R. E., Kammula, U. S., Hughes, M. S., Allen, T. E., Levy, C. L., Yellin, M., Nichol, G., White, D. E., Steinberg, S. M., and Rosenberg, S. A. (2007). Prognostic factors related to clinical response in patients with metastatic melanoma treated by CTL-associated antigen-4 blockade. *Clin Cancer Res*, 13(22 Pt 1), 6681-6688
- Dudley, M. E., Wunderlich, J. R., Robbins, P. F., Yang, J. C., Hwu, P., Schwartzentruber, D. J., Topalian, S. L., Sherry, R., Restifo, N. P., Hubicki, A. M., Robinson, M. R., Raffeld, M., Duray, P., Seipp, C. A., Rogers-Freezer, L., Morton, K. E., Mavroukakis, S. A., White, D. E., and Rosenberg, S. A. (2002). Cancer regression and autoimmunity in

- patients after clonal repopulation with antitumor lymphocytes. *Science*, 298(5594), 850-854
- Dudley, M. E., Wunderlich, J. R., Yang, J. C., Sherry, R. M., Topalian, S. L., Restifo, N. P., Royal, R. E., Kammula, U., White, D. E., Mavroukakis, S. A., Rogers, L. J., Gracia, G. J., Jones, S. A., Mangiameli, D. P., Pelletier, M. M., Gea-Banacloche, J., Robinson, M. R., Berman, D. M., Filie, A. C., Abati, A., and Rosenberg, S. A. (2005). Adoptive cell transfer therapy following non-myeloablative but lymphodepleting chemotherapy for the treatment of patients with refractory metastatic melanoma. *J Clin Oncol*, 23(10), 2346-2357
- Dudley, M. E., Yang, J. C., Sherry, R., Hughes, M. S., Royal, R., Kammula, U., Robbins, P. F., Huang, J., Citrin, D. E., Leitman, S. F., Wunderlich, J., Restifo, N. P., Thomasian, A., Downey, S. G., Smith, F. O., Klapper, J., Morton, K., Laurencot, C., White, D. E., and Rosenberg, S. A. (2008). Adoptive cell therapy for patients with metastatic melanoma: evaluation of intensive myeloablative chemoradiation preparative regimens. *J Clin Oncol*, 26(32), 5233-9
- Dummer, R., Robert, C., Chapman, P. B., Sosman, J. A., Middleton, M., Bastholt, L., Kemsley, K., Cantarini, M. V., Morris, C., Kirkwood, J. M. (2008). AZD6244 (ARRY-142886) vs temozolomide (TMZ) in patients (pts) with advanced melanoma: An open-label, randomized, multicenter, phase II study. *J Clin Oncol*, 26(May 20 suppl), ASCO annual meeting abstract 9033
- Durkacz, B. W., Omidiji, O., Gray, D. A., and Shall, S. (1980). (ADP-ribose)_n participates in DNA excision repair. *Nature*, 283(5747), 593-596
- Eigentler, T. K., Caroli, U. M., Radny, P., and Garbe, C. (2003). Palliative therapy of disseminated malignant melanoma: a systematic review of 41 randomised clinical trials. *Lancet Oncol*, 4(12), 748-759
- Eisen, T., Ahmad, T., Flaherty, K. T., Gore, M., Kaye, S., Marais, R., Gibbens, I., Hackett, S., James, M., Schuchter, L. M., Nathanson, K. L., Xia, C., Simantov, R., Schwartz, B., Poulin-Costello, M., O'Dwyer, P. J., and Ratain, M. J. (2006). Sorafenib in advanced melanoma: a Phase II randomised discontinuation trial analysis. *Br J Cancer*, 95(5), 581-586
- Fecher, L. A., Amaravadi, R. K. & Flaherty, K. T. (2008). The MAPK pathway in melanoma. *Curr Opin Oncol*, 20(2), 183-9
- Fecher, L. A., Nathanson, K., Flaherty, K. T., Amaravadi, R., Giles, L., McGettigan, S., Carberry, M., Elder, D., Schuchter, L. (2008). Phase I/II trial of imatinib and temozolomide in advanced unresectable melanoma. *J Clin Oncol*, 26(ASCO 2008 Meeting Abstract 9059)
- Fife, K. M., Colman, M. H., Stevens, G. N., Firth, I. C., Moon, D., Shannon, K. F., Harman, R., Petersen-Schaefer, K., Zacest, A. C., Besser, M., Milton, G. W., McCarthy, W. H., and Thompson, J. F. (2004). Determinants of outcome in melanoma patients with cerebral metastases. *J Clin Oncol*, 22(7), 1293-1300
- Flaherty, K., Puzanov, I., Sosman, J., Kim, K., Ribas, A., McArthur, G., Lee, R.J., Grippo, J.F., Nolop, K., Chapman, P. (2009). Phase I study of PLX4032: Proof of concept for V600E BRAF mutation as a therapeutic target in human cancer. *J Clin Oncol*, 27(15s), ASCO Annual Meeting Abstract (suppl; abstr 9000)

- Flaherty, K. T., Puzanov, I., Kim, K. B., Ribas, A., McArthur, G. A., Sosman, J. A., O'Dwyer, P. J., Lee, R. J., Grippo, J. F., Nolop, K., and Chapman, P. B. (2010). Inhibition of mutated, activated BRAF in metastatic melanoma. *N Engl J Med*, 363(9), 809-819
- Fourcade, J., Kudela, P., Sun, Z., Shen, H., Land, S. R., Lenzner, D., Guillaume, P., Luescher, I. F., Sander, C., Ferrone, S., Kirkwood, J. M., and Zarour, H. M. (2009). PD-1 is a regulator of NY-ESO-1-specific CD8⁺ T cell expansion in melanoma patients. *J Immunol*, 182(9), 5240-5249
- Gattinoni, L., Finkelstein, S. E., Klebanoff, C. A., Antony, P. A., Palmer, D. C., Spiess, P. J., Hwang, L. N., Yu, Z., Wrzesinski, C., Heimann, D. M., Surh, C. D., Rosenberg, S. A., and Restifo, N. P. (2005). Removal of homeostatic cytokine sinks by lymphodepletion enhances the efficacy of adoptively transferred tumor-specific CD8⁺ T cells. *J Exp Med*, 202(7), 907-912
- Gopal, Y. N., Deng, W., Woodman, S. E., Komurov, K., Ram, P., Smith, P. D., and Davies, M. A. (2010). Basal and treatment-induced activation of AKT mediates resistance to cell death by AZD6244 (ARRY-142886) in Braf-mutant human cutaneous melanoma cells. *Cancer Res*, 70(21), 8736-8747
- Haluska, F., Pemberton, T., Ibrahim, N., and Kalinsky, K. (2007). The RTK/RAS/BRAF/PI3K pathways in melanoma: biology, small molecule inhibitors, and potential applications. *Semin Oncol*, 34(6), 546-554
- Hamid, O., Sznol, M., Pavlick, A. C., Kluger, H. M., Kim, K. B., Boasberg, P. D., Simantov, R., Davis, T. A., Crowley, E., Hwu, P. (2010). Frequent dosing and GPNMB expression with CDX-011 (CR011-vcMMAE), an antibody-drug conjugate (ADC), in patients with advanced melanoma. *J Clin Oncol*, 28(15s), ASCO Annual Meeting Abstract 8525
- Hamid, O., Urban, W. J., Yellin, M., Nichol, G. M., Weber, J., Hersh, E. M., Tchekmedyian, S., Hodi, F. S., Weber, R., O'Day, S. (2007). Kinetics of response to ipilimumab (MDX-010) in patients with stage III/IV melanoma. *J Clin Oncol*, 25 (18S (June 20 Supplement)), Abstract 8525
- Hauschild, A., Agarwala, S. S., Trefzer, U., Hogg, D., Robert, C., Hersey, P., Eggermont, A., Grabbe, S., Gonzalez, R., Gille, J., Peschel, C., Schadendorf, D., Garbe, C., O'Day, S., Daud, A., White, J. M., Xia, C., Patel, K., Kirkwood, J. M., and Keilholz, U. (2009). Results of a phase III, randomized, placebo-controlled study of sorafenib in combination with carboplatin and paclitaxel as second-line treatment in patients with unresectable stage III or stage IV melanoma. *J Clin Oncol*, 27(17), 2823-2830
- Heinrich, M. C., Griffith, D. J., Druker, B. J., Wait, C. L., Ott, K. A., and Zigler, A. J. (2000). Inhibition of c-kit receptor tyrosine kinase activity by STI 571, a selective tyrosine kinase inhibitor. *Blood*, 96(3), 925-932
- Hino, R., Kabashima, K., Kato, Y., Yagi, H., Nakamura, M., Honjo, T., Okazaki, T., and Tokura, Y. (2010). Tumor cell expression of programmed cell death-1 ligand 1 is a prognostic factor for malignant melanoma. *Cancer*, 116(7), 1757-1766
- Hodi, F. S., Friedlander, P., Corless, C. L., Heinrich, M. C., MacRae, S., Kruse, A., Jagannathan, J., Van den Abbeele, A. D., Velazquez, E. F., Demetri, G. D., and Fisher, D. E. (2008a). Major response to imatinib mesylate in KIT-mutated melanoma. *J Clin Oncol*, 26(12), 2046-2051
- Hodi, F. S., O'Day, S. J., McDermott, D. F., Weber, R. W., Sosman, J. A., Haanen, J. B., Gonzalez, R., Robert, C., Schadendorf, D., Hassel, J. C., Akerley, W., van den

- Eertwegh, A. J., Lutzky, J., Lorigan, P., Vaubel, J. M., Linette, G. P., Hogg, D., Ottensmeier, C. H., Lebbe, C., Peschel, C., Quirt, I., Clark, J. I., Wolchok, J. D., Weber, J. S., Tian, J., Yellin, M. J., Nichol, G. M., Hoos, A., and Urba, W. J. (2010). Improved survival with ipilimumab in patients with metastatic melanoma. *N Engl J Med*, 363(8), 711-723
- Hodi, F. S., Oble, D. A., Drappatz, J., Velazquez, E. F., Ramaiya, N., Ramakrishna, N., Day, A. L., Kruse, A., Mac Rae, S., Hoos, A., and Mihm, M. (2008b). CTLA-4 blockade with ipilimumab induces significant clinical benefit in a female with melanoma metastases to the CNS. *Nat Clin Pract Oncol*, 5(9), 557-561
- Hwu, W. J., Lis, E., Menell, J. H., Panageas, K. S., Lamb, L. A., Merrell, J., Williams, L. J., Krown, S. E., Chapman, P. B., Livingston, P. O., Wolchok, J. D., and Houghton, A. N. (2005). Temozolomide plus thalidomide in patients with brain metastases from melanoma: a phase II study. *Cancer*, 103(12), 2590-2597
- Infante, J. R., Fecher, L. A., Nallapareddy, S., Gordon, M. S., Flaherty, K. T., Cox, D. S., DeMarini, D. J., Morris, S. R., Burris, H. A., Messersmith, W. A. (2010). Safety and efficacy results from the first-in-human study of the oral MEK 1/2 inhibitor GSK1120212. *J Clin Oncol*, 28(15s), ASCO annual meeting abstract 2503
- Ives, N. J., Stowe, R. L., Lorigan, P., and Wheatley, K. (2007). Chemotherapy compared with biochemotherapy for the treatment of metastatic melanoma: a meta-analysis of 18 trials involving 2,621 patients. *J Clin Oncol*, 25(34), 5426-5434
- Iwai, Y., Ishida, M., Tanaka, Y., Okazaki, T., Honjo, T., and Minato, N. (2002). Involvement of PD-L1 on tumor cells in the escape from host immune system and tumor immunotherapy by PD-L1 blockade. *Proc Natl Acad Sci U S A*, 99(19), 12293-12297
- Jayson, G. C., Mullamitha, S., Ton, C., Valle, J., Saunders, M., Munteanu, M. C., Jang, H., Trikha, M., Davis, H. M., Beckman, R. A. (2004). Phase I study of CNTO 95, a fully human monoclonal antibody (mAb) to αv integrins, in patients with solid tumors. *J Clin Oncol*, 22(14s), ASCO Meeting, Abstract 3119
- Jiang, C. C., Lai, F., Thorne, R. F., Yang, F., Liu, H., Hersey, P., and Zhang, X. D. (2011). MEK-Independent Survival of B-RAFV600E Melanoma Cells Selected for Resistance to Apoptosis Induced by the RAF Inhibitor PLX4720. *Clin Cancer Res*, 19(4), 721-730
- Johannessen, C. M., Boehm, J. S., Kim, S. Y., Thomas, S. R., Wardwell, L., Johnson, L. A., Emery, C. M., Stransky, N., Cogdill, A. P., Barretina, J., Caponigro, G., Hieronymus, H., Murray, R. R., Salehi-Ashtiani, K., Hill, D. E., Vidal, M., Zhao, J. J., Yang, X., Alkan, O., Kim, S., Harris, J. L., Wilson, C. J., Myer, V. E., Finan, P. M., Root, D. E., Roberts, T. M., Golub, T., Flaherty, K. T., Dummer, R., Weber, B. L., Sellers, W. R., Schlegel, R., Wargo, J. A., Hahn, W. C., and Garraway, L. A. (2010). COT drives resistance to RAF inhibition through MAP kinase pathway reactivation. *Nature*, 468(7326), 968-672
- Johnson, L. A., Morgan, R. A., Dudley, M. E., Cassard, L., Yang, J. C., Hughes, M. S., Kammula, U. S., Royal, R. E., Sherry, R. M., Wunderlich, J. R., Lee, C. C., Restifo, N. P., Schwarz, S. L., Cogdill, A. P., Bishop, R. J., Kim, H., Brewer, C. C., Rudy, S. F., VanWaes, C., Davis, J. L., Mathur, A., Ripley, R. T., Nathan, D. A., Laurencot, C. M., and Rosenberg, S. A. (2009). Gene therapy with human and mouse T-cell receptors mediates cancer regression and targets normal tissues expressing cognate antigen. *Blood*, 114(3), 535-546

- Kahler, K. C., and Hauschild, A. (2010). Treatment and side effect management of CTLA-4 antibody therapy in metastatic melanoma. *J Dtsch Dermatol Ges*, 9(4), 277-286
- Kefford, R., Arkenau, H., Brown, M. P., Millward, M., Infante, J. R., Long, G. V., Ouellet, D., Curtis, M., Lebowitz, P. F., Falchook, G. S. (2010). Phase I/II study of GSK2118436, a selective inhibitor of oncogenic mutant BRAF kinase, in patients with metastatic melanoma and other solid tumors. *J Clin Oncol*, 28(15s), ASCO Annual Meeting, Abstract 8503
- Lawrence, D. P., Hamid, O., McDermott, D. F., Puzanov, I., Sznol, M., Clark, J., Logan, T., Hodi, F. S., Heller, K. N., Margolin, K. A. (2010). Phase II trial of ipilimumab monotherapy in melanoma patients with brain metastases. *J Clin Oncol*, 28(15s), (suppl; abstr 8523)
- Margolin, K. A., Di Giacomo, A. M., and Maio, M. (2010). Brain metastasis in melanoma: clinical activity of CTLA-4 antibody therapy. *Semin Oncol*, 37(5), 468-472
- Meier, F., Schitteck, B., Busch, S., Garbe, C., Smalley, K., Satyamoorthy, K., Li, G., and Herlyn, M. (2005). The RAS/RAF/MEK/ERK and PI3K/AKT signaling pathways present molecular targets for the effective treatment of advanced melanoma. *Front Biosci*, 10, 2986-3001
- Middleton, M. R., Grob, J. J., Aaronson, N., Fierlbeck, G., Tilgen, W., Seiter, S., Gore, M., Aamdal, S., Cebon, J., Coates, A., Dreno, B., Henz, M., Schadendorf, D., Kapp, A., Weiss, J., Fraass, U., Statkevich, P., Muller, M., and Thatcher, N. (2000). Randomized phase III study of temozolomide versus dacarbazine in the treatment of patients with advanced metastatic malignant melanoma. *J Clin Oncol*, 18(1), 158-166
- Minor, D. R., O'Day, S., Kashani-Sabet, M., Daud, A., Salman, Z., Bastian, B. (2010). Sunitinib therapy for metastatic melanomas with KIT aberrations. *J Clin Oncol*, 28, ASCO 2010 Meeting, Abstract 8545.
- Montagut, C., Sharma, S. V., Shioda, T., McDermott, U., Ulman, M., Ulkus, L. E., Dias-Santagata, D., Stubbs, H., Lee, D. Y., Singh, A., Drew, L., Haber, D. A., and Settleman, J. (2008). Elevated CRAF as a potential mechanism of acquired resistance to BRAF inhibition in melanoma. *Cancer Res*, 68(12), 4853-4861
- Morgan, R. A., Dudley, M. E., Wunderlich, J. R., Hughes, M. S., Yang, J. C., Sherry, R. M., Royal, R. E., Topalian, S. L., Kammula, U. S., Restifo, N. P., Zheng, Z., Nahvi, A., de Vries, C. R., Rogers-Freezer, L. J., Mavroukakis, S. A., and Rosenberg, S. A. (2006). Cancer regression in patients after transfer of genetically engineered lymphocytes. *Science*, 314(5796), 126-129
- Nazarian, R., Shi, H., Wang, Q., Kong, X., Koya, R. C., Lee, H., Chen, Z., Lee, M. K., Attar, N., Sazegar, H., Chodon, T., Nelson, S. F., McArthur, G., Sosman, J. A., Ribas, A., and Lo, R. S. (2010). Melanomas acquire resistance to B-RAF(V600E) inhibition by RTK or N-RAS upregulation. *Nature*, 468(7326), 973-977
- O'Day, S. J., Maio, M., Chiarion-Sileni, V., Gajewski, T. F., Pehamberger, H., Bondarenko, I. N., Queirolo, P., Lundgren, L., Mikhailov, S., Roman, L., Verschraegen, C., Humphrey, R., Ibrahim, R., de Pril, V., Hoos, A., and Wolchok, J. D. (2010). Efficacy and safety of ipilimumab monotherapy in patients with pretreated advanced melanoma: a multicenter single-arm phase II study. *Ann Oncol*, 21(8), 1712-1717
- O'Day, S. J., Pavlick, A. C., Albertini, M. R., Hamid, O., Schalch, H., Lang, Z., Ling, J., Mata, M., Reddy, M., and Foster, B. (2011). Clinical and pharmacologic evaluation of two


- dose levels of intetumumab (CNTO 95) in patients with melanoma or angiosarcoma. *Invest New Drugs*, 2011 Feb 18.[Epub ahead of print]
- Ott, P. A., Hamilton, A., Min, C., Safarzadeh-Amiri, S., Goldberg, L., Yoon, J., Yee, H., Buckley, M., Christos, P. J., Wright, J. J., Polsky, D., Osman, I., Liebes, L., and Pavlick, A. C. (2010). A phase II trial of sorafenib in metastatic melanoma with tissue correlates. *PLoS One*, 5(12), e15588
- Paraiso, K. H., Fedorenko, I. V., Cantini, L. P., Munko, A. C., Hall, M., Sondak, V. K., Messina, J. L., Flaherty, K. T., and Smalley, K. S. (2010). Recovery of phospho-ERK activity allows melanoma cells to escape from BRAF inhibitor therapy. *Br J Cancer*, 102(12), 1724-1730
- Parry, R. V., Chemnitz, J. M., Frauwirth, K. A., Lanfranco, A. R., Braunstein, I., Kobayashi, S. V., Linsley, P. S., Thompson, C. B., and Riley, J. L. (2005). CTLA-4 and PD-1 receptors inhibit T-cell activation by distinct mechanisms. *Mol Cell Biol*, 25(21), 9543-9553
- Patel, J. K., Didolkar, M. S., Pickren, J. W., and Moore, R. H. (1978). Metastatic pattern of malignant melanoma. A study of 216 autopsy cases. *Am J Surg*, 135(6), 807-810
- Patel, S. P., Lazar, A. J., Mahoney, S., Vaughn, C., Gonzalez, N., Papadopoulos, N. E., Liu, P., Infante, J. R., LoRusso, P., Kim, K. B. (2010). Clinical responses to AZD6244 (ARRY-142886)-based combination therapy stratified by gene mutations in patients with metastatic melanoma. *J Clin Oncol*, 28(15s)
- Paulos, C. M., Kaiser, A., Wrzesinski, C., Hinrichs, C. S., Cassard, L., Boni, A., Muranski, P., Sanchez-Perez, L., Palmer, D. C., Yu, Z., Antony, P. A., Gattinoni, L., Rosenberg, S. A., and Restifo, N. P. (2007). Toll-like receptors in tumor immunotherapy. *Clin Cancer Res*, 13(18 Pt 1), 5280-5289
- Pavlick, A. C., Ott, P. A., Kannan, R., Madden, K. M., Sorlie, C., Escano, C., Escalon, J., Hernando-Monge, E., Osman, I., Bhardwaj, N. (2010). Hair depigmentation as an indicator of a durable response to CTLA-4 therapy. *J Clin Oncol*, 28 suppl(15s), ASCO Annual Meeting, abstract 8571
- Plummer, R., Lorigan, P., Evans, J., Steven, N., Middleton, M., Wilson, R., Snow, K., Dewji, R., Calvert, H. (2006). First and final report of a phase II study of the poly(ADP-ribose) polymerase (PARP) inhibitor, AG014699, in combination with temozolomide (TMZ) in patients with metastatic malignant melanoma (MM). *J Clin Oncol*, 24(18s), ASCO Meeting, Abstract 8013
- Ribas, A., Hauschild, A., Kefford, R., Punt, C. J., Haanen, J. B., Marmol, M., Garbe, C., Gomez-Navarro, J., Pavlov D., Marshall, M. (2008). Phase III, open-label, randomized, comparative study of tremelimumab (CP-675,206) and chemotherapy (temozolomide [TMZ] or dacarbazine [DTIC]) in patients with advanced melanoma. *J Clin Oncol*, 26(15S (May 20 Supplement)), Abstract 9011
- Robbins, P. F., Morgan, R. A., Feldman, S. A., Yang, J. C., Sherry, R. M., Dudley, M. E., Wunderlich, J. R., Nahvi, A. V., Helman, L. J., Mackall, C. L., Kammula, U. S., Hughes, M. S., Restifo, N. P., Raffeld, M., Lee, C. C., Levy, C. L., Li, Y. F., El-Gamil, M., Schwarz, S. L., Laurencot, C., and Rosenberg, S. A. (2011). Tumor Regression in Patients With Metastatic Synovial Cell Sarcoma and Melanoma Using Genetically Engineered Lymphocytes Reactive With NY-ESO-1. *J Clin Oncol*, 29(7), 917-924
- Robert, C., Arnault, J. P., and Mateus, C. (2010). "RAF inhibition and induction of cutaneous squamous cell carcinoma." *Curr Opin Oncol*, 23(2), 177-182

- Sampson, J. H., Carter, J. H., Jr., Friedman, A. H., and Seigler, H. F. (1998). Demographics, prognosis, and therapy in 702 patients with brain metastases from malignant melanoma. *J Neurosurg*, 88(1), 11-20
- Schartz, N. E., Farges, C., Madelaine, I., Bruzzoni, H., Calvo, F., Hoos, A., and Lebbe, C. (2010). Complete regression of a previously untreated melanoma brain metastasis with ipilimumab. *Melanoma Res*, 20(3), 247-50
- Serrone, L., Zeuli, M., Sega, F. M., and Cognetti, F. (2000). Dacarbazine-based chemotherapy for metastatic melanoma: thirty-year experience overview. *J Exp Clin Cancer Res*, 19(1), 21-34
- Shao, Y., and Aplin, A. E. (2010). Akt3-mediated resistance to apoptosis in B-RAF-targeted melanoma cells. *Cancer Res*, 70(16), 6670-6681
- Shields, J. M., Thomas, N. E., Cregger, M., Berger, A. J., Leslie, M., Torrice, C., Hao, H., Penland, S., Arbiser, J., Scott, G., Zhou, T., Bar-Eli, M., Bear, J. E., Der, C. J., Kaufmann, W. K., Rimm, D. L., and Sharpless, N. E. (2007). Lack of extracellular signal-regulated kinase mitogen-activated protein kinase signaling shows a new type of melanoma. *Cancer Res*, 67(4), 1502-1512
- Sinnberg, T., Lasithiotakis, K., Niessner, H., Schitteck, B., Flaherty, K. T., Kulms, D., Maczey, E., Campos, M., Gogel, J., Garbe, C., and Meier, F. (2009). Inhibition of PI3K-AKT-mTOR signaling sensitizes melanoma cells to cisplatin and temozolomide. *J Invest Dermatol*, 129(6), 1500-1515
- Stahl, J. M., Sharma, A., Cheung, M., Zimmerman, M., Cheng, J. Q., Bosenberg, M. W., Kester, M., Sandirasegarane, L., and Robertson, G. P. (2004). Deregulated Akt3 activity promotes development of malignant melanoma. *Cancer Res*, 64(19), 7002-7010
- Staibano, S., Pepe, S., Lo Muzio, L., Somma, P., Mascolo, M., Argenziano, G., Scalvenzi, M., Salvatore, G., Fabbrocini, G., Molea, G., Bianco, A. R., Carlomagno, C., and De Rosa, G. (2005). Poly(adenosine diphosphate-ribose) polymerase 1 expression in malignant melanomas from photoexposed areas of the head and neck region. *Hum Pathol*, 36(7), 724-731
- Strome, S. E., Dong, H., Tamura, H., Voss, S. G., Flies, D. B., Tamada, K., Salomao, D., Cheville, J., Hirano, F., Lin, W., Kasperbauer, J. L., Ballman, K. V., and Chen, L. (2003). B7-H1 blockade augments adoptive T-cell immunotherapy for squamous cell carcinoma. *Cancer Res*, 63(19), 6501-6505
- Sznol, M., Powderly, J.D. , Smith, D.C , Brahmer, J.R. , Drake, C.G. , McDermott, D.F. , Lawrence, P.D. , Wolchok, J.D. , Topalian, S.L. , Lowy, I. (2010). Safety and antitumor activity of biweekly MDX-1106 (Anti-PD-1, BMS-936558/ONO-4538) in patients with advanced refractory malignancies. *J Clin Oncol* 28:15s, 2010 (suppl; abstr 2506)
- Trikha, M., Zhou, Z., Nemeth, J. A., Chen, Q., Sharp, C., Emmell, E., Giles-Komar, J., and Nakada, M. T. (2004). CNTO 95, a fully human monoclonal antibody that inhibits alphav integrins, has antitumor and antiangiogenic activity in vivo. *Int J Cancer*, 110(3), 326-335
- Tsao, H., Atkins, M. B. & Sober, A. J. (2004). Management of cutaneous melanoma. *N Engl J Med*, 351(10), 998-1012
- Tutt, A., Robson, M., Garber, J. E., Domchek, S. M., Audeh, M. W., Weitzel, J. N., Friedlander, M., Arun, B., Loman, N., Schmutzler, R. K., Wardley, A., Mitchell, G.,

- Earl, H., Wickens, M., and Carmichael, J. (2010). Oral poly(ADP-ribose) polymerase inhibitor olaparib in patients with BRCA1 or BRCA2 mutations and advanced breast cancer: a proof-of-concept trial. *Lancet*, 376(9737), 235-244
- Ugurel, S., Hildenbrand, R., Zimpfer, A., La Rosee, P., Paschka, P., Sucker, A., Keikavoussi, P., Becker, J. C., Rittgen, W., Hochhaus, A., and Schadendorf, D. (2005). Lack of clinical efficacy of imatinib in metastatic melanoma. *Br J Cancer*, 92(8), 1398-1405
- Villanueva, J., Vultur, A., Lee, J. T., Somasundaram, R., Fukunaga-Kalabis, M., Cipolla, A. K., Wubbenhorst, B., Xu, X., Gimotty, P. A., Kee, D., Santiago-Walker, A. E., Letrero, R., D'Andrea, K., Pushparajan, A., Hayden, J. E., Brown, K. D., Laquerre, S., McArthur, G. A., Sosman, J. A., Nathanson, K. L., and Herlyn, M. (2010). Acquired resistance to BRAF inhibitors mediated by a RAF kinase switch in melanoma can be overcome by cotargeting MEK and IGF-1R/PI3K. *Cancer Cell*, 18(6), 683-695
- Vivanco, I., and Sawyers, C. L. (2002). The phosphatidylinositol 3-Kinase AKT pathway in human cancer. *Nat Rev Cancer*, 2(7), 489-501
- Weber, J., Thompson, J. A., Hamid, O., Minor, D., Amin, A., Ron, I., Ridolfi, R., Assi, H., Maraveyas, A., Berman, D., Siegel, J., and O'Day, S. J. (2009). A randomized, double-blind, placebo-controlled, phase II study comparing the tolerability and efficacy of ipilimumab administered with or without prophylactic budesonide in patients with unresectable stage III or IV melanoma. *Clin Cancer Res*, 15(17), 5591-5598
- Wilhelm, S. M., Carter, C., Tang, L., Wilkie, D., McNabola, A., Rong, H., Chen, C., Zhang, X., Vincent, P., McHugh, M., Cao, Y., Shujath, J., Gawlak, S., Eveleigh, D., Rowley, B., Liu, L., Adnane, L., Lynch, M., Auclair, D., Taylor, I., Gedrich, R., Voznesensky, A., Riedl, B., Post, L. E., Bollag, G., and Trail, P. A. (2004). BAY 43-9006 exhibits broad spectrum oral antitumor activity and targets the RAF/MEK/ERK pathway and receptor tyrosine kinases involved in tumor progression and angiogenesis. *Cancer Res*, 64(19), 7099-7109
- Wolchok JD, H. A., O'Day S, Weber JS, Hamid O, Lebbe C, Maio M, Binder M, Bohnsack O, Nichol G, Humphrey R, Hodi FS. (2009). Guidelines for the Evaluation of Immune Therapy Activity in Solid Tumors: Immune-Related Response Criteria. *Clin Cancer Res*, 15(23), 7412-7420
- Wolchok, J. D., Neyns, B., Linette, G., Negrier, S., Lutzky, J., Thomas, L., Waterfield, W., Schadendorf, D., Smylie, M., Guthrie, T., Jr., Grob, J. J., Chesney, J., Chin, K., Chen, K., Hoos, A., O'Day, S. J., and Lebbe, C. (2010). Ipilimumab monotherapy in patients with pretreated advanced melanoma: a randomised, double-blind, multicentre, phase 2, dose-ranging study. *Lancet Oncol*, 11(2), 155-164
- Wyman, K., Atkins, M. B., Prieto, V., Eton, O., McDermott, D. F., Hubbard, F., Byrnes, C., Sanders, K., and Sosman, J. A. (2006). Multicenter Phase II trial of high-dose imatinib mesylate in metastatic melanoma: significant toxicity with no clinical efficacy. *Cancer*, 106(9), 2005-2011
- Yang, J. C., Hughes, M., Kammula, U., Royal, R., Sherry, R. M., Topalian, S. L., Suri, K. B., Levy, C., Allen, T., Mavroukakis, S., Lowy, I., White, D. E., and Rosenberg, S. A. (2007). Ipilimumab (anti-CTLA4 antibody) causes regression of metastatic renal cell cancer associated with enteritis and hypophysitis. *J Immunother*, 30(8), 825-830
- Yang, S., Dudley, M. E., Rosenberg, S. A., and Morgan, R. A. (2010). A simplified method for the clinical-scale generation of central memory-like CD8+ T cells after transduction

with lentiviral vectors encoding antitumor antigen T-cell receptors. *J Immunother*, 33(6), 648-658

- Yeh, T. C., Marsh, V., Bernat, B. A., Ballard, J., Colwell, H., Evans, R. J., Parry, J., Smith, D., Brandhuber, B. J., Gross, S., Marlow, A., Hurley, B., Lyssikatos, J., Lee, P. A., Winkler, J. D., Koch, K., and Wallace, E. (2007). Biological characterization of ARRY-142886 (AZD6244), a potent, highly selective mitogen-activated protein kinase kinase 1/2 inhibitor. *Clin Cancer Res*, 13(5), 1576-1583



Treatment of Metastatic Melanoma

Edited by Ms Rachael Morton

ISBN 978-953-307-574-7

Hard cover, 348 pages

Publisher InTech

Published online 03, October, 2011

Published in print edition October, 2011

Surgery continues to be the mainstay treatment for melanoma localized to the primary tumor and/or lymph nodes. Results from randomized controlled trials indicate that sentinel node biopsy for the treatment of cutaneous melanoma of intermediate thickness has a beneficial effect on recurrence rates, and adjuvant radiotherapy to regional lymph node fields following surgical resection reduces loco-regional recurrence in patients at high risk of relapse. Isolated limb perfusion, electrochemotherapy, and photodynamic therapy continue to be evaluated for treatment of stage IV disease. However, the greatest excitement in new treatment has been with targeted therapies for genetic mutations. In particular, the promising results of partial and complete tumor response in stage IV disease from early phase trials of the B-RAF kinase inhibitors. This book provides a contemporary insight into the therapeutic treatment options for patients with metastatic melanoma and is relevant to clinicians and researchers worldwide. In addition, an update on current clinical trials for melanoma treatment has been included, and two chapters have been reserved to discuss the treatment of oral and uveal melanoma.

How to reference

In order to correctly reference this scholarly work, feel free to copy and paste the following:

Bao Lam, Patrick A. Ott and Anna C. Pavlick (2011). Promising Experimental Therapies for Metastatic Melanoma, *Treatment of Metastatic Melanoma*, Ms Rachael Morton (Ed.), ISBN: 978-953-307-574-7, InTech, Available from: <http://www.intechopen.com/books/treatment-of-metastatic-melanoma/promising-experimental-therapies-for-metastatic-melanoma>

INTech
open science | open minds

InTech Europe

University Campus STeP Ri
Slavka Krautzeka 83/A
51000 Rijeka, Croatia
Phone: +385 (51) 770 447
Fax: +385 (51) 686 166
www.intechopen.com

InTech China

Unit 405, Office Block, Hotel Equatorial Shanghai
No.65, Yan An Road (West), Shanghai, 200040, China
中国上海市延安西路65号上海国际贵都大饭店办公楼405单元
Phone: +86-21-62489820
Fax: +86-21-62489821

© 2011 The Author(s). Licensee IntechOpen. This is an open access article distributed under the terms of the [Creative Commons Attribution 3.0 License](https://creativecommons.org/licenses/by/3.0/), which permits unrestricted use, distribution, and reproduction in any medium, provided the original work is properly cited.

IntechOpen

IntechOpen