

We are IntechOpen, the world's leading publisher of Open Access books Built by scientists, for scientists

6,900

Open access books available

185,000

International authors and editors

200M

Downloads

Our authors are among the

154

Countries delivered to

TOP 1%

most cited scientists

12.2%

Contributors from top 500 universities



WEB OF SCIENCE™

Selection of our books indexed in the Book Citation Index
in Web of Science™ Core Collection (BKCI)

Interested in publishing with us?
Contact book.department@intechopen.com

Numbers displayed above are based on latest data collected.
For more information visit www.intechopen.com



Cutaneous Metastases from Malignant Melanoma: Clinical Features and New Therapeutic Perspectives

Paola Savoia, Paolo Fava and Maria Grazia Bernengo

*Department of Biomedical Sciences and Human Oncology, Section of Dermatology,
University of Turin,
Italy*

1. Introduction

In this chapter, cutaneous metastases from malignant melanoma will be analyzed from a clinical and a prognostic point of view.

This non rare condition is often distressing for the patient, as cutaneous lesions increase progressively in number and size and are frequently worsened by ulceration, bleeding and pain.

After a general introduction about the incidence of cutaneous involvement in melanoma natural history, clinical classification of skin metastases will be provided. Then, the impact of cutaneous localizations on prognosis will be evaluated. In the last paragraph, the different therapeutic options for the management of patients with loco-regional or diffused cutaneous metastases will be reviewed.

2. Epidemiology

Skin metastases from solid tumor are not rare. They affect an estimated percentage of patients ranging from 0.7 to 9% in several literature series (Spencer & Helm 1987, Lookingbill, Spangler & Helm 1993, Schwartz 1995, Hu et al. 2008), in the late phases of disease progression or, in more than 7% of patients, as first sign of disseminated disease (Lookingbill, Spangler & Helm 1993, Rosen 1980). Breast cancer is the most commonly involved tumor, accounting for more than 60% of cases of cutaneous spread, followed by colon carcinoma (Krathen, Orengo & Rosen 2003). Moreover, cutaneous metastatic disease is commonly seen with cancer of the lung, kidney and ovary and with sarcoma, lymphoma or leukemia.

As expected, tumor types are differently distributed among the two genders: lung, colon and head and neck tumours together with melanoma account for the majority of skin metastases in males; whereas, breast cancer is the most common neoplasm related to the development of cutaneous secondary lesions in females (Hu et al 2008).

Focusing on melanoma, skin metastases represent a relatively frequent event in the natural history of the disease and can develop in early as well as in late stage of disease. Cutaneous or subcutaneous lesions arise in 10-17% of patients affected by melanoma and almost the 50% of patients with metastatic disease develops skin involvement (Lookingbill, Spangler & Helm 1993, Schwartz 1995, Krathen, Orengo & Rosen 2003).

No specific clinical or histological characteristics were found in patients with cutaneous metastases from melanoma if compared to those with visceral localizations (Savoia et al 2009). However, known risk factors related to prognosis impact on the metastatic melanoma potential.

3. Classification

On the basis of the distance from the primary melanoma, skin metastases are described as local recurrences, in transit disease or distant metastases. True local recurrences are defined as the reappearance of melanoma in -or contiguous with- an excision scar or a graft and bearing an in situ component (Olsen et al 1970; Brown & Zitelli 1995). The prognosis of local recurrence defined strictly in this way is much better than that associated with in transit disease and 5-year survival rate is related only to the thickness of the primary melanoma. These recurrences are in fact considered as a result of a uncompleted resection of primary melanoma, and are for this reason becoming rare. In-transit disease (satellitosis) indicates cutaneous or subcutaneous disease between the primary site and the regional lymph nodes. Satellite nodules and in-transit disease are associated with worse prognosis (super imposible to a melanoma with nodal metastases; stage III disease), and the distance of cutaneous deposits from the primary site has no prognostic significance (Balch et al 2009). Distant cutaneous metastases are defined as tumour lesions that grow in any skin site over the regional lymph nodes. The presence of any distant metastases delineates a stage IV disease, even if patients with sole distant skin metastases (and normal serum LDH levels) have a relatively better prognosis if compared with those of other metastatic patients (Balch et al 2009). Obviously, distant skin melanoma localization can appear together with or in absence of other visceral metastases. Stage and prognosis vary according to AJCC classification as shown in table 1 (Balch et al 2009).

Clinical Staging				Pathological Staging			
0	Tis	N0	M0	0	Tis	N0	M0
IA	T1a	N0	M0	IA	T1a	N0	M0
IB	T1b	N0	M0	IB	T1b	N0	M0
	T2a	N0	M0		T2a	N0	M0
IIA	T2b	N0	M0	IIA	T2b	N0	M0
	T3a	N0	M0		T3a	N0	M0
IIB	T3b	N0	M0	IIB	T3b	N0	M0
	T4a	N0	M0		T4a	N0	M0
IIC	T4b	N0	M0	IIC	T4b	N0	M0
III	any T	N 1-3	M0	IIIA	T1-T4a	N1a/2a	M0
				IIIB	T1-T4b	N1a/2a	M0
					T1-T4a	N1b/2b	M0
					T1-T4a/b	N2c	M0
				IIIC	T1-T4b	N1b/2b/2c	M0
					any T	N3	M0
IV	any T	any N	M 1	IV	any T	any N	M 1

Table 1. Clinical and pathological staging, AJCC 2009.

4. Clinical features

Skin metastases from melanoma can arise as single or multiple nodules. The most common presentations of cutaneous metastatic disease are brown to black or skin colored papules and nodules, sometimes ulcerated. In the majority of these cases cutaneous metastases were correctly identified by the clinician before the pathologic diagnosis was given; dermoscopy could help in diagnosis, even if skin melanoma metastases have often aspects that are indistinguishable from the characteristic pattern of blue nevi (Carlos-Ortega, de Oca-Monroy & Isyta-Morales 2008). Epidermotropic melanoma metastases are histopathologically characterized by aggregates of atypical melanocytes within the dermis with thinning of the epidermis. Usually there is no lateral extension of atypical melanocytes within the epidermis beyond the concentration of the metastases on the dermis. Metastases differs from primary melanoma by the absence of inflammatory infiltrate and junctional activity, even if a prominent lymphocytic infiltrate can be sometimes observed. In few cases metastatic cells are small and nevoid, with few or any mitoses and differentiation from compound nevi is difficult (Elder E et al, 2005. Tumours and Cysts in dermis and Subcutis, in: *Lever's histopathology of the skin*. Lippincott Williams&Wilkins, Philadelphia).

Less frequently, a wide morphological spectrum of lesions has been described, including erythematous patches or plaques, inflammatory erysipela-like lesions, diffuse sclerodermiform lesions with indurations of the skin ("en cuirasse" metastatic carcinoma), telangiectatic papulovesicles, purpuric plaques mimicking vasculitis, and alopecia areate-like scalp lesions (Saeed, Keehn & Morgan 2004, Sarya et al 2007). In these cases, clinical diagnosis could be more challenging and metastases can be suspicious for benign entities (Figure 1).

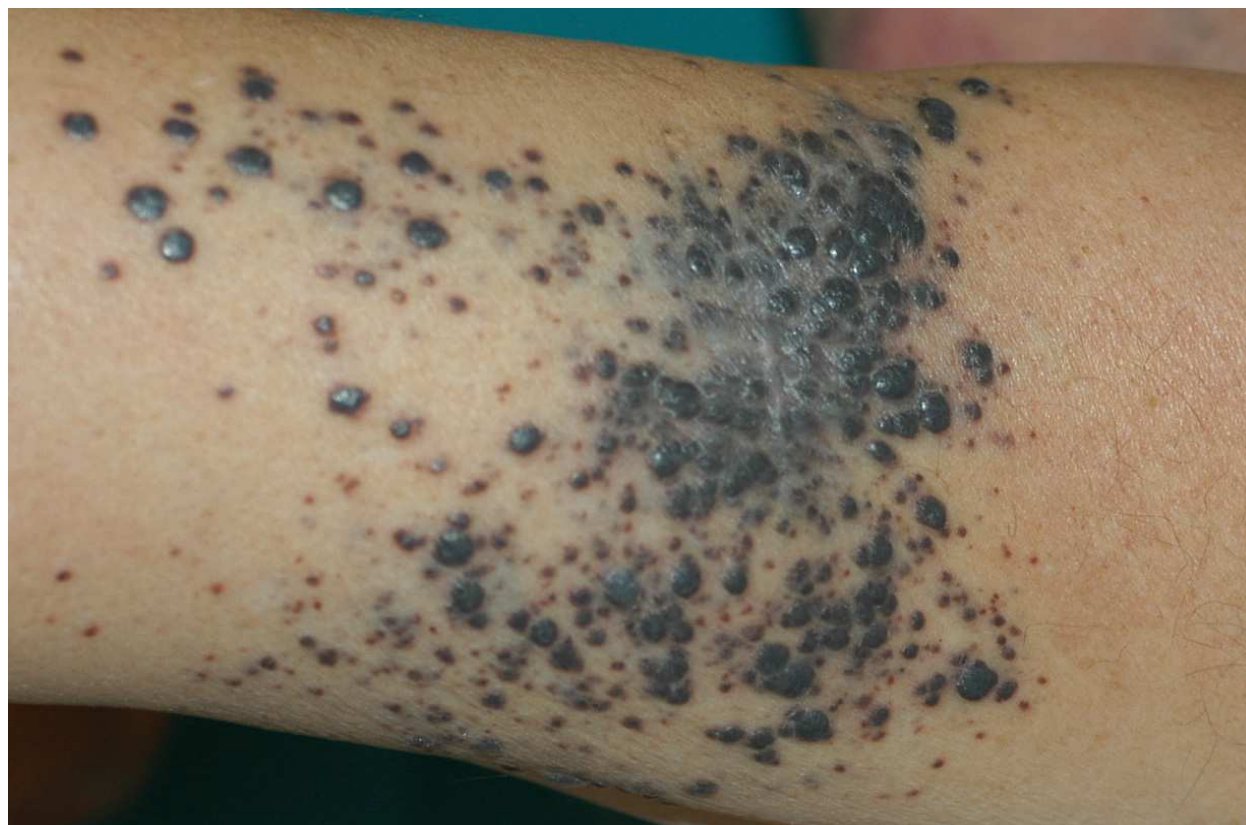

Fig. 1. Clinical features of local recurrences that are defined as the reappearance of melanoma in or contiguous with an excision scar or graft and bearing an *in situ* component.

Moreover, there are also rare cases of so-called zosteriform metastases, with vesicobullous herpetiform lesions or papules and nodules distributed along one or more dermatomes. A previous Varicella Zoster Virus (VZV) infection or widespread lymphatic obstruction by tumor cells can justify the zosteriform pattern (Figure 2).

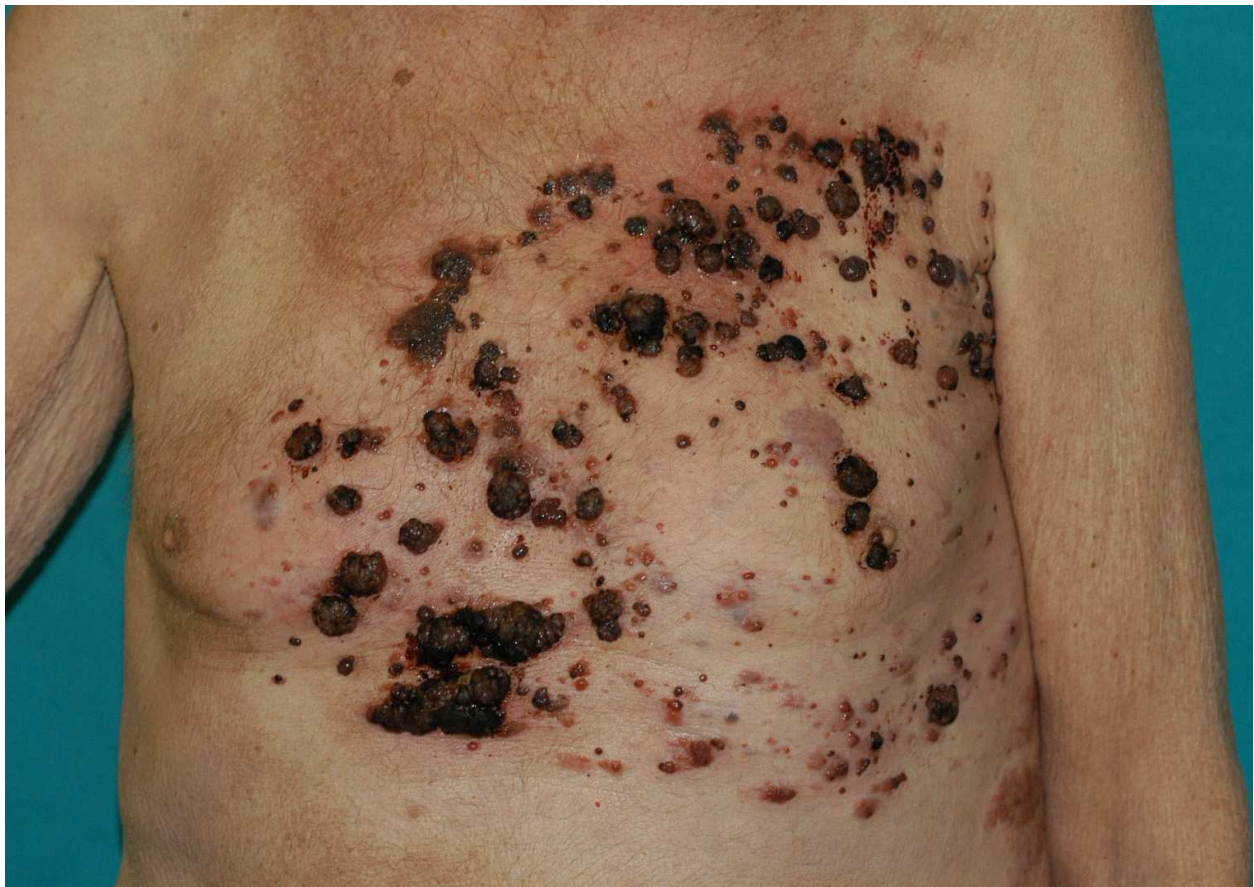

Fig. 2. Zosteriform metastases among thoracic dermatomes.

However, zosteriform metastases, as well as the rare skin metastases occurring on skin graft donor site, could be explained as a Koebner phenomenon (Savoia et al 2009, Marengo et al 2009).

From a clinical point of view, if bleeding and super-infection are not present, superficial skin metastases are usually asymptomatic, even if patients frequently report localized pain and paresthesiae anticipating the onset of clinically evident cutaneous lesions; these symptoms are related to oedema and mechanical stress on the near tissues and usually disappear in a few days. On the other hand, when subcutaneous lesions grow deep infiltrating muscles or nerves become very painful. The management of pain in these cases could be difficult and requires a multidisciplinary approach.

As mentioned earlier, bleeding and super-infections are the most frequent complications of skin metastases and can significantly impact on the patient's quality of life (Kaheler, Egeberts & Hauschild 2010). These complications can also compromise general conditions. Massive bleeding from cutaneous metastases could become life threatening; sepsis related to the bacterial dissemination of infected metastases represents an uncommon but not rare event, that lead to septic shock and death (Figure 3).

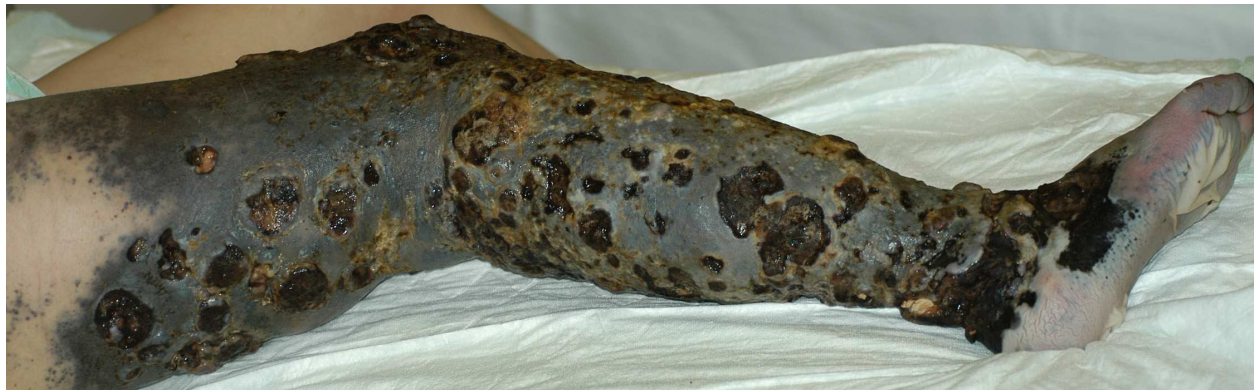

Fig. 3. Infected diffuse metastases from malignant melanoma

5. Pattern of cutaneous localizations

Cutaneous secondary lesions can occur on all anatomic sites, with skin metastases from other solid tumours more frequently found on the head, neck, anterior chest and abdomen, whereas lower extremities are rarely involved (Schwartz, 1995). Conversely, skin metastases from melanoma are more frequently observed on the back in men and on the lower limbs in women. These different patterns of cutaneous localizations among sex can be explained by the fact that in more than 30% of cases, secondary cutaneous localizations occur in the same anatomic area of the primary (Savoia et al 2009).

6. Clinical course and prognosis

In more than half of the cases, skin represents the first site of metastatic involvement after the primary melanoma diagnosis. In about one third of cases, patients develop skin involvement after evidences of regional lymph nodal metastatic disease.

The finding of concomitant distant cutaneous, visceral and nodal metastases account for more than 10% of cases, whereas skin involvement after visceral dissemination is rare, and occurs only in about the 3% of patients (Savoia et al 2009).

Cutaneous metastases are loco regional in nearly 80% of cases, whereas distant metastases were documented in the remaining 20% of patients. A different pattern of cutaneous metastases was related to the time of onset: when cutaneous metastases arise as the first site of relapse, there is a significant higher percentage of locoregional localizations, whereas distant skin involvement was more frequently observed after visceral involvement. No significant differences were found between patients with regional and those with distant metastases regarding to the known risk factors, such as Breslow thickness, Clark level, histotype of the primary melanoma and ulceration (Savoia et al 2009).

It is noteworthy that in patients with distant metastases, primary melanomas arose predominantly at trunk and back, whereas patients with cutaneous loco-regional spreading were affected mainly by primary located at leg and foot. As we know, loco-regional metastases develop as a result of tumour cell embolization in the dermal lymphatic vessels between the primary tumour site and the draining regional lymph node basin; lymphatic stasis to lower limbs consequent to nodal dissection represents an additional risk factor for cutaneous locoregional dissemination.

In contrast, the correlation between disseminated skin lesions and primary melanoma located to the trunk could be explained by the fact that the lymph drainage of this region is

not strictly dependent on a single station, but it could be resulted from more than one lymphatic basin, together with a possible role of haematogenous spreading.

Disease free survival evaluated from the first melanoma diagnosis varies in relation to the first site of metastatization. In our experience, loco regional cutaneous relapses develop early, but show a very late progression to visceral disease. On the contrary, patients with disseminated skin lesions as first site of relapse had a longer disease free interval from the first diagnosis but a shorter time to progression to visceral metastases (Savoia et al 2009).

7. Treatment and clinical management

The choice of the modality of treatment for cutaneous melanoma metastases depends on several factors, including location and number of lesions, presence of systemic involvement, age and general health conditions of patients. Moreover, the prognostic differences between patients with loco-regional and distant skin metastases justify different approaches in their clinical management.

Important therapeutic options including surgery, isolated limb perfusion, local or systemic chemo- and immuno-therapy and radiotherapy are discussed in detail below.

7.1 Surgery

Surgery is the gold standard and represents the most effective treatment for limited in-transit disease, when technically feasible. It is an adequate treatment when the lesions are relatively small and clustered in a reasonable circumscribed area. Primary melanoma should be excised widely with a 1-2 cm margin depending on Breslow thickness, whereas wide surgical margins are unnecessary for the treatment of cutaneous metastases. Usually, metastases are clearly demarcated from the surrounding normal dermis and overlying epidermis and the better approach is the complete macroscopical excision of the lesion. When microscopical involvement of margins is documented, reintervention is not mandatory (Hoekstra, 2008).

If technically possible, direct wound closure is to prefer; the second choice is represented by skin graft, because plastic surgical reconstruction can affect the lymphatic drainage pattern.

Palliative treatment should be considered when results in the control of local complications (e.g. bleeding) and/or in a consistent quality of life improvement.

Amputation should be only considered as palliation for imminent exsanguinating haemorrhage or fungation unacceptable for the patient.

7.2 Isolated limb perfusion

Isolated limb perfusion (ILP) -firstly described by Creech and Krementz in 1958- can deliver high doses of cytotoxic agents to a limb, minimizing systemic toxicity. The dose received regionally can be up to tenfold higher than the systemic mean tolerated dose. Isolated limb perfusion is widely indicated for patients with advanced or recurrent in-transit disease, showing a complete response rate around the 50% in the majority of the published series, with an overall response rate up to 80% (Lens & Dawes 2003, Rossi et al 2010). On the contrary, the role of isolated limb perfusion as adjuvant therapy is still debated (Hoekstra 2008). The tumour response after perfusion is the only demonstrated prognostic factor affecting local control of the disease and overall survival (Rossi et al 2010).

The usual agent employed is melphalan, with or without tumour necrosis factor (TNF); TNF increases response rate thanks to its selective disruption of the tumour microvasculature, with

a consequent ischemic damage of melanoma cells, even if seems not to influence the long term local control (Di Filippo et al 2006). Dacarbazine is less effective when administered regionally; other combinations of cytostatics (dactinomycin, nitrogen mustard, vindesine, thio-TEPA) have also been proposed but the published series are too small to give absolute conclusions (Daryanani et al 2000, de Wilt et al 2000, Hoeckstra 2008). Hyperthermia, with temperature between 39° to 41° act sinergically with high dose chemotherapy, even if can exacerbate loco regional toxicity (Hoeckstra 2008).

General anesthesia is required. However, age does not represent a contraindication to ILP. Systemic side effects, due to drug releasing into the systemic circulation are rare and mainly represented by nausea, vomiting and mild bone marrow suppression. Local toxic reactions are more frequently described and ranges from mild erythema to deep tissue inflammation; nearly 25% of patients develop neuropathy or pain, whereas chronic edema is usually related to lymphadenectomy (Bonifati et al 2000, Rossi et al 2002).

7.3 Electrochemotherapy

Recently, electrochemotherapy (ECT) has been proposed as a new treatment modality for skin metastases of different malignancy, including melanoma. ECT enhances membrane permeability by electric pulses thus permitting a major drug delivery in neoplastic cells and a better cytotoxic effect.

Bleomycin and cisplatin are the drugs more frequently used in ECT with an increased efficacy up to 8.000-fold for bleomycin, and up to 80-fold for cisplatin (Gaudy et al 2006).

The ECT technique requires only a regional anesthesia or mild general sedation with a lower duration if compared to isolated limb perfusion. With respect to ILP, ECT shows a minimal systemic toxicity; treatment is generally well tolerated; side effects were mainly represented by erythema and edema at the site of treated lesions, superficial erosions, scars and permanent marks from the electrodes (Quaglino et al 2008). Thus ECT can be performed also in patients with major co morbidities.

The first large study about effectiveness of ECT in melanoma treatment, was the multi center European Standard Operating Procedure of Electrochemotherapy (ESOPE), based on the new Cliniporator™ Electric Pulse Generator; this study enrolled twenty melanoma patients, with an overall response rate of more than 20% (Marty et al 2008). Several papers recently published confirm these encouraging results of ECT in the control of skin metastases (Campana et al 2009, Moller et al 2009). In our experience, the global response rate was of 79.4, with a percentage of complete remissions of 23.2%(Quaglino et al 2008); complete response was defined in accordance World Health Organization (WHO) guidelines as the total clinical disappearance of the tumor (WHO. From *Handbook for Reporting Results of Cancer Treatment*, vol 48; pp 22-27. Geneva, 1997).

The lesion size was the most predictive parameter for response; response rate for larger lesions was significantly lower. Moreover, a second limit is represented by the possible relapse of new lesions on untreated areas: ECT represent in fact a local treatment. However, it is possible to repeat ECT, both on new metastases in untreated areas and on already treated lesions with a previous partial remission or no changes. In our experience, new responses were obtained in about 60% of retreated lesions.

Appropriate dressing should be performed with the aim to control ulceration of cutaneous tumours, local infectious complications and to ensure an acceptable quality of life.

7.4 Radiotherapy

The effectiveness of radiotherapy in the treatment of melanoma metastases is still debated. A poor response was historically observed on in vitro cultures from melanoma cells treated with external-beam radiation (Barranco, Romsdahl & Humphrey 1971). So, radiotherapy was mainly used as palliation when disease was too extensive for surgery and other modalities of treatment were inadvisable or ineffective in stage III and IV melanoma patients. However, a retrospective review (Fenig et al 2009) showed a 52% response rate in stage IV patients who received radiotherapy with palliative intent and others studies (Sause et al 1991; Seegenschmeid et al 1999) demonstrated an overall response rate ranging from 60 to 79% for stage III disease. Moreover, disease-free and overall survival seems to be significant longer in patients who received radiotherapy (Olivier et al, 2007).

7.5 Chemotherapy

Usually, chemotherapy plays a role in the treatment of stage IV melanoma patients with visceral metastases. Regarding cutaneous metastases, chemotherapy can be used in patients with wide spread skin lesions not eligible for local treatments, with or without a concomitant visceral involvement.

Chemotherapy could be used also in stage III, when other loco-regional treatments have failed or are technically not feasible (e.g. cutaneous lesions diffused at trunk or back).

The global response rate is less than 25% for single agent treatment. The gold standard is still represented by Dacarbazine; new molecules as Temozolomide and Fotemustine showed a super imposing disease-free and overall survival, with major toxicity (Middelton et al, 2000). Combination regimens or chemo-immunotherapy give higher response rate but also more severe side effects. However, response to chemo-immunotherapy is not related to statistically significant benefit in term of overall survival when compared with a single-agent treatment.

Recently, Ipilimumab, a human anti-CTLA4 monoclonal antibody showed objective responses or disease stabilization in patients with advanced melanoma (O'Day et al, 2010). No data about the effectiveness of Ipilimumab in the treatment of cutaneous metastases are available, even if several studies are ongoing.

The response rate for in transit metastases treated with dacarbazine is 15-20%; the majority of the responses are partial with a median response duration less than 6 months. Chemoimmunotherapy showed also no survival benefit (Hoekstra 2008).

Finally, the clinical efficacy of RAF inhibitors in BRAF mutated melanoma patients are under evaluation after some encouraging preliminary report; a phase I study on patients with both disseminated cutaneous and visceral metastases reported an 81% of clinical responses in patients treated with selective BRAF inhibitor, with a median time to progression of 6-9 months (Flaherty, 2010).

7.6 Others

7.6.1 Laser ablation

Patients with small (<2 cm) and superficial lesions who are not suitable for isolated limb perfusion, ECT or other conventional modalities of treatment can be considered for carbon dioxide (CO₂) laser ablation. This therapy is minimally invasive: only local anesthesia is required and the resultant defect does not require surgical closure but can be covered with a dressing until secondary healing (Lingam & McKay, 1996; Gibson, Byrne & Mc Kay, 2004).

So, can be considered a minimally invasive and effective method of palliation; the role as first line treatment is still debated, in fact the technique can be used to treat only visible and superficial lesions, while deep subcutaneous metastases, large volume lesions and microscopic disease can not be treated with laser ablation (Gimbel, Delman & Zager, 2008).

7.6.2 Cryosurgery

This technique uses temperatures from -50°C to -60°C (with nitrogen spray) to obtain direct tissue destruction. The heat transfer results in vascular stasis, ice crystal and disruption of cell membranes, Ph changes, hypertonic damage and thermal shock that lead to tissue damage and necrosis. Low temperature causes the development of a bulla and a secondary healing with a scar. After the introduction of laser ablation and ECT, cryosurgery is less frequently used in the treatment of cutaneous metastases from melanoma (Hoekstra, 2008).

7.6.3 Intralesional therapy

The intralesional injection of bacillus Calmette-Guérin (BCG) was the first immunotherapy used in the local treatment of cutaneous metastases from melanoma. This procedure was accompanied by sever complications such as ulceration, skin necrosis, and superinfection without significative improvement of lesions treated (Tan & Ho, 1993). Other drugs such as IL-2, INF alpha and dinitrochlorobenzene, with or without sistemic dacarbazine, were more recently used as intralesional therapy (Radny et al, 2003; Strobbe et al, 1997); results are still debating and further investigations are necessary. Encouraging results regarding high-dose intratumoral IL-2 administration in melanoma patients with cutaneous secondarities has been reported (Weide et al, 2010): a complete local response was described in more than 60% of melanoma patients and seemed to be associated with an increased responses to subsequent chemotherapies. Recently, phase I studies confirmed the safety and an enhanced immune response for intralesional injection of Allovectin in metastatic melanoma patients. Unfortunately, phase II studies showed a complete response in only the 3.1% of treated patients, with an overall response rate of 11.8% and a median time-to-progression of 1.6 months (Beidikan et al, 2010).

Rose bengal has been proposed as a possible intralesional treatment, with an objective response rate ranging from 27 to 69%, related to the dose of injection (Thompson, Hersey & Wachter, 2008). Sistemic toxicity is low, even if phototoxic reactions have been described.

An interesting therapeutic option is represented by topical imiquimod. It enhances the immune system activity leading to an induction of melanoma-specific cytotoxic T-cells by cross presentation of melanoma antigen by dendritic cells. Partial remission of locoregional cutaneous metastases treated with imiquimod was demonstrated (Wolf, Richtig, Kopera & Kerl H, 2004).

8. Conclusions


Skin metastases from melanoma are a frequent finding in the natural history of the disease with various clinical, morphological and histopathologic backgrounds. The presence of progressively increasing metastases is often distressing for the patient, and ulceration, bleeding and super-infections can negatively impact on the life-quality. To date, many treatments are available for the clinical management of these lesions. Thus, clinicians should be informed about the prognostic implications and the therapeutic options in order to choose the best cost-effectiveness treatment modality.

9. References

- Balch CM, Gershenwald JE, Soong SJ, Thompson JF, Atkins MB, Byrd DR, Buzaid AC, Cochran AJ, Coit DG, Ding S, Eggermont AM, Flaherty KT, Gimotty PA, Kirkwood JM, McMasters KM, Mihm MC Jr, Morton DL, Ross MI, Sober AJ & Sondak VK. Final version of 2009 AJCC melanoma staging and classification. *J Clin Oncol*. 2009; 27: 6199-6206.
- Barranco SC, Romsdahl MM & Humphrey RM. The radiation response of human malignant melanoma cells grown in vitro. *Cancer Res*. 1971; 31:830-833.
- Bedikian A, Richards J, Kharkevitch D, Atkins MB, Whitman E & Gonzalez R. A phase 2 study of high-dose Allovectin-7 in patients with advanced metastatic melanoma. *Melanoma Research* 2010, 20: 218-226.
- Bonifati DM, Ori C, Rossi CR, Caira S, Fanin M & Angelini C. Neuromuscular damage after hyperthermic isolated limb perfusion in patients with melanoma or sarcoma treated with chemotherapeutic agents. *Cancer Chemother Pharmacol*. 2000; 46: 517-522.
- Brown CD, Zitelli JA. The prognosis and treatment of true local cutaneous recurrent malignant melanoma. *Dermatol Surg*. 1995 Apr;21(4):285-90.
- Campana LG, Mocellin S, Basso M, Puccetti O, De Salvo GL, Chiarion-Sileni V, Vecchiato A, Corti L, Rossi CR & Nitti D. Bleomycin-based electrochemotherapy: clinical outcome from a single institution's experience with 52 patients. *Ann Surg Oncol*. 2009 Jan; 16(1): 191-9.
- Carlos-Ortega B, de Oca-Monroy FM & Isyta-Morales A. Dermoscopy findings in malignant skin melanoma with metastases. A case report. *Rev Med Inst Mex Seguro Soc*. 2009; 47:73-76.
- Daryanani D, de Vries EG, Guchelaar HJ, van Weerden TW & Hoekstra HJ. Hyperthermic isolated regional perfusion of the limb with carboplatin. *Eur J Surg Oncol*. 2000; 26(8): 792-797.
- de Wilt JH, Soma G, ten Hagen TL, Kanou J, Takagi K, Nooijen PT, Seynhaeve AL & Eggermont AM. Synergistic antitumour effect of TNF-SAM2 with melphalan and doxorubicin in isolated limb perfusion in rats. *Anticancer Res*. 2000 Sep- Oct; 20(5B): 3491-3496.
- Di Filippo F, Rossi CR, Santinami M, Cavaliere F, Garinei R, Anzà M, Perri P, Botti C, Di Angelo P, Pasqualoni R & Di Filippo S. Hyperthermic isolation limb perfusion with TNF α in the treatment of in-transit melanoma metastasis. *In Vivo*. 2006 Nov-Dec; 20(6A):739-742.
- Fenig E, Eidelevich E, Njuguna E, Katz A, Gutman H, Sulkes A & Schechter J. Role of radiation therapy in the management of cutaneous malignant melanoma. *Am J Clin Oncol*. 1999; 22: 184-186.
- Flaherty KT. Narrative review: BRAF opens the door for therapeutic advances in melanoma. *Ann Intern Med*. 2010 Nov 2;153(9):587-91.
- Gaudy C, Richard MA, Folchetti G, Bonerandi JJ & Grob JJ. Randomized controlled study of electrochemotherapy in the local treatment of skin metastases of melanoma. *J Cutan Med Surg*. 2006 May-Jun; 10(3): 115-121.
- Gibson SC, Byrne DS & Mc Kay AJ. Ten-year experience of carbon dioxide laser ablation as treatment for cutaneous recurrence of malignant melanoma. *Br J Surg* 2004; 91: 893-895.
- Gimbel MI, Delman KA & Zager JS. Therapy for unresectable recurrent and in-transit extremity melanoma. *Cancer Control*. 2008; 15: 225-232.

- Hoekstra HJ. The European approach to in-transit melanoma lesions. *Int J Hyperthermia*. 2008; 24: 227-237.
- Hu SC, Chen GS, Lu YW, Wu CS & Lan CC. Cutaneous metastases from different internal malignancies: a clinical and prognostic appraisal. *J Eur Acad Dermatol Venereol* 2008; 22: 735-740.
- Kaheler Kc, Egeberts F& Hauschild A. Electrotherapy in symptomatic melanoma skin metastases: intraindividual comparison with conventional surgery. *Dermatol Surg*. 2010; 36: 1200-1202.
- Krathen RA, Orengo IF & Rosen T. Cutaneous metastasis: a meta-analysis of data. *South Med J* 2003; 96:164-167.
- Lens MB & Dawes M. Isolated limb perfusion with melphalan in the treatment of malignant melanoma of the extremities: a systematic review of randomised controlled trials. *Lancet Oncol*. 2003 Jun; 4(6): 359-364.
- Elder E, Elenitsas R, Johnoson B, Ioffreda M, Miller J & Miller F, 2005. Tumours and Cysts in dermis and Subcutis, in: *Lever's histopathology of the skin*. Lippincott Williams&Wilkins, Philadelphia
- Lingam MK & McKay AJ. Carbon dioxide laser ablation as an alternative treatment for cutaneous metastases from malignant melanoma. *Br J Surg* 1996; 83: 509-512.
- Lookingbill DP, Spangler N & Helm KF. Cutaneous metastases in patients with metastatic carcinoma: a retrospective study of 4020 patients. *J Am Acad Dermatol* 1993; 29: 228-236.
- Marenco F, Fava P, Macripò G, Quagliano P, Savoia P & Bernengo MG. Cutaneous melanoma metastases arising on a split-skin graft donor site. *Dermatol Surg* 2009; 35: 1-4.
- Marty M, Sersa G, Garbay JR, Gehl J, Collins CG, Snoj M, Billard V, Geertsens PF, Larkin JO, Miklavcic D, Pavlovic I, Paulin-Kosir SM, Cemazar M, Morsli N, Rudolf Z, Robert C, O'Sullivan GC & Mir LM. Electrochemotherapy-An easy, highly effective and safe treatment of cutaneous and subcutaneous metastases: results of ESOPE (European Standard Operating Procedures of Electrochemotherapy study. *Eur J Cancer* 2006; 4(Suppl): 3-13.
- Middleton MR, Lorigan P, Owen J, Ashcroft L, Lee SM, Harper P & Thatcher N. A randomized phase III study comparing dacarbazine, BCNU, cisplatin and tamoxifen with dacarbazine and interferon in advanced melanoma. *Br J Cancer*. 2000 Mar; 82(6): 1158-1162.
- Möller MG, Salwa S, Soden DM & O'Sullivan GC. Electrochemotherapy as an adjunct or alternative to other treatments for unresectable or in-transit melanoma. *Expert Rev Anticancer Ther*. 2009 Nov; 9(11): 1611-1630.
- O'Day SJ, Maio M, Chiarion-Sileni V, Gajewski V, Pehamberger H, Bondarenko NH, Queirolo P, Lundgren L, Mikhailov M, Roman L, Verschraegen C, Humphrey C, Ibrahim R, de Pril V, Hoos A & Wolchok JD. Efficacy and safety of ipilimumab monotherapy in patients with pretreated advanced melanoma: a multicenter single-arm phase II study. *Ann Oncol*. 2010 Aug; 21(8): 1712-1717.
- Olivier KR, Schild SE, Morris CG, Brown PD & Markovic SN. A higher radiotherapy dose is associated with more durable palliation and longer survival in patients with metastatic melanoma. *Cancer* 2007; 110: 1791-1795.
- Olsen G. Some views on the treatment of melanomas of the skin. *Arch Chir Neerl*. 1970; 22(2): 79-90.
- Quagliano P, Mortera C, Osella-Abate S, Barberis M, Illengo M, Rissone M, Savoia P & Bernengo MG. Electrochemotherapy with intravenous bleomycin in the local

- treatment of skin melanoma metastases. *Ann Surg Oncol*. 2008 Aug;15(8):2215-22. Epub 2008 May 23.
- Radny P, Caroli UM, Bauer J, Paul T, Schlegel C, Eigentler TK, Weide B, Schwarz M & Garbe C Phase II trial of intralesional therapy with interleukin-2 in soft-tissue melanoma metastases. *Br J Cancer*. 2003; 89: 1620-1626
- Rosen T. Cutaneous metastases. *Med Clin North Am* 1980; 64: 885-900.
- Rossi CR, Foletto M, Pilati P, Mocellin S & Lise M. Isolated limb perfusion in locally advanced cutaneous melanoma. *Semin Oncol*. 2002; 29: 400-409.
- Rossi CR, Pasquali S, Mocellin S, Vecchiato A, Campana LG, Pilati P, Zanon A & Nitti D. Long-term results of melphalan-based isolated limb perfusion with or without low-dose TNF for in-transit melanoma metastases. *Ann Surg Oncol*. 2010 Nov; 17(11): 3000-3007. Epub 2010 Apr 29.
- Saeed S, Keehn CA & Morgan MB. Cutaneous metastasis: a clinical, pathological, and immunohistochemical appraisal. *J Cutan Pathol* 2004; 31: 419-430.
- Sariya D, Ruth K, Adams-McDonnell R, Cusack C, Xu X, Elenitsas R, Seykora J, Pasha T, Zhang P, Baldassano M, Lessin SR & Wu H. Clinicopathologic correlation of cutaneous metastases: experience from a cancer center. *Arch Dermatol* 2007; 143:613-620.
- Sause WT, Cooper JS, Rush S, Ago CT, Cosmatos D, Coughlin CT, JanJan N & Lipsett J. Fraction size in external beam radiation therapy in the treatment of melanoma. *Int J Radiat Oncol Biol Phys*. 1991; 20: 429-32.
- Savoia P, Fava P, Deboli T, Quaglino P & Bernengo MG. Zosteriform Cutaneous Metastases: A Literature Meta-Analysis and a Clinical Report of Three Melanoma Cases. *Dermatol Surg*. 2009; 35: 1355-1363.
- Savoia P, Fava P, Nardò T, Osella-Abate S, Quaglino P & Bernengo MG. Skin metastases of malignant melanoma: a clinical and prognostic survey. *Melanoma Res*. 2009; 19: 321-326.
- Schwartz RA. Cutaneous metastatic disease. *J Am Acad Dermatol* 1995; 33: 161-182.
- Seegenschmiedt MH, Keilholz L, Altendorf-Hofmann A, Urban A, Schell H, Hohenberger W & Sauer R. Palliative radiotherapy for recurrent and metastatic malignant melanoma: prognostic factors for tumor response and long-term outcome: a 20-year experience. *Int J Radiat Oncol Biol Phys*. 1999; 44: 607-618.
- Spencer PS & Helm TN. Skin metastases in cancer patients. *Cutis* 1987; 39: 119-121.
- Strobbe LJ, Hart AA, Rümke P, Israels SP, Nieweg OE & Kroon BB. Topical dinitrochlorobenzene combined with systemic dacarbazine in the treatment of recurrent melanoma. *Melanoma Res*. 1997; 7: 507-512.
- Tan JK & Ho VC. Pooled analysis of the efficacy of bacille Calmette-Guerin (BCG) immunotherapy in malignant melanoma. *J Dermatol Surg Oncol*. 1993; 19: 985-990.
- Thompson JF, Hersey P & Wachter E. Chemoablation of metastatic melanoma using intralesional Rose Bengal. *Melanoma Res*. 2008 Dec; 18(6): 405-411.
- Weide B, Eigentler TK, Pflugfelder A, Leiter U, Meier F, Bauer J, Schmidt D, Radny P, Pföhler C, Garbe C. Survival after intratumoral interleukin-2 treatment of 72 melanoma patients and response upon the first chemotherapy during follow-up. *Cancer Immunol Immunother*. 2010; Dec 21.
- WHO. From *Handbook for Reporting Results of Cancer Treatment*, vol 48; Geneva, 1997
- Wolf IH, Richtig E, Kopera D & Kerl H. Locoregional cutaneous metastases of malignant melanoma and their management. *Dermatol Surg*. 2004; 30: 244-247.



Treatment of Metastatic Melanoma

Edited by Ms Rachael Morton

ISBN 978-953-307-574-7

Hard cover, 348 pages

Publisher InTech

Published online 03, October, 2011

Published in print edition October, 2011

Surgery continues to be the mainstay treatment for melanoma localized to the primary tumor and/or lymph nodes. Results from randomized controlled trials indicate that sentinel node biopsy for the treatment of cutaneous melanoma of intermediate thickness has a beneficial effect on recurrence rates, and adjuvant radiotherapy to regional lymph node fields following surgical resection reduces loco-regional recurrence in patients at high risk of relapse. Isolated limb perfusion, electrochemotherapy, and photodynamic therapy continue to be evaluated for treatment of stage IV disease. However, the greatest excitement in new treatment has been with targeted therapies for genetic mutations. In particular, the promising results of partial and complete tumor response in stage IV disease from early phase trials of the B-RAF kinase inhibitors. This book provides a contemporary insight into the therapeutic treatment options for patients with metastatic melanoma and is relevant to clinicians and researchers worldwide. In addition, an update on current clinical trials for melanoma treatment has been included, and two chapters have been reserved to discuss the treatment of oral and uveal melanoma.

How to reference

In order to correctly reference this scholarly work, feel free to copy and paste the following:

Paola Savoia, Paolo Fava and Maria Grazia Bernengo (2011). Cutaneous Metastases from Malignant Melanoma: Clinical Features and New Therapeutic Perspectives, *Treatment of Metastatic Melanoma*, Ms Rachael Morton (Ed.), ISBN: 978-953-307-574-7, InTech, Available from:
<http://www.intechopen.com/books/treatment-of-metastatic-melanoma/cutaneous-metastases-from-malignant-melanoma-clinical-features-and-new-therapeutic-perspectives>

INTECH
open science | open minds

InTech Europe

University Campus STeP Ri
Slavka Krautzeka 83/A
51000 Rijeka, Croatia
Phone: +385 (51) 770 447
Fax: +385 (51) 686 166
www.intechopen.com

InTech China

Unit 405, Office Block, Hotel Equatorial Shanghai
No.65, Yan An Road (West), Shanghai, 200040, China
中国上海市延安西路65号上海国际贵都大饭店办公楼405单元
Phone: +86-21-62489820
Fax: +86-21-62489821

© 2011 The Author(s). Licensee IntechOpen. This is an open access article distributed under the terms of the [Creative Commons Attribution 3.0 License](https://creativecommons.org/licenses/by/3.0/), which permits unrestricted use, distribution, and reproduction in any medium, provided the original work is properly cited.

IntechOpen

IntechOpen