

We are IntechOpen, the world's leading publisher of Open Access books Built by scientists, for scientists

6,900

Open access books available

186,000

International authors and editors

200M

Downloads

Our authors are among the

154

Countries delivered to

TOP 1%

most cited scientists

12.2%

Contributors from top 500 universities



WEB OF SCIENCE™

Selection of our books indexed in the Book Citation Index
in Web of Science™ Core Collection (BKCI)

Interested in publishing with us?
Contact book.department@intechopen.com

Numbers displayed above are based on latest data collected.
For more information visit www.intechopen.com



Light-Induced Fluorescence Techniques for Gastrointestinal Tumour Detection

Ekaterina Borisova¹, Borislav Vladimirov²,
Radina Ivanova³ and Latchezar Avramov¹

¹*Institute of Electronics, Bulgarian Academy of Sciences,*

²*Department of Gastroenterology, University hospital "Queen Yoanna-ISUL",*

³*Laboratory of pathomorphology, University hospital of Endocrinology,
Medical University, Sofia,
Bulgaria*

1. Introduction

Gastrointestinal tumors have major place in the statistics of newly developed cancers every year, as the colon cancer is on third place, stomach cancer is on fifth place, and esophageal cancer is also in the top ten of tumors according statistics of cancer incidence. Usually the tumors are detected on advanced III and IV stage, where the perspectives for the patients are not very optimistic (Danon, 2003; Jemal, 2011). Up to now white light endoscopy is the main method in detection of gastrointestinal tumors. White-light endoscopy is well-established and wide used modality. However, despite the many technological advances that have been occurred, conventional white light endoscopy is suboptimal and usually detects lesions, which already have symptoms of obstruction, bleeding and pain, related to tumor growth. Misdiagnoses, related to difficulties in differentiation of inflammatory from initial stage adenocarcinoma also have negative effect on the diagnostic accuracy (Da Costa, 2003). Only experienced gastroenterologists with long practice in endoscopy observations could find slight initial changes to dysplastic and neoplastic stages of esophageal, stomach or colon mucosa.

The limitations of standard endoscopy for detection and evaluation of cancerous changes in gastrointestinal tract are significant challenge and initiate development of new diagnostic modalities. Such detection and visualization techniques, additional to standard endoscopy equipment, including optical detection of tissues alterations are investigated and their feasibilities for clinical usage are evaluated. Advances in fiber optics, light sources, detectors have led to the development of several novel methods for tissue evaluation in situ. Optical methods applied for such tissue evaluation often are referred under term "optical biopsy", which indicate their possibilities to make an instant diagnosis at endoscopy, previously possible only by using of histological and/or cytological analysis (Wang, 2004).

The new optical approaches are based on light-tissue interactions and differences occurred between normal and abnormal tissue sites. In gastroenterology several optical methods are applied recently, such as optical coherent tomography (Tumlinson, 2004), chromo-endoscopy, confocal fluorescent microscopy (DaCosta, 2003a; 2003b), Raman

spectroscopy (Yan, 2005), reflectance spectroscopy (Sun, 2001) and laser- and light-induced fluorescence spectroscopy (Chissov, 2003). In general, photodiagnostic techniques may be very useful for the detection of pre-malignant dysplasia and early malignant changes in gastrointestinal tract. Spectral diagnosis can provide both imaging and spectroscopic information; and the techniques divide into those that provide morphological data and those that have the potential for molecular and biochemical information. Morphological information provides *in vivo* histology and the techniques include optical coherence tomography, light scattering spectroscopy, and confocal microscopy. Fluorescence imaging and spectroscopy provide both morphological and biochemical data. Raman spectroscopy provides the most powerful tool for obtaining precise molecular data.

Such advanced methods go beyond standard endoscopic techniques and allow receiving better image resolution, contrast, higher sensitivity, tissue penetration and could provide even biochemical, structural and molecular information about mucosal lesions investigated. One of the most sensitive optical detection approaches is light-induced fluorescence spectroscopy (LIFS) of gastrointestinal mucosa for neoplasia detection. This technique is most widely examined from among of spectroscopic techniques in general, because of its rapid and highly sensitive response to early biochemical and morphological changes in the tissues.

Fluorescent diagnosis of tumor tissues becomes a valuable tool in the clinical practice. This technique could be applied for detection and evaluation of tumors in different localizations using endoscopic equipment. Such combined white-light and fluorescent mode endoscopic systems are already developed and introduced in the clinic for the needs of bronchoscopy and lung cancer diagnosis, like D-Light system of Karl Storz GmbH, DAFE system (Diagnostic AutoFluorescence Endoscope) of Richard Wolf GmbH, LIFE (Lung Fluorescence Endoscopy System) of Xillix Technologies Corp. (DaCosta, 2003; Gabreht, 2007; McMichael, 1997; Chissov, 2003).

However, fluorescent gastroscopes are still on its research and development phases and from the best we know the few existing systems, such as Olympus Evis Lucera, has not received yet all approvals for access to the broad clinical market. This system is a digestive tract videoscope used for observing of blood vessels in mucous membranes under infrared light in the regions 790-820 nm and 905-970 nm. Variation of Xillix fluorescent endoscopic system - Xillix-LIFE-GI is applied for autofluorescence detection of stomach neoplasia and has approval for Japan and European countries. Several fluorescent endoscopy systems are developed and proposed also for applications in the practice by different research teams, demonstrating very good clinical results (Chissov, 2003; Papayan, 2006; Sokolov, 2002), using autofluorescence or exogenous fluorescence detection of gastrointestinal neoplasia.

Despite of the fluorescent endoscopic systems developed mentioned above, the fluorescent diagnosis of tumors of the upper part of gastrointestinal tract still is very interesting and extensive research and development task worldwide. On the current moment detecting the difference in autofluorescence as a gastroendoscopic image still has been relatively difficult task because of its faintness. Recent real time gastrointestinal fluorescence endoscopy is all based on the use of exogenous fluorophores (DaCosta, 2003; Sokolov, 2002; Prost, 2002), that increase the contrast, improve endoscopic resolution and sampling, and could be used to receive better 2-D visualization for the needs of clinicians.

We prepare a general review of the recent techniques, experimental achievements and general approaches applied in the field of light-induced fluorescence endoscopy of the gastrointestinal tract, as well as will provide below examples from our own research in this area. Broad literature survey is carried out to allow precise and extensive comments on advantages, drawbacks and future steps needed to be developed in this investigation area.

Advances in spectroscopic instruments will improve imaging's role as a facilitator of research translation. Results received in our studies could serve for development of tools for quantifying *in vivo* tumor growth and origin and for accelerating the transition from pre-clinical studies to early clinical trials and to routine diagnostic practice.

2. Principles and methods

Light-induced fluorescence spectroscopy of biological tissues is based on the physical phenomenon that when with a light beam in appropriate spectral region one irradiates some biological sample it could re-emit the light with a spectrum, related to its biochemical content. These molecules, which are in the tissue and re-emit the light, are called fluorophores, and the process itself is called fluorescence. Light sources that can be used include incoherent light sources such as Xe or Hg lamps, light-emitting diodes or monochromatic laser light. When light penetrate into the tissue, it could cause reflection from the tissue layers and non-homogeneities in the tissue; could cause absorption, as well as fluorescence. If only endogenous fluorophores, naturally existing in the sample, are used to obtain fluorescent signal from the tissue one could observe autofluorescence. If fluorescent compound is added (e.g. injected) into the tissue exogenous fluorescence is observed (Ell, 2003; Song, 2003, Song, 2005). Fluorescence diagnosis can be achieved by measuring either autofluorescence, generated by endogenous molecules, or tissue fluorescence following administration of an exogenous agent.

When fluorescence is observed *in situ* the resultant spectrum is superposition of several overlapping contributions of various fluorophores, which concentrations and special distribution vary depend on the stage of tissue pathology. It is typical to observe changes in intensity, or appearance/disappearance of fluorescent maxima with progression towards neoplasia. These spectral changes could indicate tissue pathological condition and stage of the lesion growth.

In endoscopic fluorescence spectroscopy measurements we could distinguish two major directions, see fig. 1:

1. Depending from the origin of the fluorescent signal detected – autofluorescence and exogenous (drug-enhanced) fluorescence;
2. Depending from the signal detected – point measurements and two-dimensional images;

Point measurements give us spectral data of the fluorescence, usually in terms of intensity of the fluorescence signal vs. wavelength, and two-dimensional images allow visualization of the mucosal area in terms of fluorescent color maps, which allow determination of boundaries and specification of the anatomic place of the pathology.

Point spectral measurements are more sensitive and allow better differentiation between inflammatory and dysplastic areas vs. tumours, as the first ones could have significant similarities with the cancer sites, if observed in two-dimensional fluorescent images. This is related to diagnostic specificity evaluation using LIFS, as a diagnostic tool and there are

different ways to improve the values of LIFS sensitivity and specificity, using spectral analysis techniques, which are applied from different research groups to improve their fluorescent diagnostic observations.

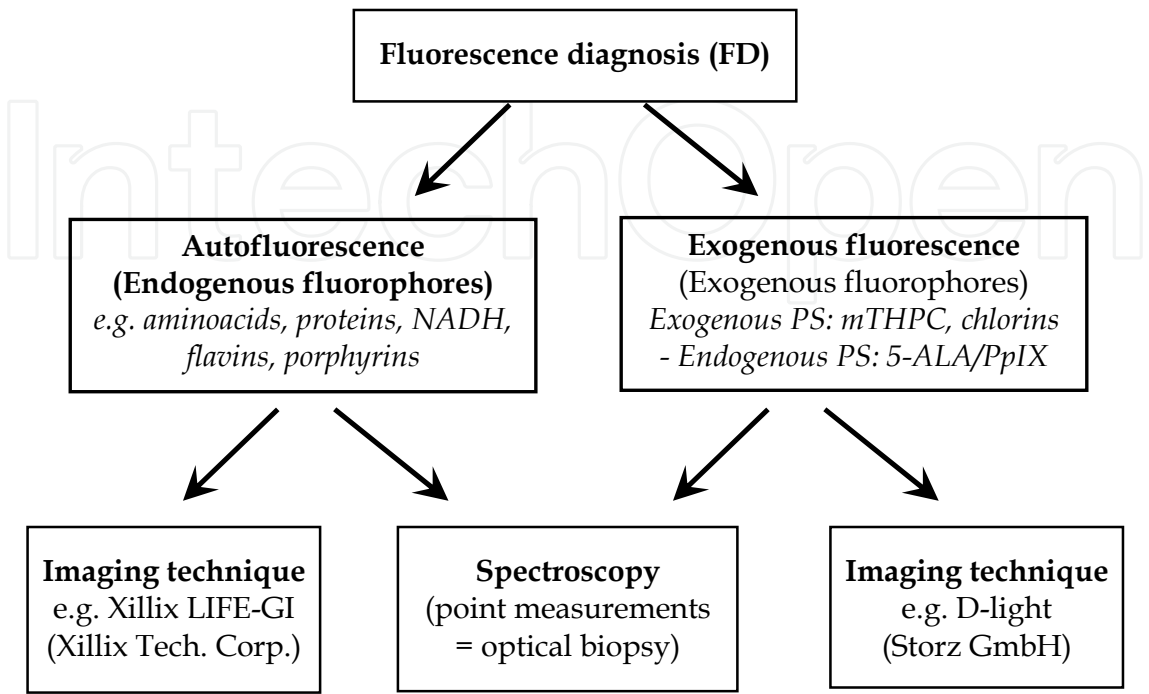


Fig. 1. Fluorescence detection techniques – principal scheme of 1-D and 2-D fluorescence imaging modalities

In many research reports about spectral techniques’ feasibility foreseen to be introduced into clinical practice, both spectral modalities – autofluorescence and exogenous fluorescence are applied for better earlier diagnosis of gastrointestinal tumors. In the case of autofluorescence detection high sensitivity and specificity could be achieved, if complex algorithms are applied for differentiation of the spectra (Ell, 2003; DaCosta, 2006). However, detecting the difference in autofluorescence as a gastroendoscopic image still has been relatively difficult task because of spectra similarity and relative faintness of the signals. Recent real time gastrointestinal fluorescence endoscopy is all based on the use of exogenous fluorophores that increase the contrast, improve endoscopic resolution and sampling, and could be used to receive better 2-D visualization.

2.1 Light-induced autofluorescence detection of gastrointestinal pathologies

Autofluorescence is a term used to describe fluorescence emission from naturally occurring tissue molecules – endogenous fluorophores) such as aromatic amino acids, NADH, collagen and porphyrins. Each group of fluorophores is characterized by specific excitation and fluorescence emission wavelength ranges (see Table I), although it is common if use one excitation wavelength to excite several fluorophores and for their emission bandwidths to overlap, resulting in a broad and relatively featureless fluorescence spectrum. Major endogenous fluorophores, which produce autofluorescent spectrum observed from gastrointestinal mucosa are presented in Table 1, according data from investigations of independant research groups (Song, 2003; DaCosta, 2002; Wildi, 2003; Filip, 2011).

Fluorophore	Origin	Optimal excitation wavelength (nm)	Peak of fluorescence emission (nm)
Tryptophan	amino acid	280, 305	340-350
Tyrosine	amino acid	275	300
Phenylalanine	amino acid	260	280
Collagen	structural protein	330-390	390-440
Elastin	structural protein	280, 360	350, 410
Protein cross-links	structural proteins	380-420	460-500
Pyrodixine	vitamin B6 compound	330-340	400
Ceroid, lipofuscin	lipo-pigment granules, oxidation products	340-395	430-460, 540-640
NADH	metabolic co-factor	340	450-470
FAD, Flavins	metabolic co-factor	420-460	500-520
Porphyrins	heme biosynthesis byproducts; bacterial flora	390-430, 630	635, 690

Table 1. Excitation and emission wavelengths of various endogenous fluorophores in human tissues

Different stages of tissue pathologies are associated with alterations in the content, special distribution and metabolic activities of these fluorophores, which affect the spectral shape of the autofluorescence signal. A number of different pathological processes – mainly neoplasia, but also inflammation and ischaemia affect the autofluorescence spectra observed from the tissue, due to their influence on metabolic, oxidative condition of the cells and their morphology.

Tumour autofluorescence intensity is strongly reduced, due to several factors: (i) changes in the intercellular matrix due to tumour cells size increase vs. normal cells, that lead to reduction of collagen and elastin concentration on volume unit and decrease of the autofluorescent signal detected from given mucosal area; (ii) metabolic change of NADH, to its oxidized form NAD⁺ in tumour cells, which is non-fluorescent molecule; (iii) thickening of the mucosa, which screens off the blue-green autofluorescence from the collagen and elastin from submucosa layer; (iv) increase of concentration of optical absorbers in the tumour area, such as hemoglobin, due to the neo-vascularization in the tumours, which absorb in blue-green spectral region with maxima of absorption at 420-450 nm, peaks at 543 and 575 nm-for oxy-hemoglobin and one broad peak at 550-580 nm for reduced hemoglobin form.

Spectral shape of the autofluorescent signal is also affected, when neoplasia occur in the gastrointestinal tract. Usually when UV – blue light is used for excitation tumour areas fluorescence is shifted in red, resulting of endogenous porphyrins concentration raise, observed in these tissues, and normal mucosa fluoresce in blue-green spectral region. Many authors use the intensity ratios blue/red, green/red or vice-versa to develop diagnostic algorithms for evaluation of neoplastic changes in the tissues under investigation (Marcon, 1999; Mayinger, 2001; DaCosta, 2002; Wildi, 2003; Mayinger, 2003; Song, 2003; Kara, 2005, Borisova, 2008; Aihara, 2009). This green/red ratio is used as a basis of Xillix Laser-Induced Fluorescence Endoscopy Gastrointestinal (LIFE-GI) (Xillix Technologies Corp., Canada) autofluorescence endoscope as a technique for detection of cancerous changes. This system

originally used blue light excitation and detected both green and red tissue autofluorescence, applying band-pass filters before two image intensifier cameras for observation of native fluorescence in the green and red spectral ranges, which are fused to create a real time “red-green” image of the pathology (DaCosta, 2006). Generally, there is less green fluorescence in neoplastic tissue, than in normal one, while red fluorescence is stronger in tumour than in normal tissue. These two systems LIFE-GI and newer LIFE II still use fiber endoscopes and not video-endoscopes (Ell, 2003).

Special attention deserves the influence of hemoglobin absorption on the autofluorescence spectra obtained. Its increase is observed in tumor areas due to the vascular growth and the distortions in the autofluorescence tissue spectrum induced by this chromophore, which molecules absorb light without re-emission of own fluorescence. Hemoglobin is responsible for spectral dips at 420 nm and in the region of 540-580 nm. Depending from the oxygenation state of hemoglobin in green spectral region one could observe two minima – at 543 and 575 nm, related to oxy-hemoglobin, or one broad minimum, in the region of 570-580 nm– related to reduced form of this compound (Vladimirov, 2007; Borisova, 2008). As tumor lesions are hypoxic in their advanced stage – this could be used as additional indicator of the lesion severity and growth. However, hemoglobin absorption of the autofluorescence signal leads to distortion of the signal obtained. Such distortions could be mathematically simulated and extracted – to reveal intrinsic autofluorescence of the tissue, unaffected by absorption and scattering events. For better processing of the autofluorescence spectra received, researchers measured reflectance spectra from the same tissue area and extract signal, related to hemoglobin re-absorption of the native fluorescence of the tissue (Georgakoudi, 2001; Filip, 2011).

In the case of autofluorescence detection high sensitivity and specificity could be achieved if complex algorithms are applied for differentiation of the spectra (Ell, 2003). However, on the current moment detecting the difference in autofluorescence as a gastroendoscopic image still has been relatively difficult task because of its faintness. The main advantage of the autofluorescence technique is the fact that it is not necessary to administrate chemical substance to the patient before fluorescence observations. Signal obtained is unstructured broad superposition of the fluorescent spectra of several intrinsic fluorophores, which do not allow easy recognition of the lesion type and need powerful mathematical algorithms for diagnostic differentiation of the normal/abnormal tissues. Significant disadvantages of exogenous fluorescent drugs usage are related to considerable medical and legal implications, as well as significant additional costs needed to obtain registration and approval for an exogenous fluorophore to be used as a medication. The advent of powerful light sources and highly sensitive detectors will lead to the development of autofluorescence endoscopy clinical systems. But on this moment real time gastrointestinal fluorescence endoscopy is based mainly on use of exogenous fluorophores.

2.2 Light-induced exogenous fluorescence detection of gastrointestinal pathologies

Tissue fluorescence could be enhanced following application of exogenous fluorescent drug, which is highly selective to cancerous and dysplastic tissues. Drug-mediated fluorescence is advantageous from the point of view of better visualization of the tumor area, with strong fluorescent signal, less ambiguous relative to autofluorescence and simpler and even cheaper instrumentation that could be used for exogenous fluorophores detection (Song, 2003). Other advantage is related to the a priori knowledge about optical properties of exogenous fluorophore – its excitation and emission spectra are well known and its

applicability is related mainly to its selective localization within tissues of interest, mode of administration and low side effects to the patients. Of course, cost related to the process of registration and approval of such exogenous fluorophore is significant drawback for faster introduction of such fluorescence systems in clinical practice.

Up to date, photosensitizers, used in photodynamic therapy, such as porphyrin derivative (HpD), delta-aminolevulinic acid (5-ALA), chlorines, have been exploited, and many of them fluoresce and demonstrate good selectivity for neoplasm. These drugs are also the most interesting for the investigators, as possible compounds applicable for exogenous fluorescence diagnosis of gastrointestinal tract.

Most typical photosensitizers used for fluorescent detection of gastrointestinal neoplasia are presented in table 2.

Photosensitizer	Excitation wavelength (nm)	Fluorescence wavelength peak (nm)	Investigated pathologies
5-ALA/ PpIX 5-aminolevulinic acid/ proto-porphyrin IX or hematoporphyrin derivative (HpD)	405, 514, 630	635, 690, 704	Barrett esophagus, low- and high-grade colon dysplasia, esophageal squamous cell cancer adenocarcinoma, stomach carcinoma (Brand, 2002; Ortner, Messmann, 2003; Song, 2005; Vladimirov, 2007; Ishizuka, 2011)
chlorin (chlorin e6, mTHPC)	660	665	Esophageal squamous cell carcinoma (Gossner, 1998; Bourre, 2002)
phthalocyanines (PCs)	410, 530, 670	675-685, 740	Stomach carcinoma, esophageal adenocarcinoma (Chissov, 2003)

Table 2. Excitation and emission wavelengths of various exogenous photosensitizers and their gastrointestinal neoplasia diagnostic application.

These compounds could be applied either for point spectroscopy or for imaging. Photosensitizers have high selectivity to neoplastic tissues and could accumulate significantly more in tumours. These compounds have strong fluorescence in red spectral region, 630-740 nm, where autofluorescence signal is very low, which allow better visualization and differentiation during video-endoscopic observations.

In the most of the studies 5-ALA/PpIX is applied as fluorescent marker for tumor detection in esophagus and stomach. Less popular are fluorescent drugs, based on phthalocyanines and chlorines, applied for diagnosis as well as for therapeutic procedures based on photodynamic effect appearance in the tumor cells after light irradiation. Results achieved with 5-ALA/PpIX show very good correlation between fluorescence signals and histology examination of the lesions investigated. Rapid lesions border determination using exogenous fluorescence signal could be obtained in 1-D scanning spectroscopic mode. Our own results from *in vivo* detection show very good differentiation between normal and abnormal tissues in 1-D spectroscopic regime and moderate discrimination in 2-D imaging using 5-ALA (Borisova, 2008b). Simple spectral discrimination algorithms allow to improve the differentiation between normal/cancerous mucosa, as well as to decrease the false positive results, related to the Protoporphyrin IX accumulation not only in tumor but in inflammatory cells of the esophagus and stomach.

For diagnostic purposes, delta-aminolevulinic acid is currently the compound that attracting greatest interest. 5-ALA is not a photosensitizer by itself, but a precursor in heme biosynthesis. In neoplastic cells activity of ferrochelatase, enzyme, attaching Fe^{2+} to the protoporphyrin IX, is strongly reduced, which lead to selective accumulation in malignant cells of this compound, which has photosensitizing properties, see figure 2. This effect could be observed using autofluorescence as well, but the concentration of PpIX in the tumour is much less than if 5-ALA is exogenously administered. Preliminary studies suggest that protoporphyrin IX (PpIX) fluorescence resulting from exogenously administered 5-aminolevulinic acid (5-ALA) may improve the detection of dysplastic mucosa in the GI tract (Brand, 2002). 5-ALA is a natural precursor of heme, which induces the formation of endogenous PpIX.

The administration of exogenous ALA results in the accumulation of PpIX in tissue due to feedback inhibition of the final step of the heme biosynthetic cycle. Enzymatic differences in dysplastic tissue (e.g., decreased ferrochelatase activity) lead to an increase in PpIX concentration and following higher intensity red fluorescence.

This mechanism of 5-ALA transformation to photosensitive PpIX is used not only for gastrointestinal tumor detection and photodynamic therapy, but as well for skin, bladder, bronchi, brain, lung cancer diagnosis and treatment. ALA-induced PpIX fluorescence has also been used successfully as a marker for dysplasia in many organs (Svanberg, 2004).

Exogenous fluorescence detection of different mucosal neoplasia becomes a valuable tool for early detection and determination of malicious lesions during standard endoscopic observation. Real time fluorescent system, based on exogenous fluorescence detection of 5-ALA/PpIX is developed by Storz company in Germany, so called D-Light system. Excitation lamp applied is filtered by short pass filter ($<440\text{ nm}$), and the blue light is delivered to the tissue investigated via illumination bundle of standard fibroscope. The fluorescent light is collected by endoscope imaging bundle and detected by video camera after second high-pass filter ($>450\text{ nm}$), which reduced strongly the excitation light coming into the detector (Eil, 2003).

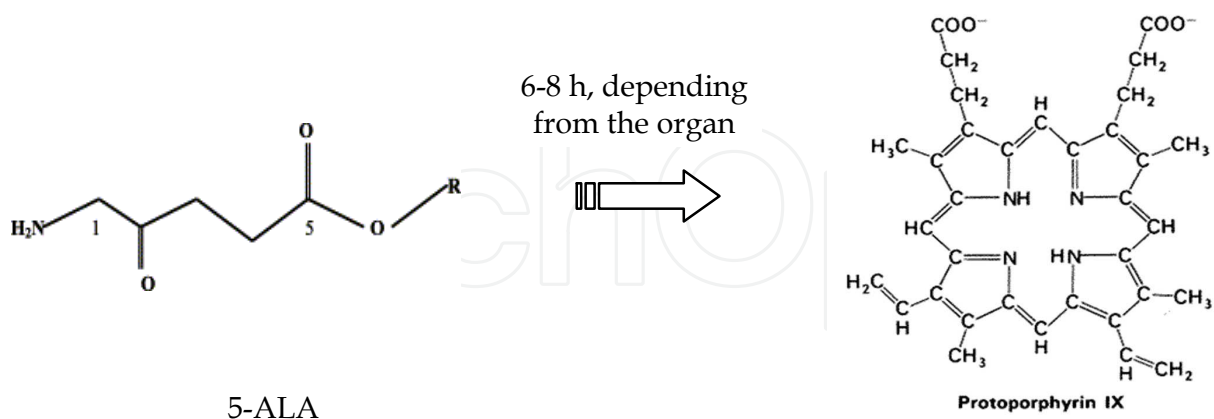


Fig. 2. Structural formulas of the compounds delta-aminolevulinic acid and protoporphyrin IX and the time of transformation of 5-ALA to Pp IX

Up to now only two gastroscopic systems- one based on autofluorescence - Xillix LIFE-GI and other based on exogenous 5-ALA/PpIX fluorescence - Storz D-Light with possibilities for fluorescence imaging detection are appeared on the market. In contrast, broad possibilities for choice of fluorescent bronchoscopes and cystoscopes exist, as the systems

are built in such way to allow fluorescent detection of tumors for example in bronchi or bladder. One of the technical problems, related to gastrointestinal applications are the losses of excitation and fluorescent signals through longer gastrointestinal endoscopes, which fade the images that could be observed. For detection of the fluorescence signal from gastrointestinal tract most of the researchers apply optical fibers through instrumental channel of the standard endoscopic equipment, which allow fluorescence detection of suspicious areas. We also applied such approach in our investigations; therefore we will present here only point spectral measurements. The 2-D pictures obtained from the common endoscopic video-equipment are relatively dim due to low level of the fluorescent light and in the improvement of the fluorescent video image is following step in our investigations.

However, results achieved from point measurements already show very good correlation between fluorescence signals and histology examination of the lesions investigated. Rapid lesions border determination using exogenous fluorescence signal could be obtained. Other important issue in such investigations is the contrast between inflammatory and tumor areas, where one could observe very good differentiation, achieving of a contrast higher then three times in the intensity of the 5-ALA/PpIX fluorescence in the tumor area vs. inflammation (Borisova, 2008a).

2.3 Advantages and drawbacks of fluorescence techniques for gastrointestinal tumours detection

As mentioned above technological advances in fiber optics, light sources, detectors, and molecular biology have stimulated the development of numerous optical methods that promise to significantly improve our ability to visualize and evaluate human epithelium in vivo (Wang, 2004).

The majority of gastrointestinal malignancies, especially adenocarcinoma, arise from epithelial surfaces. A common phenotype of all epithelial cancers is the progression from normal mucosa, through a stage of dysplasia, to cancer (Ell, 2003; Wildi, 2003; Song, 2003). The diagnosis of dysplasia based on standard endoscopy with multiple biopsies is still limited. S. M. Wildi and M. B. Wallace, 2003 discussed that in many cases dysplasia is invisible to the eye of the endoscopist, very common in flat lesions. Because of that is the need of numerous random biopsies and histological examination is the standard procedure. Although, such strategy could misses some dysplastic areas. Some visible lesions usually are not distinguished endoscopically from the surrounding nondysplastic tissue. On the other hand, the histological evaluation of biopsy specimens is difficult, especially differentiation between low grade and high grade dysplasia. There is significant inter-observer disagreement between pathologists in diagnosing dysplasia.

Different methods such as chromoendoscopy, magnifying endoscopy, and optical-based spectroscopic and imaging modalities can increase the possibility to detect endoscopically precursor lesions and early stage of gastrointestinal cancer with combination of target biopsies (Ell, 2003; Ishizuka, 2011; Marcon, 1999; Song, 2003; Wildi, 2003; Wang, 2004). They have the potential to overcome the limitations of standard endoscopic procedures by assessing wide neoplastic regions. These modalities may also provide a more accurate assessment of the extent of neoplastic lesions than conventional endoscopy, which is critical for success of the new endoscopic therapy, such as endoscopic mucosal resection (Wang, 2004). Nevertheless, all of these new techniques are also associated with various limitations and standardization.

A great advantage of different autofluorescence techniques is that they can be implemented *in vivo* and give information about tissue in its native state. The detection of occult dysplastic or cancerous lesions is more accurate than standard endoscopy with biopsies (Wildi, 2003; Song, 2003). In addition, the results of C. Ell, 2003 showed that absence of dysplasia, early cancer, or inflammation was detected in fluorescence negative areas of Barrett's mucosa, and consequently no false negative fluorescence findings were obtained. The data of L.-M. Wong Kee Song and B. C. Wilson, 2005 showed that targeted biopsies performed under LIFE endoscope in patients with short-segment Barrett esophagus identified more sites with high grade dysplasia than conventional biopsies obtained under standard endoscopy. On the opposite of these results, other study showed that both techniques had an equal sensitivity for high grade dysplasia and early cancer (Kobayashi, 2001). Fluorescence spectroscopy is associated with low rate of sensitivity and specificity of 'low risk' (non-dysplastic Barrett), and discriminating 'high-risk' (high grade dysplasia) from low grade dysplasia. False-positives results occur in the presence of inflammatory or reactive changes (Ell, 2003). The reported diagnostic accuracy have depends on the sample size and wavelength(s) selection. One other advantage of the fluorescence spectroscopy is the easy passage of the probes through the accessory channel of standard diagnostic endoscopes and highly predictable geometry between fibers that provide the source of light and those that deliver collected light to the detector (Wildi, 2003). On the other hand, spectroscopic techniques are limited by the small surface area they examine at the tip of the probe compared to standard endoscopy (Song, 2003, 2005). In parallel with point spectroscopy, real-time fluorescence imaging prototypes, such as fiberoptic endoscopes or videoendoscopes, have been developed, providing a field of view, similar to that of a conventional endoscope. The application of drug-enhanced fluorescence imaging in the upper GI tract increase the sensitivity for detection of Barrett's type dysplasia, but low specificity was found (Song, 2003). The fluorescence imaging with 5-ALA have similar limitations to autofluorescence imaging about a relative high number of false-positives results in cases with inflammation and metaplasia (Ell, 2003). In addition, the optimal dose of 5-ALA and whether topical application is capable of being as effective as oral administration is not estimated yet.

So, the potential clinical use of fluorescent endoscopy is wide-area surveillance, as in Barrett's esophagus and chronic inflammatory bowel diseases. T. Wang and J. Van Dam, J., 2004 discussed that these methods of optical biopsy are unlikely to replace conventional biopsy with histopathological interpretation of excised tissue, but they are likely to provide a more accurate and efficient approach to target biopsy of diseased tissue, thus reducing the number of conventional biopsies required, increasing surveillance intervals, and reducing cost. L.-M Wong Kee Song and K. Wang, 2003, also discussed that optical-based techniques for diagnosis of premalignant lesions, as well as early gastrointestinal cancer remains "controversial". Although they are promising modalities for detection of dysplastic or early neoplastic lesions. There is a need of technical optimization and confirmation of the preliminary results by future large number, prospective, randomized, controlled, cross-over clinical trials, as well as comparing the potential of drug-enhanced fluorescence detection relative to autofluorescence and to standard biopsy surveillance. The optimal technique may be a combination of optical modalities (multimodal optical diagnosis) with maximal diagnostic sensitivity and specificity. For instance, a lesion could be detected by a wide area surveillance technique such as autofluorescence imaging, and further characterized by a spectroscopic technique, such as exogenous fluorescence, Raman and/or confocal endoscopy.

C. Ell, 2003 discussed that fluorescent endoscopy may increase the detection of neoplastic lesions in the stomach but the clinical indications for fluorescence endoscopy is limited to patients with Barrett's esophagus. Spectroscopic procedures still have higher sensitivity and specificity rates for identifying neoplastic lesions than imaging fluorescence systems. From the clinical point of view, only real time endoscopic fluorescence imaging systems represent a practicable solution. The systems that are currently available still have weaknesses, and will need to undergo thorough clinical evaluation once they have been technically optimized. In comparison with incoherent light sources, laser-based methods seem to be too elaborate and expensive, and the former are likely to replace them. In addition, fluorescence detection will have to be possible in the future using high resolution video endoscopes.

According to the report of the American Society for Gastrointestinal Endoscopy (ASGE) Technology Committee, (Song, 2011), autofluorescence imaging, using probe-based spectroscopic devices and fiberoptic autofluorescence imaging (AFI) endoscopes have limited clinical value because of poor image quality related to fiberoptic technology. On the other hand video-endoscopic AFI systems is an improvement over earlier fiberoptic systems, but still have image quality inferior to high-resolution endoscopy. Improvements in image resolution, noise reduction, and color contrast may be achieved by further intensifying the autofluorescence signal and by optimizing the excitation and/or detection wavelength algorithms. In addition to steady-state fluorescence detection schemes, time-resolved fluorescence imaging, which measures fluorescence decay as a function of time, may be a future method to help further enhance lesion detection. Quantitative analysis of AFI images and development of autofluorescence indices for tissue discrimination have the potential to improve diagnostic accuracy and complement, if not supplement, the visual interpretation of images. Ultimately, autofluorescence combined with the detection of a fluorescent contrast agent that has high affinity for a targeted tissue receptor (ie, molecular beacon) may be the optimal solution for fluorescence-based diagnosis. In addition to technological developments, randomized controlled trials are needed to assess the accuracy of AFI relative to high-definition white light imaging and other competing technologies, such as electronic mucosal enhancement techniques (eg, narrow-band imaging, multi band imaging). Inter-observer agreement and validation studies in non-enriched patient populations are also needed before AFI can be recommended for routine endoscopic practice. The report concluded that AFI may enhance lesion detection or differentiation in the GI tract, the technique currently lacks sufficient specificity to make it useful as a stand-alone diagnostic modality during endoscopic practice. AFI may be a valuable tool when used as part of a multimodal imaging scheme, but this will require further technical advances and validation in prospective, randomized trials.

3. Light-induced point fluorescence spectroscopy of gastrointestinal tumours

Major spectral features observed during endoscopic investigations of gastrointestinal tumor, could be distinct as the next regions, according their origin and spectral region appearance, after application of 5-ALA and fluorescent excitation at 405 nm, as follow:

1. 450-650 nm region, where tissue autofluorescence is observed;
2. 630-710 nm region, where fluorescence of PpIX is clearly pronounced;
3. 530-580 nm region, where minima in the autofluorescence signal are observed, related to re-absorption of oxy-hemoglobin in this spectral area.

Normal mucosa has bright autofluorescence, related mainly to the emission of co-enzymes, phospholipids, collagen, elastin, and protein cross-links. The intensity of autofluorescence in the case of neoplasia rapidly decrease, which could be used as additional indicator of pathology evaluation.

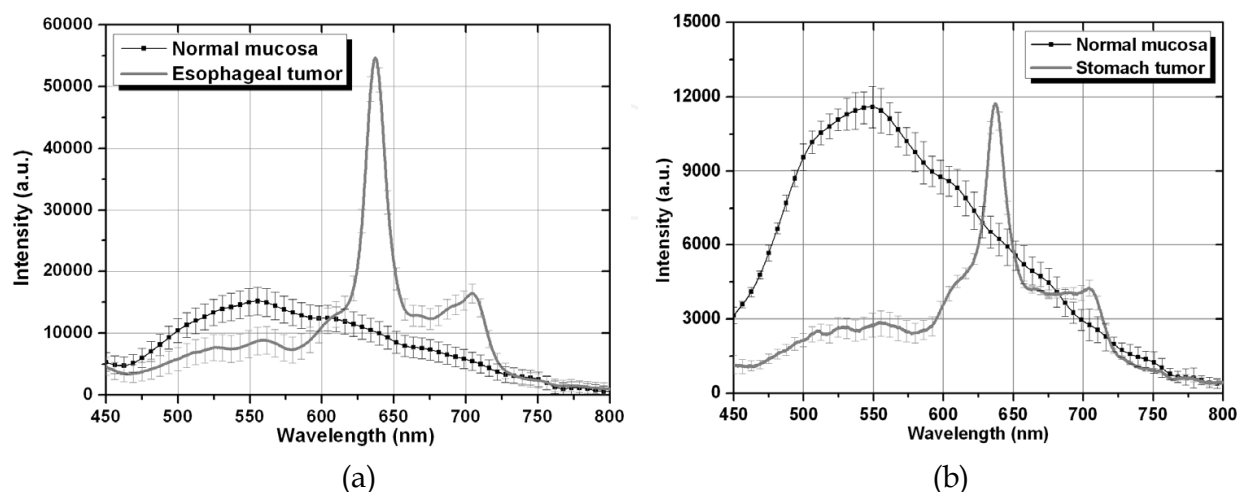


Fig. 3. Fluorescence signal detected from normal esophagus (a) and stomach (b) walls and carcinoma, as typical example of the spectral features observed with exogenous photosensitizer delta-ALA/protoporphyrin IX and 405 nm excitation is applied (Borisova et al, 2008a).

Normal esophagus and stomach autofluorescence lies in blue-green spectral area, which could be observed using video-endoscopy system such as D-Light (Filip, 2011) or autofluorescence endoscopic systems (Kara, 2005).

3.1 LIFS of gastrointestinal tumours – experimental results

Fluorescence intensity varies strongly from patient to patient; therefore most reasonable is the intra-patient comparison of the fluorescence intensity of normal tissue areas vs. suspicious ones. Even in the frames of one pathological area the intensity could vary, see fig. 4 (Borisova, 2008c). One of the disadvantages discussed in the most of the papers is related to false-positive results, which could be obtained when inflammations appear in the esophageal or stomach walls. Inflammatory areas reveal red fluorescence, due to some selectivity of 5-ALA/PpIX in the inflammatory cells, where heme synthesis is delayed. Indeed, when video-observation is applied, it is not easy to differentiate the red signal coming from inflammatory area and from neoplastic lesion, but when point spectroscopy is applied, one could observe significant differences in the intensity levels of 5-ALA/PpIX fluorescence at 635 nm. Therefore, point spectroscopy allows to reach higher specificity of the diagnosis (Georgakoudi, 2001, Ortner, 2003), than video-endoscopic observation (Endlicher, 2001; Messmann, 2003).

If compare relative intensities of normal and abnormal tissues sites for esophagus and stomach (see fig. 3b), the high level of the autofluorescence signal in the long wavelength spectral range (>600 nm) of the stomach wall, lead to problems in 2-D video-observation of the stomach tumor fluorescence. The values of the area of the autofluorescence spectrum of normal mucosa for the region >600 nm in comparison with the same region for tumor fluorescence are comparable and the ratio values between total areas of normal vs. tumor spectra in the region 600-800 nm vary from 0,7 to 1,1 for different patients.

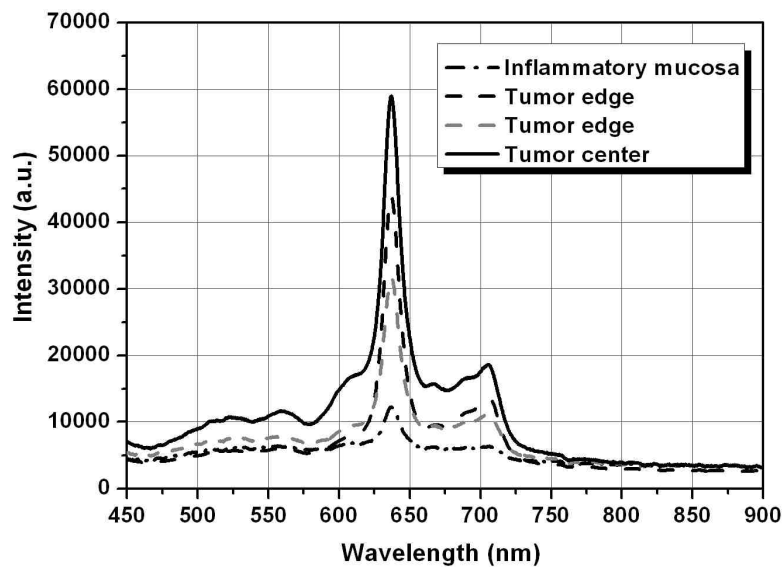


Fig. 4. Fluorescence spectra obtained *in vivo* from different suspicious areas of an esophageal mucosa of one patient, after 6 h ALA/PpIX application, using 405 nm excitation – inflammatory mucosa and different points on tumor lesion (Borisova et al., 2008c).

This effect could not be avoided by application of filter before CCD camera, as the long-pass filter (>600 nm) passed both signals – from normal mucosa autofluorescence and from exogenous 5-ALA/PpIX tumor fluorescence, see fig.5.

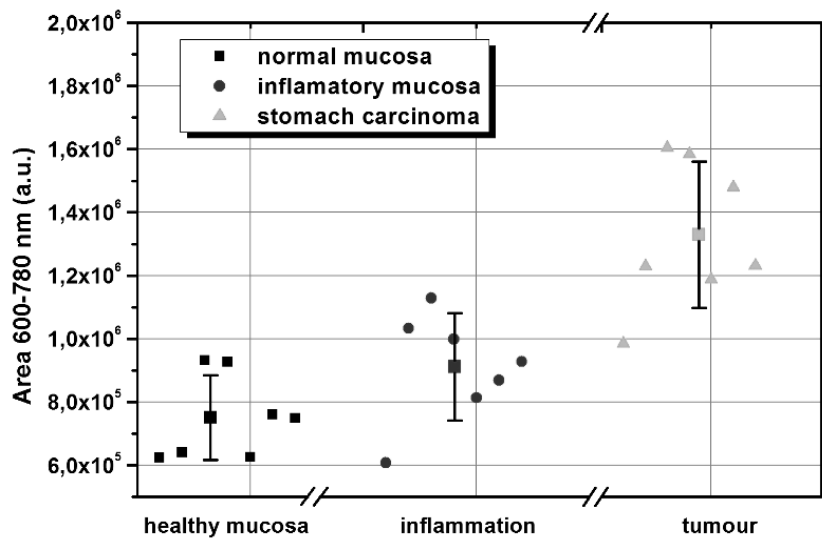


Fig. 5. Comparison of the integrated fluorescence signal for the region 600-780 nm, calculated for all cases detected from stomach normal mucosa, inflammation, and carcinoma. Data are represented with the mean values of the areas calculated (Borisova et al., 2008b).

As the human eye make an integration of the spectral signal when compare intensities, in 2-D image the endoscopist will observe similar by color and light intensity areas, which also lead to specificity reduction, when video-endoscopic observation is applied (see table 3). These specificity values could reach 51% (Messmann, 2003) or even 27% (Endlicher, 2001), which makes them absolutely useless for 2-D diagnosis. If a long-wavelength filter is

applied to reject the autofluorescence from the normal mucosa sites red “tail” of the autofluorescence from the normal mucosa will be still detected and the contrast could not be improved. In that case only spectral data could increase the fluorescence detection sensitivity and specificity.

This problem is still unsolved in the existing imaging systems for gastroscopic observations, but could be solved partially by change of excitation wavelength applied and this task is in a process of solving in our further investigations using longer wavelengths for excitation of PpIX (using peaks of absorption at 509 nm, 544 nm or 584 nm), where autofluorescence is not so strong factor, as well as back scattered excitation light from the mucosal surface does not lie in the spectral region of PpIX fluorescence itself. Drawback of this approach is the fact that fluorescence effectiveness is much less, when use excitation on these wavelengths, than at 405 nm, where the strongest absorption of PpIX is observed.

When inflammatory areas occurred in the organ under investigation false-positive red fluorescence is observed in video channel of the endoscope due to the accumulation of PpIX in the both tumor and inflammatory areas. The contrast between the fluorescent signals at 635 nm between tumor regions and inflammations observed in all patients, where such comparison was possible, usually is higher than two (Borisova, 2009). In such way one could be sure in general that using point fluorescence detection approach, he could distinguish inflammation from tumor site, and moreover, could distinguish inflammatory areas from normal mucosa.

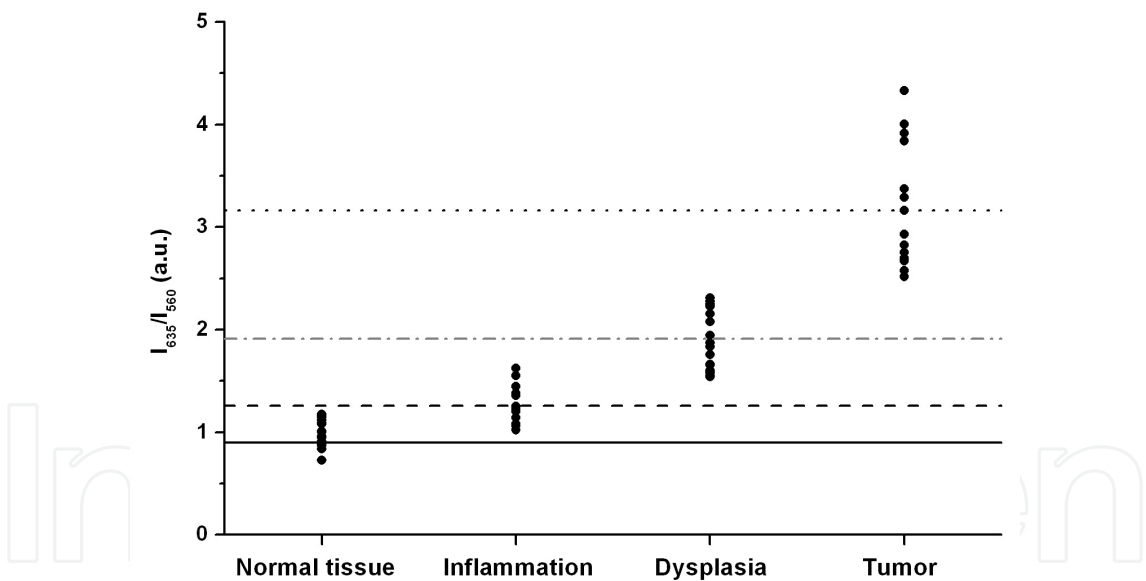


Fig. 6. Dimensionless ratio (•) $R=I_{635}/I_{560}$ calculated for all cases detected from normal mucosa, inflammation, dysplasia and tumor of stomach. Lines represent the mean values of this ratio calculated (Borisova et al., 2009).

The fluorescent intensities of the maximum at 635 nm of inflammatory area detected from stomach wall are close to the lowest signals received from tumors. Therefore, an additional criterion could be applied for better differentiation of inflammation from tumor. We used for these goals a dimensionless ratio $R=I_{635}/I_{560}$, see fig.6. Using this simple algorithm very good differentiation tumor/inflammation is obtained that could be applied for clinical practice needs. Moreover, similar approaches are proposed for differentiation of normal and

cancerous sites from other research groups, for gastrointestinal tumors, cancer detection in bronchi and lungs. Using green and red band-pass filters two complimentary images are received and ratio between them is calculated to receive more contrast image and to improve sensitivity and specificity of the fluorescent endoscopy approach (Sokolov, 2002, 2005; Goujon, 2001).

3.2 LIFS of gastrointestinal tumours – sensitivity and specificity peculiarities

When new diagnostic approach is introduced into the medical practice, major indicators of its clinical applicability are the values of sensitivity and specificity of such newly developed method. As we already mentioned, when discussed advantages and drawbacks of light-induced fluorescence diagnostics – this technique, nevertheless if autofluorescence, or drug-enhanced exogenous fluorescence detection is applied, is only complimentary on its recent level of development. In some next stage of its development, when more sensitive detectors, or more complicate mathematical algorithms for image analysis are applied in video-endoscopes used for gastrointestinal tumor observations, this high sensitive method could found primary place as a diagnostic tool.

Nowadays, all reports on exogenous fluorescence diagnostics related to evaluation of statistical diagnostic values show an excellent sensitivity of fluorescent diagnostic technique and moderate, even poor specificity values. We stopped our attention on few reasons for such low values of the specificity:

- i. false-positive red fluorescence, due to selectivity of exogenous photosensitizers, not only to tumor cells, but also to inflammatory areas;
- ii. significant autofluorescence signal in the spectral range above 600 nm, which lead to problems with differentiation during 2-D video observation of lesion fluorescent images;

As we will see from the comparison of the results, obtained from other research groups (see table 3), other possible reasons for low specificity values of this technique, up to now are:

- iii. strong dependence on the fluorescent drug concentration to the contrast tumor/normal mucosa observed;
- iv. drug application influence on the selective accumulation of the fluorophore into tumor area – intravenous, using spray catheter, enema, orally, etc.

In table 3 are presented data from investigations, which allow observing the general tendencies and influences on the sensitivity and specificity values obtained, depending from the initial conditions applied.

Messmann and group, 2003, applied 5-ALA using three different ways – orally, using spray catheter and enema for detection of low-grade and high-grade colon dysplasia. Endoscopic observations were performed using fibrescopes, connected to a light source delivering white, or blue light (D-light, Storz, Germany) and the evaluations of SE and SP were based on the observed real time fluorescence pictures. According observations, optimal way of application is using spray catheter, as there sensitivity is 100%, and moderate but relatively higher value of specificity is reached – 62 %. Authors called the fluorescent technique “promising” for detection of LGD and HGD in ulcerative colitis, but observed high rate of false-positive fluorescent signals related to inflammatory areas. Unequal absorption of 5-ALA using enema or spray catheter also need to be taken into account and cannot be excluded as possible source of methodological errors. Authors stress on the fact that they received high percentages for the negative predictive values, which allow concluding an indication that there is almost no colon dysplasia in a negative fluorescence observations.

Lesion site/type	Method	Excitation [nm]	Emission [nm]	SE [%]	SP [%]	Reference
Exogenous fluorescence						
Barrett esophagus – low grade dysplasia (LGD)	5-ALA - PpIX	505 nm	635 nm, 699 nm	100	67	Ortner, 2003
LGD and high-grade dysplasia (HGD) - colon	5-ALA -enema, 3g	390-405 nm - D-light	2-D images 635-700 nm	87	51	Messmann, 2003
LGD and HGD - colon	5-ALA -spray catheter, 3g	390-405 nm - D-light	2-D images 635-700 nm	100	62	Messmann, 2003
LGD and HGD - colon	5-ALA - orally, 20 mg/kg	390-405 nm - D-light	2-D images 635-700 nm	43	73	Messmann, 2003
Barrett esophagus	5-ALA - orally 10 mg/kg	390-405 nm - D-light	2-D images 635-700 nm	80	56	Endlicher, 2001
Barrett esophagus	5-ALA - orally 20 mg/kg	390-405 nm - D-light	2-D images 635-700 nm	100	51	Endlicher, 2001
Barrett esophagus	5-ALA - orally 30 mg/kg	390-405 nm - D-light	2-D images 635-700 nm	100	27	Endlicher, 2001
Esophageal adenocarcinoma	5-ALA - orally 15 mg/kg	<450 nm	>600 nm	85	53	Mayinger, 2000
Endogenous fluorescence (autofluorescence)						
High-grade dysplasia vs. LGD and nondysplastic tissue	LIAFS	337nm 397 nm	400-420 nm 440-480 nm	100	97	Georgakoudi, 2001
LGD and HGD vs. ND Barrett	LIAFS	337nm 397 nm	400-420 nm 440-480 nm	79	88	Georgakoudi, 2001
Barrett esophagus	Autofluorescence LIFE-GI system	N/ A	500-550 nm	97	97	Ell, 2003
Rectal cancer	Autofluorescence	375-478 nm	500-700 nm	96	93	Mayinger, 2003
Stomach adenocarcinoma	Autofluorescence	375-478 nm	500-700 nm	90	95	Mayinger, 2001
Gastric carcinoma	Autofluorescence	437 nm LIFE-GI system	490-700 nm	94	86	Kobayashi, 2001

Table 3. Sensitivity and specificity received using LIFS of gastrointestinal tract for different localisations using autofluorescent or exogenous fluorescent detection of lesions

Interesting investigation, related to the optimisation of exogenous fluorophore concentration is carried out by Endlicher and group (Endlicher, 2001) for detection of low-grade and high-grade dysplasia in Barrett esophagus. Again, the observations are made in 2-D regime, not as point spectral measurements, which explain partially the moderate values of specificity received, 4-6 hours after oral application of 5-ALA to the patients. The lower and upper limits of 5-ALA concentrations applied reveal that number of fluorescent

negative biopsies in the patients' group sensitized with 30 mg/kg was extremely low, due to the high background fluorescence. In contrary, when 5 mg/kg 5-ALA is applied to the patients, only weak fluorescence appear and therefore the number of positive biopsies is lower in that group. Additionally false positive fluorescence was induced mainly by inflammatory areas and metaplasia, as well as from reflux of bile into the esophagus, which was associated with intensive red fluorescence. Optimal values for 5-ALA oral applications are received for 15-20 mg/kg dose. Researchers also observed that while local sensitization caused no side effects, systemic application of 5-ALA with doses higher than 20 mg/kg could cause mild nausea or vomiting in a few of the patients, as well as transient increases in liver enzymes in two patients from 58 examined persons. Skin photosensitivity using 5-ALA is relatively low and disappears after several hours after systemic administration, but disappear totally after 18 hours for all patients.

In the second part of the table 3 are presented results from investigations using autofluorescence as a diagnostic tool. When autofluorescence detection is applied high values for sensitivity and specificity (higher than 90 %) are reported from all research groups. Autofluorescence spectroscopy is characterized with high values for both these diagnostic parameters. The biggest problem of this technique is the visualization of the pathologies, useful for the clinicians, which still waits for its technical solution. Point spectral data detected are useful and informative for the physicists and engineers, who work on the development of this technique for its introduction into the clinical practice. But these data are not so exciting for the clinicians, who prefer to visualize their objects of interest, developing 2-D images, based on real or pseudo-color maps, based on the optical properties of the investigated tissues. Xillix LIFE-GI system is one possible answer of such need, but still not optimized for daily clinical observations.

4. Conclusions

Theoretically spectral diagnosis can provide imaging and point spectroscopic information in both - morphological and biochemical data modes with extreme sensitivity and specificity. Advances in spectroscopic instruments will improve imaging's role as a facilitator of research translation. Results received in the recent studies could serve for development of tools for quantifying in vivo tumor growth and origin and for accelerating the transition from pre-clinical studies to early clinical trials and to routine diagnostic practice. Beyond all doubts, application of new, more sensitive tool for diagnostics of esophageal and stomach neoplasia could potentially make fluorescence surveillance clinically and cost effective procedure.

Despite of the fluorescent endoscopic systems developed and already discussed under clinical and laboratorial investigations, the fluorescent diagnosis of tumors of the gastrointestinal tract is still very challenging and extensive research and development task worldwide. With the optimization of the procedures and evaluation of diagnostic added value of the technique, through development of appropriate algorithms based on fluorescence properties of the investigated sites, a novel high sensitive diagnostic tool could be successfully applied as complementary to the standard white light endoscopy.

But on this moment real time gastrointestinal fluorescence video-endoscopy rely on the use of exogenous fluorophores and contrast, which would be observed after exogenous fluorophore application. Most popular precursor of a photosensitizer is delta-aminolevulinic acid/Protoporphyrin IX (5-ALA/PpIX) that is also used as fluorescent marker for dysplasia

and tumor detection in many other anatomical sites. 5-ALA/PpIX has low toxicity, very good selectivity to the tumor tissues and reveals high contrast normal/abnormal tissue, which makes it preferable form of exogenous fluorophore for clinical applications.

Results achieved with 5-ALA/PpIX show very good correlation between fluorescence signals and histology examination of the lesions investigated. The lack of fluorescence peaks in the red spectral area for normal mucosa is an indication for selective accumulation of 5-ALA/PpIX only in abnormal sites and gives high contrast when lesion borders are determined from clinicians during video observation in the process of diagnostic procedure. Rapid lesions border determination using exogenous fluorescence signal is obtained in such way. However, more detailed investigation about differences in the accumulation of 5-aminolevulinic acid/protoporphyrin IX in neoplastic and inflammatory areas will be useful to evaluate and optimize the contrast between these tissue conditions.

In conclusion, optical spectroscopic and imaging modalities, such as fluorescence endoscopy, narrow band imaging, optical coherence tomography, and confocal endoscopy, are still under evaluation and should be considered research tools at the current time. Although promising, instrument optimization, diagnostic reproducibility, and validation through large-scale prospective comparative trials are needed before optical spectroscopic and imaging techniques are considered part of routine endoscopic practice. Ultimately, whether and to what extent fluorescence endoscopy will find its place in clinical gastroenterology will only be decided in comparison with the other imaging options available (high resolution endoscopy, magnification endoscopy, chromo-endoscopy, etc). Additionally the cost effectiveness of spectroscopic screening needs to be further assessed in prospective studies.

5. Acknowledgment

The studies were supported by Grants of the National Science Fund, Bulgaria – grant #DO-02-112/08 “National Center on Biomedical Photonics” and grant #VU-L-01/05 “Optical biopsy of dysplasia and tumors in upper part of gastrointestinal tract”.

6. References

- Aihara, H.; Sumiyama, K.; Saito, S.; Tajiri, H. & Ikegami, M. (2009). Numerical analysis of the autofluorescence intensity of neoplastic and non-neoplastic colorectal lesions by using a novel videoendoscopy system. *Gastrointestinal Endoscopy*, Vol. 69, No. 3, pp. 726-733
- Borisova, E.; Vladimirov, B. & Avramov, L. (2008a). 5-ALAMediated Fluorescence Detection of Gastrointestinal Tumors, *Advances in Optical Technologies*, Vol. 2008, Article ID 862081, 7p., doi:10.1155/2008/862081
- Borisova, E.; Vladimirov, B. & Avramov, L. (2008b). 5-ALA/PpIX fluorescence detection of esophageal and stomach neoplasia – effects of autofluorescence background from normal and inflammatory areas, *Proceedings of SPIE*, Vol. 7027, pp. 7027-1A
- Borisova, E.; Vladimirov, B. & Avramov, L. (2008c). Fluorescence Detection of Esophageal Neoplasia, *Proc. SPIE*, Vol. 6791, SFM'07 - Optical Technologies in Biophysics and Medicine IX, ed. V. Tuchin, pp. 6791-04

- Borisova, E.; Vladimirov, B.; Terziev, I.; Ivanova, R. & Avramov, L. (2009). 5-ALA/PpIX fluorescence detection of gastrointestinal neoplasia, *Progress in Biomedical Optics and Imaging - Proceedings of SPIE*, Vol. 7368, pp.7368-24 -1-6
- Bourre, L.; Rousset, N.; Thibaut, S.; Eleouet, S.; Lajat, Y. & Patrice, T. (2002). PDT effects of m-THPC and ALA, phototoxicity and apoptosis, *Apoptosis* Vol. 7, No. 3, pp. 221-230
- Brand, S.; Wang, T.; Schomacker, K.; Ponerós, J.; Lauwers, G., Compton, C., Pedrosa, M. & Nishioka, N. (2002). Detection of high-grade dysplasia in Barrett's esophagus by spectroscopy measurement of 5-aminolevulinic acid-induced protoporphyrin IX fluorescence. *Gastrointestinal Endoscopy*, Vol.56, No.4, pp. 479-487 .
- Chissov, V.; Sokolov, V.; Bulgakova - Zharkova, N. & Filonenko, E. (2003). Fluorescence endoscopy, dermoscopy and spectrophotometry for diagnosis of malignant tumors. *Russian Biotherapeutical Journal*, No 4, pp. 45-56
- DaCosta, R.; Wilson, BC. & Marcon, NE. (2002). New optical technologies for earlier endoscopic diagnosis of premalignant gastrointestinal lesions. *Journal of Gastroenterology and Hepatology*, Vol. 17, (Suppl.) pp. S85-S104
- DaCosta, R.; Wilson, B. & Marcon, N. (2003a). Photodiagnostic techniques for the endoscopic detection of premalignant gastrointestinal lesions. *Digestive Endoscopy*, Vol. 15, pp. 153-173.
- Da Costa, R. & Marcon, N. (2003b). Neue Dimensionen in der Bildgebung: Bioendoskopie. *Endo heute* 16, pp. 75-90.
- DaCosta,R.; Wilson, B. & Marcon, N. (2006). Spectroscopy and fluorescence in esophageal diseases. *Best Practice & Research Clinical Gastroenterology*, Vol. 20, No. 1, pp. 41-57
- Danon, Sh.; Valerianova, Z.& Ivanova, Tz. (2003). Cancer Incidence in Bulgaria 2000, *Bulgarian National Cancer Registry*, Bulgarian Publishing House Ltd., (2003).
- Ell, C. (2003). Improving endoscopic resolution and sampling: fluorescence techniques. *Gut*, Vol. 52, Suppl IV, pp. iv30-iv33
- Endlicher, E.; Knuechel, R.; Hauser, T.; Szeimies, RM.; Schölmerich, J. & Messmann, H.(2001). Endoscopic fluorescence detection of low and high grade dysplasia in Barrett's oesophagus using systemic or local 5-aminolaevulinic acid sensitisation. *Gut*, Vol. 48, No. 3, pp. 314-9.
- Endlicher, E. & Messmann, H. (2003). Spectroscopy and Fluorescence Imaging. *Techniques in Gastrointestinal Endoscopy*, Vol 5, No 2, pp. 74-77
- Filip, M.; Iordache, S.; Săftoiu, A. & Ciurea, T. (2011). Autofluorescence imaging and magnification endoscopy. *World J Gastroenterol.*, Vol. 17, No. 1, pp. 9-14.
- Gabrecht, T.; Lovisa, B.; Borle, F. & Wagnieres, G. (2007). Design of an endoscopic optical referent to be used for autofluorescence bronchoscopy with a commercially available diagnostic autofluorescence endoscopy (DAFE) system. *Phys Med Biol.*, Vol. 52, No. 8, pp. 163-171.
- Georgakoudi, I.; Jacobson, BC.; Van Dam, J.; Backman, V.; Wallace, MB.; Müller, MG.; Zhang, Q.; Badizadegan, K.; Sun, D.; Thomas, GA.; Perelman, LT. & Feld, MS. (2001). Fluorescence, reflectance, and light-scattering spectroscopy for evaluating

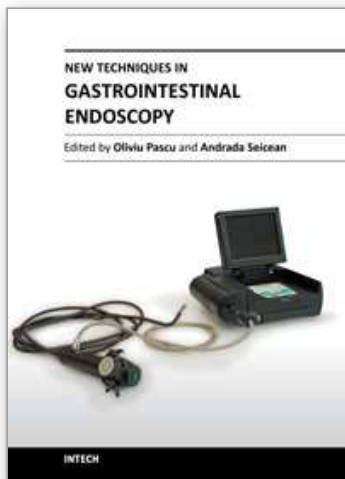
- dysplasia in patients with Barrett's esophagus. *Gastroenterology*, Vol. 120, No. 7, pp. 1620-9
- Gossner, L.; Stolte, M.; Sroka, R.; Rick, K.; May, A.; Hahn, E. G. & Ell, C. (1998). Photodynamic Ablation of high-grade Dysplasia and Early Cancer in Barrett's Esophagus by Means of 5-aminolevulinic Acid. *Gastroenterology*, Vol. 114, pp. 448-455
- Goujon, D.; Zellweger, M.; van den Bergh, H.; Wagnieres, G.; (2001). Autofluorescence imaging in the tracheo-bronchial tree. *Photodynamics News*, Vol. 3, pp. 11-14
- Ishizuka, M.; Abe, F.; Sano, Y.; Takahashi, K.; Inoue, K.; Nakajima, M.; Kohda, T.; Komatsu, N.; Ogura, S. & Tanaka, T. (2011). Novel development of 5-aminolevulinic acid (ALA) in cancer diagnoses and therapy. *International Immunopharmacology*, Vol. 11, No. 3, pp. 358-365
- Jemal, A.; Bray, F.; Center, M.; Ferlay, J.; Ward, E.; Forman, D. (2011). Global cancer statistics, *CA Cancer Journal for Clinicians*, Vol. 6, No. 2, pp. 69-90
- Kara, M.; Peters, F.; Kate, F.; Deventer, S.; Fockens, P.; Bergman, J. (2005). Endoscopic video autofluorescence imaging may improve the detection of early neoplasia in patients with Barrett's esophagus, *Gastrointest Endosc* 2005, Vol. 61, pp. 679-685
- Kobayashi, M.; Tajiri, H.; Seike, E.; Shitaya, M.; Tounou, S.; Mine, M. & Oba, K. (2001). Detection of early gastric cancer by a real-time autofluorescence imaging system. *Cancer Letters*, Vol. 165, No. 2, pp. 155-9.
- Marcon, NE. (1999). Is light-induced fluorescence better than the endoscopist's eye?. *Can J Gastroenterol.*, Vol. 113, No. 5, pp. 417-21
- Mayinger, B.; Horner, P.; Jordan, M.; Gerlach, C.; Horbach, T.; Hohenberger, W. & Hahn, EG. (2001a). Endoscopic fluorescence spectroscopy in the upper GI tract for the detection of GI cancer: initial experience. *Am J Gastroenterol.*, Vol. 96, No. 9, pp. 2616-21
- Mayinger, B.; Neidhardt, S.; Reh, H.; Martus, P. & Hahn, EG. (2001b). Fluorescence induced with 5-aminolevulinic acid for the endoscopic detection and follow-up of esophageal lesions. *Gastrointestinal Endoscopy*, Vol. 54, No. 5, pp. 572-8.
- Mayinger, B.; Jordan, M.; Horner, P.; Gerlach, C.; Muehldorfer, S.; Bittorf, BR.; Matzel, KE.; Hohenberger, W.; Hahn, EG. & Guenther K. (2003). Endoscopic light-induced autofluorescence spectroscopy for the diagnosis of colorectal cancer and adenoma. *Journal of Photochemistry and Photobiology B: Biology*, Vol. 70, No. 1, pp. 13-20
- McMichael L. Xillix and Olympus Finalize Distribution and Development Agreement - Product Launch Scheduled for Early 1997, *Business Wire*, Jan 13, (1997).
- Messmann, H.; Endlicher, E.; Gelbmann, CM. & Schölmerich, J. (2002). Fluorescence endoscopy and photodynamic therapy. *Dig Liver Dis.*, Vol. 34, No. 10, pp. 754-61.
- Messmann, H.; Endlicher, E.; Freunek, G.; Rümmele, P.; Schölmerich, J. & Knüchel, R. (2003). Fluorescence endoscopy for the detection of low and high grade dysplasia in ulcerative colitis using systemic or local 5-aminolaevulinic acid sensitisation. *Gut*, Vol. 52, No. 7, pp. 1003-7.

- Namihisa, A.; Miwa, H.; Watanabe, H.; Kobayashi, O.; Ogihara, T. & Sato, N. (2001). A new technique: light-induced fluorescence endoscopy in combination with pharmacoendoscopy. *Gastrointestinal Endoscopy*, Vol. 53, No. 3, pp. 343-8.
- Ohkawa, A.; Miwa, H.; Namihisa, A.; Kobayashi, O.; Nakaniwa, N.; Ohkusa, T.; Ogihara, T. & Sato, N. (2004). Diagnostic performance of light-induced fluorescence endoscopy for gastric neoplasms. *Endoscopy*, Vol. 36, No. 6, pp. 515-21.
- Ortner, MA.; Ebert, B.; Hein, E.; Zumbusch, K.; Nolte, D.; Sukowski, U.; Weber-Eibel, J.; Fleige, B.; Dietel, M.; Stolte, M.; Oberhuber, G.; Porschen, R.; Klump, B.; Hörtnagl, H.; Lochs, H. & Rinneberg, H. (2003). Time gated fluorescence spectroscopy in Barrett's oesophagus. *Gut*, Vol. 52, No. 1, pp.28-33.
- Papayan, GV. & Kang, U. (2006). Fluorescence endoscopic video system. *J. Opt. Technol.*, Vol. 73, pp. 739-743.
- Prost, RL. & Gahlen, J. (2002) Fluorescence diagnosis of colorectal neoplasms: a review of clinical applications. *Int J Colorectal Dis.*, Vol. 17, No. 1, pp. 1-10.
- Sokolov, V.; Filonenko, E.; Telegina, L.; Boulgakova, N. & Smirnov, V. (2002). Combination of fluorescence imaging and local spectrophotometry in fluorescence diagnostics of early cancer of larynx and bronchi. *Quantum Electron.*, Vol. 32, pp. 963-969
- Sokolov, V.; Chissov, V.; Filonenko, E.; Telegina, L.; Trahtenberg, A.; Frank, G. & Bulgakova, N.; (2005). Fluorescence diagnostics of early central cancer of the lung. *Pulmonology* Vol. 1, pp. 107-116
- Song, LM. & Wang, KK. (2003). Optical Detection and Eradication of Dysplastic Barrett's Esophagus. *Technology in Cancer Research & Treatment*, Volume 2, Number 4, pp. 289-302
- Song, LM. & Wilson, BC. (2005). Endoscopic detection of early upper GI cancers. *Best Practice & Research Clinical Gastroenterology*, Vol. 19, No. 6, pp. 833-856
- Song, LM.; Banerjee, S.; Desilets, D.; Diehl, DL.; Farraye, FA.; Kaul, V.; Kethu, SR.; Kwon, RS.; Mamula, P.; Pedrosa, MC.; Rodriguez, SA. & Tierney, WM. (2011). Autofluorescence imaging. *Gastrointest Endoscopy*, Vol. 73, No.4, pp. 647-50.
- Svanberg, S. (2004). Environmental and medical applications of photonic interactions. *Physica Scripta*, T110, pp. 39-50.
- Tumlinson, AR.; Hariri, LP.; Utzinger, U. & Barton, JK. (2004). Miniature endoscope for simultaneous optical coherence tomography and laser fluorescence measurement. *Appl Opt*, Vol. 43, No. 1, pp. 113-121.
- Wang, T. & Van Dam, J. (2004). Optical biopsy: A new frontier in endoscopic detection and diagnosis. *Clinical Gastroenterology and Hepatology*, Vol. 2, No.9, pp. 744-753.
- Wildi, SM. & Wallace, MB. (2003). Point-Probe Spectroscopy: A Real-Time Technique to Identify Gastrointestinal Dysplasia. *Techniques in Gastrointestinal Endoscopy*, Vol 5, No 2, pp. 82-88
- Vladimirov, B.; Borisova, E. & Avramov, L. (2007). Delta-ALA-mediated fluorescence spectroscopy of gastrointestinal tumors: comparison of in vivo and in vitro results. *Proceedings of SPIE*, Vol. 6727, pp. 6727-1X

Yan, XL.; Dong, RX.; Zhang, L.; Zhang, XJ. & Zhang, ZW. (2005). Raman spectra of single cell from gastrointestinal cancer patients", World J. Gastroenterol., Vol.7, No. 11, pp. 3290-3292

IntechOpen

IntechOpen



New Techniques in Gastrointestinal Endoscopy

Edited by Prof. Oliviu Pascu

ISBN 978-953-307-777-2

Hard cover, 310 pages

Publisher InTech

Published online 30, September, 2011

Published in print edition September, 2011

As result of progress, endoscopy has become more complex, using more sophisticated devices and has claimed a special form. In this moment, the gastroenterologist performing endoscopy has to be an expert in macroscopic view of the lesions in the gut, with good skills for using standard endoscopes, with good experience in ultrasound (for performing endoscopic ultrasound), with pathology experience for confocal examination. It is compulsory to get experience and to have patience and attention for the follow-up of thousands of images transmitted during capsule endoscopy or to have knowledge in physics necessary for autofluorescence imaging endoscopy. Therefore, the idea of an endoscopist has changed. Examinations mentioned need a special formation, a superior level of instruction, accessible to those who have already gained enough experience in basic diagnostic endoscopy. This is the reason for what these new issues of endoscopy are presented in this book of New techniques in Gastrointestinal Endoscopy.

How to reference

In order to correctly reference this scholarly work, feel free to copy and paste the following:

Ekaterina Borisova, Borislav Vladimirov, Radina Ivanova and Latchezar Avramov (2011). Light-Induced Fluorescence Techniques for Gastrointestinal Tumour Detection, New Techniques in Gastrointestinal Endoscopy, Prof. Oliviu Pascu (Ed.), ISBN: 978-953-307-777-2, InTech, Available from: <http://www.intechopen.com/books/new-techniques-in-gastrointestinal-endoscopy/light-induced-fluorescence-techniques-for-gastrointestinal-tumour-detection>

INTech
open science | open minds

InTech Europe

University Campus STeP Ri
Slavka Krautzeka 83/A
51000 Rijeka, Croatia
Phone: +385 (51) 770 447
Fax: +385 (51) 686 166
www.intechopen.com

InTech China

Unit 405, Office Block, Hotel Equatorial Shanghai
No.65, Yan An Road (West), Shanghai, 200040, China
中国上海市延安西路65号上海国际贵都大饭店办公楼405单元
Phone: +86-21-62489820
Fax: +86-21-62489821

© 2011 The Author(s). Licensee IntechOpen. This chapter is distributed under the terms of the [Creative Commons Attribution-NonCommercial-ShareAlike-3.0 License](https://creativecommons.org/licenses/by-nc-sa/3.0/), which permits use, distribution and reproduction for non-commercial purposes, provided the original is properly cited and derivative works building on this content are distributed under the same license.

IntechOpen

IntechOpen