

We are IntechOpen, the world's leading publisher of Open Access books Built by scientists, for scientists

6,900

Open access books available

185,000

International authors and editors

200M

Downloads

Our authors are among the

154

Countries delivered to

TOP 1%

most cited scientists

12.2%

Contributors from top 500 universities



WEB OF SCIENCE™

Selection of our books indexed in the Book Citation Index
in Web of Science™ Core Collection (BKCI)

Interested in publishing with us?
Contact book.department@intechopen.com

Numbers displayed above are based on latest data collected.
For more information visit www.intechopen.com



Motion Preservation and Shock Absorbing in Cervical and Lumbar Spine: A New Device for Anterior Cervical Arthroplasty, for Anterior or Posterior Lumbar Arthroplasty

Giuseppe Maida

Division of Neurosurgery, Department of Neurosciences and Rehabilitation

S. Anna Hospital

School of Medicine, Ferrara University

Italy

1. Introduction

In spine surgery, developing an anatomical, artificial disc prosthesis is one of the most difficult technological goals.

After surgical intervertebral disc removal, many pathologies are possible: to perform a vertebral fusion or a vertebral non fusion, depending on pathology that was treated, and in general, spinal condition in which these pathology were collocated.

While non fusion is the surgical option preferred, disc prosthesis is the preferred device.

Motion preservation, shock absorbing, biocompatibility, minimally invasive surgery for placement, and magnetic resonance imaging (MRI) compatibility, are essential technological aspects to satisfy.

Until now it was very difficult, if not impossible, to guarantee shock absorbing.

Shock absorbing, for these kinds of devices, is probably the most important biomechanical aspect.

A new device was recently ideated to resolve these problems.

Titanium and peek, materials of the devices, guarantee biocompatibility and MRI compatibility, much more resistance.

The particular shape of the device, reproducing a “molla a tazza” (“spring-cup”), the collocation and the alternation of the different materials in the device’s construction, guarantee the motion preservation and, most importantly, shock absorption characteristics.

All these elements reduce device dimensions.

Disc prosthesis, in fact, until now was implanted by an anterior surgical approach.

For lumbar surgery, much more than cervical surgery, the anterior approach is potentially a very invasive surgical way.

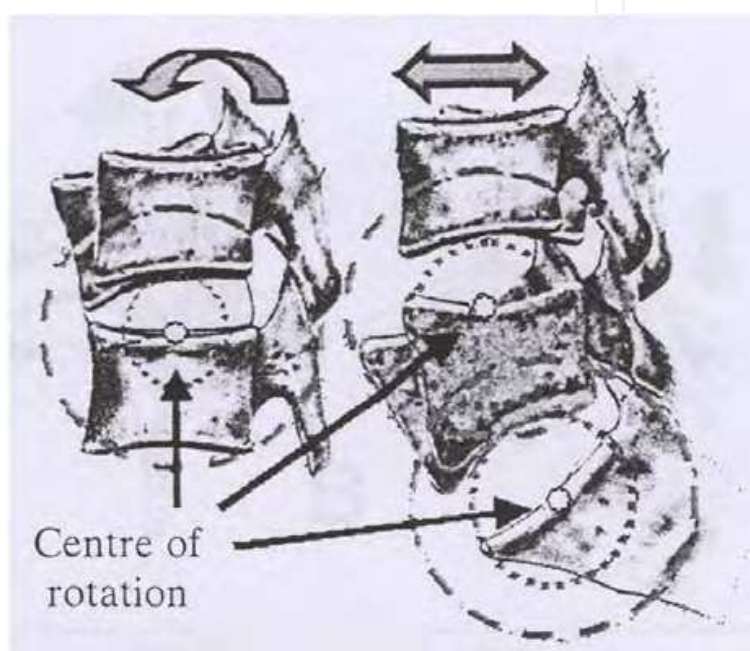
The possibility to perform a surgical lumbar disc prosthesis placement by a posterior approach is, potentially, a “revolution” in spine surgery, for the minimally invasive spine surgery goal.

After about 40 years of research and development, artificial disc technology is considered a real option in spine surgery.

Motion preservation, load sharing and cushioning are three of the most important aspects of the technology. They make the artificial device similar to the natural intervertebral disc becoming, with spinal kinematics and histologic osseointegration at the prosthetic-bone interface, a very hard research challenge.

Two vertebral bodies and the corresponding intervertebral disc are called Spinal Functional Unit (SFU): is a three-articular-complex, in which translation and rotation are allowed by X-Z-Y axis.

In flexion, extension and lateral bending, there is a variation of the SFU's instantaneous centre of rotation that, by an elliptical instantaneous axis, falls in the posterior half and inferior discal margin (picture 1).



Picture 1. SFU's instantaneous centre of rotation in X-Y-Z axis motion.

The artificial intervertebral disc, in a stand alone way, under ordinary and extraordinary load, has to perform and guarantee all these.

The Kinematical classification of the intervertebral disc prosthesis, based on the own different free motion degree, organizes the devices in 3 categories.

- unconstrained
- constrained, and,
- semiconstrained

Devices in each of the above 3 groups have advantages and disadvantages.

The first have a variable centre of rotation.

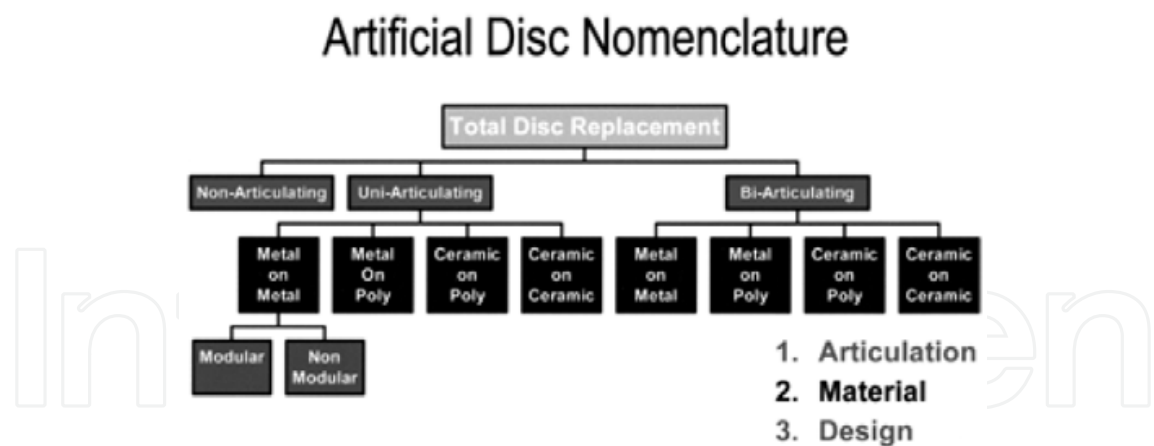
They permit anterior/posterior/lateral translation, rotation, guarantee a more physiological centre of rotation, but give more stress to the articular joints.

Prefer the preservation of the posterior longitudinal ligament (PLL) during their collocation, "forgiven" minimally positional imperfections.

The second have a fix centre of rotation.

They permit only rotation, have a less physiological centre of rotation, and give less stress to the articular joints.

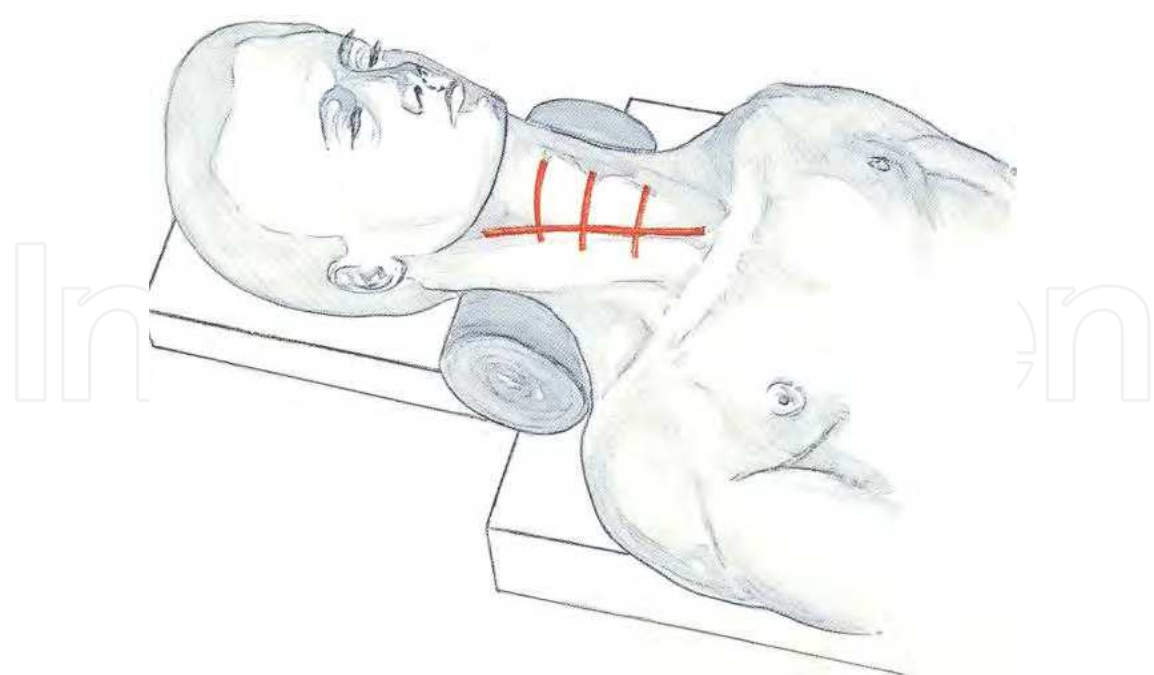
Another example of classification is reported in the picture 2.



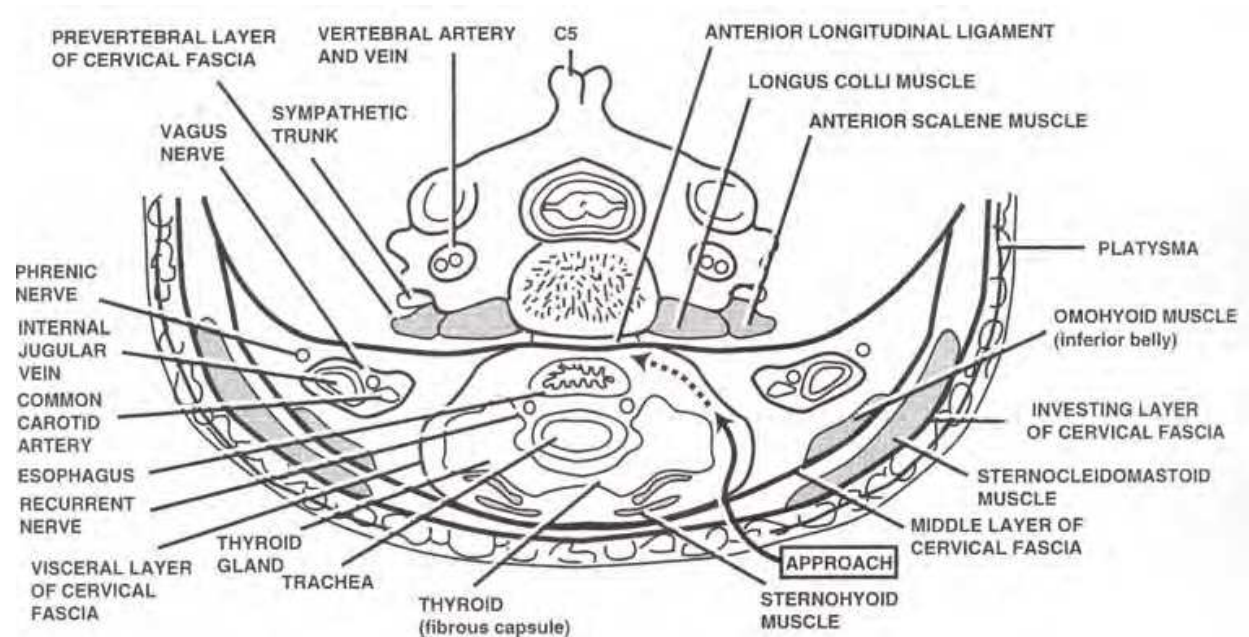
Picture 2. Cervical spine study group, 2004

2. State of art

The surgical approach used, until now, was anterior arthroplasty. For cervical spine, the anterior extrapharyngeal-presternocleidomastoideo approach is a very tested and safe way, in reoperation as well (pictures 3, 4). The incidence of cervical intraoperative complications (Haematoma, dysphagia, dysphonia), are 6.2% ; late complications (ossification, dislocation) about 5.2%. In cervical spine it is not difficult to convert, if needed, even in long follow-ups, an arthroplasty to fusion.



Picture 3. Cervical approach, position and skin incisions



Picture 4. Cervical approach, surgical way

For lumbar spine, the anterior trans-peritoneal and retroperitoneal approach (most used) are less safe (more in reoperations), because of gross vessels and nervous plexus, attached to the spine: even slight dislocation, sometime, may causes neurological damages or important vascular bleeding.

This needs a long learning curve, doing the operations with the collaboration of general or vascular surgeons.

The conversion arthroplasty-fusion may be very hard in lumbar spine.

The heterotopic ossification, with consequent block of the prosthesis and intervertebral fusion, increases from 12% to 17.8%: perioperative non steroid anti-inflammatory therapy (FANS) and intraoperative "wash-out", works out to be the best prevention.

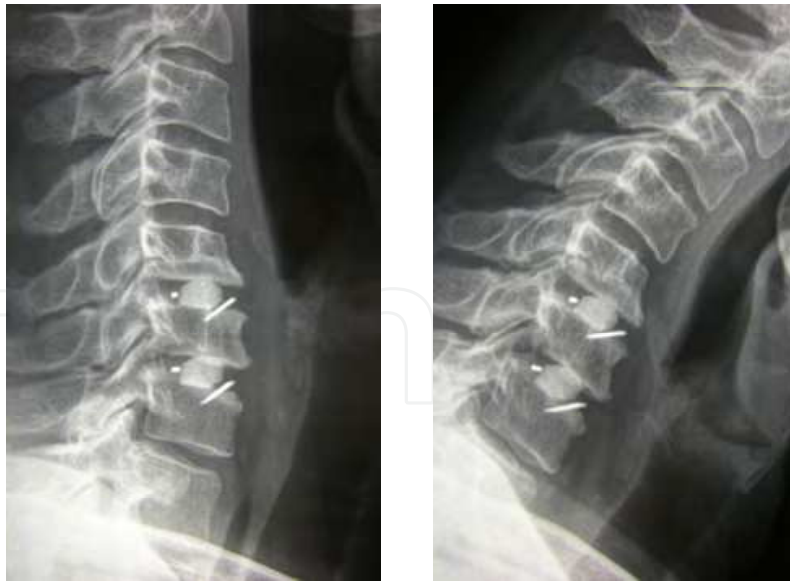The titanium alloys and the ceramics guarantee a better MRI compatibility than cobalt-chromium alloys or steel.

The biocompatibility is very important for post-operative controls, better if MR fast spin echo imaging (than T2 imaging)

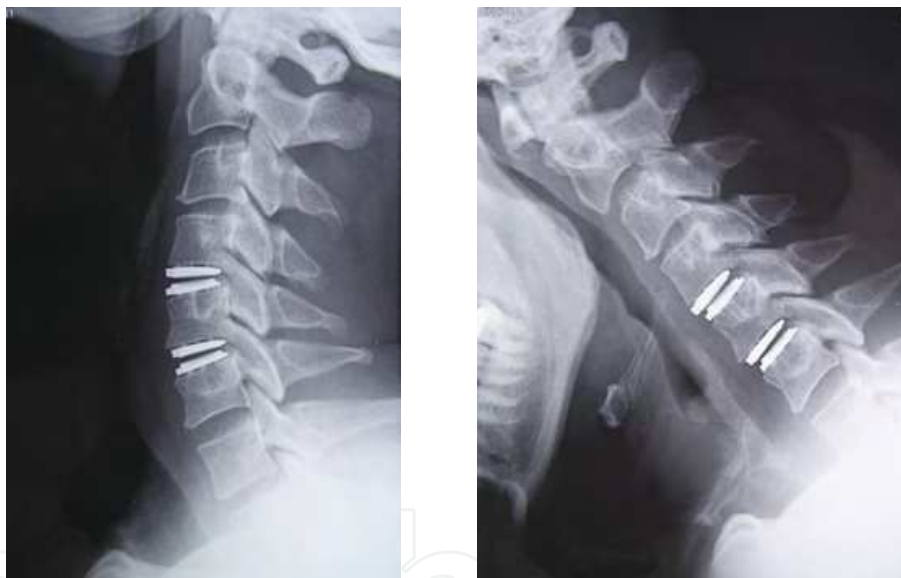These indications in disc herniation, after surgical disc removal, in alternative to anterior intervertebral fusion, preferring one single level, no more than two levels, from C4 to C6, from L4 to S1, not responding to conservative treatments, if there is a good pre-operative range of motion (ROM) to ward after the operation, for a long time and articular joints preservation (testing by MRI, bone CT scan and dynamic RX film), to avoid adjacent-segment degeneration in a long post-operative follow-up, without pre-operative bone fractures, bone tumours, bone deformities or bone infections.

Degenerative discopathy, about ten years ago, in USA, was estimated \$50 billion of annual health costs.

Arthroplasty, as alternative to fusion, was said before (pictures 5, 6).



Picture 5. Cervical fusion



Picture 6. Cervical arthroplasty

Fusion after discectomy is a consolidate surgical treatment for disc herniation.

A lot of papers, in literature, confirm long term follow-up, its effectiveness and safeness.

In last few years, some authors have reported it the other way.

Motion preservation and adjacent –segment degeneration's prevention are the Key words of arthroplasty.

The first argument is intuitive: arthroplasty, through non fusion, preserves the motion in the operated segment .

For the second question, biomechanics and kinematics, teach that in a series of mobile segments, when one of them is blocked or unable to shock absorb or cushioning functions, the caudal and the cranial segments suffer a mechanical stress, expressing in a motion alteration.

These alteration may cause structural and anatomical alterations, as well to produce clinical failures.

From a review of literature, these are the most important elements “pro” arthroplasty vs fusion:

1. motion maintenance at treated segment (stability of range of motion data: 7.4° one year post-operation and 7.9° five years post operation)
2. reduction of adjacent-discal-segment degeneration
3. reduction of intradiscal-pressure in cranial and caudal intervertebral disc
4. no aggravations of pathologies in cranial and caudal disc, if presents before the operation
5. more patient’s satisfaction, for both non post-operative orthosis dressing and early return to work.

Recently, only one paper about the not unequivocal significant utility of arthroplasty vs fusion has been reported.

In my personal surgical experience, consists of 60 patients treated with cervical microsurgical discectomy (MD group) vs 60 patients treated with cervical microsurgical discectomy and fusion (using titanium or peek devices) (MDF group) vs 60 patients treated with microsurgical discectomy and arthroplasty (MDA group), using “Discover” device[®] (picture 7).



Picture 7. “Discover” device[®].

The clinical and radiological follow-up was for a maximum period of 48 months.

The preliminary extrapolated data seems to confirm what had been reported before, from 1 to 5 points, encouraging and authorizing cervical arthroplasty vs cervical fusion, in discal pathology: rigorous and careful indication for patient selection, more long, shareable and verifiable follow-ups are imperative.

11.6% of clinical failures in MD group.

3. The new device^(patented, all rights reserved)

One of the most important limitations of discal prosthesis (cervical and lumbar) is the axial compression.

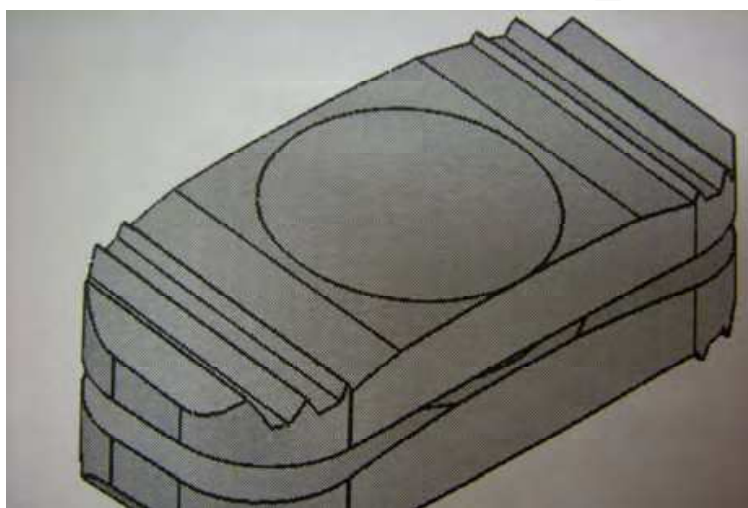
In a non pathological lumbar disc, for example, it ranges from 0.5 to 1.5 mm: this is a very important element for shock absorbing and cushioning.

Standing to the literature data, until now, no disc prosthesis has these characteristic.

Another significant limitation, only for lumbar prosthesis is, until now, the impossibility to place it by a posterior surgical approach, more handy, and safer than anterior approach.

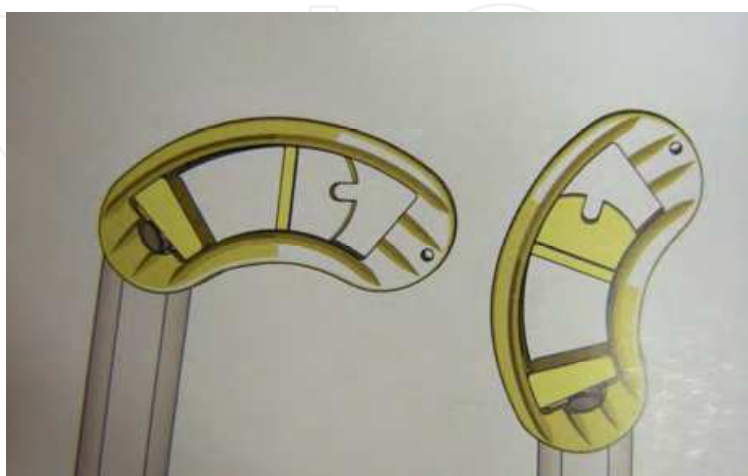These new devices (picture 8) try to satisfy the two conditions just described.

For the second question, was designed a particular way, standard sized, not more bulky (thanks to particular material used) so to introduce the device, after a bilateral posterior discectomy, after a bilateral laminar reduction, by a monolateral way into the intervertebral emptied and gently distracted space.



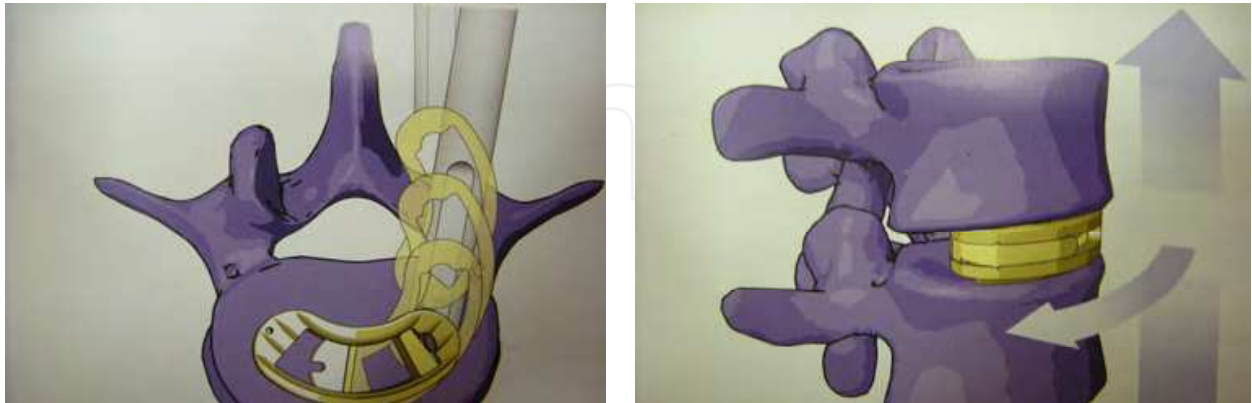
Picture 8. The new device

The device is introduced perpendicular to the intervertebral space, by a dedicated instrument and, at the anterior third of the space (verified by intraoperative RX film), by the same instruments, rotated in 180° according to the intervertebral space's axis (picture 9).



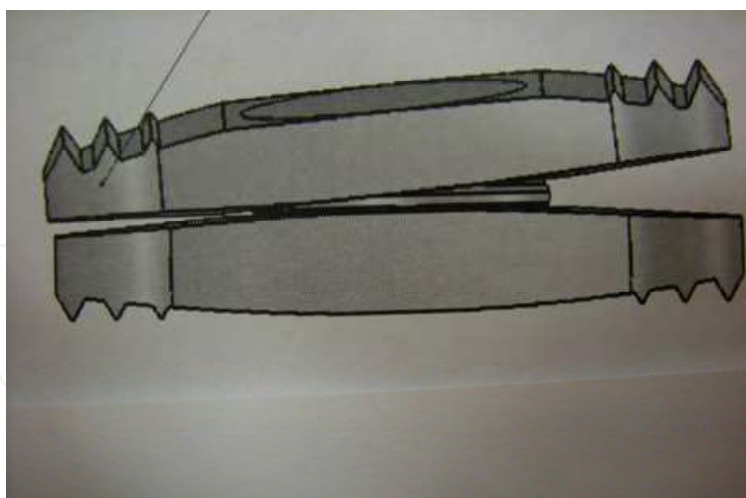
Picture 9. The device and its instruments . During the introduction (on right), after the 180° rotation (on left)

Then, unhooked the dedicated instruments, the devices remain anchored in situ after a gentle intervertebral space compression, even through its superior and the inferior tops, rough and teeth fitted, that favour a fusion, with the corresponding vertebral end plates (picture 10).



Picture 10. The device and its instruments during the introduction and rotation (on left) the device after its definitive collocation (on right)

To the second purpose, particular attention was given to the structural design, to the materials and to the sequence of the components in their assembly, in order to give to the device features similar to the non pathological intervertebral disc: bone and biocompatibility, MRI compatibility, strength to static load for maximum 330 kg , 4°-5° of maximum inclination on all side and, mostly (picture 11), features not held by other devices until now, shock absorbing, load sharing and chushioning .

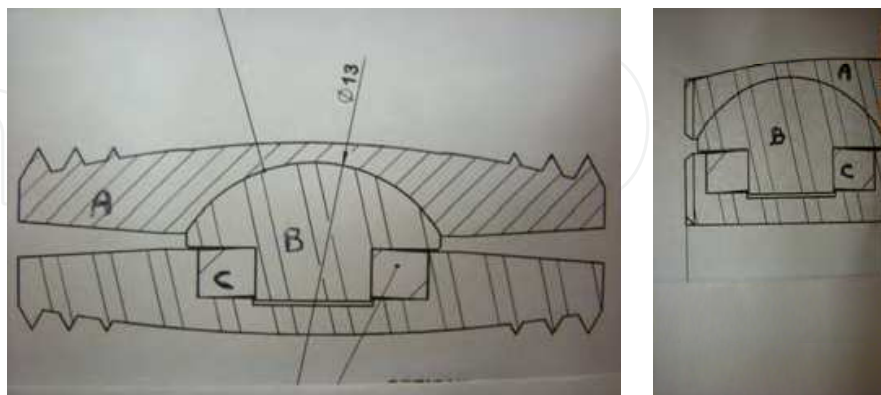


Picture 11. The device's inclination in a front view.

The use of two rough teeth fitted titanium tops (superior and inferior) , opposite to the corresponding vertebral and plates ("A" in picture 12), guarantee bone and biocompatibility, MRI compatibility, strength to static loads for maximum 330 kg.

Their mutual articulation, by a titanium spherical node (fitted of a security self-stoppage system), behaving like a "spring -cup" ("B" in picture 12), create a metal/metal antifriction interface securing strength, motion preservation and shock absorbing.

Finally, the use of an organic polymer thermoplastic (Polyether-Ether-Ketone, “PEEK”) to shape a “bed” in which is collocated the titanium spherical node (“C” in picture 12) complete the shock absorbing function, giving load sharing and cushioning features, elastic response to the loads.



Picture 12. Structural devices view, frontal (left) and lateral (right)

4. Conclusions

The literature data, until now, had cautiously encouraged the non fusion versus the fusion, in the surgical treatment of degenerative discal pathology (in cervical and lumbar spine). However, the elements that prefer arthroplasty over fusion were, in my opinion, mainly three:

1. a more long follow-up for fusion cases
2. the impossibility of a posterior surgical approach in lumbar spine
3. the impossibility to have a really shock absorbing, load sharing and cushioning function, but only motion preservation and strength to static load (both in cervical and in lumbar spine).

These studies, that led to the design and the creation of these device, aim to fill the gaps just emphasized above, giving a new prosthesis both in cervical spine (in order to really shock absorb, load share and cushioning functions) and in lumbar spine (in order both in these same features and in the really possibility to perform a posterior surgical approach, certainly more safe for the patients and experienced for the spine surgeons. Only a long follow-up may validate or not these work.

5. Acknowledgment

Andrea Bedeschi, engineer in Ferrara (Italy)

6. References

Bartles, R.H.M.A et al., 2010. No justification for cervical disk prostheses in clinical practice:a meta-analysis of randomized controlled trials. Neurosurgery, Vol.66, No.6, (June 2010), pp.1-8

- Brunner, H.J. et al., 2010. Biomechanics of polyaryletherketone rod composites and titanium rods for posterior lumbosacral instrumentation. *J Neurosurg Spine*, Vol.13, (December 2010), pp.766-772
- Coric, D. et al., 2010. Prospective study of cervical arthroplasty in 98 patients involved in 1 of 3 separate investigational sites with a minimum 2-year follow-up. *J Neurosurg Spine*, Vol 13, (December 2010), pp. 715-721
- Fehlings, M.G. et al., 2010. Motion preservation following anterior cervical discectomy. *J Neurosurg Spine*, Vol 13, (December 2010), pp.297-298
- Logroscino, C.A. et al., 2007. Artroplastica vertebrale: stato dell'arte della chirurgia protesica cervicale e lombare G.I.O.T., Vol 33 (suppl.1), pp.155-161
- Maida, G. et al., 2008. Artroplastica cervicale: la nostra esperienza. *Rivista Medica*, Vol 14, No.3, (September 2008), pp.53-56, ISSN 1127-6339, ISBN 978-88-8041-012-6
- Maida, G. et al., 2009. 60 patients follow-up, from 6 months to 2 years, in patients treated with discover arthroplasty after discectomy and preliminary comparison with discectomy and fusion and discectomy alone. *Eur.Spine.J*, Vol 18, (May 2009), pp.757
- Ryu, K.S. et al., 2010. Radiological changes of operated and adjacent segments following cervical arthroplasty after a minimum 24-month follow-up: comparison between the bryan and Prodisc-C-devices. *J Neurosurg Spine*, Vol 13, (September 2010), pp.299-307

IntechOpen



Human Musculoskeletal Biomechanics

Edited by Dr. Tarun Goswami

ISBN 978-953-307-638-6

Hard cover, 244 pages

Publisher InTech

Published online 05, January, 2012

Published in print edition January, 2012

This book covers many aspects of human musculoskeletal biomechanics. As the title represents, aspects of forces, motion, kinetics, kinematics, deformation, stress, and strain are examined for a range of topics such as human muscles, skeleton, and vascular biomechanics independently or in the presence of devices. Topics range from image processing to interpret range of motion and/or diseases, to subject specific temporomandibular joint, spinal units, braces to control scoliosis, hand functions, spine anthropometric analyses along with finite element analyses. Therefore, this book will be valuable to students at introductory level to researchers at MS and PhD level searching for science of specific muscle/vascular to skeletal biomechanics. This book will be an ideal text to keep for graduate students in biomedical engineering since it is available for free, students may want to make use of this opportunity. Those that are interested to participate in the future edition of this book, on the same topic, as a contributor please feel free to contact the author.

How to reference

In order to correctly reference this scholarly work, feel free to copy and paste the following:

Giuseppe Maida (2012). Motion Preservation and Shock Absorbing in Cervical and Lumbar Spine: A New Device for Anterior Cervical Arthroplasty, for Anterior or Posterior Lumbar Arthroplasty, Human Musculoskeletal Biomechanics, Dr. Tarun Goswami (Ed.), ISBN: 978-953-307-638-6, InTech, Available from: <http://www.intechopen.com/books/human-musculoskeletal-biomechanics/motion-preservation-and-shock-absorbing-in-cervical-and-lumbar-spine-a-new-device-for-anterior-cervi>

INTECH
open science | open minds

InTech Europe

University Campus STeP Ri
Slavka Krautzeka 83/A
51000 Rijeka, Croatia
Phone: +385 (51) 770 447
Fax: +385 (51) 686 166
www.intechopen.com

InTech China

Unit 405, Office Block, Hotel Equatorial Shanghai
No.65, Yan An Road (West), Shanghai, 200040, China
中国上海市延安西路65号上海国际贵都大饭店办公楼405单元
Phone: +86-21-62489820
Fax: +86-21-62489821

© 2012 The Author(s). Licensee IntechOpen. This is an open access article distributed under the terms of the [Creative Commons Attribution 3.0 License](https://creativecommons.org/licenses/by/3.0/), which permits unrestricted use, distribution, and reproduction in any medium, provided the original work is properly cited.

IntechOpen

IntechOpen