

We are IntechOpen, the world's leading publisher of Open Access books Built by scientists, for scientists

6,900

Open access books available

186,000

International authors and editors

200M

Downloads

Our authors are among the

154

Countries delivered to

TOP 1%

most cited scientists

12.2%

Contributors from top 500 universities



WEB OF SCIENCE™

Selection of our books indexed in the Book Citation Index
in Web of Science™ Core Collection (BKCI)

Interested in publishing with us?
Contact book.department@intechopen.com

Numbers displayed above are based on latest data collected.
For more information visit www.intechopen.com



European Braces for Conservative Scoliosis Treatment

Theodoros B. Grivas

*Orthopaedic and Spinal Surgeon, Director of Orthopaedics and Trauma Department,
"Tzanio" General Hospital of Piraeus, Piraeus
Greece*

1. Introduction

Several published articles suggest that an untreated progressive idiopathic scoliosis (IS) curve may present a poor prognosis into adulthood including back pain, pulmonary compromise, cor pulmonale, psychosocial effects, and even death [Rowe 1998, Danielsson et al 2006, Danielsson et al. 2007, Weinstein et al. 1981, Weinstein and Ponsetty 1983, Weinstein et al 2003]. Bracing, even though it hasn't gained complete acceptance, has been the basis of non-operative treatment for IS for nearly 60 years, [Negrini et al. 2009, 2010a,b, Schiller et al. 2010].

The majority of publications in the peer review literature refer to braces used in North America, [Schiller et al 2010], and there is a lack of systematic examination of the braces commonly used in Europe. The aim of this report, based on peer review publications on the issue, is to concisely describe the European braces which are widely used, focusing on their history, design rationale, indications, biomechanics, outcomes and comparison between them. Cheneau Brace, the two Cheneau derivative braces, namely the Rigo System Cheneau and the ScoliOlogiC® "Chêneau light", the Lyonnaise Brace, the Dynamic Derotating Brace (DDB) the TriaC brace, the Sforzesco brace and the Progressive Action Short Brace PASB will be described.

2. Biomechanics of brace action used for conservative treatment in spinal deformity

The brace as a mean of spinal deformity conservative treatment should be based on the following general principles:

1. Prevention of asymmetric compressive forces related to passive posture
2. Reduction of the secondary muscle imbalance
3. Prevention of the lordosing reactive forces (passive posture, repeated forward bending movements)
4. Prevention of asymmetric torsional forces from gait
5. Production of dynamic detorsional forces involving breathing mechanics. [Rigo & Grivas 2010]

Understanding the biomechanics of brace action is most important. The brace applies external corrective forces to the trunk with the aim to halt the curve progression or to correct

it during growth, [The Scoliosis Research Society Brace Manual, Rigo et al. 2006, Grivas et al. 2003, 2010, Negrini et al. 2010a] or to avoid further progression of an already established pathological curve in adulthood.

To achieve these goals, rigid supports or elastic bands can be used [Coillard et al. 2003, Wong et al 2008] and braces can be custom-made or prefabricated [Weiss et al 2008, Sankar et al 2007, Wong et al 2005a, 2005b].

The spinal correction is accomplished by the application of mechanical forces with the intention to reduce the pathological compression on given parts of the vertebral column (usually the concave side), while increasing it on others, (usually the convex side). This will result in a more symmetrical and natural loading and will make possible proper spinal growth [Lupparelli et al. 2002, Castro 2003, Weiss & Hawes 2004]. It will also prevent progressive degeneration of the spine [Lupparelli et al. 2002, Stokes et al 2006, Stokes 2008].

Although this is an old concept, the theory has been reinforced over time and for IS was recently summarized in the “vicious cycle” hypothesis [Stokes et al 2006], where it is proposed that lateral spinal curvature produces asymmetrical loading of the skeletally immature spine through movement and neuromuscular control, which in turn causes asymmetrical growth and hence progressive wedging deformity. In this respect, the role of the intervertebral discs in the progression of IS and in its possible correction using bracing has also recently been considered [Grivas et al 2006 Grivas et al 2008a]. Conversely, bracing could establish a useful “virtuous cycle”, and as a result could lead to gradual reduction of the asymmetry present in scoliosis [Rigo et al 2006, Rigo et al 2008]. In accordance with these theories, a novel concept describing a comprehensive model of IS progression, based on the patho-biomechanics of the deforming “three joint complex” was also recently presented [Grivas et al 2009].

An alternative hypothesis suggests that the use of braces leads to neuro-motor reorganization caused by the changes in external and proprioceptive inputs and movement resulting from the constraint of bracing [Coillard et al 2002, Odermatt et al 2003, Negrini et al 2006, Smania et al 2008]. According to this hypothesis, braces are considered the drivers of movement while they increase external and internal bodily sensations. This permanently changes motor behaviours, even when the brace is removed, and can have a long-term effect on bone formation. This hypothesis can be easily applied also at all pathologies and ages; can be considered correct in terms of trunk behaviour and neuro-muscular organization, while its possible effect on growing bone needs further investigation. Two other interesting and significant concepts to explain the actions of the brace have been discussed. One suggests that the brace provides mechanical support to the body (passive component), while the other suggests that the patient pulls his/her body away from pressure sites (active component) to correct the curve. Such divergent theories illustrate the complexity of this problem, but the most important point of brace treatment is to provide the three dimensional correction of the spinal deformity, and methodologies must be developed with this in mind [Negrini & Grivas 2010, Bagnall et al 2009].

3. Treatment management principles and outcome description

The analysis of the treatment management principles and outcome description is beyond the scope of this chapter, which describes the European braces in use. However it was considered that it would be very useful to cite them, at least epigrammatically and give to the reader the existing useful references.

Key elements of the recommendations are efficacy and compliance. The latter stem from the planned treatment, as well as from the responses of the patient and family. It is also highly related to behaviour of the treating team.

The recommendations concerning the standards of management of idiopathic scoliosis with bracing, with the aim to increase efficacy and compliance to treatment are extensively described in a recent SOSORT Consensus paper. It is recommended to professionals engaged in patient care to follow the guidelines of this Consensus in their clinical practice. The SOSORT criteria should also be used along with the published criteria for bracing proposed by SRS, [Negrini et al 2009b,e, Thompson and Richards 2008, Richards et al. 2005]. Several other major issues in brace management apart compliance are currently also in discussion, namely, the pressure being applied, the treatment time and the bending radiographs. These topics are also discussed in the recently published editorial on "Scoliosis" Journal Brace Technology Thematic Series by Negrini & Grivas 2010.

4. European braces for conservative scoliosis treatment

4.1 Cheneau brace

Dr Jacques Chêneau built the brace during the 60's. In 1972 the first patient's results were obtained and officially presented in 1979 at Bratislava. Initially the brace was named Cheneau-Toulouse-Munster Brace as well. Now it is accepted and used worldwide. Useful information on the brace and its philosophy can be found in <http://cheneau.info>. It is a rigid brace providing three-dimensional correction, **Figure 1**. The mechanisms of Chêneau Brace correction are a) passive mechanisms, namely 1) convex to concave tissue transfer, achieved by multiple three-point system acting in 3D, with the aim of curve hypercorrection, 2) elongation and unloading by the "cherry stone" effect, 3) Derotation of the thorax, 4) bending and b) active mechanisms, namely 1) vertebral growth acting as a corrective factor, 2) asymmetrically guided respiratory movements of the rib-cage, 3) repositioning of the spatial arrangement of the trunk muscles to provide their physiological action and 4) anti-gravitational effect, [Kotwicki & Cheneau 2008 a,b]. This brace opens anteriorly. After some modifications made by Dr Jacques Chêneau, since 1996 the brace is divided in 54 zones and provides large free spaces opposite to pressure sites. The hump should be pressed on 1/3 of the surface of apex. The corresponding dodging site involves 4/5 of the surface of the concave side of curve. Each of the remaining two pressure parts of the three-point system presses on 1/5 of the surface of the concave side. They are the apexes of the neighboring curves. Dodging opposite the latter sites allows movements and straightening of the curve in an active way. It is not permitted to hinder any of the three dodging areas, that is, the middle 4/5 of concave side and the 1/3 over and under the apex. Regarding the outcomes of brace application, the Cheneau-Toulouse-Munster brace has been found to decrease the coronal shift forward, the coronal tilt, the axial rotation, and to increase the sagittal shift forward and the sagittal vertebral tilt (3-D correction), [Périé et al. 2001], obtaining an average primary correction 41% (thoracic, lumbar, double) (n = 52 patients) and a long term correction 14.2% thoracic, 9.2% lumbar double curves: 5.5% in thoracic & 5.6% in lumbar, [Hopf & Heine 1985]. In a recent report, at the end of treatment there was an improvement of Cobb angle correction of about 23% and after 5 years there was a stabilization of about 15 % (p value < 0.05). Therefore, based on this study, it could be stated that conservative treatment with Cheneau brace not only stops progression, but it also reverses the scoliotic curve [Cinnella et al. 2009]. The effectiveness of Cheneau brace in

the management of IS was also recently analysed in a prospective observational study, [Zaborowska-Sapeta et al 2011]. It reports the results of treatment according to SOSORT and SRS recommendations on 79 patients (58 girls and 21 boys) with progressive IS, treated with Cheneau brace and physiotherapy, with initial Cobb angle between 20 and 45 degrees, no previous brace treatment, Risser 4 or more at the final evaluation and minimum one year follow-up after weaning the brace. Achieving 50 degrees of Cobb angle was considered surgical recommendation. At follow-up 20 patients (25.3%) improved, 18 patients (22.8%) were stable, 31 patients (39.2%) progressed below 50 degrees and 10 patients (12.7%) progressed beyond 50 degrees (2 of these 10 patients progressed beyond 60 degrees). Progression concerned the younger and less skeletally mature patients, [Zaborowska-Sapeta et al 2011].

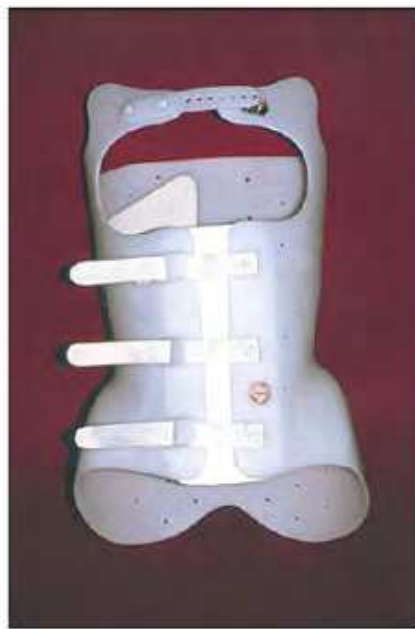

Fig. 1. The Cheneau brace

4.2 Cheneau brace derivatives (Rigo system Cheneau brace, ScolioLogiC® “Chêneau light” and the Gensingen brace™)

4.2.1 Rigo system cheneau brace

This brace was developed by Dr Manuel Rigo during the early 90s in Instituto Èlena Salvá in Barcelona, Spain. The German - Spanish collaboration for brace production and information on manufacturing can be obtained at: http://www.ortholutions.de/start_english.php. The RSCB, **Figure 2**, is based on the Chêneau Brace, and it is able to produce the required combined forces to correct scoliosis in 3D. The blueprint of the brace is based on the idiopathic scoliosis curve classification correlated with brace treatment introduced by Dr Rigo [Rigo et al 2010a]. The classification includes radiological as well as clinical criteria. The radiological criteria are utilized to differentiate five basic types of curves including: (I) imbalanced thoracic (or three curves pattern), (II) true double (or four curve pattern), (III) balanced thoracic and false double (non 3 non 4), (IV) single lumbar and (V) single thoracolumbar. In addition to the radiological criteria, the Rigo Classification incorporates the curve pattern according to SRS terminology, the balance/imbalance at the transitional point, and L4-5 counter-tilting. The principles of correction of the five basic types of curves

are also described by Dr. Rigo, [Rigo et al 2010a]. Biomechanically the RSC brace offers regional derotation. The rib cage and spine are de-rotated. The brace derotates the thoracic section against the lumbar section, with a counter-rotation pad at the upper thoracic region [Rigo and Weiss 2008]. The brace also produces physiological sagittal profile. Initial reports on outcomes using this brace indicated a 31.1% primary Cobb angle correction and 22.2% primary torsion angle correction. At a follow up of 16.8 months 54% of curves were stable, 27% improved and 19% progressed, [Rigo et al 2002]. In patients with long thoracic curves treated with a recently described RSC brace design (three-curve-scoliosis brace with pelvis open) there was 76.7 % in-brace Cobb angle correction and 55.9% in-brace axial rotation correction [Rigo & Gallo 2009]. The latter pattern is easy to correct according to the principles and it can not be compared to “Chêneau light” cohort, which in addition contains double curve patterns which correct least [Weiss et al 2007].

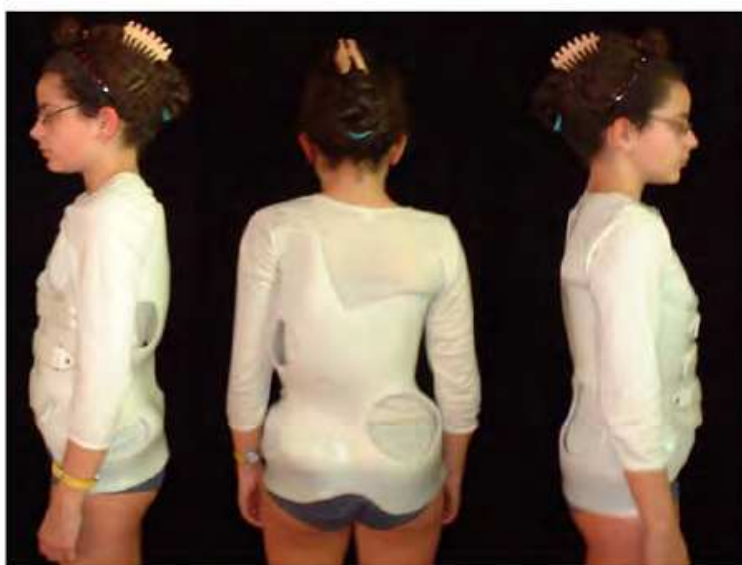

Fig. 2. Rigo System Cheneau Brace

4.2.2 ScoliOlogiC® “Chêneau light”

The brace, **Figure 3**, was invented by Dr. Hans-Rudolf Weiss. The application for the patent was presented in April 2005 and the first braces were built in May 2005. Useful information on the brace can be obtained in <http://www.koob-scolitech.com/scoliologic.php> and [Weiss et al 2007 and Weiss & Werkmann 2010].

The ScoliOlogiC® off the shelf bracing system enables the CPO to construct a light brace for scoliosis correction from a variety of pattern specific shells to be connected to an anterior and a posterior upright. This brace, when finally adjusted is called Chêneau light™ brace. The advantage of this new bracing system is that the brace is available immediately, is easily adjustable and that it can also be easily modified. This avoids construction periods of sometimes more than 6 weeks, where the curve may drastically increase during periods of fast growth. The disadvantage of this bracing system is that there is a wide variability of possibilities to arrange the different shells during adjustment, [Weiss & Werkmann 2010]. Weiss et al, 2007, reported 51% correction of Cobb angle (Cobb angle in the whole group of patients was reduced by an average of 16,4 degrees), 62 % correction for lumbar & thoracolumbar curve pattern, 36 % correction for thoracic scoliosis and 50 % correction for

double major curve pattern. The correction effect correlated negatively with age ($r = -0,24$; $p = 0,014$), negatively with the Risser stage ($-0,29$; $p = 0,0096$) and negatively with Cobb angle before treatment ($r = -0,43$; $p < 0,0001$) [Weiss et al 2007].

The reduction of material in the Chêneau light® brace seems to increase patient's comfort and reduces the stress patients may suffer from whilst in the brace. 80% of the adolescent population of scoliosis patients can be braced with the Chêneau light™ brace. In certain patterns of curvature and in the younger population with an age of less than 11 years, other approaches have to be used, such as plaster based bracing or the application of CAD/CAM based orthoses [Weiss & Werkmann 2010].

There are blueprints to build a RSC® or a Chêneau light® brace according to the conservative treatment of AIS classification by Dr M. Rigo and Dr. HR Weiss [Rigo & Weiss 2008].

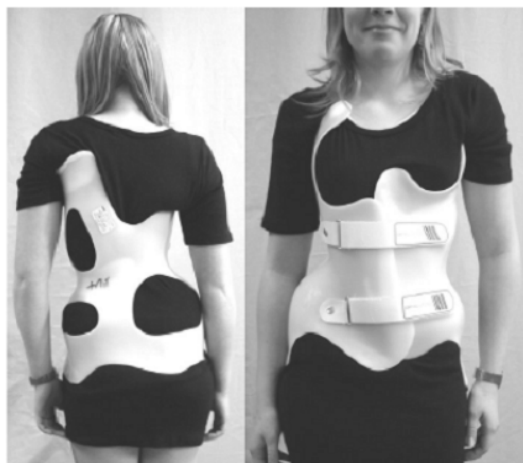

Fig. 3. ScolioOlogiC® “Chêneau light”

4.2.3 The Gensingen brace™

From the experience obtained through the Chêneau light® brace a new CAD/CAM brace has been designed and applied by Dr. Weiss since 2009 which is called the Gensingen brace®. It is extensively described, [Weiss 2010a,b]

This is a new asymmetric Chêneau style CAD/CAM derivate. It has been designed to overcome some problems the designer experienced with other Chêneau CAD/CAM systems over his medical praxis during the recent years, Figure 4.

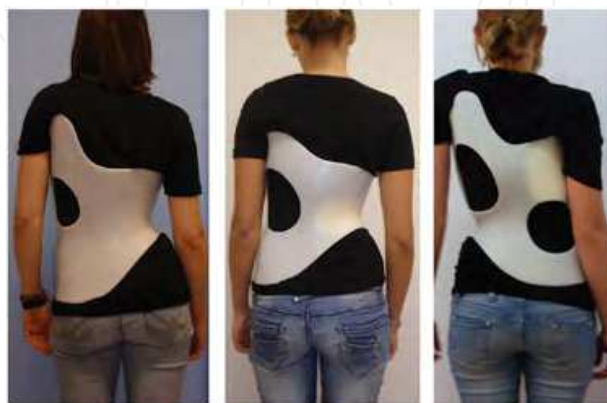

Fig. 4. Different Gensingen braces™ on the patient's body, from Weiss 2010b].

The Gensingen brace™ is adjusted according to the same principles of correction as the Chêneau light™ brace, therefore similar results in both brace types are expected, [Weiss 2010b].

As it is reported, the majority of patients treated by Dr Weiss choose the Chêneau light™ brace. However the Gensingen brace™ is used in curvature patterns a Chêneau light™ brace is not available for, or for curvatures exceeding 50°. Therefore, a direct comparison of the results achieved with both brace types will not be possible in the near future. The so far documented results are based on case reports showing sufficient in-brace corrections in certain curve patterns and in bigger curves as well, [Weiss 2010b].

According to the patients' reports the Gensingen brace™ is comfortable to wear, when adjusted properly, [Weiss 2010b].

4.3 Lyonnaise brace

It is an adjustable rigid brace, without any collar, Figure 5. The Lyon Brace was created by Pierre Stagnara in 1947. Allègre and Lecante modified it to its present form using aluminium bars and plexidur (a high rigidity material) in 1958.

The brace features several characteristics in order to allow for the child's growth of up to seven centimeters and increase in weight of seven kilograms. It is active because of the rigidity of the PMM (polymetacrylate of methyl) structure. The child's body shape is stimulated and the active axial auto correction decreases the pressures of the valve on the trunk. It is decompressive due to the effect of extension between the two pelvic and scapular girdles which decreases the pressure on the intervertebral disc and allows a better effectiveness of the pushes in the other planes. It is symmetrical and additionally to the aesthetic aspect, the brace is easier to build. It is stable and its stability of both the shoulder and pelvic girdles facilitates the intermediate 3D corrections. It is transparent and usually, it is not necessary to use "pads"; so the pressure of the shells on the skin can be directly controlled, [de Mauroy et al. 2011].

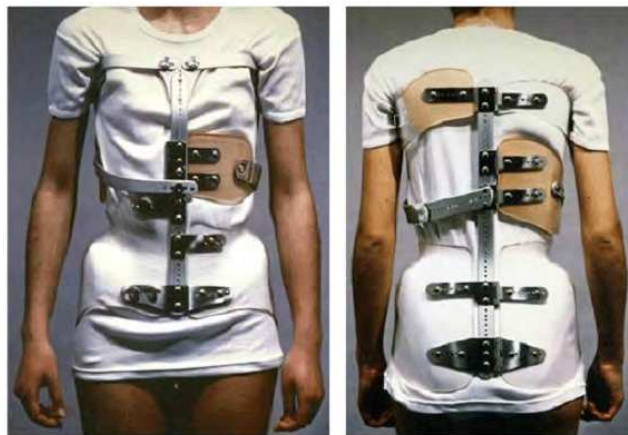


Fig. 5. The Lyonnaise Brace

The bars of the brace are made of radio see-through duralumin, the faceplate and joint of high steel and the thermo malleable plastic is made of polymetacrylate of methyl. The treatment using Lyonnaise Brace is based on two main principles of treatment. An initial plaster cast to stretch the deep ligaments before the application of Lyon brace and the subsequent application of the adjustable brace. The blueprint is designed according to

Lenke’s idiopathic scoliosis classification and there are 14 design types, figure 6. The indications for this brace are scoliotics 11-15 years old. It is not applied earlier to prevent tubular deformation of the thorax. The reported results detail an effectivity index (results of 1338 scoliosis treated in France and in Italy based on SRS - SOSORT treatment criteria 2 years after the weaning of the brace) 0,97 for lumbar curve, 0,88 for thoraco-lumbar curve and 0,80 for thoracic curve. The Cobb angle correction is reported for thoracic (n=285 cases) correction 12%, double major (n=351 cases) 10% and 25% respectively, thoraco-lumbar (n=279 cases) 24%, lumbar (n= 450 cases) 36%. Results are also obtained on cosmesis (hump in mm). The rib hump is better corrected than the Cobb angle, which is reduced by 1/3 at the thoracic level and by more than 50% at the lumbar level. The esthetical aspect is always better than the radiographs. In 1338 treated scoliotics, 67.19 % improved, 27.80 % were stable and 5.00 % deteriorated, [de Mauroy et al 2008a,b].




Fig. 6. Blueprints corresponding to 14 types of the Lenke’s classification for a right thoracic and left lumbar scoliosis

4.4 Dynamic Derotating Brace (DDB)

The dynamic derotation brace (DDB) was designed in Greece in 1982, as a modification of the Boston brace. It is a custom-made, underarm spinal orthosis featuring aluminium blades set to produce derotating and anti-rotating effects on the thorax and trunk of patients with scoliosis. It is indicated for the non-operative correction of most curves, barring the very high thoracic ones, (when the apex vertebra is T5 or above) [Grivas et al. 2010]. This brace was developed by the late Dr D. Antoniou and Dr J Valavanis at Athens. The first official announcement of Dynamic Derotating Brace (DDB) took place at the 21st common meeting of SRS and BSS, 1986. It is made of polypropylene with a soft foam polyethylene lining, Figure 7a,b. This brace opens posteriorly, [Antoniou et al 1986].

The key feature of the DDB is the addition of the aluminium-made derotating blades posteriorly. These function as a force couple, which is added to the side forces exerted by the brace itself. Corrective forces are also directed through pads. One or more of previously proposed pathomechanical models of scoliosis may underline the corrective function of the DDB: it may act directly on the apical intervertebral disc, effecting correction through the Heuter-Volkman principle; the blades may produce an anti-rotatory element against the deforming "spiral composite muscle trunk rotator"; or it may alter the neuro-motor response by constantly providing new somatosensory input to the patient.




Fig. 7. a,b. The dynamic derotation brace (DDB). (7a: anterior and posterior view), The DDB extends from underneath the axillae to the pelvis, 7b. The dynamic derotation brace (DDB), lateral view of a DDB.

More specifically, in this TLSO type brace, the anti-rotatory blades act as springs - anti-rotatory devices, maintaining constant correcting forces at the pressure areas of the brace

and, at the same time, produce movements in opposite directions of the two side-halves of the brace. The de-rotating metal blades are attached to the rear side of the brace corresponding to the most protruding part of the thorax (hump) or the trunk of the patient. They become active when their free ends are located underneath the opposite side of the brace and the brace is tightened by its straps, [Valavanis et al 1995]. The forces applied by the de-rotating blades are added to the side forces exerted by the brace, and changing of the backward angle of the blades can modify them.

There are three main types of DDB designs. The thoracic/thoracolumbar module, whose main indications are thoracic or thoracolumbar curves. It encompasses one or two de-rotatory blades, attached opposite to the thoracic or thoracolumbar hump, figure 8 The lumbar module, used in lumbar curves, is constructed with one de-rotatory blade, located opposite to the lumbar loin hump, figure 9 [Grivas et al. 2010] The double curve module, figure 10, used in patients with double major curves, is supplied with two de-rotatory blades, placed over the thoracic hump and lumbar loin hump each. Each blade acts on the contralateral posterior half of the brace. A major difference of the lumbar curve pattern module with the thoracic/thoracolumbar curve pattern and double major curve pattern modules is the longer trochanteric and the reduced thoracic extension of the former, as seen in figure 6, compared with the later two modules (see figures 8,9 and 10). The positioning of the derotation blade also differs according to the curve pattern module as described. As noted previously, the pads are always placed against the apex of the hump. [Grivas et al. 2010].



Fig. 8. The dynamic derotation brace (DDB), the thoracic/thoracolumbar module.



Fig. 9. The dynamic derotation brace (DDB), the Lumbar module.



Fig. 10. Dynamic derotation brace (DDB), the double curve module

The conservative treatment of IS using the DDB has shown favorable results. The published outcomes reports detail an overall initial Cobb angle correction of 49.54% and at 2 years follow up a correction of 44.10%, [Andoniou et al. 1992 , Valavanis et al 1995]. It was also reported that the overall 35.70% of curves improved, 46.42% were stable and 7.83% worsened – increased, [Grivas et al 2003]. Thoracic curves appear more resistant to both angular and rotatory correction. As far as the cosmesis is concerned (Angle Trunk Inclination – ATI – hump), DDB improves the cosmetic appearance of the back of IS children with all but right thoracic curves, [Grivas et al 2008b]. Study on quality of life after conservative treatment of AIS using DDB with the Brace Questionnaire (BrQ), which is specific for conservative treatment, revealed an influence on school activity and social functioning, but not on general health perception, physical functioning, emotional functioning, vitality, bodily pain, self-esteem or aesthetics, [Vasiliadis & Grivas 2008, Vasiliadis et al 2006a, Vasiliadis et al 2006b].

The published outcome data on the DDB support the authors' belief that the incorporation of aluminium blades to other orthoses would likely improve their efficacy, [Grivas et al. 2010].

4.5 TriaC brace

This brace was developed by Dr Albert Gerrit Veldhuizen in Nederland. The name TriaC derives from the three C's of Comfort, Control, and Cosmesis. The TriaC orthosis has a flexible coupling module connecting a thoracic and a lumbar part, Figure 11. The TriaC brace exerts a transverse force system, consisting of an anterior progression force counteracted by a posterior force and torque, acts on the vertebrae of a scoliotic spine. In the frontal plane the force system in the TriaC brace is in accordance with the force system of the conventional braces. However, in the sagittal plane the force system only acts in the thoracic region. As a result, there is no pelvic tilt, and it provides flexibility without affecting the correction forces during body motion, [Veldhuizen 1985, Veldhuizen et al 2002]. The introducers suggest that the inclusion criteria are: IS with a Cobb-angle between 20 and 40 degrees, in skeletally immature scoliotics, with Risser 0-1 status, pre-menarche, post-menarche\1 year, in primary thoracic apex between the 7th and 11th thoracic vertebra and primary lumbar apex between the 2nd and 5th lumbar vertebra, in flexible spinal column as evidenced by at least 40% correction on bending films [Bulthuis et al 2008].

Some other studies suggest that the TriaC™-Brace represents an alternative exclusively for the correction of lumbar curves [Zeh et al 2008]. An initial 22% correction is reported for the

primary curves within the brace and 35% for the secondary curves. The improvement remained after bracing and in a mean follow up of 1.6 years, as long as it was above a threshold of 20%. In 76% of the patients there was control or net correction of IS curves [Bulthuis et al 2008]. It is stated that the TriaC brace significantly alters the predicted natural history of AIS, [Bulthuis et al 2008].



Fig. 11. The TriaC brace

4.6 Sforzesco brace

The Sforzesco brace was developed by Stefano Negrini together with the CPO Gianfranco Marchini in 2004, in Milan, Italy, based on the SPoRT concept (Symmetric, Patient- Oriented, Rigid, Three-Dimensional, Active). The Sforzesco brace combines characteristics of the Risser cast and the Lyon, Chêneau-Sibilla and Milwaukee braces, Figure 12.

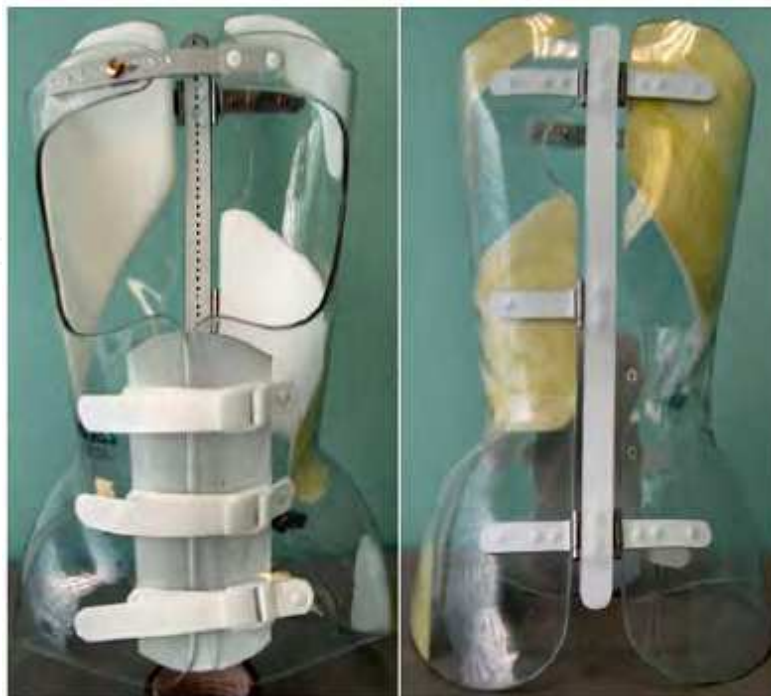

Fig. 12. The Sforzesco brace

Its main action is to push scoliosis from the pelvis up, so to deflex, derotate and restore the sagittal plane (three-dimensional action). For more information please visit <http://isico.it/approach/default.htm>. Results have been published superior to the Lyon brace [Negrini & Marchini 2007] and similar to the Risser cast with less side-effects [Negrini et al 2008a], making of the Sforzesco brace, according to authors, an instrument for worst cases [Negrini et al 2008a, Negrini et al 2009d]. It is based on the efficacy and acceptability correction principles. 1. Efficacy: a) the active brace: the patient is allowed (encouraged) to move freely, b) mechanical efficacy, achieved through pushes, escapes, stops and drivers (the last being a newly developed concept with this brace) c) versatility and adaptability; d) teamwork: MDs, CPOs, PTs patient & family, e) compliance. 2. Acceptability: a) body design and minimal visibility, b) maximal freedom in the Activities of Daily Life, c) assumption of responsibility and d) a cognitive-behavioural approach. The authors reported results on various outcomes (Cobb degrees and aesthetics) [Negrini et al 2009d, Negrini et al 2009b, Negrini et al 2008b, Negrini et al 2009e, Zaina et al 2009].

4.7 Progressive Action Short Brace (PASB)

The Progressive Action Short Brace (PASB) is used since 1976, for the treatment of thoracolumbar and lumbar idiopathic curves. It is a custom-made thoraco-lumbar-sacral orthosis (TLSO) brace of original design, devised by Dr. Lorenzo Aulisa, in Italy, Figure 13. The PASB is only indicated for the treatment of thoraco-lumbar and lumbar curves. The brace is informed by the principle that a constrained spine dynamics can achieve correction of a



Fig. 13. The Progressive Action Short Brace (PASB)

curve, by inverting the abnormal load distribution during growth. The practical application of the biomechanical principles of the PASB is achieved through two operative phases. A plaster cast phase precedes the brace application. At this stage, external forces are exerted to correct the deformity that is elongation, lateral deflection and derotation. This procedure allows obtaining transversal sections represented by asymmetric ellipsis. The finishing touch of the cast establishes the real geometry of the plastic brace. One or sometimes two casts, in relation to the curve rigidity, are manufactured before switching to the custom-

made polypropylene orthosis of the second phase of treatment, [Di Benedetto et al 1981, Aulisa et al 2009]. Aulisa et al, 2009 reported Cobb angle and Perdriole torsion angle readings of the treated thoraco-lumbar and lumbar curves. The pre treatment Cobb mean value was $29,30 \text{ degrees} \pm 5,16 \text{ SD}$ and the initial apical rotation $12,70 \text{ degrees} \pm 6,14 \text{ SD}$. The immediate Cobb correction was $14,67 \pm 7,65 \text{ SD}$ and the apical rotation correction at follow up $8,95 \text{ degrees} \pm 5,82$. Overall curve correction was noted at 94% of patients, curve stabilization in 6% of patients, [Aulisa et al 2009].

5. Conclusions

The treatment of adolescent idiopathic scoliosis (AIS) aims to stop the progression of the deformity and to improve the aesthetic appearance, trunk balance and quality of life [Negrini et al 2006]. Several centers in Europe offer full treatment, ranging from prevention (School screening), bracing with or without the use of exercises and surgery. The study and improvement of braces will ultimately improve the outcomes using the specific braces. As far as the conservative treatment with braces is concerned, there is a variety of outcomes reported in literature, [Rigo et al 2003, Maruyama et al 2003, Negrini et al 2008b, Weiss & Goodall 2008, Dolan & Weinstein 2007]. Poor results can be due to poor bracing and this could be verified through in-brace radiographs to assess the obtained correction. Poor results can also be due to improper management of the patient, a factor that can ultimately influence compliance. The latter has not been yet sufficiently stressed in literature despite its critical role in the efficacy of any treatment [Landauer et al. 2003, Negrini et al. 2009a]. Finally the documentation of all the critical aspects (history, design rationale, indications, biomechanics, outcomes and comparison between braces) of the European braces widely used will enable to draw attention to their pros and cons with the final aim not only to improve the braces, but also to offer a better conservative treatment for scoliosis.

6. Acknowledgements

We thank: Dr Jacques Chêneau and Dr Jean Claude de Mauroy for their consensus on the text, Dr Hans-Rudolf Weiss, Dr Stefano Nergini, and Prof. Lorenzo Aulisa and Dr Angelo Aulisa who read the text and made useful suggestions. We also express our appreciation for allowing the use of figures depicting their braces.

7. References

- Andoniou D, Valavanis J et al: The effectiveness of our bracing system in the conservative treatment of idiopathic scoliosis. *J Bone Joint Surg*, 74-B. Suppl, I, (1992), 86.
- Antoniou D, Valavanis J, Zachariou C, Smyrnis P. 1986 "Dynamic Derotation Brace (DDB). A new aspect for the conservative treatment of Idiopathic Scoliosis" (1986), *Presentation in 21st common meeting of SRS and BSS*.
- Aulisa AG, Guzzanti V, Galli M, Perisano C, Falciglia F and Aulisa L. Treatment of thoraco-lumbar curves in adolescent females affected by idiopathic scoliosis with a progressive action short brace (PASB): assessment of results according to the SRS

- committee on bracing and nonoperative management standardization criteria *Scoliosis*, (2009), 4:21 doi: 10.1186/1748-7161-4-21.
- Bagnall KM, Grivas TB, Alos N, Asher M, Aubin CE, Burwell RG, Dangerfield PH, Edouard T, Hill D, Lou E, et al: The International Research Society of Spinal Deformities (IRSSD) and its contribution to science. *Scoliosis* 2009, 4(1):28.
- Bulthuis GJ, Veldhuizen AG, Z Nijenbanning G. Clinical effect of continuous corrective force delivery in the non-operative treatment of idiopathic scoliosis: a prospective cohort study of the triac-brace *Eur Spine J* 17 (2008), 231-239.
- Castro FP Jr: Adolescent idiopathic scoliosis, bracing, and the Hueter-Volkman principle. *Spine J* 2003, 3(3):180-185.
- Cinnella P, Muratore M, Testa E, Bondente P.G. The Treatment of adolescent idiopathic scoliosis with Cheneau brace: long term outcome. *Oral Presentation at Lyon 2009 SOSORT Meeting*.
- Coillard C, Leroux MA, Badeaux J, Rivard CH: SPINECOR: a new therapeutic approach for idiopathic scoliosis. *Stud Health Technol Inform* 2002, 88:215-217.
- Coillard C, Leroux MA, Zabjek KF, Rivard CH: SpineCor-a non-rigid brace for the treatment of idiopathic scoliosis: post-treatment results. *Eur Spine J* 2003, 12(2):141-148.
- Danielsson AJ, Romberg K, Nachemson AL. Spinal range of motion, muscle endurance, and back pain and function at least 20 years after fusion or brace treatment for adolescent idiopathic scoliosis: a case-control study. *Spine*, 31 (2006), 275-283.
- Danielsson, A.J.; Hasserijs, R.; Ohlin, A. & Nachemson A.L. (2007). A prospective study of brace treatment versus observation alone in adolescent idiopathic scoliosis: a follow-up mean of 16 years after maturity. *Spine*, (2007 Sep 15), Vol.32, No.20, pp. 2198-2207, ISSN 0362-2436
- de Mauroy JC, Fender P, Tato B, Lusenti P, Ferracane G. Lyon brace. *Stud Health Technol Inform*. 135 (2008), 327-340.
- de Mauroy JC, Lecante C, Barral F, Daureu D, Gualerzi S, Gagliano R. The Lyon brace. *Disabil Rehabil Assist Technol*. 3(3) (2008), 139-145.
- de Mauroy JC, Lecante C, Barral F (2011) "Brace Technology" Thematic Series -The Lyon approach to the conservative treatment of scoliosis. *Scoliosis* 2011,
- Di Benedetto A, Vinciguerra A, Pennestri' E, Aulisa L: Biomechanics of Scoliosis Using a New Type of Brace. *Proceedings of the 8th Canadian Congress of Applied Mechanics*, Moncton, N.-B., Canada, 7-12 June, (1981), 785-786.
- Dolan LA, Weinstein SL: Surgical rates after observation and bracing for adolescent idiopathic scoliosis: an evidence based review. *Spine*, 32(19 Suppl) (2007), S91-S100.
- Grivas TB, Vasiliadis E, Chatziargiropoulos T, Polyzois VD, Gatos K: The effect of a modified Boston brace with anti-rotatory blades on the progression of curves in idiopathic scoliosis: aetiologic implications. *Pediatr Rehabil* 2003, 6(3-4):237-242.
- Grivas TB, Vasiliadis E, Malakasis M, Mouzakis V, Segos D: Intervertebral disc biomechanics in the pathogenesis of idiopathic scoliosis. *Stud Health Technol Inform* 2006, 123:80-83.

- Grivas TB, Vasiliadis ES, Rodopoulos G, Bardakos N: The role of the intervertebral disc in correction of scoliotic curves. A theoretical model of idiopathic scoliosis pathogenesis. *Stud Health Technol Inform* 2008a, 140:33-36.
- Grivas TB and Vasiliadis ES. Cosmetic outcome after conservative treatment of idiopathic scoliosis with a dynamic derotation brace. *Stud Health Technol Inform*. 135, 2008b, 387-392.
- Grivas T, Vasiliadis ES, Triantafyllopoulos G, Kaspiris A: A comprehensive model of idiopathic scoliosis (IS) progression, based on the pathobiomechanics of the deforming "three joint complex". *Scoliosis* 2009, 4(Suppl 2):O10.
- Grivas TB, Bountis A, Vrasami A, Bardakos NV (2010) Brace technology thematic series: the dynamic derotation brace. *Scoliosis* 2010, 5:20
- Hopf C, Heine J. Long-term results of the conservative treatment of scoliosis using the Chêneau brace. *Z Orthop Ihre Grenzgeb*. 123(3) (1985), 312-322.
- Kotwicki T, Cheneau J. Biomechanical action of a corrective brace on thoracic idiopathic scoliosis: Cheneau 2000 orthosis. *Disabil Rehabil Assist Technol*. 3(3), (2008), 146-53.
- Kotwicki T, Cheneau J. Passive and active mechanisms of correction of thoracic idiopathic scoliosis with a rigid brace. *Stud Health Technol Inform*. 135 (2008), 320-326.
- Landauer F, Wimmer C, Behensky H: Estimating the final outcome of brace treatment for idiopathic thoracic scoliosis at 6-month follow-up. *Pediatr Rehabil* 6(3-4) (2003), 201-207.
- Lupparelli S, Pola E, Pitta L, Mazza O, De Santis V, Aulisa L: Biomechanical factors affecting progression of structural scoliotic curves of the spine. *Stud Health Technol Inform* 2002, 91:81-85.
- Maruyama T, Kitagawa T, Takeshita K, Mochizuki K, Nakamura K: Conservative treatment for adolescent idiopathic scoliosis: can it reduce the incidence of surgical treatment? *Pediatr Rehabil* 6(3-4), (2003), 215-219.
- Negrini S, Grivas TB, Kotwicki T, Maruyama T, Rigo M, Weiss HR, the members of the Scientific society On Scoliosis Orthopaedic and Rehabilitation Treatment (SOSORT): Why do we treat adolescent idiopathic scoliosis? What we want to obtain and to avoid for our patients. SOSORT 2005 Consensus paper. *Scoliosis*, (2006a), 1:4.
- Negrini S, Marchini G, Tomaello L: The Sforzesco brace and SPoRT concept (Symmetric, Patient-oriented, Rigid, Three-dimensional) versus the Lyon brace and 3-point systems for bracing idiopathic scoliosis. *Stud Health Technol Inform* 2006b, 123:245-249.
- Negrini S, Marchini G. Efficacy of the symmetric, patient-oriented, rigid, three-dimensional, active (SPoRT) concept of bracing for scoliosis: a prospective study of the Sforzesco versus Lyon brace. *Eura Medicophys*. 43(2) (2007), 171- 181.
- Negrini S, Atanasio S, Negrini F, Zaina F, Marchini G. The Sforzesco brace can replace cast in the correction of adolescent idiopathic scoliosis: A controlled prospective cohort study. *Scoliosis*. (2008a) Oct 31;3:15.
- Negrini S, Atanasio S, Zaina F, Romano M, Parzini S, Negrini A. End-growth results of bracing and exercises for adolescent idiopathic scoliosis. Prospective worst-case analysis. *Stud Health Technol Inform*. 135 (2008b), 395-408.

- Negrini S, Grivas TB, Kotwicki T, Rigo M, Zaina F and the international Society on Scoliosis Orthopaedic and Rehabilitation Treatment (SOSORT). Guidelines on "Standards of management of idiopathic scoliosis with corrective braces in everyday clinics and in clinical research": SOSORT Consensus 2008. *Scoliosis* 2009a, 4:2 doi:10.1186/1748-7161-4-2.
- Negrini S, Atanasio S, Fusco C and Zaina F. Efficacy of conservative treatment of adolescent idiopathic scoliosis: end-growth results respecting SRS and SOSORT criteria. *Scoliosis*, 2009b, 4(Suppl 2):O48.
- Negrini S, Atanasio S, Fusco C and Zaina F. Efficacy of bracing immediately after the end of growth: final results of a retrospective case series. *Scoliosis* 2009c, 4(Suppl 2):O49.
- Negrini S, Atanasio S, Fusco C and Zaina F. Efficacy of bracing in worst cases (over 45°) end-growth results of a retrospective case-series. *Scoliosis* 2009d, 4(Suppl 2):O50.
- Negrini S, Atanasio S, Fusco C, Zaina F. Effectiveness of complete conservative treatment for adolescent idiopathic scoliosis (bracing and exercises) based on SOSORT management criteria: results according to the SRS criteria for bracing studies - SOSORT Award 2009 Winner. *Scoliosis*. 2009e Sep 4;4:19.
- Negrini S, Minozzi S, Bettany-Saltikov J, Zaina F, Chockalingam N, Grivas TB, Kotwicki T, Maruyama T, Romano M, Vasiliadis ES. Braces for idiopathic scoliosis in adolescents. *Cochrane Database of Systematic Reviews* 2009f, Issue 1.
- Negrini S, Minozzi S, Bettany-Saltikov J, Zaina F, Chockalingam N, Grivas TB, Kotwicki T, Maruyama T, Romano M, Vasiliadis ES: Braces for idiopathic scoliosis in adolescents. *Cochrane Database Syst Rev* 2010a, 1: CD006850.
- Negrini S, Minozzi S, Bettany-Saltikov J, Zaina F, Chockalingam N, Grivas TB, Kotwicki T, Maruyama T, Romano M, Vasiliadis ES (2010b): Braces for Idiopathic Scoliosis in Adolescents. *Spine (Phila Pa 1976)*. 2010b Jun 1;35(13):1285-93. Review.
- Negrini S and Grivas TB (2010) Introduction to the "Scoliosis" Journal Brace Technology Thematic Series: increasing existing knowledge and promoting future developments *Scoliosis* 2010, 5:2
- Odermatt D, Mathieu PA, Beausejour M, Labelle H, Aubin CE: Electromyography of scoliotic patients treated with a brace. *J Orthop Res* 2003, 21(5):931-936.
- Périer D, Sales De Gauzy J, Sévely A, Hobatho MC. In vivo geometrical evaluation of Cheneau-Toulouse-Munster brace effect on scoliotic spine using MRI method. *Clin Biomech (Bristol, Avon)*. 16(2) (2001), 129-137.
- Richards BS, Bernstein RM, D'Amato CR, Thompson GH: Standardization of criteria for adolescent idiopathic scoliosis brace studies: SRS Committee on Bracing and Nonoperative Management. *Spine* 2005, 30(18):2068-2075, discussion 2076-2067.
- Rigo M, Quera-Salvá G, Puigdevall N, Martínez M. et al 2002 (Retrospective results in immature idiopathic scoliotic patients treated with a Chêneau brace. *Stud Health Technol Inform*. 88 (2002), 241-245.
- Rigo M, Reiter C, Weiss HR: Effect of conservative management on the prevalence of surgery in patients with adolescent idiopathic scoliosis. *Pediatr Rehabil* (2003), 6(3-4):209-214.

- Rigo M, Negrini S, Weiss H, Grivas T, Maruyama T, Kotwicki T: SOSORT consensus paper on brace action: TLSO biomechanics of correction (investigating the rationale for force vector selection). *Scoliosis* 2006, 1:11.
- Rigo MD, Weiss HR 2008 The Chêneau concept of bracing-biomechanical aspects. *Stud Health Technol Inform.* 135 (2008), 303-319
- Rigo M and Gallo D. 2009 A new RSC brace design to treat single long thoracic scoliosis. Comparison of the in-brace correction in two groups treated with the new and the classical models. *Oral Presentation at Lyon 2009 SOSORT Meeting.*
- Rigo M, Villagrasa M and Gallo D (2010a) A specific scoliosis classification correlating with brace treatment: description and reliability. *Scoliosis* 2010a, 5:1
- Rigo M and Grivas TB (2010b) 'Rehabilitation schools for scoliosis' thematic series: describing the methods and results. *Scoliosis* 2010b, 5:27 doi:10.1186/1748-7161-5-27
- Rowe DE. The Scoliosis Research Society Brace Manual. Milwaukee, WI: *Scoliosis Research Society*; (1998), 1-9.
- Sankar WN, Albrektson J, Lerman L, Tolo VT, Skaggs DL: Scoliosis in-brace curve correction and patient preference of CAD/CAM versus plaster molded TLSOs. *J Child Orthop* 2007, 1(6):345-349.
- Schiller JR, Thakur NA, Eberson CP Brace Management in Adolescent Idiopathic Scoliosis. *Clin Orthop Relat Res.* 2010 Mar; 468(3):670-8. Epub 2009 May 30 PMID: 19484317 .
- Smania N, Picelli A, Romano M, Negrini S: Neurophysiological basis of rehabilitation of adolescent idiopathic scoliosis. *Disabil Rehabil* 2008, 30(10):763-771.
- Stokes IA, Burwell RG, Dangerfield PH: Biomechanical spinal growth modulation and progressive adolescent scoliosis - a test of the 'vicious cycle' pathogenetic hypothesis: Summary of an electronic focus group debate of the IBSE. *Scoliosis* 2006, 1:16.
- Stokes IA: Mechanical modulation of spinal growth and progression of adolescent scoliosis. *Stud Health Technol Inform* 2008, 135:75-83.
- The Scoliosis Research Society Brace Manual. Introduction. http://www.srs.org/professionals/bracing_manuals/section1.pdf.
- Thompson GH, Richards BS III: Inclusion and assessment criteria for conservative scoliosis treatment. *Stud Health Technol Inform* 2008, 135:157-163.
- Valavanis J, Bountis A, Zachariou C, Kokkonis D, Anagnostou D, Giahos D, Daskalakis E. Three-Dimensional Brace Treatment for Idiopathic Scoliosis. In: *Three Dimensional Analysis of Spinal Deformities* M D'Amico et al (Eds.) IOS Press, (1995), 337-341.
- Vasiliadis E and Grivas TB. Quality of life after conservative treatment of adolescent idiopathic scoliosis. *Stud Health Technol Inform.* 135 (2008), 409-413.
- Vasiliadis E, Grivas TB, Gkoltsiou K. Development and preliminary validation of Brace Questionnaire (BrQ): a new instrument for measuring quality of life of brace treated scoliotics. *Scoliosis.* (2006) May 20;1:7.
- Vasiliadis E, Grivas TB, Savvidou O, Triantafyllopoulos G. The influence of brace on quality of life of adolescents with idiopathic scoliosis. *Stud Health Technol Inform.* 123 (2006), 352-356.

- Veldhuizen AG. Idiopathic Scoliosis. A Biomechanical and Functional Anatomical Study. *Thesis, University of Groningen*. Groningen, the Netherlands: (1985).
- Veldhuizen AG, Cheung J, Bulthuis GJ, Nijenbanning G. A new orthotic device in the non-operative treatment of idiopathic scoliosis. *Medical Engineering & Physics*, 24 (2002), 209–218.
- Weinstein SL, Dolan LA, Spratt KF, Peterson KK, Spoonamore MJ, Ponseti IV. Health and function of patients with untreated idiopathic scoliosis: a 50-year natural history study. *JAMA*, 289 (2003), 559–567.
- Weinstein SL, Ponseti IV. Curve progression in idiopathic scoliosis. *J Bone Joint Surg Am*. 65 (1983), 447–455.
- Weinstein SL, Zavala DC, Ponseti IV. Idiopathic scoliosis: long-term follow-up and prognosis in untreated patients. *J Bone Joint Surg Am*. 63 (1981), 702–712.
- Weiss HR, Hawes MC (2004): Adolescent idiopathic scoliosis, bracing and the Hueter-Volkman principle. *Spine J* 2004, 4(4):484–485.
- Weiss HR, Werkmann M, Stephan C. Correction effects of the ScoliOlogiC® "Chêneau light" brace in patients with scoliosis. *Scoliosis*. 2007 Jan 26;2:2.
- Weiss HR, Goodall D (2008): The treatment of adolescent idiopathic scoliosis (AIS) according to present evidence. A systematic review. *Eur J Phys Rehabil Med* 44(2) (2008), 177–193.
- Weiss HR, Rigo M (2008). The Chêneau concept of bracing--actual standards. *Stud Health Technol Inform*. 135 (2008), 291–302.
- Weiss HR: Best Practice in conservative scoliosis care. 3rd. edition, Pflaum, Munich, 2010.
- Weiss HR and Werkmann M (2010). "Brace Technology" Thematic Series - The ScoliOlogiC® Chêneau light™ brace in the treatment of scoliosis. *Scoliosis* 2010, 5:19doi:10.1186/1748-7161-5-19.
- Weiss RH 2010: "Brace technology" thematic series - the Gensingen brace™ in the treatment of scoliosis. *Scoliosis* 2010, 5:22
- Wong MS, Cheng JC, Lam TP, Ng BK, Sin SW, Lee-Shum SL, Chow DH, Tam SY: The effect of rigid versus flexible spinal orthosis on the clinical efficacy and acceptance of the patients with adolescent idiopathic scoliosis. *Spine* 2008, 33(12):1360–1365.
- Wong MS, Cheng JC, Wong MW, So SF: A work study of the CAD/CAM method and conventional manual method in the fabrication of spinal orthoses for patients with adolescent idiopathic scoliosis. *Prosthet Orthot Int* 2005a, 29(1):93–104.
- Wong MS, Cheng JC, Lo KH: A comparison of treatment effectiveness between the CAD/CAM method and the manual method for managing adolescent idiopathic scoliosis. *Prosthet Orthot Int* 2005b, 29(1):105–111.
- Zaborowska-Sapeta K, Kowalski IM, Kotwicki T, Protasiewicz-Faldowska H, Kiebzak W.(2011) Effectiveness of Cheneau brace treatment for idiopathic scoliosis: prospective study in 79 patients followed to skeletal maturity. *Scoliosis*. 2011 Jan 25;6(1):2.
- Zaina F, Negrini S, Fusco C, Atanasio S. How to improve aesthetics in patients with Adolescent Idiopathic Scoliosis (AIS): a SPoRT brace treatment according to SOSORT management criteria. *Scoliosis*. (2009) Sep 1;4:18.

Zeh A, Planert M, Klimas S, Hein W, Wohlrab D The flexible Triac™-Brace for conservative treatment of idiopathic scoliosis. An alternative treatment option ? *Acta Orthop. Belg*, 74 (2008), 512-521.

IntechOpen

IntechOpen



Human Musculoskeletal Biomechanics

Edited by Dr. Tarun Goswami

ISBN 978-953-307-638-6

Hard cover, 244 pages

Publisher InTech

Published online 05, January, 2012

Published in print edition January, 2012

This book covers many aspects of human musculoskeletal biomechanics. As the title represents, aspects of forces, motion, kinetics, kinematics, deformation, stress, and strain are examined for a range of topics such as human muscles, skeleton, and vascular biomechanics independently or in the presence of devices. Topics range from image processing to interpret range of motion and/or diseases, to subject specific temporomandibular joint, spinal units, braces to control scoliosis, hand functions, spine anthropometric analyses along with finite element analyses. Therefore, this book will be valuable to students at introductory level to researchers at MS and PhD level searching for science of specific muscle/vascular to skeletal biomechanics. This book will be an ideal text to keep for graduate students in biomedical engineering since it is available for free, students may want to make use of this opportunity. Those that are interested to participate in the future edition of this book, on the same topic, as a contributor please feel free to contact the author.

How to reference

In order to correctly reference this scholarly work, feel free to copy and paste the following:

Theodoros B. Grivas (2012). European Braces for Conservative Scoliosis Treatment, Human Musculoskeletal Biomechanics, Dr. Tarun Goswami (Ed.), ISBN: 978-953-307-638-6, InTech, Available from: <http://www.intechopen.com/books/human-musculoskeletal-biomechanics/european-braces-for-conservative-scoliosis-treatment>

INTECH
open science | open minds

InTech Europe

University Campus STeP Ri
Slavka Krautzeka 83/A
51000 Rijeka, Croatia
Phone: +385 (51) 770 447
Fax: +385 (51) 686 166
www.intechopen.com

InTech China

Unit 405, Office Block, Hotel Equatorial Shanghai
No.65, Yan An Road (West), Shanghai, 200040, China
中国上海市延安西路65号上海国际贵都大饭店办公楼405单元
Phone: +86-21-62489820
Fax: +86-21-62489821

© 2012 The Author(s). Licensee IntechOpen. This is an open access article distributed under the terms of the [Creative Commons Attribution 3.0 License](https://creativecommons.org/licenses/by/3.0/), which permits unrestricted use, distribution, and reproduction in any medium, provided the original work is properly cited.

IntechOpen

IntechOpen