

We are IntechOpen, the world's leading publisher of Open Access books Built by scientists, for scientists

6,900

Open access books available

185,000

International authors and editors

200M

Downloads

Our authors are among the

154

Countries delivered to

TOP 1%

most cited scientists

12.2%

Contributors from top 500 universities



WEB OF SCIENCE™

Selection of our books indexed in the Book Citation Index
in Web of Science™ Core Collection (BKCI)

Interested in publishing with us?
Contact book.department@intechopen.com

Numbers displayed above are based on latest data collected.
For more information visit www.intechopen.com



Cardiovascular Implantable Cardioverter Defibrillator-Related Complications: From Implant to Removal or Replacement: A Review

Mariana Parahuleva

*University Hospital of Giessen and Marburg/Location Giessen,
Germany*

1. Introduction

Implantable cardioverter defibrillators (ICDs) use has increased exponentially during the past decade. However, these devices are associated with complications related to the implantation procedure itself and morbidity caused by the adverse functioning of the components comprising the system. In 2003, 10.8% of patients undergoing cardioverter-defibrillator implantation experienced one or more early complications (Reynolds et al., 2006). Acute implantation complication rates range from 3% to 7%. For this reason a controlling in respect to the technology, indications for use, personnel involved in monitoring and the frequency and types of monitoring events is needed (Wilkoff et al., 2008).

The European Community (EN540, European Standard, 1993) and the International Standards Organization (ISO 14155, International Standard, 1996) have provided standards for adverse events observed during trials with implantable medical devices, defining an adverse event as any undesirable clinical occurrence in a subject whether it is considered to be device related or not. These standard criteria underwent sweeping changes in the past time. The first and most evident change is the standard's new title: "ISO 1415: Clinical investigations of medical devices in human subjects – good clinical practices", harmonized with the ICH E6 GCP guidelines (Stark et al., 2011). Few studies have systematically examined the predictors of complications in this population using multivariable analysis. These data suggest that complications are driven by the 3 major components that contribute to risk: device, physician, and patient factors. This may be most relevant for patients with complex device systems, particularly heart failure patients (Curtis et al., 2009; Al-Khatib et al., 2008). Even though prospective studies defining the risk associated with ICD implantation and optimal peri-, intra- and postoperative management to ICDs are needed. Therefore the aim of this review was to report the incidence of adverse events during the initial months after pectoral implantation or replacement of an ICD system with a transvenous lead system. The usual complication including implant procedure-related complications, ICD generator-related complications, as well as lead-related complications will be discussed. This review, however, limits discussion to surgical complications. In addition, it will be reviewed the relevant clinical trials as well as prescription guidelines, because the increasing clinical relevance of this topic is the reason for the future formulation of recommendations by an interdisciplinary working group.

2. Implant procedure-related complications

The early mortality effects of implant procedure-related complications may be the direct “mechanical” effect of the procedure, such as infection, pneumothorax, or perforation, that are not well tolerated. These risks probably are largely related to procedural complexity, reflected in system configuration risk in procedural volume, and operator expertise. The second contributor is the patient; the physiological duress of even minor surgery may exacerbate comorbidities, particularly heart failure, which contributes significantly to reduced survival.

2.1 Venous access related complications

Transvenous non-thoracotomy lead systems are available and are usually implanted safely and with a high success rate by an electrophysiologist and a surgeon. The axillary and subclavian vein puncture are the standard approach in ICD implantation. However, obtaining venous access for defibrillator implantation can be complicated by vascular injury, subclavian arteriovenous fistula and/or pneumothorax or hemothorax. No-puncture strategy using the cephalic cut-down technique obviates the complication in the majority of cases and improves the safety of device implantation. Thus, the subclavian route of insertion resulted in more complications than the cephalic vein route (Kron, 2003). In addition, conventional transvenous approaches for ICD lead placement are not possible in some patients with limited vascular access and/or tricuspid valve dysfunction. On the other site transvenous ICD lead failure rates are significant and their occurrence increases with time from implant. Therefore it was recently designed an entirely subcutaneous ICD system to eliminate the need for venous access and their complication (Bardy et al., 2010).

2.1.1 Subclavian arteriovenous fistula

Subclavian arteriovenous fistula is a rare and uncommon complication of ICD implantation and it could be successful closed using an Amplatzer vascular occlusion plug (Hess et al., 2010).

2.1.2 Pneumothorax

Pneumothorax is usually a complication of subclavian venous access and may be detected during the procedure or delayed until 48 h after implantation (Aggarwal et al., 1995). This complication is a problem in unexperienced operators and is directly related to the difficulty of the subclavian puncture. Often is the pneumothorax asymptomatic, but uncommonly occurs a tension pneumothorax with hemodynamic and clinical improvement, which needs immediately placement of chest tube. The diagnosis of pneumothorax was confirmed by chest x-ray. Pneumothorax due to perforation of the atrial lead through the wall of the atrial appendage has already been reported (Rosman et al., 2006). Perforation of the right ventricle with or without pericardial effusion is also well recognized (Gondi et al., 1981). However, isolated pneumopericardium reported as an exclusive complication of a cardiac resynchronisation therapy (CRT) implantation is very uncommon. We have previously reported pneumothorax recognised days after CRT implantation and concomitant pneumopericardium secondary as a late complication of a persisting connection between the pericardium and the pleura parietalis as consequence of the former aortal-coronary surgery, three years after coronary artery bypass graft surgery (CABG) (Fig.1, Parahuleva et al., 2009).

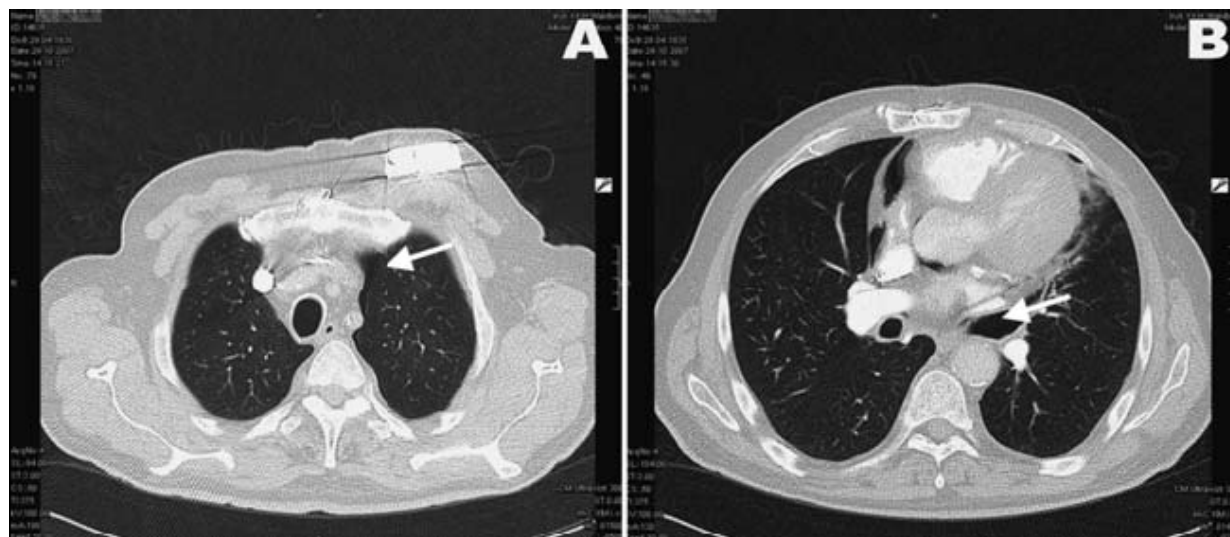

Fig. 1. Computed tomography (CT) scan of the thorax showing (A) left-sided pneumothorax with 30% reduction in lung volume and (B) moderate- sized pneumopericardium and pleuromediastinum (from Parahuleva et al., 2009).

2.1.3 Hemothorax

Hemothorax results most commonly from an arterial puncture and cannulate the artery with the intraducer, a situation that should indicate vascular surgical removal. This complication could also occur after right ventricular (RV) lead perforation beyond the cardiac border into the pleural space (Merla et al., 2007). The diagnosis of hemothorax and suspecting of RV perforation in patients with ICD implantation presenting with recurrent chest pain and/or pleural effusion is important, because it is potentially life threatening complication. Massive hemothorax may develop after placement of an ICD in patients who received postoperative anticoagulants (see also 2.2.1 ICD Hematoma). The perioperative management of anticoagulation in patients who are having implantation of a pacemaker or ICD is a common clinical problem in which best clinical practise is not established, but a strategy involving postoperative bridging with intravenous heparin confers a high risk for bleeding whereas perioperative continuation of a oral anticoagulation appears to reduce the risk for bleeding (see also 2.2.1 ICD Hematoma).

2.1.4 Venous thrombosis and superior vena cava syndrome (SVCS)

Significant vein occlusion was found in 25% of patients after placement of ICD (Lickfett et al., 2004) and in 27% of patients after pacemaker implantation (Antonelli et al., 1989). Subclavian venous obstruction or thrombosis following transvenous device implantation rarely cause clinical problems and become a significant challenge, when lead revision or device upgrade is indicated (Wilkoff et al., 2004, van Rooden et al., 2004). The reasons for these venous complications such as stenosis, occlusions, and superior vena cava syndrome have been discussed. The study has suggested that intravenous lead infection promotes local vein stenosis (Korkeila et al., 2009). Another found that the presence of a temporary wire before implantation is associated with an increased risk of stenosis (Haghjoo et al., 2007). Despite many years of experience with transcutaneous implanted intravenous pacing systems, it was unable to identify clear risk factors which lead to venous stenosis (Bar-Cohen et al., 2006). Neither the hardware (lead size, number and material) nor the access site

choice (cephalic cut down, subclavian or axillary puncture) appears to affect rate of venous complications. A few factors were proposed as predictors of severe venous stenosis/occlusion: presence of multiple pacemaker leads (compared to a single lead), use of hormone therapy, personal history of venous thrombosis, new onset of atrial fibrillation, the presence of temporary wire before implantation, previous presence of a pacemaker (ICD as an upgrade) and the use of dual-coil leads (Bulur et al., 2010). A variety of different strategies to overcome the venous obstruction have been reported: contralateral LV lead placement (Fox, 2006), innominate vein as an alternative venous access (Aleksic et al., 2007), internal jugular vein approach (Bosa-Ojeda et al., 2007), opening an occluded subclavian vein and venoplasty (Worley et al., 2007), surgical approaches with the use of minimally invasive procedures (Jaroszewski et al., 2009), supraclavicular vein approach (Antonelli et al., 2010), use of a tunneling technique (Kim et al., 2010) or iliofemoral approach by patients with occluded superior venous access (Allred et al., 2008).

Anticoagulant therapy (for other reasons than pacemaker lead) seemed to have protective antithrombotic effect (Pavia et al., 2001), but the effect of prophylactic anticoagulant treatment after pacemaker implantation have not found positive results (Goto et al., 1998). Furthermore, it was found that oral anticoagulant treatment did not differ from antiplatelet treatment in respect to protection from venous obstruction occurrence (Haghjoo et al., 2007). The patients who are candidates for multiple pacemaker leads implantation have more risk factors for venous obstruction than other device patients. These patients should be evaluated with venography before lead revision and/or device upgrade procedures. In addition, large studies are needed to investigate whether anticoagulant or antiplatelet treatment could prevent venous obstruction.

2.2 ICD pocket related complications

2.2.1 ICD hematoma

Pocket hematoma is an acute, relatively common complication. The use of electrocautery and portable drainage device for 24 hours after implantation are useful to minimize pocket hematoma. The hematomas are managed usually conservatively. Expanding in size of hematoma, tense or painful in the ICD pocket are requiring re-operation to evacuate the hematoma (Belott et al., 2000). The risk of pocket hematoma is increased in anticoagulated patients. Dual antiplatelet therapy and periprocedural heparin appears to be associated with significantly increase risk of bleeding complications at the time of pacemaker or ICD implantation (Al-Khadra et al., 2003; Giudici et al., 2004). The study of Tompkins (Tompkins, 2010) evaluated patients (n=1388) undergoing permanent pacemaker and ICD implantation over a 3-year period to determine if patients with antiplatelet or anticoagulation therapy required normalization of coagulation factors in the periprocedural period. A significant bleeding complication was defined as need for pocket exploration or blood transfusion, hematoma requiring pressure dressing or change in anticoagulation therapy, or prolonged hospitalization. It has been shown that continuation of warfarin was associated with a trend toward increased bleeding complications when compared with controls, even when held to allow the international normalized ratio (INR) to decrease below 1.5 (Fig.2). There was no statistical difference in bleeding risk between patients continued on warfarin with an INR \geq 1.5 and patients who had warfarin withheld until the INR was normal. The use of periprocedural heparin (enoxaparin or unfractionated heparin) and dual antiplatelet therapy increase the risk of bleeding complication (Fig.2).

Appropriate periprocedural management requires a thorough understanding of indications for antiplatelet or anticoagulation medications and assessing the risks of thromboembolic versus bleeding complications (Douketis et al., 2008). Brake off of antiplatelet or anticoagulation medications before device implantation could be possible in patients at low risk for thromboembolic events. Patients at high risk for thromboembolic events should continue warfarin throughout the periprocedural phase and should need bridging anticoagulation with therapeutic dose heparin. Operating with oral anticoagulation is the best alternative, because device implantation or replacement without withdrawing of oral anticoagulants and with an INR of about 2.0 is safe and was not associated with an increase of the hemorrhagic risk.

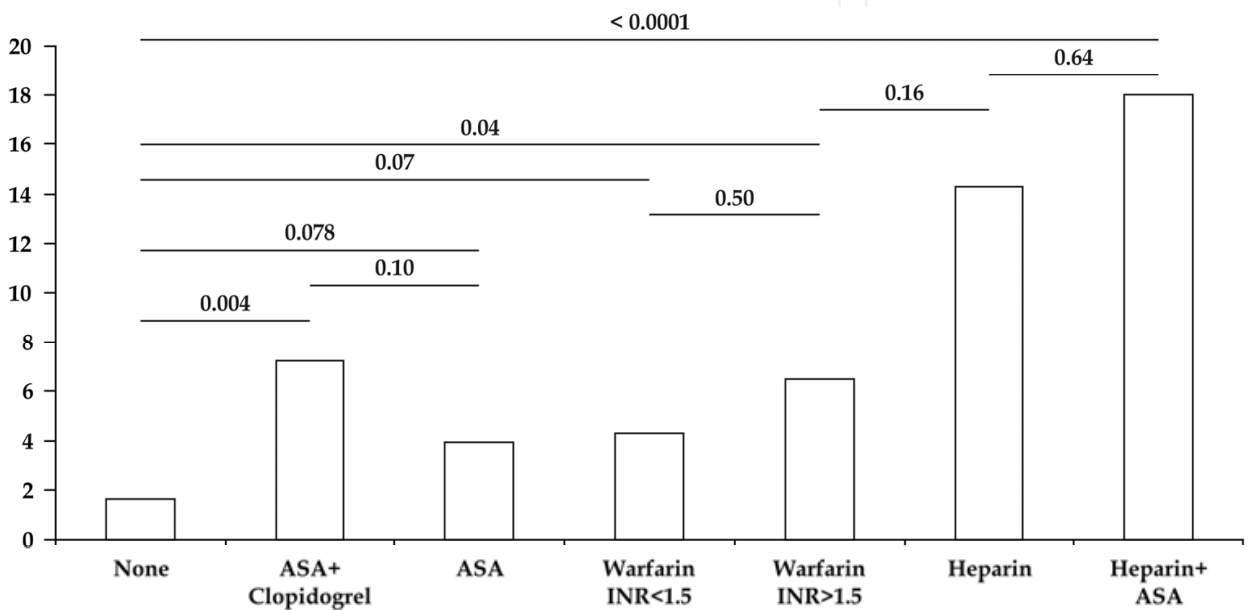


Fig. 2. Effect of antiplatelet and anticoagulation agents on bleeding complication in patients after device implantation (modified from Tompkins et al., 2010).

2.2.2 ICD infections

Device system infection is a serious complication and tended to occur within 1 year after implantation, or as late onset lead endocarditis (Mangram et al., 1999). The physical manifestations range from mild symptoms with local reaction to fulminant sepsis. Failure to use perioperative antibiotics is a predictor of system infection and ICD system infection ranges from 0.13 to 12.6% (Mela et al. 2001). Repeated operative procedures after the first device implantation were associated with increased risk of device infection (Margey et al., 2010). Female sex, older age, and preoperative antibiotics given at the first device implantation were associated with a lower risk of later device infection (Johansen et al., 2011). End-stage renal disease markedly increases bleeding and device-related infections (Tompkins, 2011). When infection is present, complete device removal with transvenous lead extraction must be followed by antimicrobial therapy. Removal of the entire pacing system is crucial for the treatment of lead endocarditis (see also 3.2. Lead extraction-related complication). The development of laser-assisted extraction techniques for chronically implanted pacemaker and defibrillator leads has reduced the need for open surgical removal (Gaca et al., 2009).

2.2.3 ICD wound dehiscence and erosion

Wound healing is a major deterrent in the post-surgical course of patients after device implantation. Insufficient closure may lead to serious complications with pocket infections leading to the device's explantation. Therefore is the skin suture approach most important for the wound healing. The absorbable intracutaneous suture is frequently used to close surgical incisions and a form of skin adhesive surgical tape is commonly also placed over the wound. It was shown that early adverse events as insufficient closure, major and minor bleeding, pocket haematoma, erythema, incrustation, dehiscence, keloid, and explantation due to infection occurred significantly more often in the patients with skin adhesive in comparison to absorbable intracutaneous suture (Spencker et al., 2011).

Skin erosion is possible when the subcutaneous pocket at the time of initial implantation is too small or too superficial and the device makes undue tension on the overlying skin. The skin erosion is also associated with potential pocket infection and sub-pectoral placement after complete explantation of the device-lead system is usually advised (Gold et al., 1996).

2.2.4 Chronic pain

Chronic pain will usually manifest an obvious infection. An allergy to nickel/cobalt and chronic painful eczema could mimic a pocket infection (Citerne et al., 2011). Alternatively, mechanical trauma from the device location adjacent to chest wall may also be the reason for chronic pain. In this situation device relocation revision may be advised.

2.2.5 Twiddler's syndrome

Twiddler's syndrome is a rare complication well described in patients with subcutaneous permanent pacemakers, but is unusual in patients with CRT-D, which typically presents with device malfunction and inappropriate shocks. The condition occurs when the patient, either consciously or unconsciously, rotates the implanted pacemaker in its pocket, resulting in torsion, dislodgement, and often fracture of the pacing lead (Veltri et al., 1984). The placement of the pulse generator in a sub-pectoral position may help prevent Twiddler's syndrome.

2.3 Perioperative ICD implantation related-complications

2.3.1 Perioperative death

A serious complication such as perioperative death is rare in patients with transvenous device implantation. Elevated BNP level was significantly associated with increased risk of cardiac arrest periprocedural in patients received ICD implants (Wei et al., 2011) and studies are needed to investigate whether reducing preprocedural BNP could manage the procedural risk of cardiac arrest or in-hospital mortality. Although the benefit of ICD therapy in patients with hypertrophic cardiomyopathy (HCM) at risk for sudden cardiac arrest is well established, there may be a higher risk for device complications and inappropriate shocks (Lin et al., 2009).

2.3.2 Strokes

The most patients with perioperative strokes after device implantation had chronic atrial fibrillation without prior oral anticoagulation. Therefore, it would be routinely performed transesophageal echocardiography prior to device implantation in patients lacking maintained anticoagulation despite increased risk for cardiac thromboembolism, e.g., atrial

fibrillation, severely reduced left ventricular function, ventricular aneurysms, and intracardiac thrombi. In the presence of intracardiac thrombi is not recommended to perform intraoperative defibrillation threshold testing (Healey et al., 2010).

2.4 Defibrillation testing-related complications

Defibrillation threshold (DFT) testing has traditionally been an integral part of ICD implantation. However, recent publications question the necessity of DFT testing during implantation, because of compelling evidence that it predicts or improves outcomes (Strickberger et al., 2004; Russo et al., 2005; Gula et al., 2008). DFT testing may now be the highest acute risk component of ICD implantation, quoting the effectiveness of the current generation of devices and the rate of complications associated with testing. The recently published experience revealed some serious testing-related complications: sudden cardiac death (SCD), spontaneous episodes of ventricular arrhythmia (sustained ventricular tachycardia, VT, and strokes (Birnie et al., 2008). Physicians favored performance of defibrillation testing in patients who are at lower risk of defibrillation testing-related complications and in those receiving amiodarone (Ruso et al., 2005). Lower left ventricular ejection fraction (LVEF) had a borderline predictive value for high DFT. The association between left ventricular function and failure of defibrillation was examined in the Post Implant Testing Study (PITS). As systolic function declined, there was a trend to a higher failure rate, which was not statistically significant (Brodsky et al., 1999). Other studies suggest that left ventricular mass or volumes are more predictive than ejection fraction to predict DFTs (Hodgson et al., 2002). The rate of complications associated with intraoperative DFT testing appears small, even allowing for the underestimation of its true rate with the current study methodology (Birnie et al., 2008; Healey et al., 2010). These slight but measurable risks must be considered when assessing the risk-benefit ratio of the procedure. The serum markers NSE, PS1B rise significantly by the ICD-test as an expression of neuronal damage in patients with poor LVEF also significantly more (Prull et al., 2011). In the primary prophylaxis ICD indication ICD-test must be therefore a critical indication. Additional data from ongoing prospective ICD registries and/or clinical trials are required to clarify whether routine DFT testing may be safely abandoned leading to a revision of current guidelines.

3. Lead-related complications

3.1 Lead Implantation-related complications

3.1.1 Lead dislocation/malposition

Device leads are placed routinely with few notable complications. The lead dislocation occurs very early postoperative (usually 24–48 hours) but may occur up to 3 months after implantation. Adverse changes in sensing and pacing thresholds compared to implant values should prompt consideration of this complication and lead repositioning or replacement is required. Further management to avoid recurrence of this complication is essential and the follow-up of devices early postoperative will help to minimize her incidence.

The lead malposition is diagnosed by unacceptable pacing, sensing, and/or defibrillation thresholds. The placement of leads into the left ventricle is a rare complication of transvenous device implantation and may be occur by intracardiac abnormality such as a ventricular septal defect. This malpositioning places the patients at risk for thromboembolic

events, including cerebrovascular insults (37% based on the reported cases of left ventricular leads, Van Gelder et al., 2000) and anticoagulation with warfarin is recommended. The median sternotomy or thoracotomy are the usual operative technique for the extraction of left ventricular lead. It was also reported a successful percutaneous removal of a left ventricular lead in patients who had been anticoagulated and had no evidence of thrombus on the lead (Trohman et al., 1991) or a minimally invasive technique for left ventricular lead extraction (Stouffer et al., 2010).

Diaphragmatic stimulation is another possible manifestation of lead malposition. It is usually due to direct phrenic nerve stimulation from the right or left ventricular lead.

Location of the left ventricular pacing lead is one of the determinants for success of cardiac resynchronization therapy (CRT). The implantation procedure includes several challenging technical issues and strongly depends on the highly variable anatomy of the coronary sinus. The optimal position of the LV pacing lead is the site of latest activation in the left ventricle, which enables effective resynchronization. Furthermore, phrenic nerve stimulation (PNS) occurs in 37% of CRT patients at implant or follow-up. To address this common problem, the manufacturers of CRT devices offer a range of configurations aimed at preventing PNS. A quadripolar LV lead has recently been designed which provides more programming configurations and may help to overcome high thresholds and PNS (Forleo GB et al., 2010; Shetty AK et al., 2011). There are several publications concerning quadripolar electrode implantation which show elimination of PNS, but the optimal LV pacing configuration should be determined on the basis of individual patient testing. We report a case in which the use of the quadripolar left ventricular lead pacing depended on the highly variable anatomy of the coronary sinus and resulted in the occurrence of stable PNS at 3- and 6-months follow-up. In this case report, even 10/10 configurations could not prevent occurrence of PNS (Parahuleva et al., 2011)

3.1.2 Lead fractures

Most dislodgements tended to occur in the 3 months following implantation, whereas lead fractures continued to occur throughout follow-up. Fractures of ICD leads may occur 5 years after the implantation and coaxial polyurethane leads have a particularly high incidence of failure. However, there are no parameters that can be used to predict lead failure during follow-up (Kitamura et al., 2006). Although implantation techniques and generator technology continue to evolve, the occurrence of lead fractures and the need for premature system revision supports the practice of close routine ICD system surveillance.

3.1.3 Lead perforation and cardiac tamponade

The device lead may perforate the atria, ventricle or coronary sinus during the implant procedure. Atrial leads perforated more frequently than ventricular leads, and ventricular ICD leads perforated more frequently than ventricular pacemaker leads. This complication almost always occurs after active fixation of pacing and ICD leads and may be associated with delayed right ventricular perforation and bleeding in to the pericardial space. Asymptomatic perforation is a common phenomenon with subacute or delayed perforation and without clinical signs (inappropriate shock, syncope, abdominal pain, mammary hematoma, diaphragm stimulation, and chest pain) of lead perforation at the time of the procedure or perforation of the right ventricle diagnosed more than 5 days (sometimes more than 6 months) after implantation. However, dyspnea with pericardial

effusion may occur requiring emergency pericardial drainage by cardiac tamponade. The risk of cardiac tamponade is increased in anticoagulated patients. Subacute ventricular perforation is a rare but potentially life threatening complication of lead implantation and the diagnosis could be emergency confirmed by chest x-ray, echocardiography, or computed tomography. A lead perforation rate is low and there were no statistically significant differences in perforation or dislodgement rates between manufacturers or lead models (Turakhia et al., 2009).

3.2 Lead extraction-related complication

Transvenous lead extraction is an essential component of management of infections and other device-related complications (Smith et al., 2008). Despite the development of more efficient and safer tools, the procedure continues to be associated with risk of major complications such as venous or myocardial damage, tamponade, and even death (Field et al. 2007). It has also been recognized that chronic leads (more than 1 year) occasionally break during the process of extraction and extraction of a fractured lead from the right ventricle is sometimes difficult.

Thus, implantation of an additional device lead versus extraction of the defective lead and implantation of a new one is one possible therapeutic approach in cases of a defective lead. Implantation of an additional or replacement of the lead in case of high-voltage pace/sense lead failure is statistically not different concerning mortality and morbidity (Wollmann et al., 2007). There are no predictors for further lead defects. Implantation of an additional lead should not be recommended in young patients. Predictors for death were an age over 70 years and renal insufficiency.

4. Pacing/sensing-related complications

Pacing/sensing-related and ICD-specific complications (oversensing, undersensing, exit block, pacemaker-mediated tachycardia, ineffective and inappropriate therapy) detected during routine follow-up visits are relatively rare. Recommended routine follow-up intervals for ICD patients are range from 3 to 6 months and 6 month follow-up interval appear to be the safest (Senges-Becker et al., 2005). In addition, inappropriate pacing/sensing parameters of right ventricular lead implanted at the right ventricular apex could occur in the perioperative period. An alternate location for implantation in these situations is the right ventricular outflow tract. However, active-fixation of right ventricular leads should be considered to limit the risk of electrode dislodgment (Lubinski et al. 2000).

5. Complications after ICD replacement and/or upgrade procedures

Device replacement is generally technically less challenging than a new implant but is associated with complications that may place the patient at substantial risk, including system infection requiring complete extraction (Gould et al., 2008; Moore et al., 2009). Patients who undergo ICD replacement or upgrade procedures often have significant cardiac conditions and noncardiac comorbidities and may therefore be at higher risk of developing complications from the procedure than has been demonstrated in randomized trials (Poole et al., 2010; Santini et al., 2006). The Canadian Heart Rhythm Society has previously reported on a retrospective series that involved 533 ICDs that were replaced because of an advisory, which demonstrated an overall complication rate of 8.1% (Gould et

al., 2006). This unexpectedly high complication rate was associated with major complications in 2.0% of patients, including death in 2 patients. A voluntary German ICD registry focusing on new implants reported rates of specific complications and found that pocket hematoma, chronic pain, and lead and device dislodgments leading to operative revisions were the most common events, with reoperation in 3.0% (Gradaus et al., 2003). Recently, the REPLACE registry reported a 4.0% complication rate in 1031 patients undergoing generator replacement and 15.3% in 713 patients with replacement and a lead addition (Poole et al., 2010). This prospective registry reported that ICDs and particularly CRT ICDs were associated with a greater risk of complications, consistent with the current study that found a higher complication in upgrade and CRT patients. However, identifying factors contributing to complications may permit identification of high-risk individuals that warrant incremental monitoring and therapy to attenuate risk. Recently, a prospective, multicenter, population-based registry of all ICD patients at 18 centers in Ontario, Canada showed, that risk factors associated with complications after ICD replacement, include the presence of angina, antiarrhythmic therapy, increased number of previous procedures, and low implanter volume (Krahn et al., 2011). Generator change is a higher risk procedure than new implants. This suggests that clinicians and researchers should consider strategies to minimize the need for device replacement, particularly because most devices are implanted for primary prevention.

6. Conclusion

Cardiovascular implantable cardioverter defibrillator-related complications are rare in patients with transvenous device implantation. The cardioverter-defibrillator can be life saving, but its potential complications could be significant and enormous. For this reason, the recognition of potential cardiovascular implantable cardioverter defibrillator-related complications is essential for advances in ICD technology and management strategies to avoid their recurrence and will assist and educate clinicians who care for an increasing number of patients with cardiovascular devices to minimize the incidence of this complication.

7. Acknowledgment

Very special thanks to Mr Svetozar Borislavov, for his loving support and understanding during my scientific and medical researches in past few years. His encouragement was the reason to complete this book chapter and I want to dedicate it to him.

8. References

- Aggarwal RK, Connelly DT, Ray SG, Ball J, Charles RG. Early complications of permanent pacemaker implantation: no difference between dual and single chamber systems. *Br Heart J*, 1995, 73: 571-5.
- Aleksic I, Kottenberg-Assenmacher E, Kienbaum P, Szabo AK, Sommer SP, Wieneke H et al. The innominate vein as an alternative venous access for complicated implantable cardioverter defibrillator revisions. *PACE*, 2007, 30:957-60.
- Al-Khadra AS. Implantation of pacemakers and implantable cardioverter defibrillators in orally anticoagulated patients. *Pacing Clin Electrophysiol*, 2003, 26:511-4.

- Al-Khatib SM, Greiner MA, Peterson ED, Hernandez AF, Schulman KA, Curtis LH. Patient and implanting physician factors associated with mortality and complications after implantable cardioverter-defibrillator implantation, 2002–2005. *Circ Arrhythm Electrophysiol*, 2008, 1:240–249.
- Allred JD, McElderry HT, Doppalapudi H, Yamada T, Kay GN. Biventricular ICD implantation using the iliofemoral approach: providing CRT to patients with occluded superior venous access. *Pacing Clin Electrophysiol*, 2008 Oct;31(10):1351–4.
- Antonelli D, Turgeman Y, Kaveh Z, Artoul S, Rosenfeld T. Short term thrombosis after transvenous permanent pacemaker insertion. *PACE*, 1989, 12:280–2.
- Antonelli D, Freedberg NA, Turgeman Y. Supraclavicular vein approach to overcoming ipsilateral chronic subclavian vein obstruction during pacemaker-ICD lead revision or upgrading. *Europace*, 2010 Nov, 12(11):1596–9.
- Bar-Cohen Y, Berul CI, Alexander ME, Fortescue EB, Walsh EP, Triedman JK, Cecchin F. Age, size, and lead factors alone do not predict venous obstruction in children and young adults with transvenous lead systems. *J Cardiovasc Electrophysiol*. 2006 Jul, 17(7):754–9.
- Bardy GH, Smith WM, Hood MA, Crozier IG, Melton IC, Jordaens L, Theuns D, Park RE, Wright DJ, Connelly DT, Fynn SP, Murgatroyd FD, Sperzel J, Neuzner J, Spitzer SG, Ardashev AV, Oduro A, Boersma L, Maass AH, Van Gelder IC, Wilde AA, van Dessel PF, Knops RE, Barr CS, Lupo P, Cappato R, Grace AA. An entirely subcutaneous implantable cardioverter-defibrillator. *N Engl J Med*, 2010 Jul 1, 363(1):36–44.
- Belott P, Reynolds D. Permanent pacemaker and implantable cardioverterdefibrillator implantation. In Ellenbogen K, Kay G, Wilkoff B (Eds): Clinical cardiac pacing and defibrillation. *WB Saunders*, Philadelphia: Saunders; 2000, 573–644.
- Birnie D, Tung S, Simpson C, Crystal E, Exner D, Ayala Paredes FA, et al. Complications associated with defibrillation threshold testing: the Canadian experience. *Heart Rhythm*, 2008, 5:387–90.
- Bosa-Ojeda F, Bethencourt-Munoz M, Vergara-Torres M, Lara-Paaron A, Rodriguez-Gonzales A, Marrero-Rodriguez F. Upgrade of a pacemaker defibrillator to a biventricular device: the internal jugular vein approach in a case of bilateral subclavian veins occlusion. *J Interv Card Electrophysiol*, 2007, 19:209–11.
- Brodsky CM, Chang F, Vlay SC. Multicenter evaluation of implantable cardioverter defibrillator testing after implant: the Post Implant Testing Study (PITS). *Pacing Clin Electrophysiol*, 1999, 22:1769–76.
- Bulur S, Vural A, Yazıcı M, Ertas G, Özhan H, Ural D. Incidence and predictors of subclavian vein obstruction following biventricular device implantation. *J Interv Card Electrophysiol*, 2010 Dec, 29(3):199–202, Epub 2010 Oct 2.
- Citerne O, Gomes S, Scanu P, Milliez P. Painful Eczema mimicking pocket infection in a patient with an ICD: a rare cause of skin allergy to nickel/cobalt alloy. *Circulation*, 2011 Mar 22, 123(11):1241–2.
- Curtis JP, Luebbert JJ, Wang Y, Rathore SS, Chen J, Heidenreich PA, Hammill SC, Lampert RI, Krumholz HM. Association of physician certification and outcomes among patients receiving an implantable cardioverter-defibrillator. *JAMA*, 2009, 301:1661–1670

- Douketis JD, Berger PB, Dunn AS, Jaffer AK, Spyropoulos AC, Becker RC, Ansell J; American College of Chest Physicians. The perioperative management of antithrombotic therapy: American College of Chest Physicians Evidence-Based Clinical Practice Guidelines (8th Edition). *Chest*, 2008 Jun, 133(6 Suppl):299S-339S.
- EN540, European Standard. *Clinical Investigation of Medical Devices for Human Subjects*, 1993, Brussels, Belgium: European Committee for Standardization.
- Field ME, Jones SO, Epstein LM. How to select patients for lead extraction. *Heart Rhythm* 2007;4:978-85.
- Forleo GB, Della Rocca DG, Papavasileiou LP, Di Molfetta A, Santini L, Romeo F. Left ventricular pacing with a new quadripolar transvenous lead for CRT: early results of a prospective comparison with conventional implant outcomes. *Heart Rhythm*, 2010, Sep 28.
- Fox DJ, Petkar S, Davidson NC, Fitzpatrick AP. Upgrading patients with chronic defibrillator leads to a biventricular system and reducing patient risk: contralateral LV lead placement. *PACE*, 2006, 29:1025-7.
- Gaca JG, Lima B, Milano CA, Lin SS, Davis RD, Lowe JE, Smith PK. Laser-assisted extraction of pacemaker and defibrillator leads: the role of the cardiac surgeon. *Ann Thorac Surg*. 2009 May;87(5):1446-50; discussion 1450-1.
- Giudici MC, Barold SS, Paul DL, Bontu P. Pacemaker and implantable cardioverter defibrillator implantation without reversal of warfarin therapy. *Pacing Clin Electrophysiol*, 2004, 27:358-60.
- Gold MR, Peters RW, Johnson JW, Shorofsky SR. Complications associated with pectoral cardioverter-defibrillator implantation: comparison of subcutaneous and submuscular approaches. Worldwide Jewel Investigators. *J Am Coll Cardiol*, 1996 Nov 1, 28(5):1278-82.
- Gondi B, Nanda NC. Real-time, two-dimensional echocardiographic features of pacemaker perforation. *Circulation*, 1981, 64: 97-106.
- Goto, Y., Abe, T., Sekine, S., & Sakurada, T. (1998). Long-term thrombosis after transvenous permanent pacemaker implantation. *Pacing and Clinical Electrophysiology*, 21(6), 1192-1195.
- Gould PA, Gula LJ, Champagne J, Healey JS, Cameron D, Simpson C, Thibault B, Pinter A, Tung S, Sterns L, Birnie D, Exner D, Parkash R, Skanes AC, Yee R, Klein GJ, Krahn AD. Outcome of advisory implantable cardioverter-defibrillator replacement: one-year follow-up. *Heart Rhythm*, 2008, 5:1675-1681.
- Gould PA, Krahn AD. Complications associated with implantable cardioverter-defibrillator replacement in response to device advisories. *JAMA*, 2006, 295:1907-1911.
- Gradaus R, Block M, Brachmann J, Breithardt G, Huber HG, Jung W, Kranig W, Mletzko RU, Schoels W, Seidl K, Senges J, Siebels J, Steinbeck G, Stellbrink C, Andresen D. Mortality, morbidity, and complications in 3344 patients with implantable cardioverter defibrillators: results from the German ICD Registry EURID. *Pacing Clin Electrophysiol*, 2003, 26:1511-1518.
- Gula LJ, Massel D, Krahn AD, Yee R, Skanes AC, Klein GJ. Is defibrillation testing still necessary? A decision analysis and Markov model. *J Cardiovasc Electrophysiol*, 2008, 19:400-5.
- Haghjoo, M., Nikoo, M. H., Fazelifar, A. F., Alizadeh, A., Emkanjoo, Z., & Sadr-Ameli, M. A. Predictors of venous obstruction following pacemaker or implantable


- cardioverterdefibrillator implantation: a contrast venographic study on 100 patients admitted for generator change, lead revision, or device upgrade. *Europace*, (2007), 9(5), 328–332.
- Healey JS, Birnie DH, Lee DS, Krahn AD, Crystal E, Simpson CS, Dorian P, Chen Z, Cameron D, Verma A, Connolly SJ, Gula LJ, Lockwood E, Nair G, Tu JV; Ontario ICD Database Investigators. Defibrillation Testing at the Time of ICD Insertion: An Analysis From the Ontario ICD Registry. *J Cardiovasc Electrophysiol*, 2010 Dec, 21(12):1344-8.
- Hess CN, Ohman EM, Patel MR. Amplatzer vascular plug closure of a subclavian arteriovenous fistula associated with implantable cardioverter-defibrillator implantation. *Catheter Cardiovasc Interv*, 2010 Sep 17.
- Hodgson DM, Olsovsky MR, Shorofsky SR, Daly B, Gold MR. Clinical predictors of defibrillation thresholds with an active pectoral pulse generator lead system. *Pacing Clin Electrophysiol*, 2002, 25:408-13.
- ISO 14155, *International Standard for Clinical Investigation of Medical Devices*, Geneva, Switzerland: International Organisation for Standardization, 1996.
- Jaroszewski DE, Altemose GT, Scott LR, Srivasthan K, Devaleria PA, Lackey J et al. Non traditional surgical approaches for implantation of pacemaker and cardioverter defibrillator systems in patients with limited venous access. *Ann Thorac Surg*, 2009, 88:112–6.
- Johansen JB, Jørgensen OD, Møller M, Arnsbo P, Mortensen PT, Nielsen JC. Infection after pacemaker implantation: infection rates and risk factors associated with infection in a population-based cohort study of 46299 consecutive patients. *Eur Heart J*. 2011 Apr;32(8):991-8. Epub 2011 Jan 20.
- Kim JB, Joung B, Lee MH, Kim SS. Use of a tunneling technique to achieve a lower defibrillation threshold during implantable cardioverter defibrillator implantation via the right subclavian vein. *J Korean Med Sci*, 2010 Oct, 25(10):1526-8.
- Kitamura S, Satomi K, Kurita T, Shimizu W, Suyama K, Aihara N, Niwaya K, Kobayashi J, Kamakura S. Long-term follow-up of transvenous defibrillation leads: high incidence of fracture in coaxial polyurethane lead. *Circ J*, 2006 Mar, 70(3):273-7.
- Korkeila P, Ylitalo A, Koistinen J, Airaksinen KE. Progression of venous pathology after pacemaker and cardioverter-defibrillator implantation: A prospective serial venographic study. *Ann Med*, 2009, 41(3):216-23.
- Krahn AD, Lee DS, Birnie D, Healey JS, Crystal E, Dorian P, Simpson CS, Khaykin Y, Cameron D, Janmohamed A, Yee R, Austin PC, Chen Z, Hardy J, Tu JV; for the Ontario ICD Database Investigators. Predictors of Short-Term Complications After Implantable Cardioverter-Defibrillator Replacement: Results From the Ontario ICD Database. *Arrhythm Electrophysiol*, 2011 Apr 1, 4(2):136-142.
- Kron J. Clinical significance of device-related complications in clinical trials and implications for future trials: insights from the Antiarrhythmics Versus Implantable Defibrillators (AVID) trial. *Card Electrophysiol Rev*. 2003 Dec;7(4):473-8.
- Laborderie J, Barandon L, Ploux S, Deplagne A, Mokrani B, Reuter S, Le Gal F, Jais P, Haissaguerre M, Clementy J, Bordachar P. Management of subacute and delayed right ventricular perforation with a pacing or an implantable cardioverter-defibrillator lead. *Am J Cardiol*, 2008 Nov 15, 102(10):1352-5.

- Lickfett L, Bitzen A, Arepally A, Nasir K, Wolpert C, Jeong KM et al. Incidence of venous obstruction following insertion of an implantable cardioverter defibrillator. A study of systematic contrast venography on patients presenting for their first elective ICD generator replacement. *Europace*, 2004, 6:25–31.
- Lin G, Nishimura RA, Gersh BJ, Phil D, Ommen SR, Ackerman MJ, Brady PA. Device complications and inappropriate implantable cardioverter defibrillator shocks in patients with hypertrophic cardiomyopathy. *Heart*, 2009 May, 95(9):709–14.
- Lubinski A, Lewicka-Nowak E, Królak T, Kempa M, Bielawska B, Wilczek R, Swiatecka G. Implantation and follow-up of ICD leads implanted in the right ventricular outflow tract. *Pacing Clin Electrophysiol*. 2000 Nov;23(11 Pt 2):1996–8.
- Mangram AJ, Horan TC, Pearson ML, Silver LC, Jarvis WR. Guideline for prevention of surgical site infection, 1999. Hospital Infection Control Practices Advisory Committee. *Infect Control Hosp Epidemiol*. 1999 Apr;20(4):250–78.
- Margey R, McCann H, Blake G, Keelan E, Galvin J, Lynch M, Mahon N, Sugrue D, O'Neill J. Contemporary management of and outcomes from cardiac device related infections. *Europace*. 2010 Jan;12(1):64–70.
- Mela T, McGovern BA, Garan H, Vlahakes GJ, Torchiana DF, Ruskin J, Galvin JM. Long-term infection rates associated with the pectoral versus abdominal approach to cardioverter- defibrillator implants. *Am J Cardiol*. 2001 Oct 1;88(7):750–3.
- Merla R, Reddy NK, Kunapuli S, Schwarz E, Vitarelli A, Rosanio S. Late right ventricular perforation and hemothorax after transvenous defibrillator lead implantation. *Am J Med Sci*, 2007 Sep, 334(3):209–11.
- Moore JW III., Barrington W, Bazaz R, Jain S, Nemec J, Ngwu O, Schwartzman D, Shalaby A, Saba S. Complications of replacing implantable devices in response to advisories: a single center experience. *Int J Cardiol*, 2009, 134:42–46.
- Parahuleva M, Chasan R, Soydan N, Abdallah Y, Neuhoof Ch, Tillmanns H, Erdogan A. Quadripolar left ventricular lead in a patient with CRT-D does not overcome phrenic nerve stimulation. *Clin Med Insights Cardiology*, 2011;5 45–47.
- Parahuleva M, Schifferings P, Neuhoof Ch, Tillmanns H, Erdogan A. Pneumopericardium and Pneumomediastinum as a Late Complication of Defibrillator Implantation after Coronary Artery Bypass Graft Surgery. *Thorac Cardiovasc Surg*, 2009, 57:489–495.
- Pavia S, Wilkoff B. The management of surgical complications of pacemaker and implantable cardioverter-defibrillators. *Curr Opin Cardiol*, 2001 Jan, 16(1):66–71.
- Poole JE, Gleva MJ, Mela T, Chung MK, Uslan DZ, Borge R, Gottipaty V, Shinn T, Dan D, Feldman LA, Seide H, Winston SA, Gallagher JJ, Langberg JJ, Mitchell K, Holcomb R. Complication rates associated with pacemaker or implantable cardioverter-defibrillator generator replacements and upgrade procedures: results from the REPLACE registry. *Circulation*, 2010, 122:1553–1561.
- Reynolds MR, Cohen DJ, Kugelmass AD, Brown PP, Becker ER, Culler SD, Simon AW. The frequency and incremental cost of major complications among medicare beneficiaries receiving implantable cardioverter-defibrillators. *J Am Coll Cardiol*, 2006 Jun 20, 47(12):2493–7.
- Prull M. W, Unverricht S, Bittlinsky A, Sasko B, Wirdemann H, Gkiouras G, Butz T, Trappe H.-J. Der ICD-Test führt zu einem zerebralen Schaden und verschlechtert die kognitive Funktion. *Clin Res Cardiol*, 100, Suppl 1, April 2011

- Rosman J, Shapiro MD, Hanon S. Pneumomediastinum and right sided pneumothorax following dual chamber-ICD implantation. *J Interv Card Electrophysiol*, 2006 Nov, 17(2):157-8.
- Russo AM, Sauer W, Gerstenfeld EP, Hsia HH, Lin D, Cooper JM, et al. Defibrillation threshold testing: is it really necessary at the time of implantable cardioverter-defibrillator insertion? *Heart Rhythm*, 2005, 2:456-61.
- Santini M, Brachmann J, Cappato R, Davies W, Farre J, Levy S, Quesada A, Ricci RP, Rowland E, Sulke N. Recommendations of the European Cardiac Arrhythmia Society Committee on device failures and complications. *Pacing Clin Electrophysiol*, 2006, 29:653-669.
- Senges-Becker JC, Klostermann M, Becker R, Bauer A, Siegler KE, Katus HA, Schoels W. What is the "optimal" follow-up schedule for ICD patients? *Europace*. 2005 Jul;7(4):319-26.
- Shetty AK, Duckett SG, Bostock J, Roy D, Ginks M, Hamid S, Rosenthal E, Razavi R, Rinaldi CA. Initial Single-Center Experience of a Quadripolar Pacing Lead for Cardiac Resynchronization Therapy. *Pacing Clin Electrophysiol*, 2011 Jan 5.
- Smith MC, Love CJ. Extraction of transvenous pacing and ICD leads. *Pacing Clin Electrophysiol* 2008;31:736-52.
- Spencer S, Coban N, Koch L, Schirdewan A, Mueller D. Comparison of skin adhesive and absorbable intracutaneous suture for the implantation of cardiac rhythm devices. *Europace*, 2011 Mar, 13(3):416-20, Epub 2010 Nov 11.
- Stark, J.N. (2011). A New Standard for Medical Device Investigations. *Journal of Clinical Research Best Practices*, Vol. 7, No. 2, (February 2011)
- Stouffer CW, Shillingford MS, Miles WM, Conti JB, Beaver TM. Lead astray: minimally invasive removal of a pacing lead in the left ventricle. *Clin Cardiol*, 2010 Jun, 33(6):E109-10.
- Strickberger SA, Klein GJ. Is defibrillation testing required for defibrillator implantation? *J Am Coll Cardiol*, 2004, 44:88-91.
- Tompkins C, Cheng A, Dalal D, Brinker JA, Leng CT, Marine JE, Nazarian S, Spragg DD, Sinha S, Halperin H, Tomaselli GF, Berger RD, Calkins H, Henrikson CA. Dual antiplatelet therapy and heparin "bridging" significantly increase the risk of bleeding complications after pacemaker or implantable cardioverter-defibrillator device implantation. *J Am Coll Cardiol*, 2010 May 25, 55(21):2376-82.
- Trohman RG, Wilkoff BL, Byrne T, et al. Successful percutaneous extraction of a chronic left ventricular pacing lead. *Pacing Clin Electrophysiol*, 1991, 14:1448-1451.
- Turakhia M, Prasad M, Olgin J, Badhwar N, Tseng ZH, Lee R, Marcus GM, Lee BK. Rates and severity of perforation from implantable cardioverter-defibrillator leads: a 4-year study. *J Interv Card Electrophysiol*. 2009 Jan;24(1):47-52.
- Van Gelder BM, Bracke FA, Oto A, et al. Diagnosis and management of inadvertently placed pacing and ICD leads in the left ventricle: a multicenter experience and review of the literature. *Pacing Clin Electrophysiol*, 2000, 23:877-883.
- Van Rooden CJ, Molhoek SG, Rosendaal FR, Schalij MJ, Meinders AE, Huisman MV. Incidence and risk factors of early venous thrombosis associated with permanent pacemaker leads. *J Cardiovasc Electrophysiol*, 2004 Nov, 15(11):1258-62.
- Veltri EP, Mower MM, Reid PR. Twiddler's syndrome: a new twist. *PACE*, 1984, 7:1004-09

- Wilkoff BL. Lead-induced venous thrombosis: consequences? *J Cardiovasc Electrophysiol*, 2004 Nov, 15(11):1263-4.
- Wilkoff BL, Auricchio A, Brugada J, Cowie M, Ellenbogen KA, Gillis AM, Hayes DL, Howlett JG, Kautzner J, Love CJ, Morgan JM, Priori SG, Reynolds DW, Schoenfeld MH, Vardas PE; (HRS; EHRA; ACC; AHA); European Society of Cardiology (ESC); Heart Failure Association of ESC (HFA); Heart Failure Society of America (HFSA). HRS/EHRA Expert Consensus on the Monitoring of Cardiovascular Implantable Electronic Devices (CIEDs): Description of Techniques, Indications, Personnel, Frequency and Ethical Considerations. *Europace*, 2008 Jun, 10(6):707-25.
- Wollmann CG, Böcker D, Löher A, Paul M, Scheld HH, Breithardt G, Gradaus R. Two different therapeutic strategies in ICD lead defects: additional combined lead versus replacement of the lead. *J Cardiovasc Electrophysiol*, 2007 Nov, 18(11):1172-7.
- Worley SJ, Ghon DC, Pulliam RW. Opening an occluded subclavian vein with a screw-like flexible hollow guide-wire and venoplasty. *PACE*, 2007, 30:1290-3.

IntechOpen



Cardiac Defibrillation - Mechanisms, Challenges and Implications

Edited by Prof. Natalia Trayanova

ISBN 978-953-307-666-9

Hard cover, 248 pages

Publisher InTech

Published online 26, September, 2011

Published in print edition September, 2011

The only known effective therapy for lethal disturbances in cardiac rhythm is deï-brillation, the delivery of a strong electric shock to the heart. This technique constitutes the most important means for prevention of sudden cardiac death. The efficacy of defibrillation has led to an exponential growth in the number of patients receiving implantable devices. The objective of this book is to present contemporary views on the basic mechanisms by which the heart responds to an electric shock, as well as on the challenges and implications of clinical defibrillation. Basic science chapters elucidate questions such as lead configurations and the reasons by which a defibrillation shock fails. Chapters devoted to the challenges in the clinical procedure of defibrillation address issues related to inappropriate and unnecessary shocks, complications associated with the implantation of cardioverter/defibrillator devices, and the application of the therapy in pediatric patients and young adults. The book also examines the implications of defibrillation therapy, such as patient risk stratification, cardiac rehabilitation, and remote monitoring of patient with implantable devices.

How to reference

In order to correctly reference this scholarly work, feel free to copy and paste the following:

Mariana Parahuleva (2011). Cardiovascular Implantable Cardioverter Defibrillator-Related Complications: From Implant to Removal or Replacement: A Review, Cardiac Defibrillation - Mechanisms, Challenges and Implications, Prof. Natalia Trayanova (Ed.), ISBN: 978-953-307-666-9, InTech, Available from: <http://www.intechopen.com/books/cardiac-defibrillation-mechanisms-challenges-and-implications/cardiovascular-implantable-cardioverter-defibrillator-related-complications-from-implant-to-removal->

INTech
open science | open minds

InTech Europe

University Campus STeP Ri
Slavka Krautzeka 83/A
51000 Rijeka, Croatia
Phone: +385 (51) 770 447
Fax: +385 (51) 686 166
www.intechopen.com

InTech China

Unit 405, Office Block, Hotel Equatorial Shanghai
No.65, Yan An Road (West), Shanghai, 200040, China
中国上海市延安西路65号上海国际贵都大饭店办公楼405单元
Phone: +86-21-62489820
Fax: +86-21-62489821

© 2011 The Author(s). Licensee IntechOpen. This chapter is distributed under the terms of the [Creative Commons Attribution-NonCommercial-ShareAlike-3.0 License](https://creativecommons.org/licenses/by-nc-sa/3.0/), which permits use, distribution and reproduction for non-commercial purposes, provided the original is properly cited and derivative works building on this content are distributed under the same license.

IntechOpen

IntechOpen