

# We are IntechOpen, the world's leading publisher of Open Access books Built by scientists, for scientists

6,900

Open access books available

186,000

International authors and editors

200M

Downloads

Our authors are among the

154

Countries delivered to

TOP 1%

most cited scientists

12.2%

Contributors from top 500 universities



WEB OF SCIENCE™

Selection of our books indexed in the Book Citation Index  
in Web of Science™ Core Collection (BKCI)

Interested in publishing with us?  
Contact [book.department@intechopen.com](mailto:book.department@intechopen.com)

Numbers displayed above are based on latest data collected.  
For more information visit [www.intechopen.com](http://www.intechopen.com)



# Sweet Syndrome

Manuel Ginarte and Jaime Toribio

*Department of Dermatology. Complejo Hospitalario Universitario de Santiago.  
Faculty of Medicine. Santiago de Compostela,  
Spain*

## 1. Introduction

Sweet syndrome (SS) was first described by Robert Sweet in 1964 as acute febrile neutrophilic dermatosis (Sweet, 1966). Despite of the descriptive value of this denomination and the advice of Robert Sweet to keep it, the eponymous became prevalent on the time. SS was the first neutrofilic dermatosis (ND) described and it represents the paradigm of them. There are three key points of SS that are of interest not only for the dermatologists but also for the general practitioners: a) its marked clinical manifestations, b) the potential systemic repercussion of neutrophilic reaction, and c) its association with extracutaneos diseases, especially with malignancies.

## 2. Definition and classification

SS is a neutrophilic dermatosis characterized by specific clinical and histopathological manifestations. In fact, the best way of defining SS is based on its diagnostic criteria. Typically, SS appears abruptly with multiple, edematous, tender red plaques that are distributed bilaterally but asymmetrically in a febrile patient. The dermatopathological image shows a neutrophilic diffuse infiltrate without vasculitis located in upper dermis. Besides this typical picture, several clinical and histopathological variants have been described (table 1). The current classification of SS is based on the associated or trigger conditions and has clinical value for the management of these patients (table 2).

Transitional forms with other neutrophlic dermatosis  
Located forms: dorsal hands and facial  
Chronic recurrent neutrophilic dermatosis  
Histiocytoid Sweet syndrome

Table 1. Main clinical and histopathological subtypes of Sweet syndrome

Idiopathic  
Parainflammatory  
Paraneoplastic  
Drug-induced  
Associated to pregnancy

Table 2. Classification of Sweet syndrome

### 3. Epidemiology

There is not reliable data regarding the incidence and prevalence of SS in general population. This relies on the fact that SS is an infrequent condition and the available data are based on series' reports of and patient's records from hospitals and dermatology departments. Moreover, it is necessary to take into account that the incidence of SS is determined by the incidence of infectious causes in general population (Hommel et al, 1993). With all these limitations, it has been reported that the incidence of SS in Scotland is 2.7 cases per million inhabitants and year (Kemmett & Hunter, 1990).

Gender distribution of SS is conditioned by the underlying or trigger disorder. There is a female predominance in parainflammatory and idiopathic cases which disappears in the infantile and paraneoplastic ones. There is no racial predilection.

### 4. Pathogenesis

The pathogenesis of SS remains to be definitively determined. Three possible pathogenical mechanisms have been considered, but none of them have been consistently demonstrated (Requena, 2007): a) a type III hypersensitivity reaction, b) an activation of T cells by antigens or superantigens, and c) a disturbance of neutrophils' function. It seems that genetic factors play a role since SS has been associated to several HLA, especially to Bw54 (Mizoguchi, 1988). Because of female predominance in parainflammatory and idiopathic cases and both pregnancy and contraconceptive pills implication in some cases of SS, hormonal background can also be involved in the development of SS.

Numerous cytokines are involved in the pathogenesis of this condition, including interleukins 1, 2, 3, 6, and 8 and gamma interferon, but the key substance is the granulocyte-colony stimulating factor (G-CSF). The administration of G-CSF can result in an outbreak of SS and this substance is elevated in serum of patients with SS and its levels are directly related with the disease activity (Kawakami et al, 2004; Ginarte & Toribio, 2010).

### 5. Clinical manifestations

#### 5.1 Skin

SS begins as an alarming feature for the patient because of its abrupt onset, the presence of general malaise, and the pain or tenderness of the multiple erythematodematous plaques (Gunawardena et al 1975; Kemmett & Hunter, 1990; Zamora et al 1990; Sitjas et al, 1993; von den Driesch 1994; Chan et al, 1994; Ginarte et al, 1997). The appearance of each individual lesion may be variable: the colour goes from vivid red to violaceous, sometimes with central paleness due to dermal edema. This edema can also be represented by pseudovesicular or true bullous lesions (figure 1). It is relatively frequent to observe dome like lesions, especially on tenar and hypotenar eminences (in "mountain range") (figure 2). Individual lesions can also be pustular. Up to a third of the lesions have an annular appearance. Plaque's size is variable but the majority range between 1 and 10 cm. The lesions are distributed bilaterally but asymmetrically. Common locations are face, neck, upper trunk, shoulders, and hands. On pretibial aspect of the legs, the lesions may exhibit a nodular morphology, which may be the clinical manifestation of a typical SS, a subcutaneous Sweet or an erythema nodosum (see forward). Pathergy may be present in up to 8% of the patients.

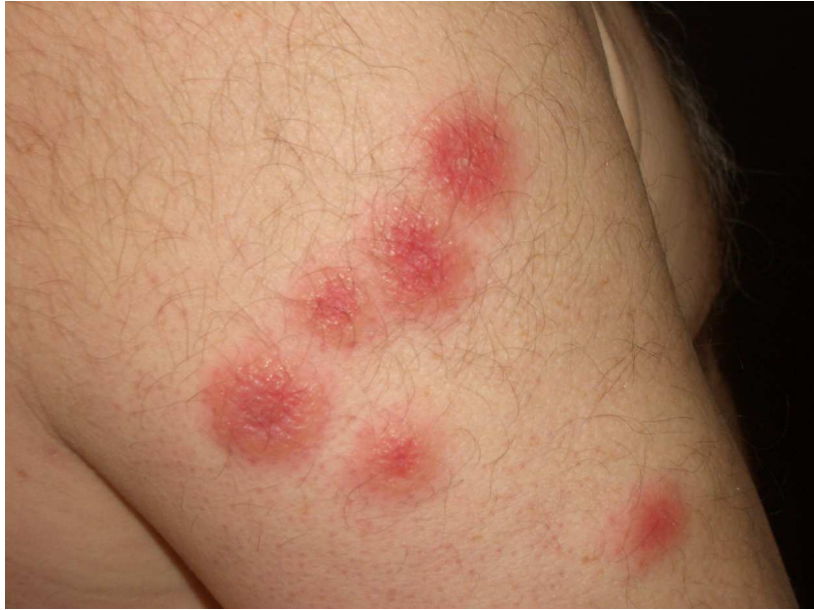

Fig. 1. Erythematous plaques with vesicular and bullous appearance due to a intense dermal edema.

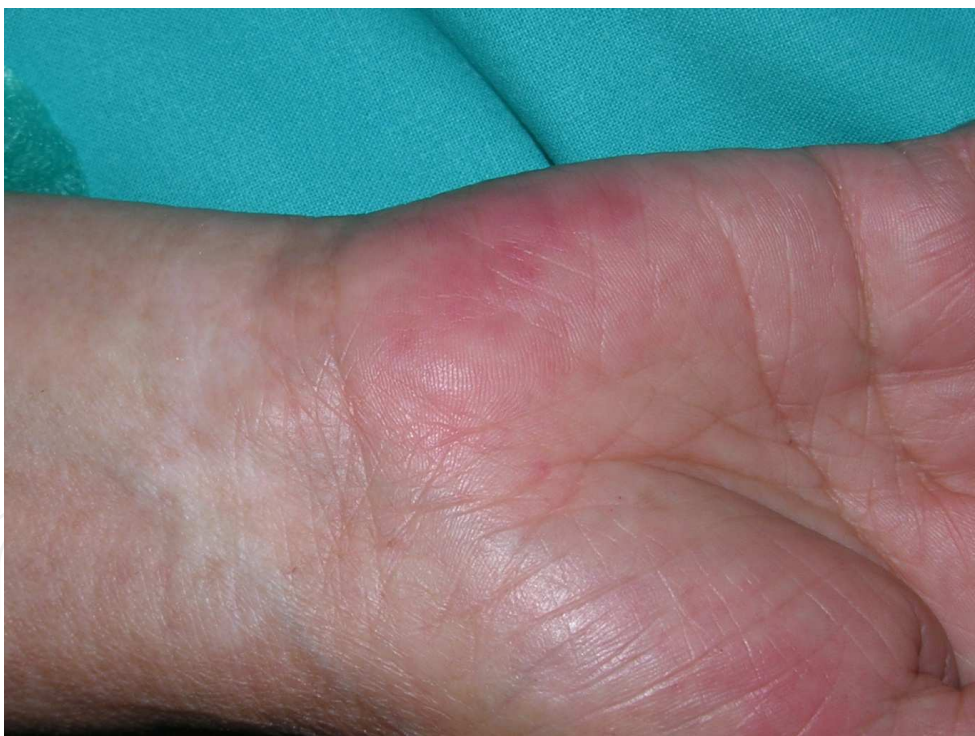

Fig. 2. The plaques on tenar and hypotenar skin have frequently a characteristic appearance of "mountain range"

### 5.2 Mucous membranes

The mucous membranes are frequently involved, especially the ocular as conjunctivitis or episcleritis (Gottlieb et al, 2008) (figure 3). Less frequent is the affectation of the oral mucosa, usually as aphthous ulcers.



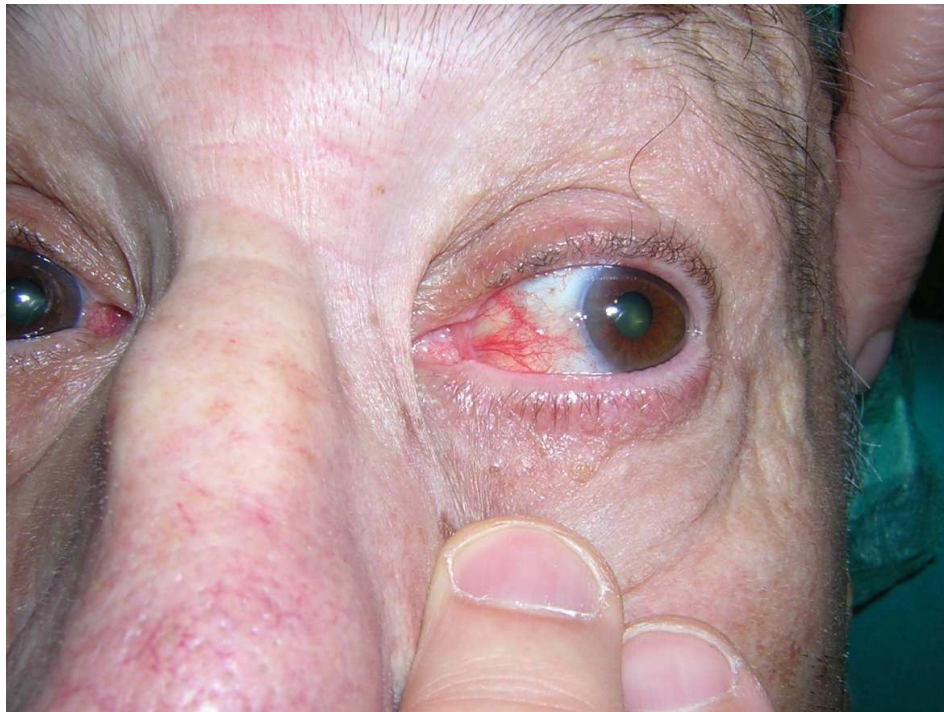

Fig. 3. Epiescleritis in a patient – with Sweet syndrome

### 5.3 Laboratory findings

Analytic alterations are very frequent and they can have diagnostic significance. The most typical but not constant alteration is leukocytosis with neutrophilia that only in the 50% of the patients exceed by  $10.0 \times 10^3$  cells/mm<sup>3</sup>. The majority of patients have the acute reactants (erythrocyte sedimentation rate and C-reactive protein) elevated and a third have mild alterations in urinary tests (haematuria, leukocyturia, and/or proteinuria) without affectation of renal function (Ginarte et al, 1997). It is necessary to distinguish the laboratory findings related to SS from the analytic changes due to trigger or associated diseases. For example, the presence of anemia, trombocytosis and/or massive leukocytosis should force us to rule out an haematologic malignancy (Cohen & Kurzrock, 1993).

### 5.4 Extracutaneous manifestations

Frequently patients with SS have extracutaneous manifestations that can be caused by two different mechanisms: a) a systemic neutrophilic reaction that affects not only the skin but also internal organs, and b) a disease or trigger condition causing the SS. These two different possibilities make more difficult the management of the patients because it is hard to distinguish by means the clinical and routine complementary tests if an internal disorder is the cause or the consequence of the SS. For example, the existence of respiratory manifestations, pulmonary infiltrates in X-ray chest, fever and leukocytosis with neutrophilia in a patient with SS set the doubt between an infectious pneumonia or a neutrophilic pneumonitis (which has important practical consequences since their treatment is quite different, i.e., antibiotics versus glucocorticoids). Despite of its original denomination as acute febrile neutrophilic dermatosis, the fever is only present in 50 to 72% of the cases (Ginarte et al, 1997). Joint involvement appear in 37 to 51% of the patients, usually as arthralgias or, more rarely, as true arthritis, which is commonly located on knees

and ankles. Neutrophilic infiltration of internal organs is less frequent. Although the infiltration of the majority of the organs has been reported, the most frequently affected are the lungs (up to 6% of the patient in a serie) (Sitjas et al, 1993). Pulmonary involvement expresses as neutrophilic alveolitis. In the literature there are abundant references about the neutrophilic affectation of internal organs, which may induce to think that it is a frequent event even though it is actually an uncommon fact. This situation is secondary to a bias in reporting the more extreme cases of SS. Nevertheless, the possibility of internal organ involvement in SS patients should always be taken in consideration and it is important distinguish it from other diseases or trigger factors (especially the infectious ones) since their clinical management is quite different. As neutrophilic internal organ involvement is relatively more frequent in paraneoplastic SS than in other subtypes of SS, its presence obligates us to rule out a malignancy (Cohen & Kurzrock, 1993). Table 3 shows the main extracutaneous manifestations of SS.

ORGAN	CLINICAL MANIFESTATIONS	REFERENCES
Bones	Chronic recurrent osteomyelitis (in children)	Majeed et al, 1989; Marie et al, 1998
Bowel	Neutrophilic bowel infiltration, pancolitis	McDermott et al, 2001; Fain et al, 1996
Central nervous system	Neuro-Sweet	Hisanaga et al, 1999; Nobeyama & Kamide, 2003; Ramos et al, 2003; Hisanaga et al, 2005; Sobol et al, 2009; Watanabe et al, 2009
Heart	Aortitis, myocarditis, cardiac insuficiency, ischemic cardiopathy	Muster et al, 1983; Shimizu, 1998; Guia et al, 1999; Dorenkamp et al, 2003
Kindney	Glomerulonephritis, alterations of urinalysis	Christ et al, 1996
Liver	Neutrophilic hepatitis, changes in liver function tests and analysis	Kemmett & Hunter, 1990; Zamora et al, 1990; Fett et al, 1995; Ginarte et al, 1997
Lung	Neutrophilic alveolitis, pleural effusion; radiologic sterile infiltrates	Cohen & Kurzrock, 1992; Sitjas et al, 1993; Fett et al, 1995; Peters et al, 1998; Astudillo et al, 2006
Muscle	Tendosinovitis, myositis, myalgias	Attias et al, 1995; Brown et al, 2002

Table 3. Systemic involvement in Sweet syndrome

## 6. Characteristics of the subsets of SS

### 6.1 Idiopathic

Classically it is the most frequent subset of SS and it represents up to 70% of the cases in old series (Requena, 2007). It predominates in women, especially in patients aged under 45 years. Most recently, this subset has become less prevalent possibly due to the better study of the patients (Corazza et al, 2008).

### 6.2 Parainflammatory

This group encompasses the SS associated or triggered by inflammatory and infectious conditions. There is a broad number of entities related with SS, some of them only based on isolated or few case reports, which makes difficult to assess the true power of the association (reviewed by Requena, 2007; von den Driesch, 1994; Cohen, 2007). The best documented inflammatory diseases associated with SS are Beçhet disease, bowel inflammatory disease, rheumatoid arthritis, lupus erythematosus, and other autoimmune collagenosis. The infectious conditions more related with SS are oropharyngeal infection (especially due to streptococcus pyogenes) and intestinal infections by *Salmonella* and *Yersinia*. Less constantly SS has been linked to other bacterial infections, tuberculosis, lepra, histoplasmosis, toxoplasmosis, HIV, and viral hepatitis. Recent reports suggest that the patients with previous oropharyngeal infection have a less severe form of this syndrome (Borges Da Costa et al, 2009).

### 6.3 Paraneoplastic SS

It is a well established subset of SS with an obvious interest. Up to 20% of SS are paraneoplastic (Cohen & Kurzrock, 1993). The SS may precede (sometime in years) or follow the malignancy. It also may arise in relation with the recurrence of previous malignancy. There are some characteristics more related to paraneoplastic than to non-paraneoplastic SS: a) lack of female predominance; b) advanced age; c) presence of anemia and/or other hematological disturbances; d) extracutaneous involvement; e) atypical, pustular, or necrotic skin lesions (Cohen & Kurzrock, 1993; Watanabe et al, 2009). The majority of paraneoplastic SS are associated with hematologic malignancies, especially with acute myelogenous leukemia and myelodysplastic syndromes (Buck et al, 2008). About 15% of paraneoplastic SS are related with solid cancers, predominating breast, gastrointestinal, and genitourinary origin.

### 6.4 Drug-induced SS

More than 25 drugs have been related to the flare of SS, but the most frequently implicated is the granulocyte-colony stimulating factor (G-CSF). Other drugs that are commonly associated with the development of SS are trimethoprim-sulphamethoxazole, oral contraceptive pills, retinoids, minocycline, hydralazine, carbamacepine, bortezomib, and imatinib. As it is usual in other skin eruptions induced by drugs, the disease fades with the withdrawal of the drug and flares up if it is re-administrated.

### 6.5 SS associated with pregnancy

It is not unanimously considered as a subgroup of SS, but its existence should be taken into account due to its relative frequency.

## 7. Clinical variations and associations with other dermatoses

The typical cases of SS present very characteristics clinicopathological manifestations so that their diagnosis usually does not represent particular difficulty. Nevertheless, the SS may occasionally show a different clinical picture or it may be associated with other cutaneous signs making difficult to set the diagnosis and/or imply a change in the patient's management. There is controversy about the need of describing such cases as "atypical" SS or as individualizing them as different entities.

### 7.1 Overlap and relationship with other ND

The group of ND represents a *continuum* of diseases that share clinical, histopathological, and causal features. The individualization of each entity is mainly based on clinical criteria. This fact explains that SS occasionally shares clinical characteristics with other ND (overlap), especially with generalized vesiculobullous forms of pyoderma gangrenosum. Other ND such as Behçet disease, bowel bypass syndrome, and neutrophilic eccrine hidradenitis may clinically resemble SS (Mizuashi et al, 2010). Sometimes patients with these features can only be diagnosed generically as suffering a ND, without a more specific denomination. In the same way, there have been reported patients suffering both SS and other ND (either simultaneously or sequentially) (Callen, 1985; Sherertz, 1987; Villanueva et al, 1989; Ginarte et al, 1997).

### 7.2 Chronic recurrent annular neutrophilic dermatosis

As its denomination indicates, it is a subtype of SS characterized by erythematous plaques with a chronic and recurrent evolution. It has neither extracutaneous signs, nor fever or neutrophilia (Christensen et al, 1989; Romero et al, 1994; Cabanillas et al, 2008).

### 7.3 Subcutaneous fat involvement

Frequently, patients with SS have nodular lesions, especially on anterior aspects of the legs. These nodules are the clinical manifestation of the alteration of the subcutaneous fat, which can be originated by two different mechanisms. The first one called subcutaneous SS is characterized by a neutrophilic inflammatory infiltrate located on subcutaneous fat (either exclusively or accompanied by dermal affectation). Such infiltrate is usually located in fat lobules, but occasionally it may be septal or mixed (Cohen & Kurzrock, 2003). In a recent study, subcutaneous SS was shown by 16% of the patients (Abbas et al, 2010). The second possibility of subcutaneous fat involvement in SS is the association between this syndrome and erythema nodosum. This association is relatively frequent (up to 30% of the cases) and can be explained because both entities share several common features: essentially both are reactive dermatoses triggered by similar stimuli and pathogenically mediated by neutrophils. They are also treated with similar treatments (Ginarte et al, 1997; Ginarte & Toribio, 2000; Ginarte & Toribio, 2007). Due to the different significance of subcutaneous SS and erythema nodosum, it is necessary to make a deep biopsy from one of the nodules.

### 7.4 Sweet syndrome in infancy

About 16% of SS appears in children (Abbas et al, 2010). Pediatric SS is similar to that in adult population, with only three differences: a) it is associated with immunodeficiency



(HIV infection and other immune disorders), b) it is less associated with malignancy (although it is necessary to investigate this condition), and c) it is particularly susceptible to recurrences (Mohr et al, 2010).

### 7.5 Located forms

It has been described as located subtypes of SS cases with clinical lesions limited to a particular body's area. The neutrophilic dermatosis of the dorsal hands shows characteristics as much SS as pyoderma gangrenosum exclusively located in this area. There is a controversy about if this entity is a subtype of SS or it is an independent disease (Walling et al, 2006; Laguna et al, 2007; Takahama & Kanbe, 2010). The same consideration is discussed about the located form in facial region (Whittle et al, 1968).

## 8. Histopathology

It is very characteristic and one of the diagnostic criteria of SS: a diffuse infiltrate of neutrophils located in the upper half of the dermis accompanied by intense edema. This edema causes the clinical appearance of pseudovesicular or bullous plaques. Leukocytoclasia is frequently present and may be prominent, but obvious vasculitis (neutrophils and fibrin deposits into blood vessel walls) must be absent in order to set the diagnosis. Occasionally swollen endothelial cells, scattered eosinophils (more typical of drug-induced SS), and epidermal exocytosis of neutrophils (even with formation of subcorneal pustules) can be observed. In older lesions the neutrophilic infiltrate is substituted by lymphohistiocytic infiltrate (Jordaan, 1989). Requena et al (Requena et al, 2005; Requena, 2007) have described the called *histiocytoid Sweet syndrome*, characterized by a dermal infiltrate constituted by immature neutrophilic granulocytes that have an appearance indistinguishable from histiocytoid cells on optic microscopy with routine stains. The majority of this histiocytoid SS is associated with hematological malignancies, although it has recently been reported an histiocytoid SS induced by trimethoprim-sulfamethoxazole therapy with bone marrow granulocytic maturation arrest (Wu et al, 2008) and two patients with inflammatory bowel disease (Requena et al, 2005; Spencer et al, 2008). Immunohistochemical analysis is necessary when histiocytes are present in SS in order to distinguish histiocytoid SS (immature neutrophils) from true histiocytes that can be present in the typical neutrophilic infiltrate, sometimes in a moderate or predominant amount (specially in older lesions) (Corazza et al, 2008).

## 9. Diagnosis

Typical forms of SS are easily diagnosed by means of criteria of Su and Liu published in 1986 (Su & Liu, 1986) (table 4). Von den Driesch provided a more evolved modification of these criteria in 1994 (von den Driesch, 1994) (table 5), but it has had less acceptance. As we previously indicated, there are patients with "atypical" SS, transitional forms of SS and other ND, as well as cases in which it is only possible to set a generic diagnosis of ND.

## 10. Differential diagnosis

As typical forms of SS exhibit a very characteristic clinicopathological picture they rarely cause problems with differential diagnosis. The disease that clinically more resembles SS is

the erythema multiforme. Other clinical differential diagnosis are drug eruptions and Behçet disease. All of these entities can be ruled out by means of a skin biopsy. Other ND (atypical pyoderma gangrenosum, bowel bypass syndrome, neutrophilic eccrine hidradenitis), vasculitis (specially erythema elevatum diutinum), and erythema nodosum may occasionally set problems with differential diagnosis both from the histopathological and clinical points of view.

**Major criteria**

- Clinic criterium: abrupt onset of tender or painful erythematous or violaceus plaques or nodules
- Histopathological criterium: predominantly neutrophilic infiltration in the dermis without leukocytoclastic vasculitis

**Minor criteria**

- Preceded by fever or infections
- Accompanied by fever, arthralgia, conjunctivitis, or underlying malignancy
- Leukocytosis
- Good response to systemic steroids and not to antibiotics

The definite diagnosis of SS demands the fulfillment of both major criteria and at least two of the minor criteria

Table 4. Diagnostic criteria by Su y Liu (1986)

**Major criteria**

1. Clinical criterium: abrupt onset of tender or painful erythematous plaques or nodules occasionally with vesicles, pustules or bullae
2. Histopathological criterium: predominantly neutrophilic infiltration in the dermis without leukocytoclastic vasculitis

**Minor criteria**

1. Preceded by a nonspecific respiratory or gastrointestinal tract infection or vaccination or associated with:
  - a. Inflammatory diseases such as chronic autoimmune disorders, infections
  - b. Hemoproliferative disorders or solid malignant tumors
  - c. Pregnancy
2. Accompanied by periods of general malaise and fever (>38°C)
3. Three of four of the following laboratory values during onset:
  - a. ESR > 20 mm
  - b. C-reactive protein positive
  - c. Segmented-nuclear neutrophils and stabs > 70% in peripheral blood smear
  - d. Leukocytosis > 8000
4. Excellent response to treatment with systemic corticosteroids or potassium iodide

Table 5. Diagnostic criteria by von den Driesch (1992)

1. Non-steroidal anti-inflammatory drugs: indometacin, naproxen
2. Tetracyclines: doxycycline, minocycline
3. Dapsone
4. Clofazimine
5. Cyclosporine

Table 6. Second-line therapies of Sweet syndrome.

**11. Treatment**

Nowadays, the first line therapies for SS are systemic corticosteroids, potassium iodide, and colchicine (Cohen, 2009). Systemic corticosteroids are the most widely used: the clinical response is so fast and brilliant that it is considered a diagnostic criterion (Su & Liu, 1986). The general malaise fades into hours and skin lesions into days (less than 10 days) (von den Driesch, 1994). Oral prednisone is given at a dosage of 0.5-1 mg/kg/day (in a single dose or divided in two doses). The dosage is progressively lowered during 3-6 weeks. Such brilliant response to prednisone is darkened by the frequent recurrences: 20-30% of the patients will suffer recurrences after treatment withdrawal and up to 10% of the cases will have a chronic and recurrent evolution for more than 1 year (Kemmett & Hunter, 1990; Sitjas et al, 1993, von den Driesch, 1994; Ginarte et al, 1997). The recurrences respond well to a new cycle of systemic corticosteroids (Ginarte et al, 1997), but their use is limited by their long-term side effects. Another limitation of systemic corticosteroids is the potential existence of an active infection that may trigger the SS. It is important to rule out such possibility.

Potassium iodide is a therapy as fast and effective as systemic corticosteroids. In fact, the response to this agent was included in the diagnostic criteria by von den Driesch (von den Driesch, 1994). Systemic symptoms disappear within 24 to 48 hours and cutaneous plaques in as much as 1 week. The dosage of potassium iodide is 300 mg administered orally, three times daily (or if it is used the Lugol saturated solution, 3 drops three times each day and then increasing progressively the dose to a maximum of 15 drops three times each day). The main adverse effects are gastrointestinal intolerance (nausea and/or diarrhea), hypothyroidism, and vasculitis (Horio et al, 1983).

The other first-line therapy for SS is colchicine. This drug is administered at a dosage of 0.5 mg, two or three times per day. It can be maintained from 2 to 4 weeks. About 90% of the patients respond favorably within a few days and its main limitation are the gastrointestinal side effects (nausea and/or diarrhea) (Maillard et al, 1999).

There have been reported favorable responses to a wide and heterogeneous group of drugs. The response to several of these drugs is only based in isolated case reports, so it must be considered with caution. Table 6 summarized the drugs most repeatedly pointed out in the literature (isolated case reports are not included). These drugs are considered second-line treatments, but it is important to keep them in mind because they may be an effective therapy in patients with frequent recurrences, intolerance or adverse effects to the first-line treatments. This fact is especially applicable to elderly or polymedicated patients.

Obviously, although it was not mentioned, it is also important to treat the underlying process when possible.

## 12. References


- Abbas O, Kibbi A-G, Rubeiz N. (2010). Sweet's syndrome: Retrospective study of clinical and histologic features of 44 cases from a tertiary care center. *Int J Dermatol* 2010; 49: 1244-9. ISSN 0011-9059.
- Astudillo L, Sailler L, Launay F, Josse AG, Lamant L, Couret B, Arlet-Suau E. (2006). Pulmonary involvement in Sweet's syndrome: a case report and review of the literature. *Int J Dermatol* 2006; 45: 677-680. ISSN 0011-9059.
- Attias D, Laor R, Zuckermann E, Naschitz JE, Luria M, Misselevitch I, Boss JH. (1995). Acute neutrophilic myositis in Sweet's syndrome: late phase transformation into fibrosing myositis and panniculitis. *Hum Pathol* 1995; 26: 688-690. ISSN 0046-8177.
- Borges Da Costa J, Silva R, Soares De Almeida L, Filipe P, Marques Gomes M. Sweet's syndrome: A retrospective study of 42 admitted patients in a Portuguese hospital. (2009). *Int J Dermatol* 2009; 48: 953-5. ISSN 0011-9059.
- Brown AM, Davies MG, Hickling P. (2002). Recurrent tenosynovitis in Sweet's syndrome. *Rheumatology (Oxford)* 2002; 41: 1067-1069. ISSN 1462-0324.
- Buck T, Gonzalez LM, Lambert WC, Schwartz RA. (2008). Sweet's syndrome with hematologic disorders: a review and reappraisal. *Int J Dermatol* 2008; 47: 775-82. ISSN 0011-9059.
- Cabanillas M, Suárez-Amor O, Sánchez-Aguilar D, Pereiro M<sup>a</sup>M, Toribio J. (2008). Dermatitis neutrofílica crónica recurrente: una posible variante en el espectro de las dermatosis neutrofílicas. *Actas Dermosifiliogr* 2008; 99: 61-3. ISSN 0001-7310.
- Callen JP. (1985). Acute febrile neutrophilic dermatosis (Sweet's syndrome) and the related conditions of "bowel bypass" syndrome and bullous pyoderma gangrenosum. *Dermatol Clin* 1985; 3: 153-63. ISSN 0733-8635.
- Chan H-L, Lee Y-S, Kuo T-T. (1994). Sweet's syndrome: clinicopathologic study of eleven cases. *Int J Dermatol* 1994; 33: 425-432. ISSN 0011-9059.
- Christ E, Linka A, Jacky E, Speich R, Marincek B, Schaffner A. (1996). Sweet's syndrome involving the musculoskeletal system during treatment of promyelocytic leukemia with all-trans retinoic acid. *Leukemia* 1996; 10: 731-734. ISSN 0887-6924.
- Christensen OB, Holst R, Svensson A. (1989). Chronic recurrent annular neutrophilic dermatosis. An entity? *Acta Derm Venereol (Stockh)* 1989; 69: 415-8. ISSN 0001-5555.
- Cohen PR, Kurzrock R. (1992). Extracutaneous manifestations of Sweet's syndrome: steroid-responsive culture-negative pulmonary lesions. *Am Rev Respir Dis* 1992; 146:269. ISSN 0003-0805.
- Cohen PR, Kurzrock R. (1993). Sweet's syndrome and cancer. *Clin Dermatol* 1993; 11: 149-157. ISSN 0738-081X.
- Cohen PR, Kurzrock R. (2003). Sweet's syndrome revisited: a review of disease concepts. *Int J Dermatol* 2003; 42: 761-78. ISSN 0011-9059.
- Cohen PR. (2007). Sweet's syndrome - a comprehensive review of an acute febrile neutrophilic dermatosis. *Orphanet J Rare Dis* 2007; 2: 34. ISSN: 1750-1172.
- Cohen PR. (2009). Neutrophilic dermatoses: a review of current treatment options. *Am J Clin Dermatol* 2009; 10: 301-12. ISSN: 1175-0561.
- Corazza M, Lauriola MM, Broghi A, Marzola A, Virgili A. (2008). Sweet's syndrome: a retrospective clinical, histopathological and immunohistochemical analysis of 11 cases. *Acta Derm Venereol (Stockh)* 2008; 88: 601-6. ISSN 0001-5555.



- Dorenkamp M, Weikert U, Meyer R, Schwimmbeck PL, Morguet AJ. (2003). Heart failure in acute febrile neutrophilic dermatosis. *Lancet* 2003; 362: 1374. ISSN 0140-6736.
- Fain O, Mathieu E, Feton N, Sibony M, Sitbon M, Lejeune F, Thomas M. (1996). Intestinal involvement in Sweet's syndrome. *J Am Acad Dermatol* 1996; 35: 989-990. ISSN 0190-9622.
- Fett DL, Gibson LE, Su WPD. (1995). Sweet's syndrome: systemic signs and symptoms and associated disorders. *Mayo Clin Proc* 1995; 70: 234-240. ISSN 0025-6196.
- Ginarte M, Garcia-Doval I, Toribio J. (1997). Síndrome de Sweet: estudio de 16 casos. *Med Clin (Barc)* 1997, 109:588-591. ISSN 0025-7753.
- Ginarte M, Toribio J. (2000). Association of Sweet's syndrome and erythema nodosum. *Arch Dermatol* 2000; 136: 673-674. ISSN 0003-987X.
- Ginarte M, Toribio J. (2007). Sweet syndrome and erythema nodosum: two neutrophilic dermatoses? *Clin Rheumatol* 2007; 26: 1215-1216. ISSN 0770-3198 .
- Ginarte M, Toribio J. (2010). Sobre la patogenia del síndrome de Sweet. *Med Clin (Barc)* 2010; 134: 424. ISSN 0025-7753.
- Gottlieb CC, Mishra A, Belliveau D, Green P, Heathcote JG. (2008). Ocular involvement in acute febrile neutrophilic dermatosis (Sweet syndrome): new cases and review of the literature. *Surv Ophthalmol* 2008; 53: 219-26. ISSN 0039-6257.
- Guia JM, Frias J, Castro FJ, Gracian M. (1999). Cardiovascular involvement in a boy with Sweet's syndrome. *Pediatr Cardiol* 1999; 20: 295-297. ISSN 0172-0643.
- Gunawardena DA, Gunawardena KA, Ratnayaka RM, Vasanthanathan NS. (1975). The clinical spectrum of Sweet's syndrome (acute febrile neutrophilic dermatosis)-a report of eighteen cases. *Br J Dermatol* 1975; 92: 363-73. ISSN 0007-0963.
- Hisanaga K, Hosokawa M, Sato N, Mochizuki H, Itoyama Y, Iwasaki Y. (1999). "Neuro-Sweet disease": benign recurrent encephalitis with neutrophilic dermatosis. *Arch Neurol* 1999; 56: 1010-1013. ISSN 0003-9942.
- Hisanaga K, Iwasaki Y, Itoyama Y, Neuro-Sweet Disease Study Group. (2005). Neuro-Sweet disease: clinical manifestations and criteria for diagnosis. *Neurology* 2005; 64: 1756-1761. ISSN 0028-3878.
- Hommel L, Harms M, Saurat JH. (1993). The incidence of Sweet's syndrome in Geneva. A retrospective study of 29 cases. *Dermatology* 1993; 187: 303-305. ISSN 1018-8665.
- Horio T, Danno K, Okamoto H, Miyachi Y, Imamura S. (1983). Potassium iodide in erythema nodosum and other erythematous dermatoses. *J Am Acad Dermatol* 1983; 9: 77-81. ISSN 0190-9622.
- Jordaan HF. (1989). Acute febrile neutrophilic dermatosis. A histopathological study of 37 patients and a review of the literature. *Am J Dermatopathol* 1989, 11:99-111. ISSN 0193-1091.
- Kawakami T, Ohashi S, Kawa Y, Takahama H, Ito M, Soma Y, Mizoguchi M. (2004). Elevated serum granulocyte colony-stimulating factor levels in patients with active phase of Sweet syndrome and patients with active Behçet disease: implication in neutrophil apoptosis dysfunction. *Arch Dermatol* 2004; 140: 570-4. ISSN 0003-987X.
- Kemmett D, Hunter JAA. (1990). Sweet's syndrome: a clinicopathologic review of twenty-nine cases. *J Am Acad Dermatol* 1990; 23: 503-507. ISSN 0190-9622.
- Laguna C, Vilata JJ, Martín B. (2007). Dermatitis neutrofílica del dorso de manos. *Actas Dermosifiliogr* 2007; 98: 102-4. ISSN 0001-7310.

- Maillard H, Leclech C, Peria P, Avenel-Audran M, Verret JL (1999). Colchicine for Sweet's syndrome. A study of 20 cases. *Br J Dermatol* 1999; 140: 565-566. ISSN 0007-0963 .
- Majeed HA, Kalaawi M, Mohanty D, Teebi AS, Tunjekar MF, Al-Gharbawy F, Majeed SA, Al-Gazzar AH. (1989). Congenital dyserythropoietic anemia and chronic recurrent multifocal osteomyelitis in three related children and the association with Sweet's syndrome in two siblings. *J Pediatr* 1989; 115: 730-734. ISSN 0022-3476.
- Marie I, Boyer A, Heron F, Joly P, Levesque H, Thomine E, Courtois H. (1998). Focal aseptic osteitis underlying neutrophilic dermatosis. *Br J Dermatol* 1998; 139: 744-745. ISSN 0007-0963
- McDermott MB, Corbally MT, O'Marcaigh AS. Extracutaneous Sweet syndrome involving the gastrointestinal tract in a patient with Fanconi's anemia. (2001). *J Pediatr Hematol Oncol* 2001; 23: 59-62. ISSN 1077-4114.
- Mizoguchi M, Matsuki K, Mochizuki M, Watanabe R, Ogawa K, Harada S, Hino H, Amagai M, Juji T. (1998). Human leukocyte antigen in Sweet's syndrome and its relationship to Behçet's disease. *Arch Dermatol* 1988; 124: 1069-73. ISSN 0003-987X.
- Mizuashi M, Sugawara M, Tanita M, Aiba S. (2010). A case of pustular vasculopathy. An atypical variant of Sweet's syndrome? *Int J Dermatol* 2010; 49:1461-3. ISSN 0011-9059.
- Mohr MR, Torosky CM, Hood AF, Cunnion KM, Fisher RG, Williams JV. (2010). Sweet syndrome in infancy. *Pediatr Dermatol* 2010; 27: 208-9. ISSN 0736-8046.
- Muster AJ, Bharati S, Herman JJ, Esterly NB, Gonzales-Crussi F, Holbrook KA. (1983). Fatal cardiovascular disease and cutis laxa following acute febrile neutrophilic dermatosis. *J Pediatr* 1983; 102: 243-248. ISSN 0022-3476.
- Nobeyama Y, Kamide R. (2003). Sweet's syndrome with neurologic manifestation: case report and literature review. *Int J Dermatol* 2003; 42: 438-443. ISSN 0011-9059.
- Peters FPJ, Drent M, Verhaegh M, van Pampus ECM, Schouten HC. (1998). Myelodysplasia presenting with pulmonary manifestations associated with neutrophilic dermatosis. *Ann Hematol* 1998; 77:135-138. ISSN 0939-5555.
- Ramos JC, Sanz J, Oliveira E, Garcia M. (2003). Meningitis aséptica y síndrome de Sweet. *Med Clin (Barc)* 2003; 121: 437. ISSN 0025-7753.
- Requena L, Kutzner H, Palmedo G, Pascual M, Fernández-Herrera J, Fraga J, García-Díez A, Yus ES. (2005). Histiocytoid Sweet syndrome: a dermal infiltration of immature neutrophilic granulocytes. *Arch Dermatol* 2005; 141: 834-42. ISSN 0003-987X.
- Requena L. Síndrome de Sweet histiocitoide. (2007). En Agustín España. Fisiopatología de las enfermedades cutáneas V. Aula Médica. Madrid, 2007. Pág 61-108. ISBN 978-84-7885-444-8.
- Romero G, López-Estebanz JL, De Pablo P, Ortiz JL, Vanaclocha F, Iglesias L. (1994). Dermatitis neutrofílica afebril crónica recurrente. *Actas Dermosifiliogr* 1994; 85: 305-308. ISSN 0001-7310.
- Sherertz EF. (1987). Pyoderma gangrenosum versus acute febrile neutrophilic dermatosis (Sweet's syndrome). *Am J Med* 1987; 83: 1011-2. ISSN 0002-9343.
- Shimizu K. (1998). Neutrophilic infiltration of the myocardium in a patient with myelodysplastic syndrome. *Am J Hematol* 1998; 58: 337-338. ISSN 0361-8609.
- Sitjas D, Cuatrecasas M, De Moragas JM. (1993). Acute febrile neutrophilic dermatosis (Sweet's syndrome). *Int J Dermatol* 1993; 32: 261-268. ISSN 0011-9059.

- Sobol UA, Sherman KL, Smith J, Nagda SN, Micetich K, Nickoloff BJ, Shoup MC. (2009). Sweet's syndrome with neurologic manifestations in a patient with esophageal adenocarcinoma: case report and review of the literature. *Int J Dermatol* 2009; 48: 1062-5. ISSN 0011-9059.
- Spencer B, Nanavati A, Greene J, Butler DF. (2008). Dapsone-responsive histiocytoid Sweet's syndrome associated with Crohn's disease. *J Am Acad Dermatol* 2008; 59 (2 SUPPL.): 558-560. ISSN 0190-9622.
- Su WPD, Liu HNH. (1986). Diagnostic criteria for Sweet's syndrome. *Cutis* 1986, 37:167-174. ISSN 0011-4162.
- Sweet RD. (1964). An acute febrile neutrophilic dermatosis. *Br J Dermatol* 1964; 76: 349-356. ISSN 0007-0963.
- Takahama H, Kanbe T. (2010). Neutrophilic dermatosis of the dorsal hands: a case showing HLA B54, the marker of Sweet's syndrome. *Int J Dermatol* 2010; 49: 1079-80. ISSN 0011-9059.
- Villanueva C, Monés J, Pujol R, Puig L, Such J, Sancho FJ. (1989). Erupción vesiculopustulosa y síndrome de Sweet asociado a 2 exacerbaciones de colitis ulcerosa en una mujer de 76 años. *Med Clin (Barc)* 1989; 93: 298-300. ISSN 0025-7753.
- von den Driesch P. (1994). Sweet's syndrome (acute febrile neutrophilic dermatosis). *J Am Acad Dermatol* 1994; 31: 535-556. ISSN 0190-9622.
- Walling HW, Snipes CJ, Gerami P, Piette WW. (2006). The relationship between neutrophilic dermatosis of the dorsal hands and Sweet syndrome. *Arch Dermatol* 2006; 142: 57-63. ISSN 0003-987X.
- Watanabe T, Nakashima K, Shindo M, Yoshida Y, Yamamoto O. (2009). Multiorgan involvement in Sweet's syndrome. *Clin Exp Dermatol* 2009; 34: e343-4. ISSN 0307-6938.
- Whittle CH, Beck GA, Champion RH. (1968). Recurrent neutrophilic dermatitis of face: a variant of Sweet's syndrome. *Br J Dermatol* 1968; 80: 806-810. ISSN 0007-0963.
- Wu AJ, Rodgers T, Fullen DR. (2008). Drug-associated histiocytoid Sweet's syndrome: A true neutrophilic maturation arrest variant. *J Cutan Pathol* 2008; 35: 220-4. ISSN 0303-6987.
- Zamora E, Martin L, de Castro A, Barat A. (1990). Síndrome de Sweet. Estudio de 10 casos y revisión de la literatura. *Rev Clin Esp* 1990, 186:264-269. ISSN 0014-2565.



## **Autoimmune Disorders - Current Concepts and Advances from Bedside to Mechanistic Insights**

Edited by Dr. Fang-Ping Huang

ISBN 978-953-307-653-9

Hard cover, 614 pages

**Publisher** InTech

**Published online** 14, November, 2011

**Published in print edition** November, 2011

Autoimmune disorders are caused due to break down of the immune system, which consequently fails in its ability to differentiate "self" from "non-self" in the context of immunology. The diseases are intriguing, both clinically and immunologically, for their diversified clinical phenotypes and complex underlying immunological mechanisms. This book offers cutting-edge information on some of the specific autoimmune disease phenotypes, respective diagnostic and prognostic measures, classical and new therapeutic options currently available, pathogenesis and underlying mechanisms potentially involved, and beyond. In the form of Open Access, such information is made freely available to clinicians, basic scientists and many others who will be interested regarding current advances in the areas. Its potential readers will find many of the chapters containing in-depth analysis, interesting discussions and various thought-provoking novel ideas.

### **How to reference**

In order to correctly reference this scholarly work, feel free to copy and paste the following:

Manuel Ginarte and Jaime Toribio (2011). Sweet Syndrome, Autoimmune Disorders - Current Concepts and Advances from Bedside to Mechanistic Insights, Dr. Fang-Ping Huang (Ed.), ISBN: 978-953-307-653-9, InTech, Available from: <http://www.intechopen.com/books/autoimmune-disorders-current-concepts-and-advances-from-bedside-to-mechanistic-insights/sweet-syndrome>

**INTECH**  
open science | open minds

### **InTech Europe**

University Campus STeP Ri  
Slavka Krautzeka 83/A  
51000 Rijeka, Croatia  
Phone: +385 (51) 770 447  
Fax: +385 (51) 686 166  
[www.intechopen.com](http://www.intechopen.com)

### **InTech China**

Unit 405, Office Block, Hotel Equatorial Shanghai  
No.65, Yan An Road (West), Shanghai, 200040, China  
中国上海市延安西路65号上海国际贵都大饭店办公楼405单元  
Phone: +86-21-62489820  
Fax: +86-21-62489821



© 2011 The Author(s). Licensee IntechOpen. This is an open access article distributed under the terms of the [Creative Commons Attribution 3.0 License](https://creativecommons.org/licenses/by/3.0/), which permits unrestricted use, distribution, and reproduction in any medium, provided the original work is properly cited.

IntechOpen

IntechOpen