

# We are IntechOpen, the world's leading publisher of Open Access books Built by scientists, for scientists

6,900

Open access books available

186,000

International authors and editors

200M

Downloads

Our authors are among the

154

Countries delivered to

TOP 1%

most cited scientists

12.2%

Contributors from top 500 universities



WEB OF SCIENCE™

Selection of our books indexed in the Book Citation Index  
in Web of Science™ Core Collection (BKCI)

Interested in publishing with us?  
Contact [book.department@intechopen.com](mailto:book.department@intechopen.com)

Numbers displayed above are based on latest data collected.  
For more information visit [www.intechopen.com](http://www.intechopen.com)



# **Eosinophilic Bronchiolitis in Asthma - A Patient with Bronchial Asthma in whom Eosinophilic Bronchitis and Bronchiolitis Developed During Treatment**

Yasutsugu Fukushima and Kuniyoshi Kamiya  
*Department of Pulmonary Medicine and Clinical Immunology,  
 Dokkyo University School of Medicine, Tochigi,  
 Japan*

## **1. Introduction**

Eosinophilic lung disease shows diverse pathological characteristics and chest imaging findings. It can be caused by various factors, including parasitic and fungal infections, allergies, drugs, radiation, hazardous materials, smoking, vasculitis, or be idiopathic. Among potential causes, allergic bronchopulmonary mycosis and allergic granulomatous vasculitis/Churg-Strauss syndrome are also associated with bronchial asthma. In 2001, chronic eosinophilic bronchiolitis was proposed as an atypical eosinophilic lung disease (Takayanagi et al., 2001). Subsequently, similar cases have been accompanied by asthma-like symptoms and dyspnea, suggesting an association with bronchial asthma (Nakagome et al., 2003; Nagata et al., 2004; Tsuburai et al., 2006; Morimoto et al., 2006). We describe a case of bronchial asthma that showed diffuse centrilobular granular shadows and airway thickening on computed tomography (CT) of the chest and was diagnosed as eosinophilic bronchitis/bronchiolitis on histopathological examination.

## **2. Case report of eosinophilic bronchiolitis in asthma**

The patient was a 56-year-old woman. Her main symptoms were dyspnea, wheezing, and a productive cough. The patient had a history of acute appendicitis at 20 years of age and sinusitis at 52 years. The family history was not relevant to the present disorder. As for lifestyle, the patient did not smoke or drink alcohol. She kept two dogs as pets outside of her home and was employed as an office worker.

Bronchial asthma was diagnosed 8 years previously and the patient had been treated by a local physician. She had been hospitalized 4 times for asthma attacks. Since November 2005, the patient received inhaled corticosteroids, a long-acting inhaled  $\beta_2$ -agonist, leukotriene modifiers, and theophylline in accordance with guidelines for the treatment of asthma. Because the patient had frequent exacerbations, she was referred to our hospital in July 2006.

The physical findings on admission were as follows: height, 155.1 cm; body weight, 57.0 kg; body mass index, 23.7; body temperature, 36.8°C; blood pressure, 120/80 mmHg; pulse rate, 80 beats/min; respiratory rate, 24 times/min; and SaO<sub>2</sub>, 94%. The patient's consciousness

was clear. Grade III wheezing was present in both lung fields, with no cardiac murmur. The abdomen was flat and soft, with no tenderness. There was no edema in the extremities. The neurological findings were normal.

The results of blood tests were as follows: white cell count,  $8.2 \times 10^9/L$  (neutrophils, 40.9%; eosinophils, 35.4%, lymphocytes, 19.3%; and monocytes, 4.0%); hemoglobin, 13.7 g/dL; hematocrit, 41.1%; platelets,  $329 \times 10^9/L$ ; serum total protein, 7.4 g/dL; serum aspartate aminotransferase, 16 U/L; serum alanine aminotransferase, 10 U/dL; serum lactate dehydrogenase, 190 U/L; C-reactive protein, 0.44 mg/dL; antinuclear antibody titer, 1:80; myeloperoxidase antineutrophil cytoplasmic antibody titer, <10 EU; proteinase 3-antineutrophil cytoplasmic antibody titer, <10 EU; and IgE, 411 IU/mL. Anti-SS-A/B antibody, aspergillus antibody, aspergillus-precipitating antibody, and human T-cell leukemia virus type-1 antibody were all negative. Radioallergosorbent testing showed that specific IgE antibodies to house dust, *Dermatophagoides pterynissinus*, aspergillus, candida, alternaria, cedar, ragweed, wormwood, orchard grass, cat dander, dog dander, and moth were negative. Blood gas values while the patient was breathing room air were as follows: pH, 7.43; PaCO<sub>2</sub>, 31.8 Torr; and PaO<sub>2</sub>, 69.8 Torr. Sputum cultures showed normal flora.

The results of lung function tests were as follows: VC, 1.84 L (74.1%); FEV<sub>1</sub>, 0.72 L (35.1%); FEV<sub>1</sub>%(G), 47.4%; and %DLCO, 77.1%. On airway hyperreactivity testing (acetylcholine inhalation test), the PC<sub>20</sub> was 2800 µg/mL. The exhaled nitric oxide concentration (eNO) was 184.4 ppb. The CXR and the HRCT findings on admission are shown in Figure 1. On bronchoscopy the numbers of cells in the bronchoalveolar lavage (BAL) fluid were as follows: total cell count,  $12.6 \times 10^5/mL$ ; monocytes, 22.9%; neutrophils, 0.4%; lymphocytes, 7.4%; and eosinophils, 68.7%. Histopathological findings of transbronchial lung biopsy (TBLB) specimens and transbronchial biopsy (TBB) specimens are shown in Figure 2.

### 3. Course after admission

The patient had symptoms of bronchial asthma such as dyspnea, wheezing, and hypoxemia on admission. Chest imaging studies showed bronchial and bronchiolar lesions. Since the patient had peripheral-blood eosinophilia, a diagnosis of eosinophilic bronchiolitis, recently proposed as a distinct clinical entity, was suspected.

Bronchoscopy was performed on the 6th day. There was an increased total cell count in the BAL fluid, and the proportion of eosinophils had risen by 68.7%. TBLB and TBB suggested bronchitis/bronchiolitis with eosinophilic infiltration. There was no evidence of allergy to aspergillus or other fungi and no peripheral neuritis or vasculitis. Allergic bronchopulmonary mycosis and allergic granulomatous vasculitis were thus unlikely. Since airway hyperreactivity was confirmed on an acetylcholine inhalation test, bronchial asthma associated with eosinophilic bronchiolitis was diagnosed.

The patient received fluticasone (400 µg/d) since the date of admission, and prednisolone (40 mg/d) was started immediately after bronchoscopy. After starting treatment, symptoms improved dramatically. Dyspnea and wheezing decreased in several days and oxygen inhalation was stopped after 5 days of prednisolone treatment. The peripheral eosinophil count decreased from  $2902 \times 10^6/L$  to  $47 \times 10^6/L$  after 7 days of treatment. There was also improvement in the shadows on the chest images, as well as lung function. The eNO level decreased from 184.4 to 42.9 ppb. The dose of prednisolone was tapered, and hydrofluoroalkane(HFA)-beclomethasone (200 µg/d) was added to fluticasone. The condition of the patient improved substantially, and she was discharged.

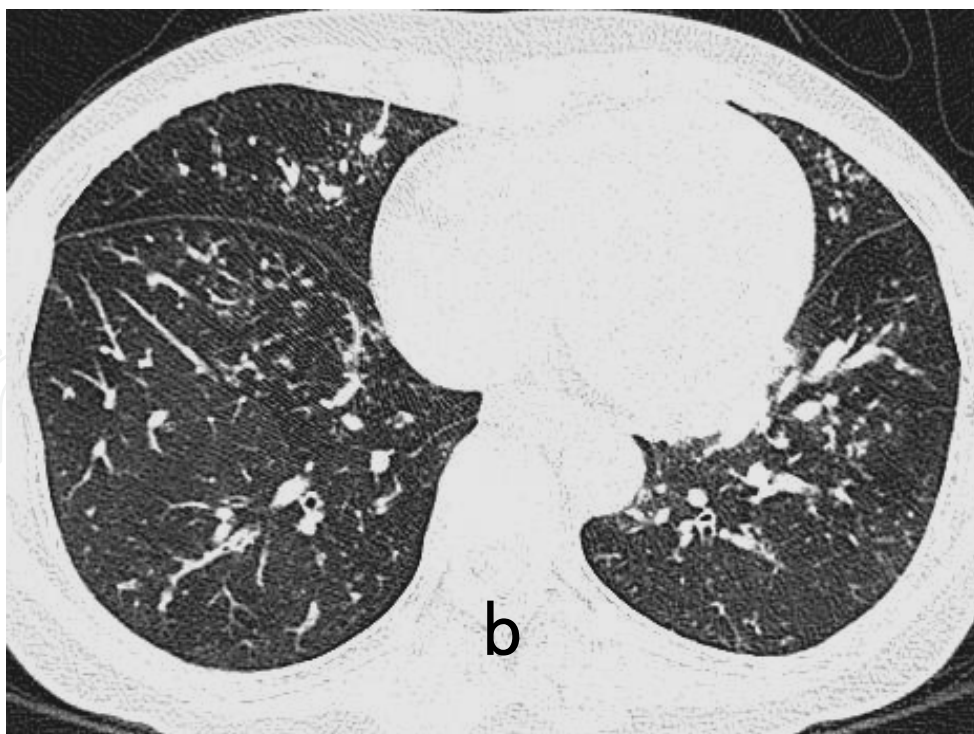
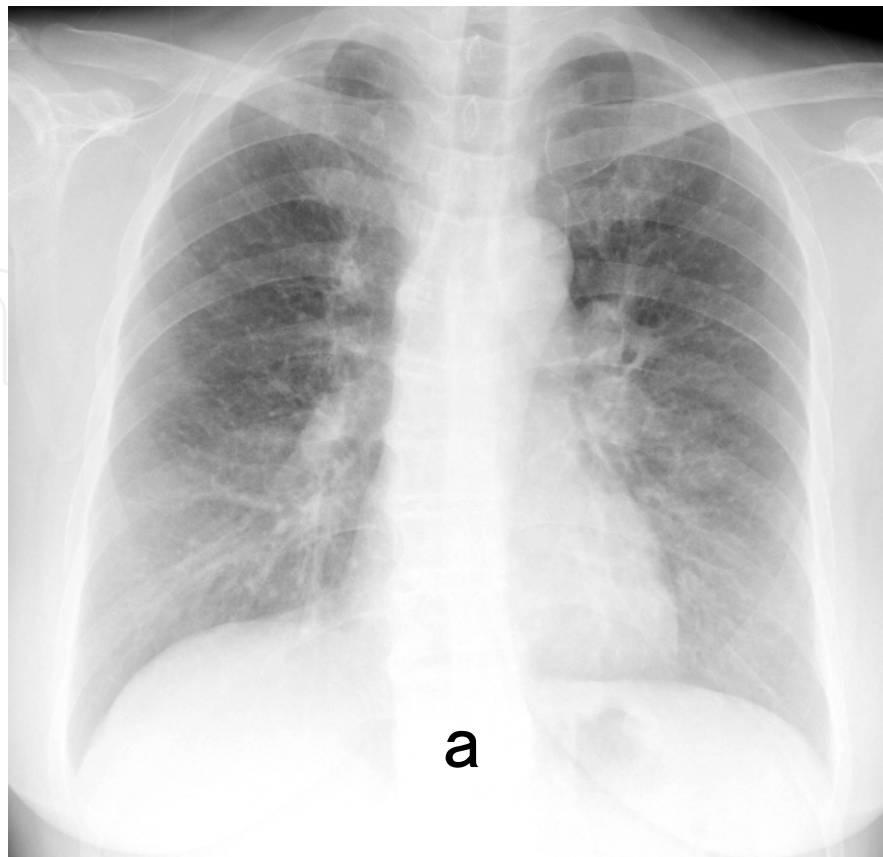
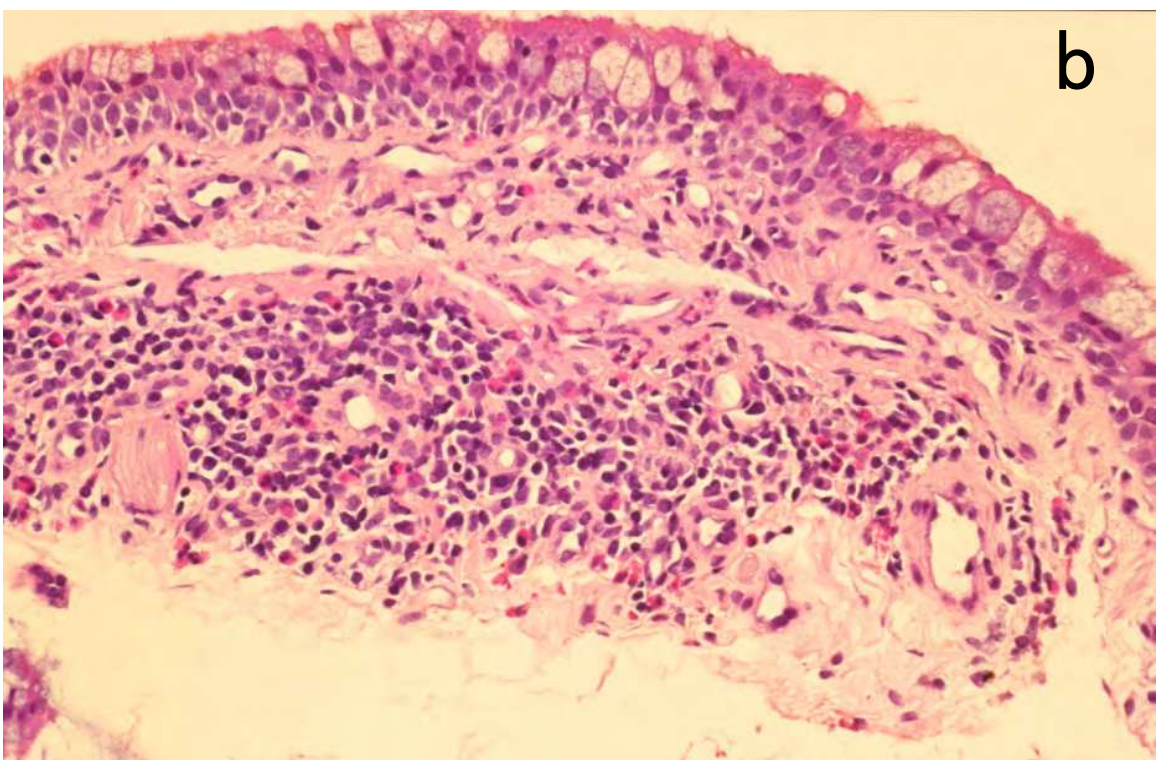
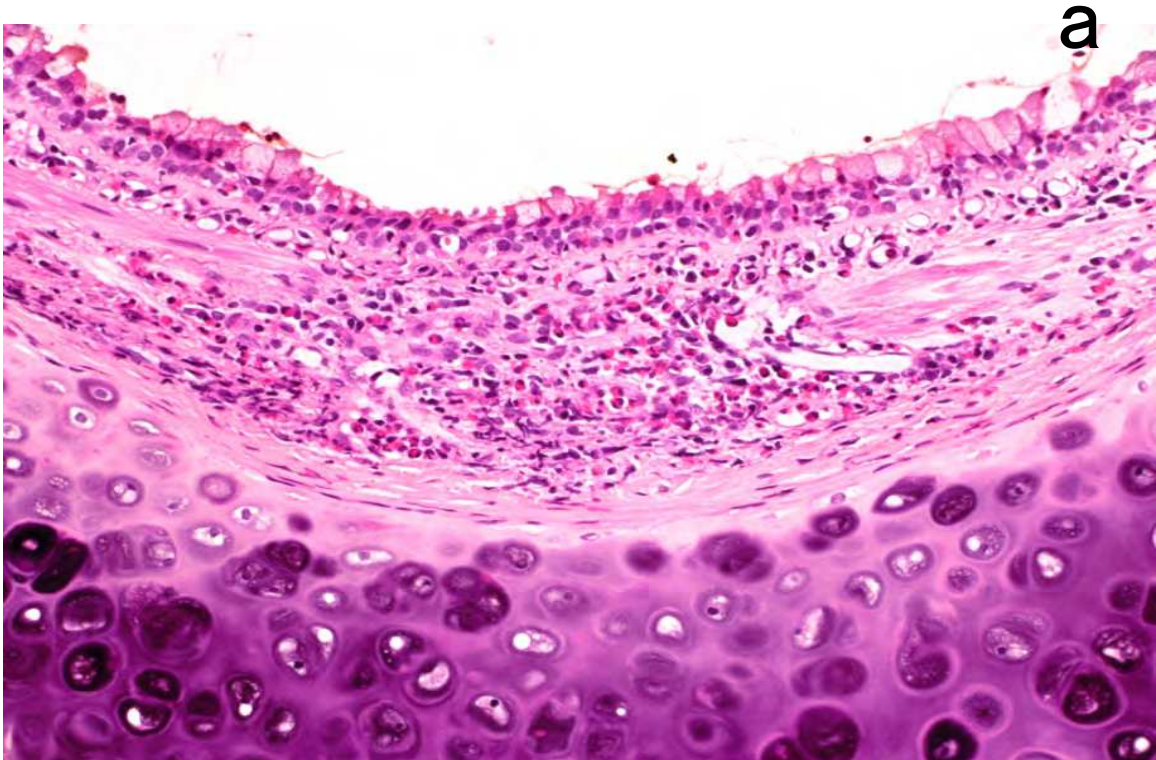


Fig. 1. Chest X-ray and HRCT on admission (a). CXR showed diffuse granular shadows in bilateral lung fields. (b). Chest HRCT scan showed diffuse centrilobular nodules in both lung fields in association with thickening of the bronchi and bronchioles.





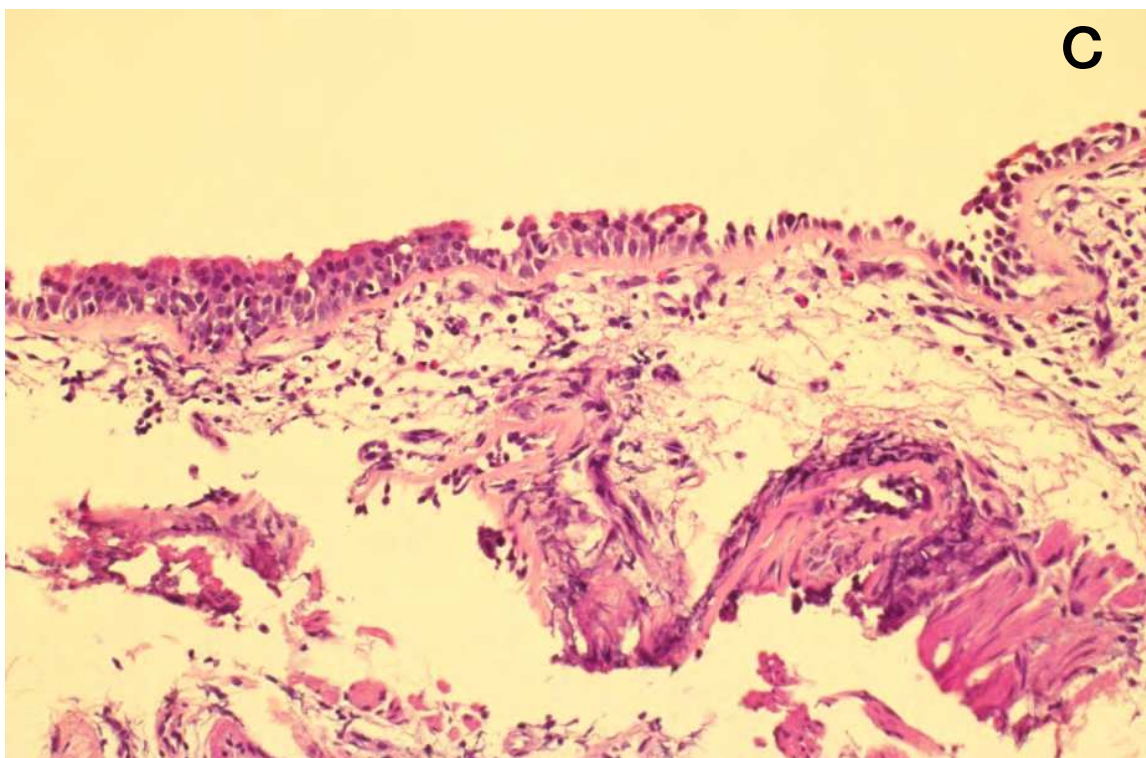


Fig. 2. Photomicrographs of TBB and TBLB specimen. (a). Significant infiltration of eosinophil is observed in the bronchial mucosal and submucosal membrane region (HE staining x100). (b). Goblet cell metaplasia is observed in the bronchiolar epithelium, and eosinophil/monocyte infiltration is observed in the subepithelial region (HE staining x200). (c). Epithelial detachment, basal membrane thickening, and eosinophil/mononuclear lymphocyte infiltration are observed in the membranous bronchiole (HE staining x200).

#### 4. Discussion

Recently, several cases of eosinophilic bronchiolitis have been reported in Japan (Table 1). Common characteristics include bronchiolitis with eosinophilic infiltration (on imaging studies and histopathological examination), obstructive ventilatory impairment, airway hyperreactivity, and blood and BAL-fluid eosinophilia. Clinically, eosinophilic bronchiolitis must be differentiated from various other diseases associated with eosinophilic infiltration and from various types of bronchiolitis and bronchial asthma. Although the radiographic findings in our patient, who had a history of sinusitis, resembled those in diffuse panbronchiolitis (DPB), the histological findings were not consistent with DPB, which is characterized by accumulations of mononuclear cells (predominantly lymphocytes, plasma cells and foamy histiocytes) in the walls of respiratory bronchioles.

The histological evaluation of TBLB specimens such as those obtained in our patient has inherent limitations as compared with lung biopsy specimens obtained surgically, in which the walls of bronchioles can undergo complete microscopical examination. Inhaled steroids



alone are not adequately effective in many patients; a moderate dose of oral steroids is usually very effective. However, decreasing the dose of steroids often triggers a recurrence, suggesting that long-term therapy with a maintenance dose of steroids is necessary. Our patient did not respond to guideline-based treatment for asthma at other clinics. However, the patient showed airway hyperreactivity, and the eNO level had increased to 184.4 ppb at admission (Rodway et al., 2009). The clinical features and the results of laboratory and histopathological examinations led to a diagnosis of bronchial asthma associated with eosinophilic bronchiolitis. In 5 previously reported cases (Table 1), not including the present one, biopsy specimens of the lung were obtained under video-assisted thoracoscopic guidance. This is a very useful technique for obtaining a sufficient quantity of peripheral lung lobules for histological examination, but is more invasive than bronchoscopic lung biopsy. Fortunately, we could make a diagnosis by bronchoscopic TBLB and TBB. The patient responded to treatment with 40 mg of oral prednisolone and is currently also receiving fluticasone and HFA-beclomethasone (considering delivery to the peripheral airways). The dosage of oral prednisolone was decreased to 2.5 mg on alternative days.

Case	Age /Sex	Present signs and symptoms	Bronchial asthma	Time to EB Onset	Therapy	Outcome	Year Author
1	46 /M	Dyspnea, wheeze, cough	- (Airway hyper-reactivity +)	3 years	Oral PSL 40 mg	Recurrence Dose of PSL decreased	2001 Takayanagi <i>et al</i>
2	23 /M	Dyspnea, wheeze, cough	- (Airway hyper-reactivity +)	3 months	Oral PSL 30 mg ICS	Recurrence Dose of PSL decreased	2003 Nakagome <i>et al</i>
3	62 /F	Dyspnea, cough	+	4 years	mPSL 80 mg d.i.v. Oral PSL, ICS	Recurrence Dose of PSL decreased	2004 Nagata <i>et al</i>
4	50 /F	Chest shadow	+	5 years	Hydrocortisone 300 mg d.i.v. Oral PSL 30 mg	No recurrence	2006 Tsuburai <i>et al</i>
5	42 /M	Dyspnea, cough	+	6 months	Oral PSL 30 mg	Recurrence Dose of PSL decreased	2006 Morimoto <i>et al</i>
6*	56 /F	Dyspnea, wheeze, cough	+	8 years	Oral PSL 40mg ICS	No recurrence	Present case

EB, eosinophilic bronchiolitis; PSL, prednisolone; mPSL, methylprednisolone; ICS, inhaled corticosteroids; d.i.v., drip intravenous infusion.

Table 1. Clinical characteristics of patients with EB reported in previous studies, including present case\*

Since the late 1990's, eosinophilic airway inflammation, a cardinal sign of bronchial asthma, has been confirmed in the peripheral as well as the central airways (Hamid et al., 1997; Travis et al., 2002). The bronchiolar region may also be involved in asthma (International Consensus Report on Diagnosis and Treatment of Asthma, 1992). However, cases showing centrilobular granular shadows on chest CT scans have not been studied in detail. Eosinophilic bronchiolitis was first reported in 2001, and several other similar cases were subsequently reported in Japan (Takayanagi et al., 2001; Nakagome et al., 2003; Nagata et al., 2004; Tsuburai et al., 2006; Morimoto et al., 2006). The present case was introduced because we believe that it satisfies the proposed diagnostic criteria. Studies of additional cases of eosinophilic bronchiolitis are necessary to establish the concept for this disease and to further elucidate its pathophysiology and thereby determine whether eosinophilic bronchiolitis should be classified as a subtype of bronchial asthma or as a distinct entity.

## 5. Conclusion

We described a case of bronchial asthma that showed diffuse centrilobular granular shadows and airway thickening on CT of the chest and was diagnosed as eosinophilic bronchitis/bronchiolitis on histopathological examination. Recently, several cases of eosinophilic bronchiolitis associated with bronchial asthma have been reported. But further studies should be needed to elucidate the pathogenesis and pathophysiology of eosinophilic bronchitis/bronchiolitis.

## 6. References


- Hamid, Q., Song, Y., Kotsimbos, TC., Minshall, E., Bai, TR. *et al.* (1997). Inflammation of small airways in asthma. *J Allergy Clin Immunol*, Vol.100, No.1, (July 1997), pp.44-51.
- International Consensus Report on Diagnosis and Treatment of Asthma. (1992). *Clin Exp Allergy*, Vol.22 (suppl1), pp.1-72.
- Morimoto, K., Oota, K., Sakamoto, T., Kamiya, H., Ando, T. *et al.* (2006). A case of eosinophilic bronchiolitis complicated with eosinophilic sinusitis. *Nihon Kokyuki Gakkai Zasshi*, Vol.44, No.12, (December 2006), pp.980-984 (in Japanese).
- Nagata, N., Harada, S., Wakamatsu, K., Shigyo, M., Kajiki, A. *et al.* (2004). Case of chronic eosinophilic bronchiolitis associated with bronchial asthma. *Nihon Kokyuki Gakkai Zasshi*, Vol.42, No.8, (August 2004), pp.767-771 (in Japanese).
- Nakagome, K., Yamaguchi, M., Shimada, K., Komiya, A., To, Y. *et al.* (2003). A case of eosinophilic lung disease presenting asthma-like symptoms and centrilobular shadows in both lung fields. *Nihon Kokyuki Gakkai Zasshi*, Vol.41, No.10, (October 2003), pp.722-727 (in Japanese).
- Rodway, G., Choi, J., Hoffman, L., Sethi, J. (2009). Exhaled nitric oxide in the diagnosis and management of asthma: clinical implications. *Chron Respir Dis*, Vol.6, No.1, pp.19-29.
- Takayanagi, N., Kanazawa, M., Kawabata, Y., Colby, TV. (2001). Chronic bronchiolitis with associated eosinophilic lung disease (eosinophilic bronchiolitis). *Respiration*, Vol.68, No.3, pp. 319-322.
- Travis, WD., Colby, TV., Koss, NM. (2002). Bronchiolar disorders. In: Travis WD, Colby TV, Koss MN. eds, *Non-Neoplastic Disorders of the Lower Respiratory Tract*. ARP and AFIP, Washington, 351-380.



Tsuburai, T., Kawabata, Y., Tsurikisawa, N., Mitomi, H., Oshikata, C. *et al.* (2006). Case of eosinophilic bronchitis and bronchiolitis associated with increased level of serum CEA in asthmatics. *Nihon Kokyuki Gakkai Zasshi*, Vol.44, No.10, (October 2006), pp.742-748 (in Japanese).

IntechOpen

IntechOpen



## **Approaches to Bronchitis**

Edited by Prof. Marianna Gañsa

ISBN 978-953-307-770-3

Hard cover, 70 pages

**Publisher** InTech

**Published online** 17, October, 2011

**Published in print edition** October, 2011

The aim of this book is to present some recent and interesting findings in the field of bronchitis, which will serve as a supplement to the book Bronchitis. In particular, this volume focuses on the successful use and development of novel tools in the diagnostics and treatment of bronchitis. Contributions include clinical case studies, the impact of air pollution on bronchitis, the presentation and diagnosis of the respiratory disease eosinophilic bronchiolitis, primary ciliary dyskinesia, the development of a method for the swift detection of the infectious bronchitis virus and studies investigating the successful use of alternative medicines in the treatment of bronchitis. The editor would like to thank the authors of the chapters who have contributed to this book and hopes that this will book not only supplement the book on Bronchitis, but may increase interest in the subject.

### **How to reference**

In order to correctly reference this scholarly work, feel free to copy and paste the following:

Yasutsugu Fukushima and Kuniyoshi Kamiya (2011). Eosinophilic Bronchiolitis in Asthma - A Patient with Bronchial Asthma in whom Eosinophilic Bronchitis and Bronchiolitis Developed During Treatment, Approaches to Bronchitis, Prof. Marianna Gañsa (Ed.), ISBN: 978-953-307-770-3, InTech, Available from: <http://www.intechopen.com/books/approaches-to-bronchitis/eosinophilic-bronchiolitis-in-asthma-a-patient-with-bronchial-asthma-in-whom-eosinophilic-bronchitis>

**INTECH**  
open science | open minds

### **InTech Europe**

University Campus STeP Ri  
Slavka Krautzeka 83/A  
51000 Rijeka, Croatia  
Phone: +385 (51) 770 447  
Fax: +385 (51) 686 166  
[www.intechopen.com](http://www.intechopen.com)

### **InTech China**

Unit 405, Office Block, Hotel Equatorial Shanghai  
No.65, Yan An Road (West), Shanghai, 200040, China  
中国上海市延安西路65号上海国际贵都大饭店办公楼405单元  
Phone: +86-21-62489820  
Fax: +86-21-62489821

© 2011 The Author(s). Licensee IntechOpen. This is an open access article distributed under the terms of the [Creative Commons Attribution 3.0 License](https://creativecommons.org/licenses/by/3.0/), which permits unrestricted use, distribution, and reproduction in any medium, provided the original work is properly cited.

IntechOpen

IntechOpen