

We are IntechOpen, the world's leading publisher of Open Access books Built by scientists, for scientists

6,900

Open access books available

186,000

International authors and editors

200M

Downloads

Our authors are among the

154

Countries delivered to

TOP 1%

most cited scientists

12.2%

Contributors from top 500 universities



WEB OF SCIENCE™

Selection of our books indexed in the Book Citation Index
in Web of Science™ Core Collection (BKCI)

Interested in publishing with us?
Contact book.department@intechopen.com

Numbers displayed above are based on latest data collected.
For more information visit www.intechopen.com



UTI in Children

Samileh Noorbakhsh and Vida Zarabi
*Research Center of Pediatric Infectious Diseases,
 Tehran University of Medical Sciences, Tehran,
 Iran*

1. Introduction

Urinary tract infection is common in children. Before the age of 6 months; boys are more susceptible to UTI than girls thereafter, the incidence is substantially higher in girls than in boys. Up to 11.3% of girls and 3.6% of boys studied in UK will have had an UTI by age 16 years. UTI is usually caused by gram-negative organisms, especially *Escherichia coli* which accounts for about 80% of all pathogens. *Proteus* is more common in boys. (1, 2)

In childhood, upper UTI with 5.3% prevalence rate, are one of the most important causes of hospitalization. Although acute pyelonephritis might presents with fever, lethargy, anorexia, and vomiting but there are no certain specific diagnostic laboratory tests and clinical symptoms for diagnosis of UTI (1, 2)

Untreated upper UTI can produce severe renal damages. Delay in treatment of acute pyelonephritis increases the risk of kidney damage. Complications of acute pyelonephritis include intra renal and peri renal abscess. Early diagnosis and treatment of urinary tract infection in children is important (3, 4)

Recurrent UTI is defined as a further infection by a new organism. Relapsing UTI is defined as a further infection with the same organism. (1-5)

Uncomplicated UTI infection requires no imaging and often shows no imaging abnormalities. Children who fail to respond to treatment or are severely ill need imaging evaluation (11) Obstructive anomalies are found in up to 4%, and vesico ureteral reflux in 8% to 40% of those with first urinary tract infection. Acute pyelonephritis and reflux are two synergistic factors in the destruction of kidneys of children (1-5)

In children, vesico ureteral reflux of infected urine is the most common cause of chronic pyelonephritis and chronic interstitial nephritis. Intra renal reflux induces reflux nephropathy, progressive renal injury and cortical scarring. Reflux nephropathy usually observed as a focal cortical scar that overlies a blunted calyx in the upper pole of kidney (11) Imaging findings in children with reflux nephropathy is similar to chronic pyelonephritis in adults. Both type of nephropathy are best demonstrated on IVP or US and CT as classically lobar, with normal lobes with normal calyces interposed between diseased lobes. (11-17) CT is more sensitive than Ultrasound in demonstrating subtle changes in the renal parenchyma associated with uncomplicated pyelonephritis. CT is normal in some patients with mild uncomplicated pyelonephritis. Complications such as renal or peri renal abscess are well demonstrated by CT or US (17)

Although imaging studies have been considered after the diagnosis of a first urinary tract infection, the effect of such studies on outcome has been unclear. Recently, low radiation procedures recommended for diagnosis of VUR (18)

Urinary tract infections accounting for a considerable percentage of antibiotic prescriptions in some countries (18-30)

The prevalence of resistant gram negative organisms is increased during last decade (19, 20)

The first febrile uncomplicated UTI in children is caused by E coli in 70% to 90% of cases. In recent studies a high rates of resistant uropathogens (other than E coli) to various antimicrobial agents in children received prophylactic antibiotics prophylaxis (21-24). So a high level of diagnostic accuracy is essential in view of the increasing prevalence of antibiotic resistance.

2. UTI diagnosis

The normal urinary tract is sterile. UTI is defined by pure growth of more than 10^5 colony forming units of bacteria per ml of urine. Urine culture is the gold standard for the diagnosis of UTI, but negative urine culture reported in up to 60 to 80% of UTI cases and urine culture is time-consuming (4, 5) In urine sample obtained by suprapubic aspiration any growth of urinary pathogens is clinically important. (6)

Upon Schmiemann et al opinion differentiating UTI from asymptomatic bacteriuria, which usually requires no treatment, can lower the frequency of unnecessary antibiotic prescriptions (7) Rapid urine tests, such as microscopy with Gram stain, for bacteria and white cells, and dipsticks, for leucocyte esterase and nitrites often used for diagnosis (6-7)

In recent years, fast screening methods that can reduce the necessity for urine cultures studied by some authors. The Sysmex UF-1000i is a urine flow cytometer that uses two separate channels for counting blood cells and bacteria such as microscopic examination and culture. (8-11)

Broeren et al reported the high percentage of false-negative results in screened negative urine samples with the sysmex UF-1000i urine flow cytometer. Broeren et al did not warrant the UF-1000i as a screening analyzer. (8) Indeed van der Zwet et al did not recommend urine flow cytometer for use in complicated patient populations, such as neutropenic patients and patients in whom yeast infection is suspected (9) Manoni et al studied 214 untreated urine samples using the Sysmex UF-1000i and compared with results obtained from quantitative manual microscopy using the Fuchs-Rosenthal counting chamber. They concluded automated urine particle analysis is sufficiently precise and improves the workflow in a routine laboratory (10) Williams et al determined that accuracy of microscopy for white cells is no better than that of dipstick. Up to 10% of children with a urinary tract infection had negative rapid tests. Rapid test cannot replace urine culture (11)

2.1 Diagnostic imaging studies

Acute pyelonephritis and reflux diagnosed by several imaging methods; ultrasonography, IVP, VCUG, CT, Doppler, DMSC scintigraphy and MRU. Danger of exposure to radiation is important in patients. Renal ultrasonography and renal scanning at the time of the acute illness are of limited value, because they do not provide information that modifies management (12-18)

3. Renal ultrasonography

Ultrasonography is a noninvasive test which routinely performed after the diagnosis of a first UTI. US has replaced IVP for evaluating the size and shape of the kidneys but is not

sensitive enough to detect the presence of hydronephrosis, hydroureter, acute pyelonephritis, or renal scarring (11) VUR which affects approximately 30 to 40 percent of young children cannot be consistently detected by US has been an important consideration in ultrasonography.

3.1 IVP (IV pyelography)

Excretory urography, the traditional method of imaging the kidneys replaced by non invasive and safe methods in last decades. However, US, CT, MR all provide better images of the renal parenchyma.

3.2 VCUG

VCUG is used to identify children with vesicoureteral reflux currently performed any time after three to four days of therapy.

Vesicoureteral reflux was graded according to the classification system of the international reflux international study committee. Prophylactic therapy recommended in children with at least grade ii VUR.

Otokesh et al compared voiding urosonography or cystosonography with radio nucleotide cystography for evaluation of VUR (12). Sensitivity and specificity of voiding urosonography was 87% and 88%, respectively, with a 94% positive predictive value and a 77% negative predictive value. It concluded that voiding urosonography is a highly accurate, safe and inexpensive tool for the screening, diagnosis and follow-up of VUR.

3.3 Renal DMSA scans

Acute pyelonephritis was defined by the presence of focal or diffuse areas of decreased uptake of labeled DMSA without evidence of cortical loss or by the presence of diffusely decreased uptake in an enlarged kidney (15).

DMSA scans obtained at presentation and six months later identify children with acute pyelonephritis and renal scarring. The degree of scarring was assessed quantitatively by outlining the scarred area (15).

The accuracy of renal artery resistive index (RI) in doppler ultrasonography with DMSA scan and VCUG for diagnosis of APN and reflux in pediatrics patients were assessed and compared. There is a significant relationship between increased RI and the severity of renal involvement.

3.4 MRU

In recent years, Dynamic gadolinium -MRU as a new alternative imaging method with free of radiation hazards presented by some authors. (16-18).

Dynamic gadolinium DTPA-enhanced MR urography has been shown to give high-quality views of the morphology of the obstructed urinary tract and an accurate evaluation of urinary excretion (17).

Zarabi et al observed good agreement between MRU and DMSA scan in results of IVP&VCUG. No agreement presented between MRU and DMSA scan with ultrasonographic studies. So, dynamic MRU might be a valuable method in diagnosis of urinary tract anomalies like as hydronephrosis, obstructive uropathy, congenital malformation, pyelonephritis, renal scar (18).

The contrast medium used in MRU is also less toxic and with fewer adverse effects than the radiographic contrast medium used in conventional IVP. Although the economic aspect is still problematic and needing for sedation, it is obvious that MR urography will continue to increase its role in clinical uro radiology. MR imaging offers a potential to reduce the need for invasive retrograde pyelography. (16-18)

4. UTI Treatment

UTI is caused by *E. coli* in over 80% of cases and treatment is a course of antibiotics. The uro pathogens other than *E. coli* in the gastrointestinal tract were selected while children were receiving antibiotic prophylaxis (1-4).

Due to acute illness caused by UTI and the risk of pyelonephritis-induced permanent kidney damage, many children are given long-term antibiotics for reducing the recurrence (5-7) The risk of delayed versus early treatment of acute pyelonephritis in children is not well defined and renal scarring would be investigated (8) The prophylactic antibiotic was not effective in reducing bacterial colonization of the prepuce. Some uro pathogens might have come from the external genitalia (19-20).

4.1 Modes of antibiotic administration

The optimal route for antibiotic therapy oral (PO) or intravenous (IV) versus intramuscular administration is not clear. Consensus guidelines from the 1990s still recommend IV antibiotics. (1-5)

The American Academy of Pediatrics recommended early antibiotic treatment, given parenterally if necessary in febrile infants and young children suspected of having a UTI (1-4).

Treatment failure for generally healthy young infants hospitalized with utis is uncommon and is not associated with the duration of intravenous antibiotic treatment. Severity of illness and the presence of known abnormalities of the genitourinary tract, but not young age, were associated with increased risk for treatment failure. (3, 4)

As intravenous antibiotic therapy is associated with side effects, toxicity, high cost, and long hospitalization period in treatment of UTIs (4,5) Switch therapy (intravenous-to-oral antibiotic) has been considered. Clinicians should consider PO antibiotics for these children who are nontoxic and have close parental and follow-up care. Treating more infants with short-course intravenous antibiotic therapy would decrease the length of hospitalization for children and families without affecting the readmission rate. (5, 6)

Recently, the national institute for health and clinical excellence published treatment guidelines advocating PO antibiotics in uncomplicated patients as young as three months of age controlled trials for choice of antibiotics in children with acute pyelonephritis. There are no data on PO antibiotics for UTIs in infants younger than one month of age due to higher risks of bacteremia, meningitis and nonspecific findings, these children would benefit from conservative IV antibiotics. (1-5)

Some authors reported no different results for renal scarring and serious adverse events between IV and PO antibiotic groups. PO antibiotic therapy for children with UTIs has the advantages of ease and cost over IV therapy. (24-30)

The lack of association between the length of intravenous antibiotic therapy and subsequent treatment failure reported in recent years. In a prospective, randomized trial the incidence of renal scars was similar in patients who received 3 days compared 8 days of intravenous

ceftriaxone. Increased renal height at initial ultrasound examination and grade 3 VUR were significant risk factors for renal scars. (28-30)

Hodson et al identified po antibiotics appear to be as effective as initial IV antibiotics for UTIs in children older than one month of age with no known structural urological abnormality. (24)

Perri et al reported the oral antibiotics equivalent to intravenous antibiotics for the initial management of pyelonephritis in children. Two nuclear radiologists interpreted the renal scans independently and resolved any discrepancies by consensus. (27)

VUR rather than antibiotic choices might affect renal scarring. There was no risk difference in renal scarring between treatment groups, despite the presence of VUR. However, these children have a higher risk of renal scarring than children without VUR. (28-30)

The standard antibiotic therapy was sequential IV cefotaxime or ceftriaxone for three days, followed by cefixime, amoxi-clavulanate or ceftibutin for either seven days or 11 days versus the same total duration with po antibiotics alone. (25-30)

Noorbakhsh et al (2004) compared the efficacy and safety of ceftriaxone with switch to cefixime, 8 mg/kg once a day with aminoglycoside therapy in urinary tract infections. Response rate in cases with switch therapy was higher than children treated with intravenous aminoglycoside (88% vs. 80%; p value = 0.82). Most of those patients had a favorable clinical/microbiologic response assessment at the 7 days post therapy. (25)

Mertz et al (26) reported the acceptable rate of response both clinically and microbiologically in children, who received ceftriaxone with switch to cefixime.

Cefixime, ceftibuten and amoxicillin / clavulanic acid recommended for oral antibiotics, or with short courses (2 to 4 days) of IV therapy followed by oral therapy. If IV therapy is chosen, single daily dosing with aminoglycosides is safe and effective. (25-30)

Cefixime is a third-generation oral cephalosporin that is highly active against a broad range of gram-negative and some gram-positive aerobic bacteria, and has a low rate of side effects. On the basis of the literature data, cefixime could be indicated in the treatment of UTIs in children either as monotherapy or as switch therapy. (25, 26)

Resistance to common PO antibiotics may be greater in UTI cases with prophylactic drugs (21-30). Several risk factors explained for the emergence of resistant organisms, including underlying genitourinary tract abnormalities, in-hospital treatment of UTI (19,20) previous antibiotic exposure, history of previous UTI. (21-23)

5. UTI management

The prevention of renal scars by early and appropriate antibiotics is essential. (1, 2) APN can induce irreversible renal scars, with a risk for hypertension or chronic renal failure at long-term follow-up. (3, 4)

In all children with a previous febrile urinary tract infection, the routine performance of urinalysis, urine culture, or both during subsequent febrile illnesses is needed. (4-10) However, different approaches to management considered on age of children: children under 1 year; young children (1-4, 5, or 7 years, depending on the information source); and older children (up to 12-16 years). [12-18]

Approximately 60 to 65 percent of imaging studies will be abnormal in children younger than 2 years who have a first febrile UTI (12-14). Currently DMSA scans, is the best way to detect renal scars, the percentage of residual renal scars after first APN episode has been

shown to vary between 25% and 60% (15) Parenchymal defects on DMSA reported in 36% of all involved kidneys and at least one scarred kidney in 59% of children with VUR. VUR was a weak predictor of renal damage in children admitted to hospital. Local or systemic immune problems are factors in the development of UTI. (14)

VUR runs in families. The incidence of reflux ranged from 26% in asymptomatic siblings to 86% in symptomatic (UTI) siblings in compare with a rate of less than 1% in the general population. No clear link has yet been established between specific genes and an adverse outcome. (14, 15)

5.1 Prophylactic treatment

A widespread practice has been to initiate long-term prophylactic antimicrobial therapy in children found to have VUR (1, 2) The currently recommended antibiotics, including co - trimoxazole, nitrofurantoin, and nalidixic acid or amoxicillin- clavulanate (5-7). Greater antimicrobial resistance observed in patients receiving antibiotic prophylaxis (21-23) Except in 1 study, with co- trimoxazole prophylaxis , decreased antimicrobial susceptibilities were as prominent as those in children receiving cephalexin or cefaclor prophylaxis. (19-23)

Although concerns have existed that VUR may be a risk factor for recurrent UTIs, recent findings had not showed an increased risk of treatment failure (eg recurrence of fever or positive urine culture) in children with VUR. (21-30)

Attitudes toward the use of prophylactic antibiotics had changed during last decade. Previous empirical approach, which has recently been questioned, was based on an international study conducted in the 1980s that compared medical management (i.e prophylactic antimicrobial therapy) with surgical management of VUR and did not include an observation group as a control. A meta - analyses in prevention and treatment of UTI had done. The usefulness of empirical prophylactic antimicrobial therapy had not confirmed by Masson et al study. (22)

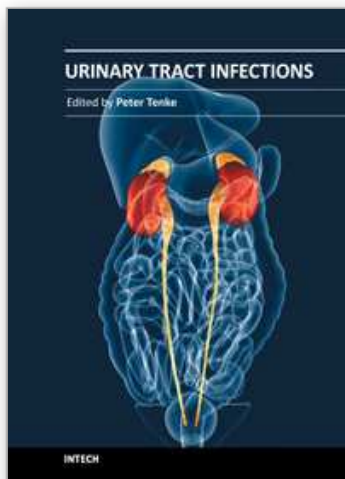
6. References

- [1] James larcombe. Urinary tract infection in children.Clinical evidence .Cochrane Data base syst Rev 2009
- [2] Sudhir K. Anand .urinary tract infections. Pediatrics, 2005, pages 738-742
Arc Int Med 2010: 8 ; 170 (5):489-90.
- [3] Gabrielle J. Williams, petra macaskill ,siew f chan. et al. absolute and relative accuracy of rapid urine tests for urinary tract infection in children: a meta-analysis. The Lancet Inf Dis :2010(10) 4:240 - 250
- [4] Drekonja DM, Okoye NC, Kuskowski MA, Johnson JR. Appropriateness of urinary tract infection diagnosis and treatment duration. Arch Intern Med 2010 :8; 170 (5):489-90.
- [5] F Bouissou, C Munzer, S Decramer, B Roussel Prospective, randomized trial comparing short and long intravenous antibiotic treatment of acute pyelonephritis in children: dimercaptosuccinic acid scintigraphic - Pediatrics, 2008 - Am Acad Pediatrics
- [6] Westwood ME, Whiting PF, Cooper J, Watt IS, Kleijnen J. Further investigation of confirmed urinary tract infection (UTI) in children under five years: a systematic review. C Pediatrics 2005 15; 5(1):2.
- [7] Schmiemann G, Kniehl E, Gebhardt K, Matejczyk MM, Hummers-Pradier E. Dtsch Arztebl Int. 2010 May;107(21):361-7. Epub 2010 May 28. The diagnosis of urinary tract infection: a systematic review.

- [8] MAC Broeren, S Bahceci, HL Vader. Screening for urinary tract infection with the sysmex UF-1000i urine flow cytometer. *J of Clinical Mic*, Volume 49, Issue 3, March 2011, Pages 1025-1029
- [9] Will C. van der Zwet, Jan Hessels, Fatih Canbolat, Martine M.L. Deckers. Clinical Evaluation of the Sysmex UF-1000i® urine flow cytometer in the diagnostic work-up of suspected urinary tract infection in a Dutch general hospital. *Chem and Lab Med*. Volume 48, Issue 12, Pages 1765-1771
- [10] Fabio Manoni, Agostino Tinello, Lucia Fornasiero, Paolo Hoffer, Valeria Temporin, Sara Valverde, Gianluca Gessoni. Urine particle evaluation: a comparison between the UF-1000i and quantitative microscopy. *Clinical Chemistry and Laboratory Medicine* Aug 2010, Vol. 48, No. 8, Pages 1107-1111
- [11] Malcolm G Coulthard, Andrew Nelson, Terry Smith. Point-of-care diagnostic tests for childhood urinary-tract infection: phase-contrast microscopy for bacteria, stick testing, and counting white blood cells. *Clini Pat* 2010 (63):823- 829.
- [12] Hang Luk, Yip Hin Woo, Wai San Au-Yeung, James Chi Sang Chan. Imaging in Pediatric Urinary Tract Infection: A 9-Year Local Experience. *Wing AnAJR*: 192, May 2009
- [13] Otukesh H, Hoseini R, Behzadi AH, et al. Accuracy of cystosonography in the diagnosis of vesico urethral reflux in children. *Saudi J Kidney Dis Transpl* . 2011 May; 22(3):488-91.
- [14] N Ataei, F Sayari-Fard, A Madani, S T Esfahani, M Khorasani, F Ataei. Scintigraphic screening in the detection of renal scarring in siblings of children with primary reflux. *Act Med Iranica* 2007;45(3): 219-226.
- [15] Chroustová D, Palyzova D, Urbanova I, Kolska M. Results of a five-year study of (99m)Tc DMSA renal scintigraphy in children and adolescents following acute pyelonephritis. *Nuc Med Rev Cent East Eur*. 2006; 9 (1):46 -50
- [16] Riccabona M. Pediatric MRU-its potential and its role in the diagnostic work-up of upper urinary tract dilatation in infants and children. *World J Urol*. 2004 Jun; 22(2):79-87
- [17] Vivier PH, Blondiaux E, Dolores M, Marouteau-Pasquier N, Brasseur M, Petitjean C, Dacher JN. Functional MR urography in children. *J Radiol* : 2009 ; 90(1 Pt 1):11-9.
- [18] V zarabi, S Noorbakhsh *, N Rahim Zadeh, K Samimi, M Ghafori, A Jafarian, A Tabatabaei. Diagnostic value of dynamic Magnetic Resonance Urogram imaging in children with Urinary Tract Infection *TUMJ* 2011, 69(2): 872-877
- [19] Chi-Hui Cheng, Ming-Horng Tsai, Yhu-Chering Huang, Lin-Hui Su, Yong-Kwei Tsau, Chi-Jen Lin, MD, Cheng-Hsun Chiu, Tzou-Yien Lin. Antibiotic Resistance Patterns of Community-Acquired Urinary Tract Infections in Children With Vesicoureteral Reflux Receiving Prophylactic Antibiotic Therapy. *PED* 2008, 122 (6):1212-1217
- [20] S Noorbakhsh, M Farhadi, A Tabatabaei. Determination of the MIC of antibiotics for gram negative microorganisms isolated from the sterile sites of children hospitalized in Rasool Akram hospital. *Iranian Journal of Pediatrics*, 2006; 16(4) : 419-425
- [21] Williams G, Craig JC. Long-term antibiotics for preventing recurrent urinary tract infection in children. *Update of Cochrane Database Sys Rev*. 2006; 3: CD001534

- [22] P. Masson, S. Matheson, A. Webster, J. Craig. Meta-analyses in Prevention and Treatment of Urinary Tract Infections. *INFECTIOUS DISEASE CLINICS OF NORTH AMERICA*, Volume 23, Issue 2, Pages 355-385.
- [23] W Gabrielle; Craig, Jonathan, Prevention of recurrent urinary tract infection in children. *Current Opinion in Inf Dis*: 2009 - Volume 22 - Issue 1 - p 72-76
- [24] Hodson EM, Willis NS, Craig JC. Antibiotics for acute pyelonephritis in children. *Cochrane Database Syst Rev*. 2007 Oct 17; (4): CD003772.
- [25] Noorbakhsh S, Lari AR, Masjedani F, Mostafavi H, Alaghebandan R. Comparison of intravenous aminoglycoside therapy with switch therapy of cefixime in urinary tract infections. *Saudi Med J*. 2004 Oct; 25(10):1513-519.
- [26] Mertz et al. Outcomes of early switching from intravenous to oral antibiotics on medical wards. *J ANTIMICROB CHEMOTHER* 2009; 64:188-199.
- [27] John D Perry, J Hom .Are oral antibiotics equivalent to intravenous antibiotics for the initial management of pyelonephritis in children? *Ped Child Health*: 2010 15(3): 150-152.
- [28] RA Santucci .New Concepts in Antimicrobial Treatment for Complicated Urinary Tract Infections: Single Daily Aminoglycoside Dosing and Switch Therapy. *Drug treatment in urology*, 2006 - books.google.com
- [26] A Pohl .Modes of administration for antibiotics for symptomatic severe urinary tract infections' *Evidence-Based Child Health: A Cochrane*; 2009
- [30] TJ Neuhaus, C Berger, K Buechner .Randomised trial of oral versus sequential intravenous/oral cephalosporins in children with pyelonephritis. *Eur J of Ped* 2008; 167(9):1037-1047.

IntechOpen



Urinary Tract Infections

Edited by Dr. Peter Tenke

ISBN 978-953-307-757-4

Hard cover, 360 pages

Publisher InTech

Published online 30, September, 2011

Published in print edition September, 2011

Urinary tract infections (UTIs) are among the most common bacterial infections worldwide, and they are also the leading cause of hospital-acquired infections. Therefore, the appropriate management of UTIs is a major medical and financial issue. This book covers different clinical manifestations of UTI, with special emphasis on some hard-to-treat diseases, and special conditions in respect of treatment; antibiotic resistance and the available alternative strategies for the prevention and treatment of UTIs and it deals with urinary tract infections in children. The aim of this book is to give a summary about the different aspects of the diagnosis, management and prevention of urinary tract infections for all medical disciplines.

How to reference

In order to correctly reference this scholarly work, feel free to copy and paste the following:

Samileh Noorbakhsh and Vida Zarabi (2011). UTI in Children, Urinary Tract Infections, Dr. Peter Tenke (Ed.), ISBN: 978-953-307-757-4, InTech, Available from: <http://www.intechopen.com/books/urinary-tract-infections/uti-in-children>

INTech
open science | open minds

InTech Europe

University Campus STeP Ri
Slavka Krautzeka 83/A
51000 Rijeka, Croatia
Phone: +385 (51) 770 447
Fax: +385 (51) 686 166
www.intechopen.com

InTech China

Unit 405, Office Block, Hotel Equatorial Shanghai
No.65, Yan An Road (West), Shanghai, 200040, China
中国上海市延安西路65号上海国际贵都大饭店办公楼405单元
Phone: +86-21-62489820
Fax: +86-21-62489821

© 2011 The Author(s). Licensee IntechOpen. This chapter is distributed under the terms of the [Creative Commons Attribution-NonCommercial-ShareAlike-3.0 License](https://creativecommons.org/licenses/by-nc-sa/3.0/), which permits use, distribution and reproduction for non-commercial purposes, provided the original is properly cited and derivative works building on this content are distributed under the same license.

IntechOpen

IntechOpen