

We are IntechOpen, the world's leading publisher of Open Access books Built by scientists, for scientists

6,900

Open access books available

186,000

International authors and editors

200M

Downloads

Our authors are among the

154

Countries delivered to

TOP 1%

most cited scientists

12.2%

Contributors from top 500 universities



WEB OF SCIENCE™

Selection of our books indexed in the Book Citation Index
in Web of Science™ Core Collection (BKCI)

Interested in publishing with us?
Contact book.department@intechopen.com

Numbers displayed above are based on latest data collected.
For more information visit www.intechopen.com



Aflatoxins and Aflatoxicosis in Human and Animals

D. Dhanasekaran¹, S. Shanmugapriya¹,
N. Thajuddin¹ and A. Panneerselvam²

¹Department of Microbiology, School of Life Sciences,
Bharathidasan University, Tiruchirappalli,

²P.G. & Research Department of Botany & Microbiology,
A.V.V.M. Sri Pushpam College, (Autonomous), Poondi, Thanjavur District, Tamil Nadu
India

1. Introduction

Moldy feed toxicosis was recognized as a serious livestock problem in the 1950's but it was only in 1960 during the investigations in the United Kingdom of moldy feed toxicosis which was called Turkey "x" disease, that *A. flavus* and *A. parasiticus* were identified as the organisms responsible for the elaboration of the toxin in the feed. The earliest symptoms of the disease are lethargy and muscular weakness followed by death. The term aflatoxin now refers to group of bisfuranocoumarin metabolites isolated from strains of *A. flavus* group of fungi. The toxic material derived from the fungus *A. flavus* was given the name "aflatoxin" in 1962 (Sargeant *et al.*, 1963).

Aflatoxins fluoresce strongly in ultra violet light. The major members are designated as B1, B2, G1 and G2. B1 and B2 fluoresces blue, while G1 and G2 fluoresces green. In some animal species in dairy cattle, aflatoxin B1 and B2 are partially metabolized to the hydroxylated derivatives namely M1 and M2, respectively.

Aflatoxin P1 is a urinary metabolite of B1 in monkeys. All aflatoxins absorb UV light in the range of 362-363nm, a characteristic used in preliminary identification. The growth of toxigenic molds and elaboration of the toxin occurs if moisture conditions are ideal following harvest and storage.

Although initially aflatoxin was detected in the peanut meal it is now known that a variety of cereals, and other plant products are susceptible to fungal invasion and mycotoxin production. The occurrence of aflatoxins in agricultural commodities depends on such factors as region, season and the conditions under which a particular crop is grown, harvested or stored.

Because of the wide spread nature of fungi producing aflatoxins in food materials, international agencies have now permitted the presence of 20 ppb of aflatoxin in food materials as the maximum permissible level. In 1993 aflatoxin by the World Health Organization (WHO) for cancer research institutions designated as a Class 1 carcinogen, is a highly poisonous toxic substances. Aflatoxin is harmful to human and animal liver tissue

has damaging effects, serious, can lead to liver cancer or even death. In the natural food contaminated with aflatoxin B1 is most common, is also its most toxic and carcinogenic.

2. Occurrence of aflatoxin in food and feed

Aflatoxin found in soil, plants and animals, all kinds of nuts, especially peanuts and walnuts. In soybean, rice (Fouzia Begum & Samajpati, 2000), corn, pasta, condiments, milk, dairy products, edible oil products are also often found aflatoxin. Aflatoxins often occur in crops in the field prior to harvest. Post harvest contamination can occur if crop drying is delayed and during storage of the crop if water is allowed to exceed critical values for the mould growth. Insect or rodent infestations facilitate mould invasion of some stored commodities.

Aflatoxins are found occasionally in milk, cheese, peanuts, cottonseed (Fig. 1), nuts, almonds, figs, spices, and a variety of other foods and feeds. Milk, eggs, and meat products are sometimes contaminated because of the animal consumption of aflatoxin contaminated feed. Cottonseed, Brazil nuts, copra, various tree nuts and pistachio nuts are the other commodities quite susceptible to the invasion of aflatoxin producing fungi.

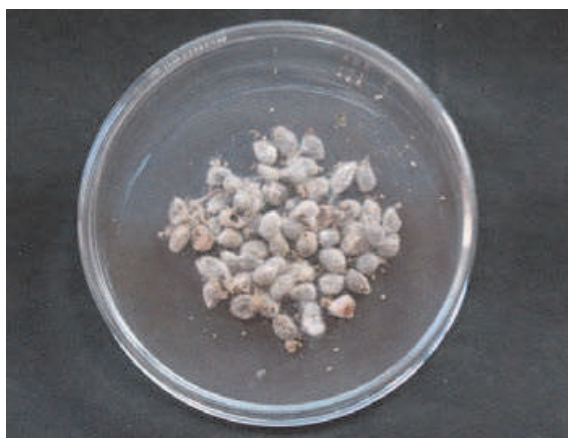

Fig. 1. Contamination of cotton seeds

2.1 Types of aflatoxins

Although 17 aflatoxins have been isolated (WHO, 1979), only 4 of them are well known and studied extensively from toxicological point of view. Being intensely fluorescent in ultraviolet light the four are designated by letters B1, B2, G1 and G2 representing their blue and green fluorescence in UV light. Two other familiar aflatoxins are M1 and M2. Because of their presence in milk of animals previously exposed to B1 and B2. Of all the above-named aflatoxins, aflatoxin B I (AFB1) is the most acutely toxic to various species.

Toxigenic *A. flavus* isolates generally produce only aflatoxins B1 and B2, whereas *A. parasiticus* isolates generally produce aflatoxins B1, B2, G1 and G2 (Davis and Diener, 1983). Other metabolites B2_a, aflatoxicol, aflatoxicol H1 and aflatoxins P1 and Q1 have been identified (FDA, 1979). Aflatoxin M1 is a metabolite of aflatoxin B1 in humans and animals. Aflatoxin M2 is a metabolite of aflatoxin B1 in milk of cattle fed on contaminated foods. Although aflatoxins B1, B2 and G1 are common in the same food sample, AFB1 predominates (60-80% of the total aflatoxin content). Generally AFB2, AFG1 and AFG2 do not occur in the absence of AFB1. In most cases AFG1 is found in higher concentrations than AFB2 and AFG2 (Weidenborner, 2001).

2.2 Favorable conditions for aflatoxin biosynthesis production

The formation of aflatoxins is influenced by physical, chemical and biological factors. The physical factors include temperature and moisture. The chemical factors include the composition of the air and the nature of the substrate. Biological factors are those associated with the host species (Hesseltine, 1983).

Specific nutrients, such as minerals (especially zinc), vitamins, fatty acids, amino acids and energy source (preferably in the form of starch) are required for aflatoxins formation (Wyatt, 1991). Large yield of aflatoxins are associated with high carbohydrate concentrations, such as wheat rice and to a lesser extent in oilseeds such as cottonseed, soyabean and peanuts (Diener and Davis, 1968).

The limiting temperatures for the production of aflatoxins by *A. flavus* and *A. parasiticus* are reported as 12 to 41°C, with optimum production occurring between 25 and 32°C (Lillehoj, 1983). Synthesis of aflatoxins in feeds are increased at temperatures above 27°C (80 F), humidity levels greater than 62% and moisture levels in the feed above 14% (Royes and Yanong, 2002).

2.3 Causes of aflatoxin

Crops grown under warm and moist weather in tropical or subtropical countries are especially more prone to aflatoxin contamination than those in temperate zones. Groundnuts and groundnut meal are by far the two agricultural commodities that seem to have the highest risk of aflatoxin contamination. Although these commodities are important as substrates, fungal growth and aflatoxin contamination are the consequence of interactions among the fungus, the host and the environment. The appropriate combination of these factors determines the infestation and colonization of the substrate and the type and amount of aflatoxin produced.

Water stress, high-temperature stress and insect damage of the host plant are major determining factors in mould infestation and toxin production. Similarly, specific crop growth stages, poor fertility, high crop densities and weed competition have been associated with increased mould growth and toxin production. The moisture content of the substrate and temperature are the main factors regulating the fungal growth and toxin formation. A moisture content of 18% for starchy cereal grains and 9-10% for oil-rich nuts and seeds has been established for maximum production of the toxin (WHO, 1979). On the other hand, the minimum, optimum and maximum temperatures for aflatoxin production have been reported to be 12°C - 27°C and 40°C-42°C respectively. Frequent contamination of corn and other commodities with high levels of aflatoxins has been a serious problem all over the world resulting in significant economic losses to farmers and a health hazard to farm animals and humans as well.

2.4 Structure of aflatoxin

In 1963, Asao *et al.*; Van Dorp *et al.* and Van der Zijden characterized the chemical and physical nature of the aflatoxins B₁, B₂, G₁ and G₂. Chemically, aflatoxins are difurocoumarolactones (difurocoumarin derivatives). Their structure consists of a bifuran ring fused to a coumarin nucleus with a pentenone ring (in B and M aflatoxins) or a six-membered lactone ring in G aflatoxins (Fig. 2). The four compounds are separated by the color of their fluorescence under long wave (Devero, 1999) ultraviolet illumination (B=blue,

G= green). Two other aflatoxins M₁ and M₂ were isolated from urine and milk and identified as mammalian metabolites of AFB₁ and AFB₂ (Patterson *et al.*, 1978).

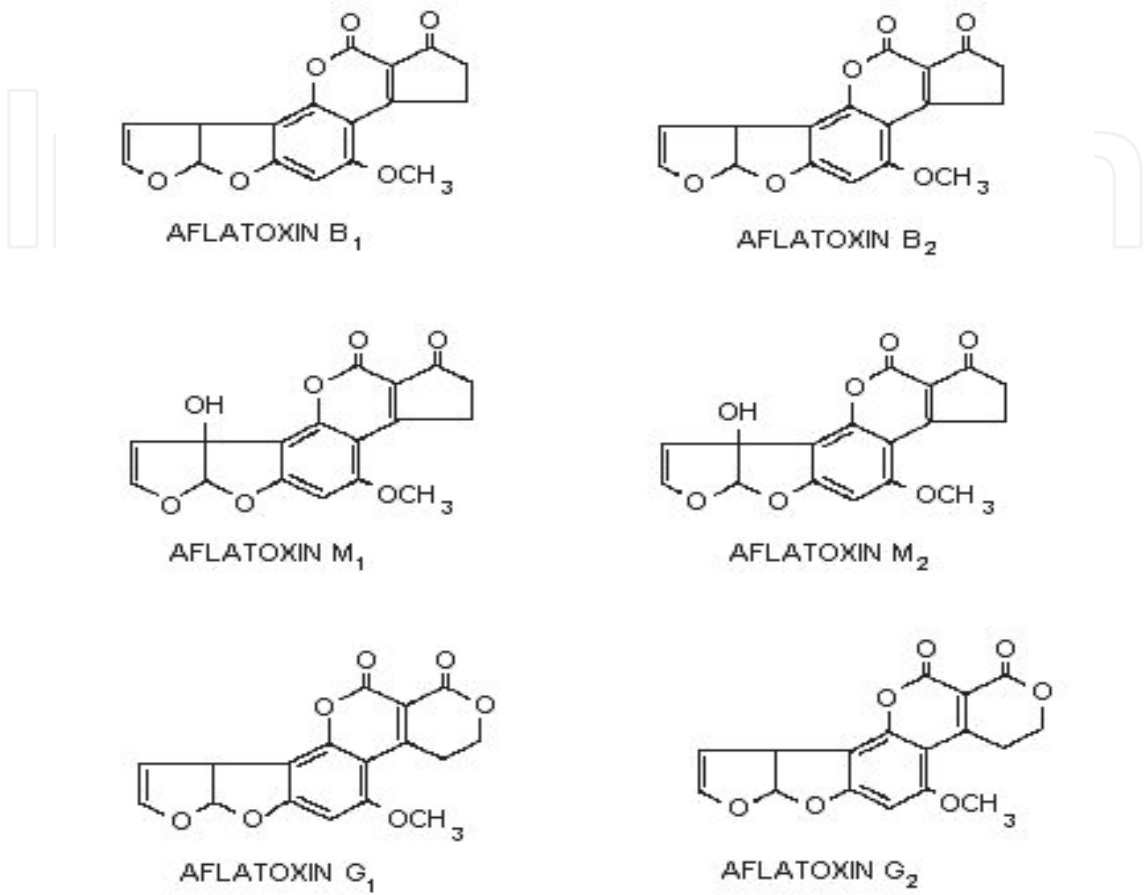


Fig. 2. Structure of aflatoxin

2.4.1 Physical properties

These four compounds were originally isolated by groups of investigators in England (Nesbitt *et al.*,1962, Sargeant *et al.*, 1961). The molecular formula of aflatoxin B₁ was established as C₁₇H₁₂O₆ and of aflatoxin G₁ as C₁₇H₁₂O₇; aflatoxins B₂ and G₂ were found to be the dihydro derivatives of the parent compounds, C₁₇H₁₄O₆ and C₁₇H₁₄O₇ (Hartley *et al.*, 1963). Some physical properties of the compounds are summarized in following Table 1.

Aflatoxin	Molecular Formula	Molecular Weight	Melting Point C	[α] _D ²³
B1	C ₁₆ H ₁₂ O ₆	312	268-269*	-559
B2	C ₁₇ H ₁₄ O ₆	314	286-289*	-492
G1	C ₁₇ H ₁₂ O ₇	328	244-246*	-533
G2	C ₁₇ H ₁₄ O ₇	330	237-240*	-473

*Decomposes

Table 1. Physical properties of aflatoxin

The spectral characteristics of the aflatoxins have been determined by several investigators and are summarized in Table 2. The ultraviolet absorption spectra are very similar, each showing maxima at 223, 265 and 363 mμ. The molar extinction coefficients at the latter two peaks, however, demonstrate that B1 and G2 absorb more intensely than G1 and B2 at these two wavelengths. Because of the close similarities in structural configuration, the infrared absorption spectra of the four compounds are also very similar, as illustrated. The fluorescence emission maximum for B1 and B2 has been reported to be 425 mμ and that for G1 and G2 is 450 mμ. The intensity of light emission, however, varies greatly among the four compounds, a property of significance in the estimation of concentrations of the compounds by fluorescence techniques.

Aflatoxin	Ultraviolet absorption (ε)		Infrared absorption (cm ⁻¹)					Fluorescence emission (mμ)
	265 mμ	363 mμ						
B1	13400	21800	1760	1684	1632	1598	1562	425
B2	9200	14700	1760	1685	1625	1600		425
G1	10000	16100	1760	1695	1630	1595		450
G2	11200	19300	1760	1694	1627	1597		450

Table 2. Spectral properties of aflatoxin

2.4.2 Chemical properties

The chemical reactivity and behavior of the aflatoxins has received relatively little systematic study beyond work associated with structure elucidation. However, it has been shown (Asao *et al.*, 1963) that catalytic hydrogenation of aflatoxin B1 to completion results in the uptake of 3 moles of hydrogen with the production of the tetrahydrodeoxy derivative. Interruption of the hydrogenation procedure after the uptake of 1 mole of hydrogen results in the production of aflatoxin B2 in quantitative yield.

Aflatoxin B1 has also been reported to react additively with a hydroxyl group under the catalytic influence of a strong acid (Andrellos *et al.*, 1964). Treatment with formic acid-thionyl chloride, acetic acid thionyl chloride or trifluoroacetic acid results in addition products of greatly altered chromatographic properties, but relatively unchanged fluorescence characteristics. Ozonolysis results in fragmentation of aflatoxin B1 and the products of this reaction include levulinic, succinic, malonic and glutaric acids (Van Drop *et al.*, 1963). The presence of the lactone ring makes the compound labile to alkaline hydrolysis, and partial recyclization after acidification of the hydrolysis product has been reported (De Iongh *et al.*, 1962).

Although few systematic studies have been carried out on the stability of the aflatoxins, the general experience would seem to indicate that some degradation takes place under several conditions. The compounds appear partially to decompose, for example, upon standing in methanolic solution, and this process is greatly accelerated in the presence of light or heat. Substantial degradation also occurs on chromatograms exposed to air and ultraviolet or visible light. These processes may give rise to some of the nonaflatoxin fluorescent compounds typically seen in chromatograms of culture extracts. The nature of the decomposition products is still unknown, and the chemical reactions involved in their formation remain to be established (Wogan *et al.*, 1966).

2.5 Biological effects of the aflatoxins

The discovery of this group of compounds as contaminants of animal feeds and the potential public health hazards involved, have stimulated considerable research effort concerned with their effects in various biological assay systems. The toxic properties of the aflatoxins manifest themselves differently depending on the test system, dose and duration of exposure. Thus, they have been shown to be lethal to animals and animal cells in culture when administered acutely in sufficiently large doses and to cause histological changes in animals when smaller doses were administered subacutely. Chronic exposure for extended periods has resulted in tumor induction in several animal species (Wogan *et al.*, 1966).

2.5.1 Aflatoxin and animal diseases

Aflatoxin poisoning (Aflatoxicosis) mainly on animal liver injury, the injured individual species of animals, age, gender and nutritional status vary. The aflatoxin can cause liver dysfunction, reduced milk production and egg production and to reduced immunity of animals. Susceptible to the infection of harmful microorganisms. In addition, long-term consumption of food containing low concentrations of aflatoxin in feed can also result in embryo toxicity. Usually young animals are more sensitive to aflatoxin. The clinical manifestations of aflatoxin are digestive disorders, reduced fertility, reduced feed efficiency and anemia. Aflatoxins not only the decline in milk production, but also the transformation of the milk containing aflatoxin M1 and M2. According to the U.S. agricultural economy scientists to statistics, the consumption of aflatoxin contaminated feed, make at least 10% of the U.S. livestock industry suffered economic losses.

2.5.2 Metabolism and mechanisms of action of aflatoxin B1

The absorption from the gastrointestinal tract should be complete since very small doses, even in the presence of food, can cause toxicity. After the absorption, highest concentration of the toxin is found in the liver (Mintzlaff *et al.*, 1974). Once in liver, aflatoxin B1 is metabolized by microsomal enzymes to different metabolites through hydroxylation, hydration, demethylation and epoxidation (Fig. 3). Thus hydroxylation of AFB1 at C4 or C22 produces, AFM1 and AFQ1, respectively. Hydration of the C2 – C3 double bond results in the formation of AFB2a which is rapidly formed in certain avian species (Patterson and Roberts, 1970). AFP1 results from o-demethylation while the AFB1 – epoxide is formed by epoxidation at the 2,3 double bond. Aflatoxicol is the only metabolite of AFB1 produced by a soluble cytoplasmic reductase enzyme system.

The liver is the target organ for toxic effects of aflatoxin B1. As a result, metabolism of proteins, carbohydrates and lipids in liver is seriously impaired by AFB1. The toxin inhibits RNA polymerase and subsequent protein synthesis at a faster rate in ducks than in rats probably because of faster liver metabolism of AFB1 in ducks than in rats (Smith, 1965). In day-old chicks, AFB1 reduces the activity of liver UDP glucose-glycogen transglucosylase resulting in depletion of hepatic glycogen stores (Shankaran *et al.*, 1970). On the other hand, there is lipid accumulation in the liver of chickens and ducklings exposed to aflatoxin (Carnaghan *et al.*, 1966; Shank and Wogan, 1966). With regard to its toxic effects on liver microsomal enzymes, AFB1 is known to decrease microsomal glucose-6-phosphatase activity (Shankaran *et al.*, 1970) whereas stimulation of microsomal enzyme activity by inducers seems to be unaffected by AFB1 (Kato *et al.*, 1970). In fact, pretreatment with the toxin actually stimulates its own metabolism in the rat when this is assayed in vitro

(Schabert and Steyn, 1969). Since aflatoxin inhibits protein synthesis, it is conceivable why aflatoxin reduces resistance of poultry to infection with *Pasteurella multocida*, *salmonella sp.*, Marek disease virus, *Coccidia* and *Candida albicans* (Smith *et al.*, 1969; Hamilton and Harris, 1971). Another effect of aflatoxin is that it causes anticoagulation of blood. This is probably because AFB₁ inhibits synthesis of factors II and VII involved in prothrombin synthesis and clotting mechanism (Bababunmi and Bassir, 1969).

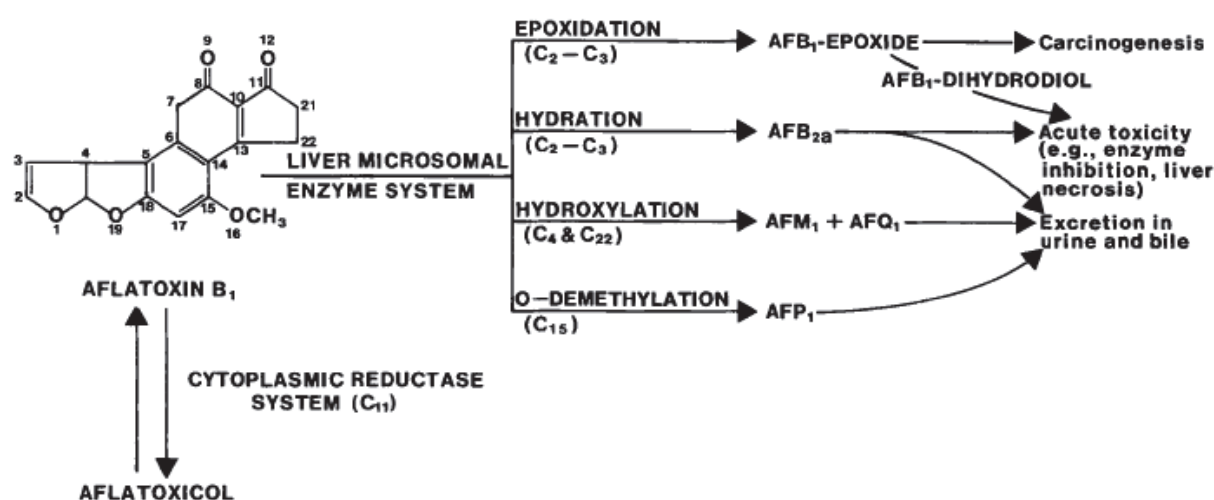


Fig. 3. Metabolism of aflatoxin in liver

Aflatoxin molecules in the double-furan ring structure, the structure is an important toxicity. Studies show that aflatoxin cytotoxic effects of toxins, is an interference RNA and DNA synthesis of information, thereby interfere with cell protein synthesis, resulting in systemic damage to animals (Nibbelink, 1988). Huangguang Qi *et al.*, (1993) research indicates that aflatoxin B₁ to form with the tRNA adduct, aflatoxin-tRNA adduct can inhibit tRNA binding activity of some amino acids on protein synthesis in the essential amino acids such as lysine, leucine, arginine and glycine and tRNA binding, have different inhibitory effect, thereby v_{\max}^{CHC3} interfering with the translation level of protein biosynthesis, affect cell metabolism.

Aflatoxin B₁ is excreted in urine and feces, and also in milk of lactating animals either unchanged or as various metabolites (Nabney *et al.*, 1967; Allcroft *et al.*, 1968). Only one milk metabolite, namely AFM₁, appears to be the major metabolite of AFB₁ that has shown appreciable oral toxicity (Holzapfel *et al.*, 1966). Its toxicity is considered to be nearly as potent as AFB₁. Even so this metabolite may be detoxified by conjugation with taurocholic and glucuronic acids prior to excretion in the bile or brine (DeLongh *et al.*, 1964; Bassir and Osiyemi, 1967). In this respect, two other metabolites of AFB₁, namely, AFP₁ and AFQ₁ are similar in that they also undergo this type of detoxication (Dalezios *et al.*, 1971; Buchi *et al.*, 1973; Masri *et al.*, 1974). Both of these metabolites are several-fold less toxic than AFB₁. For example, toxicity tests showed that AFP₁ causes some mortality in newborn mice at 150 mg/kg as compared to the LD₅₀ of 9.5 mg/kg for AFB₁ under comparable conditions.

2.6 Aflatoxin and human health

Human health hazards by aflatoxin were mainly due to people eating aflatoxin contaminated food. For the prevention of this pollution is very difficult, the reason is due to fungi in the food or food materials in the presence of a very common. The state health department has been heavily polluted enterprises to use against the grain for food production and supervision of enterprises to develop the implementation of the relevant standards. But with lower concentrations of aflatoxin food and food cannot be controlled. In developing countries, consumption of aflatoxin contaminated food and incidence of cancer was positively correlated. Asian and African research institutions, disease research showed that aflatoxin in food and liver cells cancer (Liver Cell Cancer, LCC) showed positive correlation. For a long time with low concentrations of aflatoxin consumption of food was the leading cause liver cancer, stomach cancer, colon cancer and other diseases. In 1988, International Agency for Research on Cancer (IARC) classified the aflatoxin B1 as a human carcinogen.

The median lethal dose of aflatoxin B1 0.36 mg / kg body weight is a special range of highly toxic poison (aflatoxin animal half of the lethal dose is found in the strongest carcinogens). Its carcinogenicity is 900 times more than dimethylnitrosamine induced liver cancer in the large capacity 75 times higher than the 3,4-benzopyrene, a large 4000-fold. It is mainly to induce liver cancer in animals, can also induce cancer, renal cancer, colorectal cancer and breast, ovary, small intestine and other sites of cancer.

2.7 Aflatoxicosis

The disease caused by the consumption of substances or foods contaminated with aflatoxin is called aflatoxicosis.

2.7.1 Aflatoxicosis in humans

2.7.2 Human exposure conditions

Two pathways of the dietary exposure have been identified:

- a. Direct ingestion of aflatoxins (mainly B1) in contaminated foods of plant origin such as maize nuts and their products.
- b. Ingestion of aflatoxins carried over from feed into milk and milk products including cheese and powdered milk, where they appear mainly as aflatoxin M1. In addition to the carryover into milk, residues of aflatoxins may be present in the tissues of animals that consume contaminated feed (WHO, 1979). Aflatoxin residues have been found in animal tissues, eggs and poultry following the experimental ingestion of aflatoxin-contaminated feed (Rodricks and stoloff, 1977). Contamination of milk, egg and meat can result from animal consumption of mycotoxin contaminated feed. Aflatoxins, ochratoxin and some trichothecenes have been given considerable attention, because they are either carcinogenic or economic concern in animal health (CAST, 1989).

Aflatoxin M1 is believed to be associated with casein (protein) fraction of milk. Cream and butter contain lower concentration of M1 than the milk from which these products are made, while, cheese contains higher concentration of M1 about 3-5 times the M1 in the original milk (Kiemeier and Buchner, 1977; Stoloff, 1980; Brackett and Marth, 1982).

The expression of aflatoxin related diseases in humans may be influenced by factors such as age, sex, nutritional status, and concurrent exposure to other causative agents such as viral hepatitis (HBV) or parasite infestation.

2.8 Effect on human health

2.8.1 Acute toxicity

The disease was characterized by high fever, high colored urine, vomiting, and edema of feet, Jaundice, rapidly developing ascitis, portal hypertension and a high mortality rate. The disease was confirmed to the very poor, who were forced by economic circumstances to consume badly molded corn containing aflatoxins between 6.25 -15.6 ppm, an average daily intake per person of 2-6 mg of aflatoxins (Krishnamachari *et al.*, 1975a and 1975b; Keeler and Tu, 1983).

2.8.2 Chronic toxicity

Long exposure to aflatoxins in the diet increases risk with a synergistic effect from increased alcohol consumption. Aflatoxin B1 has also been implicated as a cause of human hepatic cell carcinoma (HCC). Aflatoxin B1 also chemically binds to DNA and caused structural DNA alterations with the result of genomic mutation (Groopman *et al.*, 1985).

Ingestion of aflatoxin, viral diseases, and hereditary factors has been suggested as possible aetiological agents of childhood cirrhosis. There are evidences to indicate that children exposed to aflatoxin breast milk and dietary items such as unrefined groundnut oil, may develop cirrhosis. Malnourished children are also prone to childhood cirrhosis on consumption of contaminated food. Several investigators have suggested aflatoxin as an aetiological agent of Reye's syndrome in children in Thailand, New Zealand etc. Though there is no conclusive evidence as yet. Epidemiological studies have shown the involvement of aflatoxins in Kwashiorkor mainly in malnourished children. The diagnostic features of Kwashiorkor are edema, damage to liver etc. These outbreaks of aflatoxicosis in man have been attributed to ingestion of contaminated food such as maize, groundnut etc. Hence it is very important to reduce the dietary intake of aflatoxins.

2.9 Aflatoxicosis in animals

Aflatoxin can cause oncogenesis, chronic toxicity or peracute signs depending on the species, age of animal, dose and duration of aflatoxin exposure (Smith, 2002). All animal species are susceptible to aflatoxicosis, but outbreak occurs mostly in pigs, sheep and cattle (Radostits *et al.*, 2000). Beef and dairy cattle are more susceptible to aflatoxicosis than sheep or horses. Young animals of all species are more susceptible than mature animals to the effects of aflatoxin. Pregnant and growing animals are less susceptible than young animals, but more susceptible than mature animals (Cassel *et al.*, 1988). Nursing animals may be affected by exposure to aflatoxin metabolites secreted in the milk (Jones *et al.*, 1994). For most species, oral LD50 values of aflatoxin B1 vary from 0.03 to 18 mg/kg body weight.

2.10 Effects on animal health

There are differences in species with respect to their susceptibility to aflatoxins, but in general, most animals, including humans, are affected in the same manner.

2.10.1 Acute toxicity

Acute toxicity is less likely than chronic toxicity. Studies have shown that ducklings are the species most susceptible to acute poisoning by aflatoxins. The LD50 of a day old duckling is 0.3mg/kg bodyweight.

Species	Oral LD50/Lethal dose (mg/Kg)
Chick embryo	0.025
Duckling	0.3
Turkey poultry	0.5
Chicken, New Hampshire	2.0
Chicken, Rhode Island	6.3
Sheep	5.0
Rat(male)	7.2
Rat(female)	17.9
Rabbit	0.3
Cat	0.6
Pig	0.6
Guinea pig	1.4
Hamster	10.2
Mouse	9.0
Baboon	2.0

Table 3. Comparative LD50 or lethal values for Aflatoxin B1 (Edds, 1973 &WHO, 1979).

The principal target organ for aflatoxins is the liver. After the invasion of aflatoxins into the liver, lipids infiltrate hepatocytes and leads to necrosis or liver cell death. The main reason for this is that aflatoxin metabolites react negatively with different cell proteins, which leads to inhibition of carbohydrate and lipid metabolism and protein synthesis. In correlation with the decrease in liver function, there is a derangement of the blood clotting mechanism, icterus (jaundice), and a decrease in essential serum proteins synthesized by the liver. Other general signs of aflatoxicosis are edema of the lower extremities, abdominal pain, and vomiting.

2.10.2 Chronic toxicity

Animals which consume sub-lethal quantities of aflatoxin for several days or weeks develop a sub acute toxicity syndrome which commonly includes moderate to severe liver damage. Even with low levels of aflatoxins in the diet, there will be a decrease in growth rate, lowered milk or egg production and immunosuppression. There is some observed carcinogenicity, mainly related to aflatoxin B1. Liver damage is apparent due to the yellow color that is characteristic of jaundice, and the gall bladder will become swollen. Immunosuppression is due to the reactivity of aflatoxins with T-cells, decrease in Vitamin K activities and a decrease in phagocytic activity in macrophages.

2.10.3 Cellular effects

Aflatoxins are inhibitors of nucleic acid synthesis because they have a high affinity for nucleic acids and polynucleotides. They attach to guanine residues and form nucleic acid adducts. Aflatoxins also have been shown to decrease protein synthesis, lipid metabolism, and mitochondrial respiration. They also cause an accumulation of lipids in the liver, causing a fatty liver. This is due to impaired transport of lipids out of the liver after they are synthesized. This leads to high fecal fat content. Carcinogenesis has been observed in rats, ducks, mice, trout, and subhuman primates and it is rarely seen in poultry or ruminants. Trout are the most susceptible. In fact, 1ppb of aflatoxin B1 will cause liver cancer in trout. Carcinogenesis occurs

due to the formation of 8,9-epoxide, which binds to DNA and alters gene expression. There is a correlation with the presence of aflatoxins and increased liver cancer in individuals that are hepatitis B carriers. Animals of different species vary in their susceptibility to acute aflatoxin poisoning with LD₅₀ values ranging from 0.3 to 17.9 mg/kg (Table 4). In fact duckling liver metabolized aflatoxin very rapidly in vitro (Patterson and Allcroft, 1970), although the species is sufficiently susceptible for day old birds to be used widely in a sensitive bioassay for the toxin (Patterson, 1973). Studies indicated that rabbit, duckling and guinea-pig constitute a "fast metabolizing group" being apparently capable of handling an LD₅₀ dose in under 12 minutes. Chick, mouse, pig and sheep fall into an intermediate group, metabolizing an LD₅₀ dose in a few hours. So far, the rat is the only example of a "slow metabolizing group" in which LD₅₀ dose would probably disappear from the liver over a period of days (Patterson, 1973). Factors that influence aflatoxin toxicity residue levels in animal species include: species and breeds of animals and poultry, levels and duration of exposure, nutrition and health of animals, age, sex and diseases, drugs and other mycotoxins (FDA, 1979).

Toxin	Animal	Age/Size	LD ₅₀ (mg/kg)
AFB1			0.37
AFB2			1.69(84.8µg/50gm duckling)
AFG1	Duckling	Day old	0.79
AFG2			2.5(172.5µg/ duckling)
AFM1			0.8(16.6µg/ duckling)
	Rabbit		0.3-0.5
	Cat		0.55
	Pig	6.0-7.0 kg	0.62
	Turkey		0.5-1.0
	Dog	Puppies	0.5-1.0
	Cattle	Young calves	0.5-1.0
	Guinea pig		1.4-2.0
	Horse		2.0
	Sheep		2.0
	Monkey		2.2
	Chickens		6.5-16.5
AFB1	Mouse	Young foals	9.0
	Hamster		10.2
	Rat, male, female	21 days	5.5
	Rat male	100 gm	7.4
			17.9

Table 4. A comparison of single oral LD50 values for AFB1 in various species. (Agag, 2004)

2.10.4 Aflatoxicosis in ruminants

Aflatoxin ingested in the feed by cattle is physically bound to ruminal contents, and as little as 2-5% reach the intestine. Levels of AFB1 in excess of 100 µg/kg of feed are considered to be poisonous for cattle (Radostits *et al.*, 2000). The effects of aflatoxin fed to cattle depend on the level of aflatoxin in the ration, the length of feeding period and the age of animal (Jones *et al.*, 1994).

2.10.5 Calves

The LD₅₀ dosage of AFB₁ in calves has been estimated to be 0.5-1.5 mg/kg. Affected calves had anorexia, depression, jaundice, photosensitization of unpigmented skin, submandibular edema, severe keratoconjunctivitis and diarrhea with dysentery. Collapse and death followed. Postmortem findings showed hemorrhages in subcutaneous tissues, skeletal muscles, lymph nodes, pericardium, beneath the epicardium and serosa of the alimentary tract. The liver was pale and carcass jaundiced. Histopathological examination of the liver revealed that hepatocytes were markedly enlarged, especially in the periportal areas and occasional hepatocyte nuclei were up to 5 times the diameter of their companions. Hepatocyte cytoplasm was finely vacuolated, many of these vacuoles containing fat. Serum enzymes of hepatic origin and bilirubin were elevated.

In calves who have consumed contaminated rations for several weeks, the onset of clinical signs is rapid. The most consistent features are blindness, circling and falling down, with twitching of the ears and grinding of the teeth. Severe tenesmus and erosion of the rectum are seen in most cases, and death of some cases (Humphreys, 1988).

2.10.6 Dairy and beef cattle

The signs most commonly reported with acute toxicosis in cattle include anorexia, depression, dramatic drop in milk production, weight loss, lethargy, ascitis, icterus, tenesmus, abdominal pain (animals may stretch or kick at their abdomen), bloody diarrhea, abortion, hepatoencephalopathy, photosensitization and bleeding (Colvin *et al.*, 1984; Cook *et al.*, 1986; Ray *et al.*, 1986; Eaton and Groopman, 1994; Reagor, 1996). Other signs associated with acute aflatoxicosis include blindness, walking in circles, ear twitching, frothy at the mouth, keratoconjunctivitis and rectal prolapse (Radostits *et al.*, 2000).

Hepatic damage is a constant finding in acute aflatoxicosis. Lesions include fatty degeneration, megalocytosis and single-cell necrosis with increasing fibrosis, biliary proliferation and veno occlusive lesions as the disease progresses (Burnside *et al.*, 1957; Morehouse, 1981; Colvin *et al.*, 1984).

In additions, chronic aflatoxicosis may impair reproductive efficiency including abnormal estrous cycle (too short and too long) and abortions, induce immunosuppression and increase susceptibility to disease (Cassel *et al.*, 1988). The immunotoxic effect of AFB₁ was expressed via the cell-mediated immune system (Raisbeck *et al.*, 1991).

Other symptoms including decreased milk production, birth of smaller and healthy calves, diarrhea, acute mastitis, respiratory disorders, prolapsed rectum and hair loss are also observed in chronically exposed dairy cattle (Guthrie, 1979). High aflatoxin levels (4 ppm) can cause milk production to drop within one week while, lower levels (0.4 ppm) can cause production drop in 3 to 4 weeks (Hutjens, 1983).

Another character of aflatoxin exposure in dairy cattle is the conversion to AFM₁ in milk (Price *et al.*, 1985). Experiments have shown that milk will be free of aflatoxin after 96 hours of feeding non-contaminated feed. The level of aflatoxin in the feed and milk at the stating point will influence clearance time (Lynch, 1972; Hutjens, 1983).

The concentration of AFM₁ in milk seems to depend more on intake of AFB₁ than on milk yield (Vander Linde *et al.*, 1965). However, the toxin content of milk appears to increase rapidly when milk yield is reduced as a result of high toxin intake (Masri *et al.*, 1969). Rate of metabolism by the liver and rate of excretion by other routes (urine and feces) are also likely to influence the toxin level in milk (Applebaum *et al.*, 1982).

Decreased performance (i.e. rate of gain, milk production) is one of the most sensitive indicators of aflatoxicosis (Richard *et al.*, 1983). The ultimate cause of this effect is probably multifactorial, involving not only nutritional interactions, but also the compounding influences of anorexia, deranged hepatic protein and lipid metabolism and disturbances in hormonal metabolism (Raisbeck *et al.*, 1991). Aflatoxins have shown to affect rumen motility (Cook *et al.*, 1986) and rumen function by decreasing cellulose digestion, volatile fatty acid production and proteolysis (Fehr and Delag, 1970; Bodine and Mertins, 1983).

2.10.7 Sheep and goats

Anorexia, depression and icterus were observed in sheep and goats exposed to aflatoxin. The goats also developed a nasal discharge and dark brown urine was noted in the sheep (Hatch *et al.*, 1971; Samarajeewa, *et al.*, 1975; Abdelsalam *et al.*, 1989).

Anorexia and diarrhea occurred in sheep given aflatoxin at a rate of 0.23mg/kg. These signs were accompanied by excessive salivation, tachypnea and pyrexia at dosages of 0.59 mg/kg or more. Heavy mucous diarrhea and dysentery were observed in sheep dosed at a rate of 1.28 to 2.0mg/kg. Sheep that died within 24 hours of dosing had marked centrilobular necrosis of the liver. Sheep that survived until the 7th day after dosing had periportal congestion of the liver, widely dilated sinusoids and necrosis of liver cells (Armbrecht *et al.*, 1970).

Acutely intoxicated sheep with 4mg/kg showed anorexia, diarrhea, excessive salivation, rumen atony, scour, rectal prolapse, fever and death (Wylie and Morehouse, 1978).

2.10.8 AFB1 toxicity in equine species

The existing information on aflatoxicosis in the horse is inconclusive, although a total dietary concentration of 500–1000 µg/kg has been shown to induce clinical changes and liver damage, depending on the duration of exposure (Meerdink, 2002). The target organ in horses, as in all affected animals, is the liver, where the toxin induces centrilobular necrosis (Stoloff and Trucksess, 1979). Horses suffering from aflatoxicosis exhibit non-specific clinical signs, such as inappetence, depression, fever, tremor, ataxia and cough (Larsson *et al.*, 2003). Necropsy findings include yellow-brown liver with centrilobular necrosis, icterus, haemorrhage, tracheal exudates and brown urine (Angsubhakorn *et al.*, 1981; Cysewski *et al.*, 1982; Bortell *et al.*, 1983; Vesonder *et al.*, 1991).

Clinical signs of toxicity were observed in adult male Shetland ponies given a daily oral dose of 0.075 (over 36 or 39 days), 0.15 (over 25 or 32 days) and 0.3 mg/kg (over 12 or 16 days) of partially purified aflatoxin (47% AFB1 activity) (Cysewski *et al.*, 1982). Daily clinical observations revealed the appearance of depression, inappetence and weakness 5–7 days before the onset of severe illness and death. The onset of signs was generally dose related and appeared first in the ponies given 0.3mg/kg. Prothrombin time, sulfabromophthalein clearance time, total plasma bilirubin and the icteric index increased markedly before death. An increase in the plasma activity of aspartate amino transferase (AST) was observed. The AST activity grew significantly and generally remained at elevated levels in all animals. At the time of necropsy, pathological changes, such as generalised icterus, haemorrhage, a brown to tan liver, dark reddish brown urine and dark brown kidneys, were consistently observed. Microscopic lesions, including centrilobular fatty change, hepatic cell necrosis and periportal fibrosis, were observed in all ponies (Cysewski *et al.*, 1982).

2.10.9 Aflatoxicosis in equine species: Case reports

The first case of probable equine aflatoxicosis in which a 15-year-old Arabian stallion died, was reported by Greene and Oehme (1976). The reported symptoms included anorexia, icterus and rapid weight loss immediately prior to death. On post mortem examination, the liver was described as being black, of firm consistency and enlarged.

Histopathological examination revealed marked centrilobular hepatic necrosis and necrotic areas were engorged with erythrocytes. Kupffer cells were prominent and many contained phagocytosed haemosiderin, which was the likely cause of the black coloured liver. Bile-duct hyperplasia, congestion of renal vessels and adrenal cortex were found. Samples of the feed revealed AFB1 levels of 58.4 µg/kg, which exceeded the limit recommended by the FDA of 20 µg/kg (Greene and Oehme, 1976).

Two outbreaks of aflatoxicosis in two separate horse farms in different geographical areas of the world were later reported by Angsubhakorn *et al.* (1981). The first episode occurred in a horse breeding farm outside Bangkok, Thailand and started a few days after the introduction of a new lot of feed prepared from stored ground corn and stored peanut meal. A number of young animals had clinical signs of illness and 12 yearling colts died. At post mortem examination, a swollen fatty liver, pale swollen kidneys and hemorrhagic enteritis were found. A few animals necropsied soon after death, had pale hearts, focal myocardial necrosis and epicardial petechiae. When the cranial cavity was opened, the brain was seen to be swollen and the gyri compressed.

The second episode occurred in a farm for riding mares in southern Georgia, USA, in the autumn of 1978. After the introduction of a new mixed ration, a number of horses reduced their feed intake over a period of 3–4 days and showed signs of clinical illness. Within 5 days of the onset of clinical signs, two 2 year old horses and one 7 year old mare died. Necropsy findings were similar to those observed in the episode in Thailand. The swollen, fatty liver, epi- and endo-cardial petechiae; pale, mottled myocardium; swollen kidneys (although the paleness was more pronounced in the Georgia horses), hemorrhagic enteritis and variable mesenteric oedema.

Hematological and serum chemical examinations revealed hypoglycaemia, hyperlipidaemia and depletion of lymphocytes. The increase in haematocrit and the number of red blood cells was probably due in part to dehydration. The diagnosis of aflatoxicosis in these two episodes was based on histological examinations and isolation of the toxin from the feed and animal tissues. Microscopically, the lesions of the Georgia horses appeared the same as those seen in the Thai horses. Assay of liver specimens from two of the Georgia horses confirmed the presence of AFB1 in both samples and the results showed that AFB1 was metabolized and rapidly cleared from the liver and other tissues.

Peanut meal and corn were found to be the sources of aflatoxins in Thailand where representative samples of the mixed ration contained approximately 0.2 mg of AFB1 and 0.2 mg of AFB2 per kg (Caloni and Cortinovis, 2011).

2.10.10 Aflatoxins and COPD

Larsson *et al.* (2003) suggested a possible link between chronic obstructive pulmonary disease (COPD) and inhaled mycotoxins. *A.fumigatus* and *Mycropolyspora faeni* are potential causes of COPD in horses (Halliwell *et al.*, 1993), which is characterised by asthma like symptoms, such as chronic cough, nasal discharge, expiratory dyspnoea and reduced exercise tolerance (Gillespie and Tyler, 1969; Cook, 1976). The olfactory and respiratory mucosa of horses may be exposed to mycotoxins and other xenobiotics via inhalation of

contaminated feed-dust particles (Sorensson *et al.*, 1981; Burg and Shotwell, 1984). The inhaled aflatoxins and other xenobiotics may be activated by CYP-enzymes in the epithelial linings of the respiratory tract and contribute to the aetiology of COPD (Larsson *et al.*, 2003; Tydén *et al.*, 2008).

2.10.11 Canine

Canine aflatoxicosis was first reported in 1952 by Seibold and Bailey who described a liver disease called hepatitis "x" which was observed in dogs fed moldy contaminated feed. Dogs and cats are extremely sensitive to aflatoxins. The LD₅₀ of AFB1 in dogs is 0.5-1.5 mg/kg and in cats is 0.3-0.6 mg/kg (Rumbeiha, 2001). Feed containing AFB1 concentrations of 60 ppb or greater have caused outbreaks of aflatoxicosis in companion animals. As with other toxic compounds, sensitivity depends on individual susceptibility which in turn depends on age, hormonal status (pregnancy), nutritional status, among other factors (Rumbeiha, 2001).

Dogs exposed to aflatoxin developed the typical anorexia, depression, icterus, prostration and blood in the feces, but also may have hemorrhages, melena and pulmonary edema (FDA, 1979; Liggett *et al.*, 1986; Bastianello *et al.*, 1987; Thornburg and Raisbeck, 1988). Moreover, vomiting, increased water consumption, polyuria, polydipsia, jaundice and elevation of serum liver enzymes in acute aflatoxicosis in dogs and cats (Rumbeiha, 2001).

At neuropsy, the liver is swollen, petechial hemorrhages are observed on the gums, along the gastrointestinal tract, in the lungs, pleura, epicardium and urinary bladder. The hemorrhages are associated with a yellow, reddish-yellow, or orange discoloration of the liver, icterus of the conjunctiva, oral mucosa, serous membranes and in body fat (Chaffee *et al.*, 1969; FDA, 1979; Rumbeiha, 2001). Lymphoid depletion and necrosis of the thymus, spleen and lymph nodes, gross uterine and placental hemorrhage and congestion and hemorrhage in the adrenal cortex were also reported (Newberne *et al.*, 1966).

In subacute aflatoxicosis, affected dogs and cats will present with lethargy, anorexia, polyuria, polydipsia, elevated liver enzymes and jaundice. In chronic aflatoxicosis, dogs and cats will have clinical signs similar to subacute aflatoxicosis, with prominent jaundice. Chronic aflatoxicosis may cause also immunosuppression, followed by non-specific clinical signs, including increased susceptibility to viral, bacterial, fungal or parasitic infections (Rumbeiha, 2001).

Histologically, there is severe fatty degeneration with distinct vacuolation of hepatocytes, bile canaliculi are distended with bile, portal and central veins are congested with bile, and portal and central veins are congested in acute cases. In subacute cases, the distinct feature is bile duct proliferation and there is evidence of liver regeneration. In chronic cases, there is extensive liver fibrosis and bile duct proliferation (Rumbeiha, 2001).

2.10.12 Pigs

Young swine are extremely sensitive to aflatoxins but susceptibility decreased with age (Diekman *et al.*, 1992). The toxicity of aflatoxin is both-dose related and time related and age is an important factor in susceptibility (Lawlor and Lynch, 2001). Sows and boars normally tolerate levels > 0.5 ppm in the feed for short periods but, when fed for extended periods, contamination levels in the feed should not exceed 0.1 ppm (Blaney and Williams, 1991). Levels in excess of 0.5 ppm in the diets of lactating sows will depress growth rates in suckling pigs due to aflatoxin in milk. For growing and finishing pigs residues will build up in the liver at concentrations of even less than 0.1 ppm in the feed (Osweiler, 1992). The LD₅₀ in young pigs dosage was determined to be 0.8 mg/kg (Jones and Jones, 1978). The clinical

syndrome in pigs include rough coat, depression, anorexia, decreased feed conversion, decreased rate of gain, weight loss, muscular weakness and shivering, tremors, bloody rectal discharge and icterus (Sisk *et al.*, 1968; Jones and Jones, 1978; Hoerr and D' Andrea, 1983; Radostits *et al.*, 2000). Aflatoxins also suppress the immune system and thus make pigs more susceptible to bacterial viral or parasitic diseases (Diekman *et al.*, 1992). At necropsy, the livers from swine receiving toxic levels of AFB1 in their ration vary in close from tan to pale yellow with atrophic gall bladders, the livers contain increased fibrous connective tissue with resistance to cutting. There is icterus and petechial hemorrhages on the heart and massive hemorrhage into the ileum or throughout the digestive tract. Microscopic lesions include irregular shaped cells, centrilobular congestion, karyorrhesis and pyknosis, vacuolation, disappearance of nuclei, bile duct proliferation and extensive connective tissue in the inter and intralobular areas (FDA, 1979).

2.11 Aflatoxicosis in poultry

Aflatoxicosis have produced severe economic losses in the poultry industry affecting ducklings, broilers, layers, turkeys and quail (CAST, 1989). Susceptibility of poultry to aflatoxins varies among species, breeds and genetic lines. Comparative toxicological studies in avian species have shown that ducklings and turkey poultry are the most sensitive species to aflatoxins. Goslings, quails and pheasants show intermediate sensitivity while chickens appear to be the most resistant (Leeson *et al.*, 1995). The susceptibility ranges from ducklings > turkey poult > goslings > pheasant chicks > chickens (Muller *et al.*, 1970). Ducklings are 5 to 15 times more sensitive to the effects of aflatoxins than are laying hens, but when laying hen strains are compared, certain strains of hens may be as much as 3 times more sensitive than other strains (Jones *et al.*, 1994). In comparing sensitivity of different strains of leghorn chicks (Table 5), it was found there is up to a 2.5 difference in the LD₅₀ dose at 6 weeks of age (FDA, 1979)

Strain	LD ₅₀ mg/kg
A	6.5
B	7.25
C	9.25
D	9.50
E	11.50
F	16.50

Table 5. Sensitivity in different leghorn strains of chicks

In poultry, aflatoxin impairs all important production parameters including weight gain, feed intake, feed conversion efficiency, pigmentation, processing yield, egg production, male and female reproductive performance. Some influences are direct effects of intoxication, while others are indirect, such as from reduced feed intake (Calnek *et al.*, 1997). The direct and indirect effects of aflatoxicosis include increased mortality from heat stress (broiler breeders, Dafalla *et al.*, 1987a), decreased egg production in leghorns, (Bryden *et al.*, 1980), anemia, hemorrhages and liver condemnations (Lamont, 1979), paralysis and lameness (Okoye *et al.*, 1988), impaired performance in broilers, (Jones *et al.*, 1982), increased mortality rate in ducks, (Bryden *et al.*, 1980), impaired ambulation and paralysis in quail, (Wilson *et al.*, 1975), impaired immunization in turkeys, (Hegazy *et al.*, 1991), and increased susceptibility to infectious diseases (Bryden *et al.*, 1980 and Calnek *et al.*, 1997).

2.11.1 Chickens

Susceptibility of chickens to toxic effects of AFB1 varies with several factors such as breed, strain, age, nutritional status, amount of toxin intake and also the capacity of liver microsomal enzymes to detoxify AFB1 (Edds, 1973; Veltmann, 1984). Acute toxicity of aflatoxins in chickens may be characterized by hemorrhage in many tissues and liver necrosis with icterus.

Although number of field cases of aflatoxicosis in chickens has been diagnosed in various countries, the most severe spontaneous outbreak occurred in North Carolina, in which 50% of a flock of laying hens died within 48 hr of being fed highly toxic maize containing 100 ppm aflatoxin (Hamilton, 1971). The necropsy revealed that liver damage was the most important lesion showing paleness, occasional white pinhead-sized foci and petechial hemorrhages while gallbladder and bile ducts were distended.

Levels of aflatoxin B1 in moldy feed normally vary from 0 to 10 ppm. At low levels of feed contamination, exposed chickens show, in general, weakness, failure to gain weight with concomitant decline in feed efficiency and egg production (Smith and Hamilton, 1970; Doerr *et al.*, 1983). Hepatic damage is manifested by enlarged and putty-colored liver, petechial hemorrhages, marked vacuolation of hepatic cells and bile duct proliferation. Feed levels of AFB1 as low as 250-500 ppb given to New Hampshire chickens have been reported to result in liver damage, decreased hemoglobin, and hypoproteinemia (Brown and Abrams, 1965).

Experimental trials with naturally contaminated feed containing aflatoxin levels ranging from 1-1.5 ppm have caused growth retardation in chickens. Mortality was low but marked hepatic damage was manifested by enlarged and hemorrhagic liver (Carnaghan *et al.*, 1966). Relatively, high dietary levels of aflatoxin B1 (0-10 ppm) given to Rock type broiler chickens have been reported to cause substantial decrease in weight gain, feed efficiency and hepatic microsomal drug metabolizing enzymes with concomitant increase in serum glutamic oxalacetic transaminase activity reflecting liver damage (Dalvi and McGowan, 1984; Dalvi and Ademoyero, 1984).

Metabolic alterations caused by aflatoxins in chickens result in elevated lipid levels (Tung *et al.*, 1972; Donaldson *et al.*, 1972), disruptions in hepatic protein synthesis (Tung *et al.*, 1975) which result in several blood coagulation disorders (Doerr *et al.*, 1976; Bababunmi and Bassir, 1982), immunosuppression and decreased plasma amino acid concentrations (Voight *et al.*, 1980).

2.11.2 Ducks

Lethal aflatoxicosis in ducklings occurred as inappetance, reduced growth, abnormal vocalizations, feather picking, purple discoloration of legs and feet and lameness. Ataxia, convulsions and opisthotonus preceded death (Asplin and Carnaghan, 1961).

At necropsy, livers and kidneys were enlarged and pale. With chronicity, ascitis and hydropericardium developed accompanied by shrunken firm nodular liver, distention of the gall bladder and hemorrhages (Asplin and Carnaghan, 1961; Calnek *et al.*, 1997), distended abdomen due to liver tumors and secondary ascitis (Hetzel *et al.*, 1984).

Microscopic lesions in the liver were fatty change in hepatocytes, proliferation of bile ductules and extensive fibrosis accompanied by vascular and degenerative lesions in pancreas and kidney (Asplin and Carnaghan, 1961 and Calnek *et al.*, 1997). Bile duct hyperplasia and bile duct carcinoma are also reported (Hetzel *et al.*, 1984) in aflatoxicated Campbell ducks.

2.11.3 Turkeys

The initial clinical signs reported during the outbreak of Turkey "x" disease were anorexia and weight loss followed by depression, ataxia and recumbency. Affected birds died within a week or two and at the time of death frequently had opisthotonus characterized by arched neck, head down back and legs extended backwards (Hamilton *et al.*, 1972).

Along with decreased feed conversion and weight gain, reduced spontaneous activity, unsteady gait, recumbency, anemia and death (Siller and Ostler, 1961; Wannop, 1961; Giambrone *et al.*, 1985; Richard *et al.*, 1987).

At necropsy, the body condition was generally good but there was generalized congestion and edema. The liver and kidney were congested, enlarged and firm, the gall bladder was full, and the duodenum was distended with catarrhal content (Siller and Ostler, 1961; Wannop, 1961; Calnek *et al.*, 1997).

2.11.4 Broilers

Decreased water and feed intake, weight loss, dullness, stunting, ruffled feathers, poor appearance and paleness, trembling, ataxia, lameness, paralysis of the legs and wings gasping, prostration and death are frequently seen in experimental and natural outbreak of aflatoxicosis in broilers (Asuzu and Shetty, 1986; Okoye *et al.*, 1988; Rao and Joshi, 1993; Leeson *et al.*, 1995).

The most characteristic gross lesions appeared in the livers which were enlarged, pale yellow to grayish brown and had a prominent reticular pattern. Petechial hemorrhages were observed on the surface of some livers. Gall bladders were enlarged and bile duct distended and there was blood in the intestinal lumen (Archibald *et al.*, 1962; Azuzu and Shetty, 1986). The liver, spleen and kidney were increased in size, whereas the bursa of Fabricius and thymus were decreased (Smith and Hamilton, 1970; Huff and Doerr, 1980).

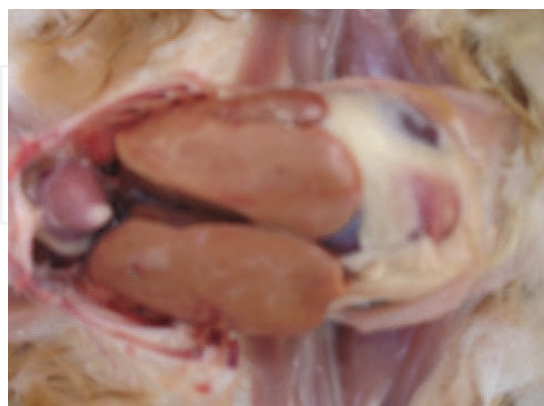Lethal aflatoxicosis can cause either dark red or yellow discoloration of the liver due to congestion or fat accumulation, respectively (Slowik *et al.*, 1985). At chronicity livers became shrunken, firm and nodular and gall bladder was distended (Asplin and Carnaghan, 1961). The kidneys of affected birds appeared enlarged and congested (Tung *et al.*, 1973) and the spleen will be enlarged and mottled in appearance (Tung *et al.*, 1975 a).

Histopathology of the liver revealed congestion of hepatic sinusoids, fecal hemorrhages, centro-lobular fatty cytoplasmic vacuolation and necrosis, biliary hyperplasia and nodular lymphoid infiltration. In the kidney, the epithelial cells of many tubules were vacuolated (Dafalla *et al.*, 1987 b). Azuzu and Shetty (1986) and Okoye *et al.*, (1988) observed severe degeneration of hepatocytes, dilation of central veins, bile duct proliferation and lymphocytic depletion in lymphoid organs in field outbreaks of aflatoxicosis in broilers.

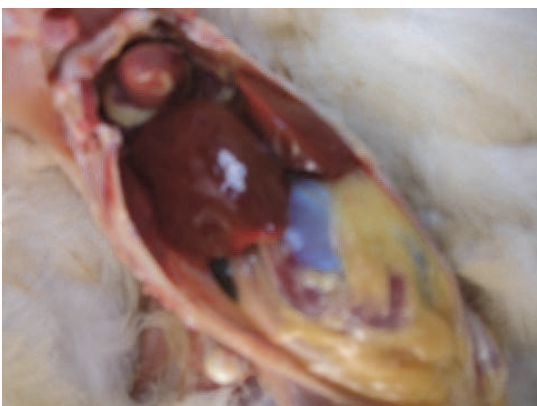
2.11.5 Laying hens

Reduced egg production and egg weight, enlarged liver and increased liver fat are the most prominent manifestations of experimental aflatoxicosis in layers (Nesheim and Lvy, 1971; Hamilton and Garlich, 1973; Leeson *et al.*, 1995). High mortality and dramatic reduction of egg production were reported to occur during a natural outbreak (Hamilton, 1971). Egg size, egg weight and yolk as percent of total egg size are decreased (Huff *et al.*, 1975). In Japanese quail, decreased feed conversion, egg production, egg weight, hatchability and exterior and interior egg quality were detected (Sawhney *et al.*, 1973a & b). Dhanasekaran *et al.*, (2009) reported that histopathological analysis of aflatoxin ingested hens reveals that lesions were

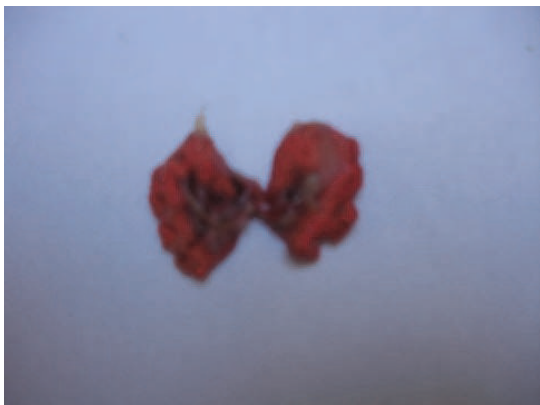observed in tissues of liver, kidney, intestine (Plate 1). Jayabharathi and Mohamudha parveen (2010) tested the aflatoxicosis in hens. Haematological analysis showed the decreased haemoglobin than the control group (Plate2).



Control Hens with various organs



Test Hens with accumulation of fatty layer

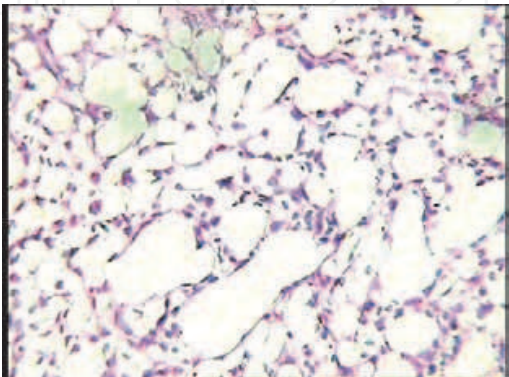


Lung (Control)

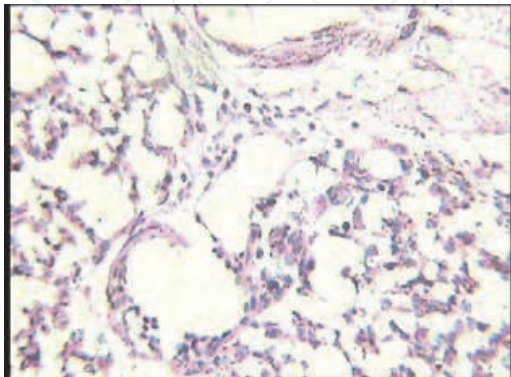


Lung (Test)

Plate 1. Organal view of Hens with Aflatoxicosis



Normal lung cells (Control)



Mild infiltration by L and P (Test)

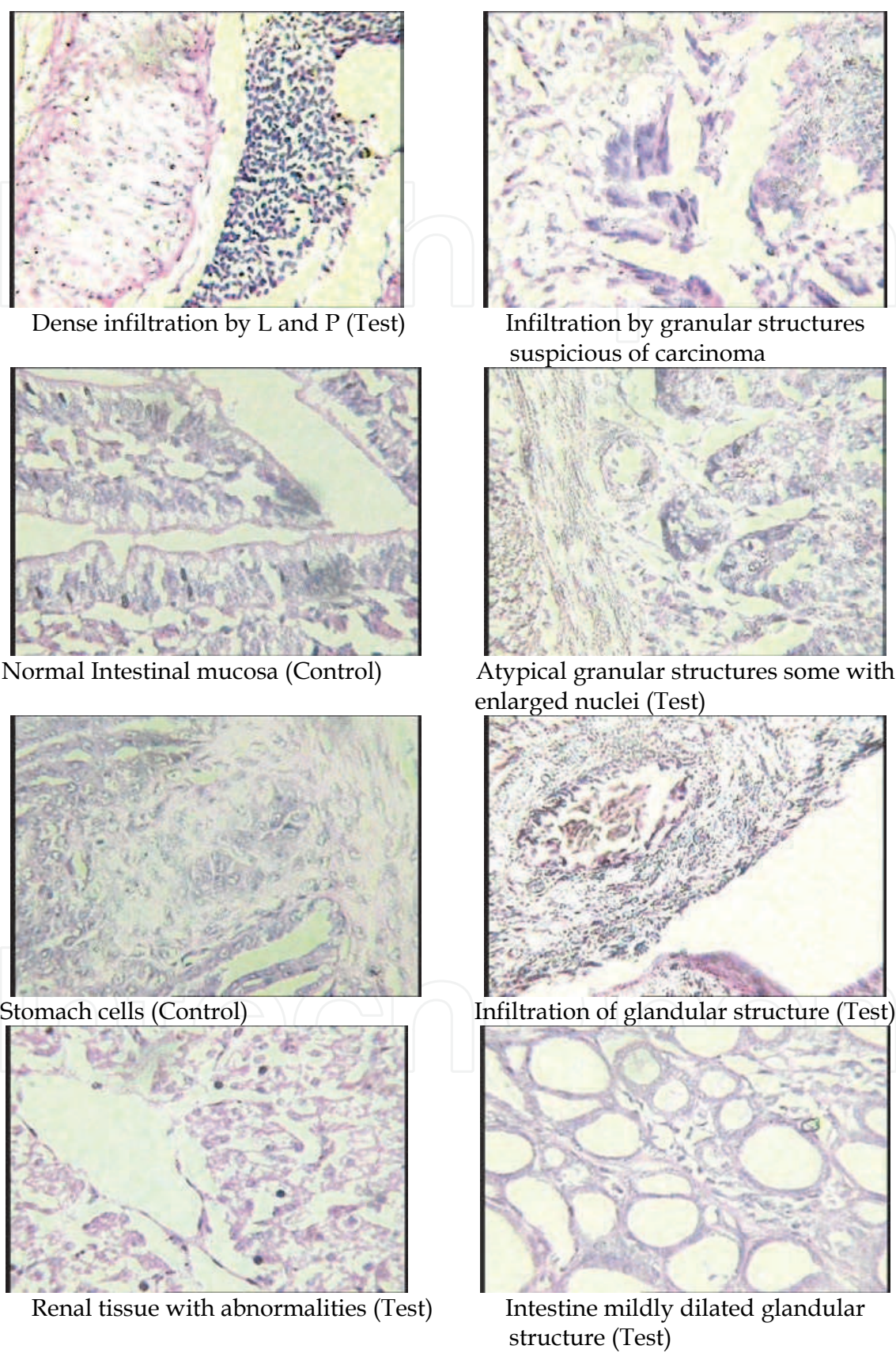


Plate 2. Histopathological analysis of various organs of hens with aflotoxicosis

2.12 Reproduction and hatchability

Aflatoxins causes delayed maturation of both males and females (Doerr, 1979; Doerr and Ottinger, 1980). Aflatoxicosis in white leghorn males resulted in decreased feed consumption, body weight, testes weight and semen volume (Sharlin *et al.*, 1980), and decreased plasma testosterone values (Sharlin *et al.*, 1980). While in broiler breeder males reduction in body weight and mild anemia with no alterations in semen characteristics were observed (Wyatt, 1991; Briggs *et al.*, 1974).

In mature laying hens experiencing aflatoxicosis, enlarged and fatty liver and marked decrease in egg production were observed (Hamilton and Garlich, 1972). Severe decline in hatchability was recorded in mature broiler breeder hens after consumption of aflatoxin (Howarth and Wyatt, 1976). Hatchability declines before egg production and is the most sensitive parameter of aflatoxicosis in broiler breeder hens (Howarth and Wyatt, 1976).

The immediate and severe decline in hatchability was found to arise from an increase in early embryonic mortality rather than infertility of the hens. The cause of the increased embryonic mortality is the transfer of toxic metabolites from the diet of the hen to the egg (Wyatt, 1991). The delayed response in egg production is thought to occur due to reducing synthesis and transport of yolk precursors in the liver (Huff *et al.*, 1975).

2.13 Immunosuppression

Aflatoxin induces immunosuppression and increases susceptibility of toxicated birds to bacterial, viral and parasitic infections. Immunosuppression caused by AFB1 has been demonstrated in chickens and turkeys as well as laboratory animals (Sharma, 1993).

Aflatoxin decreases the concentrations of immunoglobulins IgM, IgG and IgA in birds (Giambrone *et al.*, 1978a & b). The presence of low levels of AFB1 in the feed appears to decrease vaccinal immunity and may therefore lead to the occurrence of disease even in properly vaccinated flocks (Leeson *et al.*, 1995).

Thaxton *et al.*, (1974) recorded reduced antibody production following injection of sheep red blood cells in chickens experiencing aflatoxicosis. Batra *et al.*, (1991) found that chickens fed AFB1 and vaccinated against Marek's disease showed a significantly higher frequency of gross and microscopical lesions of Marek's disease than did chickens fed aflatoxin-free diet.

Cell-mediated immune response and effector cell function are also affected during aflatoxicosis (Leeson *et al.*, 1995). Aflatoxin decrease complement activity in chickens (Campbell *et al.*, 1983 and Stewart *et al.*, 1985) and turkeys (Corrier, 1991). Since complement is required for normal phagocytosis, impairment in complement activity may partially explain impairment of phagocytosis in chickens experiencing aflatoxicosis (Gewurz and Suyehira, 1976; Wyatt, 1991).

Chang and Hamilton (1979a) demonstrated reduced chemotactic ability of leucocytes, impaired phagocytosis of heterophils and impaired cellular and serum factors required for optimal phagocytosis in aflatoxicated chickens. Although thrombocytic counts are depressed by dietary aflatoxin (Mohiuddin *et al.*, 1986) their phagocytic activity is not affected by aflatoxin (Chang and Hamilton, 1979b). However, other phagocytic cells (heterophils, macrophages and monocytes) were affected by dietary aflatoxin (Chang and Hamilton, 1979a).

Chickens receiving aflatoxin-contaminated diets showed higher susceptibility to Marek's disease (Edds and Bortell, 1983), infectious bursal disease virus (Giambrone *et al.*, 1978a & b), congenitally acquired salmonellosis (Wyatt and Hamilton, 1975) and duodenal and cecal coccidiosis (Edds *et al.*, 1973) than chickens receiving aflatoxin free diet.

From the aforementioned, it is postulated that aflatoxin interferes with normal function of B and T lymphocytes, rather than causing destruction of these cells (Wyatt, 1991). The impairment of protein synthesis caused by dietary aflatoxin could account for the lack of humoral immunity without the necessity of B and T cell destruction (Wyatt, 1991). Regardless the atrophy of the bursa of fabricius and thymus gland, the apparent alteration of splenic function is also of diagnostic significance and implies alteration in the immunocompetence of birds with aflatoxicosis (Richard *et al.*, 1975).

2.14 Hematological and biochemical alterations

Aflatoxin causes hematopoietic suppression and anemia observed as decreases in total erythrocytes, packed-cell volume and hemoglobin (Reddy *et al.*, 1984; Huff *et al.*, 1986; Mohiuddin *et al.*, 1986). Total leucocytes are increased and differential leucocytic counts vary among studies with concurrent lymphopenia (Tung *et al.*, 1975a; Lanza *et al.*, 1980), monocytoses and heterophilia (Wannop, 1961).

Aflatoxin is known to produce hemolytic anemia by decreasing the circulating mature erythrocytes. Lysis of erythrocytes will result in above the normal levels of cellular debris in circulation (Tung *et al.*, 1975a) and consequently the spleen appear congested because of an unusually high concentration of inorganic iron and debris from the circulation (Wyatt, 1991).

Several biochemical parameters are affected by aflatoxin exposure. Aflatoxin decreases total serum proteins, alpha, beta and gamma globulins, with IgG being more sensitive than IgM (Tung *et al.*, 1975a). Total serum proteins contents are depressed due to reduced values of alpha and beta globulins and albumen, while gamma globulins are affected more variably (Pier, 1973).

Serum lipoproteins, cholesterol, triglycerides, uric acid and calcium are also decreased (Garlich *et al.*, 1973; Doerr *et al.*, 1983; Reddy *et al.*, 1984; Huff *et al.*, 1986). The activity of serum or plasma enzymes has been extensively used as a measure of aflatoxin activity in chickens. Increased activities of sorbitol dehydrogenase, glutamic dehydrogenase, lactate dehydrogenase, alkaline phosphatase, acid phosphatase, aspartate aminotransferase and alanine aminotransferase were reported in aflatoxicated chickens (Dafalla *et al.*, 1987b; Rao and Joshi, 1993; Leeson *et al.*, 1995). The increase in the levels of serum enzymes measured was interpreted as a consequence of hepatocyte degeneration and subsequent leakage of enzymes (Leeson *et al.*, 1995).

Aflatoxin has also shown to alter both the extrinsic and common clotting pathways in chickens. Aflatoxins causes biochemical changes in thromboplastin clotting factors V, VII and X and reduces plasma prothrombin and fibrinogen (Doerr *et al.*, 1976), and consequently increases whole blood clotting and prothrombin times (Doerr *et al.*, 1974). The elevated prothrombin time was considered to be the result of impaired hepatic synthesis of clotting factors caused by the toxication of aflatoxin on the liver cells (Huff *et al.*, 1983).

The activity of some digestive enzymes, the absorption of carotenoid compounds from the gastrointestinal tract, and the metabolism of lipids can be altered by aflatoxin exposure (Leeson *et al.*, 1995). Dietary aflatoxin produced a malabsorption syndrome characterized by steatorrhea, hypocarotenoidemia and decreased concentrations of bile salts and pancreatic lipase, trypsin, amylase and Rnase (Osbrone *et al.*, 1982). In another experiment, the specific activities of pancreatic chymotrypsin, amylase and lipase, but not trypsin were increased significantly by aflatoxin (Richardson and Hamilton, 1987).

The effect of aflatoxin on the renal function of broiler chickens was reported by Glahn (1993). Aflatoxin treated birds showed decreased fractional excretion of phosphate, total plasma calcium concentration, decreased total plasma proteins, plasma 25-hydroxyl vitamin D and plasma 1, 25-dihydroxy vitamin D.

2.15 Wild life

Birds, fishes and mammals vary among species in susceptibility to aflatoxins. Birds such as bobwhite quail and wild turkey appear to be more susceptible than mammals (Horn *et al.*, 1989). It is difficult to document the extent to which wildlife species are affected because wild animals are free roaming and elusive. In many cases, predators and scavengers may consume dead or dying animals before the dead animals are found by humans (Stewart and Larson, 2002).

Clinical signs of aflatoxicosis in wildlife vary according to the dose received, the time period of exposure, and species of animal. Toxic effects can be divided into acute, subacute and chronic exposures (Stewart and Larson, 2002). Acute effects reflect severe liver disease. Animals may be anemic and may exhibit difficulty in breathing. Sudden death with no clinical signs may occur. Subacute effects may allow animals to live for a longer period of time. These animals have yellow eyes, mucous membranes, or yellowed skin along with abnormalities in blood clotting. Bruising, nose bleeds and hemorrhaging may be observed. Chronic effects are generally related to impaired liver function. Long-term, low-level consumption of aflatoxins may result in reduced feed efficiency, weight loss, lack of appetite and increased receptivity to secondary infectious diseases. Lesions may occur in the liver and other organs and fluid may accumulate in the body cavity.

2.15.1 Fish

Fish have been found susceptible to aflatoxin and trichothecenes. Aflatoxicosis is most prevalent among fishes. The extent of lesions caused by consumption of aflatoxins depends upon the age and species of the fish. Fry are more susceptible to aflatoxicosis than adults and some species of fish are more sensitive to aflatoxins than others (Royes and Yanong, 2002). Rainbow trout are the most sensitive species to aflatoxin. Feeding trout diets containing less than 1 ppb will cause liver tumors in 20 months. (Horn *et al.*, 1989). Diet containing AFB1 at 0.4 ppb for 15 months had a 14% chance of developing tumors. Feeding trout a diet containing 20 ppb for 8 months resulted in 58% occurrence of liver tumors and continued feeding for 12 months resulted in 83% incidence of tumors (Royes and Yanong, 2002).

Deaths quickly occur in 50% of stock if dietary levels of 500 to 1000 ppb are consumed. Warm water fishes such as channel catfish (*Ictalurs punctatus*) are much less sensitive than rainbow trout, and the level required to cause 50% mortality is approximately 30 times that of rainbow trout (Horn *et al.*, 1989). Channel catfish fed a diet containing purified AFB1 at 10,000 ppb for 10 weeks exhibited decreased growth rate and moderate internal lesions (Royes and Yanong, 2002).

Initial findings associated with aflatoxicosis in fishes include pale gills, impaired blood clotting, poor growth rates or lack of weight gain. Prolonged feeding of low concentrations of AFB1 causes liver tumors, which appear as pale yellow lesions and which can spread to the kidney. Increased mortality may be observed (Royes and Yanong, 2002).

Aflatoxin can also depress the immune system indirect through their effect on enential nutrients in the diet, making fish more susceptible to bacterial, viral and parasitic diseases. Moreover, aflatoxin can cause slow growth rate and reduced weight of the finished product of warm-water fish (Royes and Yanong, 2002).

3. Conclusion

This chapter describes the food sources of aflatoxin contamination and their diseases in human and animals such as cattles, poultry, fish and other wild animals. Quality of food and feed plays the most important role in the farming as its share is 70%. Good quality food and resistant strain of animals can lead to greater production and more profit for the poultry, dairy, fishery former. However, the acute shortage of chicken, mutton, fish meat has pushed its prices steeply upwards. It is suggested that use of chicks, cow, sheep, fish, dog, horses are resistant to aflatoxicosis, would help in minimizing problem of poor growth rate and poor feed conversion which perhaps are the two most important factors in animal management.

4. References

- Abdelsalam, E. B.; Eltayeb, A.F.; Noreidin, A.A. & Abdulmagid, A. M.(1989). Aflatoxicosis in fattening sheep. *Vet. Rec*, Vol. 124, pp. 487-488.
- Agag, B.I. (2004). Mycotoxins in foods and feeds 1-Aflatoxins. *Ass Univ. Bull. Environ. Res*, Vol.7, No.1, pp.173-205
- Allcroft, R.; Roberts, B. A. & Lloyd, M. K. (1968). Excretion of aflatoxin in a lactating cow. *Food Cosmet. Toxicol*, Vol.6, pp.619- 625
- Andrellos, P. J. & Reid, G.B (1964). Confirmatory tests for aflatoxin B. *J. Assoc. Offic. Ag, Chemists* Vol.47, pp.801-803.
- Angsubhakorn, S.; Poomvises, P. Romruen, K. & Newbern, P.M. (1981). Aflatoxicosis in horses. *Am, Vet. Med. Asso.,* Vol.178, pp.274-278.
- Applebaum, R.S.; Brackett, R.E., Wiseman, D.W., & Marth, E.H. (1982). Aflatoxin toxicity to dairy cattle and occurrence in milk and milk products. *J. Food. Pro*, Vol.45, No.8, pp.752-777.
- Archibald, R.; Smith, H.J. & Smith, J.D. (1962). Brazilian groundnut toxicosis in Canadian broiler chickens. *Can. Vet. J*, Vol.3. pp.322-325.
- Armbrrecht, B.H.; Shalkop, W.T. Rollins, L.D. Pohland, A.E. & Stoloff, L. (1970). Acute toxicity of AFB1 in weathers. *Nature*, Lond. Vol.225, pp.1062-1063
- Asao, T. G.; Buchi, M. M, Abdel kader, S. B, Chang, E. L, Wick, & Wogan G.N. (1963). Aflatoxins B and G. *J. Am. Chem. So*, Vol.85, pp.1706-1707
- Asplin, F.D.& Carnaghan, R.B. (1961). The toxicity of certain groundnut meals for poultry with special reference to their effect on ducklings and chickens. *Vet. Res*, Vol.3, pp. 1215-1219.
- Asuzu, I.U. & Shetty, S.N. (1986). Acute aflatoxicosis in broiler chicken in Nsuka, Nigeria. *Trop. Vet*, Vol.4, pp.79-80
- Bababunmi, E. A.& Bassir, O. (1969). The effect of aflatoxin on blood clotting in the rat. *Brit. J. Pharmacol*, Vol.37, pp.497-500

- Bassir, O. & Osiyemi, F. (1967). Biliary excretion of aflatoxin in the rat after a single dose. *Nature*, Vol.215, pp.882
- Bastianello, S.S.; Nesbit, J.W. Williams, M.C. & Lange, A.L. (1987). Pathological findings in a natural outbreak of aflatoxicosis in dogs. *Onderstepoort J. Vet. Res*, Vol.54, pp.635-640.
- Batra, P.; Pruthi, A.K. & Sadana, J.R. (1991). Effect of AFB1 of the efficacy of turkey herpes virus vaccine against Marek's disease. *Res. Vet. Sc*, Vol.51, pp.115-119
- Blaney, B.K. & Williams, K.C. (1991). Effective use in livestock feeds of mouldy and weather damaged grain containing mycotoxins. Case histories and economic assessments pertaining to pig and poultry industries of Queensland. *Aust. J. Agric. Res*, Vol.42, pp.993-1012
- Bodine, A.B. & Mrtens, D.R. (1983). Toxicology, metabolism and physiological effects of aflatoxin in the bovine. pp.46-50. In: U.L. Diener; R.L. Asquith and J.W. Dickens Eds. *Aflatoxin and A. flavus in corn. AAES, Auburn Univ., Alabama*.
- Bortell, R.; Asquith, R.L. Edds, G.T. Simpson, C.F. Aller, W.W. (1983). Acute experimentally induced aflatoxicosis in the weanling pony. *American Journal of Veterinary Research*, Vol.44, pp.2110-2114
- Brackett, R.E. & Marth, E.H. (1982). Association of AFM1 with casein. *Z. Lebensm Unters Forsch*, Vol.174, pp.439
- Briggs, D.M.; Wyatt, R.D. & Hamilton, P.B. (1974). The effect of dietary aflatoxin on semen characteristics of mature broiler breeder males. *Poult. Sci*, Vol.53, pp.2115-2119
- Brown, J.M.M. & Abrams, L. (1965). Biochemical studies on aflatoxicosis. *Onderstepoort, J. Vet. Res.*, Vol. 32, pp. 119-146.
- Bryden, W.L.; Lioyd, A.B. & Cumming, R.B. (1980). Aflatoxin contamination of Australian animal feeds and suspected cases of mycotoxicosis. *Aust. Vet. J*, Vol.56, pp.176-180
- Buchi, G.; Spitzner, D. Paglialunga, S. & Wogan, G. N. (1973). Synthesis and toxicity evaluation of aflatoxin P1. *Life Sci*, Vol. 3, pp.1143-1149
- Burg, W.R. & Shotwell, O.L. (1984). Aflatoxin levels in airborne dust generated from contaminated corn during harvest and at an elevator in 1980. *Journal of the Association of Official Analytical Chemists* Vol.67, pp.309-312
- Burnside, J.E.; Sipple, W.L. Forgacs, J, Carll, W.T, Atwood, M.B. & Doll, E.R. (1957). A disease of swine and cattle caused by eating moldy corn. II. Experimental production with pure cultures of molds. *Am. J. Vet. Res*, Vol.18, pp.817
- Calnek, B.C.; Barnes, H.J. McDougald, L.R. & Saif, Y.M. (1997). *Diseases of poultry*. 10th ed., pp.951-979. Mosby-Wolfe, Iowa state Univ. press, Ames, Iowa, USA.
- Caloni, F. & Cortinovis, C. (2011). Toxicological effects of aflatoxins in horses. *The veterinary journal*. Vol.188, pp. 270-273
- Campbell, T.C. & Hayes, J.R. (1976). *Toxicol. Appl. Pharmacol*, Vol.35, pp.199-222. Cited by Hsieh (1983).
- Carnaghan, R. B. A.; Lewis, G. Patterson, D. S. P. & Allcroft R. (1966). Biochemical and pathological aspects of groundnut poisoning in chickens. *Pathol. Vet*.3, pp.601-615
- Cassel, E.K.; Barao, S.M. and Carmal, D.K. (1988). Aflatoxicosis and ruminants. *Texas Vet. Med. Diagnostic lab, Texas college*. The national dairy database (1992) NDB, Health, Test, Hf100200. TxT

- CAST, Council for Agric. Sci. and Technol. (1989). Mycotoxins economic and health risks. Task force report No.116
- Chaffee, V.W.; Edds, G.T. Himes, J.A. & Neal, F.C. (1969). Aflatoxicosis in dogs. *Am. J. Vet. Re.*, Vol.30, pp.1737-1749
- Chang, C.F. & Hamilton, P.B. (1979a). Impaired phagocytosis by heterophils from chickens during aflatoxicosis. *Toxicol. Appl. Pharmacol*, vol.6, pp.459
- Chang, C.F. & Hamilton, P.B. (1979b). Refractory phagocytosis by chicken thrombocytes during aflatoxicosis. *Poult. Sci*, Vol.58, pp.559-561
- Colvin, B.M.; Harrison, L.R. Grosser, H.S. & Hall, R.F. (1984). Aflatoxicosis in feeder cattle. *J. Am. Vet. Med. Assoc.* Vol.184. pp.956.
- Cook, W.O.; Richard, J.L. Osweiller, G.D. & Trampel, D.W. (1986). Clinical and pathological changes in acute bovine aflatoxicosis. Rumen motility and tissue and fluid concentrations of aflatoxins B1 and M1. *Am. J. Vet. Res*, Vol.47, pp.1817-1825
- Cook, W.R. (1976). Chronic bronchitis and alveolar emphysema in the horse. *Veterinary Record*, Vol.99, pp.448-451
- Corrier, D.E. (1991). Mycotoxicosis: Mechanism of immunosuppression. *Vet. Immunol. Immuno Pathol*, Vol.30, pp.73-87
- Cysewski, S.J.; Pier, A.C. Baetz, A.L. & Cheville, N.F. (1982). Experimental equine aflatoxicosis. *Toxicology and Applied Pharmacology*, Vol.65, pp. 354-365
- Dafalla, R.; Hassan, Y.M. & Adam, S.E.I. (1987a). Fatty and hemorrhagic liver and kidney syndrome in breeding hens caused by AFB1 and heat stress in the Sudan. *Vet. Hum. Toxicol*, Vol.29, pp.222-226
- Dafalla, R.; Yagi, A.I. & Adam, S.E.I. (1987b). Experimental aflatoxicosis in Hybro-type chicks: Sequential changes in growth and serum constituents and histopathological changes. *Vet. Human Toxicol*, Vol.29, pp.222-225
- Dalezios, J. I.; Wogan, G. N. & Weinreb, S. M. (1971). Aflatoxin P1: A new aflatoxin metabolite in monkeys. *Science*, Vol.171, pp.584-585
- Dalvi, R.R. & McGowan, C. (1984). Experimental induction of chronic aflatoxicosis in chickens by purified aflatoxins B1 and its reversal by activated charcoal, Phenobarbital and reduced glutathione. *Poult. Sci*, Vol. 63, PP. 485-491.
- Dalvi, R.R. & Ademoyero, A.A. (1984). Toxic effects of aflatoxins B1 in chickens given feed contaminated with aspergillus flavus and reduction of the toxicity by activated charcoal and some chemical agents. *Avia. dis*, Vol. 28, PP. 61-69.
- De Iongh, H.; Beerthuis, R. K. Vles, R. O. Barrett, C. B. & Ord, W. O. (1962). Investigation of the factor in groundnut meal responsible for Turkey "x" disease. *Biochim. Biophys. Acta*, Vol.65, pp.548-551
- DeIongh, H., Vles, R. O. & VanPelt, J. G. (1964). Milk of mammals fed an aflatoxin containing diet. *Nature*, Vol. 202, pp.466-467
- Devero, A. (1999). Aflatoxins: The effects on human and animal health. *Biol*, 4900; Fall, 1999
- Dhanasekaran, D.; Panneerselvam, A. & Thajuddin, N. (2009). Evaluation of Aflatoxicosis in hens fed with commercial poultry feed. *Turk. J. Vet. Anim. Sci*, Vol.33, No.5. pp.385-391
- Diekman, A.; Coffey, M.T. Purkhiser, E.D. Reeves, D.E. & Young, L.G. (1992). Mycotoxins and swine performance. CES, PTH-129, Purdue Univ., West Lafayette, Indian.

- Diener, U.L. & Davis, N.D. (1968): "Effect of environment on aflatoxin production in peanuts. *Tropical science*, Vol.10, pp.22-25
- Doerr, J.A. & Ottinger, M.A. (1980). Delayed reproductive development resulting from aflatoxicosis in Juvenile Japanese quail. *Poult. Sci*, Vol.59, pp.1995-2001
- Doerr, J.A. & Ottinger, M.A. (1980). Delayed reproductive development resulting from aflatoxicosis in Juvenile Japanese quail. *Poult. Sci.*, Vol.59, 1995- 2001.
- Doerr, J.A. (1979). *Mycotoxins and avian hematoses*. Diss. Abstr. B Sci. Eng., 4127.
- Doerr, J.A.; Huff, W.E. Wabeck, C.J. Chaloupka, G.W. May, J.D. & Merkley, J.W. (1983). Effects of low level chronic aflatoxicosis in broiler chickens. *Poult. Sci*, Vol.62, pp.1971-1977
- Doerr, J.A.; Huff, W.E. Wyatt, R.D. & Hamilton, P.B. (1974). Survey of T-2 toxin, ochratoxin and aflatoxin for their effects on the coagulation of blood in young broiler chickens. *Poult. Sci*, Vol.53, pp.1729
- Doerr, J.A.; Wyatt, R.D. & Hamilton, P.B. (1976). Impairment of coagulation function during aflatoxicosis in young chickens. *Toxicol. Appl. Pharmacol*, Vol.35, pp.437
- Donaldson, W. E.; Tung, H.T. & Hamilton, P.B. (1972). Depression of fatty acid synthesis in chick liver (*Gallus domesticus*) by aflatoxins. *Comp. Biochem. Physiol*, Vol.41, pp. 843-847.
- Eaton, D.L. and Groopman, J.D. (1994). The toxicology of aflatoxins. Human health, veterinary and agricultural significance. pp. 6-8 Academic press, San Diego, Ca.
- Edds, G.T. & Bortell, R.A. (1983). Biological effects of aflatoxins-poultry. pp. 56-61. In: L U.L. Diener, R.L. Asquith and J.W. Dickens Eds. *Aflatoxin and A. flavus in corn* AAES, Auburn Univ, Alabama
- Edds, G.T.; Nair, N.P. & Simpson, C.F. (1973). Effect of AFB1 on resistance in poultry against cecal coccidiosis and Marek's disease. *Am. J. Vet. Res*, Vol.34, pp.819-826
- FDA, Food and Drug Administration (1979). Conference on mycotoxins in animal feeds and grains related to animal health. Rockville, Maryland
- Fehr, P.M. & Delage, J. (1970). Effect de l'aflatoxine sur les fermentations du rumen. *Can. Nutr. Diet*, Vol.5, pp.59-61
- Fouzia Begum. & Samajpati.N (2000). Mycotoxins production on rice, pulses and oilseeds. *Naturwissenschaften*, Vol.87, pp.275-277
- Garlich, J.D.; Tung, H.T. & Hamilton, P.B. (1973). The effects of short term feeding of aflatoxin on egg production and some plasma constituents of laying hens. *Poult. Sci*, Vol.52, pp.2206.
- Gewurz, H. & Suyehira, L.A. (1976). *Manual of clinical immunology*. Rose, N.R. and Friedman, H.R. Eds., American Society of Microbiologists, Washington, D.C., 36.
- Giambrone, J.J.; Diener, U.I. Davis, N.D. Panangala, V.S. & Hoerr, F.J. (1985). Effects of aflatoxin on young turkeys and broiler chickens. *Poult. Sci*, Vol.64, pp.1678-1684
- Giambrone, J.J.; Ewert, D.L. Wyatt, R.D. & Eidson, C.S. (1978a). Effect of aflatoxin on the humoral and cell-mediated immune systems of chicken. *Am. J. Vet. Res*, Vol.39, pp. 305
- Giambrone, J.J.; Partadiredja, M. Eidson, C.S. Kleven, S.H. and Wyatt, R.D. (1978b). Interaction of aflatoxin with infectious bursal disease virus infection in young chickens. *Avian Dis*, Vol.22, pp.431

- Gillespie, J.R. & Tyler, W.S. (1969). Chronic alveolar emphysema in the horse. *Advances in Veterinary Science and Comparative Medicine*, Vol.13, pp.59–99
- Glahn, R.P. (1993). Mycotoxins and the avian kidney: Assessment of physiological function. *World. Poult. Sci. J*, Vol.49, pp.242-250
- Greene, H.J. & Oehme, F.W. (1976). A possible case of equine aflatoxicosis. *Clinical Toxicology*, Vol.9, pp.251–254
- Groopman, J.D.; Donahue, P.R. Zhu, J. Chen, J. & Wogan, G.N. (1985). Aflatoxin metabolism in humans. Detection of metabolites and nucleic acid adducts in urine by affinity chromatography. *Proc. Natl. Acad. Sci., USA*, Vol.82, pp.6492-6497
- Guthrie, L.D. (1979). Effect of aflatoxin in corn on production and reproduction in dairy cattle. *J. Dairy Sci*, Vol.62, pp.134
- Halliwell, R.E.W.; McGorum, B.C. Irving, P. & Dixon, P.M. (1993). Local and systemic antibody production in horses affected with chronic obstructive pulmonary disease. *Veterinary Immunology and Immunopathology*, Vol.38, pp. 201–215
- Hamilton, P. B. & Harris, J. R. (1971). Interaction of aflatoxicosis with *Candida albicans*: infections and other stresses in chickens. *Poult. Sci*, Vol. 50, pp.906-912
- Hamilton, P.B. & Garlich, J.D. (1972). Failure of vitamin supplementation to alter the fatty liver syndrome by aflatoxin. *Poult. Sci*, Vol.51, pp.688
- Hamilton, P.B. (1971). A natural and extremely severe occurrence of aflatoxicosis in laying hens. *Poult. Sci*, Vol.50, pp.1880-1882
- Hartley, R. D.; Nesbitt, B. F. & O'Kelly, J. (1963). Toxic metabolites of *Aspergillus flavus*. *Nature*, Vol.198, pp.1056-1058
- Hatch, R.C.; Clark, J.D. Jain, A.V. & Mahaffey, E.A. (1971). Experimentally induced acute aflatoxicosis in goats treated with ethyl maleate glutathione precursors or thiosulfate. *Am. J. Vet. Res*, Vol.40, pp.405-411
- Hegazy, S.M.; Azzam, A. & Gabal, M.A. (1991). Interaction of naturally occurring aflatoxins in poultry feed and immunization against fowl cholera. *Poult. Sci*, Vol.70, pp. 2425-2428
- Hesseltine, C.W. (1983). Introduction, definition and history of mycotoxins of importance to animal production. In: *Interactions of mycotoxins in animal production*. National Academy of Science, Washington, DC.
- Hetzel, D.J.S.; Hoffmann, D. Van De Ven, J. & Soeripto, S. (1984). Mortality rate and liver histopathology in four breeds of ducks following long term exposure to low levels of aflatoxins. *Sing. Vet. J*, Vol.8, pp6-14
- Holzapel, C. W.; Steyn, P. S. & Purchase, I. F. H. (1966). Isolation and structure of aflatoxins M I and M 2. *Tetrahedron Lett*, Vol. 25, pp.2799-2803
- Horn, C.W.; Boleman, L.L. Coffman, C.G. Deton, J.H. & Lawhorn, D.B. (1989). Mycotoxins in feed and food producing crops college state Texas. *Texas Vet. Med. Diagnostic*, The National Dairy Database (1992)
- Horr, F.J. & D'Andrea, G.H. (1983). Biological effects of aflatoxin in swine. pp.51-55. In: U.L. Diener; R.L. Asquith and J.D. Dickens Eds. *Aflatoxin and A. flavus in corn* AAES, Auburn Univ. Alabama

- Howarth, B.Jr. & Wyatt, R.D. (1976). Effect of dietary aflatoxin on fertility, hatchability and progeny performance of broiler breeder hens. *Appl. Environ. Microbiol*, Vol.31, pp.680-684
- Huff, W.E. & Doerr, J.A. (1980). Synergism between aflatoxin and OA in broiler chickens. *Poult. Sci*, Vol.60, pp.55
- Huff, W.E.; Doerr, J.A. Wabeck, C.J. Chaloupka, O.W. May, J.D. & Merkley, J.W. (1983). Individual and combined effects of aflatoxin and ochratoxin A on bruising in broiler chickens. *Poult. Sci*, Vol.62, pp.1764-1771
- Huff, W.E.; Kubena, R.B. Harvey, R.H. Corrier, D.E. & Mollenhaur, H.H. (1986). Progression of aflatoxicosis in broiler chickens. *Poult. Sci*, Vol.65, pp.1891-1899
- Huff, W.E.; Wyatt, R.D. & Hamilton, P.B. (1975). Effects of dietary aflatoxin on certain egg yolk parameters. *Poult. Sci*, Vol.54, pp.2014-2018
- Humphreys, D.J. (1988). *Veterinary toxicology*. 3rd ed. pp. 286, Bailiere Trindell, London
- Hutjens, M. (1983). *Aflatoxin contaminated feed and dairy*. In: J. Jacobsen, Aflatoxin 83. Texas Vet. Med. Diagnostic lab., Texas collage.
- Jayabarathi, P. & Mohamudha Parveen, R. (2010). Biochemical and histopathological analysis of aflatoxicosis in Growing hens fed with commercial poultry feed. *International Journal of Pharmaceutical Sciences Review and Research* , Vol.3, No.2, pp. 127-130
- Jones, F.T.; Beth, M. Genter, M.M. Hagler, W.M. Hansen, J.A. Mowrewy, B.A. Poore, M.H. & Whitlow, L.W. (1994). Understanding and coping with effects of mycotoxins in livestock feed and forage. Electronic publication No. DRO-29, NCCES, North Carolina State Univ., Raleigh, North Carolina.
- Jones, F.T.; Hagler, W.H. & Hamilton, P.B. (1982). Association of low levels of aflatoxin in feeds with productivity losses in commercial broiler operations. *Poult. Sci*, Vol.6, pp. 861-868
- Jones, N.R. & Jones, B.D. (1978). *Aflatoxins*. Voeding, Vol.30, pp.330
- Kato, R., Takaoka, A. Onoda, K. & Omori, Y. (1970). Different effect of aflatoxin on the induction of tryptophan oxygenase and of microsomal hydroxylase system. *J. Biochem*, (Tokyo). Vol.68, pp.589-592
- Keeler, R.F. & Tu, A.T. (1983). *Handbook of natural toxins*. Vol. I. *Plant and fungal toxin*, pp.308, New York, Marcal Dekker, Inc
- Kiemeier, F. & Buchner, M. (1977). Zur verteilung van aflatoxin M1 auf Molke and Bruch bei der Kaseherstellung. *Z. Lebensm. Unters. Forsch*, Vol.164, pp.87
- Krishnamachari, K.A.; Bhat, R.V. Nagarajan, V. & Tilak, T.B. (1975a). Investigations into outbreak of hepatitis in parts of Western India. *Indian J. Med. Res*, Vol.63, pp.1036-1049
- Krishnamachari, K.A.; Nagarajan, V.; Bhat, R.V. & Tilak, T.B. (1975b). Hepatitis due to aflatoxicosis. An outbreak in Western India. *Lancet* i. pp.1061-1062
- Lamont, M.H. (1979). Cases of suspected mycotoxicosis as reported by veterinary investigation centers. *Proc. Mycotoxins Anim. Dis*, Vol.3, pp.38-39
- Lanza, G.M.; Washburn, K.W. & Wyatt, R.D. (1980). Strain variation in hematological response of broilers to dietary aflatoxin. *Poult. Sci*, Vol.59, pp.2686-2691

- Larsson, P., Persson, E., Tydén, E. & Tjälve, H. (2003). Cell-specific activation of aflatoxin B1 correlates with presence of some cytochrome P450 enzymes in olfactory and respiratory tissues in horse. *Research in Veterinary Science*, Vol.74, pp.227-233
- Lawlor, P.G. & Lynch, P.B. (2001). Mycotoxins in pig feeds. 2: clinical aspects. *Irish Vet. J*, Vol.54, No.4, pp.172-176
- Leeson, S.; Diaz, G.J. & Summers, J.D. (1995). *Poultry metabolic disorders and mycotoxins*. pp. 249-298, University Books, Guelph, Ontario, Canada
- Liggett, A.D.; Colvin, B.M. Beaver, R.W. & Wilson, D.M. (1986). Canine aflatoxicosis: A continuing problem. *Vet. Hum. Toxicol*, Vol.28, pp.428-430
- Lillehoj, E.B. (1983). Effect of environmental and cultural factors of aflatoxin contamination of developing corn kernels. In: V.L. Diener, R.L. Asquith and J.W. Dickens (Eds). *Aflatoxin and A. flavus in corn*. Southern Coop Serv. Bull. 279, Craftmaster, Opelika, Ala, 112P.
- Lynch, G.P. (1972). Mycotoxins in feedstuffs and their effect on dairy cattle. *J. Dairy Sci*, Vol.55, pp.1243-1255
- Masri, M. S.; Booth, A. N. and Hsieh, D. P. H. (1974). Comparative metabolic conversion of aflas B1 to aflatoxin M1 and aflatoxin Q by monkey, rat, and chicken. *Life Sci*, Vol.15, pp.203-212
- Masri, M.S.; Catcia, V.C. & Page, J.R. (1969). AFM content of milk from cows fed known amounts of aflatoxin. *Vet. Rec*, Vol.84, pp.146-147
- Meerdink, G.L. (2002). Mycotoxins. *Clinical Techniques in Equine Practice* 1. pp.89-93
- Mintzlaff, H. J., Lotzsch, R. Tauchmann, F. Meyer, W. & Leistner, L. (1974). Aflatoxin residues in the liver of broiler chicken given aflatoxin-containing feed. *Fleischwirtschaft*, Vol.54, pp.774-778
- Mohiuddin, S.M.; Reddy, M.V. Reddy, M.M. & Ramakrishna, K. (1986). Studies on phagocytic activity and haematological changes in aflatoxicosis in poultry. *Indian Vet. J*, Vol.63, pp.442-445
- Morhouse, L.G. (1981). Mycotoxins-their toxicology and principle lesions. *Proc. U.S. Anim. Health Assoc.* pp.232.
- Muller, R.D.; Carlson, C.W. Semenik, G. & Harshfield, G.S. (1970). The response of chicks, duckling, goslings, pheasants and poults to graded levels of aflatoxins. *Poult. Sci*, Vol.49, pp.1346-1350
- Nabney, J.; Burbage, M. B. Allcroft, R. and Lewis, G. (1967). Metabolism of aflatoxin in sheep. Excretion pattern in the lactating ewe. *Food Cosmet. Toxicol.* Vol.5. pp.11-17
- Nesbitt, B.; O'Kelly, K.; Sargeant, K. & Sheridan, A. (1962). Toxic metabolites of *Aspergillus flavus*. *Nature*, Vol.195, pp.1062-1063
- Newberne, P.M.; Russo, R. and Wogan, G.N. (1966). Acute toxicity of AFB1 in the dog. *Pathol. Vet.* Vol.3. pp.331-340.
- Nibbelink, S.K. (1986). Aflatoxicosis in food animals. *A clinical review*. Iowa State Univ.Vet. Vol.48, pp. 28-31.
- Nesheim, M.C. & Ivy, C.A. (1971). Effect of aflatoxin on egg production and liver fat in laying hens. *Cornell Nutr. Conf. Buffalo*, pp. 126-129.
- Okoye, J.O.A.; Asuzu, I.U. & Gugnani, J.C. (1988). Paralysis and lameness associated with aflatoxicosis in broilers. *Avian Pathol*, Vol.17, pp.731-734


- Osborne, D.J.; Huff, W.E. Hamilton, P.B. & Burtmeister, H.R. (1982). Comparison of ochratoxin, aflatoxin and T-2 toxin for their effects on selected parameters related to digestion and evidence for specific metabolism of carotenoids in chickens. *Poult. Sci*, Vol.61, pp.1646-1652.
- Osweiler, G.D. (1992). Mycotoxins. In: *Diseases of swine*. 7th ed. pp.735-743. Edited by A.D. Leman, B.E. Straw, W.L. Mengeling, S.D.; Allaire & D.J. Taylor Wolfe publishing, London
- Patterson, D.S.P. & Roberts, B.A. (1970). The formation of aflatoxin B_{2a} and G_{2a} and their degradation products during the *in vitro* detoxification of aflatoxin by livers of certain avian and mammalian species. *Food Cosmet. Toxicol*, Vol. 8, pp. 527-538.
- Patterson, D.S.P. & Allcroft, R. (1970). Metabolism of aflatoxins in susceptible and resistant animal species. *Fd. Cosmet. Toxicol*, Vol.8, pp.43
- Patterson, D.S.; Galaney, E.M. & Roberts, B.A.(1978). The estimation of AFM1 in milk using 2-dimensional TLC. *Fd.Cosmet toxicol*, Vol.16, pp.49-50
- Pier, A.C. (1973). Effects of aflatoxin on immunity. *J. Amer. Vet. Med. Assoc*, Vol.163, pp.1268-1269
- Pier, A.C.; Cysewski, S.J. Richard, J.L. Baetz, A.L. & Mitchell, L. (1976). *Proc. U.S., Anim. Hlth. Assoc*, Vol.80, pp.130. In: Mackenzie *et al.* (1981)
- Price, R.L.; Paulson, J.H. Lough, O.E. Gingg, C. & Kurtz, A.G. (1985). Aflatoxin conversion by dairy cattle consuming naturally contaminated whole cottonseed. *J. Fd. Prot*, Vol.48, pp.11-15
- Radostits, O.M.; Gay, C.C. Blood, D.C. & Hinchcliff, K.W. (2000). *Veterinary medicine*, pp.1684-1688, W.B. Saunders Co. Ltd., London.
- Raisbeck, M.F.; Rottinghaus, G.E. & Kendall, J.D. (1991). Effects of naturally occurring mycotoxins on ruminants. pp. 647-677.
- Rao, V.N. & Joshi, H.C. (1993). Effect of certain drugs on acute induced aflatoxicosis in chicken (4 mg AFB1/ kg b.wt.). *Ind. Vet. J*, Vol 70, pp.344-347
- Ray, A.C.; Abbitt, B. Cotter, S.R. Murphy, M.J.; Reagor, J.C. Robinson, R.M. West, J.E. and Whitford, H.W. (1986). Bovine abortion and death associated with consumption of aflatoxin contaminated peanuts. *J. Am. Vet. Med. Assoc*, Vol.184, pp.956
- Reagor, J.C. (1996). *Implications of mycotoxins in horses*. WEVR, 96, Cybersteed, Inc.
- Reddy, D.N.; Rao, P.V. Reddy, V.R. and Yadgiri, B. (1984). Effect of selected levels of dietary aflatoxin on the performance of broiler chickens. *Indian, J. Anim. Sci*, Vol.54, pp.68-73
- Richard, J.L.; Pier, A.C. Stubblefiels, R.D. Shotwell, O.L. Lyon, R.L. and Cutlip, R.C. (1983). Effect of feeding cornnaturally contaminated with aflatoxin on feed efficiency, on physiology, immunologic and pathologic changes and in tissue residues in steers. *Am. J. Vet. Re*, Vol.44, pp.1294
- Richard, L.J.; Stubblefield, R.D. Lyon, R.L. Peden, W.M. Thurston, J.R. & Rimler, R.B. (1987). Distribution and clearance of aflatoxin B1 and M1 in turkeys fed diets containing 50 or 150 ppb aflatoxin from naturally contaminated corn. *Avian Dis*, Vol.30, pp.788-793

- Richard, T.L.; Thurston, J.R. & Pier, A.C. (1975). *Mycotoxin-induced alterations in immunity*. In: Microbiology, Schlessinger, D. Ed., American Society of Microbiologist, Washington, D.C.
- Richardson, K.E. & Hamilton, P.B. (1987). Enhanced production of pancreatic digestive enzymes during aflatoxicosis in egg-type chickens. *Poult. Sci*, Vol.66, pp.1470-1478
- Rodricks, J.V. & Stoloff, L. (1977). *Mycotoxins in human and animal health*. Pathotox publishers, park forest, south, 1L, pp.67-69
- Royes, J.B. & Yanong, R.P. (2002). *Molds in fish feeds and aflatoxicosis*. Copyright by the University of Florida, *Institute of Agric. Sci.* (UF/ IFAS)
- Rumbeiha, W. (2001). *Mycotoxins in pets*. DCPAH-Newsletter. Vol.18, No. 2.
- Samarajeewa, U.; Arseculeratne, S.N. & Tennekoon, G.E. (1975). Spontaneous and experimental aflatoxicosis in goats. *Res. Vet. Sci*, Vol.19, pp.269-277
- Sargeant, K.; Carraghan, R.B. & Allcroft, R. (1963). Toxic products in groundnuts. Chemistry and origin. *Chem. And Ind*, pp.53-55
- Sargeant, K.; Sheridan, J.; O'Kelly, J. & Carnaghan, R. B. A. (1961). Toxicity associated with certain samples of groundnuts. *Nature*, Vol.192, pp.1096-1097
- Sawhney, D.S.; Vadehra, D.V. & Baker, R.C. (1973a). Aflatoxicosis in the laying Japanese quail. *Poult. Sci*, Vol.52, pp.485-493
- Sawhney, D.S.; Vadehra, D.V. & Baker, R.C. (1973b). The metabolism of ¹⁴C aflatoxins in laying hens. *Poult. Sci*, Vol.52, pp.1302-1309
- Schabort, J. C. & Steyn, M. (1969). Substrate and Phenobarbital inducible aflatoxin-4-hydroxylation and aflatoxin metabolism by rat liver microsomes. *Biochem. Pharmacol*, Vol.1, pp.2241-2252
- Shank, R. C. & Wogan, G. N. (1966). Acute effects of aflatoxin B1 on liver composition and metabolism in the rat and duckling. *Toxicol. Appl. Pharmacol*, Vol.9, pp.468-476.
- Shank, R.C. (1977). *Environmental cancer*. pp.291-318. In: H.F. Kraybill and M.A. Mehlman (eds.), John Wiley sons Ltd New York.
- Shankaran, R.; Raj H. G. & Venkatasubramanian T. A. (1970). Effect of aflatoxin on carbohydrate metabolism in chick liver. *Enzymologia*, Vol.39, pp.371-378
- Sharlin, J.S.; Howarth, B.Jr. Thompson, E.N. and Wyatt, R.D. (1981). Decreased reproductive potential and reduced feed consumption in nature white leghorn males fed aflatoxin. *Poult. Sci*, Vol.60, pp.2701
- Sharma, R.P. (1993). Immunotoxicity of mycotoxins. *J. Dairy Sci*, Vol.76, pp.892-897
- Siller, W.G. & Ostler, D.C. (1961). The histopathology of an entero-hepatic syndrome of turkey poults. *Vet. Rec*, Vol.73, pp.134-138
- Sisk, D.B.; Carlton, W.W. and Curtin, T.M. (1968). Experimental aflatoxicosis in young swine. *Am. J. Vet. Res*, Vol.29, pp.207-215
- Slowik, J.; Graczyk, S. and Madej, J.A. (1985). The effect of single dose of AFB1 on the value of nuclear index of blood lymphocytes and on histopathological changes in the liver, bursa of fabricious, suprarenal glands and spleen in ducklings. *Folia Histochem. Cytobiol* Vol.3. pp.71-80.
- Smith, B.P. (2002). *Large animal internal medicine*. 3rd ed. pp.1627-1637. Mosby, Inc. USA.
- Smith, J. W.; Prince, W. R. & Hamilton, P. B. (1969). Relationship of aflatoxicosis to *Salmonella gallinarum* infections of chickens. *Appl. Microbiol*, Vol.18, pp.946-947

- Smith, J.E. & Hamilton, P.B. (1970). Aflatoxicosis in the broiler chicken. *Poult. Sci*, Vol.49, pp.207
- Smith, R. H. (1965). The inhibition of amino acid activation in liver and *E. coli* preparations by aflatoxin in vivo. *Biochem. J*, Vol.95, pp.438-448
- Sorensson, W.G.; Simpson, J.P. Peach, M.J. Thedell, T.D. & Olenchock, S.A. (1981). Aflatoxin in respirable dust particles. *Journal of Toxicology and Environmental Health*, Vol.7, pp.669-672
- Stewart, D. & Larson, E. (2002). *Aflatoxicosis in wildlife*. Information Sheet 1582 Mississippi State Univ. Extension Service., Cooperating with U.S. Dept. of Agriculture.
- Stewart, R.G.; Skeeles, J.K. Wyatt, R.D. Brown, J. Page, R.K. Russell, I.D. & Lukert, P.D. (1985). The effect of aflatoxin on complement activity in broiler chickens. *Poult. Sci*, Vol.64, pp.616-619
- Stoloff, L. & Trucksess, M.W. (1979). Distribution of aflatoxins B1 and M1 in contaminated calf and pig livers. *Journal of the Association of Official Analytical Chemists*, Vol.62, pp.1361-1362
- Stoloff, L. (1980). Aflatoxin M1 in perspective. *J. Food Prot*, Vol.43, pp.226
- Thaxton, J.P.; Tung, H.T. & Hamilton, P.B. (1974). Immunosuppression in chickens by aflatoxin. *Poult. Sci*, Vol.53, pp.721
- Tung, H.T.; Cook, F.W. Wyatt, R.D. & Hamilton, P.B. (1975a). The anemia caused by aflatoxin. *Poult. Sci*, Vol.54, pp.1962-1969
- Tung, H.T.; Wyatt, R.D. Thaxton, P. & Hamilton, P.B. (1973). Impairment of kidney function during aflatoxicosis. *Poult. Sci*, Vol.52, pp.873
- Tung, H.T.; Wyatt, R.D. Thaxon, P. and Hamilton, P.B. (1975b). Concentrations of serum proteins during aflatoxicosis. *Toxicol. Appl. Pharmacol*, Vol.34, pp.320-326
- Tyden, E.; Olsén, L. Tallkvist, J. Tjälve, H. & Larsson, P. (2008). Cytochrome P450 3A, NADPH cytochrome P450 reductase and cytochrome b in the upper airways in horse. *Research in Veterinary Science*, Vol.85, pp.80-85
- Van der Linde, L.A.; Van der Frens, A.M. & Van Esch, G.J. (1965). *Experiments with cows fed groundnut meal containing aflatoxin*. pp. 247. In: G.N. Wogan, ed. *Mycotoxins in foodstuffs*. MIT Press, Cambridge, mass.
- Van Der Zijden, A. S. M.; Koelensmid, W. A. A. Boldingh, J. Barrett, C. B. Ord, W. O. W. O. & Philip, J. (1962). Isolation in crystalline form of a toxin responsible for turkey X disease. *Nature*, Vol.195, pp.1060-1062
- Van dorp, D. A.; Van Der Zijden, A. S. M. Beerthuis, R. K. Sparreboom, S. Ord, K. De Jong, & Keuning, R. (1963). Dihydroaflatoxin B, a metabolite of *Aspergillus flavus* Remarks on the structure of aflatoxin B. *Rec. Trav. Chim*, Vol.82, pp.587-592
- Van dorp, D. A.; Van der zijden, A. S. M.; Beerthuis, R. K.; Sparreboom, S.; Ord, W. O.; De jong, K. & Keuning, R. (1963) Dihydroaflatoxin B, a metabolite of *Aspergillus flavus*. Remarks on the structure of aflatoxin B. *Rec. Trav. Chim*. Vol. 82, pp.587-592
- Veltmann, J. R. (1984). Reducing effects of mycotoxins through nutrition. *Poult. Digest*, pp. 190-194.
- Vesonder, R.; Haliburton, J. Stubblefield, R. Gilmore, W. & Peterson, S. (1991). *Aspergillus flavus* and aflatoxin B1, B2 and M1 in corn associated with equine death. *Archives of Environmental Contamination and Toxicology*, Vol.20, pp.151-153

- Voight, M. N.; Wyatt, R.D.; Ayers, J.C. and Koehler, P. (1980). Abnormal concentrations of B vitamin and amino acids in plasma, bile and liver of chicks with aflatoxicosis. *Appl. Environ. Microbiol*, Vol. 40, pp. 870-875
- Wannop, C.C. (1961). The histopathology of turkey "x" disease in great Britain. *Avian Dis*, Vol.5, pp. 371-381
- Weidenborner, M. (2001). *Encyclopedia of food mycotoxins*. Springer Publisher Berlin, New York, London.
- WHO, World Health Organization (1979). Environmental Health Criteria, Safety evaluation of certain food additives. pp. 1-127
- Wilson, H.R.; Douglas, C.R. Harms, R.H. & Edds, G.T. (1975). Reduction of aflatoxin effects on quail. *Poult. Sci*, Vol.54, pp.923-925
- Wogan, N. (1966). Chemical nature and biological effects of the Aflatoxins. *Bacteriological Review*, Vol.30, No.2, pp.460-470
- Wyatt, R.D. & Hamilton, P.B. (1975). Interaction between aflatoxicosis and a natural infection of chickens with *Salmonella*. *Appl. Microbiol*, Vol.30, pp.870-872
- Wyatt, R.D. (1991). *Poultry*, pp.553-578, In: Smith, J.E. and Henderson, R.S. (1991).
- Wylie, T.D. & Morehouse, L.G. (1978). *Mycotoxic fungi, mycotoxins and mycotoxicosis*. Vol.2, pp.414-427. Marcel Dekker, INC, USA

IntechOpen



Aflatoxins - Biochemistry and Molecular Biology

Edited by Dr. Ramon G. Guevara-Gonzalez

ISBN 978-953-307-395-8

Hard cover, 468 pages

Publisher InTech

Published online 03, October, 2011

Published in print edition October, 2011

Aflatoxins – Biochemistry and Molecular Biology is a book that has been thought to present the most significant advances in these disciplines focused on the knowledge of such toxins. All authors, who supported the excellent work showed in every chapter of this book, are placed at the frontier of knowledge on this subject, thus, this book will be obligated reference to issue upon its publication. Finally, this book has been published in an attempt to present a written forum for researchers and teachers interested in the subject, having a current picture in this field of research about these interesting and intriguing toxins.

How to reference

In order to correctly reference this scholarly work, feel free to copy and paste the following:

D. Dhanasekaran, S. Shanmugapriya, N. Thajuddin and A. Panneerselvam (2011). Aflatoxins and Aflatoxicosis in Human and Animals, Aflatoxins - Biochemistry and Molecular Biology, Dr. Ramon G. Guevara-Gonzalez (Ed.), ISBN: 978-953-307-395-8, InTech, Available from: <http://www.intechopen.com/books/aflatoxins-biochemistry-and-molecular-biology/aflatoxins-and-aflatoxicosis-in-human-and-animals>

INTECH
open science | open minds

InTech Europe

University Campus STeP Ri
Slavka Krautzeka 83/A
51000 Rijeka, Croatia
Phone: +385 (51) 770 447
Fax: +385 (51) 686 166
www.intechopen.com

InTech China

Unit 405, Office Block, Hotel Equatorial Shanghai
No.65, Yan An Road (West), Shanghai, 200040, China
中国上海市延安西路65号上海国际贵都大饭店办公楼405单元
Phone: +86-21-62489820
Fax: +86-21-62489821

© 2011 The Author(s). Licensee IntechOpen. This is an open access article distributed under the terms of the [Creative Commons Attribution 3.0 License](https://creativecommons.org/licenses/by/3.0/), which permits unrestricted use, distribution, and reproduction in any medium, provided the original work is properly cited.

IntechOpen

IntechOpen