

We are IntechOpen, the world's leading publisher of Open Access books Built by scientists, for scientists

6,900

Open access books available

185,000

International authors and editors

200M

Downloads

Our authors are among the

154

Countries delivered to

TOP 1%

most cited scientists

12.2%

Contributors from top 500 universities



WEB OF SCIENCE™

Selection of our books indexed in the Book Citation Index
in Web of Science™ Core Collection (BKCI)

Interested in publishing with us?
Contact book.department@intechopen.com

Numbers displayed above are based on latest data collected.
For more information visit www.intechopen.com



Recurrent Malignant Primary Brain Tumor: the Pathophysiology and Management

Victor Tse¹ and Harish Babu²

¹*Department of Neurosurgery Kaiser Permanente Medical Center,
Redwood City, CA*

²*Department of Neurosurgery Stanford University,
Palo Alto, CA,
USA*

1. Introduction

Malignant primary brain tumors exhibit high proliferation index and have the potential for local or distant dissemination. GBM is an example of this group of tumor. GBM is a World Health Organization (WHO) grade IV tumor. It represents 65% of all gliomas and 15-20% of all primary intracranial tumors (Louis et al., 2007). It is the most malignant astrocytic tumor, with histopathological features of cellular polymorphism, high mitotic activity, microvascular proliferation, and necrosis (Louis et al., 2007). Despite advances in imaging techniques and multimodal treatment options, the overall prognosis of patients with GBM remains poor. In a large retrospective study, 2.2% of the cohort resulted in longer than 2-year survival (Scott et al., 1998). The median survival is between 12-18 months with maximal treatment. With medical advancements in the past five years, there is a slight improvement in the median survival of these patients; It is estimated that about 24% of patients who underwent gross total resection followed by adjuvant chemotherapy and radiation therapy will survive 24 months, while those without any intervention succumb rapidly from time of diagnosis (Davis et al., 1998; McLendon and Halperin, 2003). Very few cases of curative outcome or long term survival have been reported (Salvati et al., 1998; Yoshida et al., 2000). Overall, the 5-year survival rate is less than 10% with a final mortality rate of near 100% (Deen et al., 1993; Kleihues and Sobin, 2000).

GBM carries an unfavorable prognosis mainly due to its high propensity for tumor recurrence. It has been suggested that GBM recurrence is inevitable after a median survival time of 32-36 weeks (Ammirati et al., 1987; Choucair et al., 1986). The natural history of recurrent GBM (rGBM), however, is largely undefined due to the lack of uniform definition and criteria for tumor recurrence, the variability in treatment philosophy among treating physicians, and the heterogeneous nature of the disease, including distinct mechanisms believed to contribute to known subtypes of GBM. In this chapter, we have summarized the definition of recurrent GBM and provide an overview on the pathophysiology, the diagnostic pathways, and treatment algorithm of this disease. We have also included a brief synopsis on the future direction in the management and the experimental target-therapies of this disease.

2. Definition

Tumor recurrence is defined as the growth of tumor after treatment. However, the criteria used to diagnose rGBM remain ambiguous due to the variety in which new lesions present. The infiltrative nature of GBM cells makes it difficult to eliminate microscopic disease despite macroscopic gross total resection. Studies have shown that GBM recurrence most often occurs in the form of a local continuous growth within 2-3 cm from the border of the original lesion (Gaspar et al., 1992; Halperin et al., 1988; Lee et al., 1999). Choucair et al. reported that over 90% of glioma cases showed recurrence at the original tumor location, while 5% developed multiple lesions after treatment (Choucair et al., 1986). Although less common ($\approx 10\%$), GBM may also recur with the development of new lesions that have little evidence of being contiguous with previous resection cavity, intraventricular spread, or dissemination along any anatomically definable subcortical white matter tracts (Loeffler et al., 1990). Bauman et al. has shown that uncommon relapse patterns are more prevalent in midline tumors and tumors that infiltrate both hemispheres (Bauman et al., 1998). Likewise, in an attempt to preserve neurological function and maintain patient quality of life, subtotal resections are sometimes performed when tumors infiltrate eloquent areas of the brain. In those circumstances, the residual tumor is treated with focal radiation in addition to conventional radiation therapy and chemotherapy. Tumor recurrence is, therefore defined by the appearance of residual tumor growth on imaging studies or the manifestation of new clinical symptoms. However, tumor recurrence is frequently used synonymously with tumor progression. Recurrent GBM is commonly referred as a change from previously documented stable tumor or an absence of tumor; it is an escape from prior tumor control. Certain authors define tumor progression from a residual tumor as a 25% increase in cross-sectional area of the tumor in the slice with the greatest amount of tumor or as a 25% increase in contrast enhancing volume (Suh and Olson, 1998), while recurrence has also been defined by a greater than 50% growth between two successive imaging studies (Barker et al., 1998). Setting aside the difference in the definition of rGBM, the “local” recurrence remains the single most striking common factor among all the patients whom have received a variety of chemotherapeutic agents, with different radiation dose and field volume, in addition to the extent of resection of the initial tumor. This suggests that the recurrence of GBM is intrinsic and independent to the choice of therapy.

3. The pathophysiology of tumor recurrence

Neural stem cell surface antigen CD133 has been used to prospectively isolate and characterize a rare population of cells within the tumor mass of GBM. This population of cells has a striking similarity to normal neural stem cells in its biology (Singh et al., 2004). Expansion of these cancer stem cells (CSC) replenishes the cells that constitute the expanding cells within the tumor. As these growing cells mature, they undergo terminal differentiation. It has been shown that there are at least two populations of cells in GBM specimens. They are the CD133⁺/telomerase^{High} which are presumed to be CSC and CD133⁻/telomerase^{Low} progenitor cells. There is general consensus that CD133⁺/telomerase^{High} CSC gives rise to CD133⁻/telomerase^{Low} progenitor cells. It is the proliferation of these progenitor cells that populate and makes up the tumor mass (Beier et al., 2011). Moreover, it has been shown that differentiated tumor cells are more susceptible to chemotherapy and radiation treatment, and are eliminated from the tumor mass. Additionally, terminally

differentiated tumor cells will eventually die off by initiating cell death cascades and there is accumulation of CD133⁺ glioma cells following high-dose irradiation by Gamma Knife surgery (GKS) plus external beam radiation (Tamura et al., 2010). Similarly, there is an accumulation of CD133⁺ glioma cells, in residual tumors particularly within the necrotic areas after GKS plus EBRT treatment, whereas CD133⁺ cells are infrequent in tumors prior to therapy. It is postulated that the longevity of cancer stem cells and their resilience to therapies, give them the ability to serve as the reservoir for regeneration of the whole tumor, which provides a plausible explanation for the recurrence of GBM (Liu et al., 2009). Additionally, CD133⁺ cancer stem cells have a higher expression of BCRP1 and MGMT. The presence of anti-apoptosis protein and inhibitors of apoptosis protein families explain their ability to withstand chemotherapy (Liu et al., 2006).

An emerging hypothesis states that CSCs drive tumorigenesis by directly inducing an inflammatory phenotype within the tumor and facilitate immuno-editing. This occurs by recruiting immunocytes and promoting stromal remodeling as seen in aberrant stem cell-vascular niche that contributes to myeloproliferative diseases (Walkley et al., 2007). In response to tumor-derived cytokines, these macrophages acquire the M2 phenotype (Stout et al., 2005). Macrophages are a potent source of the mediators that perpetuate the inflammatory process, and they release reactive oxygen and nitrogen species. ROS have also been shown to modify the activity of myeloid-derived suppressor cells (MDSCs). These cells inhibit anti-tumor immunity thus promoting tumors. In combination with nitric oxide, MDSC-derived ROS contribute to the generation of peroxynitrite (Nagaraj and Gabrilovich, 2007). The latter causes the nitration of various proteins on Tyrosine, including the T-cell receptor CD8. This modification alters antigen recognition and thereby induces T-cell tolerance (Movahedi et al., 2008). Moreover, MDSCs are directly involved in tumor angiogenesis, they stimulate angiogenesis and ECM breakdown through the production of angiogenic growth factors and MMPs. Secretion of MMPs and other proteinases by macrophages enhance cancer-cell motility, dispersion and invasion. Collectively, CSCs promote expansion of tumor mass, invasion, and revival of senescence cells.

4. The clinical profile of patients with recurrent glioblastomas

The patients with rGBM tend to be male with a reasonable Karnofsky Performance Score (KPS) and in age group of 50 to 60. This skewed epidemiological profile can easily be the reflection of the variability of treatment algorithms and patients selection employed at different institutions. In a multi-center trial of 222 patients with rGBM for evaluation of intra-operative placement of biodegradable wafer, the patient cohort was predominantly male (64.5%) in the fifth decade of life (48 years old). (Brem et al., 1995). Among a cohort of 301 GBM patients, Barker et al. identified 223 patients with tumor recurrence (Barker et al., 1998). Without selection bias, 64% of patients had a KPS >70 at time of recurrence. These predominantly male patients (63%) had a mean age of 54 years. The median interval from initial diagnosis until clinical or radiographic evidence of tumor recurrence was 4.9 months. In majority of the patients, GBM recurrence is detected during imaging surveillance or by the development of new or recurring symptoms and signs. The single most commonly reported symptom is easy fatigue. In a questionnaire-based study, patients with rGBM or anaplastic astrocytoma with a KPS >70 self-reported the following symptoms: fatigue, uncertainty about the future, motor difficulties, drowsiness, communication difficulties, and

headaches (Osoba et al., 2000a). While most symptoms were likely due to tumor recurrence, the authors stated that confounding factors such as radiation necrosis and steroid treatments may have contributed to generalized fatigue, whereas headache and uncertainty of the future may have been nonspecific for brain cancer. Difficulties with motor-sensory function and vision may be directly related to mass effect or edema.

The most commonly encountered dilemma in diagnosing rGBM is the uncertainty in differentiating real tumor progression from that of pseudo-progression/radiation necrosis at and around the previously treated site. Pseudo-progression is defined as progressive contrast enhancement in imaging study within the first three months (in 58% of the cases) of finishing treatment. Patients with pseudo-progression can be symptomatic but are highly responsive to steroid therapy. They account for 28-51% of the cases, and 9-14% of these patients will eventually show stable disease or resolution. The true mechanism of pseudoprogession is unclear. It is thought to be an exacerbated response to effective therapy (Chamberlain, 2008; Chamberlain et al., 2007; de Wit et al., 2004). Conversely, radiation is toxic to both rapid dividing tumor and the surrounding endothelium and oligodendroglial cells. This will result in demyelinating and coagulopathic necrotizing reaction 4-6 months after treatment. Importantly, radiation necrosis can mimic rGBM with its contrast enhancement, progression, and edema.

Radiation necrosis versus progression of gliomas can be positively differentiated in biopsy specimens. Should a biopsy be non-feasible, imaging becomes the next best option for evaluation. Positron Emission Tomography (PET) is not used for initial diagnosis of GBM due to relatively inferior image resolution compared to MRI. Rather [^{18}F] fluorodeoxyglucose (FDG)-PET is used to demonstrate increased regional glucose metabolism, which has been shown to correlate with tumor cellularity and patient survival (Ishikawa et al., 1993). In a study evaluating surgical outcomes of rGBM, Barker et al. included four patients whose PET suggested proliferation despite an MRI indication of a <50% increase in size of residual tumor (Barker et al., 1998). It is particularly useful in the early detection of rGBM in cases with unclear MRI information. While radiation necrosis mimics tumor recurrence on MRI, it is readily detectable with PET due to its low metabolic characteristics. Therefore, PET imaging plays an important role in the management of irradiated patients who develop new lesions or symptoms (Ishikawa et al., 1993). PET imaging has a specificity of >90% in distinguishing radiation necrosis from rGBM, however, it lacks the sensitivity to make it reliable (Thompson et al., 1999). The use of amino acid tracers such as [^{11}C]methionine and [^{18}F] tyrosine is shown to improve the sensitivity especially, when MRI-PET is used (Thiel et al., 2000).

The use of serial proton magnetic resonance spectroscopy (MRS) is becoming a standard protocol in the imaging rGBMs. This imaging technique, which can append current conventional MR imaging protocols, allows serial monitoring of tumor progression. With the ability to characterize abnormal processes based on their metabolic signature, It has shown that MRS can be used to discriminate between localized radiation necrosis and recurrent tumor possessing elevated choline levels after brachytherapy (Wald et al., 1997) (See Table 1). In a recent study of 29 patients, Weybright et al. found that both tumor recurrence and radiation necrosis demonstrated increased Cho:Cr ratio, Cho/NAA ratio, and decreased NAA/Cr when compare to normal brain (Weybright et al., 1998). However, the changes appear significantly greater when comparing tumor recurrence and radiation necrosis (Cho/Cr: 2.52 vs 1.57; Cho/NAA: 3.48 vs 1.31; NAA/Cr: 0.79 vs 1.22). Similarly, Rock et. al. were able to correctly predict the histopathology of the subsequently resected

specimen in the case of pure radiation necrosis or pure tumor recurrence (Rock et al., 2002). However, it was noted that in specimens with mixed necrosis and neoplasm, the spectral patterns were less definitive. Histologically, radiation injury is characterized by damage to the vascular endothelium that may result in ischemia and necrosis. In those circumstances one will expect an elevated lactate reflecting severe tissue ischemia and a severely depressed levels of NAA, choline, and creatine. In addition, radiation necrosis shows a broad peak between 0 and 2 ppm corresponding to cellular breakdown products and probably consisting of free fatty acids, and amino acids; whereas, in tumor recurrence one will find an elevated choline/NAA, elevated choline/creatine, and the presence of lactate. Unfortunately, within the same mass, there may be areas of radiation necrosis in combination with areas of viable tumor, reducing the specificity of MR spectroscopy. Thus, while MRS can be a practical noninvasive screening technique, certain limitations exist at this time.

	MRI (w/ gadolinium)	MRS	MR Perfusion	PET
Tumor	Hyperintense	↑↑ Cho / NAA ↑↑ Ch / Cr ↓↓ NAA / Cr	↑ rCBV (>2.6) ↑ Enhancement rate (dI/ dt)	↑ Metabolic activity (↑ glucose uptake)
Radiation Necrosis	Hypointense	↑ Cho / NAA ↑ Ch / Cr ↓ NAA / Cr	↓ rCBV (<0.6) ↓ Enhancement rate (dI/ dt)	↓ Metabolic activity (↓ glucose uptake)

Table 1. The Characteristic of Tumor and Radiation Necrosis in MRI and PET imaging studies.

Magnetic Resonance Perfusion (MRP) has recently been used to assess tissue vascular physiology and to distinguish the recurrence of tumors from radiation necrosis, especially with current interest in antiangiogenic therapy for the treatment of GBM. Contrast-enhancing T2-weighted echo-planar imaging has been evaluated for use in determining treatment response of recurrent malignant gliomas, specifically to thalidomide and carboplatin and to identify radiation necrosis (Cha et al., 2000). In general, radiation necrosis typically shows decreased relative cerebral blood volume (rCBV), whereas tumor recurrence results in high rCBV (Aronen and Perkio, 2002). For example, using gradient-echo dynamic susceptibility perfusion MR imaging, Sugahara et al found that lesions with rCBV greater than 2.6 was indicative of tumor recurrence, while rCBV of less than 0.6 was consistent with radiation necrosis (Sugahara et al., 2000). However, there was significant overlap between the groups, requiring other modalities such as PET or single photon emission computed tomography (SPECT) to allow differentiation. Using more delayed, T1-weighted MR permeability methods, Hazle et al. reliably distinguished between tumor recurrence,

radiation necrosis, or a combination of both factors, using an empiric model to study the rate of contrast enhancement (Hazle et al., 1997). In this study of 95 patients, the authors found that radiation necrosis and glioma tissue enhance at different rates, with recurrent tumors having the greatest mean maximal enhancement rates, mixed radiation necrosis and tumor having intermediate rate, and pure tumor necrosis having slowest rate.

5. Treatment options

With treatment options for rGBM relatively limited, physicians, patients and the patients' families have to be realistic with their therapeutic goals. The primary goal is palliative rather than curative. The ultimate aim is to preserve or restore neurological function to allow and prolong patients' comfort, independency, dignity and improved quality of life. The Canadian GBM recommendation committee's practical guideline-2007 addresses the issue of recurrent GBM and provides a relatively clear directive for practicing physicians. It states "Selected patients with recurrent GBM may be candidates for repeat resection when the situation appears favorable based on an assessment of individual patient factors such as medical history, functional status, and location of the tumor. Entry into a clinical trial is recommended for patients with recurrent disease" (Mason et al., 2007). It essentially stating that aggressive treatment should only be entertained if there is (1) reasonable chance to prolong meaningful survival and (2) there is "follow-up" experimental or salvaging treatment. Other than that, no aggressive treatment such as surgery or radiosurgery should be considered.

Surgical intervention is essential in the initial treatment of GBM. It is well documented that the extent of surgery, ranging from biopsy to subtotal resection to gross total resection can effect overall patient survival (Black, 1991a, b; Chamberlain and Kormanik, 1998; Mahaley et al., 1989). Gross total resection can double median survival as compared to just having a biopsy, and in some study gross total resection has a significant survival advantage as compared to subtotal or partial resection (80, 48, and 44 weeks respectively) (Nitta and Sato, 1995). When faced with evidence of rGBM, surgical intervention requires clear identification of short-term goals and a diligent consideration of overall prognosis including potential treatment side effects. In patients without medical contraindications, surgery can confirm tumor recurrence, reduce intracranial pressure, improve neurological status, and possibly improve efficacy of adjunctive therapy.

In patients with low KPS score and/or other co-morbidity, stereotactic biopsy is particularly relevant in making management decisions and potentially can expand treatment options especially when imaging studies fail to differentiate between radiation necrosis and tumor recurrence. Stereotactic approach allows for the sampling of small, inaccessible, or even multiple lesions with minimal morbidity and mortality (estimated to be 2-5% and <1% respectively) (Suh and Olson, 1998). Stereotactic aspiration of tumor-associated cyst may offer short-term relief to patient symptoms secondary to mass effect. While uncommonly used, chemotherapy or radioactive agents for interstitial brachytherapy may also be introduced. Although stereotactic biopsy is frequently performed with relatively low risk, clinicians must be aware of potential complications associated with small sampling. Multiple-pass sampling may improve overall sensitivity but must be weighed against the increased risk of hemorrhage.

The efficacy and utility of re-resection alone in rGBM remains controversial due to a lack of randomized clinical trials evaluating this intervention independently. The majority of

studies are confounded by the inherent selection bias to perform surgery on patients with high functional status, favorable anatomical locations, and lack of medical contraindications. The potential variability in the extent of surgical resection combined with the absence of uniform treatments for the initial disease render randomized control studies impractical. Despite these limitations, several studies in the literature provide anecdotal evidence and justification for re-resection in a select subset of patients with rGBM.

Prior redo-craniotomy studies, have showed the median survival time after surgical resection to be 14-50 weeks (Ammirati et al., 1987; Barker et al., 1998; Brem et al., 1995; Nieder et al., 2000; Sipos et al., 1997; Subach et al., 1999). The median survival from the time of initial GBM diagnosis among these patients was 13-22 months (Nieder et al., 2000). Rostomily et al. reported a prolonged progression-free survival of 7 weeks in patients undergoing combined chemotherapy plus re-resection versus chemotherapy alone (21 vs. 14 weeks) (Rostomily et al., 1994). However, the overall survival among this cohort of 51 patients was equivocal. Barker et al. performed a retrospective review of 222 patients with rGBM. In this study, the 46 patients who underwent secondary surgery and adjunctive therapy demonstrated a median survival time of 36 weeks post-resection (Barker et al., 1998). In comparison, patients who received similar chemotherapy and/or radiation had a median survival time of 23 wks. Interestingly, 28% of patients in the re-resection group had an improved KPS, while 49% had similar functional status. The authors noted that while the results were likely secondary to selection bias, subset of patients with rGBM might potentially benefit from surgical re-resection.

In addition to decreasing mass effect, redo-craniotomy allows for the potential administration of in situ delivery of chemotherapy or brachytherapy. In a randomized study evaluating the efficacy of Carmustine (BCNU) implantation during re-resection versus placebo, Brem et al. reported a 50% improvement in survival at 6 months following treatment (56% vs. 36%) (Brem et al., 1995). In this study, commonly discussed side effects such as serious intracranial infections (2.2%), post operative seizures, and steroid requirements for edema were reported to be within accepted ranges for redo surgery alone. The consensus belief that remains that the morbidity is higher in re-operation and wound dehiscence is relative common (5-18%).

Overall, surgical resection in rGBM may provide a modest benefit in survival (extends median survival by 36 weeks) and/or improvement in quality of life (10 weeks of high quality survival when the pre-operative KPS is > 70) within a subset of patients. Brem et al. showed that pre-operative performance status and age were significant prognostic factors (Brem et al., 1995). Similarly, in a multivariate analysis by Ammirati et al, performance status was found to be a significant predictor of outcome, however patient age appeared to be noncontributory (Ammirati et al., 1987). The extent of initial resection has also been shown to influence patient survival (Durmaz et al., 1997). While minor discrepancies exist among different studies, the general consensus is that surgical resection should be seriously considered in those with a high KPS (>70) and whose lesions are in a favorable location. Similarly, the time from the initial resection to clinical recurrence is also a useful prognosticator for re-operation.

6. Chemotherapy

Chemotherapy remains the main component in the salvage treatment of recurrent malignant gliomas (Chamberlain and Kormanik, 1998; Combs et al., 2005). Chemotherapeutic agents

such as temozolomide (TMZ), carboplatin, procarbazine (PCB), Bevacizumab, irinotecan, and imatinib mesylate are currently been used in a variety of schema to treat rGBMs (Osoba et al., 2000b). These drugs have been administered as a single-agent, multi-agent, interstitial, intrathecal and combinatorial therapies, and are hypothesized to decrease the risk of death by approximately 15% (Stewart, 2002). In this study the 2-year survival for individuals with GBM increased from 9% to 13% when chemotherapy was used.

The treatment of rGBM tumors with TMZ is promising and with a favorable toxicity profile. One has to differentiate between treatment failure and escape. Most of the patients with rGBM are relapsed from remission. In a study by Brandes et al., patients who were treated for recurrent or progressive GBM with a TMZ chemotherapy regimen showed an overall response rate of 19% and mean time to progression of 11.7 wks (Brandes et al., 2002). Similarly, it was found that treatment of rGBM with a standard TMZ regimen (150 to 200 mg/m² x 5 days in 28-day cycles) produced a progression free survival of 6 months (PFS-6) of 21% vs. another chemo-agent PCB which produced an 8% PFS-6 (Yung et al., 2000). However, more recent studies have shown that a more rigorous regimen (150 mg/m² daily on a week on/week off cycle) may yield a PFS-6 as high as 48% with an overall PFS-12 of 81% (Wick et al., 2004). A similar study has shown that PFS-6 as high as 43.8% with an overall survival (OAS) of 8.4 months. But when TMZ is used as a five days a week cycle, the PFS-6 is noted to be 39% and the OAS is 7.8 weeks. A Various combinatorial strategies have been examined including TMZ plus marimastat, a matrix metalloproteinase inhibitor, or 13-cis-retinoic acid, resulting in a PFS-6 of 39% and 32%, respectively (Jaeckle et al., 2003).

7. Antiangiogenic treatment

Increasingly, therapy that is targeting tumor angiogenesis has proven to be effective in tumor control and stabilization. Bevacizumab targets tumor angiogenesis by neutralizing VEGF-A. In May 2009, the US food and Drug Administration (FDA) has granted accelerated approval for Bevacizumab for use in patients with rGBM. A noticeable response (26%) with a median duration of response is 4.2 months is observed in the AV3708g trial, and a 20% response with a median duration of 3.9 months is reported in the NCI 06-C-0064E study, in which Bevacizumab is used on its own. However, it has been shown that antiangiogenic treatment in the form of monotherapy produces limited clinical effects; and its delayed onset allows tumor progression and reduces its use for end-stage disease (O'Reilly, 2006). However, the use of antiangiogenics in a combinatorial fashion may provide better results (Baumann et al., 2004). Often coupled with a chemotherapy agent, antiangiogenic therapies have been shown to be effective in primary GBM tumors producing a survival time of 16 months (Tuettenberg et al., 2005). Similarly, in determining which chemotherapeutic to use, it has been shown that PTK-787 (a VEGF receptor inhibitor) combined with TMZ produced a median time to progression of 15.1 wks vs. PTK-787 combined with CCNU which resulted in 10.4 wks (Zhang and Chakravarti, 2006). One of the most promising combinations is the use of Bevacizumab with irinotecan (CPT-11). With this regimen the PFS-6 and OSA is 50% and 8.7 months while with Bevacizumab on its own, the PFS and OAS was 42% and 9.2 months respectively (Jakobsen et al., 2011).

In our institute, the choice of salvaging chemotherapy for patients with rGBM is mainly based on their past therapeutic history and the toxicity profile. In general, we like to use

Bevacizumab, or Bevacizumab/CPT-11 as the first line therapy. It is especially preferred when Stereotactic radiosurgery is planned.

8. Stereotactic radiation and brachytherapy

Stereotactic radiosurgery (SRS) and hypofractionated radiotherapy are non-invasive methods for the delivery of localized irradiation, and have been shown to be effective in treating rGBM (Combs et al., 2005; Romanelli et al., 2009). The median survival of patients undergoing single fraction SRS therapy (median dose of 15 Gy) for rGBM tumors was 10 months (Combs et al., 2005). This finding is consistent with several other studies that report similar survival times (Mahajan et al., 2005; Shrieve et al., 1995). The risks associated with SRS treatment include the possibility of radiation induced necrosis, edema, hydrocephalus, worsening of pre-existing symptoms, and radiation toxicity. Specifically, the application of SRS to larger tumors has been avoided due to an increased risk of radiation induced toxicity and mass effect (Shaw et al., 2000). However, in a recent study hypofractionated stereotactic radiosurgery in combination with Bevacizumab resulted in a OAS of 12.5 months, PFS-6 of 65% and an over all response rate of 50%, along with relatively lower radiation toxicity profile.

The use of brachytherapy has evolved over the last decade. Primarily a treatment for rGBM, brachytherapy is associated with an increase in survival time. Interstitial brachytherapy is used to target greater radiation doses to tumor cells while limiting exposure to surrounding normal brain tissue. Latest brachytherapy techniques report a median survival time (post-brachytherapy) for rGBM of 9.1 months, a competitive figure when compared to re-resection alone, chemotherapy, or re-irradiation (Chan et al., 2005). Similarly, it has also been shown that treatment of rGBM tumors with high-activity removable iodine-125 interstitial brain implants elicits a long term (3-year) survival rate of 15% (Scharfen et al., 1992).

Unfortunately, the application of brachytherapy is limited. Only 20-30% of rGBM tumors meet the morphological and focal criteria necessary for the surgical intervention associated with brachytherapy (Salcman, 1994). In some cases, post-treatment reoperation is necessary to remove the therapeutic device or to address focal radiation necrosis. Possible complications associated with brachytherapy include the development of homonymous quadrantanopsia, focal necrosis, edema, and neurological deterioration (Shrieve et al., 1995). Nevertheless the efficacy of brachytherapy treatment is similar to that of SRS. Comparing the outcome of patients treated with SRS vs. brachytherapy, there was an overall survival time of 10.2 months for SRS treated patients and 11.4 months for brachytherapy treated patients (Shrieve et al., 1995).

9. Novel therapies

Most of the recent developments in chemotherapy are focus on targeted molecular therapies against the epidermal growth factor receptor (EGFR), the mammalian target of rapamycin (mTOR), and other signal transduction pathway components. Small-molecule EGFR inhibitors such as gefitinib and erlotinib are well tolerated in patients with rGBM, but the results from multiple clinical trails are disappointing (Rich et al., 2004; van den Bent et al., 2009).

The use of Temsirolimus, an mTOR inhibitor, as a single agent shows marginal success. Combinations of several agents, such as EGFR inhibitors with inhibitors of mTOR and VEGF receptors (VEGFR), are now being evaluated. Agents targeting VEGF, VEGFR, and other proangiogenic signaling pathways are relatively promising. Cediranib, a small-molecule inhibitor of VEGFR, shows a response rate of 56% PFS-6 of 26% (Batchelor et al., 2007; Galanis et al., 2005). AZD2171, a pan-VEGF receptor tyrosine kinase inhibitor, normalizes tumor vasculature and alleviates edema in GBM patients (Batchelor et al., 2007). Sorafenib and sunitinib are FDA-approved TKi that target VEGFR, but they have limited activity in rGBM. Although antiangiogenic therapies are promising, the duration of response is limited. Other therapeutic approaches such as viral gene therapies, immunotherapies, and convection-enhanced delivery of targeted immunotoxins are undergoing evaluation, but their use in rGBM remains to be determined (Wen and Brandes, 2009).

10. Conclusion

Patients with GBM continue to have a poor prognosis. In patients who have completed first-line therapy, vigilant tumor surveillance with regularly scheduled imaging and clinical evaluations may enable early detection of tumor recurrence and allow for immediate treatments. With the frequent use of radiation therapy, potential radiation induced injury/necrosis remains the major nuance in differentiating patients who develop new or repeat symptoms due to tumor recurrence. Hopefully, novel imaging techniques can help to detect the activation of tumor progression at molecular and cellular levels before conventional radiographic changes are seen. But to date we still rely on MRS, MR Perfusion and diffusion studies, and PET imaging.

Limited evidence from randomized studies have shown that among patients determined to be favorable surgical candidates (high KPS, non-eloquent location, no medical contraindications), the addition of salvaging chemotherapy appears to provide progression free survival. TMZ is now the standard chemotherapy agent due to its administrative ease, minimal side effect profile and proven survival improvement. Its use is not restricted by previous administration. Re-operation should be considered in patients with high preoperative KPS or in those whose symptoms are secondary to mass effect from superficial non-eloquent regions. The benefits of SRS treatment and chemotherapy are similar and should be chosen based on their corresponding side effect profiles. In general, improved outcomes are witnessed with combinatorial radiotherapy and chemotherapy as compared to each treatment alone.

Current trends indicate that the treatment of rGBM will remain multimodal in nature. Further understanding of underlying tumor biology is essential in developing more effective strategies. Research in gene therapy, antiangiogenic antagonists, and immunotherapies, all hold great promises. With continual improvements in treatment and imaging technique it is the hope of clinicians, researchers, and patients that GBM may become a controllable disease with favorable prognosis. Nevertheless, there will be time when no further medical and surgical treatments are going to be effective in preserving the comfort and dignity of our patients. Then, as clinicians we have to have the insight to prepare our patients from the inevitable and address the end-of life issue, and introduce them to the expertise of our hospice service.

Agent	Phase	Target
2ME2	Phase II	inhibits HIF-1 α
Cediranib	Phase II	VEGFR and PDGFR inhibitor
Enzastaurin	Phase II	Inhibits Protein Kinase C
Pazopanib	Phase II	VEGFR and PDGFR inhibitor
PTC299	Phase II	inhibits VEGF at the post-transcriptionally
sorafenib	Phase I/II	VEGFR, PDGFR and BRAF inhibitor
Sunitinib	Phase II	VEGFR and PDGFR inhibitor
Tandutinib	Phase II	Inhibits PDGFR
Vandetanib	Phase I/II	inhibits VEGFR and EGFR
Vatalanib	Phase I/II	VEGFR and PDGFR inhibitor
Vorinostat	Phase I	Inhibits Histone Deacetylases
ABT510	Phase II	inhibits CD36 receptor
Aflibercept	Phase I/II	decoy receptor for VEGF
ATN161	Phase II	peptide inhibits integrin $\alpha 5\beta 1$
Bevacizumab	Phase II/III	monoclonal antibody binds to VEGF
Cilengitide	Phase II/III	RGD synthetic peptide inhibits integrin $\alpha v\beta 3$ and $\alpha v\beta 5$
CT322	Phase I	Fibronectin based VEGFR inhibitor
Interferon Alfa 2b	Phase II	inhibits angiogenesis
TM601	Phase I	peptide binds to Annexin A2

The list includes use of agents as isolated or in combination with other dugs. Protein or peptide based inhibitors are shaded in grey.

Table 2. Antiangiogenic agents at various stages of clinical trial for rGBM

Neurosurgical treatment interventions are labeled in green.

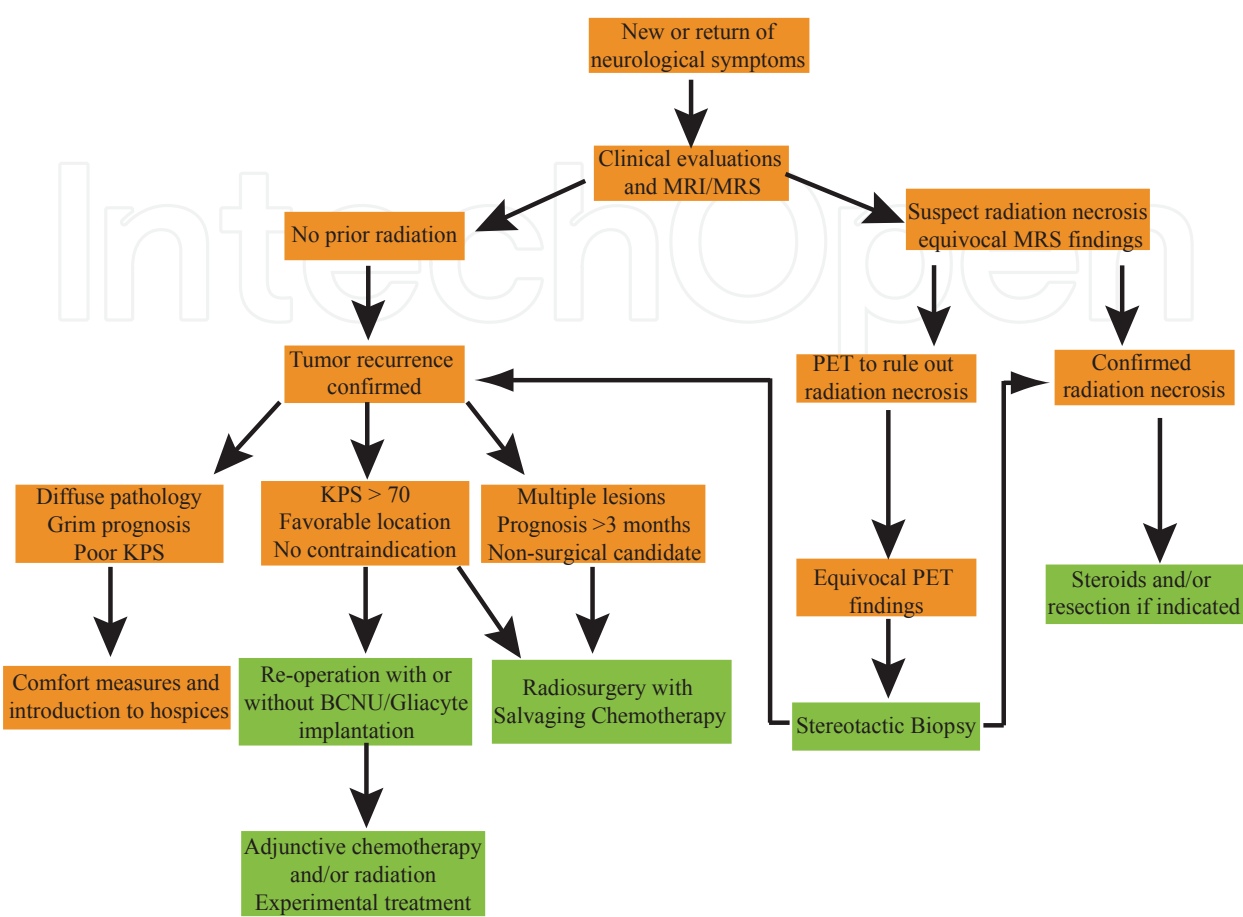


Fig. 1. Management algorithm of recurrent glioblastoma

11. References

Ammirati, M., Galicich, J.H., Arbit, E., and Liao, Y. (1987). Reoperation in the treatment of recurrent intracranial malignant gliomas. *Neurosurgery* 21, 607-614.

Aronen, H.J., and Perkio, J. (2002). Dynamic susceptibility contrast MRI of gliomas. *Neuroimaging Clin N Am* 12, 501-523.

Barker, F.G., 2nd, Chang, S.M., Gutin, P.H., Malec, M.K., McDermott, M.W., Prados, M.D., and Wilson, C.B. (1998). Survival and functional status after resection of recurrent glioblastoma multiforme. *Neurosurgery* 42, 709-720; discussion 720-703.

Batchelor, T.T., Sorensen, A.G., di Tomaso, E., Zhang, W.T., Duda, D.G., Cohen, K.S., Kozak, K.R., Cahill, D.P., Chen, P.J., Zhu, M., et al. (2007). AZD2171, a pan-VEGF receptor tyrosine kinase inhibitor, normalizes tumor vasculature and alleviates edema in glioblastoma patients. *Cancer cell* 11, 83-95.

Bauman, G.S., Fisher, B.J., Cairncross, J.G., and Macdonald, D. (1998). Bihemispheric malignant glioma: one size does not fit all. *Journal of neuro-oncology* 38, 83-89.

- Baumann, F., Bjeljac, M., Kollias, S.S., Baumert, B.G., Brandner, S., Rousson, V., Yonekawa, Y., and Bernays, R.L. (2004). Combined thalidomide and temozolomide treatment in patients with glioblastoma multiforme. *Journal of neuro-oncology* 67, 191-200.
- Beier, F., Beier, C.P., Aschenbrenner, I., Hildebrandt, G.C., Brummendorf, T.H., and Beier, D. (2011). Identification of CD133(-)/Telomerase (low) Progenitor Cells in Glioblastoma-Derived Cancer Stem Cell Lines. *Cellular and molecular neurobiology* 31, 337-343.
- Black, P.M. (1991a). Brain tumor. Part 2. *N Engl J Med* 324, 1555-1564.
- Black, P.M. (1991b). Brain tumors. Part 1. *N Engl J Med* 324, 1471-1476.
- Brandes, A.A., Ermani, M., Basso, U., Paris, M.K., Lumachi, F., Berti, F., Amista, P., Gardiman, M., Iuzzolino, P., Turazzi, S., *et al.* (2002). Temozolomide in patients with glioblastoma at second relapse after first line nitrosourea-procarbazine failure: a phase II study. *Oncology* 63, 38-41.
- Brem, H., Piantadosi, S., Burger, P.C., Walker, M., Selker, R., Vick, N.A., Black, K., Sisti, M., Brem, S., Mohr, G., *et al.* (1995). Placebo-controlled trial of safety and efficacy of intraoperative controlled delivery by biodegradable polymers of chemotherapy for recurrent gliomas. The Polymer-brain Tumor Treatment Group. *Lancet* 345, 1008-1012.
- Cha, S., Knopp, E.A., Johnson, G., Litt, A., Glass, J., Gruber, M.L., Lu, S., and Zagzag, D. (2000). Dynamic contrast-enhanced T2-weighted MR imaging of recurrent malignant gliomas treated with thalidomide and carboplatin. *AJNR American journal of neuroradiology* 21, 881-890.
- Chamberlain, M.C. (2008). Pseudoprogression in glioblastoma. *Journal of clinical oncology : official journal of the American Society of Clinical Oncology* 26, 4359; author reply 4359-4360.
- Chamberlain, M.C., Glantz, M.J., Chalmers, L., Van Horn, A., and Sloan, A.E. (2007). Early necrosis following concurrent Temodar and radiotherapy in patients with glioblastoma. *Journal of neuro-oncology* 82, 81-83.
- Chamberlain, M.C., and Kormanik, P.A. (1998). Practical guidelines for the treatment of malignant gliomas. *The Western journal of medicine* 168, 114-120.
- Chan, T.A., Weingart, J.D., Parisi, M., Hughes, M.A., Olivi, A., Borzillary, S., Alahakone, D., Detorie, N.A., Wharam, M.D., and Kleinberg, L. (2005). Treatment of recurrent glioblastoma multiforme with GliaSite brachytherapy. *International journal of radiation oncology, biology, physics* 62, 1133-1139.
- Choucair, A.K., Levin, V.A., Gutin, P.H., Davis, R.L., Silver, P., Edwards, M.S., and Wilson, C.B. (1986). Development of multiple lesions during radiation therapy and chemotherapy in patients with gliomas. *Journal of neurosurgery* 65, 654-658.
- Combs, S.E., Widmer, V., Thilmann, C., Hof, H., Debus, J., and Schulz-Ertner, D. (2005). Stereotactic radiosurgery (SRS): treatment option for recurrent glioblastoma multiforme (GBM). *Cancer* 104, 2168-2173.
- Davis, F.G., Freels, S., Grutsch, J., Barlas, S., and Brem, S. (1998). Survival rates in patients with primary malignant brain tumors stratified by patient age and tumor histological type: an analysis based on Surveillance, Epidemiology, and End Results (SEER) data, 1973-1991. *Journal of neurosurgery* 88, 1-10.

- de Wit, M.C., de Bruin, H.G., Eijkenboom, W., Sillevius Smitt, P.A., and van den Bent, M.J. (2004). Immediate post-radiotherapy changes in malignant glioma can mimic tumor progression. *Neurology* 63, 535-537.
- Deen, D.F., Chiarodo, A., Grimm, E.A., Fike, J.R., Israel, M.A., Kun, L.E., Levin, V.A., Marton, L.J., Packer, R.J., Pegg, A.E., *et al.* (1993). Brain Tumor Working Group Report on the 9th International Conference on Brain Tumor Research and Therapy. Organ System Program, National Cancer Institute. *Journal of neuro-oncology* 16, 243-272.
- Durmaz, R., Erken, S., Arslantas, A., Atasoy, M.A., Bal, C., and Tel, E. (1997). Management of glioblastoma multiforme: with special reference to recurrence. *Clinical neurology and neurosurgery* 99, 117-123.
- Galanis, E., Buckner, J.C., Maurer, M.J., Kreisberg, J.I., Ballman, K., Boni, J., Peralba, J.M., Jenkins, R.B., Dakhil, S.R., Morton, R.F., *et al.* (2005). Phase II trial of temsirolimus (CCI-779) in recurrent glioblastoma multiforme: a North Central Cancer Treatment Group Study. *Journal of clinical oncology : official journal of the American Society of Clinical Oncology* 23, 5294-5304.
- Gaspar, L.E., Fisher, B.J., Macdonald, D.R., LeBer, D.V., Halperin, E.C., Schold, S.C., Jr., and Cairncross, J.G. (1992). Supratentorial malignant glioma: patterns of recurrence and implications for external beam local treatment. *International journal of radiation oncology, biology, physics* 24, 55-57.
- Halperin, E.C., Burger, P.C., and Bullard, D.E. (1988). The fallacy of the localized supratentorial malignant glioma. *International journal of radiation oncology, biology, physics* 15, 505-509.
- Hazle, J.D., Jackson, E.F., Schomer, D.F., and Leeds, N.E. (1997). Dynamic imaging of intracranial lesions using fast spin-echo imaging: differentiation of brain tumors and treatment effects. *J Magn Reson Imaging* 7, 1084-1093.
- Ishikawa, M., Kikuchi, H., Miyatake, S., Oda, Y., Yonekura, Y., and Nishizawa, S. (1993). Glucose consumption in recurrent gliomas. *Neurosurgery* 33, 28-33.
- Jaeckle, K.A., Hess, K.R., Yung, W.K., Greenberg, H., Fine, H., Schiff, D., Pollack, I.F., Kuhn, J., Fink, K., Mehta, M., *et al.* (2003). Phase II evaluation of temozolomide and 13-cis-retinoic acid for the treatment of recurrent and progressive malignant glioma: a North American Brain Tumor Consortium study. *Journal of clinical oncology : official journal of the American Society of Clinical Oncology* 21, 2305-2311.
- Jakobsen, J.N., Hasselbalch, B., Stockhausen, M.T., Lassen, U., and Poulsen, H.S. (2011). Irinotecan and bevacizumab in recurrent glioblastoma multiforme. *Expert opinion on pharmacotherapy* 12, 825-833.
- Kleihues, P., and Sobin, L.H. (2000). World Health Organization classification of tumors. *Cancer* 88, 2887.
- Lee, S.W., Fraass, B.A., Marsh, L.H., Herbort, K., Gebarski, S.S., Martel, M.K., Radany, E.H., Lichter, A.S., and Sandler, H.M. (1999). Patterns of failure following high-dose 3-D conformal radiotherapy for high-grade astrocytomas: a quantitative dosimetric study. *International journal of radiation oncology, biology, physics* 43, 79-88.

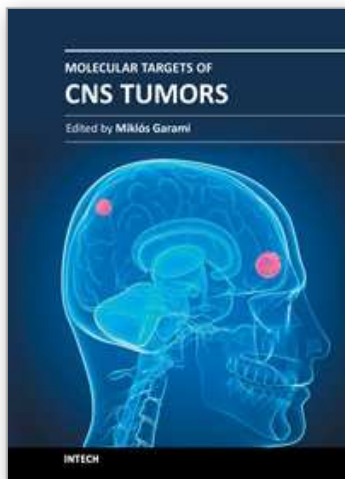
- Liu, G., Yuan, X., Zeng, Z., Tunici, P., Ng, H., Abdulkadir, I.R., Lu, L., Irvin, D., Black, K.L., and Yu, J.S. (2006). Analysis of gene expression and chemoresistance of CD133+ cancer stem cells in glioblastoma. *Molecular cancer* 5, 67.
- Liu, Q., Nguyen, D.H., Dong, Q., Shitaku, P., Chung, K., Liu, O.Y., Tso, J.L., Liu, J.Y., Konkankit, V., Cloughesy, T.F., *et al.* (2009). Molecular properties of CD133+ glioblastoma stem cells derived from treatment-refractory recurrent brain tumors. *Journal of neuro-oncology* 94, 1-19.
- Loeffler, J.S., Alexander, E., 3rd, Hochberg, F.H., Wen, P.Y., Morris, J.H., Schoene, W.C., Siddon, R.L., Morse, R.H., and Black, P.M. (1990). Clinical patterns of failure following stereotactic interstitial irradiation for malignant gliomas. *International journal of radiation oncology, biology, physics* 19, 1455-1462.
- Louis, D.N., Ohgaki, H., Wiestler, O.D., Cavenee, W.K., Burger, P.C., Jouvet, A., Scheithauer, B.W., and Kleihues, P. (2007). The 2007 WHO classification of tumours of the central nervous system. *Acta Neuropathol* 114, 97-109.
- Mahajan, A., McCutcheon, I.E., Suki, D., Chang, E.L., Hassenbusch, S.J., Weinberg, J.S., Shiu, A., Maor, M.H., and Woo, S.Y. (2005). Case-control study of stereotactic radiosurgery for recurrent glioblastoma multiforme. *Journal of neurosurgery* 103, 210-217.
- Mahaley, M.S., Jr., Hipp, S.W., Dropcho, E.J., Bertsch, L., Cush, S., Tirey, T., and Gillespie, G.Y. (1989). Intracarotid cisplatin chemotherapy for recurrent gliomas. *Journal of neurosurgery* 70, 371-378.
- Mason, W.P., Maestros, R.D., Eisenstat, D., Forsyth, P., Fulton, D., Laperriere, N., Macdonald, D., Perry, J., and Thiessen, B. (2007). Canadian recommendations for the treatment of glioblastoma multiforme. *Curr Oncol* 14, 110-117.
- McLendon, R.E., and Halperin, E.C. (2003). Is the long-term survival of patients with intracranial glioblastoma multiforme overstated? *Cancer* 98, 1745-1748.
- Movahedi, K., Williams, M., Van den Bossche, J., Van den Bergh, R., Gysemans, C., Besch, A., De Baetselier, P., and Van Ginderachter, J.A. (2008). Identification of discrete tumor-induced myeloid-derived suppressor cell subpopulations with distinct T cell-suppressive activity. *Blood* 111, 4233-4244.
- Nagaraj, S., and Gabrilovich, D.I. (2007). Myeloid-derived suppressor cells. *Advances in experimental medicine and biology* 601, 213-223.
- Nieder, C., Grosu, A.L., and Molls, M. (2000). A comparison of treatment results for recurrent malignant gliomas. *Cancer treatment reviews* 26, 397-409.
- Nitta, T., and Sato, K. (1995). Prognostic implications of the extent of surgical resection in patients with intracranial malignant gliomas. *Cancer* 75, 2727-2731.
- O'Reilly, M.S. (2006). Radiation combined with antiangiogenic and antivascular agents. *Seminars in radiation oncology* 16, 45-50.
- Osoba, D., Brada, M., Yung, W.K., and Prados, M. (2000a). Health-related quality of life in patients treated with temozolomide versus procarbazine for recurrent glioblastoma multiforme. *J Clin Oncol* 18, 1481-1491.
- Osoba, D., Brada, M., Yung, W.K., and Prados, M. (2000b). Health-related quality of life in patients treated with temozolomide versus procarbazine for recurrent glioblastoma

- multiforme. *Journal of clinical oncology : official journal of the American Society of Clinical Oncology* 18, 1481-1491.
- Rich, J.N., Reardon, D.A., Peery, T., Dowell, J.M., Quinn, J.A., Penne, K.L., Wikstrand, C.J., Van Duyn, L.B., Dancey, J.E., McLendon, R.E., *et al.* (2004). Phase II trial of gefitinib in recurrent glioblastoma. *Journal of clinical oncology : official journal of the American Society of Clinical Oncology* 22, 133-142.
- Rock, J.P., Hearshen, D., Scarpace, L., Croteau, D., Gutierrez, J., Fisher, J.L., Rosenblum, M.L., and Mikkelsen, T. (2002). Correlations between magnetic resonance spectroscopy and image-guided histopathology, with special attention to radiation necrosis. *Neurosurgery* 51, 912-919; discussion 919-920.
- Romanelli, P., Conti, A., Pontoriero, A., Ricciardi, G.K., Tomasello, F., De Renzis, C., Innocenzi, G., Esposito, V., and Cantore, G. (2009). Role of stereotactic radiosurgery and fractionated stereotactic radiotherapy for the treatment of recurrent glioblastoma multiforme. *Neurosurgical focus* 27, E8.
- Rostomily, R.C., Spence, A.M., Duong, D., McCormick, K., Bland, M., and Berger, M.S. (1994). Multimodality management of recurrent adult malignant gliomas: results of a phase II multiagent chemotherapy study and analysis of cytoreductive surgery. *Neurosurgery* 35, 378-388; discussion 388.
- Salcman, M. (1994). The value of cytoreductive surgery. *Clinical neurosurgery* 41, 464-488.
- Salvati, M., Cervoni, L., Artico, M., Caruso, R., and Gagliardi, F.M. (1998). Long-term survival in patients with supratentorial glioblastoma. *Journal of neuro-oncology* 36, 61-64.
- Scharfen, C.O., Sneed, P.K., Wara, W.M., Larson, D.A., Phillips, T.L., Prados, M.D., Weaver, K.A., Malec, M., Acord, P., Lamborn, K.R., *et al.* (1992). High activity iodine-125 interstitial implant for gliomas. *International journal of radiation oncology, biology, physics* 24, 583-591.
- Scott, J.N., Rewcastle, N.B., Brasher, P.M., Fulton, D., Hagen, N.A., MacKinnon, J.A., Sutherland, G., Cairncross, J.G., and Forsyth, P. (1998). Long-term glioblastoma multiforme survivors: a population-based study. *Can J Neurol Sci* 25, 197-201.
- Shaw, E., Scott, C., Souhami, L., Dinapoli, R., Kline, R., Loeffler, J., and Farnan, N. (2000). Single dose radiosurgical treatment of recurrent previously irradiated primary brain tumors and brain metastases: final report of RTOG protocol 90-05. *International journal of radiation oncology, biology, physics* 47, 291-298.
- Shrieve, D.C., Alexander, E., 3rd, Wen, P.Y., Fine, H.A., Kooy, H.M., Black, P.M., and Loeffler, J.S. (1995). Comparison of stereotactic radiosurgery and brachytherapy in the treatment of recurrent glioblastoma multiforme. *Neurosurgery* 36, 275-282; discussion 282-274.
- Singh, S., Hawkins, C., Clarke, I., Squire, J., Bayani, J., Hide, T., Henkelman, R., Cusimano, M., and Dirks, P. (2004). Identification of human brain tumour initiating cells. *Nature* 432, 396-401.
- Sipos, E.P., Tyler, B., Piantadosi, S., Burger, P.C., and Brem, H. (1997). Optimizing interstitial delivery of BCNU from controlled release polymers for the treatment of brain tumors. *Cancer Chemother Pharmacol* 39, 383-389.

- Stewart, L.A. (2002). Chemotherapy in adult high-grade glioma: a systematic review and meta-analysis of individual patient data from 12 randomised trials. *Lancet* 359, 1011-1018.
- Stout, R.D., Jiang, C., Matta, B., Tietzel, I., Watkins, S.K., and Suttles, J. (2005). Macrophages sequentially change their functional phenotype in response to changes in microenvironmental influences. *J Immunol* 175, 342-349.
- Subach, B.R., Witham, T.F., Kondziolka, D., Lunsford, L.D., Bozik, M., and Schiff, D. (1999). Morbidity and survival after 1,3-bis(2-chloroethyl)-1-nitrosourea wafer implantation for recurrent glioblastoma: a retrospective case-matched cohort series. *Neurosurgery* 45, 17-22; discussion 22-13.
- Sugahara, T., Korogi, Y., Tomiguchi, S., Shigematsu, Y., Ikushima, I., Kira, T., Liang, L., Ushio, Y., and Takahashi, M. (2000). Posttherapeutic intraaxial brain tumor: the value of perfusion-sensitive contrast-enhanced MR imaging for differentiating tumor recurrence from nonneoplastic contrast-enhancing tissue. *AJNR American journal of neuroradiology* 21, 901-909.
- Suh, D., and Olson, J. (1998). Management of recurrent malignant primary brain tumors. Part 1: Etiology, clinical diagnosis, and treatment options. *Contemporary Neurosurgery* 20, 1-6.
- Tamura, K., Aoyagi, M., Wakimoto, H., Ando, N., Nariai, T., Yamamoto, M., and Ohno, K. (2010). Accumulation of CD133-positive glioma cells after high-dose irradiation by Gamma Knife surgery plus external beam radiation. *Journal of neurosurgery* 113, 310-318.
- Thiel, A., Pietrzyk, U., Sturm, V., Herholz, K., Hovels, M., and Schroder, R. (2000). Enhanced accuracy in differential diagnosis of radiation necrosis by positron emission tomography-magnetic resonance imaging coregistration: technical case report. *Neurosurgery* 46, 232-234.
- Thompson, T.P., Lunsford, L.D., and Kondziolka, D. (1999). Distinguishing recurrent tumor and radiation necrosis with positron emission tomography versus stereotactic biopsy. *Stereotactic and functional neurosurgery* 73, 9-14.
- Tuettenberg, J., Grobholz, R., Korn, T., Wenz, F., Erber, R., and Vajkoczy, P. (2005). Continuous low-dose chemotherapy plus inhibition of cyclooxygenase-2 as an antiangiogenic therapy of glioblastoma multiforme. *Journal of cancer research and clinical oncology* 131, 31-40.
- van den Bent, M.J., Brandes, A.A., Rampling, R., Kouwenhoven, M.C., Kros, J.M., Carpentier, A.F., Clement, P.M., Frenay, M., Campone, M., Baurain, J.F., *et al.* (2009). Randomized phase II trial of erlotinib versus temozolomide or carmustine in recurrent glioblastoma: EORTC brain tumor group study 26034. *Journal of clinical oncology : official journal of the American Society of Clinical Oncology* 27, 1268-1274.
- Wald, L.L., Nelson, S.J., Day, M.R., Noworolski, S.E., Henry, R.G., Huhn, S.L., Chang, S., Prados, M.D., Sneed, P.K., Larson, D.A., *et al.* (1997). Serial proton magnetic resonance spectroscopy imaging of glioblastoma multiforme after brachytherapy. *Journal of neurosurgery* 87, 525-534.

- Walkley, C.R., Olsen, G.H., Dworkin, S., Fabb, S.A., Swann, J., McArthur, G.A., Westmoreland, S.V., Chambon, P., Scadden, D.T., and Purton, L.E. (2007). A microenvironment-induced myeloproliferative syndrome caused by retinoic acid receptor gamma deficiency. *Cell* 129, 1097-1110.
- Wen, P.Y., and Brandes, A.A. (2009). Treatment of recurrent high-grade gliomas. *Curr Opin Neurol* 22, 657-664.
- Weybright, P., Millis, K., Campbell, N., Cory, D.G., and Singer, S. (1998). Gradient, high-resolution, magic angle spinning ¹H nuclear magnetic resonance spectroscopy of intact cells. *Magn Reson Med* 39, 337-345.
- Wick, W., Steinbach, J.P., Kuker, W.M., Dichgans, J., Bamberg, M., and Weller, M. (2004). One week on/one week off: a novel active regimen of temozolomide for recurrent glioblastoma. *Neurology* 62, 2113-2115.
- Yoshida, T., Kawano, N., Oka, H., Fujii, K., and Nakazato, Y. (2000). Clinical cure of glioblastoma--two case reports. *Neurol Med Chir (Tokyo)* 40, 224-229.
- Yung, W.K., Albright, R.E., Olson, J., Fredericks, R., Fink, K., Prados, M.D., Brada, M., Spence, A., Hohl, R.J., Shapiro, W., *et al.* (2000). A phase II study of temozolomide vs. procarbazine in patients with glioblastoma multiforme at first relapse. *British journal of cancer* 83, 588-593.
- Zhang, M., and Chakravarti, A. (2006). Novel radiation-enhancing agents in malignant gliomas. *Seminars in radiation oncology* 16, 29-37.

IntechOpen



Molecular Targets of CNS Tumors

Edited by Dr. Miklos Garami

ISBN 978-953-307-736-9

Hard cover, 674 pages

Publisher InTech

Published online 22, September, 2011

Published in print edition September, 2011

Molecular Targets of CNS Tumors is a selected review of Central Nervous System (CNS) tumors with particular emphasis on signaling pathway of the most common CNS tumor types. To develop drugs which specifically attack the cancer cells requires an understanding of the distinct characteristics of those cells. Additional detailed information is provided on selected signal pathways in CNS tumors.

How to reference

In order to correctly reference this scholarly work, feel free to copy and paste the following:

Victor Tse and Harish Babu (2011). Recurrent Malignant Primary Brain Tumor: the Pathophysiology and Management, Molecular Targets of CNS Tumors, Dr. Miklos Garami (Ed.), ISBN: 978-953-307-736-9, InTech, Available from: <http://www.intechopen.com/books/molecular-targets-of-cns-tumors/recurrent-malignant-primary-brain-tumor-the-pathophysiology-and-management>

INTech
open science | open minds

InTech Europe

University Campus STeP Ri
Slavka Krautzeka 83/A
51000 Rijeka, Croatia
Phone: +385 (51) 770 447
Fax: +385 (51) 686 166
www.intechopen.com

InTech China

Unit 405, Office Block, Hotel Equatorial Shanghai
No.65, Yan An Road (West), Shanghai, 200040, China
中国上海市延安西路65号上海国际贵都大饭店办公楼405单元
Phone: +86-21-62489820
Fax: +86-21-62489821

© 2011 The Author(s). Licensee IntechOpen. This chapter is distributed under the terms of the [Creative Commons Attribution-NonCommercial-ShareAlike-3.0 License](https://creativecommons.org/licenses/by-nc-sa/3.0/), which permits use, distribution and reproduction for non-commercial purposes, provided the original is properly cited and derivative works building on this content are distributed under the same license.

IntechOpen

IntechOpen