

# We are IntechOpen, the world's leading publisher of Open Access books Built by scientists, for scientists

6,900

Open access books available

186,000

International authors and editors

200M

Downloads

Our authors are among the

154

Countries delivered to

TOP 1%

most cited scientists

12.2%

Contributors from top 500 universities



WEB OF SCIENCE™

Selection of our books indexed in the Book Citation Index  
in Web of Science™ Core Collection (BKCI)

Interested in publishing with us?  
Contact [book.department@intechopen.com](mailto:book.department@intechopen.com)

Numbers displayed above are based on latest data collected.  
For more information visit [www.intechopen.com](http://www.intechopen.com)



## Chronic Gastritis

Wojciech Kozłowski<sup>1</sup>, Cezary Jochymowski<sup>1</sup> and Tomasz Markiewicz<sup>1,2</sup>

<sup>1</sup>*Military Institute of Medicine / Pathology Department,*

<sup>2</sup>*Warsaw University of Technology,  
Poland*

### 1. Introduction

Proper definition, recognition and classification of chronic gastritis are fundamental for its successful therapy. Gastric inflammation based on clinical/endoscopic classification is not a pathomorphologically homogenous diagnostic group. From histopathological point of view, it seems most likely that chronic gastritis is characterized by morphological indices of chronic inflammatory changes in different parts of gastric mucosa. Chronic superficial gastritis is associated with lymphocyte and plasma cells infiltrate of the foveolar part of gastric mucosa. Chronic gastritis is associated with the inflammatory cell infiltrate predominantly consisting of lymphocyte and plasma cells in total gastric mucosa. Current classification of chronic gastritis and the worldwide accepted knowledge of the natural history of gastritis are combined in the 1994 Houston-updated Sydney System. *Helicobacter pylori* is by far the most important etiologic factor in chronic gastritis. *Helicobacter pylori* infection accompanies chronic (or chronic active) and/or superficial (or atrophic) gastritis in about 90% and the process of development of the lesions usually lasts from 20 to 40 years. Chronic gastritis, especially caused by *Helicobacter pylori*, is accompanied by disturbances in secretion of HCL, pepsinogen as well as gastrin and somatostatin. It has been reported that *Helicobacter pylori* induces increased apoptosis and hyperproliferation of gastric epithelial cells. These changes (increased apoptosis, hyperproliferation and secretion disturbances) are reduced after *Helicobacter pylori* eradication. It is worth mentioning that regenerative abilities of gastric mucosa glandular epithelium cells are the main mechanism determining their right functions concerning both integrity of the mucosa and normal function of its all epithelial cellular elements. In chronic atrophic gastritis, a significantly higher percentage of cells in mitotic phase is found as compared to both normal condition and chronic superficial gastritis. Moreover the proliferative activity of glandular epithelial cells is directly proportional to the increasing degree of gastric mucosa atrophy. An increase in proliferative activity of glandular epithelium in gastric mucosa was also observed in chronic, particularly atrophic, gastritis, independently of its etiology. There is strong evidence on possible progression of changes from chronic atrophic gastritis to intestinal metaplasia, dysplasia and finally adenocarcinoma. It is worth mentioning that not much attention has been drawn to the importance of the examination of regenerative activity of the gastric mucosa epithelium, neuroendocrine and immune cells for the study of chronic gastritis pathogenesis.

## 2. Evaluation of the morphological criteria used so far for diagnosis of superficial and atrophic chronic gastritis

Gastritis is a disorder generally acknowledged by both clinicians and pathomorphologists. At the same time it is the most frequently overused diagnosis mostly by clinicians and less commonly by pathomorphologists. On one hand, gastritis is considerably frequently diagnosed even in seemingly trivial complaints such as acid indigestion or dyspepsia. On the other hand, it should be taken into consideration that differently advanced histological indices of gastritis are diagnosed in about 40% of people with normal endoscopic picture of the stomach and no digestive tract complaints (Sipponen, 1992). It is worth noticing that according to population prognosis, about 50% of people would develop gastritis within their lives, mainly in occupational period. Therefore, the problem involves not only overuse of this type of diagnosis but also its omission in evaluating healthy people's condition. Based on the said assumption, it can be concluded that the fundament for diagnosing and classifying gastritis should be exclusively endoscopy with collection of samples and the final evaluations of the sample in histopathological test.

From pathomorphological standpoint gastritis could be defined as a syndrome caused by a heterogeneous group of pathogenic factors which lead to damage to the gastric mucous membrane manifested by acute, chronic or mixed inflammatory reaction (Strickland, 1990). Scandinavian authors claim that chronic gastritis (CHG) is an age-independent progressing disease whose onset has a form of a superficial inflammatory infiltrate (gastritis chronica superficialis), through gradual loss of gastric proper glands (gastritis chronica atrophica), to complete atrophy of these glands inclusively (atrophia mucosae ventriculi; severe atrophic gastritis). Development of morphology studies on CHG was inseparably connected with progress within endoscopic techniques as well as methodics of pathomorphological tests. The following events had significant influence on gastropathomorphology process: introduction of endoscopic examination (beginning of 50s of the previous century), immunological tests (end of 50s of the previous century), improvement of endoscopic techniques (beginnings of 70s), "rediscovery" of *Helicobacter pylori* in gastric mucous membrane and correlation of its presence with gastric lesions (beginning of 80s) (Strickland, 1990) as well as development of immunohistological techniques (beginning of 80s) and current development of molecular biology methods and molecular cytogenetics, especially the use of this type of examination techniques in pathomorphology.

The term "gastritis" (quote by Misiewicz et al., 1990) was first introduced in 1728 by Stahl who probably did not expect that in further years it would become the most commonly made diagnosis and at the same time one of the least clear ones. As it was mentioned above, classification of inflammation in the gastric mucous membrane, especially chronic one, should be based only on morphological indices of its damage while the majority of current classifications of gastritis is to a great extent based on a pathomorphological diagnosis which is a combination of the following criteria: etiologic, topographic and, according to some people, also immunological and histopathological (Correa, 1988; Dixon et al., 1996; Misiewicz et al., 1990; Owen, 1996; Price, 1991, 1999; Strickland, 1990; Tytgat, 1991). Therefore, this point of view lacks clear division into functional changes and morphological changes. In other words, the difference between the cause and the effect, morphological in this case, is blurred.

The first gastritis classification based on histopathological examination of samples collected by the so called blind biopsy and samples collected during surgical procedures was created

by Schindler in 1947. Due to inability to define anatomotopography of the collected gastric mucous membrane sample Schindler first divided inflammation into superficial and atrophic and next distinguished the group of hypertrophic inflammations. Moreover, he was the first to use the term *gastritis chronica* with full awareness in its today's meaning (quote by Misiewicz et al., 1990).

The best recognition was given to the gastritis classification created by Whitehead in 1972 (Whitehead et al., 1972). It is based only on classic pathomorphological criteria and involves separate diagnosis for region of pylorus, corpus, cardia and gastric mucous membrane welding area. Similarly to Schindler's classification, Whitehead divided gastritis into superficial and atrophic. However, Whitehead distinguished two forms for each of them: active form with presence of granulocyte infiltrates in epithelium and/or interstitium and a non-active form with inflammatory infiltration from lymphoidal and plasmatic cells located in lamina propria. Atrophy of mucous membrane proper glands was evaluated in a three-level scale (mild, moderate and severe) as well as, in justified cases, the presence of intestinal and pseudopyloric metaplasia was noted.

One year later Strickland and McKay modified CHG classifications by combining etiologic and immunologic data with pathomorphological and anatomotopographic indices and by distinguishing type A and B gastritis (Strickland & Mackay, 1973). Type A gastritis referred only to gastric corpus and was accompanied by pernicious anaemia, while in the case of type B gastritis the lesions were localized in antral regions. In the same year (Glass & Pitchumoni, 1975) Glass and Pitchumoni completed the first classification by adding AB type gastritis which included types of extensive involvement of mucous membrane of the corpus and prepyloric regions. The cases of concurrent presence of antibodies of oxyntic cell were defined as AB-plus CHG.

In 1980 (Correa, 1980) Correa introduced etiopathogenetic element into histopathological diagnosis by dividing CHG into: autoimmunization CHG with pernicious anaemia; hypersecretion CHG connected with duodenal ulceration and environmental CHG dependent mainly on the diet but also on geographic localization. In 1988 (Correa, 1988) the same author modified his previous classification by dividing CHG into: diffuse antral gastritis, diffuse corporal gastritis and multifocal atrophic gastritis. Next, in 1992 along with Yardley (Correa & Yardley, 1992) in continuation of completing and developing the previous versions of his classification of CHG he divided the inflammation into: gastritis with and without atrophy of gastric proper glands. In the group of non-atrophic gastritis he distinguished superficial CHG as initial condition and/or stationary as well as diffuse CHG connected with prepyloric region. As regards diffuse inflammation of prepyloric regions, it might be accompanied by duodenal and pyloric ulcer. Moreover, in this case *Helicobacter pylori* is the first cause and the following are not observed: gland atrophy, intestinal metaplasia or carcinogenesis. Among the types of atrophic gastritis he distinguished the following: diffuse CHG connected with the corpus, autoimmunization CHG accompanied by pernicious anaemia and multifocal CHG usually affecting mucous membrane in lower regions of gastric lesser curvature. Multifocal CHG can be accompanied by duodenal ulcer and is frequently followed by occurrence of intestinal metaplasia of mucous membrane. Moreover, cases of atrophic multifocal CHG are accompanied by increased risk of neoplasm development.

The study by Marshall from 1983 (Marshall, 1983) on *Helicobacter pylori* revolutionized the view on CHG etiology, which, among others, contributed to creation of a new CHG classification finally accepted in Sydney in 1990 (Misiewicz et al., 1990; Price, 1991).

Basically, this classification included all the previous CHG divisions, yet an etiology factor was added as a permanent element of pathomorphological diagnosis. In this classification the previous CHG morphological quantifications were exchanged with evaluation of morphological change advancement level according to a four-level scale. One of the most important practical conclusions in the Sydney classification is a necessity of routine collection of a particular number of samples (four; two from the corpus and two from the antrum, from both anterior and posterior walls) and what is equally important - fixation of those samples in properly labeled separate containers. Moreover, it was clearly stated that any other lesion confirmed by endoscopic examination requires collection of additional samples from the *muscularis mucosae* depth.

It should be noted that chronic gastritis is not characterized by a specific clinical or endoscopic picture. This also refers to particular most common etiologic factors whose action is not characterized by a defined syndrome complex. Moreover, it is worth adding that there is no correlation between endoscopic picture of gastric mucous membrane and histopathological examination, especially in the case of mild changes. The most significant issue as regards this aspect of CHG diagnostics is the fact that even in 40% of CHG cases no endoscopic changes or presence of CHG microscopic indices of various level of advancement are observed. These dependencies lead to the issue called routine collection of samples in every endoscopy as well as relevant problems, not only connected with high cost.

From histopathological standpoint, the Sydney system distinguishes three basic types of inflammation: acute, chronic and special. Acute inflammation is usually characterized by subclinical course, which is rarely used as an indication to perform stomach endoscopy. Special forms of gastritis are not frequently examined by taking biopsy as this type of disorder is extremely rare. Therefore, routine gastrologic biopsy material is most frequently connected with cases of non-specific CHG of considerably repeatable picture of pathomorphological changes due to the fact that immunological mechanisms of reaction to different pathogens in gastric mucous membrane are generally not various. Therefore, the Sydney system included all the microscopic indices of gastric mucous membrane changes that are present in CHG and were described before 1990. Some of the indices are as follows: inflammatory infiltrate (consisting of lymphoid and plasmatic cells), atrophy of gastric proper glands, active inflammatory process (measured by the number of neutrophils and eosinophils), intestinal metaplasia and intensity of *Helicobacter pylori* colonization in gastric mucous membrane evaluated in a 4-level- scale (none, mild, moderate and severe). Other CHG microscopic changes, such as mucus content in cells, degenerative changes of epithelial cells, hyperplasia of foveolar layer glands, stroma oedema, erosions, fibrosis and dilation of vascular lumen are evaluated only in terms of quality.

According to the Sydney System, the following sites of sample collection in topographic part of pathomorphological diagnosis can be determined: antrum, corpus or the whole gaster (pangastritis, antrum predominant, corpus predominant). Therefore, in the case of collecting samples from only one anatomotopographic region the diagnosis based on the Sydney system is not possible (incomplete examination). The etiologic part, which is to a possible extent defined by a clinician, includes: *Helicobacter pylori* (currently the most common cause), autoimmunization, drug-induced disorder as well as infectious etiology (bacterial, viral, parasite, fungal). In the case of no evident cause (etiology) CHG is defined as idiopathic inflammation.



The assumptions described above suggest, among others, that the Sydney system replaced classic histopathological diagnosis which involves diagnosis based on microscopic indices of changes only by means of quantitative evaluation of the advancement level of inflammatory microscopic indices. This interpretation of changes allows for quantitative consideration of morphological changes in CHG (necessary for e.g. scientific works). However, it does not allow for making an accurate histopathological diagnosis which would allow the clinician to draw prognostic and therapeutic conclusions.

This approach towards pathomorphological phenomena in the Sydney system was a probable reason for excluding generic diagnosis - gastritis chronica superficialis (CHSG) which, according to opinion of both this work's and other authors, was very significant. Superficial chronic gastritis is characterized by presence of inflammatory infiltrate built up of lymphoid and plasmatic cells localized in 1/3 of the upper part of gastric mucous membrane, namely on foveolar layer. This inflammation usually affects also the layer of stem glands. Comparing to CHSG of antral and pyloric parts, corpus of the gaster is a site of a more common CHSG development. A key diagnostic element of CHSG is evaluation of inflammatory infiltrate localization which is analyzed in terms of strictly defined histotopographic structures of gastric mucous membranes. Therefore, it is a very accurate criterion which does not require additional examination tools and/or other supporting classifications/scales. It is worth mentioning that this type of diagnosis occurred in all the CHG classifications compiled before 1900 (Correa, 1980, 1988; Correa & Yardley 1992; Whitehead, 1972). Most authors consider CHSG as the initial part of CHG. As regards the difference between the two disorders, in the case of CHG the inflammatory infiltrate of similar cellular composition affects also deeper parts of gastric mucous membrane and reaches muscularis mucosa. In the presence of granulocytes (neutrophils and/or eosinophils) in the inflammatory infiltrate composition, active inflammation - CHSG activa and CHG activa - is diagnosed.

One of the most significant advantages of the Sydney classification is that it obliges clinicians and pathomorphologist to cooperate in the process of diagnosis gastritis from the very beginning and it makes the clinicians responsible for the etiologic and anatomotopographic part of the diagnosis. Clinicians frequently have justified doubts as regards etiology of the observed gastric lesion. However, establishment of topography of the collected oligobiopoints as well as their fixation in separate containers can in no way be problematic. Following its compilation, the Sydney classification was not fully accepted, especially by American authors (Correa & Yardley, 1992). This was, among others, the reason for its revision which was finally performed in Houston in 1994 (Dixon et al., 1996). The most significant element of the revision was giving a suitable role to classic histopathological nomenclature in making CHG diagnosis, especially regarding non-atrophic CHG, particularly for *gastritis chronica superficialis* which was "forgotten" in the Sydney classification (Correa & Yardley, 1992). Visual analogue scale was added to the quantitative evaluation of histopathological changes. Also, the following rule of routine collection of samples from gastric mucous membrane, slightly different from the Sydney classification, was suggested in Houston:

- two antrum samples; 2-3cm, from pylorus from lesser and greater curvature,
- two corpus samples; 8cm, from cardia from lesser and greater curvature,
- one sample from the region of angular incisure
- five samples from angular incisure for comparable evaluation of intestinal metaplasia and/or dysplasia level.

The authors also recommend HE and PAS with Alcjan Blue as a routine staining next to *Helicobacter pylori* identification (Giemsa's method).

This vast work from Houston, apart from the revision of the Sydney system, contains a number of detailed and valuable information on a wide range of aspects connected with cooperation between endoscopist and pathomorphologist and thus, it is suggested as a fundamental educational material for both parties. The modified Sydney classification causes different reactions among pathomorphologists –full acceptance (Chen et al., 1999; Wyatt, 1995) and a certain reserve (Guarner et al., 1999), especially with respect to implementation of the classification in pediatric gastropathology (Cohen et al., 2000). However, the authors supporting the concept of Sydney classification claim that this conceptual direction of CHG classification will be maintained. They are awaiting for the nearest non-histopathological criterion, namely dependencies arising from potential effects of using vaccination against *Helicobacter pylori* (Price, 1999).

One of the latest complete divisions of gastritis was published by Appelman in 1994 (Appelman, 1994). Traditional division into acute and chronic disease was maintained. The following were distinguished from chronic gastritis: inflammation connected with *Helicobacter pylori* and atrophy gastritis, lymphocitar gastritis – also called “chemical” and focal gastritis. *Helicobacter pylori* related gastritis, the most common one, is defined variously by different authors (Axon, 1992; Borchard, 2001; Correa, 1980, 1988; Glass & Pitchumoni, 1975; Green & Graham, 1990; Sipponen, 1989, 1992; Strickland & Mackay, 1973; Whitehead et al., 1972). Commonly used synonyms are as follows: gastritis chronica diffusa antralis, gastritis chronica typus B, gastritis chronica activa antralis, gastritis chronica non specifica and gastritis typus hypersecretions. Many publications (Arkkila et al., 2006; Axon, 1992; Correa & Yardley, 1992; Green & Graham, 1990; Marshall, 1983; Sipponen, 1992; Zhang et al., 2005a, 2005b) clearly confirmed that *Helicobacter pylori* causes chronic gastritis by affecting mainly prepyloric part of the stomach. It can lead to atrophy of gastric proper glands, cancer and less frequently to lymphoma. It usually accompanies duodenal ulcer. Its morphological indices are inflammatory infiltrates of neutrophils localized on the foveolar layer stroma of gastric mucous membrane in the case of acute gastritis. Chronic gastritis is characterized by an infiltrate of lymphoid cells, plasmatic cells and acidophilic granulocytes. Moreover, it is accompanied by lymphadenoplasia foci and the infiltrate affects the whole gastric mucous membrane (Appelman, 1994; Axon, 1992; Correa, 1988; Marshall, 1983; Misiewicz et al., 1990; Price, 1991; Sipponen, 1992; Strickland, 1990; Wyatt, 1995).

As regards autoimmunization inflammation, it is frequently defined as gastritis autoimmunogenes, gastritis chronica atrophica typus A, gastritis chronica typus A and gastritis chronica diffusa corporis. It is most frequently observed in Scandinavia and in northern areas of Europe. This inflammation affects gastric corpus and can be accompanied by: pernicious anaemia, autoimmunization Hashimoto thyroiditis, diabetes, adrenal insufficiency and thyroid function disorders. Common complications are stomach cancer and carcinoid. However, it is assumed that enterohormonal disorders (hypergastrinemia) which accompany carcinoid development are initiated by achlorhydria in the course of inflammation (Appelman, 1994; Strickland, 1990).

Interestingly, focal atrophic gastritis is more frequently observed in the USA and Japan. Its most common synonyms are: gastritis chronica atrophica typus B or environmental gastritis. In terms of frequency of occurrence it affects lesser curvature, prepyloric region and gastric corpus. The most serious complication is cancer, mainly intestinal (Correa, 1980, 1988; Correa & Yardley, 1992).

Lymphocitar gastritis can be divided into the previously distinguished types of inflammation: gastritis chronica superficialis, gastritis chronica erosiva, gastritis varioliformis and morbus Menetrier. Basic morphological index of the lesions is an infiltrate which consists mainly of lymphocytes localized within superficial epithelium of gastric mucous membrane foveolar layer. This group comprises lesions of gastric mucous membrane which accompany among others celiac disease (Appelman, 1994; Price, 1991; Wyatt, 1995).

The so called chemical gastritis is by some authors also referred to as: "chemical" gastropathy, gastritis refluxiva, gastritis biliaris, gastritis postmedicamentosa. Basic morphological indices of this inflammation are: proliferation of foveolar layer, decreased mucous secretion, stroma oedema with low inflammatory reaction (Appelman, 1994; Borchard, 2001; Strickland, 1990; Wyatt, 1995). According to both the authors as well as other authors (Borchard, 2001; Dixon et al., 1996), the number of mixed CHG cases, in which some of the most significant components are microscopic indices of chemical gastritis, is increasing (or they are more frequently diagnosed).

According to pathomorphological standpoint, the authors of this work, following prior mental, substantial and emotional acknowledgement of potential addresses, assume and suggest implementation of CHG classification based almost exclusively on pathomorphological criteria acknowledged also by other authors. Histopathological diagnoses used in this classification contain data on severity and distribution of inflammatory infiltrate, its activity and condition of potential atrophy of gastric proper glands (*gastritis chronica superficialis activa et nonactiva*; *gastritis chronica activa et nonactiva*, *gastritis chronica atrophica et atrophia mucosae ventriculi*) as well as they take into consideration also histotopographical data on the examined samples (*CHG antralis, corporis, fundi, cardiae, pylori*). In every justified case, dysplasia level is evaluated as well as the presence of : glandular *hyperplasia of foveolar layer, intestinal and pseudopyloric metaplasia*. Focal gastritis is a kind of systemic disease which causes among others lesion in the gaster and is characterized by specific morphological indices of diagnosis CHG type. The suggested classification also comprises other CHG types enumerated by Appelman: lymphocitar, the so called chemical CHG, and gastritis chronica erosiva. According to the Sydney classification system, identification of *Helicobacter pylori* is obligatorily taken into consideration in histological evaluation along with the assessment of this microorganism. However, etiopathogenetic standpoint is a supplementary element found in additional comment to the basic histopathological diagnosis.

A number of factors, such as different classifications, the increasing number of reports on the Sydney classification analysis, both initial and updated version, and the opinions of cooperating clinician groups, lead to a conclusion similar to Appelman's view: the best CHG classification is the one that both provides the best possible and the clearest contact between clinician and pathologist and most of all facilitates effective diagnostic and therapeutic management.

### **3. Analysis of the proliferative activity of gastric mucosa glandular epithelium in relation to the chronic gastritis type**

Regenerative abilities of glandular epithelium cells of gastric mucosa constitute the main mechanism determining their correct functions concerning both integrity of the mucosa and normal function of all its epithelial cell elements (Goodlad & Wright, 1995). One of more



important cell elements in this process are mucous cells of the cervical part of gastric glands (Goodlad & Wright, 1995; Hellander, 1981) and also isthmus cells, as stressed by other authors (Goodlad & Wright, 1987). Mucous cells of the cervical part of gastric glands are present singly and/or in cellular clusters in the epithelium of the cervical region of gastric glands (Goodlad & Wright, 1995) and are usually invisible after routine H-E staining. These cells, besides purely secretory function, are the pool of cells that are the source for regenerating cells of the glandular epithelium, among which the presence of primary alimentary tract cells for gastric mucosal epithelium (so called stem cells) can be observed (Goodlad & Wright, 1995; Solcia et al., 1979).

One of more frequently used immunocytochemical markers for cells in proliferation phase is proliferating cell nuclear antigen (PCNA) (Goodlad & Wright, 1995). It is a protein of 36 kDa mass, co-factor for DNA delta-polymerase and it participates in DNA synthesis (S-phase of cell cycle) and DNA repair (Keleman, 1997; Waseem & Lane, 1990). PCNA usually undergoes overexpression in conditions connected with activity of growth factors (Hall et al., 1990). PCNA expression is genetically regulated, and mRNA PCNA is present in both proliferating cells and those in resting phase (Hall et al., 1990).

The control of glandular epithelium regeneration centres in the alimentary tract, including the stomach is multidirectional, starting from simple negative feedback with damaged superficial epithelial cells, finishing on the effect of intragastric environment (Goodlad & Wright, 1995). The main point of this regulation includes hormonal, neuropeptide, peptide and genetic actions with simultaneous influence of immune-nervous factors and mesenchymal components on the stroma (Goodlad & Wright, 1995). Apart from the group of factors associated with enteroglucagon, a particular role in the stimulation of regenerative processes regulation in gastric mucosa is played by gastrin (Goodlad & Wright, 1995; Walsh, 1990). It should be stressed that drugs influencing gastrin level also exert indirect influence on glandular epithelium proliferation in gastric mucosa (Havu, 1986). Prostaglandins, in their broad spectrum of activity, have the ability to stimulate proliferation of glandular epithelial cells of gastric mucosa, including also acceleration of these cells' migration (Goodlad et al., 1989). As regards the growth factors, epidermal growth factor (EGF) plays the main role in the regulation of regeneration processes in gastric mucosa (Weaver & Walker, 1988).

Most of the regenerating cells of glandular epithelium migrate along the wall of foveolar layer glands to the surface of gastric mucosa during about seven days (Lee, 1985). This migration far less frequently occurs deep into gastric glands and takes longer time, i.e. about 200 days (Hattori, 1976). As it is commonly known, cell division includes four phases, making up jointly the so called cell cycle (cell cycle phases: G1, S, G2 and M), and the duration of this cycle depends mainly on the duration of the G1 phase (Goodlad & Wright, 1995; Preston-Martin et al., 1990). A cell may go out of the cell cycle to enter G0 resting state or may pass to maturation phase. It has been disclosed, however, that in the case of alimentary tract mucosal cells, the resting state is practically not observed, perhaps with the exception of the large bowel (Goodlad & Wright, 1995).

Apoptotic regulations of these cells, and, in the first place, genetically determined regulations, play, besides regenerative abilities of the epithelium, an important role in the homeostatic process of gastric mucosa (Goodlad & Wright, 1995; Oren, 1992; Yanagihara & Tsumuraya, 1992). Growth factors and other factors, for example c-myc, bcl-2, p53, TGF-beta, TNF and other cytokines participate in the apoptotic process (Oren, 1992; Yanagihara & Tsumuraya, 1992).

Proliferative activity of the glandular epithelium of stomach corpus and fundus mucosa is normally located in the cervical part of gastric glands, while in the prepyloric part it occupies the middle 1/3 part of the mucosa where also G cells are present (Ito et al., 1986). In this part an intensive expression of chromogranin-A-positive cells can also be observed. In own studies it has been demonstrated that these regions are the place where the most intensive PCNA expression is observed. Most authors think that proliferative activity of glandular epithelial cells in gastric mucosa increases with *Helicobacter pylori* colonization (Bechi et al., 1996; Jang & Kim, 2000; Lynch & Axon, 1995; Panella et al., 1996), which is particularly visible in the corpus (Bechi et al., 1996). On the other hand, after eradication, the proliferative activity returns to normal (Lynch & Axon, 1995). According to other authors, bile participates in the increase of gastric glandular epithelial activity in the course of *H.pylori* colonization (Lynch & Axon, 1995), while the markers of this activity are observed mainly within the epithelial zone of foveolar layer glands (Bechi et al., 1996). It is worth mentioning that other authors (Ito et al., 1986) found a deepening of proliferative zone within gastric glands in the same gastric mucosal inflammatory conditions, with accompanying significant reduction of EC cell number. According to some authors, increased proliferative activity of gastric mucosal glandular epithelium, particularly that measured by PCNA expression, in the course of chronic inflammatory conditions and *H.pylori* colonization may be even the marker of risk of malignancy development (Irazusta et al., 1998; Panella et al., 1996). Other authors (Diebold et al., 1998), however, demonstrated that during *H.pylori* colonization a decrease in the number of argyrophilic cells occurs along with simultaneous reduction of their proliferative potential. This seems to be in concordance with the studies in which an inhibitory effect of VacA on the proliferation of epithelial cells of gastric mucosal glands through impairment of their migration ability was demonstrated (Ricci et al., 1996). The same authors also proved that another antigen, CagA, exerts no effect on the proliferative potential of gastric mucosal glandular epithelium. The results of these studies may be, in a certain way, compared with own studies according to which no significant influence of *H.pylori* colonization on proliferative activity of gastric mucosal glandular epithelium was demonstrated. An increase in proliferative activity of glandular epithelium in gastric mucosa was also observed in chronic gastritis, independently of its etiology (Bechi et al., 1996; Deschner et al., 1972; Irazusta et al., 1998; Panella et al., 1996). It was usually accompanied by a decrease in G cell count, including adrenomodulin-containing cells (Kitani et al., 1999), particularly frequently when the gastritis was associated with atrophic lesions. According to the studies by other authors (Bielicki et al., 1993; Guerci et al., 1992), a significantly higher percentage of cells in division phase is found in chronic atrophic gastritis as compared to both normal condition and to chronic superficial gastritis, and the proliferative activity of glandular epithelial cells is directly proportional to the increasing degree of atrophy. Other authors (Ito et al., 1986) noted that, together with intensification of inflammatory processes in gastric mucosa, the zone of increased proliferation of glandular epithelial cells involves also deeper layers of the lamina propria of gastric mucosa, and also. the number of ECn cells is reduced. It should be added that in hypergastrinaemia, the expression of neuroendocrine cells and their proliferative abilities increase but such changes were not observed during antisecretory treatment. No such hypergastrinaemia inducing effect was observed during activation of gastric mucosal inflammatory processes or in biomorphotic process. In the course of *Helicobacter pylori* colonization other authors (Jang & Kim, 2000) found intensification of both apoptosis and

proliferative activity of neuroendocrine cells, mainly G and D, correlated with gastritis activity and with the degree of *H.pylori* colonization.

Own studies are partially in concordance with the observations described above since they demonstrated that proliferative zone of mucosal epithelial cells becomes deeper with intensification of inflammatory lesions but only in the case of stomach corpus. At this point, however, it should be noted that this applies only to males who have higher proliferative activity in this zone of mucosa as compared with females. Regardless of that, in own studies a significantly higher proliferative activity was found, but only in superficial gastritis, in relation to deep gastritis, which had not been described by other authors. Apart from this, it was demonstrated that changes of proliferative activity of gastric mucosal epithelium were independent of age, location (prepyloric part – corpus), and also *Helicobacter pylori* colonization in gastric mucosa.

### 3.1 Conclusions (own studies)

1. Chronic superficial gastritis coexists with significantly higher proliferative activity of gastric mucosal glandular epithelium, particularly in relation to the prepyloric part.
2. Changes of proliferative activity of gastric mucosal glandular epithelium are independent of age, histotopography and *H.pylori* colonization.

## 4. Assessment of the current status of neuroendocrine and immune cells for the study of pathogenesis of chronic gastritis

Gastric mucosal neuroendocrine cells are usually located in the epithelial layer of the gastric glands in the corpus and prepyloric part, sometimes in their cervical zone, but they are never found in the superficial epithelium of the foveolar layer glands of gastric mucosa (Dayal, 1992; Kozłowski et al., 1993, 1995; Portela-Gomes & Grimelius, 1986). Modern classifications of gastric mucosal neuroendocrine cells tend to divide them according to anatomic-topographic location in the stomach (Bordi et al., 2000; Dayal, 1992; Tzaneva, 2001). The following neuroendocrine cells are present in the mucosa of gastric corpus and fundus: ECL (enterochromaffin-like), D (somatostatin), ECn (enterochromaffin), X/A, D1, and P cells. ECL cells occur almost exclusively in gastric fundus mucosa. However, the prepyloric part of the stomach contains G (gastrin), D, and ECn cells. D cells produce somatostatin and are present almost in the whole alimentary tract and also in the pancreas (Canese & Bussolati, 1977). In course of their long cytoplasmic processes they exert paracrine effect on other neighbouring gastric mucosal cells (Larsson et al., 1984). At least 20% of D cells have axon processes through which they are in contact with G cells in the prepyloric part and parietal cells in gastric corpus mucosa (Larsson et al., 1984), inhibiting their secretory function. Moreover, D cells in the prepyloric part have specialised tubules through which they are in contact with gastric lumen (autoregulation with intragastric environment). D cells in gastric fundus mucosa have no such contact with stomach lumen (Fenoglio-Preiser, 1999). As far as now, no publications on correlations between gastric mucosa neuroendocrine and degree of chronic gastritis can be found in scientific literature.

The applied own method of studying gastric mucosal neuroendocrine cells allowed for assessment of their count and rate of changes in the course of non-specific gastritis of various progression in a repeatable way. It is worth mentioning that on the basis of examination of one cross-section type it is possible to assess the most probable total count of a definite type of gastric mucosal neuroendocrine cells in a highly correlated way (about

95% confidence level). This type of histological quantitative examinations is very practical in routine histopathological diagnosis.

Contrary to the results reported by other authors (Coupe et al., 1990; Tzaneva & Julianov, 1999), changes concerning D cells and CgA cells located in the stomach corpus mucosa were found in own studies. The latter, however, demonstrated a significant decrease of D cell count in the oxyntic mucosa with simultaneous increase of CgA cell count in the prepyloric mucosa. It should be mentioned that the latter changes were observed only in patients with *Helicobacter pylori* colonization in gastric mucosa, which was in agreement with the results obtained by other authors (Chamouard et al., 1997; Graham et al., 1993; Kozłowski et al., 1993, 1995; Tzaneva & Julianov, 1999).

According to literature data, the most numerous neuroendocrine cells of gastric mucosa include the following cells: ECL, G, and D, since together they account for over 75% of all mucosal endocrine cells in the prepyloric part and corpus of the stomach (Dayal, 1992; Fenoglio-Preiser, 1999; Solcia et al., 1975). It can be assumed that the increasing number of CgA cells in the prepyloric mucosa means simultaneous increase of G cell count. Therefore, the results obtained in own studies may be regarded as a confirmation of the fact already known from papers by other authors (Chamouard et al., 1997; Graham et al., 1993; Kozłowski et al., 1993, 1995; Tzaneva & Julianov, 1999) and also obtained empirically (Lee et al., 1992) which point to participation of disturbances of interrelations between D and G cells in the pathomechanism of hypergastrinaemia that accompanies *Helicobacter pylori* colonization of gastric mucosa. It should be stressed that due to other causes, e.g. chronic atrophic gastritis in the corpus, the numbers of ECL as well as D cells in hypergastrinaemia increase (Borch et al., 1987; Bordi et al., 1987; Carney et al., 1983; Cattani et al., 1989; Hodges et al., 1981; Iacangelo et al., 1988), which is accompanied by characteristic vacuolar lesions observed under electron microscope in ECL cells (D'Adda et al., 1990; Rubin, 1972).

Chromogranin A, used, as mentioned above, for identification of neuroendocrine cells, is an acid protein of 49 kDa mass located in secretory granules of APUD system cells (Lloyd et al., 1984; Wiedemann & Huttner, 1989) which belongs to the family of proteins called granins/secretogranins. The most important members of this protein family include: chromogranin A, B, and secretogranin II (Lloyd et al., 1984). Chromogranin A is present in both endocrine and neuroendocrine cells (Cetin, 1992; Iacangelo et al., 1988). It is also present in most neuroendocrine tumours and, therefore, serves as a commonly used marker for their identification (Wiedemann et al., 1989). At the same time, it participates in the biosynthesis of pancreatostatin (Iacangelo et al., 1988) which inhibits insulin and hydrochloric acid secretion. It is worth mentioning that Chromogranin A also binds intracellular calcium and catecholamines, significantly regulating intracellular homeostasis along this pathway (Iacangelo et al., 1988). It is distributed in neuroendocrine cell granules in rather close association with serotonin which is simultaneously connected with both its synthesis and accumulation (Tzaneva, 2001). Chromogranin A expression in a significant per cent of neuroendocrine cells agrees with argyrophilic reaction e.g. according to Grimelius (Cetin, 1992).

From the standpoint of methodological principles of indentifying individual neuroendocrine cell types in humans, an extremely important and frequently forgotten fact is that D cells (secreting somatostatin) give no positive argyrophilic reaction according to Grimelius, and show no Chromogranin A expression in immunohistochemical reaction (Cetin, 1992; Tzaneva, 2001). However, in neuroendocrine aminergic cells the both above mentioned colour reactions gave positive results (Cetin, 1992). It is worth mentioning that



even purely mathematical calculation of G cell number among CgA cells is more precise than analogous mode of ECL cell calculation since only G, D and ECn cells are present in the prepyloric part (Bordi et al., 2000; Dayal, 1992; Tzaneva, 2001).

Decreased D cell count was found in duodenal ulcer with *Helicobacter pylori* colonization of gastric mucosa and in cases of hypergastrinaemia, yet sometimes also in conditions without hypergastrinaemia (Zverkov et al., 1996). Many authors are convinced that hypergastrinaemia, observed in cases of *H.pylori* colonization of gastric mucosa, is just caused by reduction of D cell count (Haruma et al., 1995; Kozłowski et al., 1993; Kozłowski et al., 1995). No such hypergastrinaemia-inducing effect was observed during activation of gastric mucosal inflammatory processes or in biomorphotic process. As regards the course of *Helicobacter pylori* colonization, other authors (Jang & Kim, 2000) found intensification of both apoptosis and proliferative activity of endocrine cells, mainly G and D, correlated with gastritis activity and with the degree of *H.pylori* colonization. Not all authors (Tzaneva & Julianov, 1999) found lesions in CgA and D cells of gastric corpus mucosa with *H.pylori* colonization. At the same time, these authors stressed that D cells did not participate in the pathomechanism of hypergastrinaemia observed in this case.

Experimental pathology demonstrates that together with deepening biomorphosis, the expression of G cells decreases while D and ECn cells are more numerous (Sandstrom et al., 1999). However, these relations are not so easy to explain, what has been already reported by the authors cited above, due to e.g. the fact that it is not certain whether pathogenic factors other than biomorphosis leading to the above described lesions in G, D and ECn cells, can be excluded. The own study confirmed lack of changes in the neuroendocrine cells status in the gastric mucosa depending on the biomorphosis.

Studies of endocrine cells in gastric mucosa and gastrointestinal tract mucosa in general, require extensive continuation. However, in order to provide significant progress in medical knowledge, it is necessary to standardise, in the first place, the method of quantitative assessment of these cells and also to establish a generally accepted strictly histopathological classification of chronic gastritis.

## 5. Presented results and conclusions

*Helicobacter pylori* presence in about 50% of healthy population without any clinical symptoms, and in 30% also without any morphological changes in gastric mucosa, requires further evaluations, both clinical and pathological. Endoscopic biopsy evaluations have firmly indicated that there is a poor correlation between the gastric mucosal appearance and histological indices of superficial and atrophic chronic gastritis. The Sydney System and its updated 1994 Houston status of the gastritis classification remains incompletely accepted. Many pathological reports on gastritis have individual, non-standard styles, which poorly correlates with both clinical symptoms and endoscopic lesions. As chronic gastritis is both overdiagnosed and underdiagnosed, a cooperation between clinicians and pathologists in diagnostics of a particular type of chronic gastritis is a necessity. Finally, in order to provide significant progress in medical knowledge, it is necessary to standardize, in the first place, the clinic-pathological cooperation and the method of quantitative or semi-quantitative assessment of the inflammatory and epithelial (histoarchitectural structure) cells of the gastric mucosa and also to establish a generally accepted strictly histopathological classification of chronic gastritis.

## 6. References

- Appelman H.D. (1994). Gastritis: terminology, etiology, and clinicopathological correlations: another biased view. *Hum Pathol*, Vol.25, No.10, (October 1994), pp.1006-1019, ISSN 0046-8177
- Arkkila P.E., Seppala K., Farkkila M.A., et al. (2006). Helicobacter pylori eradication in the healing of atrophic gastritis: a one-year prospective study. *Scand J Gastroenterol*, Vol.41, No.7, (July 2006), pp.782-90, ISSN 0036-5521
- Axon A.T.R. (1992). Clinical and histological consequences of Helicobacter pylori suppression/eradication. *J Gastroenterol Hepatol*, Vol.4, Suppl.2, (1992), pp.49-52, ISSN 1440-1746
- Bechi P., Balzi M., Becciolini A., et al. (1996). Helicobacter pylori and cell proliferation of the gastric mucosa: possible implications for gastric carcinogenesis. *Am J Gastroenterol*, Vol.91, No.2, (February 1996), pp.271-276, ISSN 0002-9270
- Bielicki D., Markiewicz M., Marlicz K., et al. (1993). PCNA/cyclin defined proliferative activity of epithelial cells in normal gastric mucosa in chronic gastritis. *Polish J Pathol*, Vol.44, (1993), pp.75, ISSN 1233-9687
- Borch K., Renvall H., Kullman E., et al. (1987). Gastric carcinoid associated with syndrome of hypergastrinemic atrophic gastritis: A prospective analysis of 11 cases. *Am J Surg Pathol*, Vol.11, No.,(1987), pp.435-444, ISSN 0147-5185
- Borchard F. (2001). Chemical-reactive gastritis. *Pathologe*, Vol.22, No.1, (January 2001), pp.44-55, ISSN 0172-8113
- Bordi C., D'Adda T., Azzoni C., et al. (2000). Classification of gastric endocrine cells at light and electron microscopical levels. *Microsc Res Tech*, Vol.48, No.5, (March 2000), pp. 258-271, ISSN 1097-0029
- Bordi C., Ferrari C., D'Adda T., et al. (1986) Ultrastructural characterization of fundic endocrine cell hyperplasia associated with atrophic gastritis and hypergastrinemia. *Virchows Arch*, Vol.404, No., (1986), pp.335-347, ISSN 0945-6317
- Canese M.G., Bussolati G. (1977). Immuno-Electron-Cytochemical Localization of the Somatostatin Cells In The Human Antral Mucosa. *J Histochem Cytochem*, Vol.25, No., (1977), pp. 1111-1118, ISSN 0022-1554
- Carney A., Go V., Fairbanks V., et al. (1983). The syndrome of gastric argyrophil carcinoid tumours and nonantral gastric atrophy. *Ann Intern Med*, Vol.99, No.6, (December 1983), pp.761-766, ISSN 0003-4819
- Cetin Y. (1992). Chromogranin A immunoreactivity and Grimelius' argyrophilia. A correlative study in mammalian endocrine cells. *Anat Embryol*, Vol.185, No.3, (September 1992), pp.207-15, ISSN 0340-2061
- Chamouard P., Walter P., Wittersheim C., et al. (1997). Antral and fundic D-cell numbers in Helicobacter pylori infection. *Eur J Gastroenterol Hepatol*, Vol.9, No.4, (April 1997), pp.361-365, ISSN 0954-691X
- Chen X.Y., Van der Hulst R.W., Bruno M.J., et al. (1999). Interobserver variation in the histopathological scoring of Helicobacter pylori related gastritis. *J Clin Pathol*, Vol.52, No.8, (August 1999), pp.612-615, ISSN 0021-9746
- Cohen M.C., Cueto-Rua E., Balcarce N., et al. (2000). Assessment of the Sydney System in Helicobacter pylori-associated gastritis in children. *Acta Gastroenterol Latinoam*, Vol.30, No.1, (January 2000), pp.35-40, ISSN 0300-9033

- Correa P., Yardley J.H. (1992). Grading and classification of chronic gastritis: one american response to the Sydney System. *Gastroenterology*, Vol.102, No.1, (January 1992), pp.355-359, ISSN 0016-5085
- Correa P. (1988). Chronic gastritis: a clinico-pathologic classifications. *Am J Gastroenterol*, Vol.83, No.5, (May 1988), pp.504-509, ISSN 0002-9270
- Correa P. (1980). The epidemiology and pathogenesis of chronic gastritis. Three etiologic entities. *Front Gastroenterol Res*, Vol.6, (1980), pp.98-108, ISSN 0302-0665
- Coupe M., Rees H., Springer C.J., et al. (1990). Gastric enterochromaffin-like (ECL) cells in hypergastrinaemic duodenal ulcer disease. *Gut*, Vol.31, No.2, (February 1990), pp.144-147, ISSN 0017-5749
- D'Adda T., Corleto V., Pilato F.P., et al. (1990). Quantitative ultrastructure of endocrine cells of oxyntic mucosa in Zollinger-Ellison syndrome. *Gastroenterology*, Vol.99, No.1, (July 1990), pp.17-26, ISSN 0016-5085
- Dayal Y. (1992). Hyperplastic proliferations of the ECL cells. *Yale J Biol Med*, Vol.65, No.6, (Nov-Dec 1992), pp.805-825, ISSN 0044-0086
- Deschner E.E., Winawer S.J., Lipkin M. (1972). Patterns of nucleic acid and protein synthesis in normal human gastric mucosa and atrophic gastritis. *J Nat Cancer Inst*, Vol.48, No.6, (June 1972), pp.1567-1574, ISSN 0027-8874
- Diebold MD, Richardson S, Duchateau A, et al (1998) Factors influencing corpus argyrophil cell density and hyperplasia in reflux esophagitis patients treated with antisecretory drugs and controls. *Dig Dis Sci*, Vol.43, No.8, (August 1998), pp.1629-1635, ISSN 0163-2116
- Dixon M.F., Genta R.M., Yardley J.H., Correa P., et al., (1996), Classification and grading of gastritis. The updated Sydney System. *Am J Surg Pathol*, Vol.20, No.10, (October 1996), pp.1161-1181, ISSN 0147-5185
- Fenoglio-Preiser CH (ed.). (1999). *Gastrointestinal Pathology*. Lippincott-Raven, ISBN 9780397516407, Philadelphia New York
- Glass G.B.J., Pitchumoni C.S. (1975). Structural and ultrastructural alterations, exfoliative cytology and enzyme cytochemistry and histochemistry, proliferation kinetics, immunological derangements and other causes, and clinical associations and sequellae. *Hum Pathol*, Vol.6, No.2, (March 1975), pp.219-250, ISSN 0046-8177
- Goodlad R.A., Madgwick A.J.A., Moffatt M.R., et al. (1989). Prostaglandins and the gastric epithelium: Effects of misoprostol on gastric epithelial cell proliferation in the dog. *Gut*, Vol.30, No.3, (March 1989), pp.316-21, ISSN 0017-5749
- Goodlad R.A., Wright N.A. (1987). Peptides and epithelial growth regulation. *Experientia*, Vol.43, No.7, (July 1987), pp.780-784, ISSN 0014-475
- Goodlad R.A., Wright N.A. (1995). Epithelial kineticks; control and consequences of alteration in disease. In: *Gastrointestinal and oesophageal pathology (2<sup>nd</sup> ed)*, Whitehead R. (Ed.) , pp.97-115, Churchill Livingstone, ISBN 9780443047640, New York
- Graham D.Y., Lew G.M., Lechago J. (1993). Antral G-cell and D-cell numbers in *Helicobacter pylori* infections effect of H. Pylori eradication. *Gastroenterology*, Vol.104, No.6, (June 1993), pp.1655-1660, ISSN 0016-5085
- Green L.K., Graham D.Y. (1990). Gastritis in the elderly. *Clinics North Am*, Vol.19, No.2, (June 1990), pp.273-292, ISSN 0889-8553

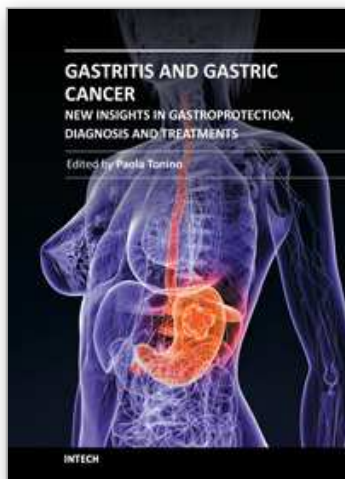
- Guarner J., Herrera-Goepfert R., Mohar A., et al. (1999). Interobserver variability in application of the revised Sydney classification for gastritis. *Hum Pathol*, Vol.30, No.12, (December 1999), pp.1431-1434, ISSN 0046-8177
- Guerci A., Chambre J.F., Franck P., et al. (1992). Flow cytometric analysis of the cell cycle in chronic gastritis. *Anal Cell Pathol*, Vol.4, No.5, (September 1992), pp.381-338, ISSN 0921-8912
- Hall P.A., Levison D.A., Woods A.L., et al. (1990). Proliferating cell nuclear antigen (PCNA) immunolocalization in paraffin sections: an index of cell proliferation with evidence of deregulated expression in some neoplasm. *J Pathol*, Vol.162, No.4, (December 1990), pp.285-294, ISSN 1096-9896
- Haruma K., Sumii K., Okamoto S., et al. (1995). Helicobacter pylori infection associated with low antral somatostatin content in young adults. Implication for the pathogenesis of hypergastrinemia. *Scandinavian J Gastroenterol*, Vol.30, No.6, (June 1995), pp.550-553, ISSN 0036-5521
- Hattori T. (1976). Tritiated thymidine autoradiographic study on cellular migration in the gastric gland of the golden hamster. *Cell Tiss Res*, Vol.172, No.2, (September 1976), pp.171-184, ISSN 0302-766X
- Havu N. (1986). Enterochromaffin-like cell carcinoids of gastric mucosa in rats after life-long inhibition of gastric secretion. *Digestion*, Vol.35, Suppl.1, (1986), pp.42-55, ISSN 0012-2823
- Hellander H.E. (1981). The cells of the gastric mucosa. *Int Rev Cytol*, Vol.70, (1981), pp.217-82, ISSN 0074-7696
- Hodges J., Isacson P., Wright R. (1981). Diffuse enterochromaffin-like (ECL) cell hyperplasia and multiple gastric carcinoids; complication of pernicious anemia. *Gut*, Vol.22, No.3, (March 1981), pp.237-241, ISSN 0017-5749
- Iacangelo A., Fischer-Colbrie R., Koller K.J., et al. (1988). The sequence of porcine chromogranin A can serve precursor for the biologically active hormone, pancreastatin. *Endocrinology*, Vol.122, No.5, (May 1988), pp.2339-2341, ISSN 0013-7227
- Irazusta S.P., Vassallo J., Magna L.A., et al. (1998). The value of PCNA and AgNOR staining in endoscopic biopsies of gastric mucosa. *Pathol Res Pract*, Vol.194, No.1, (1998), pp.33-39, ISSN 0344-0338
- Ito H., Yokozaki H., Tokumo K., et al. (1986). Serotonin containing E cells in normal human gastric mucosa and in gastritis. Immunohistochemical, electron microscopic and autoradiographic studies. *Virchows Arch A*, Vol.409, No.3, (1986), pp.313-323, ISSN 0174-7398
- Jang T.J., Kim J.R. (2000). Proliferation and apoptosis in gastric antral epithelial cells of patients infected with Helicobacter pylori. *J Gastroenterol*, Vol.35, No.4, (April 2000), pp.312-314, ISSN 0944-1174
- Keleman Z. (1997). PCNA: Structure, Function and Interactions. *Oncogene*, Vol.14, No.6, (February 1997), pp.629-640, ISSN 0950-9232
- Kimura N., Sassano N., Yamada R., et al. (1988). Immunohistochemical study of chromogranin in 100 cases of pheochromocytoma, carotid body tumor, medullary thyroid carcinoma and carcinoid tumour. *Virchows Arch*, Vol.413, No.1, (1988), pp.33-38, ISSN 0945-6317



- Kitani M., Asada Y., Sakata J., et al. (1999). Cell density of adrenomedullin-immunoreactive cells in the gastric endocrine cells decreases in antral atrophic gastritis. *Histopathology*, Vol.34, No.2, (February 1999), pp.134-139, ISSN 0309-0167
- Konecki D.S., Benedum U.M., Gerdes H.H., et al. (1987). The primary structure of human chromogranin A and pancreastatin. *J Biol Chem*, Vol.262, No.35, (December 1987), pp.17026-17030, ISSN 0021-9258
- Kozłowski W., Kulig A., Czekwianianc E., et al. (1995). Morphological and immunohistochemical examinations of the dynamic changes of gastric mucosa associated with the treatment of *Helicobacter pylori* infection in children. *An Ac. Med Bial*, Vol.40, No.3, (1995), pp. 678-684, ISSN 1427-941X
- Kozłowski W., Kulig A., Czekwianianc E., et al. (1993). Histochemical and immunohistochemical evaluations of the gastric endocrine cells (ECL, EC, G and D) with *Helicobacter pylori* infection in children. *Przegl Pediatr*, Vol.XXIII, Suppl.1, (1993), pp.249-254, ISSN 0137-723X, (In polisch),
- Larsson L., Rehfeld J., Stockbrugger R., et al. (1978). Mixed endocrine tumours associated with hypergastrinemia of antral origin. *Am J Pathol*, Vol.93, No.1, (October 1978), pp.53-68, ISSN 0002-9440
- Larsson L.I. (1984). Evidence for anterograde transport of secretory granules in processes of gastric paracrine (somatostatin) cells. *Histochemistry*, Vol.80, No.8, (1984), pp.323-326, ISSN 0301-5564
- Lee E.R. (1985). Dynamic histology of the antral epithelium in the mouse stomach. III. Ultrastructure and renewal of pit cells. *Am J Anat*, Vol.172, No.3, (March 1985), pp.225-240, ISSN 0002-9106
- Lee H., Hakanson R., Karlsson A., et al. (1992). Lansoprazole and Omeprazole Have Similar Effect on Plasma Gastrin Levels, Enterochromaffin-Like Cells, Gastrin Cells and Somatostatin Cells in the Rat Stomach. *Digestion*, Vol.51, No.3, (1992), pp.125-132, ISSN 0012-2823
- Lloyd R.V., Mervak T., Schmidt K., et al. (1984). Immunohistochemical detection of chromogranin and neuron-specific enolase in pancreatic endocrine neoplasms. *Am J Surg Pathol*, Vol.8, No.8, (August 1984), pp.607-614, ISSN 0147-5185
- Lynch D.A., Axon A.T. (1995). *Helicobacter pylori*, gastric cancer and gastric epithelial kinetics: a review. *Europ J Gastroenterol Hepatol*, Vol.7, Suppl.1, (August 1995), pp.S17-23, ISSN 0954-691X
- Warren J.R., Marshall B. (1983). Unidentified curved bacilli on gastric epithelium in active chronic gastritis. *Lancet*, Vol.321, No.8336, (June 1983), pp.1273-1274, ISSN 0140-6736
- Mathews M.B., Bernstein R.M., Franza B.R., et al. (1984). Identity of the proliferating cell nuclear antigen and cyclin. *Nature*, Vol.309, No.5966, (May 1984), pp.374-376, ISSN 0028-0836
- Misiewicz J.J., Tytgat G.N.J., Goodwin C.S., et al. (1990). The Sydney System: a new classification of gastritis. *World Congresses of Gastroenterology*; 1990 August 26–31. Sydney, pp.1-10
- Murray S.S., Deaven L.L., Burton D.W., et al. (1987). The gene for human chromogranin A (CgA) is located on chromosome 14. *Biochem Biophys Res Commun*, Vol.142, No.1, (January 1987), pp.141-146, ISSN 0006-291X

- Oren M. (1992) The involvement of oncogenes and tumour suppressor genes in the control of apoptosis. *Cancer and Metastatic Review*, Vol.11, No.2, (September 1992), pp.141-148, ISSN 0167-7659
- Owen D.A., (1996) The Morphology of Gastritis. *Yale J Biol Med*, Vol.69, (1996), pp.51-60, ISSN 0044-0086
- Panella C., Ierardi E., Polimeno L., et al. (1996). Proliferative activity of gastric epithelium in progressive stages of *Helicobacter pylori* infection. *Dig Dis Sci*, Vol.41, No.6, (June 1996), pp.1132-1138 ISSN 0163-2116
- Portela-Gomes G.M., Grimelius L. (1986). Identification and characterisation of enterochromaffin cells with different staining techniques. *Acta Histochem*, Vol.79, (1986), pp.161-174, ISSN 0065-1281
- Preston-Martin S., Pike M.C., Ross R.K., et al. (1990). Increased cell division as a cause for human cancer. *Cancer Research*, Vol.50, No.23, (December 1990), pp.415-421, ISSN 0008-5472
- Price A.B. (1999). Classification of gastritis: yesterday, today and tomorrow. *Verh Dtsch Ges Pathol*, Vol.83, (1999), pp.52-55, ISSN 0070-4113
- Price A.B. (1991). The Sydney System: Histological division. *J Gastroenterol Hepatol*, Vol.6, No.3, (May-June 1991), pp.209-222, ISSN 1440-1746
- Ricci V., Ciacci C., Zarrilli R., et al. (1996). Effect of *Helicobacter pylori* on gastric epithelial cell migration and proliferation in vitro: role of VacA and CagA. *Infection Immunity*, Vol.64, No.7, (July 1996), pp.2829-2833, ISSN 0019-9567
- Rosa P., Hille A., Lee R.W.H., et al. (1985). Secretogranins I and II: two tyrosinesulfated secretory proteins common to a variety of cells secreting peptides by the regulated pathway. *J Cell Biol*, Vol.101, No.5 Pt 1, (November 1985), pp.1999-2011, ISSN 0021-9525
- Rubin W. (1972). Endocrine cells in the normal human stomach. A fine structural study. *Gastroenterology*, Vol.63, No.1, (November 1972), pp.784-800, ISSN 0016-5085
- Sandstrom O., Mahdavi J., el-Salhy M. (1999). Age-related changes in antral endocrine cells in mice. *Histol Histopathol*, Vol.14, No.1, (January 1999), pp.31-36, ISSN 0213-3911
- Sipponen P. (1989). Atrophic gastritis as a premalignant condition. *Ann Med*, Vol.21, No.4, (August 1989), pp.287-290, ISSN 0785-3890
- Sipponen P. (1992). Long-term consequences of gastroduodenal inflammation. *J Gastroenterol Hepatol*, 1992, Vol.4, Suppl.2, (1992), pp.25, ISSN 1440-1746
- Solcia E., Capella C., Buffa R., et al. (1979). Endocrine cells of the gastrointestinal tract and related tumors. *Pathobiol Ann*, Vol.9, (1979), pp.163-204, ISSN 0362-3025
- Solcia E., Capella C., Vassallo G. (1975). Endocrine cells of the gastric mucosa. *Int Rev Cytol*, Vol.42, (1975), pp.223-286, ISSN 0074-7696
- Strickland R.G., Mackay I.R. (1973). A reappraisal of the nature and significance of chronic gastritis. *Am J Dig Dis*, Vol.18, No.5, (May 1973), pp.426-440, ISSN 0002-9211
- Strickland R.G. (1990). Gastritis. *Springer Seminars in immunopathology* 1990, Vol.12, No.2-3, (1990), pp.203-217, ISSN 0344-4325
- Tytgat G.N.J. (1991). The Sydney System: Endoscopic division. Endoscopic appearance in gastritis/duodenitis. *J Gastroenterol Hepatol*, Vol.6, No.3, (May-June 1991), pp.223-234, ISSN 1440-1746

- Tzaneva M. (2001). Electron microscopic immunohistochemical investigation of chromogranin A in endocrine cells in human oxyntic gastric mucosa. *Acta Histochem*, Vol.103, No.2, (April 2001), pp.179-194, ISSN 0065-1281
- Tzaneva M., Julianov A. (1999). Chromogranin A-, somatostatin- and serotonin-containing endocrine cells in the corporal gastric mucosa of patients with *Helicobacter pylori* associated gastritis. *Endocr Regul*, Vol.33, No.2, (June 1999), pp.79-82, ISSN 1210-0668
- Walsh J.H. (1990). Role of gastrin as a trophic hormone. *Digestion*, Vol.47, Suppl.1, (1990), pp.11-16, ISSN 0012-2823
- Waseem N.H., Lane D.P. (1990). Monoclonal antibody analysis of the proliferating cell nuclear antigen (PCNA). Structural conservation and the detection of a nucleolar form. *J Cell Sci*, Vol.96, Pt.1, (May 1990), pp.212-219, ISSN 0021-9533
- Weaver L.T., Walker W.A. (1988). Epidermal growth factor and the developing human gut. *Gastroenterology*, Vol.94, No.3, (March 1988), pp.845-847, ISSN 0016-5085
- Whitehead R., Truelove S.C., Gear M.W.L. (1972). The histological diagnosis of chronic gastritis in fiberoptic gastroscope biopsy specimens. *J Clin Pathol*, 1972, Vol.25, No.1, (January 1972), pp.1-11, ISSN 0021-9746
- Wiedemann B., Huttner W.B. (1989). Synaptophysin and chromogranin/secretogranins widespread constituents of distinct types of neuroendocrine vesicles and new tools in tumor diagnosis. *Virchows Arch B*, Vol.58, No.2, (1989), pp.95-121, ISSN 0340-6075
- Wilson B.S., Lloyd R.V. (1984). Detection of chromogranin in neuroendocrine cells with a monoclonal antibody. *Am J Pathol*, Vol.115, No.3, (June 1984), pp.458-468, ISSN 0002-9440
- Wyatt J.I. (1995). Histopathology of gastroduodenal inflammation: the impact of *Helicobacter pylori*. *Histopathology*, Vol.26, No.1, (January 1995), pp.1-15, ISSN 0309-0167
- Yanagihara K., Tsumuraya M. (1992). Transforming growth factor beta-1 induces apoptotic cell death in cultured human gastric carcinoma cells. *Cancer Res*, Vol.52, No.14, (July 1992), pp.4042-4045, ISSN 0008-5472
- Zhang Ch., Yamada N., Wu Y-L., et al. (2005a). *Helicobacter pylori* infection, glandular atrophy and intestinal metaplasia in superficial gastritis, gastric erosion, erosive gastritis, gastric ulcer and early gastric cancer. *World J Gastroenterol*, Vol.11, No.6, (February 2005), pp. 791-796, ISSN 1007-9327
- Zhang Ch., Yamada N., Wu Y-L., et al. (2005b). Comparison of *Helicobacter pylori* infection and gastric mucosal histological features of gastric ulcer patients with chronic gastritis patients. *World J Gastroenterol*, Vol.11, No.7, (February 2005), pp. 976-981, ISSN 1007-9327
- Zverkov I.V., Isakov V.A., Aruin L.I. (1996). *Helicobacter pylori*, endocrine cells of the gastric mucosa, and their function in duodenal ulcer. *Arkh Patol*, Vol.58, No.1, (January-February 1996), pp.33-37, ISSN 0004-1955



## **Gastritis and Gastric Cancer - New Insights in Gastroprotection, Diagnosis and Treatments**

Edited by Dr. Paola Tonino

ISBN 978-953-307-375-0

Hard cover, 296 pages

**Publisher** InTech

**Published online** 15, September, 2011

**Published in print edition** September, 2011

This book is a comprehensive overview of invited contributions on *Helicobacter pylori* infection in gastritis and gastric carcinogenesis. The first part of the book covers topics related to the pathophysiology of gastric mucosal defense system and gastritis including the gastroprotective function of the mucus, the capsaicin-sensitive afferent nerves and the oxidative stress pathway involved in inflammation, apoptosis and autophagy in *H. pylori* related gastritis. The next chapters deal with molecular pathogenesis and treatment, which consider the role of neuroendocrine cells in gastric disease, DNA methylation in *H. pylori* infection, the role of antioxidants and phytotherapy in gastric disease. The final part presents the effects of cancer risk factors associated with *H. pylori* infection. These chapters discuss the serum pepsinogen test, K-ras mutations, cell kinetics, and *H. pylori* lipopolysaccharide, as well as the roles of several bacterial genes (*cagA*, *cagT*, *vacA* and *dupA*) as virulence factors in gastric cancer, and the gastrokine-1 protein in cancer progression.

### **How to reference**

In order to correctly reference this scholarly work, feel free to copy and paste the following:

Wojciech Kozłowski, Cezary Jochymowski and Tomasz Markiewicz (2011). Chronic Gastritis, Gastritis and Gastric Cancer - New Insights in Gastroprotection, Diagnosis and Treatments, Dr. Paola Tonino (Ed.), ISBN: 978-953-307-375-0, InTech, Available from: <http://www.intechopen.com/books/gastritis-and-gastric-cancer-new-insights-in-gastroprotection-diagnosis-and-treatments/chronic-gastritis>

**INTECH**  
open science | open minds

### **InTech Europe**

University Campus STeP Ri  
Slavka Krautzeka 83/A  
51000 Rijeka, Croatia  
Phone: +385 (51) 770 447  
Fax: +385 (51) 686 166  
[www.intechopen.com](http://www.intechopen.com)

### **InTech China**

Unit 405, Office Block, Hotel Equatorial Shanghai  
No.65, Yan An Road (West), Shanghai, 200040, China  
中国上海市延安西路65号上海国际贵都大饭店办公楼405单元  
Phone: +86-21-62489820  
Fax: +86-21-62489821



© 2011 The Author(s). Licensee IntechOpen. This chapter is distributed under the terms of the [Creative Commons Attribution-NonCommercial-ShareAlike-3.0 License](https://creativecommons.org/licenses/by-nc-sa/3.0/), which permits use, distribution and reproduction for non-commercial purposes, provided the original is properly cited and derivative works building on this content are distributed under the same license.

IntechOpen

IntechOpen