

We are IntechOpen, the world's leading publisher of Open Access books Built by scientists, for scientists

6,900

Open access books available

186,000

International authors and editors

200M

Downloads

Our authors are among the

154

Countries delivered to

TOP 1%

most cited scientists

12.2%

Contributors from top 500 universities



WEB OF SCIENCE™

Selection of our books indexed in the Book Citation Index
in Web of Science™ Core Collection (BKCI)

Interested in publishing with us?
Contact book.department@intechopen.com

Numbers displayed above are based on latest data collected.
For more information visit www.intechopen.com



Laparoscopic Radical Prostatectomy

Pierluigi Bove and Valerio Iacovelli
*Tor Vergata University of Rome, Rome
 Italy*

1. Introduction

Cancer cure, normal continence and preserving sexual function are the primary goals of radical prostatectomy (RP). By adopting the laparoscopic technique with adherence to established oncological principles, the aim is to duplicate the open surgical method in its entirety.

1.1 Historical aspects

Laparoscopic radical prostatectomy (LRP) has become an established treatment for organ-confined prostate cancer and is increasingly performed at selected centers worldwide even though open radical retropubic prostatectomy (RRP) is widely considered the treatment of choice (Walsh, 2000).

For the first time in 1992, Schuessler, a non-academic, attempted the first LRP assisted by two endourologists with laparoscopic experience in renal surgery (Schuessler et al., 1992). These pioneers were able to successfully perform 9 LRP procedures, but found no benefit over open prostatectomy. The operation was cumbersome and difficult with unacceptably prolonged operative time. The authors concluded that the procedure offered no advantage compared to RRP (Schuessler et al., 1997).

In 1998 Guillonnet et al. detailed their stepwise approach to transperitoneal LRP. After substantially improving the techniques at Montsouris in France, Guillonnet and associates published their series demonstrating substantial improvements in postoperative convalescence. The operation was shown to be feasible, but more importantly, although the learning curve remained steep (Guillonnet et al., 1999).

Since then, various European teams have added to the overall experience with this technique (Bollens et al., 2001; Rassweiler et al., 2001; Türk et al., 2001; De La Rosette et al., 2002). In USA, even experienced laparoscopists remained very skeptical about LRP. Gill and Zippe, who at that time focused on renal laparoscopic surgery, were one of the few who established a program of laparoscopic pelvic surgery (Gill & Zippe, 2001).

After 1997 LRP has slowly risen in popularity and became, in some centers, the surgical approach of choice for the treatment of the localized prostate cancer for its advantages. The lower blood loss and transfusion rate associated with the laparoscopic approach together with shorter hospital stay, reduced catheterization time, better pain control and the faster return to everyday activities seem the most encouraging improvements obtained (Hoznek et al., 2005).

2. Preoperative assessment: Patient selection

2.1 Indications

The indications for LRP are identical to that for open surgery, that is, patients with clinically localized prostate cancer (stages T1 and T2) with no evidence of metastasis either clinically or radiographically (CT, Computer Tomography and bone scan), a low PSA level (<10 ng/mL), a Gleason score < 7 and are age 70 or younger (Steinberg & Gill, 2004).

2.2 Contraindications

As with open surgery, previous abdominal and/or perineal surgery (such as transurethral resection of the prostate, pelvic surgery, laparoscopic inguinal hernia repair), history of radiation to the prostate, morbid obesity, large prostate size (e.g., >100g) and/or androgen deprivation may complicate organ dissection and are more challenging, but these features are not by themselves contraindications for laparoscopic prostatectomy.

Specific and absolute contraindications to minimally invasive laparoscopic prostatectomy include an active peritoneal inflammatory process, an uncorrectable bleeding diatheses or the inability to undergo general anesthesia due to severe cardiopulmonary compromise, akin to open surgery (Brown et al., 2005).

3. Preoperative preparation

3.1 Bowel preparation and prophylaxis

No bowel preparation is given usually. Since operations are done under general anesthesia, patients should receive nothing by mouth for at least six hours before surgery. Fasting starts at midnight before surgery. Thromboprophylaxis is implemented with good hydration, placement of compressive elastic stockings on the lower extremities, and low-molecular-weight heparin. A single intravenous dose of a 3rd generation cephalosporin low molecular weight subcutaneous heparin are given on call to the operating room. Patients admitted the day before surgery receive 4000 units of low molecular weight heparin the night before surgery (e.g., Enoxaparin such as Clexane®, 40 mg sc 1 × day) and continued daily until the patient is discharged from the hospital. Blood type and crossmatch are determined (Rosenblatt et al., 2008) .

3.2 Informed consent

The importance of informed consent is due to patient information. Patients undergoing LRP must be aware of the potential for conversion to open surgery, for possible bleeding, transfusion and infection. Impotence, incontinence, incisional hernia as complications and the risks of general anesthesia must also be presented to the patient.

3.3 Operating room personnel and configuration

Skills and training are key requirements of the operating room staff. The surgical team includes a scrub nurse, circulating nurse and surgical assistant(s). Only one surgeon is usually sufficient, but a second assistant may be useful in retracting tissues. The scrub nurse must be very versed in the laparoscopic surgery field in order to accomplish this procedure. The surgeon operates from the patient's left side, and the first assistant is placed at the opposite side of the surgeon. The laparoscopic cart is placed at the patient's feet, while the instruments table and the coagulation unit are positioned at the left side of the patient. The

scrub nurse is positioned beside the left lower extremity of the patient. The video monitor is placed between the patient's feet, at the eye level of the surgeon. (Fig. 1).

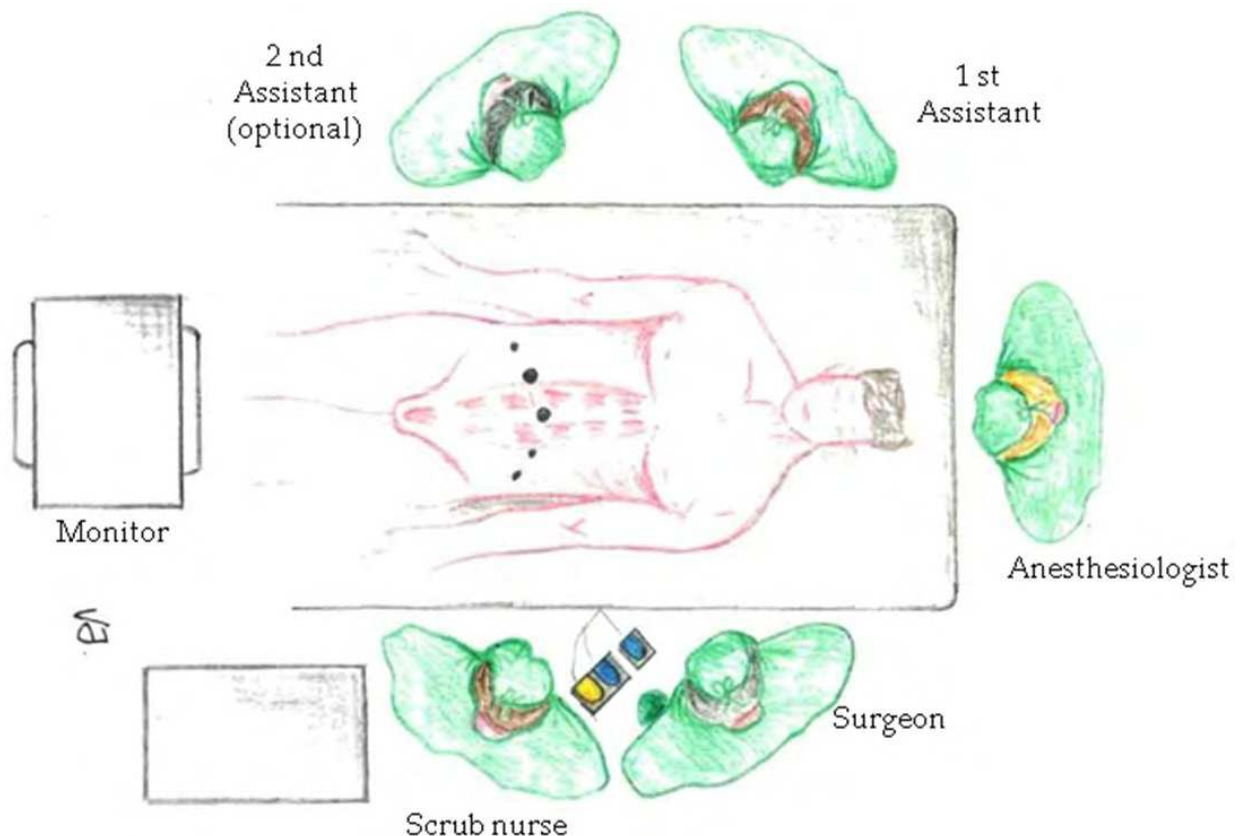


Fig. 1. Operating room personnel, position of the operative team and trocar configuration for laparoscopic radical prostatectomy. Steps are placed in front of the surgeon, and the bipolar and monopolar pedals are placed over the steps.

3.4 Instruments

It is preferable to choose the best instruments, even if they are more expensive. A good instrument is more effective and lasts longer. The following list corresponds to our personal preferences and does not claim to be exhaustive (Vallancien et al., 2002).

The following list corresponds to the essential instruments used for laparoscopic prostatectomy:

- An 18 Fr Foley catheter;
- 3 reusable, long 5-mm trocars, including 1 with an insufflators;
- 2 reusable 10-/12-mm trocars;
- 3 long forceps;
- 1 pair of unipolar forceps;
- 2 large bipolar forceps;
- A small bipolar forceps;
- 2 needle holders;
- Pledgets;
- 1 metal Béniqué sound;

- 1 rectal bougie;
- 1 aspirator-irrigator;
- Suture materials: they must be solid and must not form loops spontaneously;
- Lactomer 9-1: 3/0, 5/8 or 3/8 needle;
- Polyglactin 910: 2/0, 36 needle for the retropubic space;
- Polyglactin 910 1/0, 40 needle for the abdominal wall;
- Video equipment adapted to urology;
- Video camera and monitor with excellent definition;
- A rapid insufflators with modern safety features.

3.5 Patient positioning

The patient is positioned supine. The legs are slightly abducted and are fixed into the padded receptacles. The arms are fixed beside the body in arm padding. The abdomen is prepared from the xiphisternum to the perineum, including the genitals. The patient is secured to the table with adhesive tape, with both arms alongside his body. The thighs and the lower extremities are also secured. Strapping must be secure enough to prevent patient movement with the 30–40°. Trendelenburg position is used during surgery, but breathing should not be impeded. The base of the table must be positioned below the patient's hip to avoid elevation of the abdomen while in the Trendelenburg position.

Foam pads are used to pad the patient at all bony prominences to minimize pressure injury. A 18Ch Foley urethral catheter with 10mL in the balloon is introduced after the placement of the sterile drapes. An orogastric tube is placed to decompress the stomach. The abdomen, pelvis, and genitalia are skin prepared in case conversion to an open procedure is required.

3.6 Anesthesia considerations

General anesthesia is required in LRP. Before patient positioning is necessary to establish an accurate pulse oximetry, intravenous access and blood pressure gauge placement. Special attention is paid to the control of the CO₂ insufflation and pneumoperitoneum consequences such as oliguria and hypercapnia. Prompt and continues adjustments by the anesthesiologist and surgeon may be required.

Absolute contraindications: history of intracranial surgery or intracranial tumors. Relative contraindications: respiratory failure, severe heart failure and glaucoma.

4. Surgical technique

Comprehensive understanding of the anatomical landmarks and its implications in the patient's future quality of life are mandatory when attempting the procedure. The normal anatomical landmarks to consider during trocar placement while performing any of the minimally invasive techniques are umbilicus, anterior superior iliac spine, pubic symphysis and lateral border of rectus sheath. Generally, these procedures are accomplished using 4 to 6 trocars placed in a "W" or *inverted fan* configuration. Vesicourethral anastomosis is accomplished by either a continuous or an interrupted suturing technique, and the prostate is usually removed via an extension of the umbilical port site.

Several approaches to minimally invasive prostatectomy have been described, including the transperitoneal (TP) or Montsouris 1 and extraperitoneal (EP) or Montsouris 2. Each approach has its own unique merits and drawbacks. Each operator must choose the preferred technique based on experience (Levinson & Su, 2007; Vallancien et al., 2002).

The extraperitoneal approach provides a rapid access to the space of Retzius, minimizes bowel complications and intra-abdominal organ damage. The extraperitoneal method closely resembles the open RRP. However, the pelvic and prostate anatomy is magnified during laparoscopy, making dissection of important structures much more precise. Because no bowel is manipulated, the chance of an ileus or injury is decreased. Less Trendelenburg positioning is needed since the bowel does not need to be retracted, which may result in improved anesthetic and cardiovascular factors. Intraperitoneal contamination is not a concern, and the confined retroperitoneal space may aid in venous tamponade. The main limitation is the restricted working space, but with experience this does not seem to be an important drawback. However, recent studies comparing transperitoneal versus extraperitoneal approaches have not found any significant differences (Brown et al., 2005; Cathelineau et al., 2004). The extraperitoneal approach may be preferable in obese patients as it may shorten the distance between the trocar insertion site and operative field, and in patients with previous abdominal surgery where time-consuming adhesiolysis is avoided and the risk of bowel injury is minimized (Rassweiler et al., 2006).

We prefer to adopt the extraperitoneal route. Steps are placed for the surgeon, and the bipolar and monopolar pedals are placed over the step.

4.1 Extraperitoneal approach

The various steps of the operation are:

1. Abdominal access, insufflation and port placement
2. Dissection of the retropubic space
3. Opening of the pelvic fascia on each side
4. Mobilization of the bladder
5. Dissection of the seminal vesicles
6. Dissection of the neurovascular bundles
7. Haemostasis of vessels of the retropubic space
8. Dissection of the apex and section of the urethra
9. Vesicourethral anastomosis
10. Extraction of the surgical specimen and closure of the abdomen wall.

4.1.1 Abdominal access, insufflation and port placement

The first extraperitoneal laparoscopic approach was described in 1997 by Raboy et al. (Raboy et al., 1997). With this approach, the initial step is to create the extraperitoneal space. Five laparoscopic ports are used: two 10-/12-mm ports and three 5-mm ports. A 1,5 cm cutaneous incision is made at 1 cm below the inferior margin of the umbilicus. . With blunt finger dissection, a space is created anterior to the peritoneum. The subcutaneous fatty tissue is dissected with blunt scissors, resulting in visualization of the superficial fascia (rectus sheath). The fascia is grasped by two Kocher clamps and incised (Fig.2).

The first trocar is inserted into the abdominal wall without preliminary insufflations. The instrument must be directed more tangentially than for the transperitoneal route (20° to the horizontal instead of 45°). A trocar-mounted balloon dilator device is inserted into the preperitoneal space and about 300 ml of air is inflated to develop the space of Retzius as shown in Fig.3 (pneumo-Retzius). Pneumodissection occurs spontaneously. The scope is introduced and is used to collapse the loose connective tissue in order to enlarge the prevesical space. The pubic arch is rapidly identified and the tissues are largely dissected

on both sides to provide sufficient space. Pneumoextraperitoneum is created (15 mmHg) and four secondary ports are placed in a fan array. This way, secondary trocars are then placed under laparoscopic view by placing them slightly lower towards the pubis, as the working space is slightly narrower than transperitoneal approach. In the *inverted fan* configuration, the second 10-/12-mm port is inserted at the lateral border of the right rectus abdominis muscle to place the bipolar grasper. The three 5-mm trocars are one pararectus on the right iliac fossa and two are placed halfway between the anterior-superior iliac crest and pararectus trocars on the left iliac fossa. With port placement in the *fan* configuration, the surgeon operates through the two ports on the left side and the assistant uses the two right-sided ports (Fig.2). (Landman et al., 2004).

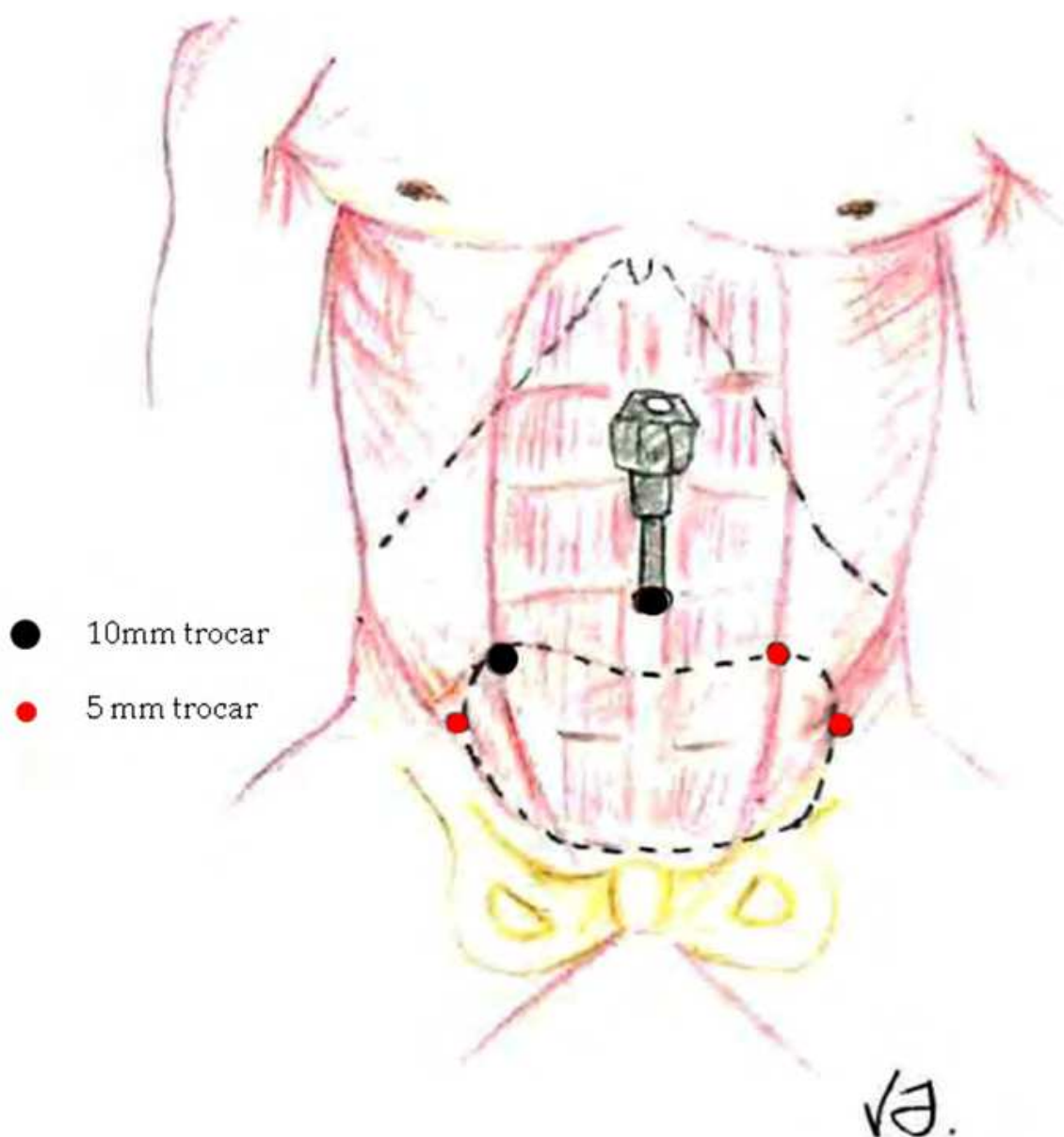


Fig. 2. Access and port placement.

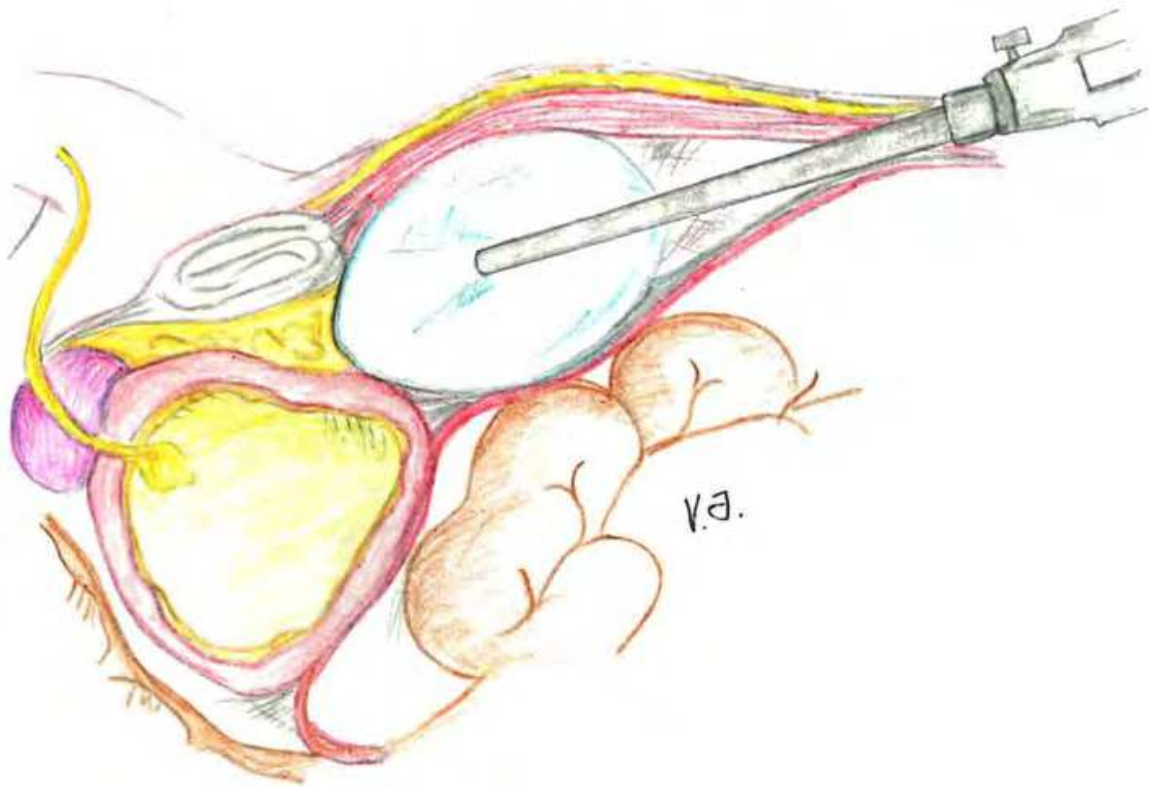


Fig. 3. Trocar-mounted balloon dilator device creating the pneumo-Retzius, a working space for extraperitoneal laparoscopic radical prostatectomy.

4.1.2 Dissection of the retropubic space

The patient is placed in the Trendelenburg position, with the head tilted down approximately 30-40°. This position aids the correct displacement of the intestine above the promontory by gently pushing back the loops of the small bowel.

The retropubic space is dissected by simple insufflation after directly placing the 10 mm trocar in an infraumbilical position. This space is rich in fatty tissue. The fibroareolar and fatty tissue layers between the superolateral aspect of the bladder and the medial aspect of the external iliac vein are bilaterally released (Rosenblatt et al., 2008). Once entry into the retropubic space is gained, dissection in the prevesical space of Retzius is performed in a deliberate manner, maintaining hemostasis at all times. The superficial dorsal vein, included in the small fatty area in the midline in the vicinity of the puboprostatic ligaments, is coagulated with bipolar electrocautery. Subsequently, the endopelvic fascia is cleaned bilaterally. The removal of this fatty tissue facilitates visualization and dissection of the bladder neck, which is usually located under the crossing of the fibers of the puboprostatic ligament (Vallancien et al., 2002).

4.1.3 Opening of the pelvic fascia on each side

The pelvic fascia is incised on each side, which partially mobilized the prostate. The right and the left sides of the endopelvic fascia are incised along the dotted line. The prostate is

retracted contralateral placing the endopelvic fascia on stretch. The endopelvic fascia is incised using a J-hook electrocautery or cold endoshears. The fascial incision is carried distally up to the lateral-most puboprostatic ligament. The fibers should not be divided close to the prostate to avoid lacerating the large veins that cross lateroposterior to the prostate (Kelly's veins). As the two layers of endopelvic fascia become more adherent moving toward the apex, they are then incised with the monopolar scissors to open the plane between the prostate and the endopelvic fascia. Visualization of the prostate apex is the endpoint of this dissection.

The completed incision of the endopelvic fascia bilaterally, exposing the convex contours of the prostatic lobes. The apex of the prostate is defined bilaterally. (Fig.4). The lateral puboprostatic ligaments are divided as necessary (Vallancien et al., 2002).

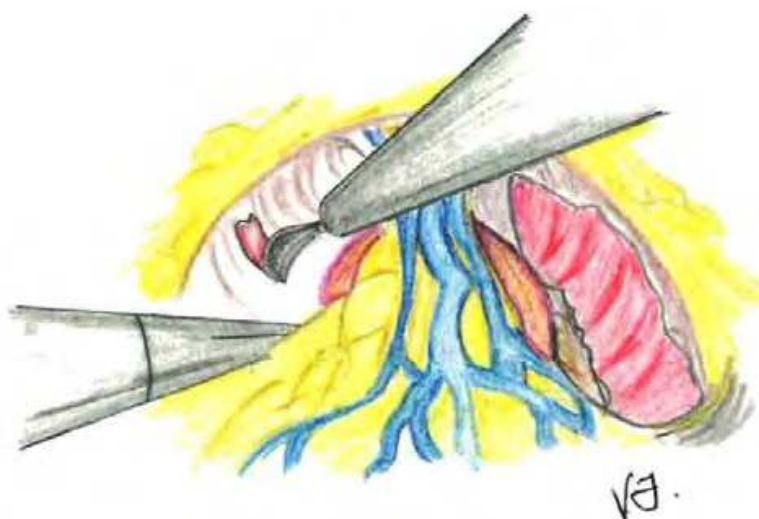


Fig. 4. The fatty tissue from the pubic symphysis is removed espousing the endopelvic fascia and the puboprostatic ligaments. The endopelvic fascia is incised.

4.1.4 Mobilization of the bladder

The bladder neck is situated under the crossing of the fibers of the puboprostatic ligaments. The bladder catheter balloon is inflated with 15-20 ml and is pulled on by the scrub nurse in order to reveal the bladder and its limits with the prostate. The limit between the two organs is most clearly defined by the perivesical fat. The assistant grasps the bladder dome and draws it downwards to give a good curvature. The bladder is incised at its junction with the prostate.

The incision progresses to assume an inverted U-shape to avoid dissecting through the lateral sides of the prostate. At the medial portion of the dissection, the longitudinal muscle fibers of the anterior urethral wall are exposed. The urethra is dissected at its anterior and lateral aspect and then transversally transected (Rosenblatt et al., 2008).

At this point, the Foley catheter is removed and replaced by a Béniqué sound, providing a good visualization of the bladder. The anterior surface of the prostate and the first detrusor muscle fibres are clearly visible. The dissection is carried out from the lateral side to the center and continues to the other side to fully separate the bladder neck from the base of the prostate. This is an important step in order to ensure good preservation of the bladder neck.

As this phase of the operation can cause bleeding, the tissues must be regularly coagulated. One of the best methods of coagulation is bipolar forceps.

Once the bladder is extensively dissected on both sides, it appears to be attached only by the bladder neck around the midline Béniqué sound. The bladder neck is meticulously opened close to the prostate and the urine is aspirated. A tip is to avoid tearing the bladder neck in order to preserve a small diameter. The posterior surface of the bladder neck can be seen. Care must be taken not to perforate the bladder at this level as the ureteral orifices are in close proximity. When the bladder neck is preserved, the ureteric orifices are situated further away. The posterior lip of the bladder neck is grasped with forceps and lowered to provide access to the interprostato-rectal plane (Vallancien et al., 2002) (Fig.4).

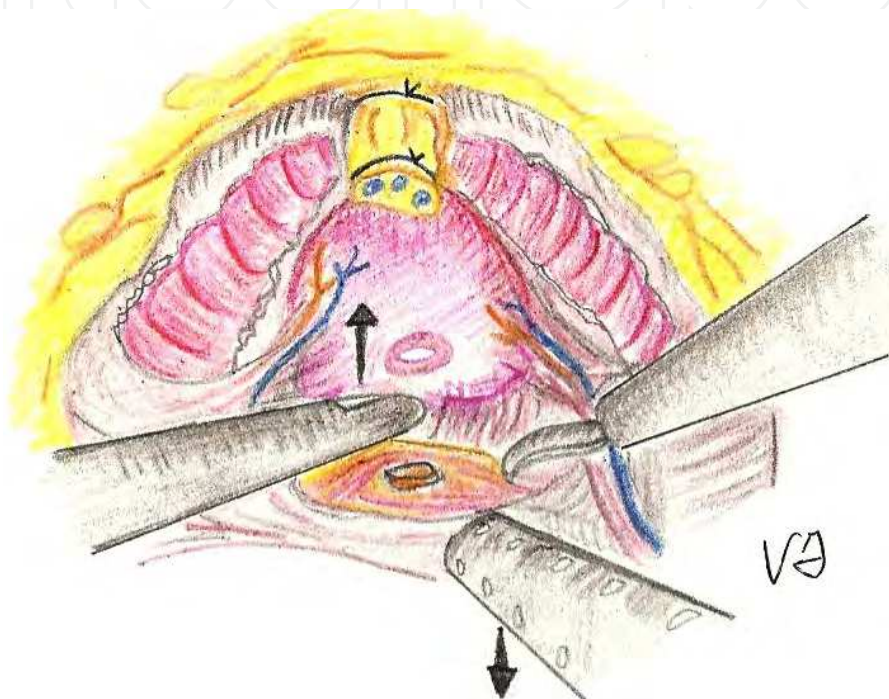


Fig. 4. Bladder incision at its junction with the prostate. Dorsal vein complex appears to be ligated just to focus on the incision. This procedure is done and analyzed later.

4.1.5 Dissection of the seminal vesicles and vasa deferentes

The plane of longitudinal muscle fibers behind the bladder neck is transversally incised to expose the vas deferens. The vertical fibers of the anterior plane of Denonvillier's fascia covering the seminal vesicles are incised (Rosenblatt et al., 2008). The ampullae of the left and right vasa deferentes (or vasa deferentia) can be seen in a fairly midline position, protecting the rectum from damage by the instruments. The ampullae of the right vas deferens is sectioned after coagulation with cold scissors or clipped with a Hem-o-lock clip and divided at its lower point, as in the transperitoneal technique. A large grip is used to simultaneously coagulate the anterior deferential artery. The seminal vesicle is dissected circumferentially from the base to the apex, taking care to control the vessels. It is important to remain flush with its lateral surface to avoid any diffusion of heat and any trauma to branches of the pudendal nerve. The lateral pedicle of the seminal vesicle is dissected and coagulated, and following the inferior pedicle dissection and coagulation, the seminal vesicle tip is then freed. This way, the right vas deferens and seminal vesicle have been completely mobilized. The left vas deferens is dissected in the same way. The left seminal

vesicle is then closely dissected to allow maximum mobilization. The seminal vesicles may then be dissected after the bladder neck dissection is complete, via an anterior approach.

At this time, we preferred to use harmonic or bipolar scalpel in order to avoid dissipation of thermal energy that could damage the nervi erigentes. It is essential to remain close to the seminal vesicles in order to prevent damage to the neurovascular bundles (NVB) and for this reason use of thermal energy should be limited to avoid the neuropraxia of the cavernous nerves, which lie in close proximity to the seminal vesicle. In order to preserve the NVB hemoclips are applied along the lateral aspect and tip of the seminal vesicle to secure the vascular pedicle.

By lifting both vasa deferentia and the seminal vesicles with a grasper, the Denonvillier's fascia is exposed as shown in Fig. 5 (Vallancien et al., 2002).

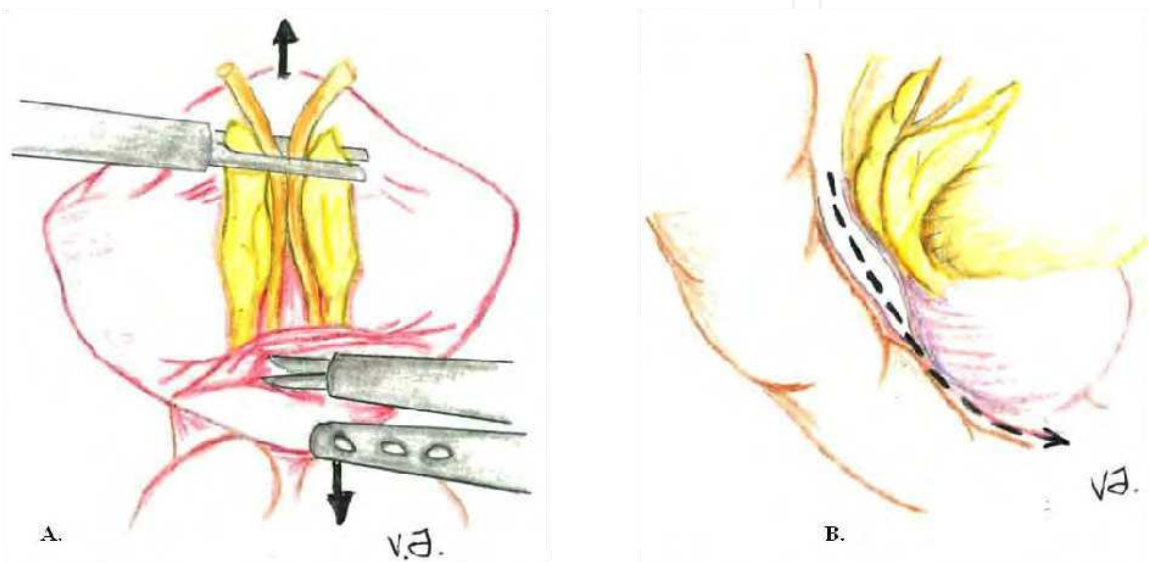


Fig. 5. Dissection of the prostate. A) By lifting both vasa deferentia and the seminal vesicles with a grasper, the Denonvillier's fascia is exposed. A transverse incision is made in Denonvillier's fascia below the seminal vesicles and blunt dissection is used to develop a plane between Denonvillier's fascia and the rectum. B) Dissection towards the prostate apex.

4.1.6 Dissection of the neurovascular bundles

The fibers of the Denonvillier's fascia are stretched and identified when the assistant holds the completely dissected seminal vesicles anteriorly. Two planes of dissection are correct: a) plane between the Denonvilliers' fascia and the prostate, which is the plane developed for neurovascular bundle preservation; b) posterior plane between the rectum and the Denonvillier's fascia—developed in cases of wide excision of the prostate without neurovascular bundle preservation (Rosenblatt et al., 2008).

The Denonvillier's fascia is transversely incised for 2-3 mm in the midline about 0,5 cm below the base of the seminal vesicles that are grasped with forceps and are drawn superiorly placing tension. Blunt dissection is carried out between the Denonvillier's fascia and the rectum till to visualize perirectal fat and the posterior aspect of the prostate.

The seminal vesicles are used to draw on the prostate to start dissection of the right NVB. The assistant inserts forceps into the dissection between the bladder and the prostate. The aspirator is used to lower the bladder to tighten the vescicoprostatic pedicles. Bipolar forceps are used to dissect and ensure haemostasis of the right vesicoprostatic pedicles.

These pedicles can bleed abundantly and good preventive coagulation is essential. The largest vessels visible, should be coagulated separately. The left vesicoprostatic space is opened by drawing the left seminal vesicle towards the right with forceps. Haemostasis is performed in the same way as on the right side with bipolar forceps. The left NVB is situated much lower. At this point, the bladder is completely mobilized. The prostate is only attached by the puboprostatic ligaments and NVBs.

Dissection of NVBs starts with the assistant who holds the forceps placed on the vesicoprostatic dissection and gently retracts the tissues of the NVB with the aspirator. The operator uses bipolar forceps and scissors. Access to the NVB is achieved by dissecting the endoprostic fascia high on the right lobe to avoid damage to small nerve branches. As the neurovascular bundle usually runs at a minimal distance from the prostate at the level of the apex, the dissection of the bundle is easier at this level. The lobe has a characteristic white color. Dissection is continued along the lobe by gently retracting the NVB with the aspirator. If the capsule is penetrated, the operator must immediately return to the right plane. The prostatic fascia is gradually separated from the lobe, limiting coagulation to a minimum. This phase is only slightly hemorrhagic. Small bipolar forceps are used, advancing step by step to avoid penetrating the prostatic capsule. The NVB is gently drawn towards the right with the aspirator meanwhile the dissected right edge of the prostate is clearly visible. Dissection is continued with scissors and coagulation should be used as little as possible and only using the small bipolar forceps with a reduced power. The right NVB, identified by its arterial pulsations, is dissected, without going as far as the apex. Dissection is terminated in retrograde fashion after having released the apex. On the left side the steps are identical. On both sides dissection must start at the top of the prostate and the lateral part is gradually dissected (Fig. 6 A & B).

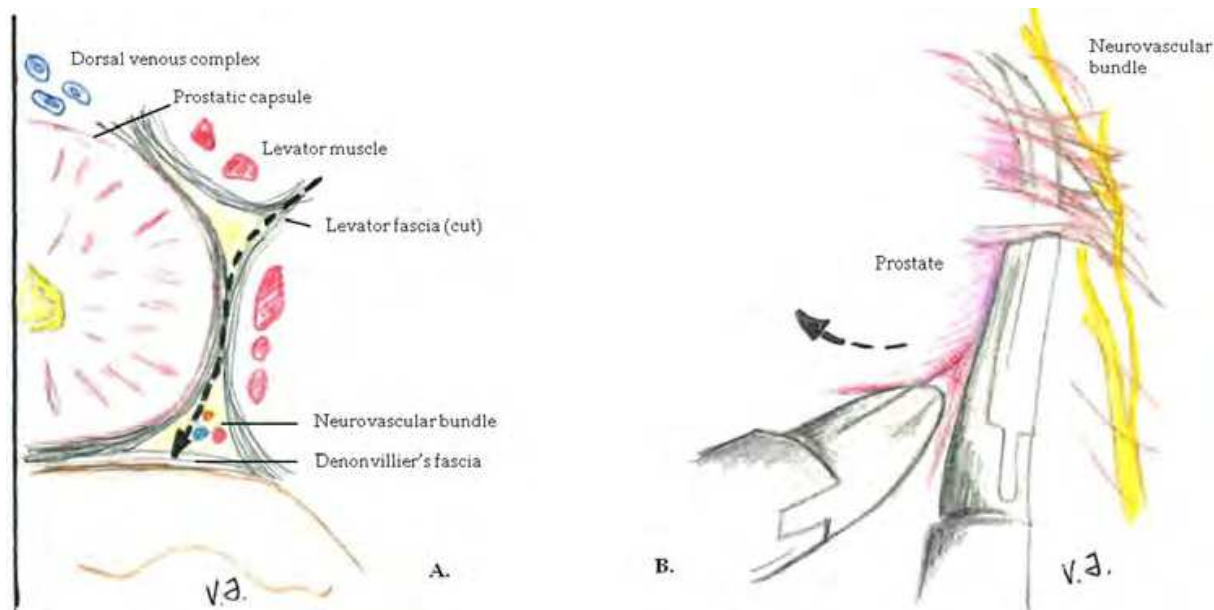


Fig. 6. Dissection of the neurovascular bundles. A) Emi-cross section of the prostate demonstrating the periprostatic fascial planes with respect to the location of the neurovascular bundles. The dashed line indicates the direction of interfascial dissection. B) developing the interfascial plane of dissection. A fine-tipped curved or right-angled dissector is gently passed immediately beneath the levator fascia to develop the interfascial plane of dissection.

The prostate can be stripped on the left. The NVB is perfectly visible. In patients with a history of endoscopic resection, prostatitis or hormonal therapy, the plane of cleavage may be difficult to find.

A simple veil of tissue remains, which is gently retracted. Haemostasis of visible perforating arteries is performed with small bipolar forceps. The prostate has been released and is now only attached by the apex, which will facilitate the following step of ligation of the vessels of the retropubic space, as it becomes very mobile in the lesser pelvis. The two puboprostatic ligaments are preserved. During dissection of the apex and section of the urethra, the operator must continually verify the position of the NVBs in relation to the instruments.

In the case of a very large tumor on one side or if the Gleason score is greater than 7, it is preferable not to perform intrafascial dissection, but to leave one or two millimeters of periprostatic tissue all along the lobe to avoid an excessively high positive margin rate without necessarily resectioning the NVB (Vallancien et al., 2002).

4.1.7 Haemostasis of vessels of the retropubic space

The dorsal vein complex at the apex of the prostate is legated with Polyglactin 910 2/0 suture material on a 36 needle. The needle is introduced through the right medial iliac 10-/12-mm trocar with a n. 10 reducer. There is no clearly defined limit beyond which the needle may be too deep. The Béniqué sound is useful to detect when the needle is inserted too deeply towards the urethra.

At the midpoint of insertion of the suture, push the right needle holder downwards and to the left so that the needle tends to rise upwards towards the left. When this maneuver is not performed, the needle will enter the pelvic muscles on the left side, where it cannot be reached. The needle is grasped on the left side with the right needle holder and is then pulled with the left needle holder, in a harmonious curve to avoid tearing the tissues. The aspirator, held by the assistant in the right medial 5-mm trocar, is used to retract the left prostatic lobe so that the needle remains visible.

As a safety measure, a double suture is performed by inserting the needle more superficially from right to left to ensure excellent haemostasis (Fig.7). The needle is grasped on the left near the puboprostatic ligament.

The suture is tied with four knots. The tissues are coagulated with bipolar forceps (Vallancien et al., 2002).

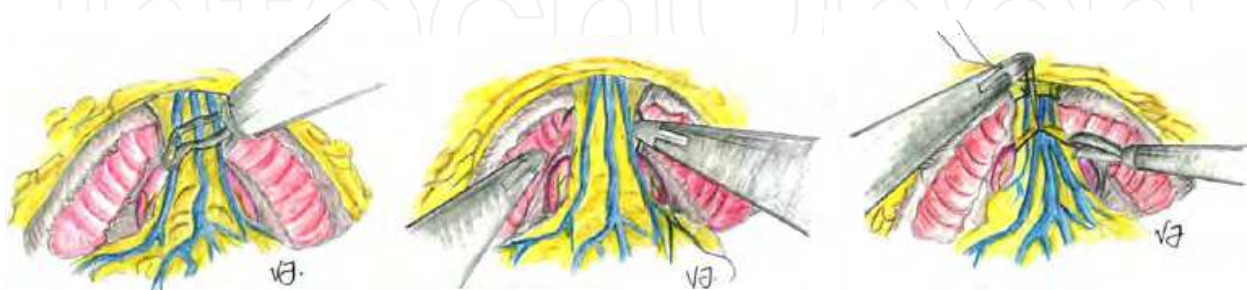


Fig. 7. Dorsal vein complex ligation. The common trunk of the Santorini deep venous plexus and lateral venous plexuses are covered and concealed by the prostatic and endopelvic fascia. Any laceration of these friable structures can lead to considerable blood loss.

4.1.8 Dissection of the apex and section of the urethra

Dissection of the apex starts with retraction of the preprostatic tissues using unipolar scissors. The urethra is reached gradually by incising the frequently thickened tissues covering the anterior surface of the urethra.

Scissors, concave upwards, are used to detach the prostatic apex from preurethral tissues. The Béniqué sound is advanced to make the urethra more prominent. Scissors, concave downwards, are used to retract the apex in order to preserve a maximum of urethra which is incised laterally, avoiding any risk of damage to the left NVB. The same procedure is performed on the right. The posterior surface of the urethra is sectioned at the end. Fibers of the rectourethralis muscle are sectioned, revealing the plane of the rectum. The fibers still attached to the left prostatic lobe are sectioned close to the prostate to avoid damage to the NVB at first on the left and then on the right side. Excessive tension must not be applied to the prostate to prevent rectal injuries. In case of adhesions due to history of prostatitis, multiple biopsies, previous irradiation placing the left index finger in the rectum (finger-assisted laparoscopy) is a practical way to limit the risk of injuries (Vallancien et al., 2002).

4.1.9 Vesicourethral anastomosis

Good-quality needle holders are essential during this procedure. The grip must be powerful and needle holders must be sufficiently long and rigid. The vesicourethral anastomosis requires also an excellent dexterity in the use of needle holders and, especially for a right-hander, the ability to use either the left and the right hand. The suture material must have different qualities such as resistance, no spontaneous loops forming and recognizable colour. During initial experience, the urethrovesical anastomosis is the most time-consuming and challenging part of the operation. However, with experience, suturing is predictable and precise.

Prior to performing urethrovesical anastomosis, bladder neck reconstruction (necessary in only 10–15% of cases) can be performed by placing two to four running stitches posteriorly or anteriorly in a tennis racket fashion. It is important to visualize the position of the ureteral orifices before the closure is initiated to avoid inadvertent passage of the suture through the ureter. The bladder neck is narrowed to approximate the diameter of the urethra (Rosenblatt et al., 2008).

The initial stitch is placed at the 6-o'clock position of the bladder neck and the urethral stump with Lactomer 9-1 3/0 on a 5/8 needle using interrupted suture placed in the same way for all patients. At least three to four needle passes are necessary in a clockwise direction to create an adequate posterior plate.

The first stitch is made from inside to outside on the urethra. The right needle holder is used with a twisted forehand movement (Fig. 8). The needle is passed through the aperture of the Béniqué sound, then introduced into the urethra at 6-o'clock, as the operator gradually withdraws the Béniqué sound with the left hand. The needle is brought out posteriorly near the rectum using the left needle holder, making sure that it has not included the right NVB. The suture must remain strictly in the midline. Movements of needle holders must describe curves to avoid tearing the urethra. The length of suture material is calculated by the length of the 10-/12-mm trocar plus 2 cm. the solidity of this first stitch is verified by pulling on the two ends of the suture, which reveals the urethral lumen. Two sets of forceps are used to grasp the bladder neck, with the mobile jaws facing downwards to enter the posterior lip of the bladder neck. The needle is passed through the bladder, taking care not to include a ureteric orifice by remaining strictly in the midline at 6-o'clock. The bladder is then lowered

towards the urethra. The knot is composed of four loop, the first two of which are formed in the same direction to allow the suture material to slide freely.

The second suture is performed in a similar way: using the Béniqué sound, the needle is passed with the right hand from inside to outside the urethra at 8-o'clock. Once again, in order to be well coordinated, the maneuver must be performed by the operator himself. The operator holds the needle holder in his right hand and the Béniqué sound in his left hand and gradually withdraws it as the needle holder advances into the urethra. The left border of the bladder sometimes needs to be retracted with the aspirator in order to see the needle leave the urethra. These two bridge suture are essential as they ensure the solidity of the posterior plane of the vesicourethral anastomosis. Sutures are cut 5mm from the knots. Both ends of the knots must be cut before extracting the needle to avoid tearing the urethra. The needle must always be removed through the right medial iliac 10 mm trocar by holding the tip of the needle with the right needle holder, otherwise the needle may be trapped at the entry of the trocar and fall into the abdomen from where it will be difficult and time consuming to find.

The third suture is performed to the right of the first suture at 4-o'clock. The needle held in the right needle holder is inserted into the bladder with a forehand movement from outside to inside and the needle is then extracted with the left hand. The needle is kept in the left hand and is inserted into the urethra from inside to outside. The curve made by the left hand with the needle holder can be more accurately guided with the right hand. To facilitate passage of the needle using the left needle holder, the urethra is retracted with the Béniqué sound directed towards the left to open the urethra. By simply rotating the left wrist, the needle enters the urethra atraumatically. The needle is extracted with the right needle holder.

The fourth suture is performed to the left. The needle enters the urethra at 9-o'clock over the Béniqué sound, using the right needle holder, with the needle back to front. The left NVB must be clearly visualized to avoid injury. The suture passes from inside to outside the urethra. After extracting the needle with the left needle holder, it is inserted into the bladder from outside to inside, making sure that the left ureteric orifice is not included. The knot is tied inside with 4 loops. The tension on the two ends of the suture held by the needle holders must be equal to avoid tearing the urethra.

The fifth suture is performed to the right from outside to inside, passing first through the urethra, at 3-o'clock. The position of the needle is unusual: instead of holding the needle, as for the other suture, about 2/3 from the base, the needle is held by the middle with the right needle holder at an angle of about 120°. The needle holder is placed outside the urethra, to the right, and is passed through the urethra horizontally; the Béniqué sound drawn towards the left opens the urethral lumen. The needle is brought out in the urethra and grasped with the left needle holder to complete the curve without tearing the urethra. The needle is then grasped with the left needle holder and inserted into the bladder, from inside to outside, and is then extracted with the right needle holder. Both hands must be used to accompany the passage of the needles without forcing, to avoid tearing the tissues.

The sixth suture is performed on the left, starting from the urethra, starting at 10-o'clock with the needle held by the right needle holder, with the needle tip facing upwards and towards the right. By simply rotating the wrist, the needle enters the urethra to the left. The needle is recovered with the left needle holder. The bladder is then included from outside to inside before tying the knot inside the anastomosis.

The seventh suture is situated anteriorly and enters the urethra from outside to inside at 11-o'clock. The needle is then taken with the right hand and inserted into the bladder from inside to outside. The knot is tied outside the anastomosis.

The eighth suture starts in the bladder on the right. The needle is inserted from outside to inside, using the right needle holder. The needle is then taken with the left needle holder and enters the urethra immediately, at 2-o'clock, from inside to outside. The knot is tied outside the anastomosis.

The other sutures (9-12) run from the urethra to the bladder anteriorly or from the bladder to the urethra independently. The knots are tied outside the anastomosis. If there is a step between the bladder and the urethra, sutures are added from the bladder to the anterior surface of the bladder. This tennis racket reconstruction is easier to perform than a posterior reconstruction at the beginning of creation of the anastomosis.

Before tying the last anterior suture, the Béniqué sound is removed and the bladder catheter is inserted, making sure that it follows the right passage. If the anastomosis has been correctly performed posteriorly, the bladder catheter rarely passes underneath the bladder. The presence of bubbles from the bladder catheter indicates a false passage and the catheter must be replaced using an angled stylet. After completing the vesicourethral anastomosis, the Foley catheter balloon is inflated with 10 ml. The watertightness of the suture is checked by injecting 250 ml of saline without pulling on the Foley (traction on the balloon could mask a leak) (Vallancien et al., 2002).

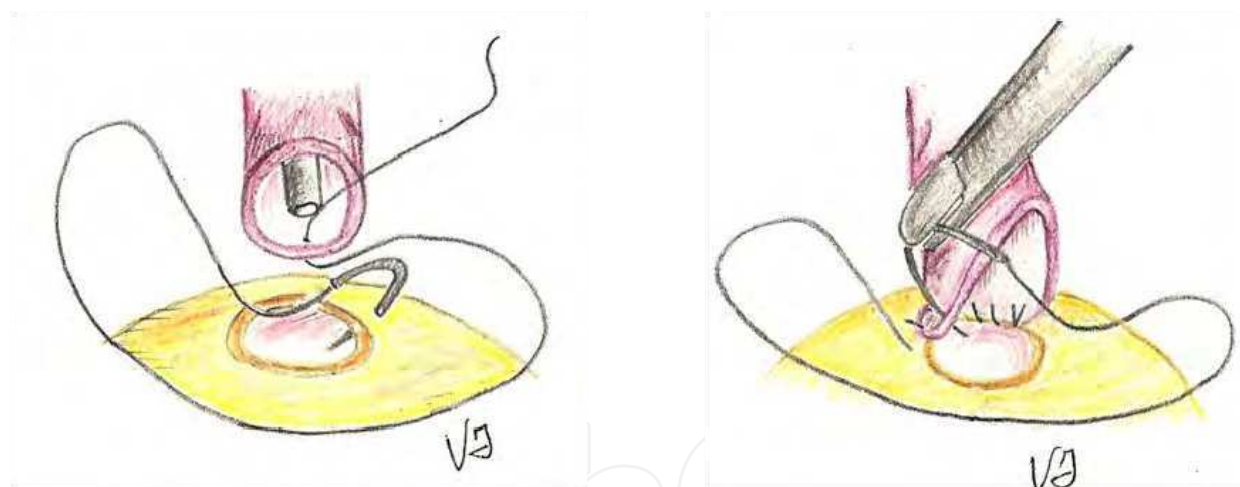


Fig. 8. Vesicourethral anastomosis. The vesicourethral anastomosis requires an excellent dexterity in the use of needle holders and, especially for a right-hander, the ability to use either the left and the right hand.

4.1.10 Extraction of the surgical specimen and closure of the abdomen wall.

Once the vesicourethral anastomosis has been completed, an 8 F suction drain is introduced via the left lateral iliac trocar and is then immediately sutured to the skin after removing the 5-mm trocar. The drain is placed in the pouch of Douglas, which is the most dependent site. It is usually removed on Day 2.

The prostate localized in the right iliac fossa is grasped with forceps inserted via the left medial iliac trocar and transferred to the lesser pelvis where it is placed in an endobag and extracted via the umbilical port.

The scope is therefore transferred to the right medial 10-/12- mm trocar, leaving the umbilical 10-/12-mm trocar free. The umbilical 10-/12-mm trocar orifice is slightly enlarged to allow extraction of the prostate in its bag. The bag is grasped with Kelly forceps and extracted by applying traction and rotation movements. The abdominal wall must be closed meticulously to avoid an incisional hernia. The two angle sutures are inserted before completing the suture by one or two sutures in the midline. Polyglactin 910 1/0 suture material is usually used on a 40 needle (Vallancien et al., 2002).

4.2 Transperitoneal approach

The various steps of the operation are the same as in extraperitoneal prostatectomy, but they are performed in a different order:

1. Patient positioning, insufflation and insertion of trocars
2. Pelvic lymph node dissection
3. Dissection of seminal vesicles and the interprostato-rectal space
4. Dissection of the bladder and lobes of the prostate
5. Opening and mobilization of the bladder
6. Dissection of neurovascular bundles
7. Haemostasis of vessels of retropubic space
8. Dissection of the apex and the section of the urethra
9. Vesicourethral anastomosis
10. Extraction of the prostate and closure of the incision.

The Montsouris technique 1 was described by Guillonnet and Vallancien, in which dissection commences initially at the rectovesical cul-de-sac. The sigmoid colon is retracted cephalad and a transverse peritoneotomy created at the second (distal) peritoneal fold in the rectovesical cul-de-sac.

The seminal vesicles and vas deferens are mobilized circumferentially using bipolar cautery. Denonvilliers' fascia is opened to enter the pre-rectal plane. Subsequently the bladder is dropped posteriorly, the space of Retzius developed, the dorsal vein ligated, the bladder neck transected, and the prostatic pedicles incised while preserving the neurovascular bundle if indicated. The urethra is transected, prostate excision completed and the vesico-urethral anastomosis made (Steinberg & Gill, 2004).

The potential advantages of the transperitoneal laparoscopic radical prostatectomy compared to the extraperitoneal approach are a greater working space and reduced tension on the urethrovesical anastomosis. Furthermore, when performing extended pelvic lymphadenectomy for high-risk prostate cancer patients, the transperitoneal technique is technically less demanding than the extraperitoneal approach (Guillonnet & Rozet, 2002; Türk et al., 2001; Vallancien et al., 2002).

5. Postoperative considerations

The nasogastric tube is removed at the end of the procedure. The patient is given appropriate analgesia as per protocol, including intravenous paracetamol during the first 24 h and major analgesics as necessary. The intravenous perfusion is stopped on day 1 after surgery, oral fluids are started the morning after surgery, and a light diet can generally be resumed on day 2. The suprapubic drain is usually removed after 48–72 h or after secretions are below 50 mL. The bladder catheter is removed on day 5 after surgery if urine is clear, but in case of persistent residual haematuria, a cystogram is performed. Normal activity is resumed four weeks after surgery (Rosenblatt et al., 2008).

6. Intra- and perioperative complications

6.1 Operating time

Lengthy operating times have often been reported for laparoscopic radical prostatectomy. However, times have been shown to decrease with experience. Guillonneau and colleagues reported times of 4.6 hours in their first 50 cases, 4 hours in the next 50, and 3.4 hours in the last 140 cases (Guillonneau & Rozet, 2002).
Currently, our average time ranges from 2 hours to 3 hours.

6.2 Intraoperative blood loss, transfusion rates

High intraoperative blood loss and transfusion rates are common problems of prostate surgery. Reports of open prostatectomy series have reported blood loss of 500 mL, 1 L, or more. During laparoscopy, excellent visualization of the dorsal venous complex and a tamponade effect from the 15-mm Hg pressure of the carbon dioxide pneumoperitoneum minimizes blood loss. The necessity of transfusion varied from 1.6% to 31% among the analyzed series (Bove et al., 2009).

6.3 Conversion to open surgery and other perioperative complications

The rate of conversion from laparoscopic to open surgery remains low (0 to 5%), but some centers had a high conversion rate in their early experience. The low conversion rates in all major series are a testimony to the careful introduction of LRP. With increasing experience, even challenging situations, such as cases following previous laparoscopic hernioplasty can be managed (Bove et al., 2009).
Following the current literature we could deduce that there is a 4% (1-6.1%) of intraoperative complications (rectal injury 1.5% (1-2.4%), ileal or sigmoid injury 1% (0.8-1.9%), epigastric vessels injury 0.27% (0-0.5%), bladder injury 0.81% (0-1.6%), ureteral injury 0.36% (0-0.7%), external iliac vein injury 0.09% (0-0.8%). The early postoperative complications amounted to 20.7% of cases and they mainly included anastomotic leakage (10.3%), hemorrhagic complications (2.8%), urinary retentions (2.35%) and ileus (1.4%). However, anastomotic stricture, phlebitis/embolism/thrombosis, urinary tract infections, neurological complications, fistulas, lymphorrea, trocar hernia accounted for percentages below 1% (Bove et al., 2009). These data are summarized in Table1.

Intra and Postoperative Complications	Percentage
Rectal injury	3,3
Ileus/sub-ileus	2,5
Blood transfusion	2,2
Neurologic lesion	1,8
Bowel injury	0,9
Thrombosis/embolism	0,8
Bladder injury	0,4
Renal failure	0,3
Ureteral injury	0,1
Other	0,6
Total complication rate	12,9

Table 1. Main intra and postoperative complications of laparoscopic radical prostatectomy in late series (Lein et al., 2006).

7. Oncological outcome

7.1 Surgical pathology

Prostate cancer is a multifocal disease with an average of seven distinct cancerous sites within each radical prostatectomy specimen. Any surgical procedure aimed at eradicating prostate cancer must completely remove the prostate gland. Then, the removed prostate tissue must undergo pathologic analysis to determine if the edges of the removed tissue (ie, the “surgical margin”) show evidence of tumor cells or not (Humphreys et al., 2004).

7.2 Surgical margins and cancer control

Generally, a surgical margin is considered positive if tumor cells reach the “inked” boundaries of the prostate specimen on pathologic examination. The risk of cancer recurrence increases significantly with positive surgical margins independent of pathologic grade, PSA, and DNA ploidy for organ-confined disease. Several series have stressed the importance of surgical margin status in the development of postoperative multivariate models to determine patient prognosis ((Bove et al., 2009; Humphreys et al., 2004).

In the most representative series of laparoscopic radical prostatectomy follow-up is not long enough to give a definitive oncologic evaluation of its surgical efficacy. Nevertheless, preliminary data suggest that this approach can guarantee the same results in terms of cancer control as those of open procedures.

No cases of trocar track metastasis or local relapse have so far been reported after LRP. The extraperitoneal approach avoids this potential risk of intraperitoneal dissemination of tumor cells.

Depending on the surgical approach the location of surgical positive margins differs: the apex with the retropubic radical prostatectomy, the bladder neck with the perineal radical prostatectomy, the posterolateral regions of the prostate (that contain the neurovascular bundles and prostatic pedicles) in the LRP (probably because of the instrument axis and its smaller amplitude during dissection of the prostatic pedicles, which are closer to the trocar ports).

As concerns oncologic results of RP, these are evaluated based on the rate of positive surgical margins (that reflect the quality of tumor excision) and survival with no biological progression.

The positive surgical margins, defined as the presence of cancer at the inked margin of resection on the prostatectomy specimen, influence the prognosis, as they determine a higher risk of biochemical, local and systemic progression.

Authors	pT2	pT3	Overall Positive Surgical Margin Rate
Guillonneau et al. (1000 pts)	15.5%	31%	19.2%
Rassweiler et al. (500 pts)	7.4%	31.8%	19%
Stolzenburg et al. (700 pts)	10.8%	31.2%	19.8%

Table 2. Cancer control: positive surgical margin rate.

The results on the positive surgical margin rate are summarized in Table 2. Recent data, suggest a significant decrease of positive surgical margins over time without any evidence of downward stage migration, in both organ-confined and non-organ-confined disease (Bove et al., 2009).

Given the fact that LRP has only been regularly performed since 1998, information about long term follow-up is unavailable. Although the data continue to mature for LRP series, the short-term biochemical-free recurrence results appear similar to those reported in open radical prostatectomy experience with a biochemical recurrence-free probability between 83 and 94.5% at 3 years as shown in Table 3 (Bove et al., 2009).

Declaring “cure” of prostate cancer requires long-term follow-up. Currently available data are still quite immature. Long-term results on biochemical recurrence-free survival are eagerly awaited.

Authors	3-year Biochemical Recurrence-Free Probability	5-year Biochemical Recurrence-Free Probability	Definition of Progression
Montsouris	90.5%	73.1%	PSA > 0.1 ng/mL confirmed by a second increase
Heilbronn	83%		2 PSA values > 0.2 ng/mL
Johns Hopkins	94.5%		2 PSA values > 0.2 ng/mL

Table 3. Progression free (Montsouris refers to Guillonneau et al., 2002; Heilbronn refers to Rassweiler et al., 2001; Johns Hopkins refers to Pavlovich et al, 2008).

8. Functional outcome

8.1 Continence

The issue of continence is a central concern among most patients. The wide range of incontinence rates reported in the literature indicates the difficulty to obtain an accurate assessment of urinary control after radical prostatectomy. Moreover, the lack of a uniform definition of post-operative continence is crucial to this problem. While some studies use a strict definition of continence as a “no pads” condition, others allow the use of 1 precautionary pad per day as determined by patient report (Bove et al., 2009).

LRP seems initially to offer an earlier continence recovery, but the number of continent patients at one year follow up is comparable to that after open radical prostatectomy. In incontinent patients, even the severity of incontinence seems to be similar after the two procedures. Published reports on the rate of urinary continence after radical prostatectomy (RP) vary widely, at 31–92%, and have been shown to depend on the surgeon’s experience, surgical technique (nerve-sparing, bladder neck reconstruction), patient age and, perhaps most significantly, methods of analysis. The physician-determined urinary status after RP can underestimate the problems compared with the results of direct patient-questionnaire surveys (Bove et al., 2009).

Meticulous handling and tissue dissection have allowed the continence rates to improve. Recently Rocco et al. demonstrated that a posterior reconstruction of the rhabdosphincter allowed a rapid recovery of the continence after transperitoneal videolaparoscopic radical prostatectomy. They report that the musculo-fascial plate, comprised of the striated sphincter, Denonvillier’s fascia, and the dorsal aspect of the prostate, acts as a suspensory system for the prostatic-membranous urethra and that its division during RP results in the loss of the posterior cranial insertion of the sphincter, the caudal displacement of the sphincteric complex, and a prolapse of the perineum. Therefore, they propose to reconstruct this musculo-fascial plate by joining the posterior median raphe with the connected dorsal wall of the RS to the residuum of the Denonvillier’s fascia and to suspend it to the posterior wall of the bladder, 1-2 cm cranially and dorsally to the new bladder neck (Rocco et al., 2007).

8.2 Potency

Laparoscopic nerve sparing prostatectomy is performed by dissecting the pedicles in an antegrade fashion. This maneuver releases the neurovascular bundle laterally and allows the dissection of the prostate. The delicate NVB is intimately related to the postero-lateral surface of the prostate. As such, complete avoidance of any thermal or electrical energy during lateral pedicle transection and NVB release comprises a hallmark principle during open surgery. However, the use of conventional dissection with hemostatic suture ligatures did not compromise the erectile response to nerve stimulation. Current laparoscopic and robotic techniques for lateral pedicle transection fall short in this important regard, typically using either monopolar or bipolar electrocautery, or ultrasound energy with the harmonic scalpel, with or without clips. Once postoperative potency is established patients reported ability to achieve sexual intercourse with or without the use of PDE-inhibitors. Potency rates after bilateral nerve sparing LRP have been reported from 33% to 67% in various series worldwide. Most experts agree that at least 18 months of follow-up is necessary to assess potency outcomes adequately (Curto et al., 2006).

Series	Number of BNS	% of Postoperative Potency with or without PDE5-I
Guillonneau et al., 2003	47	66%
Rassweiler et al., 2003	41	67%
Curto et al., 2006	137	58.5%

Table 4. Potency rates (with or without use of PDE5-I) after bilateral nerve sparing (BNS) procedure for patients preoperatively potent.

9. Learning curve: The importance of the mentor

Laparoscopic radical prostatectomy is presently being performed by selected surgical teams with advanced laparoscopic skills. The learning curve is long and steep. Since the surgical technique has now been established, the learning curve should become shorter. Furthermore, as urologists at several centers become proficient at the surgery, colleagues and residents will be trained at the procedure. This can be achieved by an experienced surgeon assisting a novice surgeon.

A learning curve includes the necessity for continuous self-evaluation in terms of cancer control, continence and potency. Many different methods can be used to acquire the technique: dry lab, animal live lab, cadaveric laparoscopic dissection or mentoring with an expert. All of these steps may not be essential, as laparoscopic radical prostatectomy is not too dissimilar to open prostatectomy. The transfer of technology and surgical experience/aptitude is problematic. It has been clearly shown that weekend training courses and weekend laboratory sessions do not translate into clinical ability to perform these procedures. The transfer of training from open surgical experience to newly introduced laparoscopic skills does not occur, emphasizing the need for intensive training (Bove et al., 2009).

These common difficulties clearly highlight the importance of mentoring programs. The mentor is an expert in laparoscopic technique able to direct trainee operative maneuvers increasing his efficiency. Lack of progression is often cited as the most common reason for open conversion during a laparoscopic procedure; in this case the mentor ensures forward progression. The most difficult aspects of this procedure, such as suturing the dorsal vein complex and urethrovesical anastomosis, bladder neck dissection and dissection off of the rectum cannot be effectively learned through laboratory simulation.

We can conclude that an intensive, mentor initiated approach can decrease the learning curve and maintain outcomes (Bove et al., 2009).

10. Cost comparison of LRP versus open radical prostatectomy

Despite the advantages of LRP regarding its minimally invasive character, the operative times for this procedure have been consistently longer than those of retropubic radical prostatectomy and the cost of the disposable operating room equipment is greater, suggesting that LRP is more expensive than RRP. Given the large number of men diagnosed with prostate cancer and presumably seeking treatment, it is desirable that treatment options are not only efficacious but also cost effective (Bove et al., 2009; Humphreys et al., 2004).

11. Conclusions

LRP can be safely performed with early results comparable to open surgery. However, the procedure requires advanced laparoscopic skills and has a steep learning curve. Decreased blood loss during surgery and possibly a shorter duration of convalescence following surgery are definite advantages to the laparoscopic approach. Intracorporeal suturing skills may be developed and refined in the pelvic trainer, to help decrease operating time during early experience.

12. References


- Bollens, R., Vanden Bossche, M., Roumeguere, T., Damoun, A., Ekane, S. & Hoffmann, P. (2001). Extraperitoneal laparoscopic radical prostatectomy. Results after 50 cases. *Eur Urol.* 40, 2001, pp. 65-69.
- Bove, P., Asimakopoulos, A.D., Kim, F.J. & Vespasiani, G. (2009). Laparoscopic Radical Prostatectomy: a Review. *Int Braz J Urol.*, 35, April 2009, pp. 125-139.
- Brown, J.A., Rodin, D., Lee, B. & Dahl, D.M. (2005). Transperitoneal versus extraperitoneal approach to laparoscopic radical prostatectomy: an assessment of 156 cases. *Urology.* 65, 2005, pp. 320-324.
- Cathelineau, X., Cahill, D., Widmer, H., Rozet, F., Baumert, H. & Vallancien, G. (2004). Transperitoneal or extraperitoneal approach for laparoscopic radical prostatectomy: a false debate over a real challenge. *J Urol.* 171, 2004, pp. 714-716.
- Curto, F., Benijts, J., Pansadoro, A., Barmoshe, S., Hoepffner, J.L. & Mugnier C. (2006). Nerve sparing laparoscopic radical prostatectomy: our technique. *Eur Urol.* 49, 2006, pp. 344-352.
- De La Rosette, J.J., Abbou, C.C., Rassweiler, J., Laguna, M.P. & Schulman, C.C. (2002). Laparoscopic radical prostatectomy: a European virus with global potentials. *Arch Esp Urol.* 55, 2002, pp. 603-609.
- Gill, I.S. & Zippe, C.D. (2001). Laparoscopic radical prostatectomy: technique. *Urol Clin North Am.* 28, 2001, pp. 423-436.
- Guillonneau, B., Cathelineau, X., Barret, E., Rozet, F. & Vallancien, G. (1999). Laparoscopic radical prostatectomy: technical and early oncological assessment of 40 operations. *Eur Urol.* 36, 1999, pp. 14-20.
- Guillonneau, B. & Rozet, F. (2002). Perioperative complications of laparoscopic radical prostatectomy: the Montsouris 3-year experience. *J Urol.* 167, 1, 2002 Jan, pp. 51-56.
- Guillonneau, B., Cathelineau, X., Doublet, J.D., Baumert, H. & Vallancien, G. (2003). Laparoscopic radical prostatectomy: assessment after 550 procedures. *Crit Rev Oncol Hematol.* 43, 2002, pp. 123-133.
- Hoznek, A., Menard, Y., Salomon, L. & Abbou, C.C. Update on laparoscopic and robotic radical prostatectomy. *Curr Opin Urol.* 15, 2005, pp. 173-180.
- Humphreys, M.R., Gettman, M.T., Chow, G.K., Zincke, H. & Blute, M.L. (2004). Minimally Invasive Radical Prostatectomy. *Mayo Clin Proc.*, 79, 9, Sept 2004, pp. 1169-1180.
- Landman, J., Venkatesh, R., Vanlangendonck, R. & Andriole, G.L. (2004). Application of a fixed retraction system to facilitate laparoscopic radical prostatectomy. *J Urol.* 171, 2004, pp. 783-785.
- Lein, M., Stibane, I., Mansour, R., Hege, C., Roigas, J. & Wille, A. (2006). Complications, urinary continence, and oncologic outcome of 1000 laparoscopic transperitoneal radical prostatectomies-experience at the Charité Hospital Berlin, Campus Mitte. *Eur Urol.* 50, 2006, pp. 1278-1282; discussion 1283-4.

- Levinson, A.W. & Su, L.M. (2007). Laparoscopic radical prostatectomy: current techniques. *Curr Opin Urol*, 17, 2, (Mar 2007), pp.98-103.
- Pavlovich, C.P., Trock, B.J., Sulman, A., Wagner, A.A., Mettee, L.Z. & Su, L.M. (2008). 3-year actuarial biochemical recurrence-free survival following laparoscopic radical prostatectomy: experience from a tertiary referral center in the United States. *J Urol*. 179, 2008, pp. 917-921; discussion 921-2.
- Raboy, A., Ferzli, G. & Albert, P. (1997). Initial experience with extraperitoneal endoscopic radical retropubic prostatectomy. *Urology*. 50, 1997, pp.849-853.
- Rassweiler, J., Sentker, L., Seemann, O., Hatzinger, M., Stock, C. & Frede, T. (2001). Heilbronn laparoscopic radical prostatectomy. Technique and results after 100 cases. *Eur Urol*. 40, 2001, pp.54-64.
- Rassweiler, J., Seemann, O., Hatzinger, M., Schulze, M. & Frede, T. (2003). Technical evolution of laparoscopic radical prostatectomy after 450 cases. *J Endourol*. 17, 2003, pp. 143-54.
- Rassweiler, J., Hruza, M., Teber, D. & Su, L.M. (2006). Laparoscopic and robotic assisted radical prostatectomy – critical analysis of the results. *Eur Urol*. 49, 2006, pp. 612-624.
- Rocco, F., Carmignani, L., Acquati, P., Gadda, F., Dell’Orto, P. & Rocco, B. (2007). Early continence recovery after open radical prostatectomy with restoration of the posterior aspect of the rhabdosphincter. *Eur Urol*. 52, 2007, pp. 376-383.
- Rosenblatt, A., Bollens, R. & Espinoza Cohen, B. (2008). Extraperitoneal laparoscopic radical prostatectomy, In: *Manual of Laparoscopic Urology*, Springer-Verlag, ISBN 978-3-540-74726-0, Berlin Heidelberg, pp. 63-89.
- Schuessler, W.W., Kavoussi, L.R., Clayman, R.V. & Vancaille, T. (1992). Laparoscopic radical prostatectomy: initial case report. *J Urol*. 147, 1992, pp. 147: 246A, Abstract no. 130.
- Schuessler, W.W., Schulam, P.G., Clayman, R.V. & Kavoussi, L.R. (1997). Laparoscopic radical prostatectomy: initial short-term experience. *Urology*. 50, 1997, pp. 854-857.
- Steinberg, A.P. & Gill, I.S. (2004). Laparoscopic prostatectomy: A promising option in the treatment of prostate cancer. *Cleveland Clinic Journal of Medicine*. 71, 2, 2004, pp. 113-121.
- Stolzenburg, J.U., Rabenalt, R., Ho, K., Dorschner, W. & Waldkirch, E. (2005). Endoscopic extraperitoneal radical prostatectomy: oncological and functional results after 700 procedures. *J Urol*. 174, 2005, pp. 1271-5; discussion 1275.
- Türk, I., Deger, S., Winkelmann, B., Schönberger, B. & Loening, S.A. (2001). Laparoscopic radical prostatectomy. Technical aspects and experience with 125 cases. *Eur Urol*. 40, 2001, pp. 46-52; discussion 53.
- Vallancien, G. & Guillonnet, B. (2002). *Laparoscopic Radical Prostatectomy*, Ecole Européenne de Chirurgie Collection, ISBN 2-913487-10-6, Paris, France.

Walsh, P.C. (2000). Radical prostatectomy for localized prostate cancer provides durable cancer control with excellent quality of life: a structured debate. *J Urol.* 163, 2000, pp. 1802-1807.

IntechOpen

IntechOpen



Laparoscopy - An Interdisciplinary Approach

Edited by Dr. Ivo Meinhold-Heerlein

ISBN 978-953-307-299-9

Hard cover, 146 pages

Publisher InTech

Published online 12, September, 2011

Published in print edition September, 2011

Over the last decades an enormous amount of technical advances was achieved in the field of laparoscopy. Many surgeons with surgical, urological, or gynaecological background have contributed to the improvement of this surgical approach which today has an important and fixed place in the daily routine. It is therefore comprehensible to compose a book entitled laparoscopy serving as a reference book for all three disciplines. Experts of each field have written informative chapters which give practical information about certain procedures, indication of surgery, complications and postoperative outcome. Wherever necessary, the appropriate chapter is illustrated by drawings or photographs. This book is advisable for both beginner and advanced surgeon and should find its place in the libraries of all specialties – surgery, urology, and gynecology.

How to reference

In order to correctly reference this scholarly work, feel free to copy and paste the following:

Pierluigi Bove and Valerio Iacovelli (2011). Laparoscopic Radical Prostatectomy, Laparoscopy - An Interdisciplinary Approach, Dr. Ivo Meinhold-Heerlein (Ed.), ISBN: 978-953-307-299-9, InTech, Available from: <http://www.intechopen.com/books/laparoscopy-an-interdisciplinary-approach/laparoscopic-radical-prostatectomy>

INTECH
open science | open minds

InTech Europe

University Campus STeP Ri
Slavka Krautzeka 83/A
51000 Rijeka, Croatia
Phone: +385 (51) 770 447
Fax: +385 (51) 686 166
www.intechopen.com

InTech China

Unit 405, Office Block, Hotel Equatorial Shanghai
No.65, Yan An Road (West), Shanghai, 200040, China
中国上海市延安西路65号上海国际贵都大饭店办公楼405单元
Phone: +86-21-62489820
Fax: +86-21-62489821

© 2011 The Author(s). Licensee IntechOpen. This chapter is distributed under the terms of the [Creative Commons Attribution-NonCommercial-ShareAlike-3.0 License](https://creativecommons.org/licenses/by-nc-sa/3.0/), which permits use, distribution and reproduction for non-commercial purposes, provided the original is properly cited and derivative works building on this content are distributed under the same license.

IntechOpen

IntechOpen