

We are IntechOpen, the world's leading publisher of Open Access books Built by scientists, for scientists

6,900

Open access books available

185,000

International authors and editors

200M

Downloads

Our authors are among the

154

Countries delivered to

TOP 1%

most cited scientists

12.2%

Contributors from top 500 universities



WEB OF SCIENCE™

Selection of our books indexed in the Book Citation Index
in Web of Science™ Core Collection (BKCI)

Interested in publishing with us?
Contact book.department@intechopen.com

Numbers displayed above are based on latest data collected.
For more information visit www.intechopen.com



Abdominal Aortic Graft Infection

Dimitrios Tsapralis, Anestis Charalampopoulos and Andreas M. Lazaris
*Attikon Teaching Hospital, University of Athens
 Greece*

1. Introduction

Despite the advances in operative techniques and perioperative management of patients suffering from abdominal aortic aneurysms (AAAs) or occlusive aorto-iliac disease, there are many early and late complications related to aortic graft insertion, either in open or endovascular approach, that every vascular surgeon should bear in mind. One of the most dreaded complication is the infection of prosthetic aortic grafts which continues to be problematic despite improvements in biomaterials and fabrication of prosthetics, refinements in implantation techniques, and better understanding of the pathogenesis of graft infections.

This article reviews the epidemiology, pathogenesis, diagnosis, and current state-of -the art management of prosthetic aortic graft infections.

1.1 Incidence and risk factors

The overall incidence of aortic graft infection has probably changed little in the past two decades despite an improved understanding of graft infections and more specified efforts at prevention (Perera et al., 2006). The true incidence of graft infections is difficult to establish and depends on how one defines the problem (graft infection or graft exposure in a nonhealing wound), the graft material (autogenous vein, Dacron, polytetrafluoroethylene [PTFE]), the duration of follow-up, and other factors (Chiesa et al., 2002; Perera et al., 2006). However, most recent series document an incidence ranging from just under 1% to as high as 6%, with an overall incidence of approximately 4% (Bisdas et al., 2010; FitzGerald et al., 2005). It is estimated that the cost of caring for a patient with an infected vascular graft currently averages \$40,000 (Ali et al., 2009).

Both patient variables and technical factors predispose to the development of vascular graft infections. Patient factors include disease processes such as diabetes mellitus, obesity, uremia, malnutrition, and immunosuppressive states (Yeager et al., 1992). Ulceration or infection in an extremity distal to a graft and emergency procedures are also known to increase infectious risks (Perera et al., 2006). Wound healing complications, such as cellulitis, seroma, lymphocele, hematoma, or skin necrosis, further contribute to graft infections (Gutowski, 1998). Reoperation in the early postoperative period for thrombosis or bleeding is an additional predisposing factor. Special emphasis should be placed to the higher incidence of infection accompanied the implementation of aortofemoral bypass grafts compared to aortoiliac grafts, since the groin area is frequently contaminated and prone to wound complications (Yeager et al., 1992).

1.2 Pathogenesis

The vast majority of prosthetic aortic graft infections occur as a result of bacterial contamination of the perigraft space around the time of original graft placement. Under these circumstances, endogenous skin flora constitutes the causative organisms of such infections. Most patients who undergo arterial revascularization or aneurysm repair have significant numbers of mucin-producing coagulase-negative staphylococci on their skin, and at least 15% have methicillin-resistant (MRSA) strains preoperatively (Kieffer et al., 2001). Incomplete sterilization of instruments or grafts rarely does play a role in the incidence of aortic graft infections, but breaks in sterile technique, particularly during emergency procedures, are more common (Valentine, 2001). Graft seeding by bacteria from transected lymphatics in the presence of distal extremity infections may be important. Moreover, microorganisms from the native arterial thrombus or arteriosclerotic plaque may contaminate grafts. Careful culturing of the arterial wall during elective procedures demonstrates the presence of microorganisms in about 40% of specimens (Farkas et al., 1993; Hsu et al., 2004). Other studies suggest that aortic graft infections increase from 2% to approximately 10% if arterial wall cultures are positive, but some authors have concluded that bacteria in aneurysm contents is not linked to subsequent graft infections (Macbeth et al., 1984). Concomitant contaminated procedures increase the likelihood of prosthetic infection and should be avoided whenever possible. Lengthy procedures and those with larger blood loss are associated with higher infection rates (Yeager et al., 1992).

Irrespective of the origin or the type of offending microorganism, the pathogenetic mechanism of the ensuing infection represents a common denominator. During the early postoperative period, the fluid filled (blood, serum, lymph) perigraft environment is poorly perfused and relatively isolated from the natural host defenses (Chiesa et al., 2002). These poorly vascularized, perigraft fluid collections serve as a receptive medium for bacteria, enabling their survival and proliferation. Any early contamination of the perigraft space with even low numbers of bacteria, can lead to eventual prosthetic graft infection. Without early contamination, however, the prosthetic material becomes incorporated into surrounding, vascularized tissues, which functionally obliterates the perigraft space and, after several months, appears to render the graft more resistant to infection.

As described below in the section of clinical presentation, the prosthetic vascular graft infections are classified as early or late depending on presentation before or after four months from the time of surgical implantation. Even when considering the pathogenesis of late graft infections, the majority of them are caused by graft contamination at the time of implantation with indolent disease progression, in a manner identical to that mentioned previously in detail. Nevertheless, other mechanisms unique in this subgroup of patients with late presentation, comprise transient bacteremia and mechanical erosion of the graft into surrounding tissues (Kibria et al., 2010; Lazaris et al., 2009). Erosion into the urinary or gastrointestinal tracts or through the skin occurs in 1% to 3% of patients. Graft-enteric fistula complicates 0,6% to 2,3% of cases of aortic graft placement (Koshy et al., 2010). Transient bacteremia is presumed to be an occasional mechanism for late graft infections.

1.3 Microbiology

Staphylococcus species are the most common causative organism of aortic graft infections (Kaebnick et al., 1987; Sharp et al., 1994). This fact is consistent with our understanding that the pathogenesis of prosthetic graft infection is related to bacterial contamination at the time

of graft placement. *Staphylococcus epidermidis* is the slow-growing, slim-producing organism classically causing late, indolent graft infection. The more virulent *Staphylococcus aureus* typically causes early graft infection and frequently is associated with overt signs of sepsis. It is estimated that *Staphylococcus aureus* accounts for approximately 25% to 50% of graft infections (FitzGerald et al., 2005). Methicillin-resistant (MRSA) strains of *Staphylococcus aureus* are increasingly common in early infections, and gram-negative bacilli, such as *Enterobacter*, *Klebsiella*, *Escherichia coli*, *Proteus*, and *Pseudomonas*, have also been slowly increasing in frequency (Kitamura et al., 2005).

For all organisms, bacterial adherence to the prosthetic graft is the initial event in the process of graft infection. Adherence is dependent on physical characteristics of the graft, such as pore size and surface area, and upon chemical properties, such as hydrophobicity (O'Brien & Colin, 1992). The production of an extracellular glycocalyx (mucin, slime) by staphylococci promotes adherence to biomaterials and provides protection against host defenses. This biofilm decreases antibiotic penetration and impairs phagocyte and antibody functions but will stimulate a chronic inflammatory process around an infected prosthesis. Organisms that produce a biofilm are more difficult to culture from an infected graft. Proteases produced by gram-negative organisms contribute to the higher rates of vessel wall necrosis, anastomotic disruption, and pseudoaneurysm formation with infection from these bacteria (Kitamura et al., 2005; O'Brien & Colin, 1992). Finally, it is important for every vascular surgeon to bear in mind that, in contrast to primary aortic infections, *Salmonella* almost never is the causative organism for prosthetic graft infection.

1.4 Prevention

As indicated above, the preponderance of evidence suggests that in the majority of cases bacterial seeding of the conduit at the time of implantation leads the way to the development of postoperative graft infection whenever such an infection manifests. Based on this observation, it seems safe to conclude that careful observation of fundamental principles of patient management during that critical perioperative period can minimize the incidence of this detrimental complication. At first, prophylactic antibiotics should be administered intravenously before the skin incision. Although there is no compelling evidence that antibiotic use prevents frank infection, there is good evidence that the incidence of surgical site infection is reduced, and wound infection is an important contributor to graft infection in many cases (Kayser et al., 1978). The duration of antibiotic therapy postoperatively is controversial. Although there is no strong support for such policy, it is reasonable to continue antibiotics for 24 hours postoperatively (Barie & Eachempati, 2005). Because skin flora is an important source of graft contamination, the operative field should be widely cleansed with povidone-iodine solution, and ischemic or ulcerative lesions in the limbs should be isolated (Barie & Eachempati, 2005; Mangram et al., 1999). Lymphatics are another potential route of infection, and thus lymphatic tissue should be ligated and sharply divided. Last, the duration of hospitalization during the primary aortic graft insertion might interfere with the development of a graft infection at a later stage. Patients who are hospitalized for a prolonged time before operative intervention undergo an alteration in their microbial flora and may be at an increased risk of developing graft infection secondary to colonization with resistant organism (Angle et al., 2002).

Thorough investigation has been centered for many years around the potential benefit of antibiotic-bonded Dacron and PTFE grafts to resist infection (O'Connor et al., 2006; Wilson,

2001). Most work has focused on rifampin-bonded grafts, which have been shown to elute the antibiotic at the implantation site for only a few days, possibly limiting their efficacy in this regard (Bandyk et al., 2001). Although there is some evidence that they are effective against *Staphylococcus epidermidis* and *Staphylococcus aureus*, they may have more limited efficacy against gram-negative organisms and MRSA *Staphylococcus* species.

1.5 Clinical presentation and classification

Patients with aortic prosthetic graft infection may present early (within 4 months) or late (after 4 months) following original graft placement (Orton et al., 2000). Szilagyi classified early infections of vascular prostheses into three grades according to the depth of wound involvement as assessed by clinical observation and wound exploration (Szilagyi et al., 1972). Grade I infections involve only the skin (cellulitis); Grade II involve the subcutaneous tissue; and Grade III involve the prosthesis. Samson has modified the widely used classification system of extracavitary vascular graft infections established by Szilagyi (Samson, 1988). These modifications allow for more precise prognostication and directed treatment. Early graft infections, presented within the first 4 months after implantation, are typically caused by *Staphylococcus aureus* and gram-negative bacilli, and are accompanied by systemic signs of infection, including malaise, fever, and leukocytosis. Wound infections, anastomotic disruptions with bleeding, and tender groin masses are also common presenting signs (Valentine, 2001). Graft thrombosis, physical evidence of pseudoaneurysm, and distal embolization may also occur. Acute infection of intraabdominal aortic graft is rare but should be suspected when fever, leukocytosis, persistent adynamic ileus, and abdominal tenderness are present in the perioperative period without other evident etiologies.

Most aortic graft infections relate to aortobifemoral grafts and involve one or both the inguinal regions. In such cases the manifestation of infection is often obvious and consists in development of erythema overlying the graft, a palpable fluid collection, a draining sinus tract, or a pseudoaneurysm. The presence of any of the above signs revealed during physical examination should be assumed to be indicative of graft infection (Bandyk & Esses, 1994).

Conversely, the presentation of late-onset infections (presented after the first 4 months after implantation) tends to be subtle, without any specific signs or symptoms. Absence of fever is not uncommon. These patients are more likely to present with complications of aortic graft infection, such as pseudoaneurysm, sepsis or gastrointestinal bleeding as a result of erosion of the graft into the gastrointestinal tract, and hydronephrosis (Bandyk & Esses, 1994). Aortoenteric fistula may involve any segment of the large or small bowel, but the third and fourth portions of duodenum are the most common sites. In some instances, the anastomosis between the graft and the aorta remains intact, and erosion of the intact graft into the intestine causes mucosal bleeding. Alternatively, the anastomosis may communicate directly with the intestinal lumen, as a result of a pseudoaneurysm. A "herald bleed" from mucosal erosion usually precedes massive gastrointestinal bleeding from an established aortoenteric fistula (Montgomery & Wilson, 1996).

1.6 Diagnosis

The diagnosis of aortic graft infections is usually made on the ground of clinical findings, supported by radiological and microbiological investigations (FitzGerald et al., 2005). When a vascular surgeon raises the possibility of prosthetic graft infection, there are numerous modalities in his/her armamentarium that he/she has to recourse to in order to confirm or

exclude that possibility. Unfortunately, under some circumstances, no laboratory or imaging modality can completely exclude the likelihood of aortic graft infection, and operative exploration is necessary to establish its diagnosis. In cases when signs of infection are evident in the inguinal region, duplex ultrasonography is often considered the best initial screening test. Features such as perigraft fluid or anastomotic pseudoaneurysm found at ultrasound, represent supportive evidence to the clinical suspicion. In addition, duplex ultrasound evaluates the patency of peripheral vessels of the afflicted extremity, playing a central role in drawing a potential surgical plan (Calligaro & Feith, 1991). It is of less benefit for diagnosis of intraabdominal graft infections due to the deep location of such grafts and the difficulty in discrimination of subtle findings.

Computed tomography (CT) scan is the most commonly performed study and the standard against which all other imaging modalities are compared (Mark et al., 1982). Both intravenous and oral contrast media are necessary to identify the graft lumen and the relationship of the prosthesis to adjacent structures (FitzGerald et al., 2005). CT scan has sensitivity more than 95% and specificity in the range of 85% when the criteria of perigraft fluid, perigraft soft tissue attenuation, ectopic gas, pseudoaneurysm, or focal bowel wall thickening are used (Balink & Reijnen, 2007). Importantly, CT scan provides an assessment of the entire graft in contrast to duplex ultrasound as mentioned before. In the early postoperative period, it may be difficult to distinguish graft infection from normal postoperative changes even with CT scan. Perigraft air is not common beyond 1 week after operation, but it is not pathognomonic of graft infection until 4-7 weeks after surgery (Qvarfordt et al., 1985; Soetevent et al., 2004). Similarly, perigraft fluid that persists beyond 4 months postoperatively is highly suspicious for the presence of infection (Qvarfordt et al., 1985). In the initial 4 months after surgery, perigraft fluid may be present without infection, and CT-guided aspiration may assist with definitive diagnosis when clinical circumstances raise such a possibility.

Magnetic resonance imaging (MRI) has a somewhat higher accuracy for diagnosis of intraabdominal graft infections than CT scan because of its superiority for discrimination of tissue planes, particularly in the retroperitoneum (Olofsson et al., 1988). Hence, it is quite sensitive in the detection of small amounts of perigraft fluid, but differentiation between gas in the perigraft space and calcifications in the native arterial wall may be difficult (FitzGerald et al., 2005). Owing to signal characteristics on T-1 and T-2 weighted images, MRI permits differentiation of perigraft fluid and inflammatory changes of surrounding structures from acute and chronic hematoma. However, MRI does not allow distinction between the various types of nonhemorrhagic fluid (infected vs. sterile) (Olofsson et al., 1988). Compared with CT, reconstruction of multiple tissue planes is more easily performed, and nephrotoxicity from intravenous agents may be avoided. In conclusion, because of its wide availability, lower cost, and high sensitivity and specificity, CT scan should be considered the standard reference among imaging modalities for the diagnosis of aortic graft infection. Even when graft infection manifests in the groin and documented with the use of duplex ultrasound, it is imperative to complement the work-up of the patient with CT in order to stage accurately the extent of infection and plan the surgical or conservative management.

Radioisotope scans with labeled leukocytes or immunoglobulin (indium or gallium) may confirm the presence of infection and outline its extent. Indium is considered more accurate than gallium due to higher background levels caused by nonspecific intestinal uptake of

gallium (Mark et al, 1985). Accuracy rates for indium-labeled leukocyte scans are reported to be 90% to 100% in most studies, but both false-positive and false-negative results may occur. False-positive studies are more common in the first 3-4 months postoperatively, when there is normal inflammation in perigraft region. Correlation of positive findings with anatomic results from CT or MRI scans is useful to minimize false-positive scans. Several modifications of radioisotopic labeling techniques have been used and claimed to supplant CT scan as the first line in the diagnosis of aortic graft infections, but none have achieved this goal despite their promising initial results (Delgado et al., 1999; Mark et al., 1985; Palestro et al., 2001).

Compared with other anatomic imaging studies, arteriography is of limited value for the diagnosis of vascular graft infections because of false-negative results when native vessels are not involved in the infectious process. Arteriography is of assistance when planning reoperation for aortic graft infection because of its assessment of proximal and distal circulations and characterization of graft anastomosis. However, CT angiography or MR angiography have been predominated over arteriography, even in operation planning.

Sinography may demonstrate communication with the prosthetic graft and, thus, definitely confirms the diagnosis. However, a negative study does not preclude the presence of infection.

Gastrointestinal endoscopy should be considered in any patient with a possible gastrointestinal bleeding source after aortic bypass grafting. Endoscopists should be aware that aortoenteric fistula most often occurs in the distal portions of duodenum. The absence of bleeding from other gastrointestinal (GI) sources should prompt a high level of suspicion for the presence of an aortoenteric fistula, even if there is not clear visualization of the graft or ulceration in the duodenum. When other GI sources of bleeding are excluded, surgical exploration and inspection of the duodenum and aortic graft may be the only method to confirm or exclude aortoenteric fistula before the hemodynamic decompensation of the patient takes place.

Apart from imaging modalities, blood cultures have an integral part in the evaluation of such patients, as they guide the antibiotic coverage, either in the form of preoperative preparation of the patient, or in the context of conservative management with preservation of the infected graft.

1.7 Treatment

1.7.1 Goals

In dealing with an infected vascular aortic graft, the primary goal of treatment is to save life and limb. This can be achieved by initial and long-term eradication of the local and systemic septic process and maintenance of normal arterial perfusion to involved tissues. Secondary goals are to minimize morbidity, to restore normal function, and to maintain long-term function without the need for repeated intervention or amputation.

1.7.2 Principles of management

Bunt (Bunt, 2001) has elegantly described 4 principles of management for vascular graft infections. First, excision of the graft as a foreign body potentiating infection. Second, wide and complete debridement of devitalized and infected tissue to provide a clean wound in which healing can occur. Third, establishment of vascular flow to the distal bed. Fourth, institution of intensive and prolonged antibiotic coverage to reduce sepsis and prevent secondary graft infection.

The gold standard for treatment of an infected prosthetic aortic graft remains explantation of the graft and reperfusion of the area by placement of a new graft through an extra-anatomic uninfected route. However, recently it has been recognized that the bacterial characteristics of early versus late abdominal graft infections differ (early graft infections generally associated with more virulent organisms whereas late graft infections with less virulent organisms). Similarly to pathogen factors (type of microorganisms, virulence), the extent of graft infection, and antibiotic susceptibility guide appropriate operative selection. This has led to a plethora of alternative operative and antimicrobial strategies. Route of reconstruction (in situ versus extra-anatomic), timing and sequence of the procedures, type of bypass conduit, and manner of excision (partial versus complete) remain under controversy. Recently, endovascular options have been proposed, enriching the armamentarium of available treatment options, but also complicating the proper decision algorithm. The lack of sufficient Level I evidence data, allow occasionally an ad hoc choice of the proper treatment in each case (Perera et al., 2006).

With few exceptions, the treatment of aortic graft infection is surgical. Definitely, patient hemodynamic stability and antibiotic coverage are essential. Patients with hemodynamic instability secondary to hemorrhage from aortoenteric fistula or ruptured pseudoaneurysms require immediate resuscitation and operation. Limited efforts using the dogma of hypotensive haemostasis in order to stabilize the patient and allow further evaluation and planning may be appropriate. The patient's condition and ability to tolerate a definitive procedure as an emergency must be weighed against the option of a limited initial procedure and subsequent definitive management (staged operation).

1.7.2.1 Antibiotics

When prosthetic graft infection is suspected, empiric agents should be selected based on the presumed organism and expected sensitivities and initiated after appropriate cultures have been taken. For example, an early infection should be treated with agents active against methicillin-resistant staphylococci and gram-negative bacilli. Late infections that are presumed to be caused by coagulase negative staphylococci are treated with vancomycin, with or without rifampin (Perera et al., 2006). Antibiotics should be adjusted once the etiologic microorganism and its sensitivity have been identified. The length of antibiotic coverage is controversial, and recommendations are for a minimum of 2 to 4 weeks of parenteral antibiotics (Perera et al., 2006). Oral antibiotics are typically administered for an additional 1 to 6 months period, but some authors have recommended lifetime administration in cases when preservation of the potentially infected graft is warranted (Barrie & Eachempati, 2005).

There is no consensus on which agents are preferred for initial empiric therapy before adjustments can be made based on culture results. The British Society of Antimicrobial Chemotherapy (BSAC) Steering Group on the treatment of hospital infections has recommended treatment with cefuroxime and metronidazole, with or without amoxicillin, as suitable empirical therapy for early-onset prosthetic vascular graft infections. Ciprofloxacin and clindamycin should be considered as second line treatment in penicillin-allergic patients. However, as *S. aureus* is the organism most likely to be isolated in early-onset infections and, as methicillin resistance is increasingly common, empirical treatment should include a glycopeptides according to regional epidemiologic data (Darouiche, 1994). With regard to late-onset infections, guidelines recommend that antibiotic treatment be deferred until the infective etiology has been confirmed, except in the critically ill (.

1.7.2.2 Surgery

Successful surgical treatment of aortic graft infection requires balancing strict adherence to the principles of managing the problem while trying to predict a patients' ability to withstand the proposed operation. Operative strategies include graft excision without revascularization, graft excision with extra-anatomic bypass procedures, and graft excision with in situ reconstruction using a prosthetic conduit, allograft, or autogenous tissue.

The extent of graft involvement should guide the extent and type of the operation, and, thus, should be scrutinized thoroughly. Limited infections may be treated by excision of the involved segment and preservation of the uninvolved, well-incorporated graft. Because graft infection may be more extensive at operation than indicated by preoperative studies, the surgeon should be prepared to change his/her plan according to the intraoperative findings.

As there is no evidence-based support for the efficacy, safety, and appropriateness of the graft salvage approach in the routine management of patients with aortic graft infections, and details of its outcomes come from case reports and series only, the explantation of the graft and vascular reconstruction is still considered the *sine qua non* for these patients to be cured. All of the reconstructive options are valid and appropriate depending upon patient characteristics, extent and virulence of infection, and severity of underlying vascular disease. It is a mistake to think that a single surgical approach is applicable to all patients with this condition. Knowing the pros and cons of each procedure, the vascular surgeon can tailor the surgical plan to the individualized requirements, and achieve the best outcome possible in each case.

1.7.3 Restoring perfusion in lower limbs

a. No revascularization

Graft excision without revascularization is associated with a 33-36% amputation rate and is rarely performed today (Bunt, 2001). It is usually reserved for patients with aortic graft infections with known thrombosed grafts but yet viable extremities. Often, the original indication for graft placement, as well as whether the graft was placed in an end-to-end or end-to-side manner is a crucial factor in determining the need for distal revascularization. The degree of limb ischemia and presence of collateral circulation are the most important aspects of selecting this option. For example, patients having grafts placed for occlusive disease with rest pain or tissue loss are more likely to need a bypass to restore blood to the distal bed. On the contrary, patients that had an aortic graft implantation for purely aneurysmal disease or claudication may not necessarily require a lower limbs revascularization procedure. Also, grafts having end-to-side configuration are more likely to have native collateral circulation still intact, thus being less likely to require a lower extremity revascularization.

b. Extra-anatomic bypass

Extra-anatomic bypass is a good option for the treatment of an infected aortic graft when groin infection is absent and lower extremity run-off is good. For instance, extra-anatomic bypass would be an excellent choice in a patient with an infected aortoiliac graft. The mortality and morbidity of this approach has decreased significantly since evidence supported preceding graft excision with extra-anatomic bypass rather than exploration and resection of the graft as the initial step. This reduces the duration of peripheral ischemia, operative blood loss, and attendant complications. One can stage the procedure by one or

several days, especially in critically ill patients that require stabilization (Seeger et al., 2000). In the stable and good risk patient, we favor proceeding with graft excision under the same anesthetic, although there is only little evidence that the new extra-anatomic graft will experience thrombosis or become secondarily infected during the interval (Landry et al., 2000). Conversely, in patients who are bleeding the initial step should be exploration and removal of the infected graft.

In cases that involve groin infection due to prior aortofemoral bypass graft, the extra-anatomic reconstruction involves constructing the new femoral anastomosis to the profunda femoral artery (or superficial femoral artery) beyond the inguinal region through a lateral incision distal to the original femoral anastomosis. In these cases the PTFE axillofemoral graft is routed lateral to the anterior superior iliac spine circumventing the infected, original femoral incision. It should be emphasized that the aortic suture line, during aortic graft explantation, must be excised back to viable aortic tissue and oversewn in two layers with propylene suture, using omentum or prevertebral fascia to support the suture line. If necessary, one or both renal arteries may be sacrificed to obtain a satisfactory aortic stump closure, and splenorenal or hepatorenal bypass (or both) is carried out as needed. The periaortic tissue should be cultured and aggressively debrided.

The advantages of extra-anatomic bypass are that they may be physiologically less stressful to the patient, especially in the context of staged approach, they are technically straightforward, and there is minimal lower extremity ischemic time (Lehnert et al., 1993). The disadvantages consist in poor patency (about 60% at 5 years), especially in patients with multilevel occlusive disease, a 10% to 20% reinfection rate, that often proves fatal, the potential of aortic stump blow out, the high long-term amputation rate, estimated in the range of 30%, and the need for lifelong antithrombotic therapy (Lehnert et al., 1993; Mussa et al., 2007). Reinfection of extra-anatomic bypass following removal of an infected aortic prosthesis is a limb- and life-threatening problem about which little is known (Gordon et al., 1999). There are few options left other than to try to construct a new extra-anatomic bypass through uninfected tissues. This is usually not feasible, especially when distal, femoral anastomotic sites are involved with infection. Gorgon et al, has performed in situ femoral-popliteal vein reconstruction along with removal of the infected extra-anatomic bypass with satisfactory results (Gordon et al., 1999).

c. In-situ reconstruction

Because of persistent problems with durability and patency, as well as the other aforementioned complications, many authors have advocated the use of in situ reconstructions (Bandyk et al., 2001; Clagett et al., 1997; Noel et al., 2002). In situ arterial allografts were used extensively for infrarenal aortic replacement during the first decade of aortic surgery, but they were abandoned in the early 1960's due to difficulties in procurement and preservation, late degeneration, and availability of suitable aortic prosthetic grafts (DeBakey & Creech, 1954; Oudot & Beaconsfield, 1953). Allograft replacement, compared with the conventional method of graft excision and axillofemoral bypass, has the advantages of being expedient, associated with lower amputation rates (on the average 2%), and averting complications such as aortic stump blow out and reinfection or occlusion events (Verhelst et al., 2000). It also enables surgical reconstruction of hypogastric and deep femoral arteries, as indicated, thereby preventing the development of postoperative ischemic colitis or lower limb ischemia. However, mixed results have been reported regarding the efficacy of in situ replacement of infected aortic grafts with arterial

homografts (Vogt et al., 1996). In one report, a 20% mortality was associated with this method of treatment (Speziale et al., 1997). Aortic allografts are also subject to long-term complications such as aneurysmal dilation, late allograft rupture, and thrombosis (Brown et al., 2009). Reinfection of allografts, although lower than in extra-anatomic bypass grafting, may also occur and usually proves fatal. Currently, aortic allografts are available only on a limited basis. Their shortage diminishes their use in situations where they may be most useful, namely in patients who are unstable, for example, those with actively bleeding aortoenteric fistula.

The same advantages and disadvantages accompany the use of antibiotic-treated prosthetic grafts. Their placement is expedient and technically straightforward, thus rendering them a reasonable option in critically ill, unstable patients. Moreover, they leave no aortic stump and are associated with relatively low amputation rate (Batt et al., 2003). We do not use in situ replacement with antibiotic-coated prosthetic grafts as the reported results are very poor, except in the replacement of one limb of an aortic graft infected with *Staphylococcus epidermitis* (Young et al., 1999). We have occasionally used such grafts in the initial temporizing treatment of aortoenteric fistula, thereby converting an unstable patient into a more stable with an infected aortic graft needing further treatment. Typically, the new prosthetic graft is soaked in rifampin, 60mg/ml, for 15 minutes before implantation (Walker et al., 1987). However, the reinfection rate is high and unpredictable, and patients must undergo lifelong antibiotic therapy.

d. Neo-aortoiliac bypass procedures

Because of the limitations of the other procedures, the use of in situ autogenous venous reconstruction technique, also termed neoaortoiliac system or NAIS procedure, has known great advocacy since its first description by Clagett in 1993 (Clagett et al., 1993). We should give credit to Erenfield who introduced first the concept of autogenous replacement of infected aortic grafts but it was Clagett's introduction of the graft constructed of femoral popliteal veins that made the routine use of this method feasible. Early attempts that made use of greater saphenous vein grafts proved unsuccessful because the small caliber of the venous conduit resulted in low patency rates. Subsequent attempts using larger-caliber femoropopliteal (FPV) vein grafts, proved highly successful. FPV grafts have excellent long-term patency and are resistant to reinfection. Moreover, they are ideal conduits for patients with multilevel occlusive disease, in whom venous grafts would have better patency than prosthetic grafts. The 5-year patency rates for aortoiliac/aortofemoral reconstructions using FPV grafts range from 85% to 100% (Beck et al., 2008). According to the conventional method described by D'Addio and Clagett in 1993, the patient is prepared and draped from the nipples to the feet under general anesthesia (Clagett et al., 1993). A longitudinal incision along the course of the Sartorius muscle is used to expose an adequate length of the deep femoral and popliteal veins. The side branches are divided and ligated. Care is taken to preserve the profunda femoris vein in order to reduce the incidence of postoperative venous hypertension. The aortic graft is then exposed, either through a transperitoneal or retroperitoneal exposure and excised. Complete debridement of the aorta and surrounding tissues is performed. A sufficient length of deep vein is harvested. Reconstruction of the aortofemoral continuity is accomplished by either creating a bifurcated pantaloons graft, or by a unilateral aortofemoral graft, combined with an iliofemoral crossover graft.

A modification of the conventional NAIS procedure has been advocated by many authors in recent years. It is termed staged NAIS and refers to any aortoiliofemoral reconstruction using deep femoral popliteal veins in the treatment of aortic graft infections that is not completed in a single operation (Ali et al., 2008). At the initial operation, the deep veins are exposed, the side branches are divided and suture-ligated, and the incisions temporarily closed over closed-suction drains. The femoral veins are left in situ, so that flow is not interrupted. Overnight, sequential, compression devices are recommended, in addition to the use of low molecular weight heparin, as a prophylaxis against deep vein thrombosis.

The next day, the infected aortic graft is excised and the aortic reconstruction performed. In selected patients with graft occlusion and ischemia, the NAIS procedure may be further staged by performing unilateral revascularization of the most ischemic leg first, followed by revascularization of the contralateral limb at a later date.

Harvest of the deep vein is a critical part of the operation and has to be done meticulously. The staging of NAIS procedure, with harvesting the vein a day before definitive reconstruction, does not seem to cause any ill effects, and, in fact, may be beneficial in selected groups of patients (Modral et al., 2004). Especially in the presence of limb-threatening ischemia in conjunction with aortic graft infection, the advocates of the staged version, argue that deep femoral popliteal vein mobilization may cause disruption of collaterals and precipitate acute ischemia. In such cases, the authors recommend that aortofemoral bypass be performed in the ischemic limb first, followed by femorofemoral bypass to the contralateral limb within 4 to 18 days later (Ali et al., 2008).

The advantages of autogenous femoroepopliteal vein replacement (NAIS) can be summarized as follows: a) superior long-term patency, limb salvage, b) minimal chance or reinfection, c) no aortic stump in the context of infected field, d) long-term antibiotic/antithrombotic therapy unnecessary (Lopera et al., 2008). Although reasonable limb salvage rates can be achieved using extra-anatomic bypass, achieving this goal requires careful follow up and multiple graft revisions or even new graft procedures. The advent of NAIS procedure has essentially obliterated the need for a secondary intervention in such fragile patients.

The main disadvantage is that the procedure is time consuming and technically demanding. The mean operating time is 8 hours and the lower extremity ischemic time is longer than that of patients undergoing the other procedures (Lopera et al., 2008). An additional disadvantage is the 20% incidence of short-term venous morbidity requiring leg fasciotomy (Modral et al., 2004).

A modification of the NAIS procedure with the use of the superficial femoral arteries as autologous neo-aortoiliac grafts have sporadically been reported in the literature as well (Dinis de Gama et al., 2004).

e. Conservative treatment

In an attempt to avoid submitting high-risk patients to a complex procedure with high morbidity and mortality, many authors have reported on a more conservative strategy, including aggressive local wound care with preservation of most, or all, of the involved graft (Calligaro et al., 2003). Although traditionally used in peripheral vascular graft infections, local care may also be carried out in selected patients with aortic graft infection. So, when clinical signs and preoperative imaging studies indicate that the infection is localized to the groin in a patient having undergone an aortofemoral bypass, drainage of all gross infection, extensive soft-tissue debridement, repetitive wound dressing changes, and

the administration of antibiotics both topically and parenterally may effect sterilization of the wound and allow healing to occur by secondary intention. There have been few if any well-designed trials to study antimicrobial therapy as the main treatment of prosthetic aortic graft infection. Most studies are carried out by surgeons, and, as such, antibiotic therapy is mentioned as adjunct to surgical treatment. There is no evidence on which to decide the optimal duration of antibiotic administration (Perera et al., 2006). As mentioned above, this may vary from 2 weeks to one year, although a minimum of 4-6 weeks of intravenous therapy, followed by up to 6 months of oral therapy is commonly recommended (Nevelsteen et al., 1995). A small number of cases in which operation was deemed an unacceptably high risk to the patient have reported success with long-term suppressive treatment, including in some occasions lifelong antibiotic administration (Baddour, 2001; Roy & Grove, 2000).

A recent addition to our therapeutic armamentarium in managing infected aortic graft infection, when infection is suspected to be confined to one or both groins and the patient considered high risk to be submitted to operation, has been the use of a vacuum-assisted closure system (VAC). It has been reported that VAC therapy reduces the bacteria count in open wounds; removing excess fluid in the wound may stimulate lymphatic and blood flow and increase oxygen concentration, thereby killing bacteria (Dosluoglu et al., 2005). Further experience is necessary to evaluate the potential for VAC therapy to eradicate graft infections in the groin.

Although a trial of graft salvage is considered warranted in selected patients, as it avoids the morbidity inherent in excising the original graft and performing arterial ligation and repair in an infected field and obviates the necessity to perform an extra-anatomic bypass that is susceptible to recurrent thrombotic episodes, there are several disadvantages to this approach. A protracted period of hospitalization is required at considerable financial cost, and during this interval, the graft and patient are vulnerable to a number of complications such as anastomotic hemorrhage, thrombosis, and superinfection with more virulent organisms. A baseline CT scan is performed in these patients prior to discharge. This examination serves as a useful scan for comparison during routine follow-up or if patients develop additional septic or graft complications.

In the absence of evidence or consensus the treatment of aortic graft infection is often somewhat ad hoc and varies from center to center. As a conclusion of what previously described, two are the main criteria of choosing a plan of action. First the extent of graft infection, according to the Szilagyi and Samson criteria, and second, the microorganism cultured. Patients with limited graft infection (Samson 3, i.e. involving the body of the graft but not at an anastomosis) can be considered for graft salvage or route salvage (in situ reconstruction), with aggressive debridement with muscle transposition. On the contrary, graft salvage likely has limited application in advanced infection (Sampson 4 & 5, i.e. infection surrounding an exposed anastomosis with or without bacteremia). In these cases, the current literature suggests excision of the graft and it should be performed if tolerated. With regard to the microorganisms cultured, graft preservation or in situ reconstructions should be attempted when low virulence organisms are found, such as *S. epidermidis*. Methicillin resistant *S. aureus* and gram negative bacteria when met in graft infection should lead to graft explantation and extra-anatomical arterial reconstruction, unless when there is only minor graft involvement.

1.8 Endovascular stent graft infection

There has been no reason to believe that endovascular aortic stent grafts would be immune from septic complications, particularly because these procedures are increasingly being performed outside of the formal operating room and by nonsurgical vascular specialists. The infection rate of endovascular grafts implanted for abdominal aortic aneurysm disease is unclear, but Fiorani et al estimated a rate around 0,4% (Fiorani et al., 2003). Due to the minimal invasive nature of the procedure compared with the open counterpart, it is expected to be associated with lower septic complications.

The pathogenetic mechanisms of endograft infections consist mainly due to the following reasons:

1. Breaks in sterile technique during its implantation,
2. Superinfection during bacteremia from a variety of sources,
3. Severe intraperitoneal or retroperitoneal inflammation (i.e. rupture of hollow viscus, necrotizing pancreatitis),
4. Inoculation of bacteria during postoperative percutaneous interventions to manage various types of endoleaks (Hulin & Morris, 2007).
5. External injury of endograft (Lazaris et al., 2009).

The management of patients with infected aortic endografts must be based on the same fundamental principles as those analyzed above. The gold standard involves the explantation of the graft with subsequent reconstruction according to individualized parameters (Setacci et al., 2010). Some reports on the use of surgical or percutaneous placement of drains into the aneurysmal sac abscess contiguous to the graft in conjunction with irrigation of the perigraft area with antibiotic instilled through the drains and simultaneous systemic antibiotics administration, show promising results and have altered the approach to patients without signs of severe sepsis (Blanch et al., 2010; Pryluck et al., 2010).

1.9 Outcome

The perioperative mortality in patients with aortic prosthetic graft infection has improved over the past two decades. The conventional approach of graft removal and extra-anatomic reconstruction is associated with 12% mortality and 2% incidence of aortic stump infection/disruption (2). Three-year survival is estimated at 63% (Kitamura et al., 2005). Clearly, axillofemoral graft complications occur more frequently in patients with infected aortofemoral prosthetic grafts than in those with aortoiliac bypasses. This is specifically related to the technical challenge posed when attempting to avoid infection in the femoral region and simultaneously construct a durable prosthetic extra-anatomic bypass. On the other hand, the autogenous femoral vein graft is resistant to infection and appears to have a 2-year patency rate that exceeds 90% (Ali et al., 2008).

2. Conclusion

Aortic graft infections could be considered as the most dreadful complications that a vascular surgeon may encounter with. However, there are therapeutic options that can achieve remarkable results. Achieving the best result requires that the attending vascular surgeon takes advantage of the best features of each of the management plans available in his/her armamentarium. None of the approaches described here represents a perfect

solution to the problem. What has become clear in recent years, however, is that although many patients with graft sepsis will continue to require graft explantation, an increasing number of autogenous and allograft options are available that offer the opportunity to maintain in-line anatomic arterial perfusion and preserve long-term limb viability.

3. References

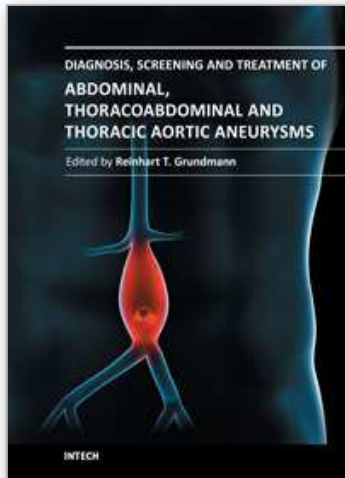
- Ali, A.; McLeod, N.; Klapatapu, V.; Moursi, M. & Eidt, J. (2008). Staging the neoaortoiliac system: feasibility and short-term outcomes. *Journal of Vascular Surgery*, Vol.48, No.5, (Nov), pp.1125-1131, ISSN 1097-6809
- Angle, N. & Freischlag, J.A. (2002) Prosthetic graft infections. In: *Vascular Surgery: A Comprehensive Review*, ch. 38, ed.6, ed. By Moore WS. Philadelphia: WB Saunders, pp. 741-750
- Baddour, L.M. (2001). Long-term suppressive antimicrobial therapy for intravascular device-related infections. *American Journal of the Medical Sciences*, Vol.322, No.4, (Oct), pp. 209-212, ISSN 0002-9629
- Balink, H. & Reijnen, M.M. (2007). Diagnosis of abdominal aortic prosthesis infection with fdg-pet/ct. *Vascular & Endovascular Surgery*, Vol.41, No.5, (Oct-Nov), pp. 428-432, ISSN 1538-5744
- Bandyk, D.F. & Esses, G.E. (1994). Prosthetic graft infection. *Surgical Clinics of North America*, Vol.74, No.3, (Jun), pp. 571-590, ISSN 0039-6109
- Bandyk, D.F.; Novotney, M.L.; Johnson, B.L.; Back, M.R. & Roth, S.R. (2001). Use of rifampin-soaked gelatin-sealed polyester grafts for in situ treatment of primary aortic and vascular prosthetic infections. *Journal of Surgical Research*, Vol.95, No.1, (Jan), pp. 44-49, ISSN 0022-4804
- Barie, P.S. & Eachempati, S.R. (2005). Surgical site infections. *Surgical Clinics of North America*, Vol.85, No.6, (Dec), pp. 1115-1135, viii-ix, ISSN 0039-6109
- Batt, M.; Magne, J.L.; Alric, P.; Muzj, A.; Ruotolo, C.; Ljungstrom, K.G.; Garcia-Casas, R. & Simms, M. (2003). In situ revascularization with silver-coated polyester grafts to treat aortic infection: Early and midterm results. *Journal of Vascular Surgery*, Vol.38, No.5, (Nov), pp. 983-989, ISSN 0741-5214
- Beck, A.W.; Murphy, E.H.; Hocking, J.A.; Timaran, C.H.; Arko, F.R. & Clagett, G.P. (2008). Aortic reconstruction with femoral-popliteal vein: Graft stenosis incidence, risk and reintervention. *Journal of Vascular Surgery*, Vol.47, No.1, (Jan), pp. 36-43; discussion 44, ISSN 0741-5214
- Bisdas, T.; Breddt, M.; Pichlmaier, M.; Aper, T.; Wilhelmi, M.; Bisdas, S.; Haverich, A. & Teebken, O.E. (2010). Eight-year experience with cryopreserved arterial homografts for the in situ reconstruction of abdominal aortic infections. *Journal of Vascular Surgery*, Vol.52, No.2, (Aug), pp. 323-330, ISSN 1097-6809
- Blanch, M.; Berjon, J.; Vila, R.; Simeon, J.M.; Romera, A.; Riera, S. & Cairols, M.A. (2010). The management of aortic stent-graft infection: Endograft removal versus conservative treatment. *Annals of Vascular Surgery*, Vol.24, No.4, (May), pp. 554 e551-555, ISSN 1615-5947
- Brown, K.E.; Heyer, K.; Rodriguez, H.; Eskandari, M.K.; Pearce, W.H. & Morasch, M.D. (2009). Arterial reconstruction with cryopreserved human allografts in the setting of infection: A single-center experience with midterm follow-up. *Journal of Vascular Surgery*, Vol.49, No.3, (Mar), pp. 660-666, ISSN 1097-6809
- Bunt, T.J. (2001). Vascular graft infections: An update. *Cardiovascular Surgery*, Vol.9, No.3, (Jun), pp. 225-233, ISSN 0967-2109

- Calligaro, K.D. & Veith, F.J. (1991). Diagnosis and management of infected prosthetic aortic grafts. *Surgery*, Vol.110, No.5, (Nov), pp. 805-813, ISSN 0039-6060
- Calligaro, K.D.; Veith, F.J.; Yuan, J.G.; Gargiulo, N.J. & Dougherty, M.J. (2003). Intra-abdominal aortic graft infection: Complete or partial graft preservation in patients at very high risk. *Journal of Vascular Surgery*, Vol.38, No.6, (Dec), pp. 1199-1205, ISSN 0741-5214
- Chiesa, R.; Astore, D.; Frigerio, S.; Garriboli, L.; Piccolo, G.; Castellano, R.; Scalamogna, M.; Odero, A.; Pirrelli, S.; Biasi, G.; Mingazzini, P.; Biglioli, P.; Polvani, G.; Guarino, A.; Agrifoglio, G.; Tori, A. & Spina, G. (2002). Vascular prosthetic graft infection: Epidemiology, bacteriology, pathogenesis and treatment. *Acta Chirurgica Belgica*, Vol.102, No.4, (Aug), pp. 238-247, ISSN 0001-5458
- Clagett, G.P.; Bowers, B.L.; Lopez-Viego, M.A.; Rossi, M.B.; Valentine, R.J.; Myers, S.I. & Chervu, A. (1993). Creation of a neo-aortoiliac system from lower extremity deep and superficial veins. *Annals of Surgery*, Vol.218, No.3, (Sep), pp. 239-248; discussion 248-239, ISSN 0003-4932
- Clagett, G.P.; Valentine, R.J. & Hagino, R.T. (1997). Autogenous aortoiliac/femoral reconstruction from superficial femoral-popliteal veins: Feasibility and durability. *Journal of Vascular Surgery*, Vol.25, No.2, (Feb), pp. 255-266; discussion 267-270, ISSN 0741-5214
- Darouiche, R.O. (2004). Treatment of infections associated with surgical implants. *New England Journal of Medicine*, Vol.350, No.14, (Apr 1), pp. 1422-1429, ISSN 1533-4406
- Debakey, M.E.; Creech, O., Jr. & Cooley, D.A. (1954). Occlusive disease of the aorta and its treatment by resection and homograft replacement. *Annals of Surgery*, Vol.140, No.3, (Sep), pp. 290-310, ISSN 0003-4932
- Delgado, M.; Prats, E.; Benito, J.L.; Abos, M.D.; Garcia-Lopez, F.; Tomas, A.; Razola, P.; Pina, J.I. & Banzo, J. (1999). [scintigraphy with 99mtc-hmpao labeled leukocytes and computed tomography in the diagnosis of vascular graft infection. A comparative study]. *Revista Espanola de Medicina Nuclear*, Vol.18, No.2, pp. 77-83, ISSN 0212-6982
- Dinis da Gama, A.; Rosa, A.; Soares, M. & Moura, C. (2004). Use of autologous superficial femoral artery in surgery for aortic prosthesis infection. *Annals of Vascular Surgery*, Vol.18, No.5, (Sep), pp. 593-596, ISSN 0890-5096
- Dosluoglu, H.H.; Schimpf, D.K.; Schultz, R. & Cherr, G.S. (2005). Preservation of infected and exposed vascular grafts using vacuum assisted closure without muscle flap coverage. *Journal of Vascular Surgery*, Vol.42, No.5, (Nov), pp. 989-992, ISSN 0741-5214
- Farkas, J.C.; Fichelle, J.M.; Laurian, C.; Jean-Baptiste, A.; Gigou, F.; Marzelle, J.; Goldstein, F.W. & Cormier, J.M. (1993). Long-term follow-up of positive cultures in 500 abdominal aortic aneurysms. *Archives of Surgery*, Vol.128, No.3, (Mar), pp. 284-288, ISSN 0004-0010
- Fiorani, P.; Speziale, F.; Calisti, A.; Misuraca, M.; Zaccagnini, D.; Rizzo, L. & Giannoni, M.F. (2003). Endovascular graft infection: Preliminary results of an international enquiry. *J Endovasc Ther*, Vol.10, No.5, (Oct), pp. 919-927, ISSN 1526-6028
- FitzGerald, S.F.; Kelly, C. & Humphreys, H. (2005). Diagnosis and treatment of prosthetic aortic graft infections: Confusion and inconsistency in the absence of evidence or consensus. *Journal of Antimicrobial Chemotherapy*, Vol.56, No.6, (Dec), pp. 996-999, ISSN 0305-7453
- Gordon, L.L.; Hagino, R.T.; Jackson, M.R.; Modrall, J.G.; Valentine, R.J. & Clagett, G.P. (1999). Complex aortofemoral prosthetic infections: The role of autogenous superficial femoropopliteal vein reconstruction. *Archives of Surgery*, Vol.134, No.6, (Jun), pp. 615-620; discussion 620-611, ISSN 0004-0010

- Gutowski, P. (1998). [aortoiliac graft infection as a diagnostic and treatment problem]. *Annales Academiae Medicae Stetinensis*, Vol.Suppl 41, pp. 1-72, ISSN 1427-440X
- Hsu, R.B.; Chen, R.J.; Wang, S.S. & Chu, S.H. (2004). Infected aortic aneurysms: Clinical outcome and risk factor analysis. *Journal of Vascular Surgery*, Vol.40, No.1, (Jul), pp. 30-35, ISSN 0741-5214
- Hulin, S.J. & Morris, G.E. (2007). Aortic endograft infection: Open surgical management with endograft preservation. *European Journal of Vascular and Endovascular Surgery*, Vol.34, No.2, (Aug), pp. 191-193, ISSN 1078-5884
- Kaebnick, H.W.; Bandyk, D.F.; Bergamini, T.W. & Towne, J.B. (1987). The microbiology of explanted vascular prostheses. *Surgery*, Vol.102, No.4, (Oct), pp. 756-762, ISSN 0039-6060
- Kaiser, A.B.; Clayson, K.R.; Mulherin, J.L., Jr.; Roach, A.C.; Allen, T.R.; Edwards, W.H. & Dale, W.A. (1978). Antibiotic prophylaxis in vascular surgery. *Annals of Surgery*, Vol.188, No.3, (Sep), pp. 283-289, ISSN 0003-4932
- Kibria, R.; Rao, P.K. & Siva, S. (2010). Secondary aortoenteric fistula presenting with recurrent episodes of sepsis. *Southern Medical Journal*, Vol.103, No.6, (Jun), pp. 594-595, ISSN 1541-8243
- Kieffer, E.; Sabatier, J.; Plissonnier, D. & Knosalla, C. (2001). Prosthetic graft infection after descending thoracic/ thoracoabdominal aortic aneurysmectomy: Management with in situ arterial allografts. *Journal of Vascular Surgery*, Vol.33, No.4, (Apr), pp. 671-678, ISSN 0741-5214
- Kitamura, T.; Morota, T.; Motomura, N.; Ono, M.; Shibata, K.; Ueno, K.; Kotsuka, Y. & Takamoto, S. (2005). Management of infected grafts and aneurysms of the aorta. *Annals of Vascular Surgery*, Vol.19, No.3, (May), pp. 335-342, ISSN 0890-5096
- Koshy, A.K.; Simon, E.G. & Keshava, S.N. (2010). Education and imaging. Gastrointestinal: Aortoenteric fistula. *Journal of Gastroenterology and Hepatology*, Vol.25, No.5, (May), pp. 1014, ISSN 1440-1746
- Landry, G.J.; Moneta, G.L.; Taylor, L.M., Jr. & Porter, J.M. (2000). Axillobifemoral bypass. *Annals of Vascular Surgery*, Vol.14, No.3, (May), pp. 296-305, ISSN 0890-5096
- Lazaris, A.M.; Tsapralis, D.; Patapis, P.; Mproutzos, E.; Tzathas, H.; Kakisis, J.D. & Vasdekis, S.N. (2009). Aortoiliac endograft-enteric fistula due to an ingested toothpick. *Journal of Vascular Surgery*, Vol.50, No.3, (Sep), pp. 640-643, ISSN 1097-6809
- Lehnert, T.; Gruber, H.P.; Maeder, N. & Allenberg, J.R. (1993). Management of primary aortic graft infection by extra-anatomic bypass reconstruction. *European Journal of Vascular Surgery*, Vol.7, No.3, (May), pp. 301-307, ISSN 0950-821X
- Lopera, J.E.; Trimmer, C.K.; Josephs, S.; Dolmatch, B.; Valentine, R.J. & Clagett, G.P. (2008). Neo-aortoiliac reconstructions using femoropopliteal veins: MdcT angiography findings. *AJR. American Journal of Roentgenology*, Vol.191, No.2, (Aug), pp. 569-577, ISSN 1546-3141
- Macbeth, G.A.; Rubin, J.R.; McIntyre, K.E., Jr.; Goldstone, J. & Malone, J.M. (1984). The relevance of arterial wall microbiology to the treatment of prosthetic graft infections: Graft infection vs. Arterial infection. *Journal of Vascular Surgery*, Vol.1, No.6, (Nov), pp. 750-756, ISSN 0741-5214
- Mangram, A.J.; Horan, T.C.; Pearson, M.L.; Silver, L.C. & Jarvis, W.R. (1999). Guideline for prevention of surgical site infection, 1999. Hospital infection control practices advisory committee. *Infection Control and Hospital Epidemiology*, Vol.20, No.4, (Apr), pp. 250-278; quiz 279-280, ISSN 0899-823X
- Mark, A.; Moss, A.A.; Lusby, R. & Kaiser, J.A. (1982). Ct evaluation of complications of abdominal aortic surgery. *Radiology*, Vol.145, No.2, (Nov), pp. 409-414, ISSN 0033-8419

- Mark, A.S.; McCarthy, S.M.; Moss, A.A. & Price, D. (1985). Detection of abdominal aortic graft infection: Comparison of ct and in-labeled white blood cell scans. *AJR. American Journal of Roentgenology*, Vol.144, No.2, (Feb), pp. 315-318, ISSN 0361-803X
- Modrall, J.G.; Sadjadi, J.; Ali, A.T.; Anthony, T.; Welborn, M.B., 3rd; Valentine, R.J.; Hynan, L.S. & Clagett, G.P. (2004). Deep vein harvest: Predicting need for fasciotomy. *Journal of Vascular Surgery*, Vol.39, No.2, (Feb), pp. 387-394, ISSN 0741-5214
- Montgomery, R.S. & Wilson, S.E. (1996). The surgical management of aortoenteric fistulas. *Surgical Clinics of North America*, Vol.76, No.5, (Oct), pp. 1147-1157, ISSN 0039-6109
- Mussa, F.F.; Hedayati, N.; Zhou, W.; El-Sayed, H.F.; Kougiass, P.; Darouiche, R.O. & Lin, P.H. (2007). Prevention and treatment of aortic graft infection. *Expert Rev Anti Infect Ther*, Vol.5, No.2, (Apr), pp. 305-315, ISSN 1744-8336
- Nevelsteen, A.; Lacroix, H. & Suy, R. (1995). Autogenous reconstruction with the lower extremity deep veins: An alternative treatment of prosthetic infection after reconstructive surgery for aortoiliac disease. *Journal of Vascular Surgery*, Vol.22, No.2, (Aug), pp. 129-134, ISSN 0741-5214
- Noel, A.A.; Gloviczki, P.; Cherry, K.J., Jr.; Safi, H.; Goldstone, J.; Morasch, M.D. & Johansen, K.H. (2002). Abdominal aortic reconstruction in infected fields: Early results of the united states cryopreserved aortic allograft registry. *Journal of Vascular Surgery*, Vol.35, No.5, (May), pp. 847-852, ISSN 0741-5214
- O'Brien, T. & Collin, J. (1992). Prosthetic vascular graft infection. *British Journal of Surgery*, Vol.79, No.12, (Dec), pp. 1262-1267, ISSN 0007-1323
- O'Connor, S.; Andrew, P.; Batt, M. & Becquemin, J.P. (2006). A systematic review and meta-analysis of treatments for aortic graft infection. *Journal of Vascular Surgery*, Vol.44, No.1, (Jul), pp. 38-45, ISSN 0741-5214
- Olofsson, P.A.; Auffermann, W.; Higgins, C.B.; Rabahie, G.N.; Tavares, N. & Stoney, R.J. (1988). Diagnosis of prosthetic aortic graft infection by magnetic resonance imaging. *Journal of Vascular Surgery*, Vol.8, No.2, (Aug), pp. 99-105, ISSN 0741-5214
- Orton, D.F.; LeVeen, R.F.; Saigh, J.A.; Culp, W.C.; Fidler, J.L.; Lynch, T.J.; Goertzen, T.C. & McCowan, T.C. (2000). Aortic prosthetic graft infections: Radiologic manifestations and implications for management. *Radiographics*, Vol.20, No.4, (Jul-Aug), pp. 977-993, ISSN 0271-5333
- Oudot, J. & Beaconsfield, P. (1953). Thrombosis of the aortic bifurcation treated by resection and homograft replacement; report of five cases. *AMA Arch Surg*, Vol.66, No.3, (Mar), pp. 365-374, ISSN 0096-6908
- Palestro, C.J.; Weiland, F.L.; Seabold, J.E.; Valdivia, S.; Tomas, M.B.; Moyer, B.R.; Baran, Y.M.; Lister-James, J. & Dean, R.T. (2001). Localizing infection with a technetium-99m-labeled peptide: Initial results. *Nuclear Medicine Communications*, Vol.22, No.6, (Jun), pp. 695-701, ISSN 0143-3636
- Perera, G.B.; Fujitani, R.M. & Kubaska S.M. (2006). Aortic graft infection: Update on Management and Treatment Options. *Vasc Endovascular Surg*, Vol.40, No.1, (Jan), pp. 1-10, ISSN 1538-5744
- Pryluck, D.S.; Kovacs, S.; Maldonado, T.S.; Jacobowitz, G.R.; Adelman, M.A.; Charles, H.C. & Clark, T.W. (2010). Percutaneous drainage of aortic aneurysm sac abscesses following endovascular aneurysm repair. *Vasc Endovascular Surg*, Vol.44, No.8, (Nov), pp. 701-707, ISSN 1938-9116
- Qvarfordt, P.G.; Reilly, L.M.; Mark, A.S.; Goldstone, J.; Wall, S.D.; Ehrenfeld, W.K. & Stoney, R.J. (1985). Computerized tomographic assessment of graft incorporation after aortic reconstruction. *American Journal of Surgery*, Vol.150, No.2, (Aug), pp. 227-231, ISSN 0002-9610

- Roy, D. & Grove, D.I. (2000). Efficacy of long-term antibiotic suppressive therapy in proven or suspected infected abdominal aortic grafts. *Journal of Infection*, Vol.40, No.2, (Mar), pp. 184-204, ISSN 0163-4453
- Samson, R.H.; Veith, F.J.; Janko, G.S.; Gupta, S.K. & Scher, L.A. (1988). A modified classification and approach to the management of infections involving peripheral arterial prosthetic grafts. *Journal of Vascular Surgery*, Vol.8, No.2, (Aug), pp. 147-153, ISSN 0741-5214
- Seeger, J.M.; Pretus, H.A.; Welborn, M.B.; Ozaki, C.K.; Flynn, T.C. & Huber, T.S. (2000). Long-term outcome after treatment of aortic graft infection with staged extra-anatomic bypass grafting and aortic graft removal. *Journal of Vascular Surgery*, Vol.32, No.3, (Sep), pp. 451-459; discussion 460-451, ISSN 0741-5214
- Setacci, C.; De Donato, G.; Setacci, F.; Chisci, E.; Perulli, A.; Galzerano, G. & Siringano, P. (2010). Management of abdominal endograft infection. *Journal of Cardiovascular Surgery*, Vol.51, No.1, (Feb), pp. 33-41, ISSN 0021-9509
- Sharp, W.J.; Hoballah, J.J.; Mohan, C.R.; Kresowik, T.F.; Martinasevic, M.; Chalmers, R.T. & Corson, J.D. (1994). The management of the infected aortic prosthesis: A current decade of experience. *Journal of Vascular Surgery*, Vol.19, No.5, (May), pp. 844-850, ISSN 0741-5214
- Soetevent, C.; Klemm, P.L.; Stalenhoef, A.F. & Bredie, S.J. (2004). Vascular graft infection in aortoiliac and aortofemoral bypass surgery: Clinical presentation, diagnostic strategies and results of surgical treatment. *Netherlands Journal of Medicine*, Vol.62, No.11, (Dec), pp. 446-452, ISSN 0300-2977
- Speziale, F.; Rizzo, L.; Sbarigia, E.; Giannoni, M.F.; Massucci, M.; Maraglino, C.; Santoro, E. & Fiorani, P. (1997). Bacterial and clinical criteria relating to the outcome of patients undergoing in situ replacement of infected abdominal aortic grafts. *European Journal of Vascular and Endovascular Surgery*, Vol.13, No.2, (Feb), pp. 127-133, ISSN 1078-5884
- Szilagyi, D.E.; Smith, R.F.; Elliott, J.P. & Vrandecic, M.P. (1972). Infection in arterial reconstruction with synthetic grafts. *Annals of Surgery*, Vol.176, No.3, (Sep), pp. 321-333, ISSN 0003-4932
- Valentine, R.J. (2001). Diagnosis and management of aortic graft infection. *Seminars in Vascular Surgery*, Vol.14, No.4, (Dec), pp. 292-301, ISSN 0895-7967
- Verhelst, R.; Lacroix, V.; Vraux, H.; Lavigne, J.P.; Vandamme, H.; Limet, R.; Nevelsteen, A.; Bellens, B.; Vasseur, M.A.; Wozniak, B. & Goffin, Y. (2000). Use of cryopreserved arterial homografts for management of infected prosthetic grafts: A multicentric study. *Annals of Vascular Surgery*, Vol.14, No.6, (Nov), pp. 602-607, ISSN 0890-5096
- Vogt, P.R.; von Segesser, L.K.; Goffin, Y.; Niederhauser, U.; Genoni, M.; Kunzli, A.; Lachat, M. & Turina, M.I. (1996). Eradication of aortic infections with the use of cryopreserved arterial homografts. *Annals of Thoracic Surgery*, Vol.62, No.3, (Sep), pp. 640-645, ISSN 0003-4975
- Walker, W.E.; Cooley, D.A.; Duncan, J.M.; Hallman, G.L., Jr.; Ott, D.A. & Reul, G.J. (1987). The management of aortoduodenal fistula by in situ replacement of the infected abdominal aortic graft. *Annals of Surgery*, Vol.205, No.6, (Jun), pp. 727-732, ISSN 0003-4932
- Wilson, S.E. (2001). New alternatives in management of the infected vascular prosthesis. *Surg Infect (Larchmt)*, Vol.2, No.2, (Summer), pp. 171-175; discussion 175-177, ISSN 1096-2964
- Yeager, R.A. & Porter, J.M. (1992). Arterial and prosthetic graft infection. *Annals of Vascular Surgery*, Vol.6, No.5, (Sep), pp. 485-491, ISSN 0890-5096
- Young, R.M.; Cherry, K.J., Jr.; Davis, P.M.; Gloviczki, P.; Bower, T.C.; Panneton, J.M. & Hallett, J.W., Jr. (1999). The results of in situ prosthetic replacement for infected aortic grafts. *American Journal of Surgery*, Vol.178, No.2, (Aug), pp. 136-140, ISSN 0002-9610



Diagnosis, Screening and Treatment of Abdominal, Thoracoabdominal and Thoracic Aneurysms

Edited by Prof. Reinhart Grundmann

ISBN 978-953-307-466-5

Hard cover, 414 pages

Publisher InTech

Published online 12, September, 2011

Published in print edition September, 2011

This book considers mainly diagnosis, screening, surveillance and treatment of abdominal, thoracoabdominal and thoracic aortic aneurysms. It addresses vascular and cardiothoracic surgeons and interventional radiologists, but also anyone engaged in vascular medicine. The high mortality of ruptured aneurysms certainly favors the recommendation of prophylactic repair of asymptomatic aortic aneurysms (AA) and therewith a generous screening. However, the comorbidities of these patients and their age have to be kept in mind if the efficacy and cost effectiveness of screening and prophylactic surgery should not be overestimated. The treatment recommendations which will be outlined here, have to regard on the one hand the natural course of the disease, the risk of rupture, and the life expectancy of the patient, and on the other hand the morbidity and mortality of the prophylactic surgical intervention. The book describes perioperative mortality after endovascular and open repair of AA, long-term outcome after repair, and the cost-effectiveness of treatment.

How to reference

In order to correctly reference this scholarly work, feel free to copy and paste the following:

Dimitrios Tsapralis, Anestis Charalampopoulos and Andreas M. Lazaris (2011). Abdominal Aortic Graft Infection, Diagnosis, Screening and Treatment of Abdominal, Thoracoabdominal and Thoracic Aortic Aneurysms, Prof. Reinhart Grundmann (Ed.), ISBN: 978-953-307-466-5, InTech, Available from: <http://www.intechopen.com/books/diagnosis-screening-and-treatment-of-abdominal-thoracoabdominal-and-thoracic-aortic-aneurysms/abdominal-aortic-graft-infection>

INTeCH
open science | open minds

InTech Europe

University Campus STeP Ri
Slavka Krautzeka 83/A
51000 Rijeka, Croatia
Phone: +385 (51) 770 447
Fax: +385 (51) 686 166
www.intechopen.com

InTech China

Unit 405, Office Block, Hotel Equatorial Shanghai
No.65, Yan An Road (West), Shanghai, 200040, China
中国上海市延安西路65号上海国际贵都大饭店办公楼405单元
Phone: +86-21-62489820
Fax: +86-21-62489821

© 2011 The Author(s). Licensee IntechOpen. This chapter is distributed under the terms of the [Creative Commons Attribution-NonCommercial-ShareAlike-3.0 License](https://creativecommons.org/licenses/by-nc-sa/3.0/), which permits use, distribution and reproduction for non-commercial purposes, provided the original is properly cited and derivative works building on this content are distributed under the same license.

IntechOpen

IntechOpen