

We are IntechOpen, the world's leading publisher of Open Access books Built by scientists, for scientists

6,900

Open access books available

185,000

International authors and editors

200M

Downloads

Our authors are among the

154

Countries delivered to

TOP 1%

most cited scientists

12.2%

Contributors from top 500 universities



WEB OF SCIENCE™

Selection of our books indexed in the Book Citation Index
in Web of Science™ Core Collection (BKCI)

Interested in publishing with us?
Contact book.department@intechopen.com

Numbers displayed above are based on latest data collected.
For more information visit www.intechopen.com



Diagnosis of Aortic Aneurysm

Serosha Mandika Wijeyaratne
*University of Colombo,
 Sri Lanka*

1. Introduction

For most of its course the aorta lies in front of the vertebral bodies, well away from the anterior abdominal wall and is not visible or palpable unless it is significantly dilated. The physician, during routine abdominal palpation or less commonly the patient him/ herself may note abnormal and excessively prominent upper abdominal pulsations that will point to the possibility of an abdominal aortic aneurysm. More frequently, an uncomplicated aortic aneurysm comes to light as an incidental finding during radiologic imaging as part of a routine health check or investigation for other conditions.

The aortic wall per se is insensate and its gradual stretching is not perceived, which explains the clinical silence in the uncomplicated state. Pain is experienced only when adjacent sensitive structures such the pleura or peritoneum comes into contact with blood or the adjacent vertebral structures are compressed and eroded. Thus aortic aneurysms become clinically apparent only when such complications set in. Clinical presentation with complications is characterized by severe pain and shock, where the severity depends on the magnitude of the bleed. Other rare complications include rupture into the adjacent intestinal tract or cava, aneurysm occlusion due to thrombosis, distal embolisation, and consumptive coagulopathy. In most instances, these complications cause death over a short time interval. Thus an accurate clinical diagnosis without delay becomes crucial.

However clinical diagnosis is in no way straightforward and has become a major challenge to clinicians. Understanding the reasons for this is important in overcoming the problem. An aortic aneurysm is often impalpable and symptoms and signs of complications non specific. Clinical presentation of aneurysm complications often mimic other more common conditions and this is the main reason for not suspecting the diagnosis. This chapter examines the frequency with which different presentations occur and the reliability of individual symptoms and signs.

It may be perceived that modern imaging would overcome clinical deficiencies in diagnosing aneurysm complications. This again is incorrect in some instances. Haemodynamic instability at presentation is common and this does not allow time for imaging. In instances where imaging is feasible results may be equivocal and clinical judgment must take over.

Ultrasound, computerized tomography and magnetic resonance are all being used to confirm the presence of an aneurysm, its location, physical dimensions and morphology. These parameters are assuming greater importance today with the emergence of endovascular stent repair of aneurysms. Furthermore, these modalities contribute to the diagnosis of complications and the relative merits of each of these will be discussed.

2. Methods

Method: A review of literature, to determine the evidence base on the accuracy of diagnostic modalities commonly used in the diagnosis of aortic aneurysm, was performed using MEDLINE from 1966 and EMBASE from 1988 to the present. This was supplemented by a bibliographic search of papers identified by hand searching publications on vascular surgery.

3. Uncomplicated aneurysm

Most aortic aneurysms are uncomplicated and asymptomatic. Aneurysms that produce symptoms are at increased risk for rupture. Abdominal or back pain and tenderness are the two main clinical features suggestive of either recent expansion or a leak. Complications are often life threatening, and can occur over a short time span. Therefore the challenge is to diagnose prior to onset of symptoms. Asymptomatic aneurysms are often detected incidentally, during physical examination when a pulsatile mass is felt at or above the umbilicus (the aorta bifurcates at the level of the umbilicus) or during imaging for other reasons. This was confirmed by Kakos et al in a study based in a district general hospital where 48% of abdominal aortic aneurysms were discovered clinically compared with 37.4% radiologically, and 14.6% at laparotomy (Karkos, Mukhopadhyay et al. 2000). Of those diagnosed radiologically, subsequent physical examination showed that one third were palpable but missed at presentation. This suggests that there is greater room for improvement in the clinical detection of asymptomatic abdominal aortic aneurysms. The average size of those discovered clinically (6.48 cm \pm 1.32 cm) was significantly larger than those discovered either radiologically (5.37 cm \pm 1.44 cm, $P < 0.001$) or at laparotomy (5.43 cm \pm 1.48 cm, $P = 0.039$) (Karkos, Mukhopadhyay et al. 2000). Of course it seems easier to detect large aneurysms, particularly those occurring in slim persons. Even the most experienced clinician might miss an abdominal aortic aneurysm at palpation when there is abdominal obesity, abdominal distention, or inability to relax the anterior abdominal wall musculature during the examination (Sabiston and Townsend 2008). This explains the wide variation in sensitivity of physical examination in the detection of abdominal aortic aneurysms. The documented sensitivity of clinical detection of aneurysms ranges from 22 to 96 percent, reflecting differences in the populations screened (Houston, Elster et al. 1998).

In a blinded assessment of abdominal palpation in detecting aortic aneurysms > 3 cm among 200 subjects over the age of 50 years with and without an aneurysm, the sensitivity and specificity for abdominal palpation was 68 and 75 percent respectively. The positive likelihood ratio, defined as the increase in the odds of having the disease when the finding is positive (sensitivity/ $1 - \text{specificity}$), was 2.7 and the negative likelihood ratio, defined as the decrease in odds of having the disease when the finding is negative ($1 - \text{sensitivity} / \text{specificity}$), was 0.43. Sensitivity increases with increasing aortic diameter, from 61% for those of between 3.0 and 3.9 cm to 69% for those between 4.0 and 4.9 cm, and 82% for those that are 5.0 cm or greater. A 1.0 cm increase in abdominal aortic aneurysm diameter doubles the odds of detecting it on clinical examination. An additional factor that was found to affect the detection rate was abdominal girth. A girth less than 100 cm (40 cm in waistline) increases sensitivity from 52% to 91% (Fink, Lederle et al. 2000). In a further analysis of pooled data from 15 studies of patients not previously known to have an aneurysm who were screened by both abdominal palpation and ultrasound, the sensitivity

of abdominal palpation increased significantly with the abdominal aortic aneurysm diameter; the sensitivities for aneurysms 3 to 3.9, 4 to 4.9, and ≥ 5.0 cm were 29, 50, and 76 percent respectively ($p < 0.001$). The reviewers concluded that palpation was moderately sensitive for detecting an aneurysm that is large enough to be referred for surgery (Lederle and Simel 1999).

Awareness of the high risk groups for aortic aneurysms, i.e. ≥ 65 years, peripheral atherosclerotic vascular disease, smoking, chronic obstructive pulmonary disease, hypertension ("Screening for abdominal aortic aneurysm: recommendation statement" 2005) and Marfan and Ehlers-Danlos syndromes or having an affected first-degree relative, may help anticipate and improve sensitivity to palpation. It is disappointing that there have been no large scale community studies on this subject. It is worth emphasizing that palpation of abdominal aortic aneurysms is safe and has not been reported to precipitate rupture. It must be noted that during palpation a tortuous aorta or other retroperitoneal mass lesions can sometimes be confused with an aneurysm. However, the borders of a tortuous aorta can usually be distinguished, and pulsating peri-aortic retroperitoneal masses are not expansile. A false positive physical exam is usually harmless and can easily be clarified by imaging. Finally the vascular examination should include auscultation of the abdomen. The presence of a bruit may indicate aortic or visceral arterial atherosclerotic disease, turbulence within an aneurysm or an aorto-caval fistula. Such a finding would warrant imaging to clarify the situation.

3.1 Imaging studies

The diagnostic drawback due to the limited sensitivity of abdominal palpation in the detection of abdominal aortic aneurysms has been largely overcome by easy access to and a low threshold for imaging. The incidental finding of an asymptomatic abdominal aortic aneurysm has become commonplace, largely due to the increased use of abdominal ultrasound, computed tomography and magnetic resonance imaging for most abdominal symptoms and during preoperative staging and follow up of abdominal malignancies. Furthermore, an aneurysm may be incidentally noted during left sided cardiac catheterization.

An abdominal aortic aneurysm may be suspected on plain x-ray studies, when there is curvilinear calcification outlining both opposing aortic walls. Nevertheless, in more than 50% of cases the calcification is inadequate and does not mark opposing walls. In such instances a tortuous, calcified aorta may in fact mimic an AAA. The lack of overlying bony structures in the lateral projection may allow clearer definition of an aneurysm. However, real-time ultrasonography is the preferred modality for the initial assessment and follow up of abdominal aortic aneurysms because of its portability, easy availability, lack of ionizing radiation, low cost and a sensitivity and specificity approaching 100 percent (LaRoy, Cormier et al. 1989)), (Lindholt, Vammen et al. 1999). Routine sonographic evaluation of an abdominal aortic aneurysm involves measuring the anteroposterior, longitudinal, and transverse dimensions of the aorta. Echo dense calcifications in or adjacent to the aortic wall also may be visualized. Patients are asked to undergo the examination after fasting to reduce the presence of overlying bowel gas which can obscure the aorta. Potential problems with abdominal ultrasonography are that it is operator dependent and frequently does not give an accurate depiction of the iliac arteries which also may be aneurysmal. In addition, in approximately 1 to 2 percent of cases, the aorta cannot be imaged because of technical difficulty such as overlying bowel gas or obesity (Scott, Ashton et al. 1991).

If the aneurysm is approaching 5 cm or more or if rapid enlargement is seen on serial US images, a computed tomography (CT) or CT angiography (CTA) scan should be obtained, to better determine the size, presence of dissection and mural thrombus and delineate the extent of disease, prior to conventional surgery or treatment with the insertion of an endovascular graft. Disadvantages of CT scan compared to ultrasound include greater cost, significant irradiation, the requirement for contrast, failure to provide clear visualization of aortic branch vessel origins, and in some cases inaccuracy localizing the aneurysm neck as compared with contrast angiography (Ernst 1993). In patients whose renal function does not permit the administration of iodinated contrast material, magnetic resonance imaging (MRI) and magnetic resonance angiography (MRA) provide good alternatives. Nevertheless, MRI has several absolute contraindications, including cardiac pacemakers and intracranial aneurysm clips. Claustrophobia and a patient's inability to remain motionless are likely to yield a non-diagnostic study. Finally access to MRI is less than that for other modalities (Ernst 1993; Petersen, Cambria et al. 1995). Angiography is invasive and has greater risks to the patient. The true size of the aneurysm may not be discernible because of a mural thrombus; therefore, underestimation of the true extent of the aneurysm is common and it has no place in the diagnosis of aortic aneurysms. The role of angiography is in planning surgical or endovascular repair.

Clinical examination plays an important part in the detection of abdominal aortic aneurysm and has moderate overall sensitivity; however, it cannot be relied upon to exclude them, especially if rupture is a possibility. Larger abdominal aortic aneurysms are usually palpable and more likely to be detected on clinical examination, particularly in patients who do not have a large abdominal girth. Ultrasound is accurate in the detection of non-ruptured abdominal aortic aneurysms, with a sensitivity and specificity approaching 100%.

4. Complicated aortic aneurysms

Complications are symptomatic and life threatening. These include acute rupture into the retroperitoneal (85.3%) or peritoneal space (7.1%), or gastrointestinal tract (1.8%) (Miani, Mingazzini et al. 1984). Such ruptures typically cause exsanguinating hemorrhage and profound, unstable hypotension leading to death. In contrast some ruptures do not have an acute presentation, but are slow and contained, presenting with chronic low grade symptoms. Additionally rupture could also occur into major abdominal and pelvic veins (5.8%). Other complications include acute thrombotic occlusion of the aneurysm, distal thromboembolism and disseminated intravascular coagulation.

4.1 Rupture of aortic aneurysms

4.1.1 Acute rupture of abdominal aortic aneurysms

Rupture into the retroperitoneum typically originates from the left posterior aspect of the abdominal aortic aneurysm, whereas intra peritoneal rupture tends to occur from the right anterior aspect (Bergan and Thompson 1987). Whenever the hemorrhage is tamponaded by the surrounding retroperitoneum and temporarily contained, hemodynamic compensatory mechanisms are able to maintain vital organ perfusion allowing the patient time to reach the hospital. Clinical suspicion of aneurysm rupture is therefore crucial for rational management and to prevent death.

Clinically, hypotension, pulsatile abdominal mass, and flank or back pain constitutes the classic triad for the diagnosis of abdominal aortic aneurysm rupture. However, this triad

may be incomplete in as many as 50% of patients contributing to misdiagnoses in 24-42%. The patient's blood pressure often recovers and stabilizes giving normal vital signs at examination. An important clue to the diagnosis of rupture, a syncopal attack at the outset indicative of hypotension, may be easily overlooked. Abdominal obesity and muscle guarding contribute to impalpability of an aneurysm. Furthermore, when hypotensive, the aneurysm may become less pulsatile making it more difficult to detect. More than 80% of patients with ruptured abdominal aortic aneurysm present without a previous diagnosis of an aneurysm. Even when it is known that there is an abdominal aneurysm, only 25% of vascular surgeons are able to palpate it at the time of preparation of the patient for surgery. Despite the incomplete triad, a correct and early diagnosis of rupture can still be made in the majority of cases, enabling prompt surgical or endovascular intervention. In the remainder, rupture of aneurysms of the abdominal aorta simulates other clinical conditions, where symptoms are related to impingement of the hematoma on adjacent structures.

These include renal colic, acute cholecystitis, acute diverticulitis of the sigmoid colon, and other gastrointestinal pathology that may delay the correct diagnosis and reduce the patient's chance of survival.

In most instances the obvious clinical feature of rupture is severe abdominal or back ache in an elderly male. This clinical picture is easily confused with several other abdominal emergencies. The leading misdiagnosis is renal colic (Marston, Ahlquist et al. 1992). Blood dissects out into the perirenal space and tracks down the iliac fossa to the groin mimicking the loin to groin radiation of a renal colic. Concomitant dissection of the renal artery may contribute to flank pain and cause hematuria (Eckford and Gillatt 1992).⁷⁰

Right sided aneurysm leaks often cause right upper quadrant pain which could easily be misinterpreted as biliary colic or acute cholecystitis. It is interesting that the well known physicist, Albert Einstein, died from rupture of abdominal aortic aneurysm that simulated acute cholecystitis, and this symptomatology was subsequently described as Einstein's sign (Solberg 1998; Treska 2003). Retroperitoneal hematoma in the left iliac fossa mimics acute diverticulitis with an inflammatory mass (Lederle, Parenti et al. 1994).

Other reported conditions that mimic a leaking or ruptured abdominal aortic aneurysms include ureteral obstruction (Tejada, Becker et al. 1990),¹³ obstruction of the left colon (Politoske 1990), upper gastrointestinal obstruction from compression of the third portion of the duodenum (Pal and Cameron 2009), hiccoughs (Stine and Trued 1979) and haematuria (Fetting, Eagan et al. 1973).

An irreducible inguinal mass is commonly due to an incarcerated hernia and the diagnosis is usually straightforward and correct. Rarely this simple presentation may be the external manifestation of a high volume retroperitoneal hematoma which has extended to the extremes of its anatomical boundaries that includes the inguinal canal. There are several reports of ruptured aneurysms presenting as irreducible symptomatic inguinal masses often diagnosed as complicated inguinal hernia (Abulafi, Mee et al. 1991; Grabowski and Pilcher 1981; Khaw, Sottiurai et al. 1986; Louras and Welch 1984; Owen and Klark 1990; Villegas-Cabello and Siller 1999). Therefore, the presence of haematoma within the inguinal canal warrants further exploration to identify the primary cause.

Retroperitoneal acute rupture with blood tracking inferiorly between the iliacus and psoas, may cause acute femoral nerve compression neuropathy (L2, 3, 4) with quadriceps weakness and anterior thigh pain (Fletcher and Frankel 1976). It may irritate the ilioinguinal nerve (L1) causing groin pain (Lynch 2002), irritate the femoral branch of the genitofemoral nerve (L1) causing testicular pain (O'Keefe and Skiendzielewski 1989) or irritate the lateral cutaneous

nerve of thigh (L2, 3) causing lateral thigh pain. Finally, the posterior cutaneous nerve of the thigh (L2, L3) or the origin of the sciatic nerve (L4- S3) may be irritated by retroperitoneal blood, presenting as pain in the hip or buttock (Mahmood, Ahsan et al. 2005). Any one of these presentations may or may not be associated with thigh ecchymoses, abdominal pain or palpable masses. The only clue to the diagnosis of aneurysm rupture could be a syncopal attack pointing to acute circulatory collapse at the very outset which may have been ignored because of subsequent recovery and dominant extra-abdominal symptoms.

Marston and co-workers(Marston, Ahlquist et al. 1992) catalogued the initial erroneous diagnosis in 46 of 152 retrospectively reviewed cases of ruptured abdominal aortic aneurysm as shown in in Table 1 below.

Initial Diagnosis	Misdiagnosed Cases %	Average Delay, Hours
Renal Colic	24	15
Diverticulitis	13	79
GI Hemorrhage	13	17
Acute MI	8.7	13
Back pain	8.7	18
Motor vehicle accidents	6.5	15
Sepsis	6.5	26
Other GI problems	6.5	4
Other diagnoses	13	18

Table 1. Percentage misdiagnosis and delay in diagnosis

Misdiagnosis in the case of atypical presentations is the main cause of treatment delays leading to increased mortality. The inclusion of abdominal aortic aneurysm in the differential diagnosis of a wide spectrum of symptoms should lead to a low threshold for confirmatory diagnostic imaging that would minimize treatment delays and improve outcomes.

4.1.2 Chronic contained rupture of aneurysms

Although aortic aneurysm ruptures usually present with acute symptoms requiring emergency treatment, in rare instances these get localized to the retroperitoneum and present with chronic compressive symptoms of hematoma which are more subtle and include months of back pain. Other symptoms have been described, including obturator neuropathy, obstructive jaundice and groin hernia (Caynak, Onan et al. 2008; Saiki, Urata et al. 2006). Chronic contained aneurysms represent only 4% of all ruptured aortic aneurysms

(Bansal, Thukral et al. 2006) and 2.7% of operated infrarenal abdominal aortic aneurysms (Jones, Reilly et al. 1986).

The descriptive criteria of chronic contained rupture includes a known history of AAA, pain that radiates to the lower back, a stable condition and normal hematocrit value, radiologic findings of retroperitoneal hematoma, and pathologic confirmation of an organized hematoma. Retroperitoneal hematoma can lead to vertebral erosion in 30% of cases (Booth and Galland 2002).

Symptoms are attributable to tissue compression or erosion and are most often found in the workup of back pain or an abdominal problem. The differential diagnosis includes primary and metastatic spinal tumors, retroperitoneal tumors, iliopsoas muscle abscess, rheumatoid arthritis, osteoporosis, and osteomalacia.

A thorough clinical and radiological workup is required, and the radiological examination should involve a careful look at all structures surrounding the vertebral body. CT scans or magnetic resonance imaging provide a rapid and noninvasive approach for the diagnosis and the extent of bony destruction (Ando, Igari et al. 2003)

4.1.3 Imaging for rupture

Although the imaging findings of abdominal aortic aneurysm rupture are usually obvious, small ruptures can be mistaken for unopacified bowel, lymph node enlargement, or perianeurysmal fibrosis. Careful examination of the morphology of the aneurysm may aid in detecting subtle ruptures.

In a retrospective study (Siegel, Cohan et al. 1994) that evaluated CT scans of patients with ruptured and non ruptured abdominal aortic aneurysms to determine whether a number of morphologic features were associated with rupture, the length of the aneurysm was not significantly different between the rupture and control groups. The ruptured aneurysms had significantly larger anteroposterior and transverse dimensions. The two groups had similar rates of lumen irregularity. Ruptured aneurysms contained a lesser amount of thrombus than aneurysms that were not ruptured. Thrombus calcification was seen more commonly in non ruptured aneurysms, which was thought to be related to the greater amount of thrombus in the non ruptured aneurysms.

Attenuation characteristics of the thrombus that were not associated with rupture included the homogeneous, diffusely heterogeneous, and low-attenuation periluminal halo patterns (Siegel, Cohan et al. 1994). High-attenuation crescents within the mural thrombus were seen only in ruptured aneurysms (Siegel, Cohan et al. 1994). Mural calcification patterns were also evaluated, and a focal discontinuity in otherwise circumferential calcification was rare and seen only in ruptured aneurysms. It was noted, however, that mural calcification was often discontinuous, and the discontinuity was most useful when shown to be new compared with a prior scan (Siegel, Cohan et al. 1994).

There are several studies that have examined hyperattenuating crescents as a sign of impending rupture. It has been reported that thrombus transformation with contrast extravasation into the thrombus and lumen irregularity signify impending rupture (Pillari, Chang et al. 1988). Mehard et al reported a significant correlation between impending rupture and high-attenuating crescents in the wall of abdominal aortic aneurysms on unenhanced CT scans (Mehard, Heiken et al. 1994). In this retrospective study, the high-attenuating crescents were present in 77% of patients with complicated aneurysms, with complications including intramural hematoma, contained rupture, and frank rupture. The

specificity of the "high-attenuating crescent" sign was 93%. For a crescent to be considered high attenuation, the crescent needed to be well defined and of higher attenuation than the psoas muscle on enhanced scans or of higher attenuation than that of the patent lumen on unenhanced scans. In another study, crescents of increased attenuation were present in 21% of ruptured aneurysms and in none of the patients with intact aneurysms (Siegel, Cohan et al. 1994).

Hyperattenuating crescents have been attributed histopathologically to hemorrhage into the mural thrombus or into the aneurysm wall, with clefts of blood seeping from the lumen into the thrombus. The hemorrhage later penetrates the aneurysm wall, which weakens the wall. This places the aneurysm at risk for frank rupture, and prompt surgical consultation should be obtained (Arita, Matsunaga et al. 1997).

4.1.3.1 Imaging in chronic contained rupture

The following criteria have been proposed to enable diagnosis of chronic contained ruptures: known abdominal aortic aneurysm, previous pain symptoms that may have resolved, stable hemodynamic status with a normal hematocrit, CT scans showing retroperitoneal hemorrhage, and pathologic confirmation of organized hematoma (Jones, Reilly et al. 1986). Draping of the posterior aspect of the aorta over the adjacent vertebral body is an indicator of aortic wall insufficiency and contained rupture. Even in the absence of retroperitoneal hemorrhage associated vertebral body erosion may be seen (Halliday and al-Kutoubi 1996).

However, in urgent situations in which the clinical diagnosis is fairly certain and the patient is unstable, there is no place for confirmatory imaging. In such instances the diagnosis is confirmed at open surgery or during angiography as part of endovascular stenting.

4.2 Rupture elsewhere

Aneurysm rupture is not limited to the retroperitoneum or the general peritoneal cavity alone. Rarely an aneurysm may rupture into an adjacent structure and manifest with clinical features pointing towards a primary lesion in that particular viscus. Examples are ruptures into the gastrointestinal tract (aortoenteric fistula) causing gastrointestinal bleeding and rupture into an adjacent vein (cava, renal, lumbar, or common iliac vein) causing hematuria, priapism or lower extremity swelling.

4.2.1 Aortoenteric fistula

Primary aortoenteric fistula (PAEF) is a potentially fatal condition which poses a considerable diagnostic challenge because of its infrequency and the nonspecific presentation. Such fistulae may involve any part of the aorta, with the intestinal tract from the esophagus to the colon, the esophagus and the duodenum being most common (Song, Liu et al. 2008). Secondary fistulae are more common after previous open or endovascular aortic interventions (Saratzis, Saratzis et al. 2008) and mycotic aneurysms (Bunt 1983).

Although rare, primary fistulae from fusiform aortic aneurysms must be considered when the combination of gastrointestinal bleeding and aortic aneurysm coexist (Wijeyeratne SM, Ubayasiri R et al. 2009). Disappointingly, the combination of a pulsatile abdominal mass and gastrointestinal bleeding has been reported in only 23% (Sweeney and Gadacz 1984) to 27.8% (Song, Liu et al. 2008) for aortoduodenal fistulae. These proportions would in fact increase with the use of ultrasound and computerized tomography. Even in such

instances the common assumption is that the bleed is from either diverticuli, ulcers or varices (Jiao, Zong et al. 2009; Senadhi, Brown et al. 2010; Thomson, Gopinath et al. 2009) and the aneurysm is usually considered an incidental finding.

The pattern of bleeding from an aortoenteric fistula (AEF) is of interest. A “herald” hemorrhage is followed hours, days, or weeks later by catastrophic hemorrhage and this is characteristic of an AEF (Song, Liu et al. 2008). This initial self limiting bleed is the result of a small fistula occluded by thrombus. Since 70% survive at least 6 hours (Sweeney and Gadacz 1984) and up to 50% for 24 hours (Steffes and O’Leary 1980) after the initial bleed, a “herald” hemorrhage should be viewed as an opportunity for prompt surgical intervention. Hence clinical awareness is crucial and should be broad based, particularly among emergency care specialists, gastroenterologists, general surgeons and physicians.

Endoscopy is the cornerstone in the diagnostic work up for haematemesis. Nevertheless the detection of non bleeding erosions, ulcers, varices or polyps may be misleading (Jiao, Zong et al. 2009) and negative endoscopy does not rule out an AEF as the length of the endoscope does not allow visualization of the distal duodenum where AEFs commonly occur (Brand, Sivak et al. 1979).

Although no single imaging modality demonstrates the condition with sufficient sensitivity and specificity, computed tomography (CT), owing to its widespread availability and high efficiency, has become the imaging modality of choice for evaluations in the emergency setting. CT has widely variable sensitivity (40%-90%) and specificity (33%-100%) for the diagnosis of aortoenteric fistulae. To use this modality effectively for the initial diagnostic examination, radiologists must be familiar with the spectrum of CT appearances. Mimickers of aortoenteric fistulae include retroperitoneal fibrosis, infected aortic aneurysm, infectious aortitis, and perigraft infection without fistulization. Differentiation is aided by the observation of ectopic gas, loss of the normal fat plane, extravasation of aortic contrast material into the enteric lumen, or leakage of enteric contrast material into the paraprosthetic space; these features are highly suggestive of aortoenteric fistula in a patient with bleeding into the gastrointestinal tract (Daly, Nott et al. 1997; Vu, Menias et al. 2009). But the absence of these features in the presence of an AEF is not unusual and one must be aware of its limited negative predictive value (Ranasinghe, Loa et al. 2011). This awareness would help in justifying proceeding with interventions based on high clinical suspicion when there is uncontrolled bleeding.

It must also be remembered that percutaneous angiography is of little value since the need for it coincides with the need for immediate surgery (Yeong 1995). Despite technological advances in endoscopy and imaging, the cornerstone in the diagnosis of an AEF remains clinical suspicion (Mehmood, Mushtaq et al. 2007; Wijeyeratne SM, Ubayasiri R et al. 2009)

4.2.2 Aortocaval fistula

Aortocaval fistula is a rare complication of AAA, involving less than 1% of all aortic aneurysms. The diagnosis is dependent on recognition of its clinical features. The dramatic picture of a patient with pain, a large pulsatile abdominal mass, a machinery-like abdominal bruit, and acute dyspnea is pathognomic for an aortocaval fistula and has been well described (Bednarkiewicz, Pretre et al. 1997). However, classic features may be absent in up to one half of patients (Reckless, McColl et al. 1972). Absence of characteristic findings together with the rarity of such lesions and resultant lack of awareness may lead to delay in diagnosis.

Several factors may contribute to misdiagnosis. Failure to auscultate the abdomen for a bruit is probably a key reason for non diagnosis before surgery (Brewster, Cambria et al. 1991) and underscores the importance of routine auscultation of the abdomen in all patients with an aneurysm.

In some instances the diagnosis may be missed despite detecting the abdominal bruit because of the inability to detect a palpable pulsatile abdominal mass, more so in those patients with isolated iliac aneurysms. Finally the mural thrombus within the aneurysm sac may partially or totally obstruct the fistula and obliterate the typical continuous bruit (Baker, Sharzer et al. 1972; Dardik, Dardik et al. 1976; Weinbaum, Riles et al. 1984).

Although the principal hemodynamic effects of left-to-right AV shunts have been well characterized in general, the specific clinical features of large vessel central AV fistulas may be quite variable. Factors influencing the clinical manifestations of such lesions include the size, and location of the fistula as well as its duration. In addition, differences in patient age, preexistent cardiopulmonary or renal disease, and possible associated retroperitoneal blood loss at the time of fistula occurrence can markedly alter the manner of clinical presentation in individual patients.

In the case of high output fistulae, a sensation of fullness in the chest, and that the heart is about to burst, the aptly named "bursting heart " syndrome has been reported (Leigh-Smith and Smith 2000). Chest pain in such instances are often misdiagnosed as angina (Beierlein, Walker et al. 2002) and acute coronary syndrome (Vigna, Santoro et al. 2008). Decompensated high-output cardiac failure, occurring when the increased venous return overwhelms cardiac compensatory mechanisms, has often been emphasized as the predominant clinical feature (Brewster, Cambria et al. 1991). Predisposition to cardiac failure would depend on available cardiac reserve, fistula size and duration of illness (Kazmier and Harrison 1973; Nennhaus and Javid 1968; Reckless, McColl et al. 1972).

Caval compression by the adjacent aortic aneurysm tends to minimize flow towards the heart and augment peripheral venous flow and pressure. Diversion of most shunted blood toward the pelvis and extremities produces marked *regional* venous hypertension and accounts for many of the symptoms and findings, which may confuse or obscure correct diagnosis (Brewster, Cambria et al. 1991).

Regional venous hypertension is responsible for the often marked swelling of the lower extremities frequently seen and explains the often striking contrast of bluish, congested lower extremities and the presence of cool, pale, ischemic upper extremities and trunk. Distended veins in the lower abdomen and legs in the lying down position and even with leg elevation are diagnostic. Careful examination may detect pulsation. The presence of long saphenous bruits suggests saphenofemoral incompetence due to arterialized, reversed venous flow dynamics and strengthens the clinical diagnosis of aortocaval fistula (Phillips, Chaudhuri et al. 2006).

Phlegmasia cerulea dolens, characterized by the triad of limb swelling, cyanosis, and acute ischemic pain, usually arises because of acute massive thrombosis of major deep, collateral, and superficial veins of an extremity. A similar clinical picture has been reported following aneurysm rupture into the cava (Myers, Kalangos et al. 2008) .

Transmission of such venous hypertension to the pelvic venous system may also lead to hematuria, which may cause diagnostic confusion. Hematuria has been reported in 17% to 24% of patients with an aortocaval fistula (Brewster, Cambria et al. 1991; Crawford, Turell et al. 1963; Nennhaus and Javid 1968; van Driel, van Gelder et al. 1984). The presence of

hematuria in a patient suffering from an abdominal aortic aneurysm is an indication for imaging to rule out an aortocaval fistula (Salo, Verkkala et al. 1990). Prompt clearing of hematuria with repair of the fistula, supports the key role of pelvic venous hypertension (Brewster, Cambria et al. 1991).

Rupture of distended superficial colorectal mucosal veins may cause rectal bleeding (Doty, Wright et al. 1978; van Driel, van Gelder et al. 1984). A similar mechanism accounts for reported cases of painless priapism thus indicating high flow as the cause in the case of an aortocaval fistula (Gordon, Marsh et al. 2004).

Aortocaval fistula may also present primarily with renal insufficiency, manifesting with oliguria or anuria and acidosis, and cause diagnostic confusion. Spontaneous aortocaval fistula can also present with acute liver and renal failure (Kanbay, Gur et al. 2004). Furthermore the rapid increase of intra-abdominal blood volume due to a massive fistula has been reported to cause acute abdominal compartment syndrome leading to multi-organ dysfunction (Music, Radevic et al. 2006).

Abdominal color doppler ultrasonography is useful in establishing the diagnosis, which will show the jet effect of aortic flow into the IVC. Characteristic findings for the CT diagnosis include early synchronous and equivalent enhancement of the IVC and aorta and dilatation of IVC and pelvic veins. Furthermore CT angiography would help in the delineation of anatomy that may be particularly important for its management.

4.3 Acute thrombosis

Thrombosis of an abdominal aortic aneurysm is a rare (0.6-1.8%, less than 60 reported cases) (Bolduc, Clayson et al. 1989; Fairhead, Phillips et al. 2005; Hachiro, Kawaharada et al. 2004; Hirose, Takagi et al. 2000; Shnacker, Witz et al. 2001; Suliman, Raffetto et al. 2003) yet devastating complication with an estimated mortality rate of 50%. Unlike AAA rupture, the risk of developing an AAA thrombosis is independent of the size of the aneurysm (Beach and Manthey 1998; Hachiro, Kawaharada et al. 2004).

The usual presentation of AAA thrombosis is that of abrupt vascular compromise of the lower extremities, with absent distal pulses (68%), pain (45.7%) involving lower extremities, coolness (31.4%), numbness (34.3%) and mottled skin below the umbilicus (42.9%) being the most frequent findings (Hachiro, Kawaharada et al. 2004; Suliman, Raffetto et al. 2003). Some motor disturbance is found in 22.9% of these cases (Hachiro, Kawaharada et al. 2004).

The differential diagnosis for AAA thrombosis includes aortic dissection and AAA rupture. Abdominal pain is more indicative of AAA rupture, whereas AAA thrombosis usually has severe lower limb pain (Hachiro, Kawaharada et al. 2004).

Hypertension can be associated with both AAA thrombosis and aortic dissection, and an initial presentation of paralysis has also been documented with aortic dissection (Ayerdi, Gupta et al. 2002). Usually chest or upper back pain will be expected with aortic dissection in addition to the paralysis. When the thrombus obstructs the artery of Adamkiewicz, the main blood supply to the lower spinal cord, spinal ischemia and paralysis can occur without pain or other features of limb ischaemia (Bogie, Willigendael et al. 2008; Bolduc, Clayson et al. 1989; Lo, Vallee et al. 2002; van Zyl 2005). Rarely an abdominal aortic aneurysm may thrombose without causing acute limb ischaemia (Brandao, Simoes et al. 2009; Moulakakis, Maras et al. 2010).

4.4 Coagulopathy as a form of presentation of aortic aneurysms

Infrequently, a large abdominal aortic aneurysm is associated with clinically overt disseminated intravascular coagulation causing a consumptive coagulopathy and hemorrhagic and thrombotic complications; the reported incidence being as high as 3 to 4 percent (Aboulafia and Aboulafia 1996; Fisher, Yawn et al. 1983).

In the majority of cases, consumptive coagulopathy is asymptomatic and has a chronic course, but in 0.5-4% of patients it is clinically overt and may be the presenting feature leading to the diagnosis of a previously unknown aortic aneurysm (Peters, Triolo et al. 2005; Trelinski, Stelagowski et al. 2009).

4.5 Inflammatory aortic aneurysms

In contrast with atherosclerotic aortic aneurysms, the majority of patients with an intact inflammatory aneurysm are symptomatic (Goldstone, Malone et al. 1978). The most common symptom is abdominal and/or back pain while anorexia and weight loss are frequent associates. Ureteric entrapment causing colic is another unique feature (Crawford, Stowe et al. 1985). Interestingly the majority (85%) of these aneurysms are palpable at the time of diagnosis while one fourth are tender and have a bruit. There are several reports of these patients having a moderate rise in the erythrocyte sedimentation rate (Bainbridge and Woodward 1982; Darke, Glass et al. 1977; Pennell, Hollier et al. 1985) and this would further strengthen the accuracy of diagnosis of inflammatory aneurysms in symptomatic patients.

Nevertheless the classic triad of chronic abdominal or back pain, elevated ESR, and weight loss is rare, implying a low diagnostic sensitivity but has high specificity for inflammatory aneurysms. When ureteric obstruction is added the diagnostic accuracy increases further.

Although preoperative clinical diagnosis of an inflammatory aneurysm was infrequent in the past, routine preoperative imaging since of late has significantly facilitated the diagnosis. The thickening of the aortic wall occurs in the anterior and lateral walls. This can be demonstrated by both CT scan and ultrasonography. The ultrasound scan shows an echolucent halo anteriorly and laterally with clear definition of the posterior aortic wall (Bundy and Ritchie 1984; Pennell, Hollier et al. 1985; Walker, Bloor et al. 1972). The diagnostic accuracy is greater with CT scanning. The characteristic findings are a preaortic retroperitoneal soft tissue density that is sometimes enhanced with intravenous contrast (Pahira, Wein et al. 1979; Vint, Usselman et al. 1980). It must be noted that these features could easily be mistaken for those from a leaking aneurysm with retroperitoneal hematoma (Aiello and Cohen 1980; Pang, Chan et al. 2010; Pennell, Hollier et al. 1985). Medial ureteral deviation or obstruction on CT ureterography in a patient with an aneurysm strongly suggests the inflammatory variety. Although lateral ureteral deviation may be seen with large atherosclerotic aneurysms, ureteral obstruction is very rare (Culp and Bernatz 1961).

5. Conclusion

Typically uncomplicated aortic aneurysms are asymptomatic and discovered incidentally, but abdominal pain and back pain are the most common symptoms and point to complications which are often life threatening.

Diagnosis relies on clinical suspicion confirmed by imaging. Ultrasound remains the definitive test for initial diagnosis and screening. CT scan is typically required for confirmation of rupture in stable patients and for preoperative planning in uncomplicated

cases. In the case of complications with hemodynamic instability there is no time for imaging and one must proceed with definitive care based on clinical judgment alone.

6. Acknowledgement

Sara Mohammed Jinnah

7. References

- Aboulafia, D. M. and E. D. Aboulafia (1996). "Aortic aneurysm-induced disseminated intravascular coagulation." *Ann Vasc Surg* 10(4): 396-405.ISSN 0890-5096.
- Abulafi, A. M., W. M. Mee, et al. (1991). "Leaking abdominal aortic aneurysm presenting as an inguinal mass." *Eur J Vasc Surg* 5(6): 695-696.ISSN 0950-821X
- Aiello, M. R. and W. N. Cohen (1980). "Inflammatory aneurysm of the abdominal aorta." *J Comput Assist Tomogr* 4(2): 265-267.ISSN 0363-8715
- Ando, M., T. Igari, et al. (2003). "CT features of chronic contained rupture of an abdominal aortic aneurysm." *Ann Thorac Cardiovasc Surg* 9(4): 274-278.ISSN 1341-1098.
- Arita, T., N. Matsunaga, et al. (1997). "Abdominal aortic aneurysm: rupture associated with the high-attenuating crescent sign." *Radiology* 204(3): 765-768.ISSN 0033-8419
- Ayerdi, J., S. K. Gupta, et al. (2002). "Acute abdominal aortic thrombosis following the Heimlich maneuver." *Cardiovasc Surg* 10(2): 154-156.ISSN 0967-2109
- Bainbridge, E. T. and D. A. Woodward (1982). "Inflammatory aneurysms of the abdominal aorta with associated ureteric obstruction or medial deviation." *J Cardiovasc Surg (Torino)* 23(5): 365-370.ISSN 0021-9509
- Baker, W. H., L. A. Sharzer, et al. (1972). "Aortocaval fistula as a complication of abdominal aortic aneurysms." *Surgery* 72(6): 933-938.ISSN 0039-6060
- Bansal, M., B. B. Thukral, et al. (2006). "Contained rupture of a thoracoabdominal aortic aneurysm presenting as a back mass." *J Thorac Imaging* 21(3): 219-221.ISSN 0883-5993
- Beach, C. and D. Manthey (1998). "Painless acute aortic dissection presenting as left lower extremity numbness." *Am J Emerg Med* 16(1): 49-51.ISSN 0735-6757
- Bednarkiewicz, M., R. Pretre, et al. (1997). "Aortocaval fistula associated with abdominal aortic aneurysm: a diagnostic challenge." *Ann Vasc Surg* 11(5): 464-466.ISSN 0890-5096
- Beierlein, W., T. Walker, et al. (2002). "[Angina pectoris as initial clinical manifestation of ruptured abdominal aortic aneurysm with aortocaval fistula]." *Med Klin (Munich)* 97(6): 357-360.ISSN 0723-5003
- Bergan, J. J. and J. E. Thompson (1987). "The ruptured abdominal aortic aneurysm. In: Bergan JJ, Yao JT, eds. ." *Vascular Surgical Emergencies*: 285-297.ISSN.
- Bogie, R., E. M. Willigendael, et al. (2008). "Acute thrombosis of an abdominal aortic aneurysm: a short report." *Eur J Vasc Endovasc Surg* 35(5): 590-592.ISSN 1532-2165
- Bolduc, M. E., S. Clayson, et al. (1989). "Acute aortic thrombosis presenting as painless paraplegia." *J Cardiovasc Surg (Torino)* 30(3): 506-508.ISSN 0021-9509
- Booth, M. I. and R. B. Galland (2002). "Chronic contained rupture of an abdominal aortic aneurysm: a case report and review of the literature." *Eur J Vasc Endovasc Surg Extra*(3): 33-35.

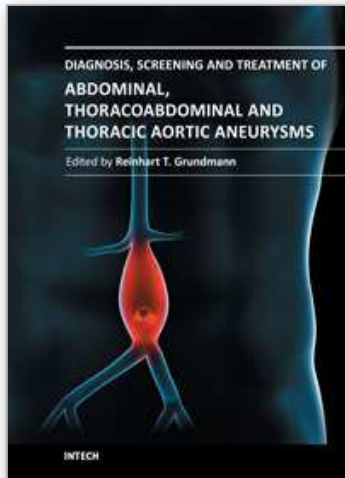
- Brand, E. J., M. V. Sivak, Jr., et al. (1979). "Aortoduodenal fistula: endoscopic diagnosis." *Dig Dis Sci* 24(12): 940-944. ISSN 0163-2116
- Brandao, D., J. C. Simoes, et al. (2009). "Occlusion of inferior vena cava: a singular presentation of abdominal aortic aneurysm." *Case Report Med* 2009: 827954. ISSN 1687-9635
- Brewster, D. C., R. P. Cambria, et al. (1991). "Aortocaval and iliac arteriovenous fistulas: recognition and treatment." *J Vasc Surg* 13(2): 253-264; discussion 264-255. ISSN 0741-5214
- Bundy, A. L. and W. G. Ritchie (1984). "Inflammatory aneurysm of the abdominal aorta." *J Clin Ultrasound* 12(2): 102-104. ISSN 0091-2751
- Bunt, T. J. (1983). "Synthetic vascular graft infections. II. Graft-enteric erosions and graft-enteric fistulas." *Surgery* 94(1): 1-9. ISSN 0039-6060
- Caynak, B., B. Onan, et al. (2008). "Vertebral erosion due to chronic contained rupture of an abdominal aortic aneurysm." *J Vasc Surg* 48(5): 1342. ISSN 1097-6809
- Crawford, E. S., D. J. Turell, et al. (1963). "Aorto-inferior vena caval fistula of neoplastic origin. Hemodynamic and coronary blood flow studies." *Circulation* 27: 414-421. ISSN 0009-7322
- Crawford, J. L., C. L. Stowe, et al. (1985). "Inflammatory aneurysms of the aorta." *J Vasc Surg* 2(1): 113-124. ISSN 0741-5214
- Culp, O. and P. E. Bernatz (1961). "Urologic aspects of lesions in the abdominal aorta." *J Urol* 86: 189-195. ISSN 0022-5347
- Daly, C. A., D. M. Nott, et al. (1997). "Aortoduodenal fistula: appearances on computed tomography." *Aust N Z J Surg* 67(10): 745-746. ISSN 0004-8682
- Dardik, H., I. Dardik, et al. (1976). "Intravenous rupture of arteriosclerotic aneurysms of the abdominal aorta." *Surgery* 80(5): 647-651. ISSN 0039-6060
- Darke, S. G., R. E. Glass, et al. (1977). "Abdominal aortic aneurysm: Perianeurysmal fibrosis and ureteric obstruction and deviation." *Br J Surg* 64(9): 649-651. ISSN 0007-1323
- Doty, D. B., C. B. Wright, et al. (1978). "Aortocaval fistula associated with aneurysm of the abdominal aorta: current management using autotransfusion techniques." *Surgery* 84(2): 250-252. ISSN 0039-6060
- Eckford, S. D. and D. A. Gillatt (1992). "Abdominal aortic aneurysms presenting as renal colic." *Br J Urol* 70(5): 496-498. ISSN 0007-1331
- Ernst, C. B. (1993). "Abdominal aortic aneurysm." *N Engl J Med* 328(16): 1167-1172. ISSN 0028-4793
- Fairhead, J. F., D. Phillips, et al. (2005). "Embolic spinal cord infarction as a presentation of abdominal aortic aneurysm." *J R Soc Med* 98(2): 59-60. ISSN 0141-0768
- Fetting, J. H., J. W. Eagan, Jr., et al. (1973). "Hematuria due to an abdominal aortic aneurysm leaking into a ureteral stump." *Johns Hopkins Med J* 133(6): 339-342. ISSN 0021-7263
- Fink, H. A., F. A. Lederle, et al. (2000). "The accuracy of physical examination to detect abdominal aortic aneurysm." *Arch Intern Med* 160(6): 833-836. ISSN 0003-9926
- Fisher, D. F., Jr., D. H. Yawn, et al. (1983). "Preoperative disseminated intravascular coagulation associated with aortic aneurysms. A prospective study of 76 cases." *Arch Surg* 118(11): 1252-1255. ISSN 0004-0010
- Fletcher, H. S. and J. Frankel (1976). "Ruptured abdominal aneurysms presenting with unilateral peripheral neuropathy." *Surgery* 79(1): 120-121. ISSN 0039-6060

- Goldstone, J., J. M. Malone, et al. (1978). "Inflammatory aneurysms of the abdominal aorta." *Surgery* 83(4): 425-430. ISSN 0039-6060
- Gordon, S., P. Marsh, et al. (2004). "Priapism as the presenting symptom of an aortocaval fistula." *Emerg Med J* 21(2): 265. ISSN 1472-0213
- Grabowski, E. W. and D. B. Pilcher (1981). "Ruptured abdominal aortic aneurysm manifesting as symptomatic inguinal hernia." *Am Surg* 47(7): 311-312. ISSN 0003-1348
- Hachiro, Y., N. Kawaharada, et al. (2004). "[Thoracoabdominal aortic aneurysm repair after detection of the Adamkiewicz artery by magnetic resonance angiography; a way to shorten operating time and improve outcome]." *Kyobu Geka* 57(4): 280-283. ISSN 0021-5252
- Halliday, K. E. and A. al-Kutoubi (1996). "Draped aorta: CT sign of contained leak of aortic aneurysms." *Radiology* 199(1): 41-43. ISSN 0033-8419
- Hirose, H., M. Takagi, et al. (2000). "Acute occlusion of an abdominal aortic aneurysm--case report and review of the literature." *Angiology* 51(6): 515-523. ISSN 0003-3197
- Houston, T. P., A. B. Elster, et al. (1998). "The U.S. Preventive Services Task Force Guide to Clinical Preventive Services, Second Edition. AMA Council on Scientific Affairs." *Am J Prev Med* 14(4): 374-376. ISSN 0749-3797
- Jiao, Y., Y. Zong, et al. (2009). "Aorto-esophageal fistula: a case misdiagnosed as esophageal polyp." *World J Gastroenterol* 15(47): 6007-6009. ISSN 1007-9327
- Jones, C. S., M. K. Reilly, et al. (1986). "Chronic contained rupture of abdominal aortic aneurysms." *Arch Surg* 121(5): 542-546. ISSN 0004-0010
- Kanbay, M., G. Gur, et al. (2004). "Spontaneous aortocaval fistula presenting with acute liver and renal failure: a case report." *Turk J Gastroenterol* 15(3): 169-172. ISSN 1300-4948
- Karkos, C. D., U. Mukhopadhyay, et al. (2000). "Abdominal aortic aneurysm: the role of clinical examination and opportunistic detection." *Eur J Vasc Endovasc Surg* 19(3): 299-303. ISSN 1078-5884
- Kazmier, F. J. and C. E. Harrison, Jr. (1973). "Acquired aortocaval fistulas." *Am J Med* 55(2): 175-183. ISSN 0002-9343
- Khaw, H., V. S. Sottiurai, et al. (1986). "Ruptured abdominal aortic aneurysm presenting as symptomatic inguinal mass: report of six cases." *J Vasc Surg* 4(4): 384-389. ISSN 0741-5214
- LaRoy, L. L., P. J. Cormier, et al. (1989). "Imaging of abdominal aortic aneurysms." *AJR Am J Roentgenol* 152(4): 785-792. ISSN 0361-803X
- Lederle, F. A., C. M. Parenti, et al. (1994). "Ruptured abdominal aortic aneurysm: the internist as diagnostician." *Am J Med* 96(2): 163-167. ISSN 0002-9343
- Lederle, F. A. and D. L. Simel (1999). "The rational clinical examination. Does this patient have abdominal aortic aneurysm?" *JAMA* 281(1): 77-82. ISSN 0098-7484
- Leigh-Smith, S. and R. C. Smith (2000). "Aorto caval fistula--the "bursting heart syndrome"." *J Accid Emerg Med* 17(3): 223-225. ISSN 1351-0622
- Lindholt, J. S., S. Vammen, et al. (1999). "The validity of ultrasonographic scanning as screening method for abdominal aortic aneurysm." *Eur J Vasc Endovasc Surg* 17(6): 472-475. ISSN 1078-5884
- Lo, D., J. N. Vallee, et al. (2002). "Unusual origin of the artery of Adamkiewicz from the fourth lumbar artery." *Neuroradiology* 44(2): 153-157. ISSN 0028-3940

- Louras, J. C. and J. P. Welch (1984). "Masking of ruptured abdominal aortic aneurysm by incarcerated inguinal hernia." *Arch Surg* 119(3): 331-332. ISSN 0004-0010
- Lynch, R. M. (2002). "Ruptured abdominal aortic aneurysm presenting as groin pain." *Br J Gen Pract* 52(477): 320-321. ISSN 0960-1643
- Mahmood, F., F. Ahsan, et al. (2005). "Ruptured abdominal aortic aneurysm presenting as buttock pain." *Emerg Med J* 22(6): 453-454. ISSN 1472-0213
- Marston, W. A., R. Ahlquist, et al. (1992). "Misdiagnosis of ruptured abdominal aortic aneurysms." *J Vasc Surg* 16(1): 17-22. ISSN 0741-5214
- Mehard, W. B., J. P. Heiken, et al. (1994). "High-attenuating crescent in abdominal aortic aneurysm wall at CT: a sign of acute or impending rupture." *Radiology* 192(2): 359-362. ISSN 0033-8419
- Mehmood, R. K., A. Mushtaq, et al. (2007). "Clinical presentation of a missed primary aorto-enteric fistula." *J Pak Med Assoc* 57(12): 616-618. ISSN 0030-9982
- Miani, S., P. Mingazzini, et al. (1984). "Influence of the rupture site of abdominal aortic aneurysms with regard to postoperative survival rate." *J Cardiovasc Surg (Torino)* 25(5): 414-419. ISSN 0021-9509
- Moulakakis, K. G., D. Maras, et al. (2010). "'Silent' thrombosis of an abdominal aortic aneurysm not producing acute limb ischemia." *Vasa* 39(3): 265-267. ISSN 0301-1526
- Music, D., B. Radevic, et al. (2006). "[Abdominal compartment syndrome caused by ruptured abdominal aortic aneurysm in vena cava]." *Vojnosanit Pregl* 63(9): 843-846. ISSN 0042-8450
- Myers, P. O., A. Kalangos, et al. (2008). "Ruptured aortic aneurysm masquerading as phlegmasia cerulea." *Am J Emerg Med* 26(9): 1067 e1061-1062. ISSN 1532-8171
- Nennhaus, H. P. and H. Javid (1968). "The distinct syndrome of spontaneous abdominal aortocaval fistula." *Am J Med* 44(3): 464-473. ISSN 0002-9343
- O'Keefe, K. P. and J. J. Skiendzielewski (1989). "Abdominal aortic aneurysm rupture presenting as testicular pain." *Ann Emerg Med* 18(10): 1096-1098. ISSN 0196-0644
- Owen, E. R. and A. E. Klark (1990). "Irreducible inguinal hernia as a presentation of ruptured abdominal aortic aneurysm." *J R Coll Surg Edinb* 35(6): 399. ISSN 0035-8835
- Pahira, J. J., A. J. Wein, et al. (1979). "Bilateral complete ureteral obstruction secondary to an abdominal aortic aneurysm with perianeurysmal fibrosis: diagnosis by computed tomography." *J Urol* 121(1): 103-106. ISSN 0022-5347
- Pal, A. and A. E. Cameron (2009). "Superior mesenteric artery syndrome in association with an abdominal aortic aneurysm." *Ann R Coll Surg Engl* 91(7): W6-7. ISSN 1478-7083
- Pang, Y. C., Y. C. Chan, et al. (2010). "Tender inflammatory infrarenal aortic aneurysm simulating acute rupture." *Asian Cardiovasc Thorac Ann* 18(2): 180-182. ISSN 1816-5370
- Pennell, R. C., L. H. Hollier, et al. (1985). "Inflammatory abdominal aortic aneurysms: a thirty-year review." *J Vasc Surg* 2(6): 859-869. ISSN 0741-5214
- Peters, K. A., P. T. Triolo, et al. (2005). "Disseminated intravascular coagulopathy: manifestations after a routine dental extraction." *Oral Surg Oral Med Oral Pathol Oral Radiol Endod* 99(4): 419-423. ISSN 1079-2104
- Petersen, M. J., R. P. Cambria, et al. (1995). "Magnetic resonance angiography in the preoperative evaluation of abdominal aortic aneurysms." *J Vasc Surg* 21(6): 891-898; discussion 899. ISSN 0741-5214

- Phillips, A. W., A. Chaudhuri, et al. (2006). "Bilateral long saphenous bruits: a marker of aortocaval fistula." *Eur J Vasc Endovasc Surg* 32(5): 529-531. ISSN 1078-5884
- Pillari, G., J. B. Chang, et al. (1988). "Computed tomography of abdominal aortic aneurysm. An in vivo pathological report with a note on dynamic predictors." *Arch Surg* 123(6): 727-732. ISSN 0004-0010
- Politoske, E. J. (1990). "Ruptured abdominal aortic aneurysm presenting as an obstruction of the left colon." *Am J Gastroenterol* 85(6): 745-747. ISSN 0002-9270
- Ranasinghe, W., J. Loa, et al. (2011). "Primary aortoenteric fistulae: the challenges in diagnosis and review of treatment." *Ann Vasc Surg* 25(3): 386 e381-385. ISSN 1615-5947
- Reckless, J. P., I. McColl, et al. (1972). "Aorto-caval fistulae: an uncommon complication of abdominal aortic aneurysms." *Br J Surg* 59(6): 461-462. ISSN 0007-1323
- Sabiston, D. C. and C. M. Townsend (2008). *Sabiston textbook of surgery : the biological basis of modern surgical practice*. Saunders/Elsevier, ISBN 9781416036753
- Saiki, M., Y. Urata, et al. (2006). "Chronic contained rupture of an abdominal aortic aneurysm with vertebral erosion: report of a case." *Ann Thorac Cardiovasc Surg* 12(4): 300-302. ISSN 1341-1098
- Salo, J. A., K. A. Verkkala, et al. (1990). "Hematuria is an indication of rupture of an abdominal aortic aneurysm into the vena cava." *J Vasc Surg* 12(1): 41-44. ISSN 0741-5214
- Saratzis, N., A. Saratzis, et al. (2008). "Aortoduodenal fistulas after endovascular stent-graft repair of abdominal aortic aneurysms: single-center experience and review of the literature." *J Endovasc Ther* 15(4): 441-448. ISSN 1526-6028
- Scott, R. A., H. A. Ashton, et al. (1991). "Abdominal aortic aneurysm in 4237 screened patients: prevalence, development and management over 6 years." *Br J Surg* 78(9): 1122-1125. ISSN 0007-1323
- "Screening for abdominal aortic aneurysm: recommendation statement." (2005). *Ann Intern Med* 142(3): 198-202. ISSN 1539-3704
- Senadhi, V., J. C. Brown, et al. (2010). "A Mysterious Cause of Gastrointestinal Bleeding Disguising Itself as Diverticulosis and Peptic Ulcer Disease: A Review of Diagnostic Modalities for Aortoenteric Fistula." *Case Rep Gastroenterol* 4(3): 510-517. ISSN 1662-0631
- Shnacker, A., M. Witz, et al. (2001). "Acute thrombosis of an aortic aneurysm." *J Cardiovasc Surg (Torino)* 42(1): 111-113. ISSN 0021-9509
- Siegel, C. L., R. H. Cohan, et al. (1994). "Abdominal aortic aneurysm morphology: CT features in patients with ruptured and nonruptured aneurysms." *AJR Am J Roentgenol* 163(5): 1123-1129. ISSN 0361-803X
- Solberg, S. (1998). "[Curriculum vitae aortae]." *Tidsskr Nor Laegeforen* 118(30): 4644-4647. ISSN 0029-2001
- Song, Y., Q. Liu, et al. (2008). "Diagnosis and management of primary aortoenteric fistulas--experience learned from eighteen patients." *Surgery* 143(1): 43-50. ISSN 1532-7361
- Steffes, B. C. and J. P. O'Leary (1980). "Primary aortoduodenal fistula: a case report and review of the literature." *Am Surg* 46(3): 121-129. ISSN 0003-1348
- Stine, R. J. and S. J. Trued (1979). "Hiccups: an unusual manifestation of an abdominal aortic aneurysm." *JACEP* 8(9): 368-370. ISSN 0361-1124

- Suliman, A. S., J. D. Raffetto, et al. (2003). "Acute thrombosis of abdominal aortic aneurysms--report of two cases and review of the literature." *Vasc Endovascular Surg* 37(1): 71-75. ISSN 1538-5744
- Sweeney, M. S. and T. R. Gadacz (1984). "Primary aortoduodenal fistula: manifestation, diagnosis, and treatment." *Surgery* 96(3): 492-497. ISSN 0039-6060
- Tejada, E., G. J. Becker, et al. (1990). "Two unusual manifestations of aortic aneurysms." *Clin Cardiol* 13(2): 132-135. ISSN 0160-9289
- Thomson, V. S., K. G. Gopinath, et al. (2009). "Primary aorto-enteric fistula: a rare complication of abdominal aortic aneurysm." *J Postgrad Med* 55(4): 267-269. ISSN 0022-3859
- Trelinski, J., M. Stelagowski, et al. (2009). "[Disseminated intravascular coagulation in abdominal aortic aneurysm--case report]." *Pol Merkur Lekarski* 27(158): 116-118. ISSN 1426-9686
- Treska, V. (2003). "[The Einstein sign]." *Rozhl Chir* 82(2): 73-74. ISSN 0035-9351
- van Driel, M., B. van Gelder, et al. (1984). "Hematuria as a presenting symptom of an aortic-vena caval fistula from ruptured aortic aneurysm." *J Urol* 132(4): 774-775. ISSN 0022-5347
- van Zyl, H. P. (2005). "Paralysis: a rare presentation of abdominal aortic aneurysm thrombosis." *CJEM* 7(6): 420-422. ISSN 1481-8035
- Vigna, C., T. Santoro, et al. (2008). "Aortocaval fistula mimicking an acute coronary syndrome." *J Cardiovasc Med (Hagerstown)* 9(11): 1138-1139. ISSN 1558-2027
- Villegas-Cabello, O. and J. Siller (1999). "Asymptomatic rupture of an aortoiliac aneurysm." *Tex Heart Inst J* 26(3): 219-222. ISSN 0730-2347
- Vint, V. C., J. A. Usselman, et al. (1980). "Aortic perianeurysmal fibrosis: CT density enhancement and ureteral obstruction." *AJR Am J Roentgenol* 134(3): 577-580. ISSN 0361-803X
- Vu, Q. D., C. O. Menias, et al. (2009). "Aortoenteric fistulas: CT features and potential mimics." *Radiographics* 29(1): 197-209. ISSN 1527-1323
- Walker, D. I., K. Bloor, et al. (1972). "Inflammatory aneurysms of the abdominal aorta." *Br J Surg* 59(8): 609-614. ISSN 0007-1323
- Weinbaum, F. I., T. S. Riles, et al. (1984). "Asymptomatic vena caval fistulization complicating abdominal aortic aneurysm." *Surgery* 96(1): 126-128. ISSN 0039-6060
- Wijeyeratne SM, Ubayasiri R, et al. (2009). "Haematemesis due to primary aortic aneurysm-duodenal fistula - clinical suspicion is the cornerstone of diagnosis: a case report." *Cases J* 2(7803). ISSN 1757-1626-2-7803.
- Yeong, K. Y. (1995). "Angiographic demonstration of primary aorto-enteric fistula--a case report." *Ann Acad Med Singapore* 24(3): 467-469. ISSN 0304-4602



Diagnosis, Screening and Treatment of Abdominal, Thoracoabdominal and Thoracic Aneurysms

Edited by Prof. Reinhart Grundmann

ISBN 978-953-307-466-5

Hard cover, 414 pages

Publisher InTech

Published online 12, September, 2011

Published in print edition September, 2011

This book considers mainly diagnosis, screening, surveillance and treatment of abdominal, thoracoabdominal and thoracic aortic aneurysms. It addresses vascular and cardiothoracic surgeons and interventional radiologists, but also anyone engaged in vascular medicine. The high mortality of ruptured aneurysms certainly favors the recommendation of prophylactic repair of asymptomatic aortic aneurysms (AA) and therewith a generous screening. However, the comorbidities of these patients and their age have to be kept in mind if the efficacy and cost effectiveness of screening and prophylactic surgery should not be overestimated. The treatment recommendations which will be outlined here, have to regard on the one hand the natural course of the disease, the risk of rupture, and the life expectancy of the patient, and on the other hand the morbidity and mortality of the prophylactic surgical intervention. The book describes perioperative mortality after endovascular and open repair of AA, long-term outcome after repair, and the cost-effectiveness of treatment.

How to reference

In order to correctly reference this scholarly work, feel free to copy and paste the following:

Serosha Mandika Wijeyaratne (2011). Diagnosis of Aortic Aneurysm, Diagnosis, Screening and Treatment of Abdominal, Thoracoabdominal and Thoracic Aortic Aneurysms, Prof. Reinhart Grundmann (Ed.), ISBN: 978-953-307-466-5, InTech, Available from: <http://www.intechopen.com/books/diagnosis-screening-and-treatment-of-abdominal-thoracoabdominal-and-thoracic-aortic-aneurysms/diagnosis-of-aortic-aneurysm>

INTECH
open science | open minds

InTech Europe

University Campus STeP Ri
Slavka Krautzeka 83/A
51000 Rijeka, Croatia
Phone: +385 (51) 770 447
Fax: +385 (51) 686 166
www.intechopen.com

InTech China

Unit 405, Office Block, Hotel Equatorial Shanghai
No.65, Yan An Road (West), Shanghai, 200040, China
中国上海市延安西路65号上海国际贵都大饭店办公楼405单元
Phone: +86-21-62489820
Fax: +86-21-62489821

© 2011 The Author(s). Licensee IntechOpen. This chapter is distributed under the terms of the [Creative Commons Attribution-NonCommercial-ShareAlike-3.0 License](https://creativecommons.org/licenses/by-nc-sa/3.0/), which permits use, distribution and reproduction for non-commercial purposes, provided the original is properly cited and derivative works building on this content are distributed under the same license.

IntechOpen

IntechOpen