

We are IntechOpen, the world's leading publisher of Open Access books Built by scientists, for scientists

6,900

Open access books available

185,000

International authors and editors

200M

Downloads

Our authors are among the

154

Countries delivered to

TOP 1%

most cited scientists

12.2%

Contributors from top 500 universities



WEB OF SCIENCE™

Selection of our books indexed in the Book Citation Index
in Web of Science™ Core Collection (BKCI)

Interested in publishing with us?
Contact book.department@intechopen.com

Numbers displayed above are based on latest data collected.
For more information visit www.intechopen.com



Advanced Lipotransfer Techniques

Guillermo Blugerman et al.*
Argentina

1. Introduction

1.1 Liposhifting: Treatment of post-liposuction irregularities

One of the most frequent complications after liposuction is the presence of residual fat accompanied by surface irregularities such as ridges, waves and depressions.

According to some statistics, about 15 to 20% of liposuction require some type of secondary correction to fill irregularities or should have a second session of liposuction to improve the result. Gerald Pittmann ⁽¹⁾ states that a 15% required minor adjustments or lipofillings in office, and 9% required a second liposuction with or without lipofilling.

Until 2001, post-liposuction irregularities were attempted to be corrected by auto-graft of fat cells aspirated from other body areas, with varying results over time ⁽²⁾. Lipofilling as unique technique has not proven to be the correct solution for such irregularities. There is evidence that the transfer of large volumes of fat in an unfavorable area, as it occurs after liposuction does not survive. In our opinion this is not the best option to fill post-liposuction irregularities ^(3,4). In 2001, after many years of disappointment with fat fillings in post-liposuction irregularities, Dr. Ziya Saylan ⁽⁵⁾ decided to internally mobilize the surrounding fat tissue to the affected area without any vacuum, suction, contact with air or injection. He named this new technique liposhifting. With internal lipomobilization or liposhifting, the fat tissue is cut into micro grafts that are mobilized under the skin without any suction and without removing the fat from the body during the procedure. Avoiding contact with air lowers the risk of apoptosis promoted by dehydration of fat tissue. After the internal lipomobilization a special type of bandage and fixation is needed for the first 48 hours. The results obtained have been very satisfactory.

1.2 Our approach

Our experience is that the lipofilling of small liposuction irregularities can be useful, but never offers a long-term outcome for large irregularities or undulations. After a few months, a great quantity of the injected fat disappears and sometimes patients complain of new

* Roger Amar¹, Diego Schavelzon², Marco A. Pelosi II³, Marco A. Pelosi III³, Javier A. Soto⁴, Anastasia Chomyszyn², Maurizio Podda⁵, Andrea V. Markowsky⁴, Jorge A. D'Angelo⁴ and Rodrigo Moreno⁴

¹Amar Clinic, Marbella, Malaga

^{2,4}Centros B&S "Excelencia en Cirugía Plástica", Buenos Aires, Argentina

³Pelosi Medical Center, Bayonne, NewYersey

⁵Department of Dermatology of Darmstadt Hospital, German,

⁴Universidad Nacional del Nordeste, Corrientes, Argentina

undulations at the donor site. In liposhifting, as published by Saylan, avoiding suction (which causes tissue damage), by not removing the tissue from the body (no pressure, no contact with air) and no re-injection (applied external force on the fat to be grafted), ensures the production of adipose tissue micro-grafts of excellent quality and vitality.

Based on this work, in 2001 we began to apply the technique originally described by Saylan, with good results but, looking for a more predictable result, in 2002 we therefore designed a set of specific instruments for this useful technique ^(6,7,8,9). (Fig. 1)



Fig. 1. Liposhifting instruments set.

This set of instruments has three basic elements.

- A spatula dissector with atraumatic flat and round tip to make pre-tunelization of the receptor area with minimal bleeding given that hematoma formation diminishes the possibility of "engraftment of fat."
- A tubular knife cannula named Micro Graft Fat Cutter, (MGFC) with multiple cutting edge holes of 1.5 mm in diameter, distributed in the first 2 centimeters from the tip and two holes of 3 mm in diameter located proximately to allow the output without damaging the fat tissue micrografts. This instrument looks similar to a liposuction cannula, its main difference is that it has no connection to the vacuum pump, and operates as a "cheese grater" in the fatty tissue, cutting and releasing microscopic portions of adipose tissue in the donor areas, which remain floating in the tumescent solution.
- The third element is a roller that is used over the skin surface in order to mobilize these grafts in the spatula creating tunnels in the recipient area.

1.3 Patient selection

Patients that can be favored with this technique are those with a localized deficit of adipose tissue, with available donor areas around them.

This group includes:

- Sequelae of liposuction.
- Fat atrophy from application of steroids.
- Circular fat atrophy.
- Depressed scars or scars adhered to deep planes.
- Sequels of abscesses or hematomas drainage.
- Traumatic fat atrophy.
- Irregularities after lipofilling.

1.4 Technique

This procedure must meet the following stages:

- Pictures with frontal and tangential light. (Fig. 2)
- Marking the skin with the patient standing.
- Tumescence Anesthesia.
- Creation of receptor tunnels in the depressed zones (receptors).
- Preparation of adipose tissue micrografts with MGFC in the donor area.
- Mobilizing micrografts.
- Tunneling
- Stabilization of mobilized tissue. (Microporing and Reston foam for fixing)

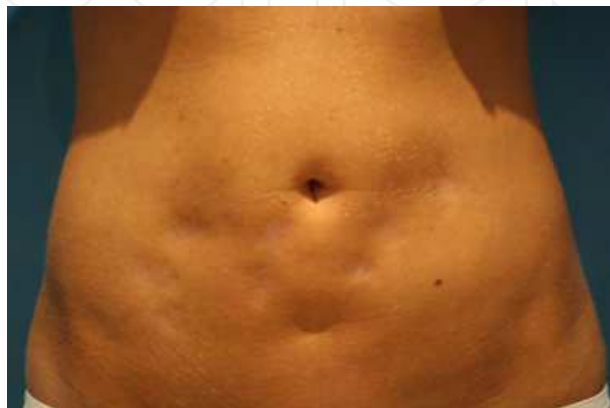

Fig. 2. Taking photographs with a tangential light is an important key to document the patients defect. See patient post-op in Fig. 5.

1.4.1 Marking the skin

The marking of the skin is very important because the tumescent anesthesia hides the fat irregularities. The markings have to be done while the patient is standing, which allows the surgeon to locate appropriate sites for liposhifting. Edges, elevations and undulations should be marked with different colors. Do not forget that when the patient lies on the operating table fatty deposits surrounding depression can change their position. The place where the fat is required should be marked (receiving area) with one color and the surrounding area where the tissue is obtained (donor area) with a different one. Photographic documentation of marking is very important for future comparison (Fig.3)

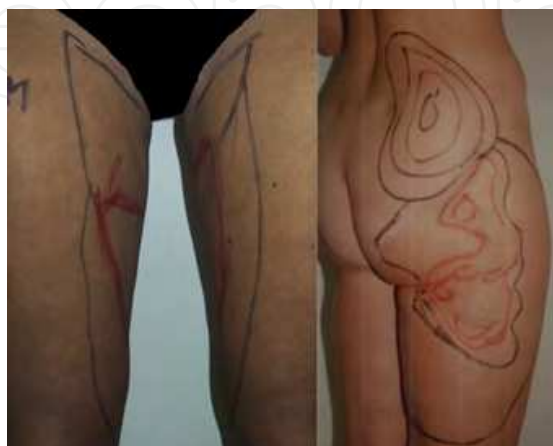

Fig. 3. A previous marking and photograph is important for an optimal result.

1.4.2 Anesthesia

We perform this type of procedures under tumescent anesthesia ⁽¹⁰⁾ given that the presence of fluid facilitates the internal mobilization of the micrografts, and this also allows us to vary the position of the patient during the procedure for the proper location of the fat to be mobilized.

1.4.3 Tumescent technique

The tumescent solution is used to lubricate the adipose tissue, to provide anesthesia, to stabilize tissues and also to re-expand the collapsed areas by excessive resection of adipose tissue in previous liposuction.

After infiltration of tumescent solution, time is required to diffuse into the tissues, lending the necessary vasoconstriction to reduce the risk of hematoma and allowing the instrument to glide smoothly cutting accurately the micrografts.

1.4.4 Tunneling or tunnel creation in the target tissues

The spatula is inserted through a two mm incision in the skin held from the edges of the marking, at least 3 cm to prevent graft loss during mobilization maneuvers. Multiple tunnels must be made throughout the thickness of subcutaneous tissue (SCT). These tunnels will be used as beds for fat grafting receptors.

It is important to use the spatula's flat tip perpendicular to the skin surface to diminish trauma of the vascular plexus that runs along the walls of the SCT from the muscles to the skin. (Fig.4)

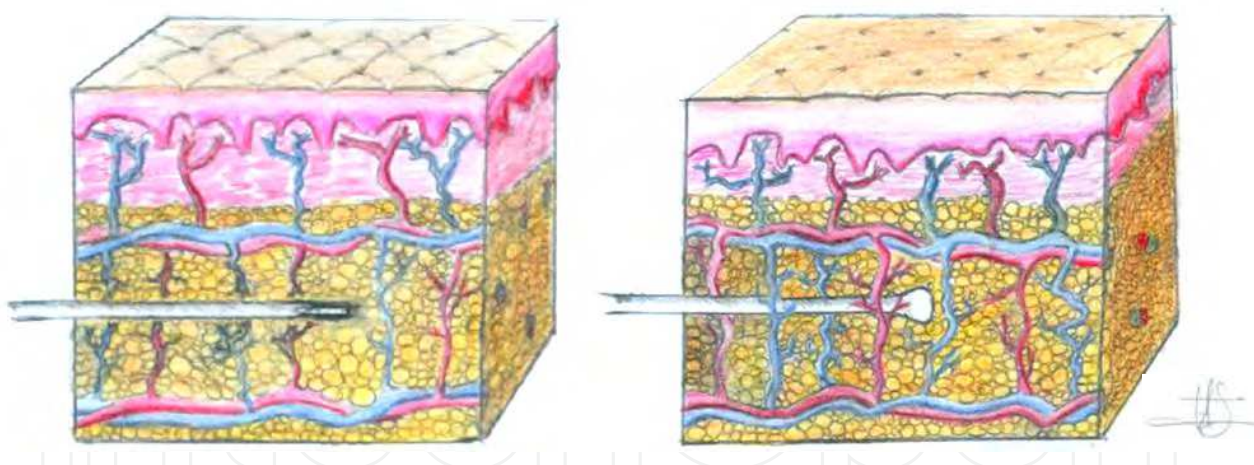


Fig. 4. Incorrect way of using the spatula cannula when doing the tunnels, will lead to damage the blood vessels.

The correct way of using the spatulated cannula is perpendicularly regarding the skin, thus preserving the vascular plexus.

1.4.5 Preparation micrografts

Tumescent anesthesia stabilizes the fatty tissue of the donor area allowing the fat to acquire consistency enough so it can be cut with the edge of the holes of the cannula. For this purpose, we introduce the MGFC through the same incision, to be mobilized under the skin in a criss-cross technique to produce grafts from the donor areas.

1.4.6 Quality of the micrografts

To assess the quality of micrografts and their ability to survive, Dr Maurizio Podda ⁽¹¹⁾ in 2003 conducted a study in the Department of Dermatology at the Goethe University of Frankfurt. The study consisted of the separation of fat cells obtained from different types of cannulas and a portion cut with a scalpel with collagenase. They measured total lipids and DNA. Lipolysis was stimulated in these cells with Isoproterenol and Fosfokin, and the production of glycerol was spectrophotometrically measured.

These evaluations established that grafts taken with a scalpel, with Liposhifting cannula and vibrating cannula tip were the ones which showed greater survival rate.

The results have shown that micrografts obtained with cannula Liposhifting have the same quality and percentage of survival than those obtained with a scalpel and were better than those obtained with vacuum suction (fig.4).

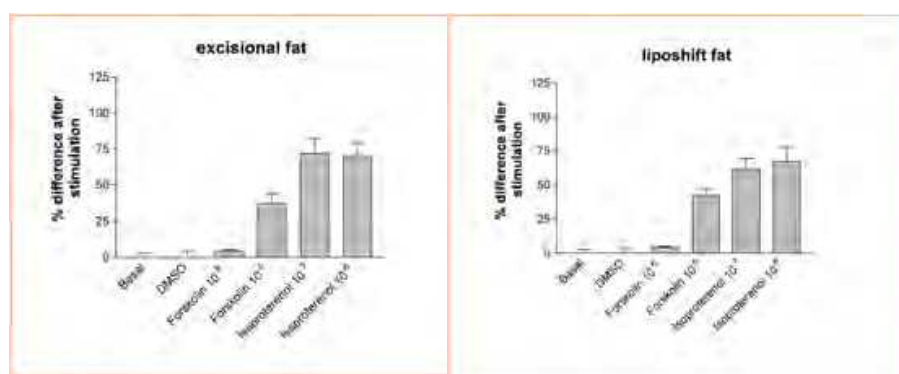


Fig. 4. Dr Maurizio Podda's study showing similar survival rate from the grafts taken with the scalpel and the MGFC.

1.4.7 Mobilization

The mobilization of fat under the skin is effected by rolling maneuvers and massages on the skin directed from the donor to the recipient areas.

A 6-9mm thick cannula may be useful for this purpose. The cannula is held in the surgeon's hands like a rolling pin, and the fatty tissue under the skin will move to the imperfection that is to be filled. The place to fill must be watched very carefully and when the pit is full it reaches the same level of the surrounding skin, overcorrection of 20-30% is thought to represent the amount of tumescent solution which will be absorbed in a few hours. During these maneuvers the entrance hole should be closed with a suture to prevent loss of micrografts.

1.4.8 Fixation

After fat mobilization into the depressed area, a Micropore® tape fastening and Reston® are placed to keep the fat in its new site. Pressure is applied to the donor parts and no compression is left in the receiving areas. The film and the setting can be removed after 72 hours.

1.5 Results

We have applied this technique in 140 patients over a period of seven years. Some cases with large defects should be treated more than once. This should be explained to the patient before surgery. An interval of 4 to 6 months is recommended between treatments. The final

results are not ready before 3-6 months. The rate of patient satisfaction was nearly 90%. The same results were obtained by other authors ⁽¹²⁾ (Fig.5, 6 and 7).

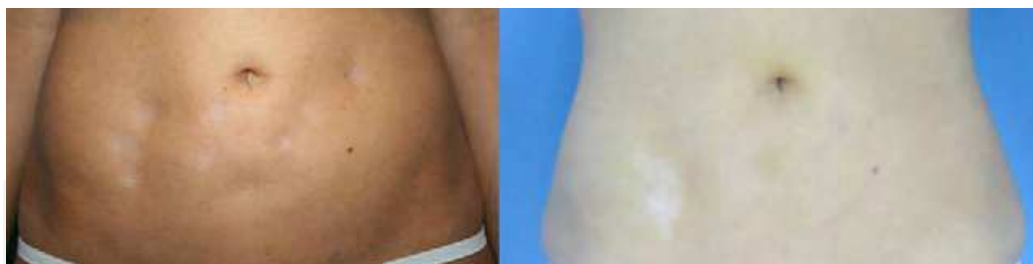

Fig. 5. Pre-operative and post-operative results of liposhifting after 10 months, in a patient with fat and dermal atrophy after intralesional steroid injection.

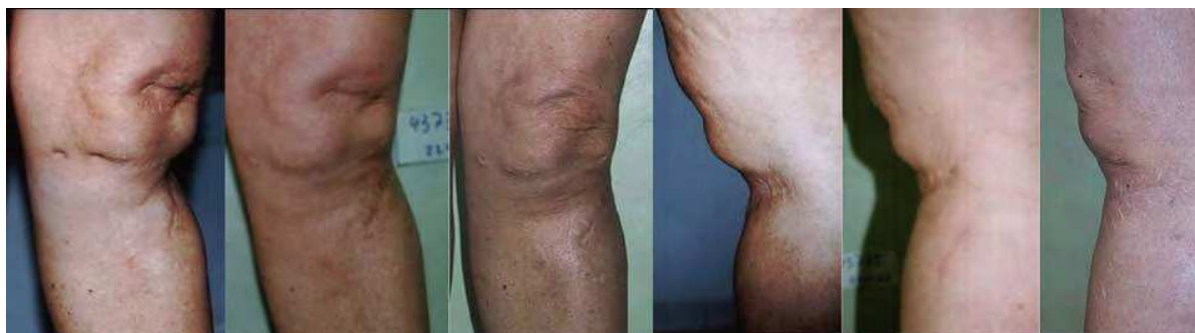

Fig. 6. Pre-operative and post-operative results in traumatic scarring in knee.

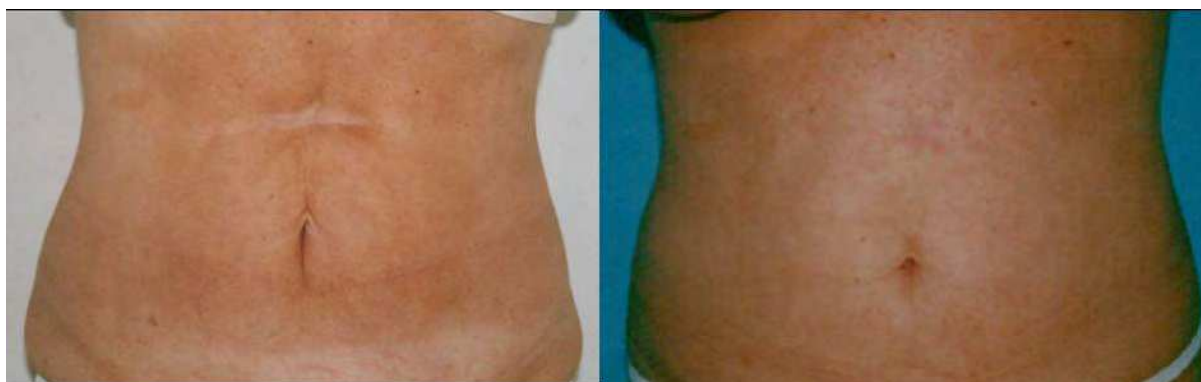

Fig. 7. Before and after liposhifting of a post-liposuction defect.

1.6 Complications

The most common complication was hematoma at the recipient site when we used sharp prongs for tunneling, the incidence decreased markedly with the use of a spatula perpendicularly to the skin.

We had no cases of infection. Hypoesthesia was more often seen than in liposuction, but it disappears after a few months.

Hemosiderin pigmentation (pigmentation of the superficial dermis by the iron in the blood) was seen in two cases that had bruises and remained between 6 and 9 months. In these cases we used a gel with heparinoids that enhances resolution.

1.7 Conclusions

We believe Liposhifting is a very good technique to eliminate extensive and deep subcutaneous tissue irregularities caused by liposuction or due to trauma and previous surgery. As a single procedure it reduces the volume of surrounding tissue and fill the central defect, so that ultimately a smaller volume of tissue is moved and so the success rate rises considerably.

It is useful both in the limbs and in the abdominal region. It is practical and safe. The risk of contamination of the fat transplant, having no contact with air, is impossible. The fixation of the treated region is very important to stabilize the mobilized fat and to raise its survival.

2. Enriched adipose micrografts with autologous plasma (EAM)

2.1 Summary

Liposuction fat transfer used to fill facial and body areas is now one of the most fascinating treatments of plastic, reconstructive, and cosmetic surgery.

Still today it is common to have reports of failures with the traditional technique of harvesting by liposuction, which is why we have refined the technique in each step in order to obtain Micrografts of adipose tissue that are of better quality to ensure a good survival of these once grafted into the recipient area.

Micrografting implantation in combination with Total Plasma (TP) or Platelet Rich Plasma (PRP) has allowed in our hands to achieve more predictable and permanent results opening a wide range of therapeutic possibilities, ranging from cosmetic to reconstructive procedures.

Plasma from the patient is an autologous non-toxic, non allergenic preparation, easily obtained by centrifugation of blood. Once the platelets are activated and mixed with the collected micrografts, you obtain a gel that is a natural support for the transplanted tissue, favoring the formation of extracellular matrix, collagen fibers and angiogenesis in an accelerated way. It promotes neovascularization and decreases the reabsorption of the grafted adipose tissue.

In our opinion, Enriched Adipose Micrografting (EAM) is now the ideal material for the restoration of aesthetic or postraumatic subcutaneous tissue defects of the face and body.

2.2 Introduction

The use of autologous fat as a filler has been around for over 100 years. In 1983 ^(13,14), fat grafts were made to achieve tissue remodeling and improve asymmetries with good results. In 1910 Erix Lexer ⁽¹⁵⁾ used autologous fat to improve depression made from zygomatic fractures with acceptable results and stable for years, and later, Peer ⁽¹⁶⁾ reaffirmed the use and survival of these grafts. The biggest problem remained the need for extirpation of adipose tissue through acceptable skin incisions.

The introduction of liposuction in the 80's opened new possibilities of obtaining fat and subsequent grafting, without scarring sequelae in the donor area. Our first results were presented at the Brazilian Congress Belho Horizonte in 1986 ⁽¹⁷⁾. Since then we continue to improve our technique, looking for the best protocol to cover all aspects of this procedure, despite being easily reproducible, it has a high rate of failure if the basic principles of tissue transplantation are not respected ⁽¹⁸⁾.

This chapter summarizes our current technique of EAM, based on the results of the last 5 consecutive years of its application.

2.3 Healing and growth factors

Healing is a process that takes time and compliance with a series of steps that begin with the activation of multiple growth factors. The increased availability of these factors during this process shortens time and improves results, reducing inflammatory reaction and scarring sequelae.

The availability of growth factors (GF) at the tissue level may be increased using autologous platelet concentrate obtained from the patient's own blood.

Growth Factors (GF) are polypeptides of amino acids that form a globular protein and belong to the group of cytokines. They are produced in greater quantities by macrophages and platelets ^(19, 20).

These cytokines have the ability to join cell membrane receptors that activate or inhibit cellular functions by target cells on which they act.

The most studied growth factors are:

- The epithelial growth factor. It was the first to be discovered. It induces proliferation of epidermal cells in-vitro. It is a peptide of 52 amino acids produced by keratinocytes, platelets, the kidney, the gastrointestinal tract and the brain. It stimulates the synthesis of DNA and RNA from keratinocytes and fibroblasts, and helps in wound repair.
- The Growth Factor of Fibroblasts is a peptide derived from fibroblasts. It increases the division of the keratinocytes, promotes epithelialization of the tissues and provides tensile strength to collagen matrix.
- The Growth Factor, Platelet-derived is the one with the highest participation in wound repair. Its effect is vasoconstriction and stimulation of mitosis and chemotaxis of polymorphonuclear cells, monocytes, keratinocytes, fibroblasts and endothelial cells. The arrival of platelets to the site of injury causes a rapid activity of this factor and therefore an early wound repair.
- The use of growth factors was initiated in the field of maxillofacial surgery and dentistry as a biological material to stimulate bone remodeling, and then its use was expanded to other areas of medical science.

2.3 EAM Indications

2.3.1 Facial corrections

- Poorly defined jaw line.
- Naso-labial fold, looking sad or tired.
- Lip augmentation to correct thin lips achieving greater volume and more youthful appearance-^(21, 22, 23).
- Asymmetries or lack of volume on cheeks and malar or chin area.
- Facial lipo-dystrophy in patients with HIV treatment or Romberg Syndrome ⁽²⁴⁾.

2.3.2 Body corrections

- Surface defects by subsidence, posttraumatic sequelae or scarring.
- Imperfections or asymmetries from previous surgical procedures.
- Hand defects, reaching its rejuvenation ⁽²⁵⁾.
- Buttock contour deformities ^(26, 27, 28).
- Any type of asymmetric atrophy or hypotrophy of soft tissue.
- Correction or lengthening of the penile region ⁽²⁹⁾.
- Post-Mammary Implant deformities, with or without removal of implant placed.

- Breast deformities such as: Tuberoze breast, micromastia, Poland Syndrome, breast tissue damage by radiation therapy.
- Post-surgical chest deformities.
- Defects caused by conservative or reconstructive breast treatment using implants and/or flaps (latissimus or rectus abdominis).
- Cosmetic-gynecological procedures.

2.4 Surgical technique

2.4.1 Documentation and marking ⁽³⁰⁾

The recognition of the problem areas must be made initially (donor and recipient) by the surgeon, in consultation with the patient, documenting them with pictures. Patient selection and the realistic expectations of possible outcomes are important points to arrive at a good percentage of satisfied patients. Photographs, as well as the marking of the patient, are made standing so that the posture does not change the default. In some surface defects, a tangential light on the skin is useful for a better documentation and marking of the defects. It is important to use natural colored long-term markers to avoid erasure during the procedure. The main issue to consider when choosing the donor site is to approach a site with adequate tissue volume, which is specific to each patient, and also taking into account the surgeon's preference. There is no heavy evidence on the choice of the donor site in the efficacy of fat grafting, but some studies suggest that there are areas with a higher number of stem cells than others.

2.4.2 Obtaining inactive plasma

Before starting the procedure, obtain a blood sample from the patient, and then process it, to obtain the TP, or PRP, given that, after the surgical procedure has started, there is going to be a lower platelet count in the patient's blood.

Following our protocol we proceed to extract the blood with a 20 ml sterile syringe in cases where the treatment was carried out in the facial region and a 40 ml of blood when the treatment was performed in a body area. (Fig. 8)

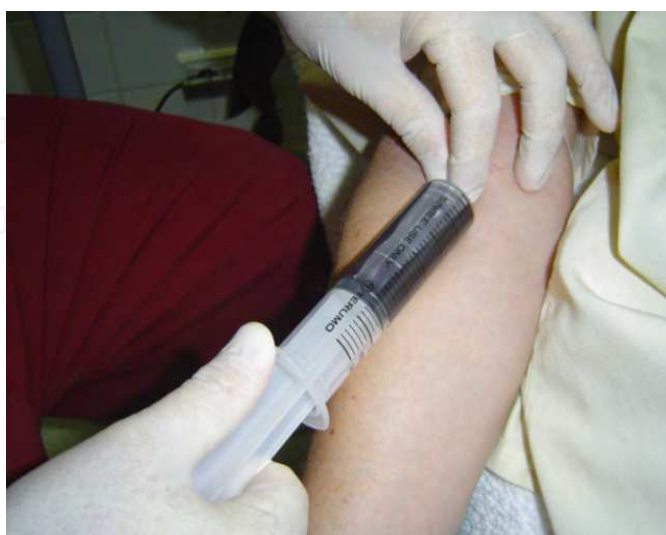

Fig. 8. Obtaining the patient's blood before the surgery is important to maintain a good platelet count.

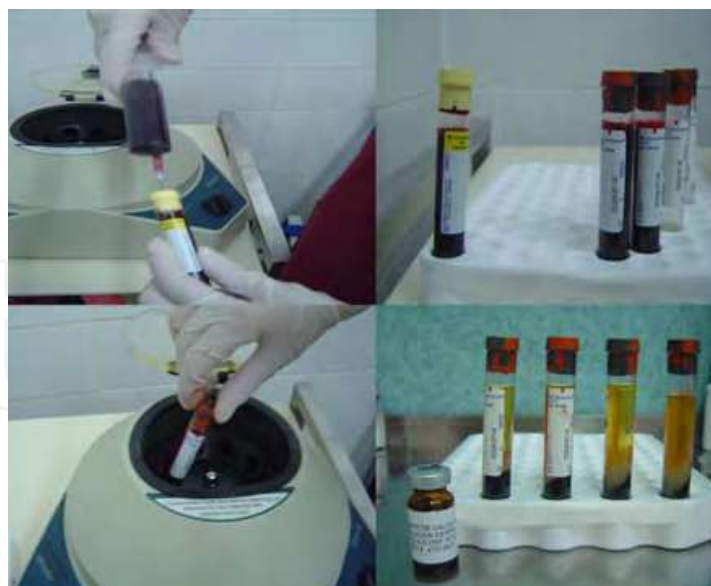


Fig. 9. Blood components separation process.

The blood is collected in tubes of 8.5 ml. each, containing calcium citrate (BD Vacutainer ® ACD Solution A) to prevent activation of the coagulation process. Then the anticoagulated blood is passed to other special tubes that contain a separation gel (BD Vacutainer ® SST) that allows mechanical separation of red cells and plasma during centrifugation. The separation process is performed at 3000rpm for 10 minutes using our equipment, so this step will be adaptable to the functionality of each centrifuge. (Fig.9.)

2.4.3 Anesthesia of the donor area

The use of epinephrine or lidocaine in the donor site, has been accused to affect the viability of the graft, but there is not much research about it. Following the previous markings anesthetic infiltration of the donor site is performed using tumescent anesthesia with a solution composed of 0.06% lidocaine with epinephrine 1:1000000 and 12.5 meq of sodium bicarbonate for each liter of saline (0.9%Na Solution). The infiltration is performed using Klein cannulas connected to the B&S peristaltic pump ⁽³¹⁾.

2.4.4 Anesthesia of the receiving area

Likewise, through microcannulas or selected needles according to the graft area, we proceed with local anesthesia of the receiving area previously marked. Same concentrations of tumescent anesthesia are used without infiltrating large quantities of liquid, so it does not modify the area to be corrected, achieving only anesthetic effect. In the face we prefer the nerve blocks as described by Amar ⁽³²⁾.

2.4.5 Preparing micrografts of adipose tissue ^(33, 34, 35, 36, 37, 38, 39)

The main points to consider when taking the tissue are the degree of tissue invasiveness (patient safety) and tissue viability (efficiency). With this in mind, mechanical damage is minimized in this step.

In our protocol, the procedure requires the use of specific instruments, which we called MGFC (Micro Graft Fat Cutter) or BGC (Blugerman Graft Cutter). (Fig.10)

In the study by Dr. Maurizio Podda, University of Frankfurt ⁽⁴⁰⁾ it was found that the

micrografts obtained with our instrumental had the same characteristics and survival rate than grafts cut with a scalpel, surpassing those obtained with liposuction cannulas. This instrument could be defined as a tubular multiscalpel that works without suction or vacuum, cutting edge micrografts by presenting the holes, which act similarly to those of a grater, aided by external compression of the fingers pushing the adipose tissue into the holes to facilitate the splitting of the tissue.

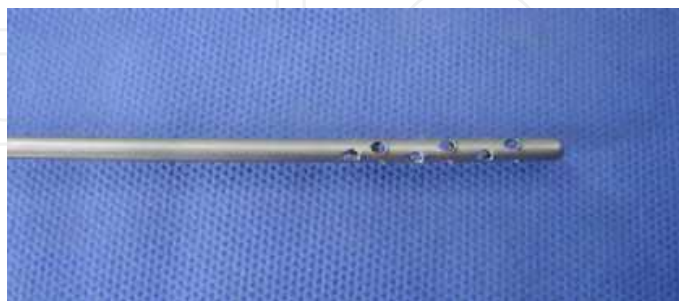

Fig. 10. Blugerman Graft Cutter (BGC).

Micrografts produced by the actions of MGFC remain suspended in the tumescent solution in the donor area, ready for collection.

2.4.6 Collection of manufactured micrografts

To collect the micrografts we prefer to use a 3 to 4 mm large hole atraumatic blunt cannula. This step is performed by sucking the material with 10 ml syringes at low vacuum pressure, when the volume required is small, or with a B&S peristaltic pump when volume is larger. In our hands, using the B&S peristaltic pump to recover micrografts in the donor site allows us to work in a closed circuit, minimizing the risk of contamination, preventing the entry of large volumes of contaminated air and avoiding the "Cyclone" effect inside the bottle. Reduced air contact also avoids fat dehydration with a consequent decreased rate of apoptosis, thus ensuring a better vitality of micrografts.

2.4.7 Settling or centrifugation of the material ^(41, 42, 43, 44, 45, 46, 47, 48)

When we work in the facial region, the material obtained is centrifuged at 3000 rpm for 3 minutes to separate the micrografts from the tumescent fluid and the oil resulting from the rupture of adipocytes.

When using volumes exceeding 100 cc. we prefer to decant the material, without any filtering or transfer.

The special features that our system has, allow the tissue to be sucked in through a hole in the bottom of the collector and immediately there is an automatic washing of grafts in the previously sucked fluid, making the process of separation by gravity faster and more efficient than using a top hole bottle. This avoids the need of any material washing before implanting and minimizes the risk of contamination.

Finally, by reversing the direction of rotation of the peristaltic B&S pump, tumescent fluid is removed leaving only the concentration of micrografts ready to use.

2.4.8 Plasma activation

The platelet concentrate (600,000 to 1,500,000 x mm) obtained from blood centrifugation has a first supernatant that corresponds to the platelet-poor plasma (PPP), and the second

corresponding the Platelet Rich Plasma (PRP), which is the portion closest to the Red Blood Cells (RBCs). (Fig.11)

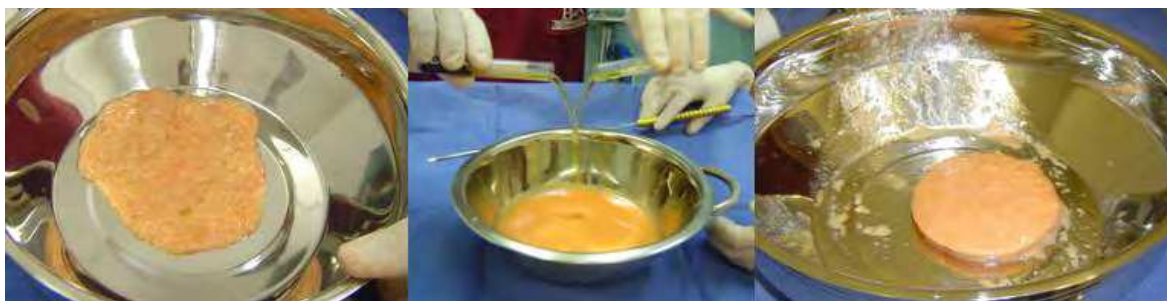

Fig. 11. Enriching the adipose tissue micrografts with plasma. EAM gelification.

When using facial EAM, in which precision in milliliters is important, we use only the PRP to prevent dilution of micrografts.

When working in the body area, we use TP, as we add the PRP properties to the PPP, which is the residual plasma and contains clotting factors, mainly fibrinogen, thrombin and calcium molecules that stabilize the blood clot and contribute to a rapid and effective healing of the soft tissues.

In our experience the use of total plasma (PPP + PRP) in the process has submitted satisfactory and comparable with the use of PRP only, while this allows simplifying the procedure and reduces material handling with the risk of contamination.

Technically you activate the PRP or PT by adding 10% CaCl (0.05 cm³ of CaCl per 3 ml), thereby activating the coagulation cascade.

2.4.9 Preparation of the recipient's site ⁽⁴⁹⁾

Antisepsis of the recipient area and placement of surgical wraps are performed. If the local anesthesia of the recipient region has not been previously performed, this is the moment to do it, before the infiltration of the micrografts. Depending on the region to be treated micro-incisions are carried out taking into account the location of the defect and the aesthetic result on the skin.

2.4.10 Injection technique of EAM ^(50, 51)

To optimize the viability of enriched adipose micrografts the mechanical damage of the implanted tissue has to be minimized.

In the face we follow the basic principles of the FAMI technique.

In the body, we prefer subcutaneous implantation of the grafts instead of the muscular implantation, thus lowering the risk of fat embolism.

Prior to the implantation of micro grafts, the technique of pre-tunneling of the subcutaneous tissue (SCT) is done with the spatulated cannula (Fig. 12). By using the spatulated cannula it creates paths or tunnels on several levels where the micrografts will be deposited for better distribution.

This pre-tunneling should be done with the bevel of the spatulated cannula perpendicularly in respect to the surface of the skin in an attempt to preserve the sub-dermal plexus, which is highly needed to ensure rapid revascularization and consistent implementation of micrografts.

The preservation of the vascular elements also reduces the risk of hematoma, which if present leads to necrosis due to the loss of oxygenation and nutrition of micrografts in their early stages.



Fig. 12. Luer-loock cutter.



Fig. 13. Spatulated cannula.

From the mixing of micrografts and PRP or TP a gel is obtained (EAM) that is placed in 1 ml syringes when implemented in the facial region and in 5, 10 or 20 ml when used in the body. The syringes should have a Luer-Lock receptor. Using a special tool, the central portion of the beak is removed to increase the diameter of the hole through which the micrografts must pass. (Fig. 13)

Material injection in the facial area is performed using a set of micro-cannulas designed by Dr. Roger Amar, specific to each area and depth of the tissue following the FAMI technique parameters (fig 18).

When working in the body area we prefer the 1.5 to 3mm Tulip spatulated cannula (Fig. 14).

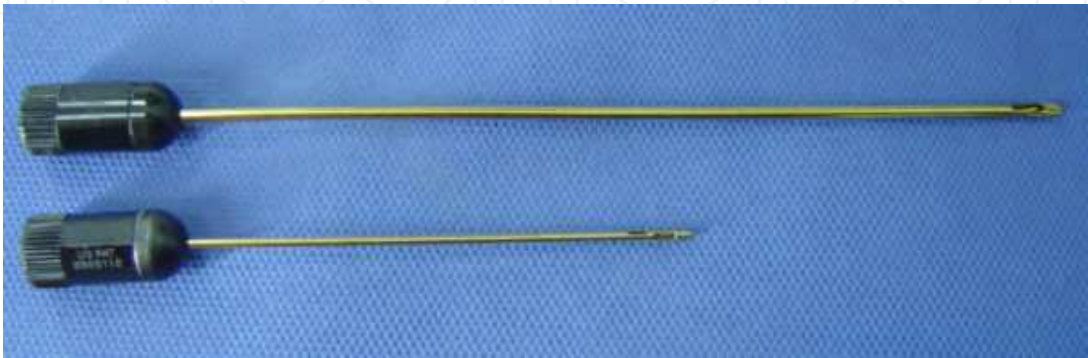

Fig. 14. Long and short tulip spatulated cannulas.

2.4.11 Retunnelization

After the implementation of the micrografts, the spatula is reintroduced and new re-tunneling maneuvers are done using the same instrument that will continue to work perpendicularly to the skin. This maneuver will redistribute the grafted tissue more evenly and will reduce the compression exerted from the surrounding tissues to the micrografts.

2.4.12 Post-operation bandage

At the end of the procedure a bandage of the micro-incisions with sterile Micropore® tape is done in the recipient's area, exposing the treated area and leaving it free of compression. In special cases Reston® may be applied to keep the implanted areas free from external pressure. The donor site incisions are left opened to promote drainage of the tumescent solution, sterile dressings are placed and compressive bandaging is applied.

2.5 Risks and complications associated with fat grafts

- There were no reported cases of complications related to anesthesia and the use of fat grafting. These complications are rare considering that most cases are performed under local anesthesia with or without sedation, which minimizes the risk of surgery.
- Some cases were reported of patients with prolonged inflammation, Staphylococcus infection and septic shock, most treated with antibiotic therapy (52, 53).
- Regarding blood loss there were reported cases of seroma or hematoma associated with this procedure, but none were severe or unresolved (52, 53).
- Poor results or expectations that do not cover expected are rare (52, 53, 54, 55). In general the results of this procedure are reported as excellent or good. Most cases reported as unsatisfactory, are due to the volume loss of the grafted tissue due to necrosis or reabsorption.
- Cases of graft hypertrophy or overgrowth have been documented on rare occasions.
- Other complications include the formation of calcified and non calcified masses.
- As for its relationship with breast cancer, although there is no strong evidence of interference, fat grafting is not recommended in patients potentially biased (56, 57, 58).
- Two cases of breast cancer were reported after the completion of fat grafts; however, this procedure did not interfere with the detection and treatment.
- Imaging studies (ultrasound, mammography and MRI) can identify fatty tissue grafts as micro-calcifications or the presence of suspicious lesions, determining the need for a biopsy to clarify the diagnosis if required.
- Based on the limited number of cases reported, we can establish that fat graft does not interfere with breast cancer, but further studies still needed to confirm.
- Other risks that should be taken into account are the level of invasiveness during the procedure, the experience of the surgeon and unforeseen complications during the procedure.
- The potentially severe or fatal cases are rare, considering the invasiveness of the procedure and the frequency with which it is performed.
- Patients should know the risks and potential complications, and sign an appropriate informed consent of the procedure (52, 53, 54, 55).

2.6 Results

We have used this EAM protocol over the past 5 years. (Fig. 15, 16 and 17)

During this period we have performed a total of 945 EAM procedures. 234 corresponded to facial applications and 711 to body applications. The patient satisfaction was high in all procedures. Our complication rate was less than 10 %.

It is important to inform patients about the possibility of re-implantation of new micrografts in the treated area, based on the concept of a progressive increase in volume, so that the patient is prepared for this eventuality.

In our case the need for further sessions of EAM depended on the degree of the defect and the results achieved, with a maximum of 3 sessions in the most complex cases which corresponded to 15% of the treated cases.

It is clear that in most cases the second procedure corresponded to minor corrections or minimum volume of tissue irregularities.

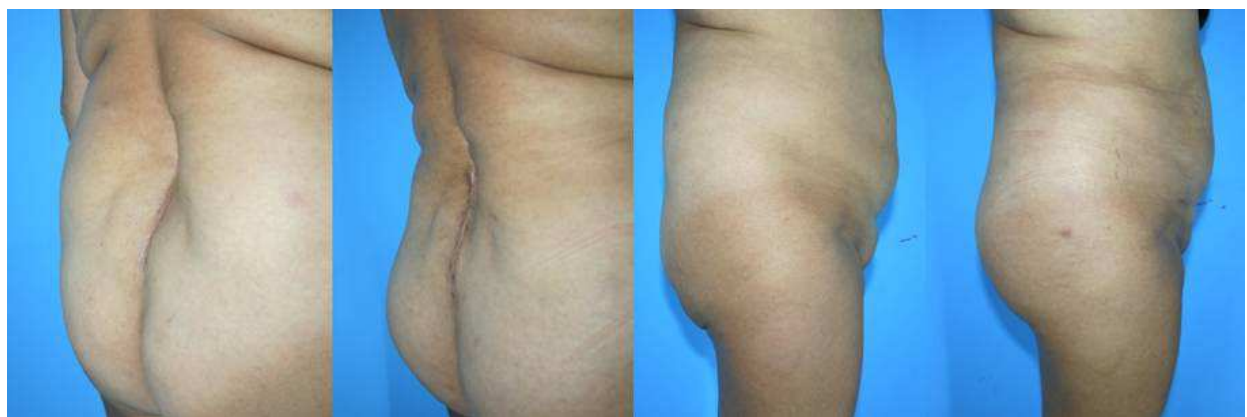

Fig. 15. Before and after RFAL in upper and lower back combined with 250cc of subcutaneous EAM in each buttocks.

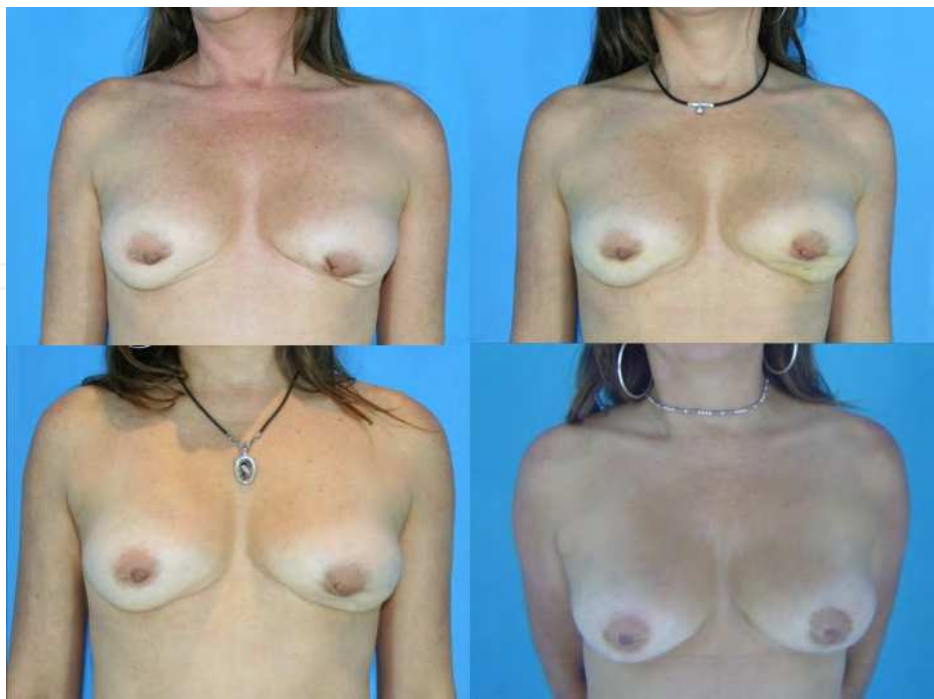

Fig. 16. Patient with multiple mammary implant replacement due to implant rejection, which later on is treated with EAM for breast augmentation and correction of the sequelae.

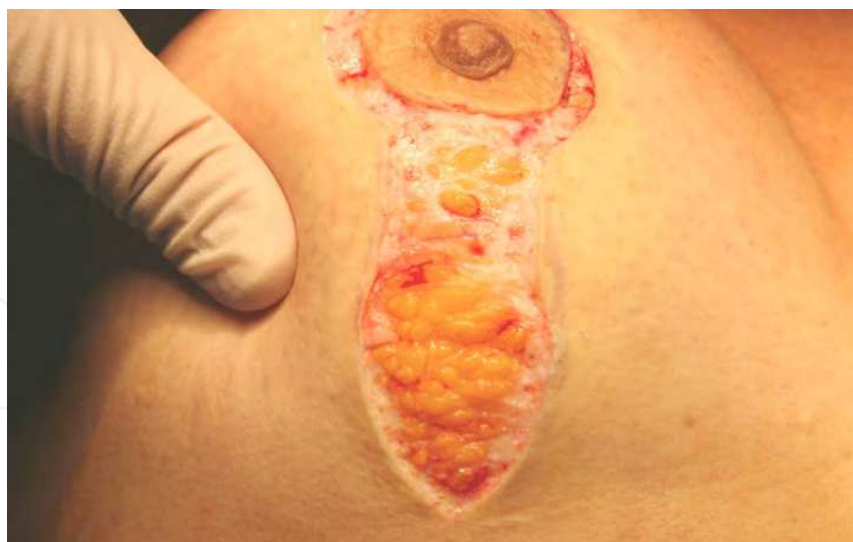

Fig. 17. Same patient, 6 months later from the last EAM, when doing a vertical mastopexy we found the good quality of the previously grafted adipose tissue.

2.7 Conclusions

The combination of adipose tissue micrografts with concentrate PRP or PT allows us to accelerate the restoration of facial and body tissues, with a low risk of complications when using autologous material.

We noticed that the resulting gel is easier to enter through the cannula, creating less friction and requiring less pressure for the passage of the micrografts through the syringe to the prefabricated tunnel. Prefabrication of these tunnels reduces the resistance of the tissues to the entrance of the micrografts, facilitating transplantation and uniform distribution.

In our experience the use of EAM has increased fat graft survival in all body areas, further improving the quality of skin in patients with radiation dermatitis or skin atrophy and achieving greater satisfaction for our patients.

3. The FAMI procedure (fat auto-grafting muscle Injection): an anatomically based pan-facial rejuvenation with adipose stem cells

3.1 Introduction

The use of autologous fat for facial augmentation has been advocated for over a century^(59, 60). Interest in facial fat grafting intensified twenty years ago with French authors using rough decanted lipo-aspirates to correct facial deformities due to age, trauma or surgery^(61,62).

Subsequent innovators introduced modifications such as centrifugation, to purify the samples and blunt-tipped cannulas to make the injection less traumatic^(63, 64, 65, 66, 67).

Fat injections relied more on artistry and technique than on a precise anatomical algorithm and often gave unpredictable outcomes, necessitating repeated engrafting sessions to achieve good results. A recent survey showed that current techniques still do not consider specific anatomic targets, but refer only to general areas related to surface topography⁽⁶⁸⁾.

FAMI (Fat Auto-grafting Muscle Injection) has been in development by the author for 14 years⁽⁶⁹⁾ and addresses atrophic aging changes using the patients underlying anatomy as the template^(70, 71). The central thesis of this technique is that the placement of autologous

lipo-aspirates and their adult mesenchymal stem cells, into the appropriate microenvironment will have the restorative effects that are sought: sub-periosteally for bone, intramuscularly for muscle reshaping, and into the fat pads to restore contours. Graft survival, predictability, and symmetry are greatly enhanced by targeting the rich vascular bed of the muscles of facial expression. Augmenting regressed boney surfaces with subperiosteal injections as well as the deep and subcutaneous fat pads leads to a more natural restoration of youthful contours and volumes.

3.2 Methods

3.2.1 Instrumentation

In 1998 10 reusable 18 gauge cannula were designed to approach the facial musculature from their origin to their insertions or conversely, following the skull curvatures to make the injection less traumatic. Their 7 main curvatures duplicate the contours of the skull with 3 different lengths, 2 different blunt tips - round and spatula-like. More recently, to insure sterility, disposable cannulas are used which are lighter and more precise. The tumescent local anesthesia is performed with a 17gauge disposable infiltration cannula leaving the reusable ones as a backup (Fig. 18). Each blunt-tipped cannula is made for a muscle or group of muscle or bone surface (Table 1).

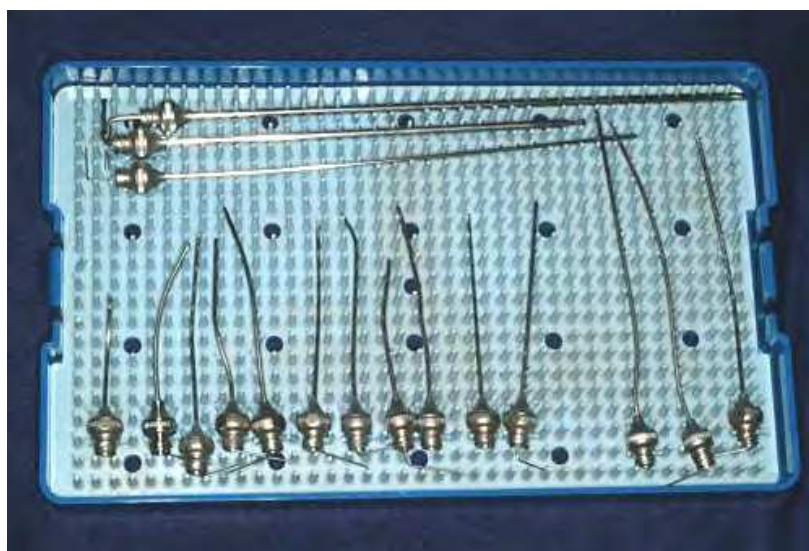


Fig. 18. The set of reusable cannulas is made of 14 injecting cannulas, plus 1 for injecting the tumescent anesthesia.

3.2.2 Procedure

Many articles have been published on fat injection; therefore we will only describe the points that make FAMI so specific.

Centrifugation: To prevent any leakage and air mixture during the spinning process an aluminum cap seals the 10 cc syringes. After removal the syringe from the centrifuge we can observe, on top, a layer of less density, yellow in color, mainly composed of the oil from destroyed fat cells; this layer can be up to 5cc after applying 13,000 G. In the bottom, the pink layer is mainly constituted of blood, Lidocaine, and saline with debris. The middle layer is composed by an accumulation of tissues: free fat cells, fat cells within a stromal vascular network containing mesenchymal stem cells, and a lower white crescent of pure collagen.

17 Cannulae	Target
Cannula # I:	for the Levators Labii superioris
Cannula # II:	for the Orbicularis oculii
Cannula # III:	for the Risorius muscle
Cannula # IIIA:	for the Pillars of the Cheek
Cannula # IV:	for the Zygomaticus minor cheek part and SOOF
Cannula # IVA:	for the Zygomaticus minor lip part and cupid’s bow
Cannula # V:	for the Frontalis, Buccinator, Depressor Anguli Oris
Cannula # VA:	for the Platysma and neck bands
Cannula # VI:	for the Corrugators and Procerus
Cannula # VIA:	for the Temporal extension of the Bichat fat pad
Cannula #VII:	for the Depressor Labii inferioris, Mentalis, and LAO
Cannula #VIII:	malleable cannula for testing
Cannula # IX:	dissecting solid tube for scar undermining
Cannula # X:	for the Zygomaticus major and Platysma origin
Cannulae P1,P2,P3:	for Subperiosteal injections

Table 1. Cannulas list developed for a full face FAMI on the basis of one cannula for one specific muscle.

Different spinning speeds are used according to the facial tissue to be augmented: bone, muscle or fat pad (Table 2).

Spinning speed / 1or 2 minutes in G Force*	Tissue to repair
10,000 to 13,000 G	Subperiosteal
5,000 to 6,000 G	Muscles
1,000 G	Fat pads

Table 2. This table shows the different G force applied on lipo-aspirates to obtain purified tissues for restoration of bone, muscle and fat pads.

Lipo-aspirates centrifuged at higher G force (13,000) tend to be more liquid and are injectable sub-periosteally. Lower G force (1000) processing is done when larger volume corrections with lobulated fat aggregations are desired, such as in the fat pads.

3.2.3 Anesthesia

Complete trigeminal sensory nerve block is administered using Naropin 0.5% (Ropivacaine 5mg/100ml - Astra-Zeneca) along with cervical sensory branches if neck bands are to be addressed. Lorazepam 0.5mg PO or similar sedative, and Clonidine 0.1 – 0.2mg are useful adjuncts preoperatively.

3.2.4 The graft placement

The processed lipo-aspirates are transferred into 1cc and 3 cc Luer-lock syringes for injection with the appropriate cannula. Acquired technical skill and a detailed knowledge of the anatomy are necessary to successfully place the grafts (Table 3).

Correct intramuscular placement is associated with no resistance when the plunger is depressed, injecting with each withdrawal, for the 1-3 passes used for each muscle. The systematization of the injections, from periosteum to skin, plane after plane, is one characteristic of the FAMI procedure.

Approach site	Subperiosteal	Muscle	Fat pad
1.Frontal		Frontalis Corrugator Procerus	
2.Temporal	Temporal crest		Superficial temporal
3.Orbital	Orbital rim	Orbicularis oculii Zygomaticus minor	Brow / Charpy's/ ROOF SOOF
4.Zygoma	Zygoma, Zygoma orbital process, Zygomatic arch		
5.Nasal	Nasal frame, nasal spine	Levator Labii superior, Lev Labii sup alaque nasi	
6. Oral commissure	Alveolus superior and inferior	Levator Anguli Oris Zygomaticus major Orbicularis Oris Buccinator Platysma	Bichat / buccal FP Buccinator FP
7.Mandibular	Mandibular body	Platysma (neck bands) Depressor Anguli Oris Depressor Labii inferioris, Digastric	
8.Mental	Chin	Mentalis	Submental FP

Table 3. This table shows the detailed anatomy of the face to successfully place the grafts.

3.3 Complications

In our 726 cases the FAMI procedure has been remarkably free of complications. No cytosteatonecrosis, pseudocyst formation, or infections have been noted in 14 years of practice. Nerve injury, sensory or motor, has never occurred.

3.4 Conclusion

The FAMI Technique achieves a true facial volume correction with natural and proper vectors to return a youthful appearance to the aging face appearance of the aging face. The time is coming where injecting the face disregarding the micro-anatomy of the underlying tissues will no longer be tolerated. By aiming principally on the 30 muscles of facial expression, the FAMI technique has proved to be gratifyingly effective to rejuvenate and/or restore facial contours without creating deformities. (Fig.19)

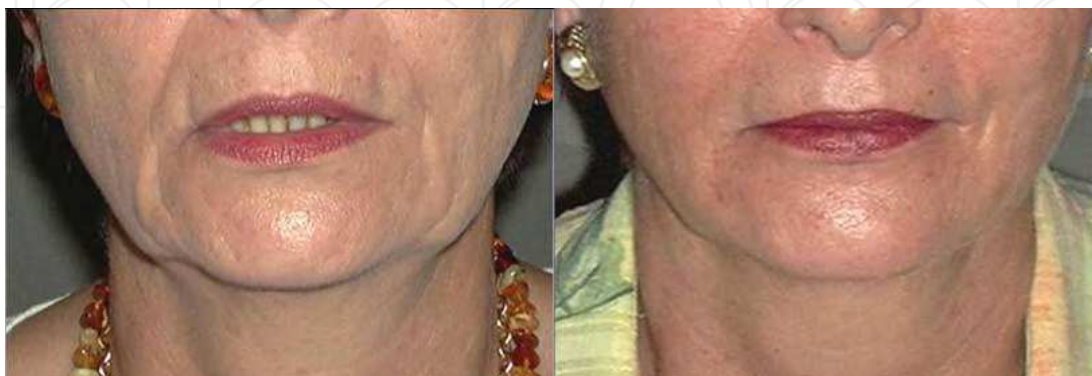

Fig. 19. Patient with 33cc of fat injection in depressor of labii inferioris, platysma, and depressor anguli oris. Previous the injection and 6 months later.

4. Labia majora cosmetic volume enhancement with autologous fat transfer

4.1 Introduction

The surgical aesthetic management of the vulva is poorly understood and as a result it is often neglected by gynecologists and cosmetic surgeons. Factors explaining the reluctance to treat these women include the scarcity of medical literature detailing operative techniques for the cosmetic enhancement of the labia majora and mons pubis and the surgeon's concern of creating sexual dysfunction as a result of the surgery.

Women seeking cosmetic improvement of the labia majora and mons pubis can be divided into two distinctive groups. The first group includes those women who request the correction of large and ptotic labia majora and mons pubis related to unsightly fat deposits that may persist even after dramatic weight loss, as is frequently seen after bariatric surgery. The second group are those who seek cosmetic surgical help to improve labia majora volume loss, secondary to both age and weight loss that result in ptotic and deflated labia majora with looseness and wrinkling of the overlying skin. Patients belonging to the second group can be effectively treated using autologous fat transfer for the volume enhancement of the labia majora.

4.2 Anatomical considerations

The vulva is composed of the labia majora and the mons pubis. The labia majora consist of skin and appendages, including hair follicles, sebaceous glands, sweat gland, and two prominent swellings on both sides of the vulva - the result of sub-dermal fat deposits. The two labia come together in the midline creating the anterior commissure, and posteriorly at the perineum the two labia also come together creating the posterior commissure.

The majority of the tissue beneath the skin of the labia majora is fat (95 %) through which course numerous superficial vessels and nerves. The next layer is composed by a fibro-

condensation of fat called the Colles's fascia. The thin bulbo-cavernosus muscle is found beneath the Colles's fascia. The bulbocavernosus muscles cover the very vascular vestibular bulbs. These vascular structures have a typical bluish hue - the result of the venous blood held within the sinuses. The Bartholin's glands are partially covered by the posterior ends of the vestibular bulbs. The vascular and neural supply of the vulva originates from both the internal and external pudendal arteries and nerves. The posterior femoral cutaneous, ilioinguinal and genital femoral nerves also supply areas of the vulva. ⁽⁷²⁾

4.3 Technique

4.3.1 Fat harvesting

Tumescent anesthesia (a combination of lidocaine, epinephrine, and sodium bicarbonate in a bag of saline solution) is infiltrated in the area where the fat will be removed. Typical donor sites are the medial aspect of the knee, the abdomen, and hips. A sufficient amount of fat is harvested from a suitable site under sterile conditions by liposuction under low negative pressure using 3 mm suction cannulas or by syringe. When the syringe technique is used, a small diameter (2 mm) blunt cannula with a lateral distal opening is connected to a 10 cc or 20 cc Luer-Lok syringe for the fat harvesting.

4.3.2 Fat preparation

After sufficient fat is harvested, the fat is placed in 10 cc syringes after the syringe plungers have been removed. The syringes are then centrifuged at 3000 rpm for 3 minutes. At the end of the centrifugation, 3 levels are present: an upper level with oil from broken fat cells, a middle level with the fat tissue, and a lower level with blood and residual tumescent fluid. The upper and lower levels are discarded.

Autologous platelet-rich-plasma (PRP) is then prepared. The PRP is a platelet concentrate that contains numerous protein and growth factors that has demonstrated to accelerate and improve the healing process. It has been used extensively to accelerate soft and hard tissue healing. The PRP is prepared using a small volume of blood taken from a peripheral vein. We use a self-contained disposable kit (Selphyl, Cascade Medical Enterprises, LLC, Princeton, New Jersey) to process 18 cc of peripheral blood. Recent studies have shown excellent results when autologous fat is combined with PRP in aesthetic plastic surgery ^(73, 74, 75). In order to increase the potential for autologous fat graft acceptance and retention we mix the harvested fat with the autologous PRP in a 4:1 ratio. The PRP mixed with the fat tissue is then aseptically injected in the labia majora.

4.3.3 Fat Injection

The labia majora areas to be treated with the autologous fat injections are drawn. The procedure is performed under local tumescent anesthesia. The solution includes lidocaine, epinephrine, and sodium bicarbonate diluted in one liter bag of saline solution. The solution creates complete local anesthesia and optimal hemostasis. Approximately 15-20 ml are carefully injected in the subcutaneous layer of each labia majora. Approximately 20 ml of the autologous fat mixed with the PRP are injected subcutaneously in a fan-like pattern through bilateral 1 mm labia majora incisions with a 15 cm long, 14 gauge, blunt cannula. Deep injections must be avoided as they may disrupt and traumatize the deep vascular structures of the vestibular bulbs. In some patients the injection of the fat may be difficult due to the presence of sheets of connective tissue in the subcutaneous layer (Figures 20 a-d).

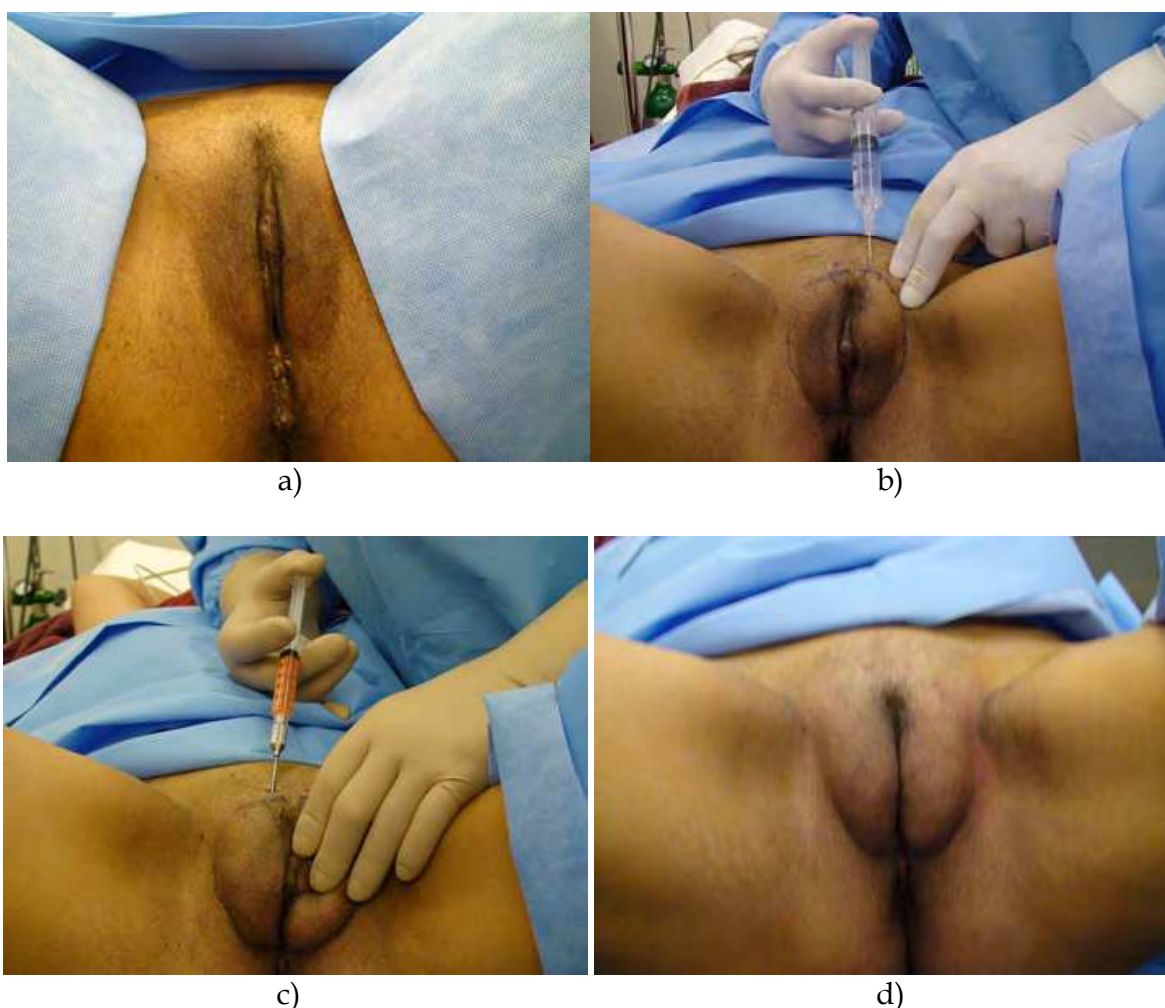


Fig. 20. a. Following significant weight loss a 49 year old requested cosmetic correction of the labia majora. Notice the deflated appearance of the labia majora and the associated looseness of the underlying skin, b. Local tumescent anesthesia is infiltrated bilaterally in the labia majora, c. Following the infiltration of tumescent solution, a autologous platelet enriched plasma fat is injected in each labia for volume enhancement, d. Notice the cosmetic improvement of the labia majora as a result of the fat transfer.

4.4 Labia majora convergence improvement using autologous fat transfer

In the young woman the two prominent subdermal fat swellings of the labia majora converge anteriorly creating the anterior labial commissure, and posteriorly creating the posterior labial commissure. With age or weight loss some women find that their labia majora diverge away from the clitoris or away from the perineal body and they find cosmetically unacceptable that their anterior and/or posterior commissures do not come together.

The convergence of the labia majora can be obtained using reduction surgery with a moderate excision of inner labia majora to pull the labia towards the midline to give a more aesthetically appealing contouring of the labia majora above and below the vaginal openings. The use of autologous fat transfer avoids the need to perform reduction surgery and can achieve a significant improvement of the labia convergence. The technique of fat transfer to correct this problem is similar to the procedure to create labia majora enhancement. It requires a careful

pre-injection drawing of the anterior and posterior labial commissures in order to place the fat in the correct areas to recreate the commissures. (Figures 21a-d)

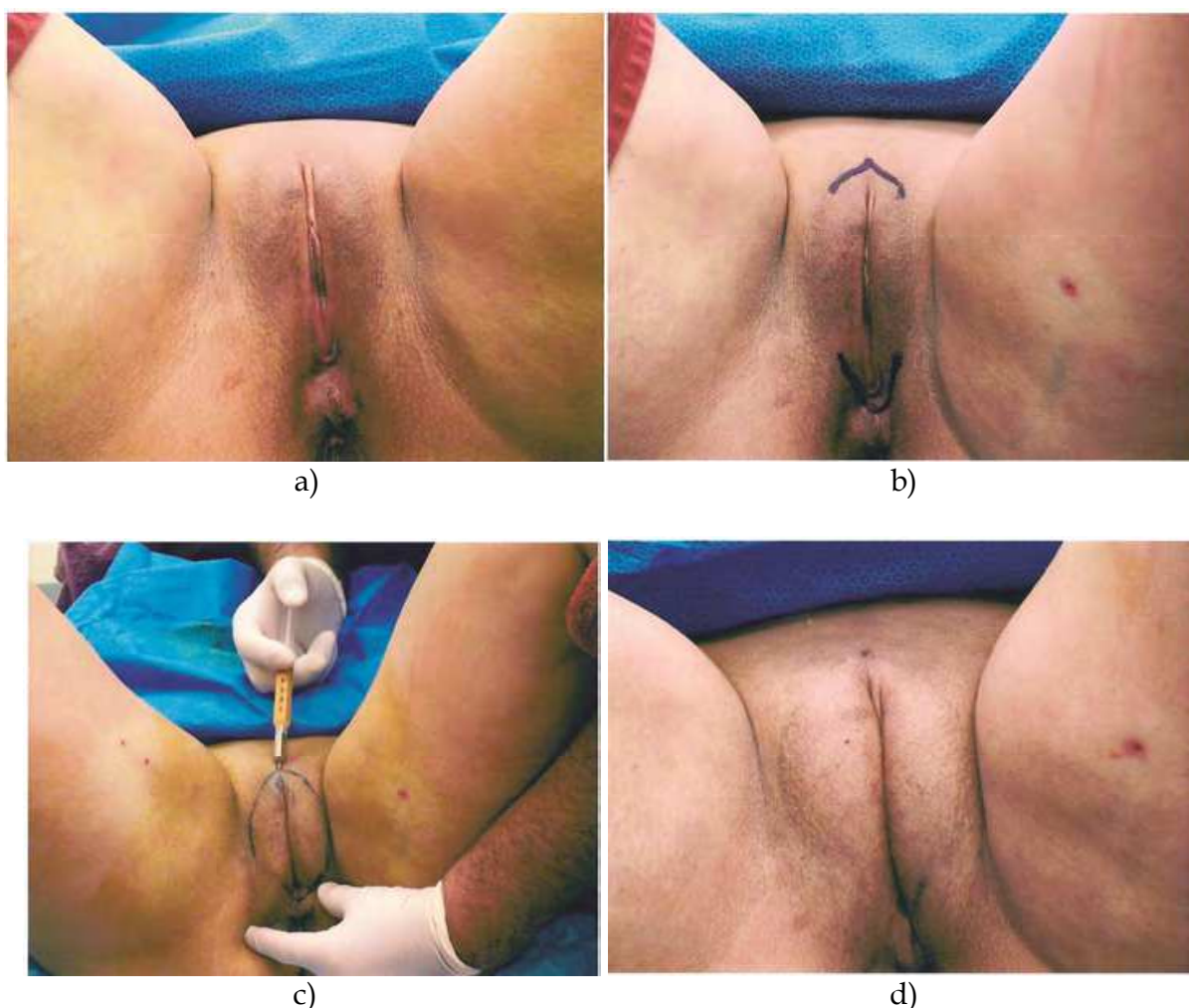


Fig. 21. a. Patient requested labia majora volume enhancement and that the right and left labial fat swellings meet in the midline, b. The anterior and posterior labial commissural angles are marked, c. Autologous platelet enriched plasma fat is injected bilaterally to achieve adequate volume and convergence. Approximately 25 ml were placed in each labia majora, d. Notice the cosmetically improved appearance of the labia majora following the injection of fat for volume replacement and the more aesthetically appealing contour of the labia in the midline.

4.5 Conclusions

Prophylactic antibiotics are routinely used. Patients are advised to refrain from intercourse for 6 weeks. Standard instructions for the care of the small labia incisions are given.

We have performed over 100 consecutive cosmetic volume enhancements of the labia majora using the technique described here. The minimal follow-up has been 12 months.

We have not encountered hematomas, infections, persistent pain, the development of irregularities or nodulations in the subcutaneous layer of the labia or anatomical distortions requiring correction. The retention of the transplanted fat has been excellent. Only 3

patients, approximately 6 months later have required a second fat injection to replace volume. In approximately one third of the cases undergoing labia majora volume enhancement with autologous fat transfer, additional cosmetic vaginal procedures were performed at the same time (vaginal rejuvenation/tightening, labia minora labiaplasty, and mons pubis liposuction or fat injection). The addition of the labia majora fat grafting did not compromise the performance or the recovery of the other vaginal cosmetic procedures. The satisfaction rate of the patients has been 100 % and all of them stated that they will recommend the surgery to others. ⁽⁷⁶⁾

In our experience labia majora cosmetic volume enhancement using autologous fat transfer has been an effective and safe cosmetic vaginal procedure with a very high patients' satisfaction rate.

An additional advantage of volume enhancement and correction of labia convergence using fat grafting in some patients is the ability of the procedure to conceal an associated labia minora enlargement or distortion, thus avoiding the need to perform a labia minora labiaplasty. In those situations, following the completion of the fat transfer to the labia majora the excessive labia minora protrusion or distortion will be effectively covered by the volume enhanced labia majora.

6. Final conclusions

The authors have presented different approaches in advanced lipotransfer techniques. The common pattern is to take advantage of adipose tissue as an autologous filler to obtain safe and consistent results.

7. References

- [1] Pittman, Gerald, MD; Liposuction and Aesthetic Medicine, QMP Inc. St. Louis, Missouri, 1993
- [2] Niechajev, I., and Sevcuk, O. Long-term results of fat transplantation: clinical and histologic studies. *Plast Reconstr Surg* 94:496-506, 1994
- [3] Boschert MT, Beckert BW, Puckett CL, Concannon MJ. Analysis of lipocyte viability after liposuction. *Plast Reconstr Surg* 109:761-5 766-7, 2002
- [4] Shiffman MA, Mirrafati S. Fat transfer techniques: the effect of harvest and transfer methods on adipocyte viability and review of the literature. *Dermatol Surg* 27:819-26, 2001
- [5] Saylan Z; Liposhifting instead of Lipofilling; Treatment of the Post-Liposuction Irregularities. *Aesthetic Surgery Journal*, March/April 2001, Volume 21 Number 2
- [6] Blugerman G; Liposhifting. Vortrag auf dem Kongress der Deutschen Gesellschaft für Ästhetische Chirurgie, Heidelberg 2002
- [7] Blugerman GS, Schavelzon DE, Liposhifting para el Tratamiento de las Irregularidades Post-liposucción y Celulitis, *Procedimientos Estéticos Minimamente Invasivos* Capítulo 55: Santos Livraria Editora Sao Paulo Brazil 2005, 425-430
- [8] Shiffman MA, Blugerman GS, Fat Shifting for The Treatment of Skin Indentations, *Liposuction Principles and Practice*, Chapter 53 Springer- Verlag 2006: 353-356
- [9] Blugerman G, et al. Movilización adiposa interna (Liposhifting) con espátula y cortador de microinjertos de grasa. *Dermatología CMQ* Abr- Jun 2007; 5 (2):105-111.


- [10] Klein J.A.: Tumescence technique chronicles. Local anesthesia, liposuction and beyond. *Dermatol surg* 1995; 21:449-457
- [11] Blugerman G, M. Podda. Movilización adiposa interna (Liposhifting) con espátula y cortador de microinjertos de grasa. *Dermatología CMQ* Abr- Jun 2007; 5 (2):105-111.
- [12] Sommer B. Liposuktion und Eigenfett-Transplantation: Update 2004 *Haut* 3/2004 Band XV / 112-116
- [13] Mojallal A, Foyatier J-L. Historical review of the use of adipose tissue transfer in plastic and reconstructive surgery [In French]. *Ann Chir Plast Esthet* 2004;49(5):419-25.
- [14] Van de Graaf RC, Korteweg SFS. Gustav Adolf Neuber (1850-1932) and the first report on fat auto-grafting in humans in 1893. *Hist Plast Surg* 2010;1(1):7-11.
- [15] Lexer E. Die Freien transplantationen, 1 Teil. Stuttgart: Verlag von Ferdinand Enke 1919:264-547.
- [16] Peer, L. A. Transplantation of Fat. In *Transplantation of Tissue*. Baltimore: Williams & Wilkins, 1969. Pp. 165-244.
- [17] Blugerman G. y col. Metodología actual para Lipoinjerto Autólogo. Actas del XXIII Congreso Brasileiro de Cirugía Plástica. Noviembre 1986. Belho Horizonte. Brasil.
- [18] Kaufman MR, BradleyJP, DickinsonB, et al. Autologousfat transfer national consensus survey: Trends in techniques for harvest, preparation, and application, and perception of short- and long-term results. *Plast Reconstr Surg*. 2007; 119: 323.
- [19] Serra-Renom,JM y Fontdevila,J: "Treatment of Facial Fat Atrophy Related to Treatment with Protease Inhibitors by Autologous Fat Injection in Patients with Human Immunodeficiency Virus.Infection" *Plast. Reconstr. Surg*. 2004,114:551.
- [20] Eppley, B Woodell, J.Higgins, J.: "Platelet Quantification and Growth Factor Analysis from Platelet-Rich Plasma: Implications for Wound Healing". *American Society of Plastic Surgeons* 2004; 114(6): 1502.
- [21] Duskova M, Kristen M. Augmentation by autologous adipose tissue in cleft lip and nose: Final esthetic touches in clefts. Part I. *J Craniofac Surg*. 2004;15:478.
- [22] Bertossi D, Zancanaro C, Trevisiol L, et al. Lipofilling of the lips. *Arch Facial Plastic Surg*. 2003;5:392.
- [23] Fulton JE Jr, Rahimi AD, Helton P, et al. Lip rejuvenation. *Dermatol Surg*. 2000;26:470.
- [24] Iñigo F y col.: Tratamiento estético de la enfermedad de Romberg. *Cir Plast* 2001;11(2):67-75
- [25] Coleman SR. Hand rejuvenation with structural fat grafting. *Plast Reconstr Surg*. 2002;110:1731.
- [26] Harrison D, Selvaggi G. Gluteal augmentation surgery: Indications and surgical management. *J Plast Reconstr Aesthet Surg*. 2007;60:922.
- [27] Restrepo JCC, Ahmed JAM. Large-volume lipoinjection for gluteal augmentation. *Aesthet Surg J*. 2002;22:33.
- [28] Roberts TL, Toledo LS, Badin AZ. Augmentation of the buttocks by micro fat grafting. *Aesthet Surg J*. 2001;21:311.
- [29] Panfilov DE. Augmentative phalloplasty. *Aesthet Plast Surg*. 2006;30:183.
- [30] Rohrich RJ, Sorokin ES, Brown SA. In search of improved fat transfer viability: A quantitative analysis of the role of centrifugation and harvest site. *Plast Reconstr Surg*. 2004; 113:391.

- [31] D. Bergfeld, B. Sommer, G. Sattler. Technik der Infiltration. Tumescenz-Localanästhesie: praktische Anwendung. Springer. 1999, pg 50.
- [32] Amar O, Bruant-Rodier C, Lehmann S, et al. [Fat tissue transplant: Restoration of the mammary volume after conservative treatment of breast cancers, clinical and radiological considerations.] *Ann Chir Plast Esthet.* 2007;53:169.
- [33] Coleman SR, Saboeiro AP. Fat grafting to the breast revisited: Safety and efficacy. *Plast Reconstr Surg.* 2007;119:775.
- [34] Guyuron B, Majzoub RK. Facial augmentation with core fat graft: A preliminary report. *Plast Reconstr Surg.* 2007;120:295.
- [35] Coleman SR. Structural fat grafting: More than a permanent filler. *Plast Reconstr Surg.* 2006;118:108S.
- [36] Burnouf M, Buffet M, Schwarzing M, et al. Evaluation of Coleman liposuction for treatment of facial lipoatrophy in patients with human immunodeficiency virus and parameters associated with the efficiency of this technique. *Arch Dermatol.* 2005;141:1220.
- [37] Gonzalez AM, Lobocki C, Kelly C, et al. An alternative method for harvest and processing fat grafts: An in vitro study of cell viability and survival. *Plast Reconstr Surg.* 2007; 120:285.
- [38] Piasecki JH, Gutowski KA, Lahvis G, et al. An experimental model for improving fat graft viability and purity. *Plast Reconstr Surg.* 2007;119:1571.
- [39] Ozsoy Z, Kul Z, Bilir A. The role of cannula diameter in improved adipocyte viability: A quantitative analysis. *Aesthet Surg J.* 2006;26:287.
- [40] Blugerman G, M. Podda. Movilización adiposa interna (Liposhifting) con espátula y cortador de microinjertos de grasa. *Dermatología CMQ* Abr- Jun 2007; 5 (2):105-111.
- [41] Pu LL, Cui X, Fink B, et al. The viability of fatty tissues within adipose aspirates after conventional liposuction: A comprehensive study. *Ann Plast Surg.* 2005;54:288.
- [42] Karacalar A, Orak I, Kaplan S, et al. No-touch technique for autologous fat harvesting. *Aesthet Plast Surg.* 2004;28:158.
- [43] Jackson IT, Simman R, Tholen R, et al. A successful long-term method of fat grafting: Recontouring of a large subcutaneous postradiation thigh defect with autologous fat transplantation. *Aesthet Plast Surg.* 2001;25:165.
- [44] Shiffman MA, Mirrafati S. Fat transfer techniques: The effect of harvest and transfer methods on adipocyte viability and review of the literature. *Dermatol Surg.* 2001;27:819.
- [45] Fagrell D, Enestro S, Berggren A, Kniola B. Fat cylinder transplantation: An experimental comparative study of three different kinds of fat transplants. *Plast Reconstr Surg.* 1996;98:90.
- [46] Rose JG Jr, Lucarelli MJ, Lemke B, et al. Histologic comparison of autologous fat processing methods. *Ophthal Plast Reconstr Surg.* 2006;22:195.
- [47] Smith P, Adams WP Jr, Lipschitz A, et al. Autologous human fat grafting: Effect of harvesting and preparation techniques on adipocyte graft survival. *Plast Reconstr Surg.* 2006; 117:1836.
- [48] Karacaoglu E, Kizilkaya E, Cermik H, et al. The role of recipient sites in fat-graft survival: Experimental study. *Ann Plast Surg.* 2005;55:63.

- [49] Hu S, Zhang H, Feng Y, et al. Introduction of an easy technique for purification and injection of autogenous free fat parcels in correcting of facial contour deformities. *Ann Plast Surg*. 2007;58:602.
- [50] Kuran I, Tumerdem B. A new simple method used to prepare fat for injection. *Aesthet Plast Surg*. 2005;29:18.
- [51] Lacy EL, Bartness TJ. Effects of white adipose tissue grafts on total body fat and cellularity are dependent on graft type and location. *Am J Physiol Regul Integr Comp Physiol*. 2005; 289:R380–R388.
- [52] Valdatta L, Thione A, Buoro M, et al. A case of lifethreatening sepsis after breast augmentation by fat injection. *Aesthet Plast Surg*. 2001; 25:347.
- [53] Guaraldi G, De Fazio D, Orlando G, et al. Facial lipohypertrophy in HIV-infected subjects who underwent autologous fat tissue transplantation. *Clin Infect Dis*. 2005;40:e13–e15.
- [54] Miller JJ, Popp JC. Fat hypertrophy after autologous fat transfer. *Ophthalm Plast Reconstr Surg*. 2002;18:228.
- [55] Coleman SR. Lower lid deformity secondary to autogenous fat transfer: A cautionary tale. *Aesthet Plast Surg*. 2008; 32:415.
- [56] Yoshimura K, Sato K, Aoi N, et al. Cell-assisted lipotransfer for cosmetic breast augmentation: Supportive use of adipose-derived stem/stromal cells. *Aesthet Plast Surg*. 2008;32: 48.
- [57] Hang-FuL, MarmolyaG, FeiglinDH. Liposuction fat-fillant implant for breast augmentation and reconstruction. *Aesthet Plast Surg*. 1995;19: 427.
- [58] Pierrefeu-Lagrange AC, Delay E, Guerin N, et al. [Radiological evaluation of breasts reconstructed with lipomodeling.] *Ann Chir Plast Esthet*. 2006; 51:18.
- [59] Neuber. Fetttransplantation. Bericht über die Verhandlungen der deutschen Gesellschaft für Chirurgie. *Zentralbl Chir*. 1893;22:66.
- [60] Lexer E. Fett transplantation,. *Dtsch Med. Wochenschr* 1910;36:640.
- [61] Illouz YG. The fat cell "graft": a new technique to fill depressions. *Plast Reconstr Surg* 1986;78(1):122-3.
- [62] Fournier PF. Microlipoextraction et microlipoinjection,. *Rev. Chir. Esthét. Lang. Fr* 1985;10:p. 40.
- [63] Carraway JH, Mellow CG. Syringe aspiration and fat concentration: a simple technique for autologous fat injection. *Ann Plast Surg* 1990;24(3):293-6; discussion; 297.
- [64] Coleman WP, 3rd. Autologous fat transplantation. *Plast Reconstr Surg* 1991;88(4):736.
- [65] Bircoll M, Novack BH. Autologous fat transplantation employing liposuction techniques. *Ann Plast Surg* 1987;18(4):327-9.
- [66] Ellenbogen R. Free autogenous pearl fat grafts in the face--a preliminary report of a rediscovered technique. *Ann Plast Surg* 1986;16(3):179-94.
- [67] Matsudo PK, Toledo LS. Experience of injected fat grafting. *Aesthetic Plast Surg* 1988;12(1):35-8.
- [68] Coleman SR. Facial augmentation with structural fat grafting. *Clin Plast Surg* 2006;33(4):567-77.
- [69] Amar RE. Adipocyte microinfiltration in the face or tissue restructuring with fat tissue graft. *Ann Chir Plast Esthet* 1999;44(6):593-608.
- [70] Amar RE, Fox DM, Balin A (2010) Cannulation and injection of the muscles of facial expression: a cadaver study. *Dermatol Surg* 36:1–8

- [71] Amar RE, Fox DM. The Facial Autologous Muscular Injection (FAMI) Procedure: An Anatomically Targeted Deep Multiplane Autologous Fat-Grafting Technique Using Principles of Facial Fat Injection. *Aesth Plast Surg, Online First™*, 5 February 2011.
- [72] Baggish MS . Vulvar and Perineal Anatomy. In Baggish MS, Karram MM (editors): *Atlas of Pelvic Anatomy and Gynecologic Surgery*. Second edition. Elsevier. Philadelphia, PA. Chapter 62: 835-850
- [73] Azzena B, Mazzoleni F, Abatangelo G, et al. Autologous Platelet-Rich Plasma as an Adipocyte In Vivo Delivery System: Case report. *Aesth Plast Surg* 2008; 32: 155-158
- [74] Sclafani AP. Applications of Platelet-Rich Fibrin Matrix in Facial Plastic Surgery. *Facial Plast Surg* 2009; 25:270-276
- [75] Cervelli V, Gentile P, Grimaldi M. Regenerative Surgery: Use of Fat Grafting Combined with Platelet-Rich Plasma for Chronic Lower-extremity Ulcers *Aesth Plast Surg* 2009;33:340-345
- [76] Pelosi MA II, Pelosi MA III. Cosmetogynecology. In Jay N. (editor): *State of the Art, Atlas of Endoscopic Surgery in Infertility and Gynecology*. Second Edition. Jaypee Brothers Medical Publishers, London (UK) 2010; Chapter 39: 422-439

IntechOpen



Advanced Techniques in Liposuction and Fat Transfer

Edited by Prof. Nikolay Serdev

ISBN 978-953-307-668-3

Hard cover, 230 pages

Publisher InTech

Published online 12, September, 2011

Published in print edition September, 2011

Liposuction is the first cosmetic procedure to change beautification surgery from open extensive excision surgery into a more atraumatic closed one. It gave rise to the modern understanding of minimally scarring and minimally invasive surgery and changed the understanding and preferences of both patients and doctors. It also became the most common procedure in cosmetic surgery world-wide, practiced by an increased number of physicians from various specialties. The techniques of fat grafting, closely bound with liposuction, have found widespread application and fat stem cells seem to be changing the future of many areas in medicine. Turning the pages, the reader will find a lot of information about advances, tips and tricks, as well as important milestones in the development of the different methods available, such as classic, power, ultrasound, laser and radio-frequency assisted liposuction etc. Most useful anesthesia techniques are described and discussed, and guidelines have been established for medical indications. Special attention is paid to good patient selection, complications and risks.

How to reference

In order to correctly reference this scholarly work, feel free to copy and paste the following:

Guillermo Blugerman, Roger Amar, Diego Schavelzon, Marco A. Pelosi II, Marco A. Pelosi III, Javier A. Soto, Anastasia Chomyszyn, Maurizio Podda, Andrea V. Markowsky, Jorge A. D'Angelo and Rodrigo Moreno (2011). Advanced Lipotransfer Techniques, Advanced Techniques in Liposuction and Fat Transfer, Prof. Nikolay Serdev (Ed.), ISBN: 978-953-307-668-3, InTech, Available from: <http://www.intechopen.com/books/advanced-techniques-in-liposuction-and-fat-transfer/advanced-lipotransfer-techniques>

INTeCH
open science | open minds

InTech Europe

University Campus STeP Ri
Slavka Krautzeka 83/A
51000 Rijeka, Croatia
Phone: +385 (51) 770 447
Fax: +385 (51) 686 166
www.intechopen.com

InTech China

Unit 405, Office Block, Hotel Equatorial Shanghai
No.65, Yan An Road (West), Shanghai, 200040, China
中国上海市延安西路65号上海国际贵都大饭店办公楼405单元
Phone: +86-21-62489820
Fax: +86-21-62489821

© 2011 The Author(s). Licensee IntechOpen. This chapter is distributed under the terms of the [Creative Commons Attribution-NonCommercial-ShareAlike-3.0 License](https://creativecommons.org/licenses/by-nc-sa/3.0/), which permits use, distribution and reproduction for non-commercial purposes, provided the original is properly cited and derivative works building on this content are distributed under the same license.

IntechOpen

IntechOpen