

We are IntechOpen, the world's leading publisher of Open Access books Built by scientists, for scientists

6,900

Open access books available

185,000

International authors and editors

200M

Downloads

Our authors are among the

154

Countries delivered to

TOP 1%

most cited scientists

12.2%

Contributors from top 500 universities



WEB OF SCIENCE™

Selection of our books indexed in the Book Citation Index
in Web of Science™ Core Collection (BKCI)

Interested in publishing with us?
Contact book.department@intechopen.com

Numbers displayed above are based on latest data collected.
For more information visit www.intechopen.com



Application of the Liposuction Techniques and Principles in Specific Body Areas and Pathologies

Diego Schavelzon et al.*
Argentina

1. Introduction

1.1 Three dimensional gluteoplasty

The buttocks have been a symbol of attraction, sexuality and eroticism since ancient times and therefore, they have an important role in defining the posterior body contour.

More and more people are talking about and understand the meaning and the role that buttocks play in modeling and physical beauty.

The three dimensional gluteoplasty (3-DGP) is an innovative technique that allows us to change volume, shape and firmness, not only in the buttocks but also in the adjacent regions such as the thighs and trochanters, becoming an ideal tool to answer the frequent reasons of consultation of our patients about this particular area of the body:

I want to reduce the volume of my buttocks

I want to lift my buttocks...

I want to improve the shape of my buttocks.

Numerous factors conspire against an ideal buttock.

First, the weight of the buttocks and the variations of fatty tissue component in addition to the presence of a strong lower groove skin adhesion called subgluteal fold or inferior gluteal groove, which is strongly influenced by the action of gravity, cause the appearance of ptosis with subsequent buttock deformity and that of the adjacent regions.

Other factors such as obesity, the lack of muscle activity (gluteal muscles), the aging process, a significant decrease in weight and extreme thinness play an important role in the development of gluteal ptosis.

The word ptosis comes from the Greek word meaning "falling" or "fall". From a medical perspective refers to prolapsus or caudal displacement, outside its natural site, of a tissue or organ.

The ophthalmologists were the first to use the term to define the upper eyelid drop, and by analogy, over time its use became widespread.

*Louis Habbema, Stefan Rapprich, Peter Lisborg, Guillermo Blugerman, Jorge A. D'Angelo, Andrea Markowsky, Javier Soto, Rodrigo Moreno and Maria Siguen
Centros B&S "Excelencia en Cirugía Plástica", Buenos Aires, Argentina
Medisch Centrum 't Gooi, The Netherlands
Department of Dermatology, Darmstadt Hospital, Germany
PrivatKlinik Lisborg & Parner, Österreich
Universidad Nacional del Nordeste, Corrientes, Argentina,

1.2 Gluteal Ptosis⁽¹⁾

What does gluteal ptosis mean?
Gluteal ptosis refers to the excess skin and/ or adipose tissue of the gluteal region that exceeds the caudal inferior gluteal groove. The progression of gluteal ptosis is usually from medial to lateral.
What does pseudo-ptosis mean?
(Sad or long gluteus). When the buttock support system gradually loses its strength and its power to lift, the entire gluteus falls, and subgluteal groove descends moving distally. With the consequent loss of natural contour and shape the buttocks have.
It is critical to have a classification of gluteal ptosis, which serves to select the most appropriate technique in each case.
The extension in depth and length of the subgluteal groove is a key indicator of ptosis.

1.2.1 Gonzalez classification of gluteal ptosis

To determine the degree of ptosis the marking is done with the patient in standing position, with straight hips, and facing backwards. We identify the ischial tuberosity by palpation, and from there we draw a vertical line (Line T) and a second parallel to the first one (line M) corresponding to the midpoint of the posterior thigh ⁽¹⁾ (Figure 1).

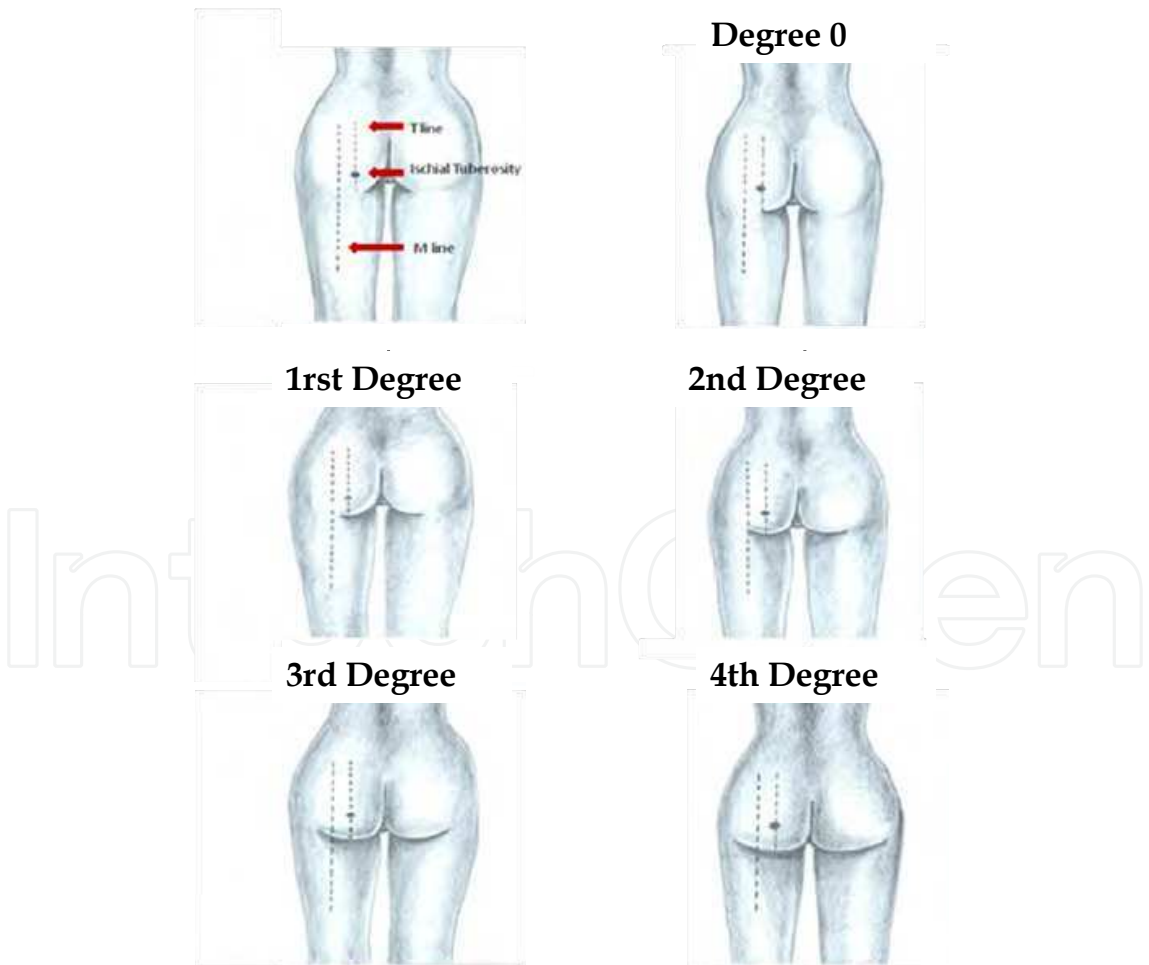


Fig. 1. Gonzalez classification of gluteal ptosis in degrees.

Degree 0 No ptosis.

1st Degree Minimal pre-ptosis, subgluteal groove lies between the line T and M.

2nd Degree Moderate pre-ptosis, subgluteal groove reaches the M-line and there is ptotic tissue at line T.

3rd Degree Borderline Ptosis, subgluteal groove goes beyond the M-line, but without ptotic tissue.

4th Degree Real ptosis, adipose tissue is projected on the thigh. From here on the excess of ptotic tissue is measured in centimeters.

Since the creation of liposuction Dr. Illouz ^(2,3), Pierre Fournier ⁽⁴⁾ and others (Fig.2 y 3) pointed the buttocks as a taboo area for this technique, prohibiting the performance of liposuction due to the bad results they had obtained.

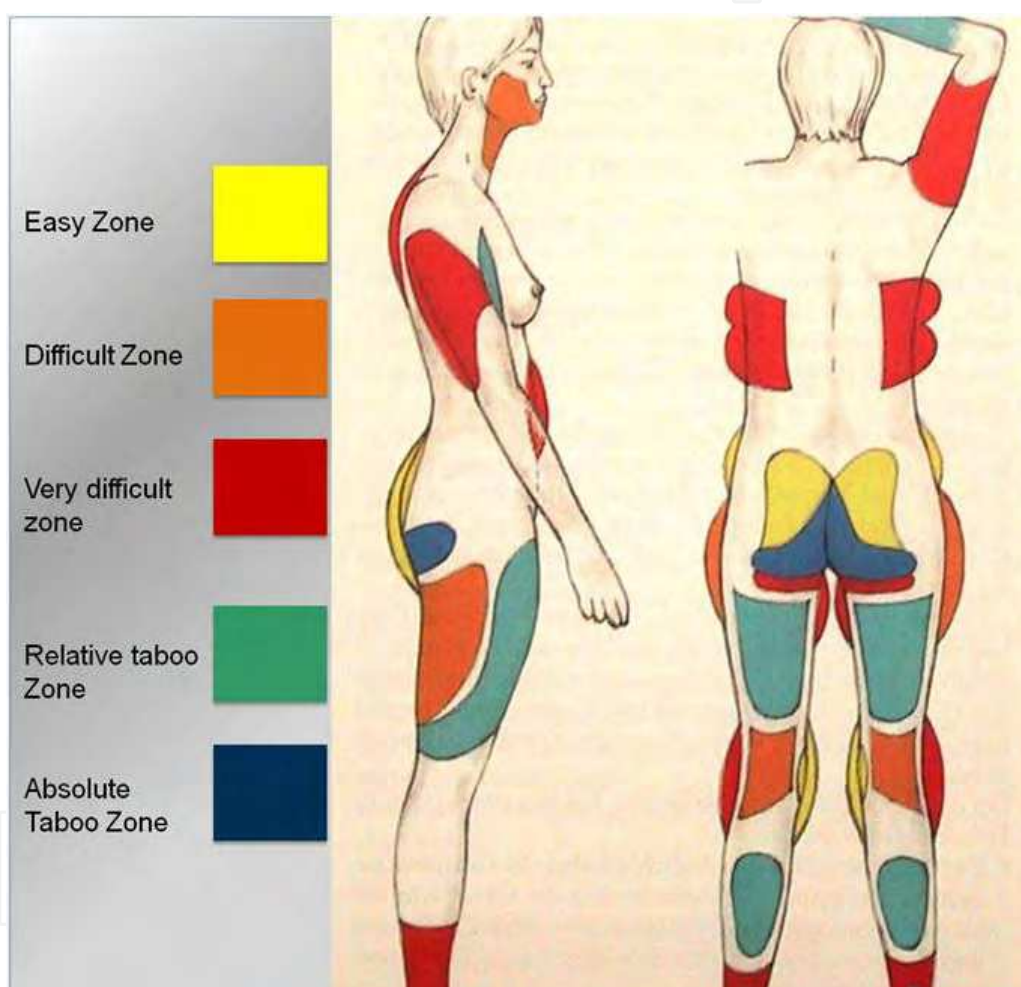


Fig. 2. Liposuction zones described by a Gottfried Lemperle in "Ästhetische Chirurgie". Note the zone shaded as "Absolute Taboo Zone". ⁽¹⁰⁾

Despite technical advances and the arrival of tumescent local anesthesia ⁽⁵⁾ the rule continued to be applied until 2002, when evaluating photographic images, based on an anatomical study ^{(6) (7) (8) (9)} and a correct diagnosis of ptosis we started working the adipose tissue of buttocks with a concept of three-dimensional fat remodeling.

The results obtained were very promising, as for the first time we gave the buttocks a more harmonious shape with the rest of the body.

The three-dimensional technique has given indirect benefits to adjacent areas as well as to the trochanter and the "Banana fold", so called to the deposit of adipose tissue in the posterior thigh below and parallel to the inferior gluteal groove.

This fat deposit is a result of buttocks pressure on the subgluteal groove, transmitting that pressure on the posterior thigh fat layer thus creating this fold deformity ⁽¹⁾.

There are multiple surgery techniques performed to correct this kind of defect, but all without much success because they are treating the defect and not its cause.

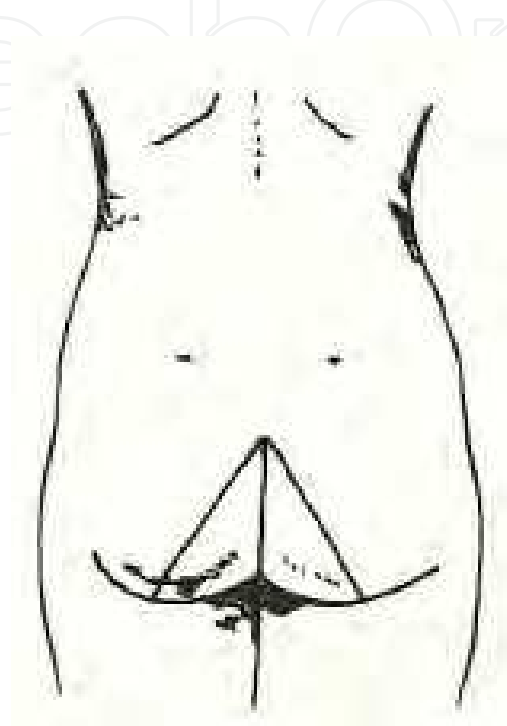


Fig. 3. The Bermuda short triangle. Its corners are the level of the ischial tuberosities and the upper edge of the intergluteal crease. ⁽⁴⁾

1.3 Surgical technique

The preoperative marking is done with the patient in standing position. Then the marking is done comprising the surrounding tissue of inter-gluteal and sub-gluteal groove thus determining an L-shaped marking. This mark is divided into two zones, a vertical one which is parallel to the inter-gluteal groove in which the liposuction is done in both deep and superficial plane, and another horizontal to sub-gluteal groove in which the liposuction is only done deeply to avoid flaccidity and wrinkles in the skin. (Figure 4).

Two incisions are used to perform this procedure. One located over the sacrum and another on the trochanter area at the end of the sub-gluteal groove.

Later on the subcutaneous fat is infiltrated with tumescent solution at all levels with the B&S peristaltic pump ⁽¹¹⁾ and a Klein needle ⁽⁵⁾, covering the areas previously marked until reaching tumescence and the area is stabilized.

Regularly it is needed only 500 to 1000 ml to achieve adequate tumescence point, due to the special characteristics of the gluteal fat (Fig. 5).

To obtain a more accurate and better skin contraction we then begin the treatment of fat through the use of an Nd: YAG 1064 laser assisted liposuction or bipolar radiofrequency assisted liposuction (RFAL) with the Body Tite® ⁽¹²⁾. The action of laser or radiofrequency

energy on the adipocytes causes the rupture of cell membranes due to the abrupt rise of interstitial temperature, causing a characteristic noise known as "Popcorn Effect". Once the fat is processed, we proceed to evacuate the oil emulsion obtained, using a vibrating tube of 3 mm.

MAST (Manual Assisted Stabilization Tissue) is a very helpful maneuver in which an assistant presses on the buttock to prevent accompanying the movements of the tissues performed by the surgeon's cannula during the procedure, thus achieving a greater accuracy and reducing surgical time.

The lipo-aspirated volume usually does not exceed 100 ml per buttock, but the influence of those few milliliters into the final shape of the area is really important (Figure 6 y 7).

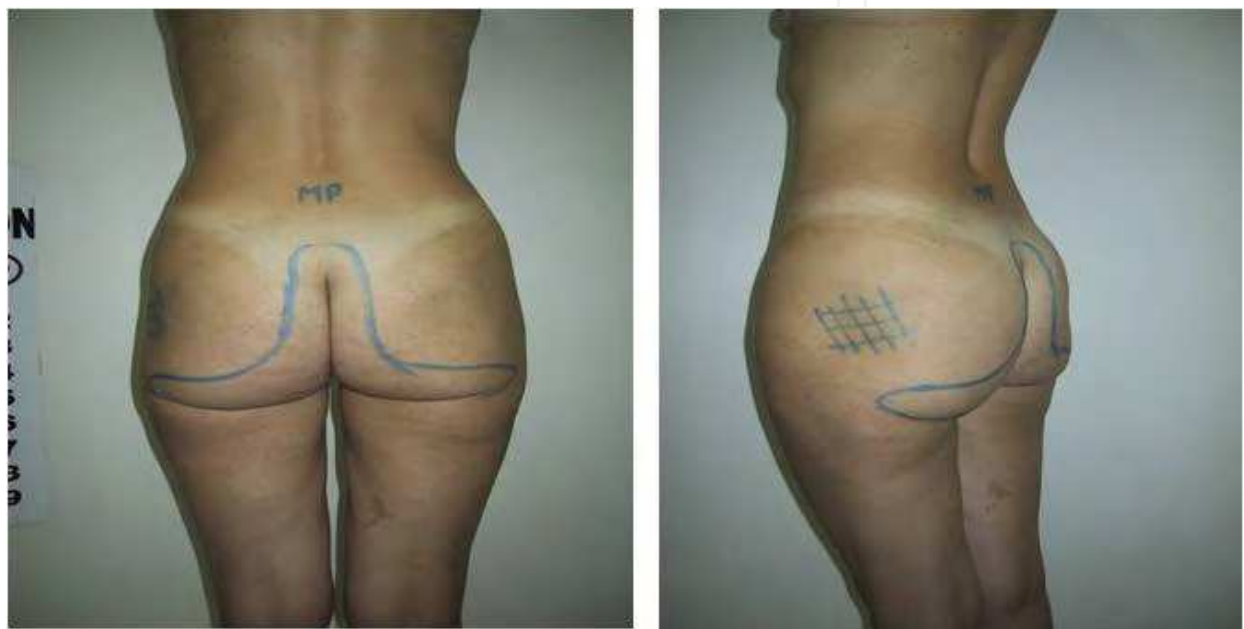


Fig. 4. Markings guiding the surgeon for areas and planes of fat removal. Front and lateral views.

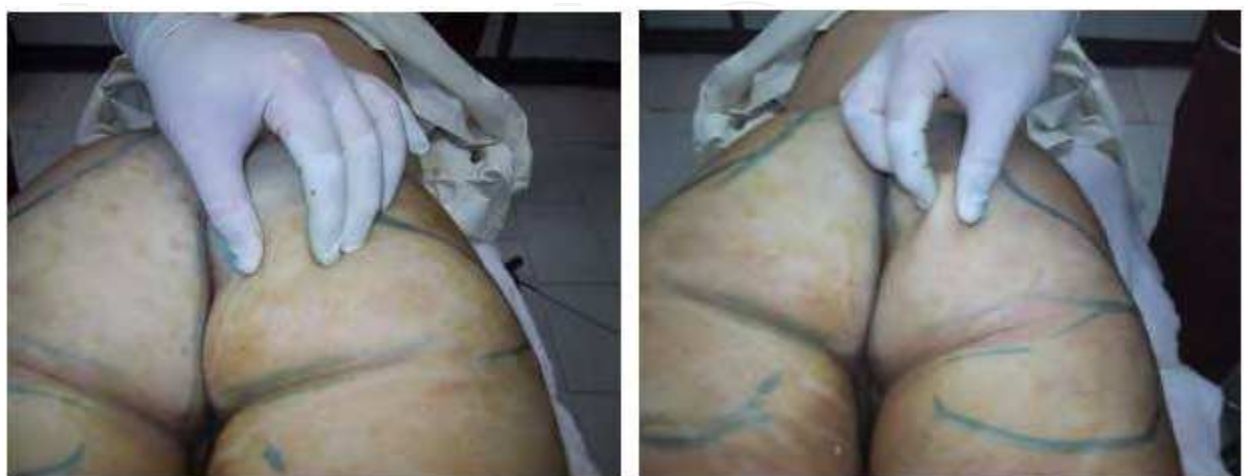

Fig. 5. Intra-operative views with tumescent anesthesia (left) and after liposuction (right).

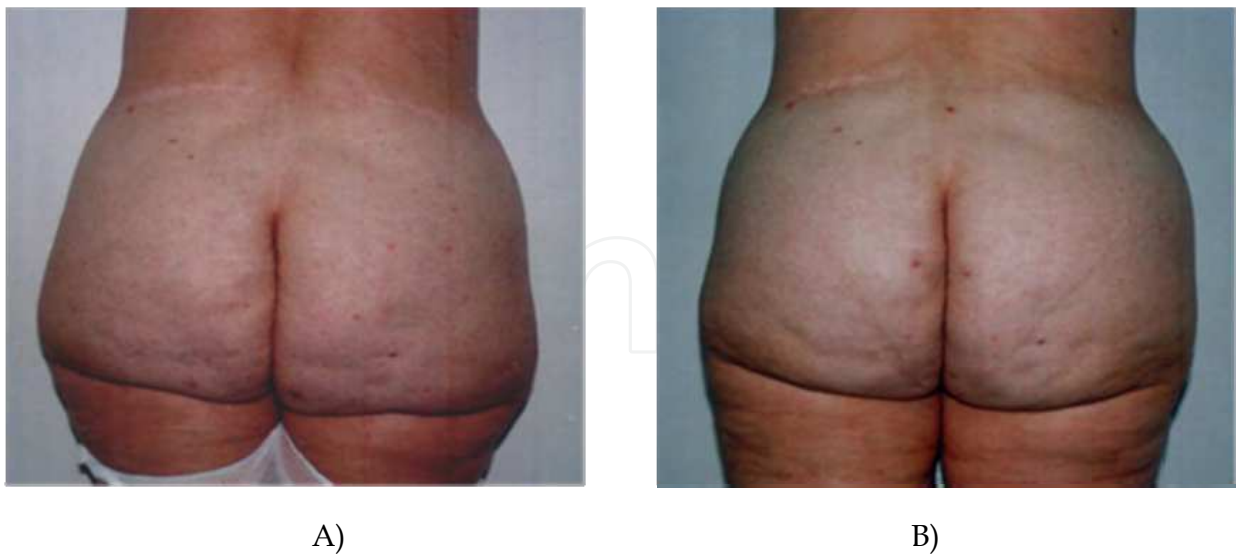

Fig. 6. A Pre-operative view of a 42 year-old woman B. Post-operative view 1 month after a Three Dimensional Gluteoplasty (3-DGP).

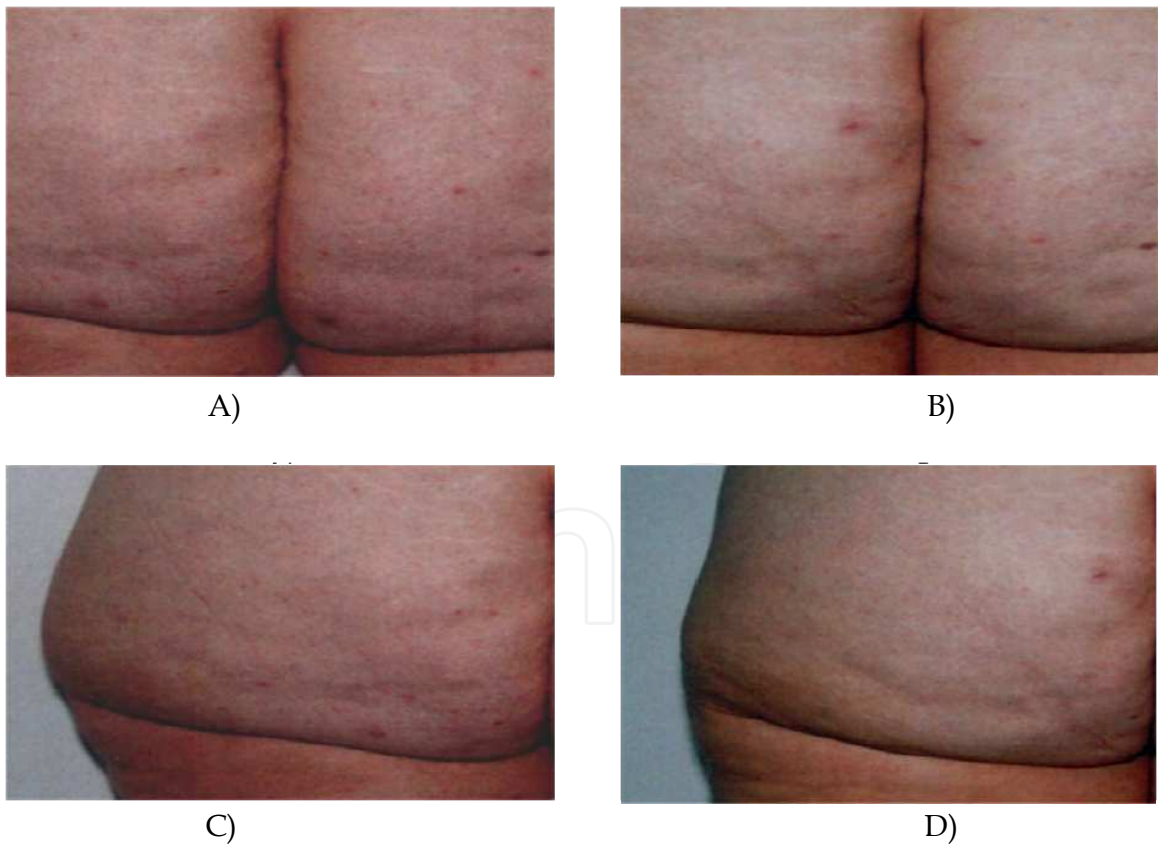


Fig. 7. A Preoperative view of ptosis and subgluteal crease B. Improvement in the inter-gluteal aspect and in the lower gluteal area. C. Preoperative view of the trochanteric area. D. Postoperative view of the trochanteric area without performing any type of procedure in this area, only the 3-DGP.

Our actual concept of three-dimensional remodeling buttocks includes the combination of several procedures as described below, in association with:

- Liposuction to the near buttocks areas.
- Enriched Adipose Micrografts with Autologous Plasma.
- Liposhifting superficial and deep subcision procedures.
- Sub-muscular gluteal implant.

1.3.1 Liposuction to the near buttocks areas

Liposuction of the adjacent buttock regions allows a much better result of the final shape. Liposuction in upper and lower back gives a good skin retraction due to its greater thickness and its fibrous tissue content, which produces a significant improvement in the posterior contour and therefore in the buttocks. Another region that responds to liposuction is the sacral region, thus enhancing and defining the buttocks.

In our practice the best results are obtained with RFAL (Body Tite®) ⁽¹²⁾ that allows us to achieve greater tissue retraction in less time.

1.3.2 Enriched Adipose Micrografts (EAM)

In some cases due to the marked ptosis we use adipose grafting, this theme is explained in “Enriched Adipose Micrografts with Autologous Plasma” ^(13,14) (Figure 8).

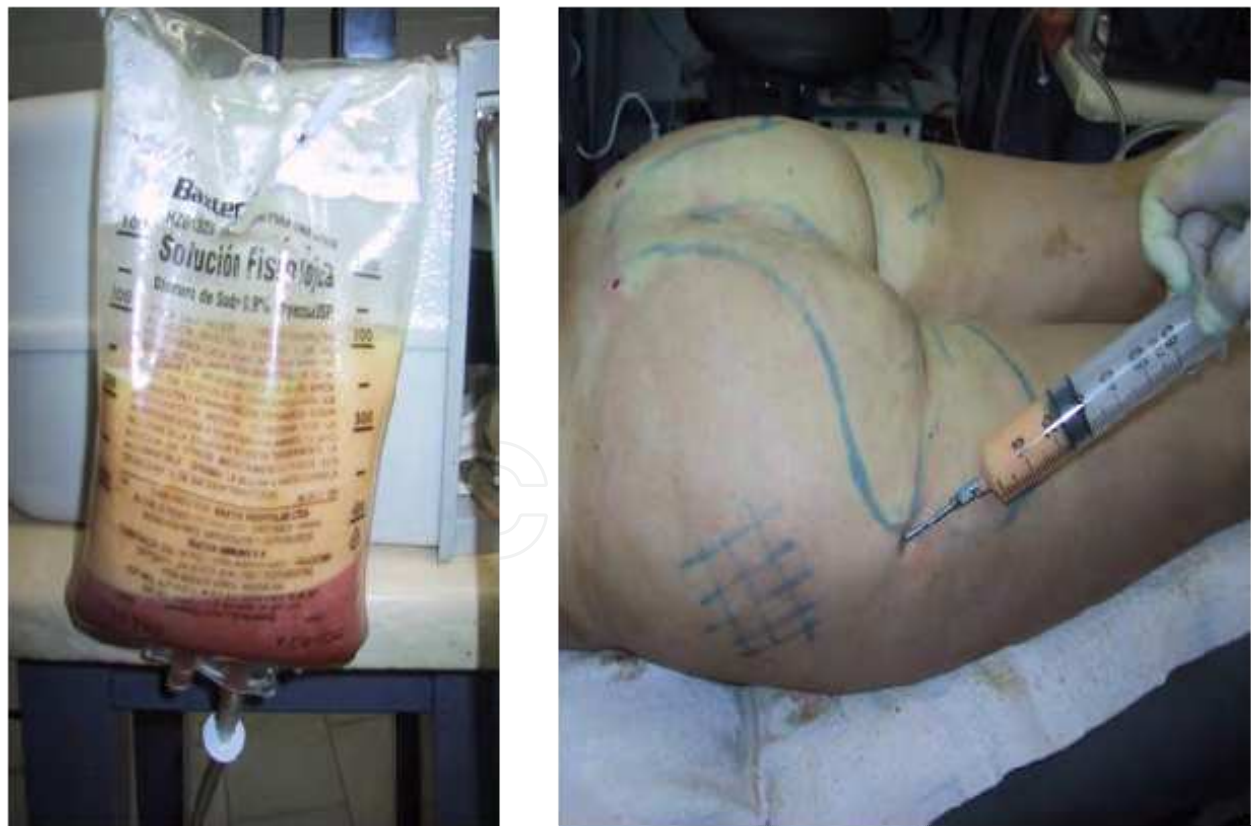

Fig. 8. View of the fat tissue post-liposuction. Lateral view of EAM technique in trochanteric depression.

1.3.3 Liposhifting and deep-superficial subsicion

Liposhifting technique allows us to repair irregularities and depressions found in the gluteal region.⁽¹⁴⁾ For treatment of depressions or irregularities we cut the fibrous septa that cause adhesions of the skin to deeper layers. This allows for the formation of new tissue and replacement of fibrin by vascularized fibrous tissue. Superficially we use Nokor ® type needles; it has a tapered end similar to the scalpel blade. For the deeper plane we use a hook instrumental that only cuts when removed.

1.3.4 Buttocks implants

Where there is a lack of volume in the gluteal region that can not be resolved by the procedures previously described we opt for the placement of cohesive gel implants in a submuscular plane through an incision in the inter-gluteal groove ⁽¹⁵⁾.

1.4 Conclusion

There are different procedures to improve the gluteal area.

The Three Dimensional Gluteoplasty is a global useful technique not only to correct gluteal ptosis and to raise the subgluteal crease or correct skin asymmetry but also to reshape the buttock.

The result in this procedure depends on patient selection, and a correct technique development.

2. Liposuction treatment for lipedema

2.1 Introduction

Lipedema is a painful, hereditary disorder usually affecting women that involves accumulation of excess fatty tissue on the extremities. Characteristic symptoms include pain as well as sensitivity to touch and pressure. Patients also tend to bruise easily after minimal trauma. Over time, the disorder progressively worsens ^(16, 17, 18).

2.2 Classification

The diagnosis is based on clinical appearance (Figure 12). Lipedema should be differentiated from lipohypertrophy and lymphedema ⁽³³⁾. Lipedema may be divided into three types : whole leg, thigh and lower leg lipedema. In about 30% of patients, there is also involvement of the arms ^(19, 20, 28).

2.3 Etiology and pathophysiology

The cause of lipedema is unknown. Hormones are certainly one factor, as lipedema occurs virtually exclusively in women. In addition, early signs of disease tend to appear with the onset of puberty or after pregnancy. During these stages, the disease may also be referred to as lipohypertrophy which may develop into lipedema. Full-blown symptomatic disease usually manifests in the third or fourth decade of life. In addition to hormonal factors, a genetic disposition may be presumed, as the disease often affects several women in the same family.

An important factor in the patho-physiology of lipedema is increased capillary leading to orthostatic edema. This, and not the amount of adipose tissue, is responsible for the increased sensitivity of the tissue to touch and pressure. The increased capillary fragility also explains the tendency to hematoma development.

Lymph drainage is undisrupted. Indeed, it is even increased in the early stages of lipedema. In later stages, the capacity of the lymphatic system is exhausted and can no longer ensure adequate drainage. This results in dynamic insufficiency. With decompensation of the lymphatic system, secondary lymphedema develops. In clinical terms this is known as lipolymphedema – with all related sequel including leg ulcers. There are no characteristic histological changes associated with the disease.

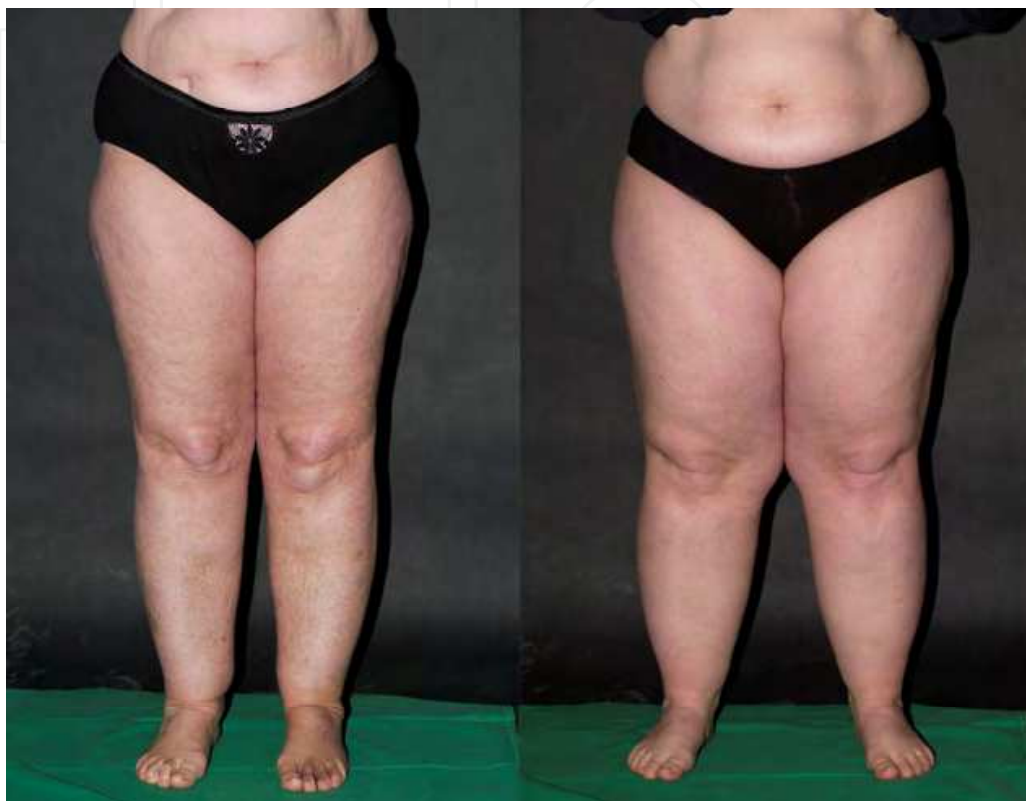

Fig. 12. Mother and her daughter with lipedema.

The disorder occurs in three stages :

Stage I: Thickening and softening of the subcutis with small nodules; skin is smooth

Stage II: Thickening and softening of the subcutis with larger nodules; skin texture is uneven.

Stage III: Thickening and hardening of the subcutis with large nodules, disfiguring lobules of fat on the inner thighs and inner aspects of the knees.

2.3 Therapeutic options

Complex physical therapy (CPT), which is widely recommended, is only effective against edema. Only some patients actually experience an improvement in symptoms, and then only for a short period of time following each treatment session.

The removal of excess fatty tissue using liposuction has been made possible by microcannulae and – in a more advanced form – with vibrating cannula under tumescent local anesthesia (Figure 13 and 14) (21, 22, 23, 24, 25, 29, 31, 32, 34).

The procedure of the liposuction in lipedema does not differ from aesthetic indications (26, 27, 28). Stringent guidance of the cannula in longitudinal direction and aspects of safety have to be considered in the same way.

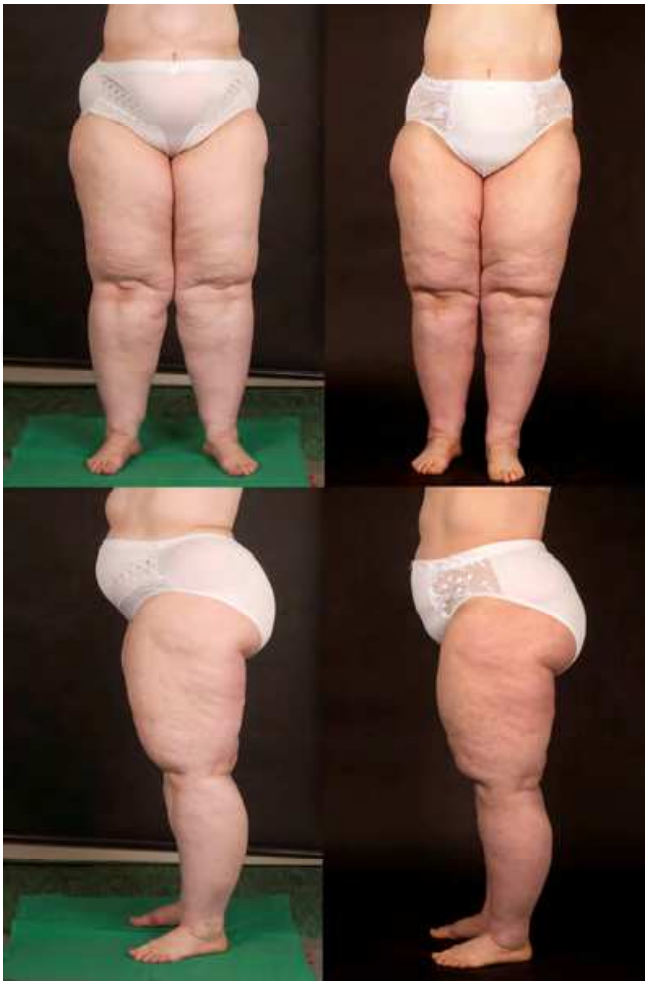

Fig. 13. Patient pre- and 6 months postoperative, 3 sessions

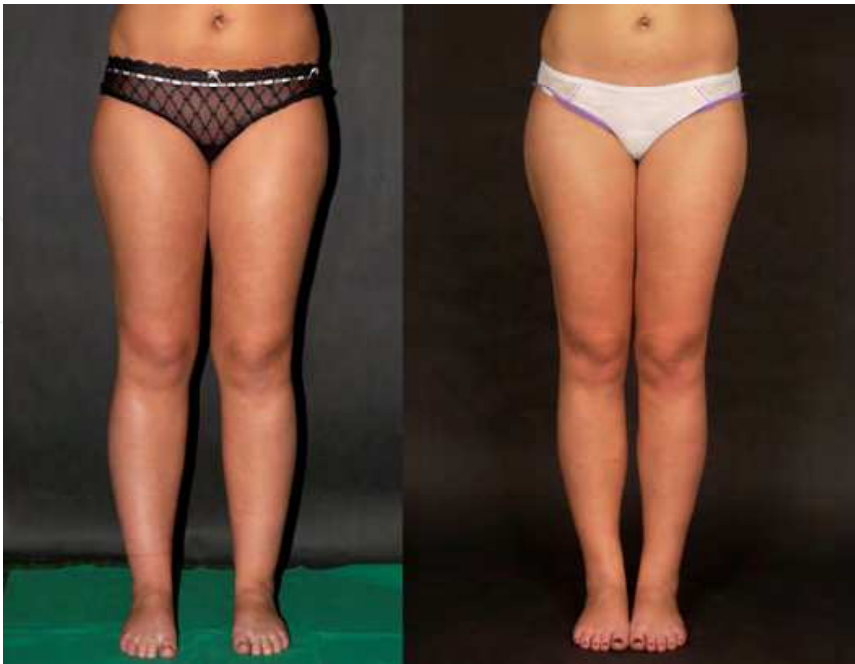

Fig. 14. Patient pre- and 6 months postoperative, 1 session lower legs

Just as much important is the postoperative complex physical therapy (CPT). CPT consists in manual lymph drainage (MLD) and compression therapy for 4-6 weeks or for the time of visible postoperative edema. The combination of liposuction and CPT is the optimal treatment to lipedema.

2.4 Results

A study with 25 patients demonstrated the effectiveness of liposuction against lipedema ⁽³⁵⁾. All patients were between 22 and 65 years old. Twenty patients had lipedema affecting the whole leg, 3 had lipedema of the thigh, and 2 had lower leg involvement only. Clinical examination pre- and postoperative included leg volume measurement using 3D imaging (Image3D, Bauerfeind) and self-assessment, based on a questionnaire with 15 criterias. They were assessed by the patient using a visual analogue scale (VAS) of 0 to 10. The survey was completed prior to beginning therapy and again at 6 months after the final liposuction treatment (Figure 15).

Questionnaire		Results		
Rate the level of pain on a scale of 1-10 (no pain to very severe pain)	<div>keine<div>012345678910</div>sehr starke</div>	Mean VAS before liposuction	Mean VAS 6 months after liposuction	Significance
Are the affected areas painful?	<div>keine<div>012345678910</div>sehr starke</div>	7.2	2.1	p<0.001
Are the affected areas sensitive to touch or pressure?	<div>keiner<div>012345678910</div>sehr stark</div>	6.4	1.9	p<0.001
Do you bruise easily (hematoma)?	<div>keine<div>012345678910</div>sehr stark</div>	7.9	4.2	p<0.001
Do you feel tension in your legs?	<div>keines<div>012345678910</div>sehr stark</div>	7.7	2.3	p<0.001
Do you feel excessive warmth in the legs?	<div>keines<div>012345678910</div>sehr stark</div>	3.0	1.4	p<0.008
Do you legs feel cold?	<div>keines<div>012345678910</div>sehr stark</div>	3.8	2.1	p<0.120
Do you have muscle cramps?	<div>keine<div>012345678910</div>sehr häufig</div>	2.7	1.3	p<0.043
Do your legs feel heavy?	<div>keines<div>012345678910</div>sehr stark</div>	8.4	3.6	p<0.001
Do your legs feel tired?	<div>keines<div>012345678910</div>sehr stark</div>	8.4	3.5	p<0.001
Do you something have swelling?	<div>keine<div>012345678910</div>sehr starke</div>	6.9	3.3	p<0.001
Is there skin involvement?	<div>keine<div>012345678910</div>sehr starke</div>	3.5	1.3	p<0.001
Is there itching?	<div>keiner<div>012345678910</div>sehr stark</div>	4.2	1.9	p<0.001
Do you have difficulty walking?	<div>gar nicht<div>012345678910</div>sehr stark</div>	4.6	1.6	p<0.001
How much does the condition affect your quality of life?	<div>keine<div>012345678910</div>sehr stark</div>	8.7	3.6	p<0.001
How satisfied are you with the appearance of your legs?	<div>sehr zufrieden<div>012345678910</div>sehr unzufrieden</div>	9.5	5.0	p<0.001
Total score	(maximum 150)	92.0	39.0	p<0.001

Fig. 15. Questionnaire and results.

In most patients about 6000 ml tumescent solution (0,05% prilocaine) was infiltrated per session, with a maximum of 7000 ml and a minimum of 2000 ml. Liposuction was performed with vibrating cannula of 4 mm diameter. Patients were treated in 1 to 5 sessions (mean 2,5). The following regions on the body were combined and treated symmetrically:

- Medial aspects of the thighs and inner aspects of the knee
- Lateral aspects of the thighs and hip in the same or an additional session
- For larger-volume thighs the anterior aspects were also treated
- Lower legs

Three sessions at 4-week intervals were generally needed. The therapy usually began with the medial aspects of the thighs and knees or with the area that was causing the greatest discomfort. For each session the aspirated volume was an average of 2482 ± 968 ml and the pure fat component was on average 1909 ± 874 ml respectively 77%.

3D imaging showed a reduction in leg volume of 18.0 ± 3.8 to 16.8 ± 3.5 l. This corresponds to an average reduction of leg volume of 1.2 ± 1.0 l or 6.9 %.

The results of self-assessment of symptoms indicate a significant or highly significant improvement in all areas. With regard to pain, the chief symptom of lipedema, there was an improvement of 7.2 ± 2.2 to 2.1 ± 2.1 (Figure 16). There was also significant improvement in sensitivity to pressure, which is typical of lipedema, and bruising. The results showed also a highly improvement of quality of life (Figure 17).

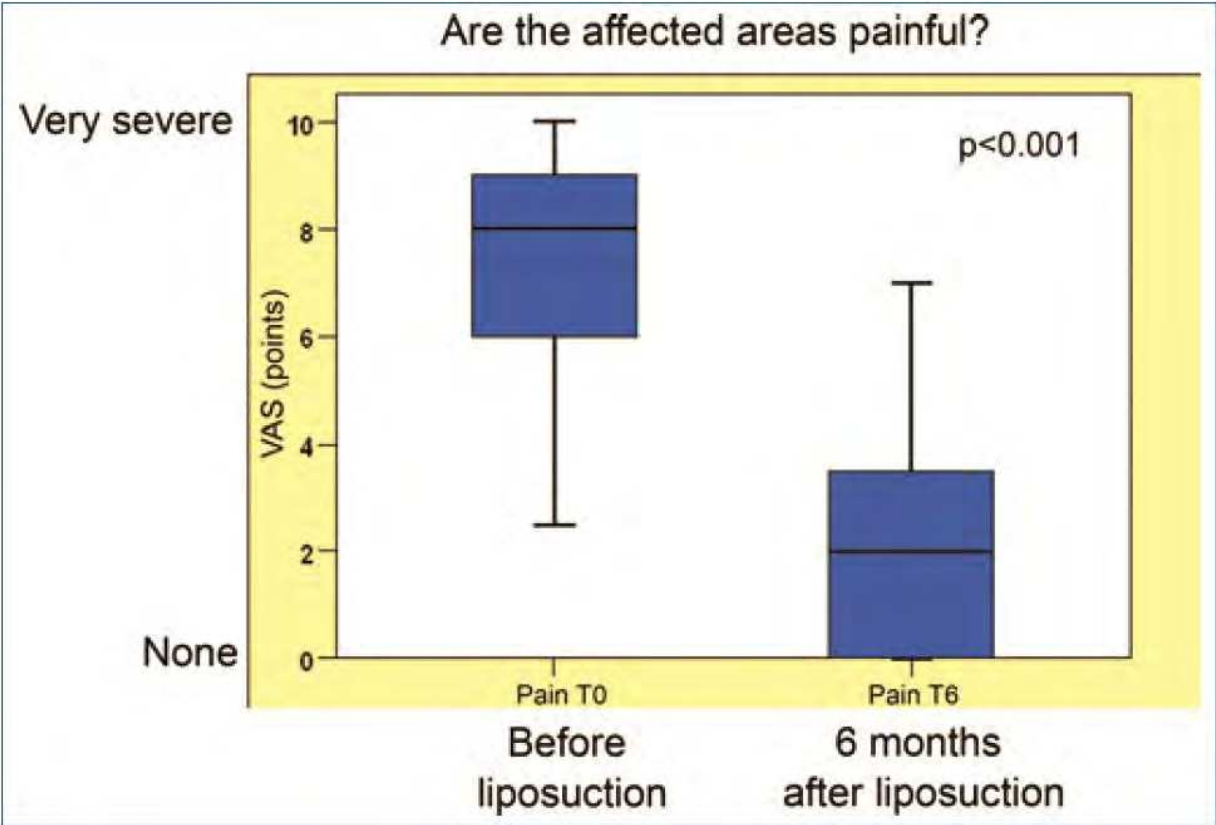


Fig. 16. Significant reduction of pain before and 6 month post liposuction

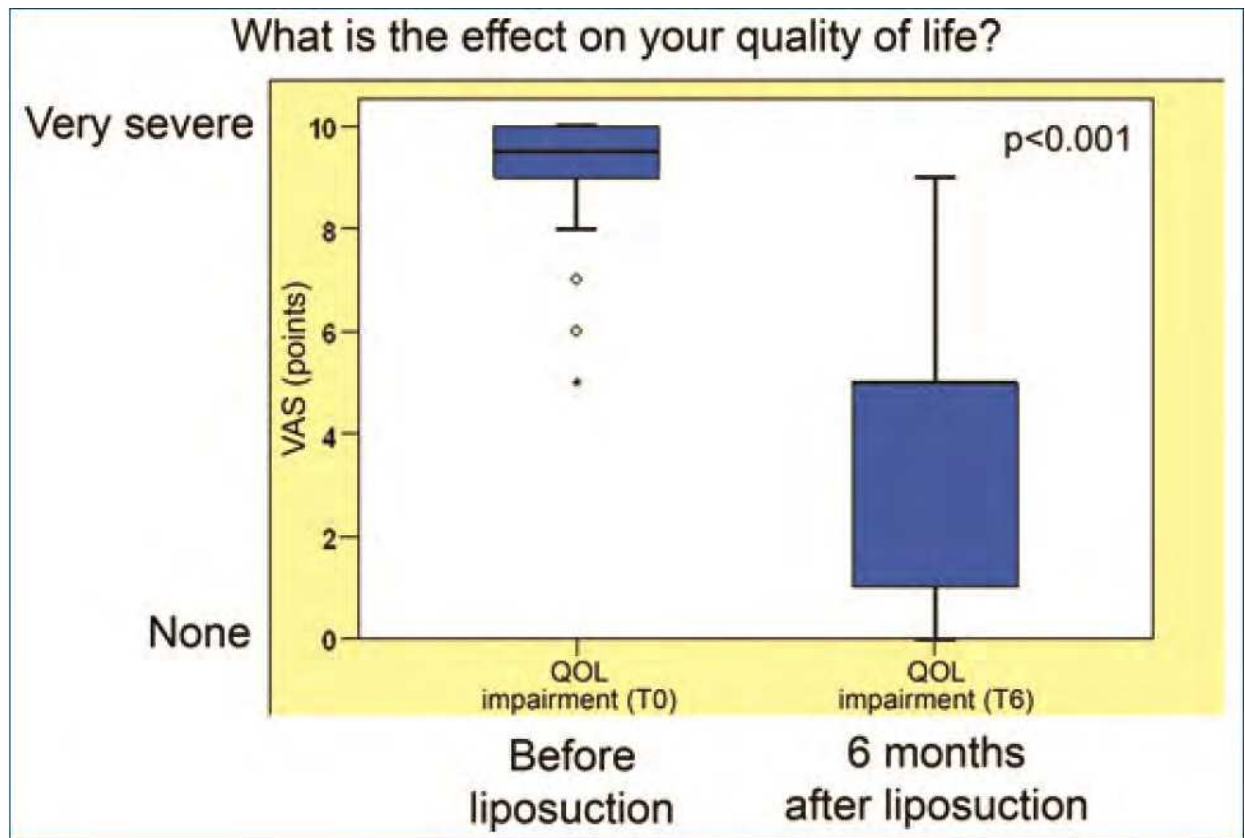


Fig. 17. Significant improvement of quality of life before and 6 month post liposuction.

2.5 Conclusion

When performed by an experienced practitioner, tumescent liposuction is a safe and effective method of treatment for lipedema. The results of therapy are better in younger patients with early-stage disease compared with more severe disease in older patients. CPT, before and after liposuction, is an important part of therapy.

3. Medial thigh lift combining energy assisted liposuction and dermal flaps suspension to the adductor tendon

3.1 Introduction

The medial thigh area remains a troublesome region for body contouring in patients with lipo-dystrophy and/or skin flaccidity. Liposuction has proven to be effective in patients with excess of fat deposits without a significant degree of skin laxity. The skin in this particular body area is often thin and inelastic and in most circumstances where skin laxity is present liposuction alone fails. To contour and tighten the inner thigh, it is necessary to combine liposuction with skin excision to achieve acceptable cosmetic results ⁽³⁶⁾.

Adverse results associated with current inner thigh lifting ⁽³⁷⁾ surgery include pigmented or hypertrophic scars, flattening of the vulva as result of excess of traction created by the lower flap on the vulvae tissues, caudal wound migration that cannot be hidden when using swimming suits (Figure 18), and recurrence of the inner thigh ptosis that may require additional corrective surgery ⁽³⁸⁾.

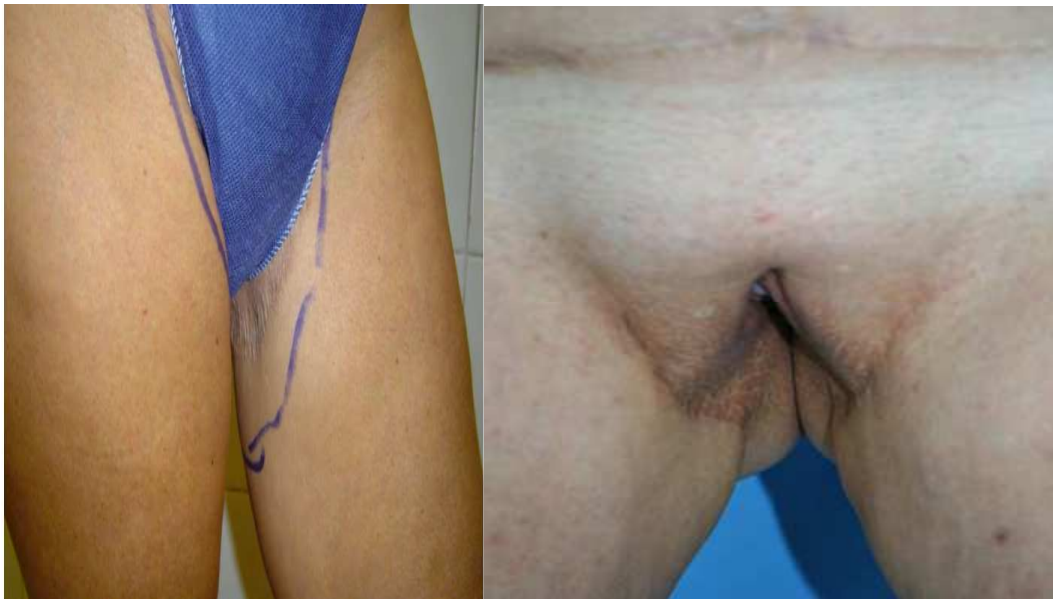

Fig. 18. Caudal wound migration that cannot be hidden when using swimming suits. Scar traction producing vaginal distortion

The anatomical absence of a well-defined and strong superficial fascial structure to anchor the inferior flap in a stable position and the histological skin characteristics of the inner thigh are two of the main reasons for poor results.

The purpose of this paper is to present the authors' technique of inner thigh lift using a new resection design of the dermo adipose flap. This technique allows an effective anchoring of the inferior flap of the inner thigh into the adductor major tendon at the pubic bone insertion. This new approach creates a strong and stable anchoring place for the inferior inner thigh flap. In the authors' experience this technique has proved safe and effective with a decreased morbidity and satisfactory cosmetic results.

3.2 Anatomy

The skin in the medial thigh has a minimal dermal component and has an average thickness of 0.03 mm.

The subcutaneous tissue of this area is separated in two layers by a poorly defined superficial fascia ⁽³⁹⁾. The thickness and quality of the fascia varies considerably from patient to patient and identification of this structure can be difficult at the time of surgery when tumescent local anesthesia is used.

The adductor muscle tendon added to the gracilis tendon is a fibrous structure, a finger thick in diameter that inserts on the ischiopubic portion of the pelvic bone (Figura.19).

It is easily identifiable and there are no significant anatomical structures located behind the tendon. The superficial fascia covers the tendon.

3.3 Patient selection

Correct patient selection and evaluation of their expectations are paramount. The strategy to treat these patients who frequently require various body lifting and liposuction procedures is planned at the initial visit. Evaluation of the degree of skin laxity and its quality, the overall extent of deformity of the inner thigh and the extent of lipodystrophy is relevant ⁽⁴⁰⁾.

An important aspect of the initial physical examination is the evaluation of the lower

abdomen and pubis. In the presence of significant lower abdomen fat deposits and skin excess along with a ptotic and enlarged fat pubic area, these parts should be treated before the performance of the inner thigh lift procedure ⁽⁴¹⁾.

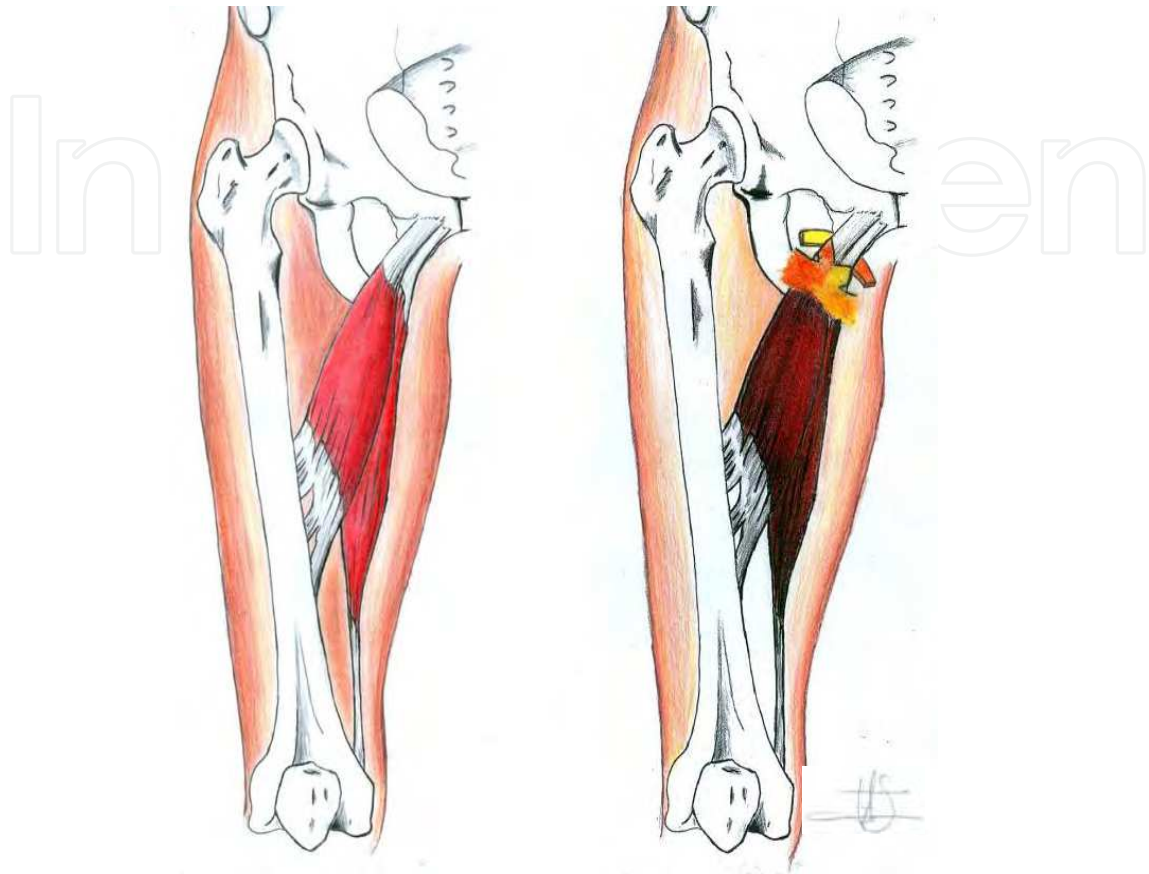


Fig. 19. Anatomy of the adductor muscles. Notice the situation in which the dermal flap is fixed to the tendon.

In our experience a conservative approach to the inner thigh area using energy-assisted liposuction (Ultrasound, Laser or Radiofrequency) without skin resection has resulted in satisfactory improvement in 50 % of our patients.

When the liposuction fails to achieve adequate cosmetic results the inner thigh lift surgery is performed 3 to 6 month after the initial liposuction. Most of our patients undergoing inner thigh lift are females between the ages of 35 and 75. We have found that in men the presence of hair in the inner thigh skin makes difficult to create a dermal flap free of hair follicles.

The Mathes ⁽⁴²⁾ and Kenkel classification has been very useful in deciding what patients are good candidates for the authors' inner thigh lift procedure.

A standard comprehensive preoperative work up is performed in all patients. In patients at high risk for DVT active preventive maneuvers at surgery such as sequential compression and the use of compression socks are used. Contraceptive pills are discontinued.

3.4 Surgical technique

A Clorexidine soap shower is routinely performed just before the patient is moved to the operating room. Standard preoperative photographs are taken. Using a good quality pen, the patient is marked in the standing position with the knees apart. Using the "pinch test"

we determine the degree of redundant skin that needs to be removed and the amount of fat that will be suctioned by liposuction ⁽⁴³⁾. Marking the patient in a resting position may result in over-resection of the inner thigh lower flap. The marking of the outer border of the ellipsoid-shaped skin incision is then completed (Figure 20).

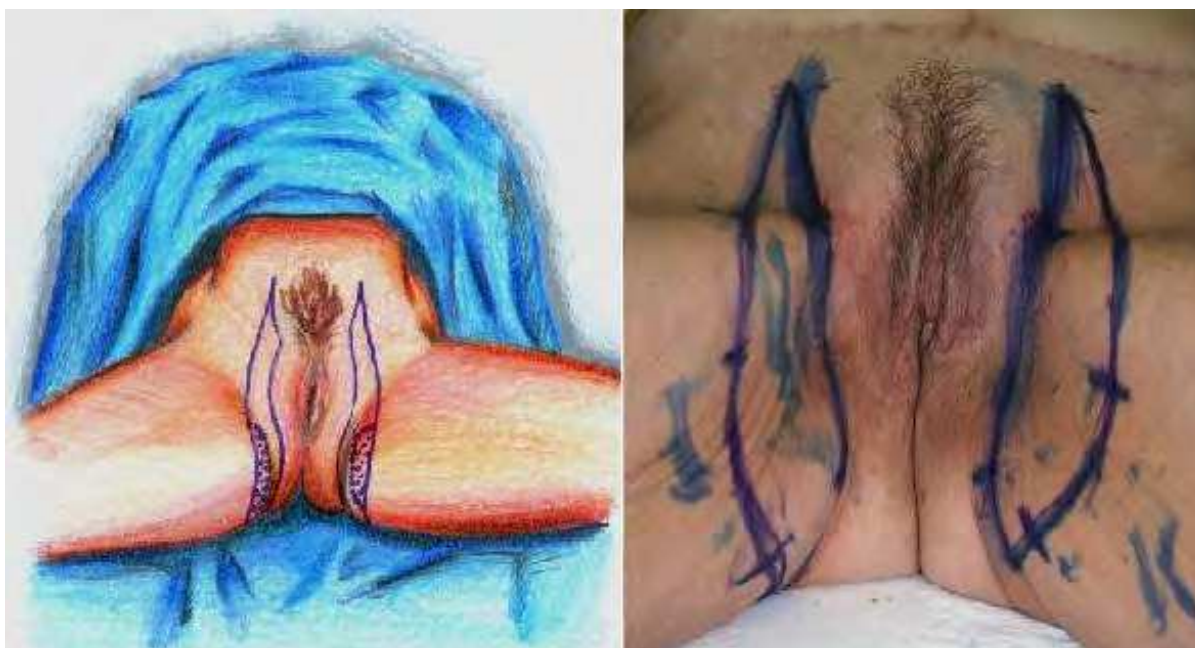

Fig. 20. Marking of the skin to be resected, the dotted area corresponds to the dermal-adipose flap.

Our patients prefer the scars placement on the sides of their pubis instead of the inguinal sulcus because it is easier to cover it with their underwear or beach garments. The medial incision of each side is marked in a vertical way in one of the lateral borders of the mons pubis and advanced vertically to the adductor tendon projection on the skin (Figure 21).

From the adductor tendon projection to the ischion projection the skin incision is placed in the sulcus that exists between the labia major lateral aspect and the inner thigh. We avoid the extension of the skin incision beyond the point of projection of the ischion at the buttock's fold. Care is taken to keep enough skin on the labia side in order to avoid distortions and preserve the normal anatomy of this area. (Fig. 18)

The extent of the ellipsoid skin excision ranges from 2 cm to 5 cm at the central area of the ellipse to be excised.

With the patient in the prone position we mark the dermal-adipose fixation flap.

The dermal-adipose fixation flap is 1 cm. wide and 8 to 10 cm. long, with a central area 2 cm wide just in the projection of the vector that we want to create during the flap elevation.

The patient is then placed in a frog-leg position with both feet in contact. Standard sterilization preparation is completed and local tumescent anesthesia is infiltrated ⁽⁴⁴⁾. A 0.06% solution of Lidocaine is infiltrated in the area to undergo liposuction and 0.12 % Lidocaine is infiltrated on the area of skin resection. Following the completion of the liposuction using the Avelar approach ⁽⁶⁵⁾, the epidermis is removed from the skin of the dermal-fat flap preserving as much dermis as possible. This step is carefully performed because this small flap is the anchor of the lower inner thigh flap and holds the lower flap in place under tension following the completion of the surgery.

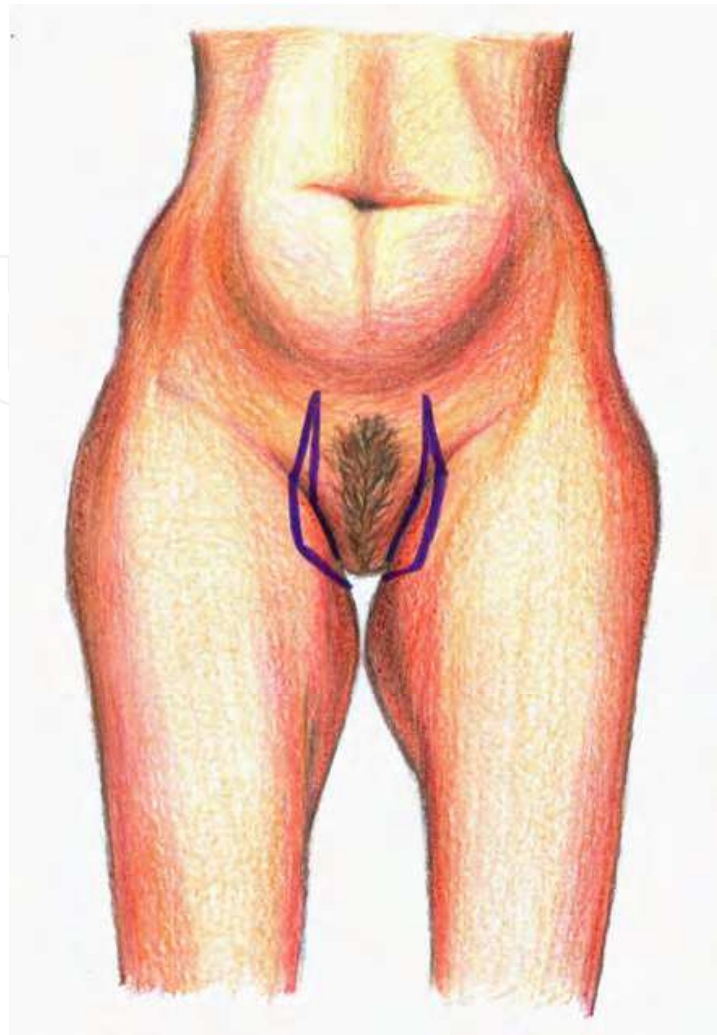


Fig. 21. Front view of the marking with the patient standing.

The rest of the skin ellipsoid area is then removed.

During surgery deep dissection of the femoral triangle area is avoided to prevent potential serious bleeding and lymphatic trauma.

At the dermal-fat flap two strips 1 cm wide and 4 cm long are performed.

Using blunt dissection with a Halsted forceps a tunnel is created under the adductor major tendon. With the same forceps the end of each dermo-adipose strip flap is grasped and both ends are then passed under the tendon. The two flaps are then wrapped around the tendon. The flaps are fixed to the tendon suturing them to each other and to the tendon with 2/0 permanent multifilament sutures. The excess of the flaps is resected.

The superficial fascia of Colles is identified. Anchoring sutures using 2/0 Vicryl, are placed to approximate the Colles' fascia with the subdermal layer of both superior and inferior skin flaps (Figure 22).

Superficial subcutaneous sutures are placed with 3-0 Monocryl sutures and sterile Micropore tape is placed on the skin to reduce the tension on the inner thigh suture line.

All patients receive single IV doses of antibiotics (Cefazoline) during the procedure.

Drains are not routinely placed. Compression garments are used for 3 weeks. Early ambulation starts the night of the surgery and is encouraged to reduce the risk of DVT. The majority of patients are discharged the day of the surgery.

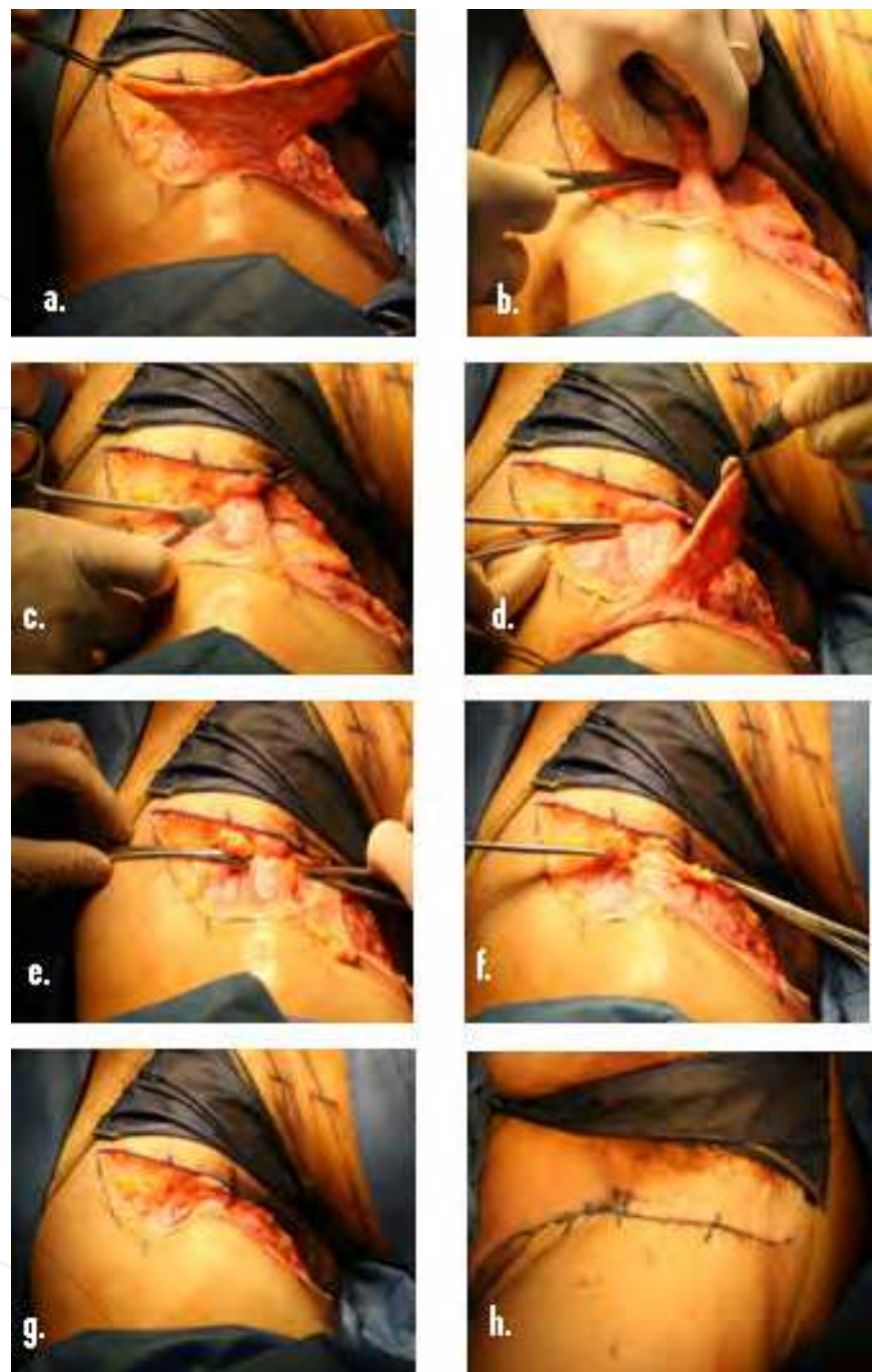

Fig. 22. Consecutive steps from the carving of dermal-adipose flap, tendinous tunnel creation and subsequent fixation

3.5 Discussion

Most of the current medial thigh lift techniques are based on Lockwood’s ^(45, 46) concept of supporting the thigh tissues with sutures ^(44, 47). The authors' technique introduces a more substantial approach to support the flap while reducing distortions of the vulva and mons pubis (Figure 18). This technique also avoids the T incision. The success in this procedure depends on patient selection, surgical planning and patients' realistic expectations (Figure 23).

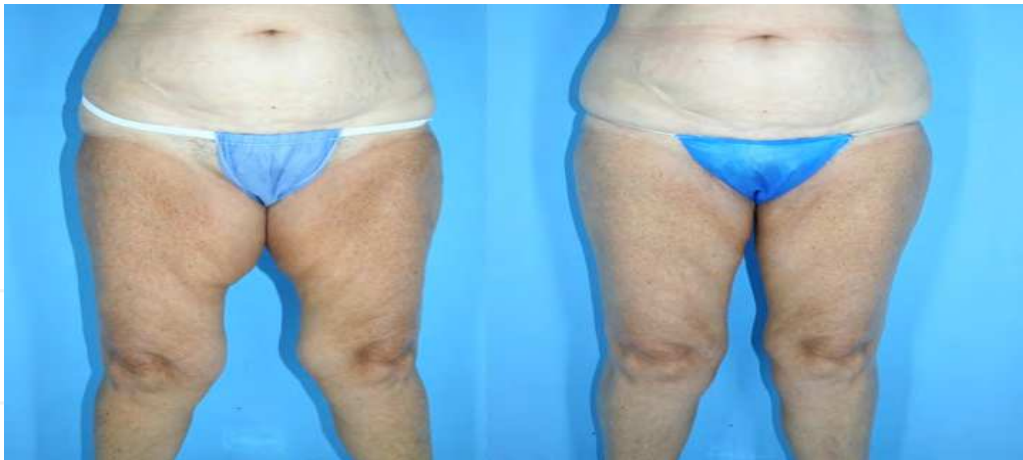

Fig. 23. Pre-and postoperative photographs of Medial Thigh Lift combining liposuction and Dermal Flaps Suspension to the Adductor Tendon

4. Breast reduction by liposuction

4.1 Introduction

Several techniques for breast reduction by excision under general anesthesia are available. Extensive scarring, necrosis of the nipple-areolar complex and postoperative pain are common sequelae, contributing to a long recovery time. The potential for breast-feeding following surgical reduction may be impaired.

Breast reduction by liposuction using tumescent local anesthesia (TLA) and powered cannulas eliminates most of the complications of the excisional technique. There is no need for hospitalization, the downtime is minimal and there are no disfiguring scars. Therefore, this technique could be the preferred treatment modality in a selected group of patients.

Patient satisfaction is high, which can be explained by the significant volume reduction (average 50%) in combination with a ptosis reduction, short downtime and minimal scarring. However, secure and careful patient selection is critical.

4.2 Patient selection

The content of fat in the breast increases with age. This is independent from the BMI. For that reason, older women are good candidates for breast reduction by liposuction as this technique reduces the fat amount only. The breasts of younger women as an average contain less fat and more glandular tissue, which diminishes the amount of fat that can be aspirated. The Body Mass Index (BMI) could be used to indicate the amount of fat in the breasts in younger women. However, the BMI cannot be used as an absolute selection criterion, because patients with fatty legs and a high BMI as a consequence, as we see in patients with lipedema, do not necessarily have a high percentage of fat in the breasts.

With the exception of post-menopausal women, patients who desire more than 50% reduction in breast size are not good candidates for breast reduction by liposuction using TLA. Moderate lifting and conservation of the original shape of the breasts are realistic goals; however, patients who are more concerned about breast lifting than volume reduction should not have breast reduction using TLA. The ideal candidate is one who refuses excision and will accept any degree of breast reduction that is possible with liposuction using TLA. All patients should understand and accept the relative unpredictability of the

amount of fat that can be removed with liposuction, especially in younger women. There is no reliable benchmark for the amount of size reduction a patient may expect with liposuction. Bra size is unreliable because it is affected by the individual wearing it. A personal history of breast cancer is an absolute contraindication.

4.3 Technique

A preoperative mammogram should be performed to identify malignant or benign tumors, and the mammogram serves as a baseline. The mammogram should be repeated yearly to detect post-operative calcification, although this is very unlikely.

Photo-documentation and precise measurements for volume and ptosis are performed (Figure 24).

Preoperative antibiotics are administered.

Preoperative markings are made with the patient in the upright position (Figure 25). They may extend under the armpit in case the lateral extension of the breast should be treated as well.

Local anesthesia is given to 8 skin sites on each breast.

Sharp needles are introduced to start the infiltration of the tumescent solution in the breast using a peristaltic infiltration pump (Table 1). The needles are regularly re-positioned in the breast tissue as tumescence is obtained in each area (Figure 26). The infiltration is initiated in the deepest plane, just above the muscle layer. Also the more superficial layers, including the most superficial subdermal plane, are meticulously infiltrated.

After completion of the infiltration, at least 30 minutes is dedicated to the even diffusion of the solution through the breast tissue and to develop adequate anesthesia and vasoconstriction. A second infiltration can then be performed to achieve profound tumescence. The total volume of tumescent solution infiltrated will be 150-200 percent of the measured breast volume (eg. 1500-2000 ml) will be infiltrated when the breast volume was measured as 1000 ml by water displacement.

Incisions are made in the lateral and medial infra-mammary crease. Liposuction is then started using a powered blunt cannula with a 3 mm diameter. A criss-cross pattern is performed through the various layers of the breast. The entire procedure is performed from the infra-mammary incisions only. Most of the fat lies deeply, but the layers close to the surface must also be suctioned in case the maximum amount of fat has to be removed. The surgeon must avoid aggressive suction from the upper pole of the breast. Otherwise, irregularities may be created and/or the breast may take on an unnatural shape which may become visible when wearing garments with low necklines.

After suction of the second breast, one hour should be allowed for separation of infranatant and supranatant in the canister before calculating the final volume of tissue removed.

Excessive suction under the nipple should not be performed in order to avoid necrosis and loss of sensation.

One breast is suctioned completely before the other is begun. When breasts are of equal size, care must be taken to remove the same amount of fat from each breast. The breasts are wrapped in a special absorbent material and an elastic garment which allows tight but adjustable compression. A second more tight compression band can be applied for 1 day to prevent extensive hematoma.

4.4 Postoperative period

The patient may shower on the morning after surgery. Compression is continued for 2-4 weeks. The incisions may still have some drainage. During the first days, relatively firm

compression is maintained in order to prevent seroma and edema. After the first or second week a sport-bra is used. Mild activity can be resumed after two days. Solid masses will be noticed in the weeks following treatment. It takes about four months for complete resolution of the masses. The surgical procedure itself is generally easier on the patient than they expect. Normal office work can be resumed within a few days of surgery, but intense physical activity must be delayed because of sensitivity of the breasts during motion. Postoperative visits are scheduled after 6 and 16 weeks. At these times, photodocumentation and measurements of volume and ptosis are repeated.

4.5 Expected benefits of the procedure

The goal of breast reduction by liposuction is a reduction in volume with negligible scars, minimal risk of complications and conservation of the original shape of the breasts.

Patients are concerned that breasts will look like “empty bags”. Surgeons who practice liposuction using TLA with powered microcannulas are aware of the considerable retraction of subcutaneous tissues on other body areas, especially on the abdomen and neck. A similar phenomenon is seen after liposuction of the breast. This can be explained by reduction in breast weight, the irritation of the connective tissue in the subcutaneous layer and subsequent contraction during healing and contraction of Cooper’s ligaments. Induction of scar tissue results in further contraction. The “empty bag” phenomenon does not occur even when 50 percent or more of the breast volume has been removed. The average lifting effect is 3 cm and rises with age (Table 2).

Experience demonstrates that in properly selected cases, a 20-70 percent reduction can be achieved. Patients who have had 30 percent or more of the breast volume removed are usually very satisfied also because they feel that their breasts are the same shape as before surgery but without the feeling of being heavy.

Preoperative back and shoulder pain usually disappears or diminishes substantially when 30 percent or more of the breast volume has been removed.

4.6 Considerations

If the patient wishes a reduction in ptosis and/or a change in breast shape, liposuction is not the correct procedure. If volume reduction is the goal, then liposuction should be considered (Table 3).

If long scars and general anesthesia are rejected, a second opinion focusing on breast reduction by excision may be unnecessary. The short recovery period and minimal risk of complications may be major deciding factors for patients who chose breast reduction by liposuction (Figure 27,28).

If the breast size has increased over the years, discounting the effect of pregnancy and hormonal treatment, the amount of fat in the breasts has probably increased. This may suggest that a considerable reduction is possible with liposuction. When excessive weight is gained during puberty, the breast probably contain a great deal of fat. A considerable reduction by liposuction is possible in these patients. When large breasts are caused by glandular hypertrophy, liposuction will probably be less successful. When the development of larger breast are associated with a gain in body weight, a successful reduction by liposuction is likely.

There is no reason to pretend that glandular tissue might be damaged. The evaluation of specimens taken from the supranatant fat showed only minor fragments of ductuli in a small minority of younger patients. It is extremely unlikely that lactation will be impaired by this minimal damage.

4.7 Side effects and complications

Most patients develop a temporary loss of sensation around the nipple. The breasts are usually sensitive for at least several weeks following surgery. Hematoma may develop in the hours or days following surgery. Drainage must be followed by firm compression. Other side-effects and complications are similar as those in liposuction using TLA in other body areas. Postoperative mammograms rarely reveal any new calcifications.

4.8 Conclusion

Breast reduction by liposuction using TLA and powered cannulas is a safe and effective treatment modality in properly selected patients. Complications are minor and infrequent, and patients are able to return to normal daily activities within 3-4 days after the procedure. Sports and heavy physical activities can be gradually resumed, and patient satisfaction is excellent.

NaCl 0.9%	1000 mL
Lidocaine	500 mg
Epinephrine	1 mg
Sodium bicarbonate 8.4%	10 mL

Table 1. Solution as used in breast reduction under tumescent local anesthesia.

	Average	Spread
Age (years)	46	16-77
Ptosis reduction (cm)	3	0-7,0
Supranatant Fat Removed per breast (mL)	550	80-2275
Breast Volume Removed (%)	54	24-87
TLA infiltrated per breast (mL)	1925	650-4900

Table 2. Data on 200 women after breast reduction by liposuction using Tumescent Local Anesthesia.

Women who refuse breast reduction by excision
Women who will accept a reduction of 50% or less
Women > 40 years of age
Unoperated large breasts
Large breasts after surgical reduction
Asymmetry in volume of the breasts
Patients who prefer local anesthesia over general anesthesia
Patients with (relative) contra-indications for general anesthesia

Table 3. Good candidates for breast reduction by liposuction using Tumescent Local Anesthesia.

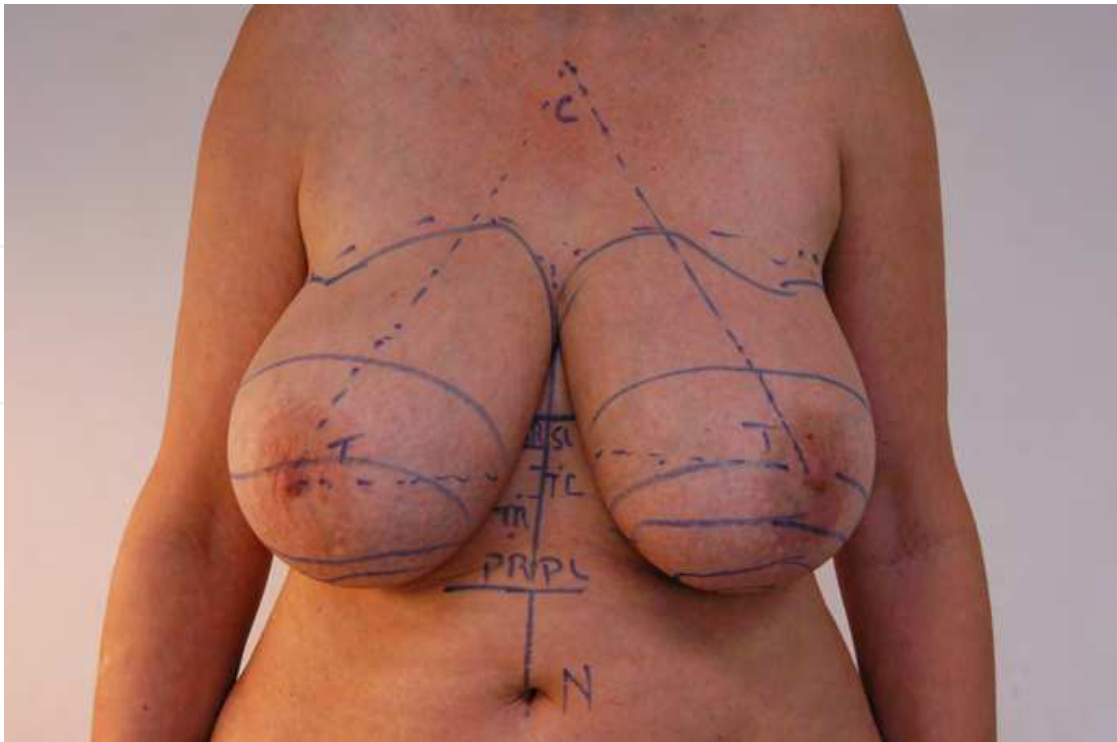


Fig. 24. Preoperative measurements, S representing position of inframammary fold, P representing lowest projection of breast and T representing projection of the nipple. L represents Left, R represents Right.

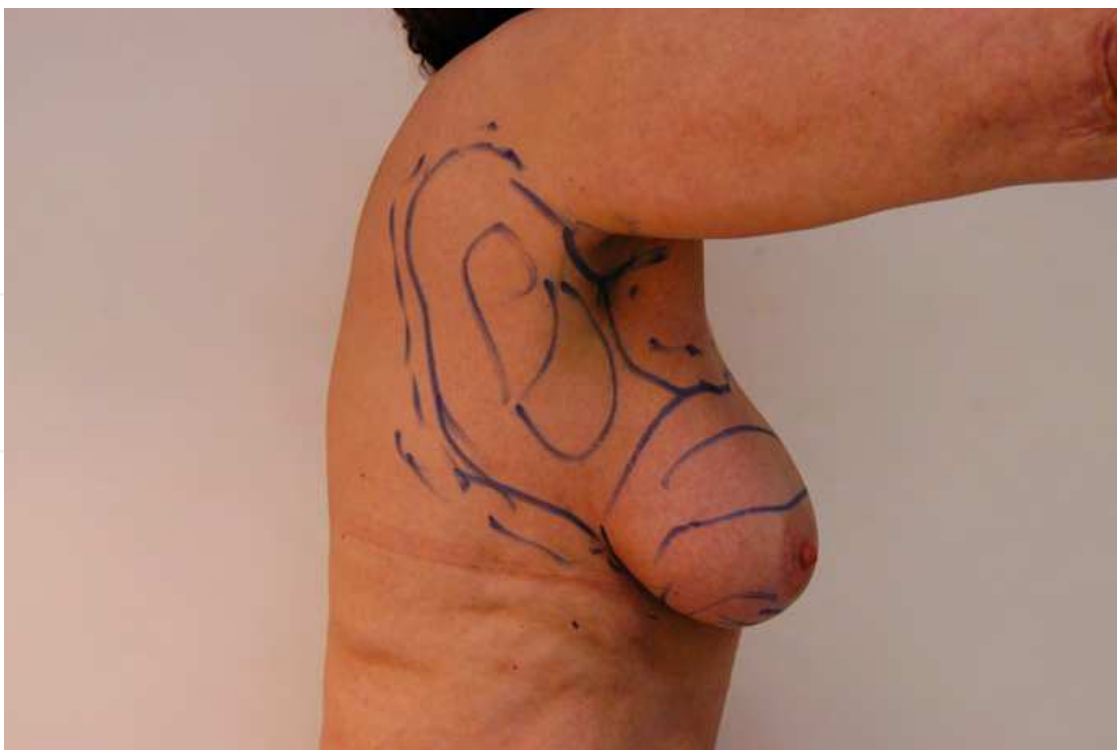

Fig. 25. Markings guiding the surgeon for areas and planes of fat removal side view with axillary tail.

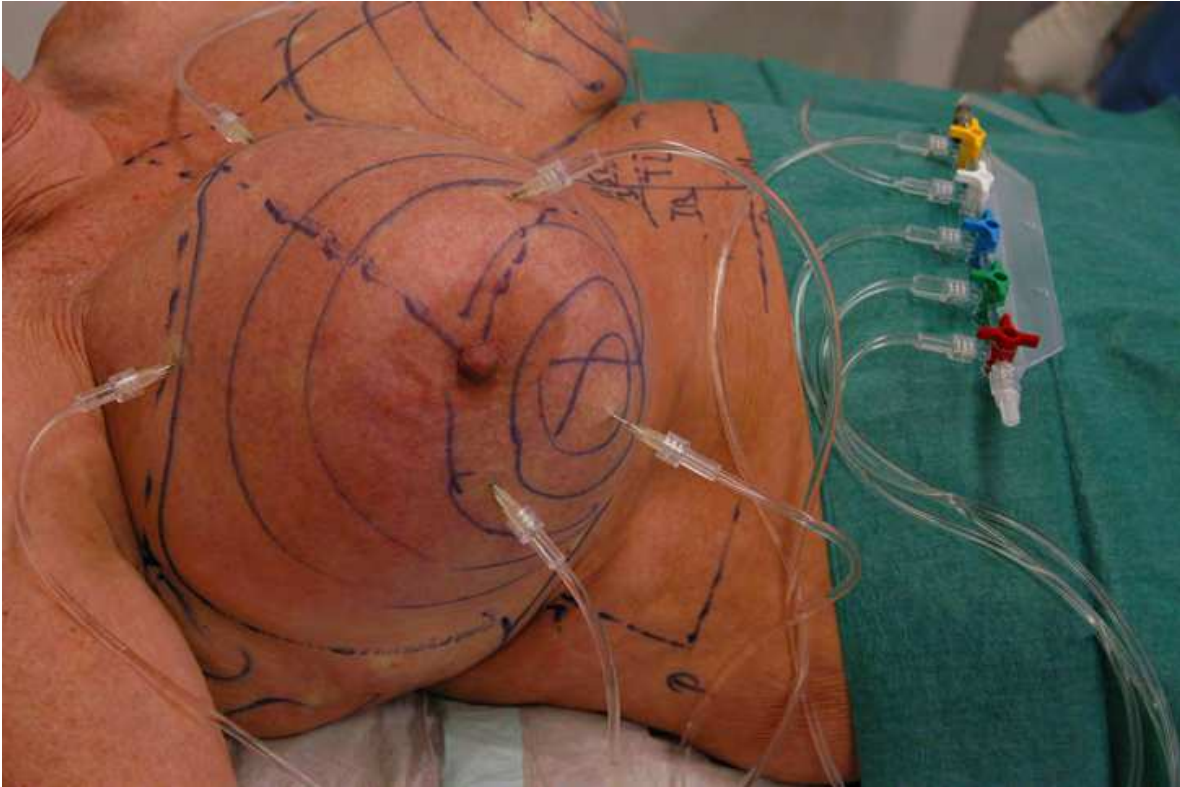


Fig. 26. Five infiltration needles are used during infiltration.

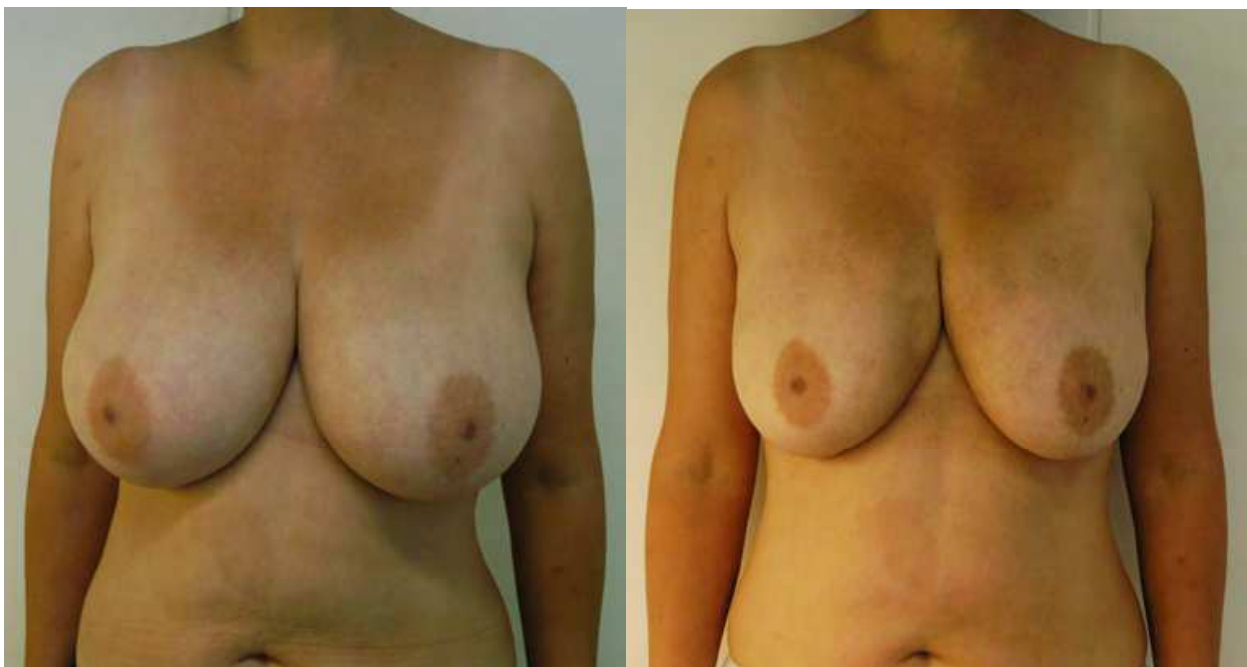

Fig. 27. A: Before liposuction of the breast in a 42 year-old woman. B: 4 months after liposuction: volume reduction 675 ml supranatant fat per breast (56%) and ptosis reduction 3,7 cm (50%).

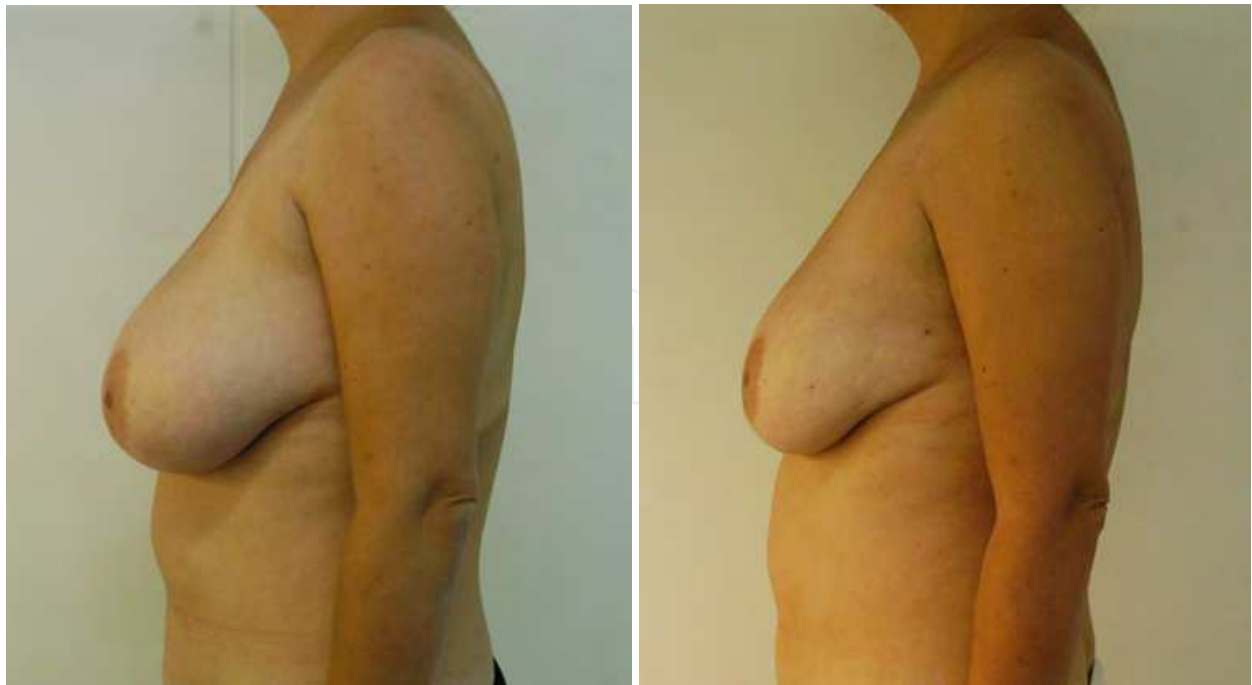

Fig. 28. From axillary tails additional 200 ml supranatant fat aspirated. A Postoperative view.

5. Safety combination of liposuction and abdominoplasty with B&S technique

5.1 Introduction

Tummy tuck, or abdominoplasty, is the fifth most frequently requested cosmetic procedure. More than 116,000 abdominoplasty surgeries were performed in the United States alone during the year 2010 ⁽⁴⁸⁾.

The abdominoplasty with simultaneous liposuction is a procedure that has become a safe and effective solution for the abdominal contouring and flaccidity. The history of abdominoplasty goes back to the late eighteenth century in the Johns Hopkins Hospital where it was described as a conjunct procedure for large abdominal wall hernias, and through out the twentieth century it had evolved into a procedure with acceptable aesthetic results.

Although this procedure is becoming more popular, classical abdominoplasty is related to a relatively high complication rate. General and local complications include pulmonary thrombo-embolism, seroma, hematoma and necrosis of the dermal-fat flap.

According to a national survey, postoperative mortality in a national survey was 0.2% in 1972 ⁽⁴⁹⁾ and decreased to 0.04% by 1989 ⁽⁵⁰⁾. The last national survey had no mortalities in over 11,000 procedures ⁽⁵¹⁾. Factors leading to the decrease in the incidence of wound healing problems were: undermining the flap in an inverted "V" fashion, avoiding operating on active smokers, avoiding excess tension on the flap closure, limited flap thinning and avoiding excessive flap liposuction.

Although major complications have diminished in recent decades, wound complication rates remain high—up to 30 % ^(50, 51, 52, 53, 54).

After the creation and publishing of the blunt-tipped liposuction by Yves-Gerard Illouz ⁽⁵⁶⁾, the history of the abdominoplasty was changed completely and new combinations of surgeries emerged. Through out the past three decades there has been a series of publications and creations of new surgical techniques related to the association of

liposuction and abdominal surgery, including proposals for reduction of abdominal flap dissection to decrease the complications statistics.

During the 1990s, the combination of liposuction and abdominoplasty gained much popularity ^(55, 57, 58, 59). The increased use of tumescent anaesthesia in particular, enabled the procedure to be performed ambulatory – often in a physician's office setting ^(60, 61, 62, 63, 64). Despite these developments, wound complications such as seromas, dehiscence and necrosis still remained high ^(58, 59, 60).

Juarez Avelar, MD, postulated that large-scale undermining of the abdominal flap involving the rupture of the lymphatic and perforator blood supply caused wound complications. To reduce these complications, he developed a new surgical technique that avoids wide undermining, which he presented at the 36th Brazilian Congress of Plastic Surgery in 1999^(65, 66). Blugerman then modified this specific technique by including the use of tumescent anaesthesia ⁽⁶⁷⁾.

This technique with the combined use of liposuction in abdominoplasty under the tumescent local anesthesia has been proved to be an effective technique to reduce complications. The tumescent infiltration used for liposuction of the abdominal wall creates an internal ex-sanguination and vasoconstriction which eliminates all stagnant blood that can be injurious for the flap, reduces in an important manner the vascular injury and the blood loss. Also the liposuction of the superior portion of the abdomen and flanks makes it possible to do a selective undermining of the flap thus preserving the vascularity and sensitivity of the flap. Adding to this, liposuction of the flap and contiguous areas greatly improve the cosmetic outcome.

Nowadays we have combined the use of laserlipolysis and radiofrequency assisted liposuction ⁽⁶⁰⁾ with the abdominoplasty in patients with different indications, such as vascular fragility or cutaneous flaccidity correspondingly, bringing better results with lower risks.

The purpose of this article is to demonstrate the safety and effectiveness of this relatively new abdominoplasty technique.

6. Patients and methods

Between April 2002 and December 2010, 852 patients underwent surgery to remove excess abdominal skin and fat. All of these patients had surgery in well-equipped office facilities on an outpatient basis. Of those patients, 97% were female and ranged in age between 20 and 82; the average age was 47.

Indications for abdominoplasty were localized adiposities with flaccid, poor-quality skin.

Patients were premedicated with 3–5 mg of midazolam, sedated with propofol and locally infiltrated with 0.05–0.1% of tumescent solution (lidocaine, epinephrine, and sodium bicarbonate). The concentration and volume of tumescent solution was adapted to allow maximal volume infiltration of the treated areas and did not exceed 50 mg lidocaine/kg.

Liposuction with powered cannula (PAL) was then performed on the entire abdominal region, starting at the deep and ending at the superficial levels. Under the skin to be resected, a radical liposuction was performed to remove as much fatty tissue as possible. On the upper abdomen a moderate liposuction was performed. The skin of the lower abdomen was then resected very superficially (Fig.29).

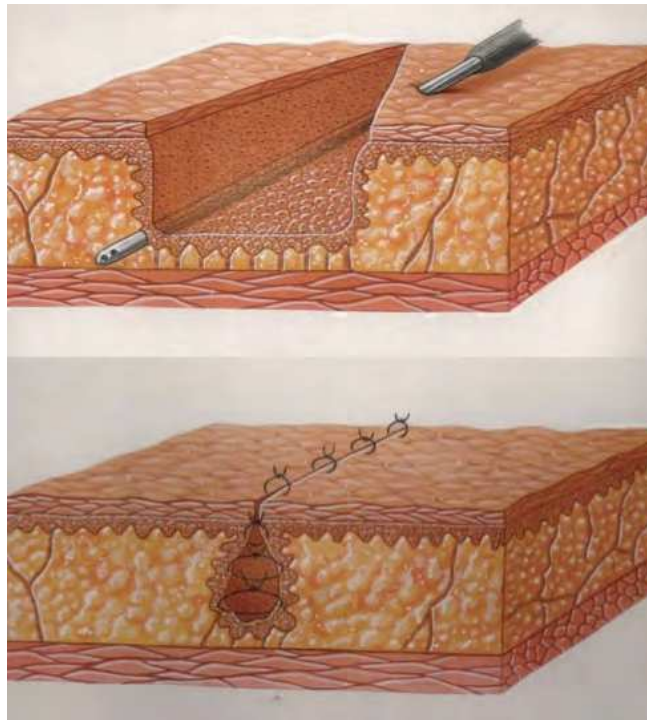


Fig. 29. The original concept of this procedure, consisting in radical liposuction of the area where the desepithelization will be done with subsequent plication.

Caution was given to specifically resect only the dermis and preserve the subcutaneous structures. For umbilicus transformation, undermining was performed restrictively and only in the medial plane to preserve the para-median perforating neurovascular bundles (Fig. 30) and to enable umbilicus re-implantation.

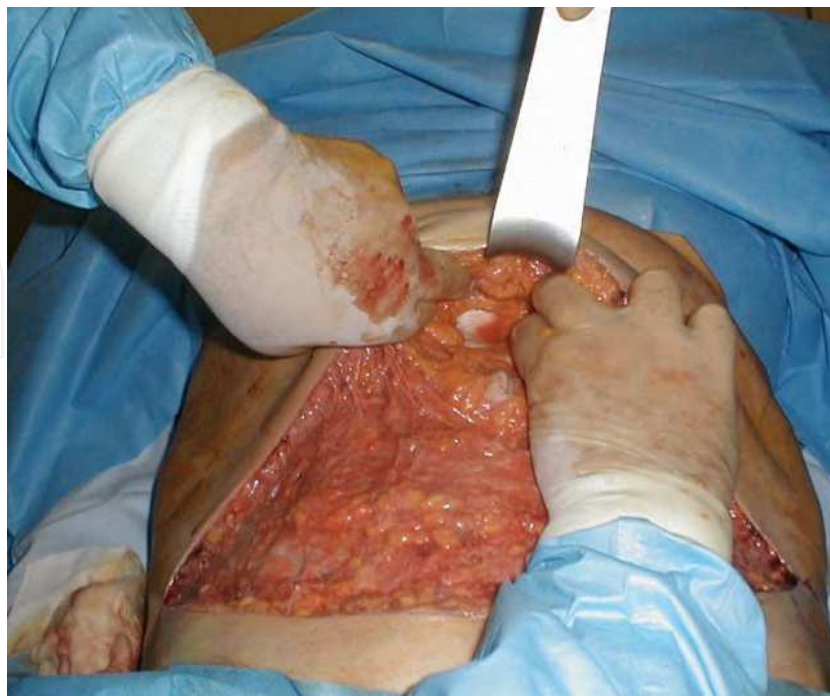

Fig. 30. Medial plane undermining, thus preserving the abdominal wall perforators.

In cases with rectus diastasis ($n=27$), the undermining of the median plane was continued superiorly until the xiphoid. When necessary, small amounts of tumescent solution were infiltrated under the rectus fascia, enabling the diastasis to be closed with strong nylon sutures under direct vision.

Wound closure was performed directly, without further undermining, by folding over the subcutaneous structures. No drains were used. Patients were mobilized immediately after the operation and then given non-steroid antiphlogistic to control their postoperative pain.

7. Results and follow-up

Full abdominoplasty with umbilicus transposition was performed in 556 patients. Mini-abdominoplasty with liposuction was performed in 296 patients. There were no intra-operative complications. There were no cases of skin necrosis. Wound infections were observed in 13 patients (5,2%). One patient was admitted to hospital for minor wound care. There were no cases of skin necrosis and no seromas were aspirated. One patient developed a suture fistula with a resulting wound dehiscence (4 cm diameter), and achieved secondary healing under ambulatory care. Two patients reported prolonged pain (more than one week), and only one patient required more than one week to resume normal activity (Fig. 31).

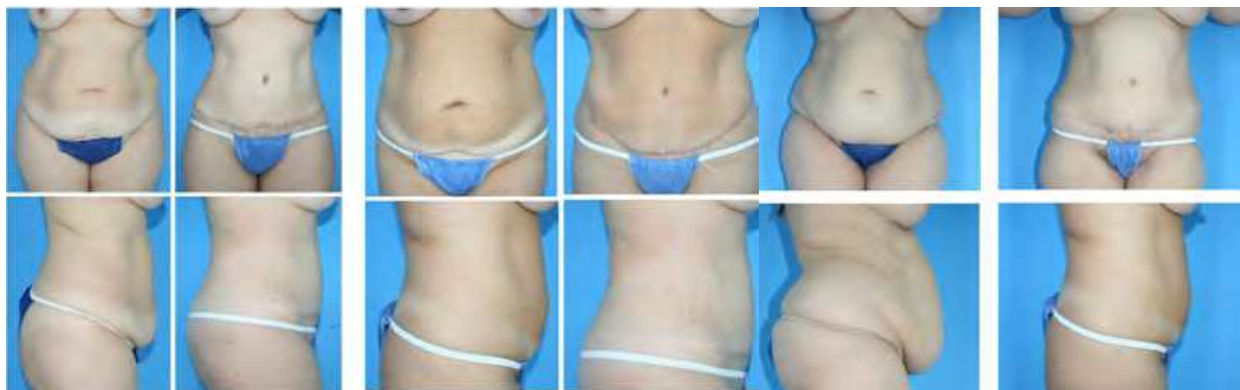

Fig. 31. Pre-operative results of 3 different patients.

8. Conclusion

Classical abdominoplasty with wide-flap undermining certainly achieves the best aesthetic result with low scarring. The aesthetic result may be improved by combining it with liposuction, although not always considered to be safe ⁽⁶⁸⁾. The elimination of general anaesthesia may reduce systemic complications, as was demonstrated by Rosenberg ⁽⁶⁹⁾. The rate of local complications however remained high, so Avelar temporarily refrained from performing the procedure ⁽⁶⁵⁾.

Conventional abdominoplasty with wide undermining results in profound devascularisation of the abdominal flap, ^(70, 71) explaining complications such as skin and/or fat necrosis. Furthermore, wide undermining creates a large wound surface that is prone to seroma. Lymph drainage is also impaired by separating the perforating vessels that are exasperating the problem. The trend towards inverted “V” type undermining certainly acknowledges the need to preserve better flap perfusion. Decreased sensibility in the hypo-gastric region is also a problem not to be underestimated after wide undermining ⁽⁷¹⁾.

The principle of minimal undermining combined with extended liposuction, as originally proposed by Avelar ⁽⁶⁵⁾, appears to solve most of these problems (Fig 32).

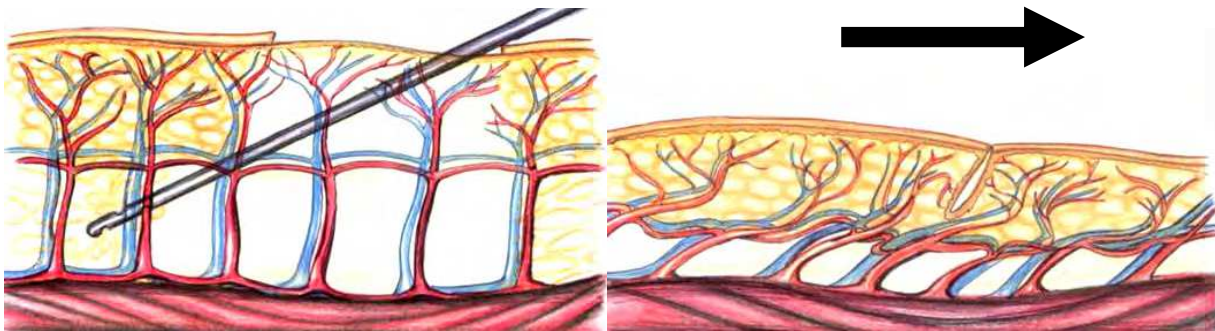


Fig. 32. Extended liposuction with minimal undermining described by Avelar ⁽⁶⁵⁾.

Performing abdominoplasty in sedonalgesia using the tumescent solution on an outpatient basis appears to be a safe procedure. Further studies are required to confirm the low complication rates.

Liposuction of the upper abdomen is, of course, not comparable to wide undermining; but the aesthetic compromise of a slightly higher scar seems acceptable in view of the low complication rate.


9. References

- [1] Gonzalez R. Buttocks Reshaping, Indexa, 219:291
- [2] Illouz Y, et al. Lipoaspiration Hipocrates, 201:208
- [3] Illouz Y. Une nouvelle technique pour les lipodystrophies localisées. Rev Chir Esthet.
- [4] Fournier P. Liposculpturing: The Syringe Technique. "The Bermuda Triangle" 185:190. Arnette Blackwell.
- [5] Klein J. Tumescent Technique. Tumescent Anesthesia and Microcannular Liposuction. Mosby , Chap 1 :23.
- [6] Rouviere H, et al. Human Anatomy. 11 Ed. Elsevier, 412:413
- [7] Jacob . S Atlas of Human Anatomy Elsevier ,160:162
- [8] Latarjet et al. Human Anatomy Panamericana, 715:731
- [9] Moore K. Clinical Orientation of Anatomy. Panamericana; 731:732
- [10] Liposuction zones described by a Gottfried Lemperle in "Ästhetische Chirurgie" ecomed medizine
- [11] D. Bergfeld, et al. Technik der Infiltration. Tumeszenz-Localanästhesie: praktische Anwendung. Springer,. 50.
- [12] Blugerman G, Schavelzon D, Paul MD. A safety and feasibility study of a novel radiofrequency assisted liposuction technology. Plast Reconstr Surg. 2010;125(3):998-1006
- [13] Blugerman G. et al. Actual methodology for autologous fat graft. Actas del XXIII Brazilian Congress of Plastic Surgery
- [14] Yamaguchi Ch. Proc. Minimal Invasive Aesthetic Procedures 381:425 Santos
- [15] Gonzalez R. Buttocks Reshaping. Indexa : 95:160
- [16] Allen EV, Hines EA. Lipedema of the legs. Proc Mayo Clin 1940; 15: 184-7.

- [17] AWMF. Leitlinien der Deutschen Gesellschaft für Phlebologie (DGP): Lipödem. AWMF-Leitlinien-Register Nr. 037/012. 2009.
- [18] Schmeller W, Meier-Vollrath I. Lipödem – Aktuelles zu einem weitgehend unbekannten Krankheitsbild. *Akt Dermatol* 2007; 33: 1-10.
- [19] Herpertz U. Ödeme und Lymphdrainage. Diagnose und Therapie von Ödemkrankheiten. Schattauer, Stuttgart, New York, 2003.
- [20] Herpertz U. Krankheitsspektrum des Lipödems an einer Lymphologischen Fachklinik – Erscheinungsformen, Mischbilder und Behandlungsmöglichkeiten. *Vasomed* 1997; 5: 301-7.
- [21] Meier-Vollrath I, Schneider W, Schmeller W. Lipödem: Verbesserte Lebensqualität durch Therapiekombination. *Deutsches Ärzteblatt* 2005; 102: A-1061-67.
- [22] Schmeller W, Meier-Vollrath I. Erfolgreiche operative Therapie des Lipödems mittels Liposuktion. *Phlebologie* 2004; 33: 23-9.
- [23] Schmeller W, Meier-Vollrath I. Moderne Therapie des Lipödems: Kombination von konservativen und operativen Maßnahmen. *Lymph-Forsch* 2004; 8: 22-6.
- [24] Schmeller W, Meier-Vollrath I. Tumescent liposuction: a new and successful therapy for lipedema. *J Cutan Med Surg* 2006; 10: 7-10.
- [25] Schmeller W, Meier-Vollrath I. Das Lipödem: neue Möglichkeiten der Therapie. *Schweiz Med Forum* 2007; 7: 150-5.
- [26] Kaufmann R, Landes E, Podda M. Dermatologische Operationen. 3. Auflage, Thieme Verlag, Stuttgart, New York, 2005.
- [27] Rompel R, Petres J. Operative Dermatologie. 2. Auflage, Springer Verlag, Heidelberg, 2007.
- [28] Cornely ME. Lipödem und die Differentialdiagnosen. *Journal für Lymphologie* 2001; 1: 32-3.
- [29] Rapprich S, Loehnert M, Hagedorn M. Therapy of lipoedema syndrome by liposuction under tumescent local anaesthesia. *Ann Dermatol Venereol* 2002; 129: 1S711.
- [30] Sattler G, Bergfeld D, Sommer B. [Liposuction]. *Hautarzt* 2004; 55: 599-604.
- [31] Sattler G, Hasche E, Rapprich S et al. Neue operative Behandlungsmöglichkeiten bei benignen Fettgewebeerkrankungen. *Z Hautkr* 1997; 72: 579-82.
- [32] Sattler G, Rapprich S, Hagedorn M. Tumeszenz-Lokalanästhesie – Untersuchung zur Pharmakokinetik von Prilocain. *Z Hautkr* 1997; 7: 522-5.
- [33] Herpertz U. Die häufigsten Beinödeme. Differenzierung zwischen Phlebödem, Lymphödem und Lipödem. *Phlebologie* 2001; 30: 48-52.
- [34] Langendoen SI, Habbema L, Nijsten TE, Neumann HA. Lipoedema: from clinical presentation to therapy. A review of the literature. *Br J Dermatol* 2009; 161(5): 980-6.
- [35] Rapprich S, Dingler A, Podda M. Liposuction is an effective treatment for lipedema – results of a study with 25 patients. *Journal of the German Society of Dermatology. JDDG*; 2010 • 8 – 1-8
- [36] Lewis JR Jr. Correction of ptosis of the thighs: the thigh lift. *Plast Reconstr Surg* 1966; 37(6):494-8.
- [37] Candiani P, Campiglio GL, Signorini M. Fascio-fascial suspension technique in medial thigh lifts. *Aesthetic Plast Surg* 1995; 19(2): 137-40.
- [38] Ersek RA, Salisbury AV. The saddle lift for thigh . *Aesthetic Plast Surg* 1995; 19(4):341-3.
- [39] Spirito D. Medial thigh lift and DE.C.LI.VE. *Aesthetic Plast Surg* 1998; 22(4):298-300.

- [40] Hurwitz DJ. Single-staged total body lift after massive weight loss. *Ann Plast Surg* 2004;52(5): 435-41.
- [41] Pitanguy I. Surgical reduction of the abdomen, thighs and buttocks. *Surg Clin North Am* 1971; 51(2):479-89.
- [42] Mathes DW. Current Concepts in Medial Thighplasty. *Clin. Plastic. Surg* '35 (2008) 151-163
- [43] Vilain R, Dardour JC. Aesthetic surgery of the medial thigh. *Ann Plast Surg* 1986; 17(3):176-83.
- [44] Le Louarn C, Pascal JF. The concentric medial thigh lift. *Aesthetic Plast Surg* 2004; 28(1):20-3 [Epub 2004 Mar 25].
- [45] Lockwood TE. Fascial anchoring technique in medial thigh lifts. *Plast Reconstr Surg* 1988; 82(2):299-304.
- [46] Lockwood T. Lower body lift with superficial fascial system suspension. *Plast Reconstr Surg* 1993; 92(6):1112-22 [discussion: 1123-5]
- [47] Planas J. The "Crural Meloplasty" for lifting of the thighs. *Clin Plast Surg* 1975; 2:495-503.
- [48] American Society of Plastic Surgeons, National Plastic Surgery Statistics 2010, ASPS 2011.
- [49] Grazer FM, Goldwyn RM. Abdominoplasty assessed by survey, with emphasis on complications. *Plast Reconstr Surg.* 1977;59(4): 513-517.
- [50] Teimourian B, Rogers WB III. A national survey of complications associated with suction lipectomy: a comparative study. *Plast Reconstr Surg.* 1989;84(4):628-631.
- [51] Matarasso A, Swift RW, Rankin M. Abdominoplasty and Abdominal Contour Surgery: A National Plastic Surgery Survey. *Plast Reconstr Surg.* 2006;117(6):1797-1808.
- [52] Manassa EH, Hertl CH, Olbrisch RR. Wound healing problems in smokers and nonsmokers after 132 abdominoplasties. *Plast Reconstr Surg.* 2003;111(6): 2082-2089.
- [53] Hensel JM, Lehman JA Jr, Tantri MP, Parker MG, Wagner DS, Topham NS. An outcomes analysis and satisfaction survey of 199 consecutive abdominoplasties. *Ann Plast Surg.* 2001;46(4):357-363.
- [54] Chaouat M, Levan P, Lalanne B, Buisson T, Nicolau P, Mimoun M. Abdominal dermolipectomies: early postoperative complications and long-term unfavorable results. *Plast Reconstr Surg.* 2000;106(7): 1614-1618.
- [55] Matarasso A. Abdominoplasty: a system of classification and treatment for combined abdominoplasty and suction-assisted lipectomy. *Aesthetic Plast Surg.* 1991;15(2):111-121.
- [56] Avelar J., Illouz Y., Lipoaspiração, Hipócrates 1986
- [57] Shestak KC. Marriage abdominoplasty expands the mini-abdominoplasty concept. *Plast Reconstr Surg.* 1999;103(3):1020-1035.
- [58] Cardenas-Camarena L, Gonzalez LE. Large-volume liposuction and extensive abdominoplasty: a feasible alternative for improving body shape. *Plast Reconstr Surg.* 1998;102(5):1698-1707.
- [59] Dillerud E. Abdominoplasty combined with suction lipoplasty: a study of complications, revisions, and risk factors in 487 cases. *Ann Plast Surg.* 1990;25(5):333-343.

- [60] Kryger ZB, Fine NA, Mustoe TA. The outcome of abdominoplasty performed under conscious sedation: six-year experience in 153 consecutive cases. *Plast Reconstr Surg.* 2004;113(6):1807-1817.
- [61] Namias A, Kaplan B. *Dermatol Surg.* Tumescant anesthesia for dermatologic surgery. Cosmetic and Noncosmetic Procedures. 1998;24(7):755-758.
- [62] Byrd HS, Barton FE, Orenstein HH, Rohrich RJ, Burns AJ, Hobar PC, Haydon MS. Safety and efficacy in an accredited outpatient plastic surgery facility: a review of 5316 consecutive cases. *Plast Reconstr Surg.* 2003;112(2): 636-646.
- [63] Cochran TA. Abdominal lipectomy as an office procedure. *J Med Assoc Ga.* 1991;80(11):631-633.
- [64] Abramson DL. Tumescant abdominoplasty: an ambulatory office procedure. *Aesthetic Plast Surg.* 1998;22(6):404-407.
- [65] Avelar JM. A new technique for abdominoplasty-closed vascular system of subdermal flap folded over itself combined with liposuction. *Revista Brasileira de Cirurgia* 1999;88/89:3-20.
- [66] Avelar JM. Abdominoplasty without panniculus undermining and resection: analysis and 3-year follow-up of 97 consecutive cases. *Aesthet Surg J.* 2002 Jan;22(1):16-25.
- [67] Blugerman G. Modified abdominoplasty, a new South American technique. Vortrag auf dem Kongress der Deutschen Gesellschaft für Ästhetische Chirurgie, Heidelberg 2002. 19a.
- [68] Matarasso A. Abdominal dermolipectomies: early postoperative complications and long-term unfavourable results (Discussion). *Plast Reconstr Surg.* 2000;106(7):1619-1623.
- [69] Rosenberg MH, Palaia DA, Bonanno PC. Abdominoplasty with procedural sedation and analgesia. *Ann Plast Surg.* 2001;46(5):485-487.
- [70] Mayr M, Holm C, Hoffer E, Becker A, Pfeiffer U, Muhlbauer W. Effects of aesthetic abdominoplasty on abdominal wall perfusion: a quantitative evaluation. *Plast Reconstr Surg.* 2004;114(6):1586-1594.
- [71] Graf R, de Araujo LR, Rippel R, Neto LG, Pace DT, Cruz GA. Lipoabdominoplasty: liposuction with reduced undermining and traditional abdominal skin flap resection. *Aesthetic Plast Surg.* 2006 Jan-Feb;30(1):1-8.
- [72] Kolker AR. Improving esthetics and safety in abdominoplasty with broad lateral subcostal perforator preservation and contouring with liposuction. *Ann Plast Surg.* 2008 May;60(5):491-7.
- [73] Heller JB, Teng E, Knoll BI, Persing J. Outcome analysis of combined lipoabdominoplasty versus conventional abdominoplasty. *Plast Reconstr Surg.* 2008 May;121(5):1821-9.
- [74] Farah AB, Nahas FX, Ferreira LM, Mendes Jde A, Juliano Y. Sensibility of the abdomen after abdominoplasty. *Plast Reconstr Surg.* 2004;114(2): 577-583.



Advanced Techniques in Liposuction and Fat Transfer

Edited by Prof. Nikolay Serdev

ISBN 978-953-307-668-3

Hard cover, 230 pages

Publisher InTech

Published online 12, September, 2011

Published in print edition September, 2011

Liposuction is the first cosmetic procedure to change beautification surgery from open extensive excision surgery into a more atraumatic closed one. It gave rise to the modern understanding of minimally scarring and minimally invasive surgery and changed the understanding and preferences of both patients and doctors. It also became the most common procedure in cosmetic surgery world-wide, practiced by an increased number of physicians from various specialties. The techniques of fat grafting, closely bound with liposuction, have found widespread application and fat stem cells seem to be changing the future of many areas in medicine. Turning the pages, the reader will find a lot of information about advances, tips and tricks, as well as important milestones in the development of the different methods available, such as classic, power, ultrasound, laser and radio-frequency assisted liposuction etc. Most useful anesthesia techniques are described and discussed, and guidelines have been established for medical indications. Special attention is paid to good patient selection, complications and risks.

How to reference

In order to correctly reference this scholarly work, feel free to copy and paste the following:

Diego Schavelzon, Louis Habbema, Stefan Rapprich, Peter Lisborg , Guillermo Blugerman, Jorge A. D'Angelo, Andrea Markowsky, Javier Soto, Rodrigo Moreno and Maria Siguen (2011). Application of the Liposuction Techniques and Principles in Specific Body Areas and Pathologies, Advanced Techniques in Liposuction and Fat Transfer, Prof. Nikolay Serdev (Ed.), ISBN: 978-953-307-668-3, InTech, Available from: <http://www.intechopen.com/books/advanced-techniques-in-liposuction-and-fat-transfer/application-of-the-liposuction-techniques-and-principles-in-specific-body-areas-and-pathologies>

INTECH
open science | open minds

InTech Europe

University Campus STeP Ri
Slavka Krautzeka 83/A
51000 Rijeka, Croatia
Phone: +385 (51) 770 447
Fax: +385 (51) 686 166
www.intechopen.com

InTech China

Unit 405, Office Block, Hotel Equatorial Shanghai
No.65, Yan An Road (West), Shanghai, 200040, China
中国上海市延安西路65号上海国际贵都大饭店办公楼405单元
Phone: +86-21-62489820
Fax: +86-21-62489821

© 2011 The Author(s). Licensee IntechOpen. This chapter is distributed under the terms of the [Creative Commons Attribution-NonCommercial-ShareAlike-3.0 License](https://creativecommons.org/licenses/by-nc-sa/3.0/), which permits use, distribution and reproduction for non-commercial purposes, provided the original is properly cited and derivative works building on this content are distributed under the same license.

IntechOpen

IntechOpen