

We are IntechOpen, the world's leading publisher of Open Access books Built by scientists, for scientists

6,900

Open access books available

185,000

International authors and editors

200M

Downloads

Our authors are among the

154

Countries delivered to

TOP 1%

most cited scientists

12.2%

Contributors from top 500 universities



WEB OF SCIENCE™

Selection of our books indexed in the Book Citation Index
in Web of Science™ Core Collection (BKCI)

Interested in publishing with us?
Contact book.department@intechopen.com

Numbers displayed above are based on latest data collected.
For more information visit www.intechopen.com



Surgical Treatment of Post-Burn Trophic Ulcers and Cicatrices of the Foot Calcaneal Area

Babur M. Shakirov

*Samarkand State Medical Institute,
Burn department of RSCUMA,
Inter-regional Burn Center, Samarkand
Uzbekistan*

1. Introduction

The term 'plantar' ulcer was introduced by Price in 1959 and was defined as a chronic ulceration of the anaesthetic sole of the foot, situated in well-defined areas overlying bony prominences, resistant to local or systemic therapy and characterized by a marked tendency to recurrence.

First time Grabb & Argenta (1981) offered the graft, with blood supply from the artery malleolaris anterior that makes it possible to close the affected zone with limited lesions. Some authors prefer Blair-Brown grafts (Vihriev & Belonogov, 1978).

Initially, Elshahy (1978) had used the local skin and fatty graft, prepared on the lateral or medial surface of ankle joint. According to Amarante et al. (1986), good results were achieved with plasty of defects in the area of the Achilles tendon and with skin-fascial graft on the distal base from medial surface in malleolus.

Shakirov et al., (2009) offered the L-form skin and fatty graft in the case of trophic ulcers in the post-burn wounds of this calcaneal area.

The feature of the clinical course of so - called sandal burns that occurred in the past in some in mountain areas of Middle Asia, where primitive heating devices -sandals, were used, is noteworthy (Shakirov, 2004). Sandal burns are characterized by such severe deep injuries because of a close contact plantar of the foot with ash of coals or woods and include not only skin injuries of various depths but also injuries to underlying tissues: subcutaneous fat, fascia, muscles, and even bones (Shakirov & Tursunov, 2005).

The burn trauma of the posterior surface of talus area and ankle joint with the following formation of cicatrix is often complicated by unhealing trophic ulcer.

Ulcerous cicatrices located in the Achilles tendon zone are constantly traumatised on walking with shoes on, because the area of the tendon adjoining the talus on the surface of the support. As a result, ulcers gradually increase and cicatrices become rough and deep. The wound fundus gets a grey staining and the margins become dense without granulation and with signs of epithelisation. In spite of a large number of methods used, the problem of elimination of extensive defects in a zone of the Achilles tendon is not solved to the end. The study of features of skin structure, blood supply and innervations' of the talus area showed

that soft tissues, located in the area of external talus and lateral surface, are good plastic surgery materials for tendon covering.

The donor area from where the skin and fatty graft had been taken had the following features: first, the skin in the talus area was rather thick and rough, stable to traumatisation with shoes and easily shifted with marked subcutaneous fat layer so it can be taken in a fold; second, it has a good arterial blood supply as there is an artery fubularis behind the donor site and the peripheral ramus of the same artery in front of the donor site that form the vascular network Barsley et. al.,(1983), Holmes et.al. (1984) and third, the area of external talus has axial innervations provided by the sural nerve. The sural nerve passes in the anterior area of the talus. Enumerated anatomical features of blood-supply structure and innervations make the area of lateral talus and foot rather valuable as the donor area for preparation of skin-fatty graft and re-animation of normal-covering tissues above the Achilles tendon and posterior surface of calcaneus.

2. Material and methods

A total of 12 patients (7 men and 5 women, aged 9 to 54 years) have been on under the author’s observation at Samarkand Burn Centre, Uzbekistan, for prolonged unhealing ulcers and cicatrices located in the Achilles tendon zone (Table 1). The causes of the trophic ulcers included sandal burns (10 patients), sulphuric acid burns (1 patient), and electro-trauma burns (1 patients). Would assume one since you had 12 total. Ulcers sizes were from 1,0-3,5 to 4-5 sm. in diameter. All patients had undergone operation before (2 - 4 times). The donor area, from where the skin and fatty graft had been taken from, had the following features.

Causes of burns	males		females	
	Quantity	%	Quantity	%
Sandal burns	5	41,7	5	41,7
Sulfuric acid burns	1	8,3	-	-
electro burn	1	8,3	-	-

Table 1.

2.1 The operation technique

After cicatrices dissection, a deep wound measuring 5-11 cm in length was formed. For orientation, we divided the posterior surface of the calcaneal tendon area into three parts: calcaneal, ankle and supramalleolaris areas (Figure 1).

Large wound surfaces can be closed by L-form graft. Posterior crural surface above the Achilles tendon is its base between the distal and middle-third of the leg. The graft is directed lateral and forwards, its posterior border is the margin of cicatrices and its anterior side is about 2 cm farther from the talus apex. Then the graft passes through the lateral surface of the foot at an angle of about 90 along the foot margin. The width of the graft is 5-6 cm and the length is 18-20cm. Of these, the vertical part is 13-14 cm and the horizontal part is 5- 6 sm.

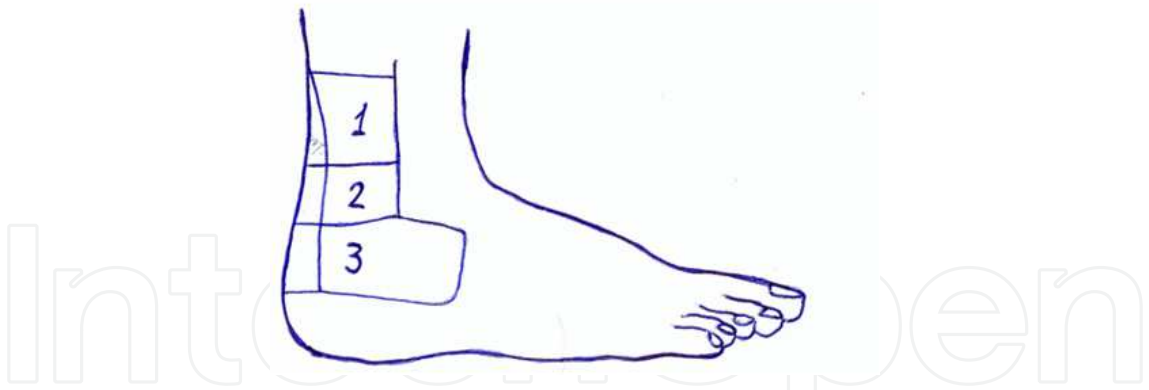


Fig. 1. Division of Achilles tendon into calcaneal, ankle, supramalleolaris areas

The correlation of parts is 3.1, 2.1 and 1.1. Based on the spread of the tissue defect, the graft is planned with a surplus length of 4-5 cm as the graft contracts after mobilisation and when it covers the calcaneal tendon and the calcaneus are fixed on the condition of some extension of width on account of length.

The graft mobilization starts from its apex, penetrating at once to the fascia and covering the muscles by means of the incision and strictly along the fascia from which the graft was raised up to superior distal third of the ankle joint. With this, the terminal branches of artery fibular is intersected and the other branches that penetrated into the graft on the foot from the side of the planta in the zone of the ankle joint, which is higher from the side of the tendon of long fibular muscle, where their number is less than on the foot, the graft was mobilized to be placed above the Achilles tendon. Graft sensitivity is provided by the calf nerve, rete venosum plantare, and arterial blood supply is collateral due to a thick network making up the base of the graft through the long post-fibular muscle, moving away from artery tibialis anterior and also along the anterior border of the pointed muscle, a little more distal to the artery tibialis branch. Depending on the area and localisation of the defects, cicatrices and ulcers, the L-form graft was placed on the wound surface either longitudinally or at an angle when its vertical part, lying across, closed the wound distal zone. The medial margin and the end of the graft were connected with the proper wound margin by one or two rows of sutures, and by means of the lateral margin of the graft, the lateral surface of the Achilles tendon was closed and was fixed by catgut sutures to the fascia through the sub dermal layer. The donor wound was closed with a split thickness skin graft and compression bandage was applied with fixed using stretched sutures.

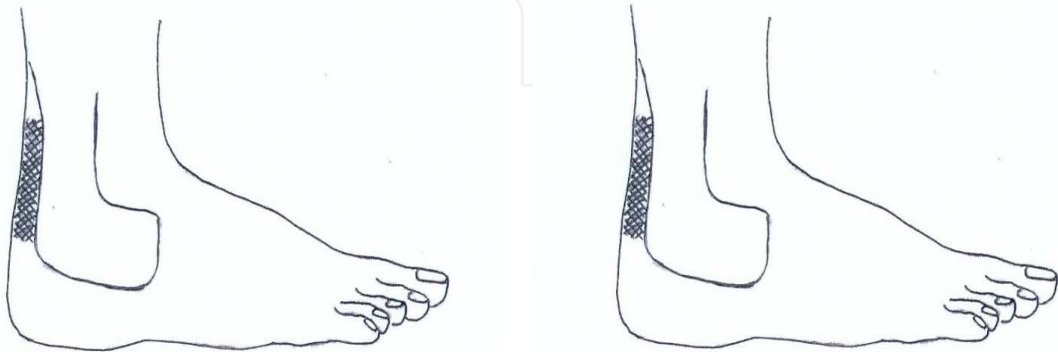


Fig. 2. Ulcerating cicatrix in the area of the Achilles tendon zone. The borders of the L-form skin fascial graft have been pointed out.

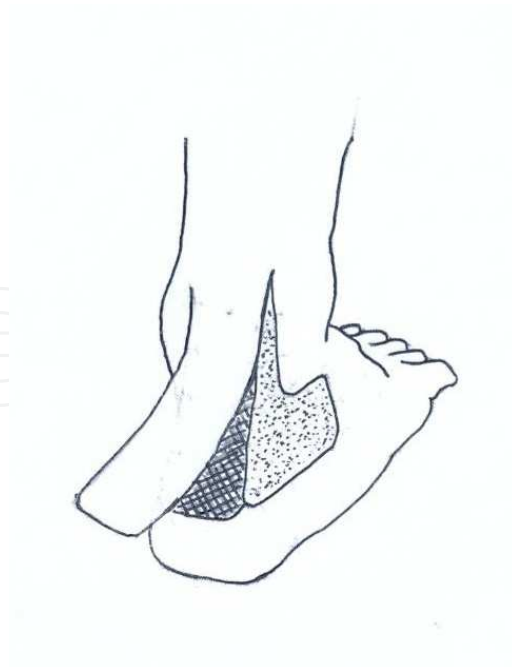

Fig. 3. L-form skin- fascial graft from the inferior third of the crus and foot has been mobilized.

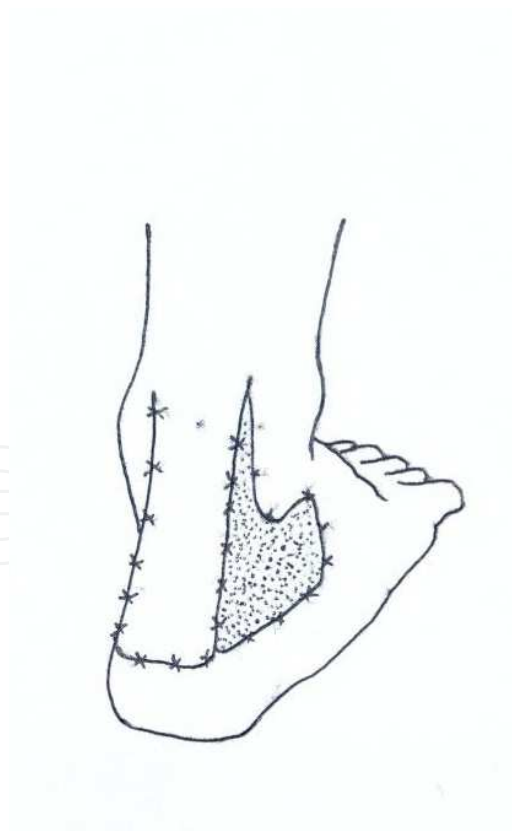


Fig. 4. After ulcerating cicatrices dissection the wound was covered by mobilized skin-fascial graft

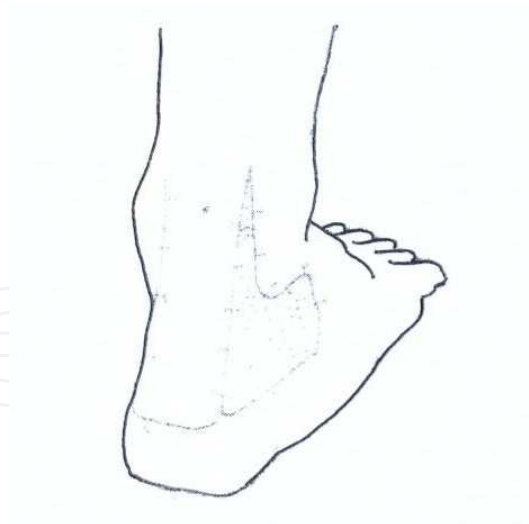

Fig. 5. The result of the Achilles tendon plastics by means of L-form skin-fascial graft.

Patient A., aged 15, was hospitalized with complaints of chronic unhealing wound in the calcaneal area of the left foot. It was determined, from the patient's self-report, that he had received a sandal burn 4 years ago during an epileptic attack. He was treated at Burn Centre. At 3 months after healing, trophic ulcer had developed. The size of the ulcer increased gradually. So the patient was operated on in the Burn Centre for unhealing trophic ulcers, where free-skin transplantation was performed. However, trophic ulcer recurred, and the patient was re-admitted to the Burn Centre. During medical examination of the calcaneal area of the left foot, a post-burn unhealing trophic ulcer (2,0- 2.5 cm in diameter) was revealed.

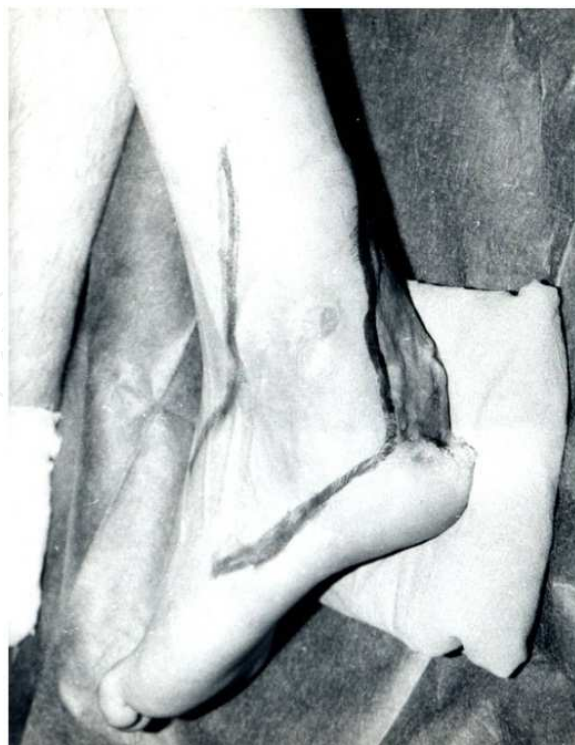

Fig. 6. Ulcerating cicatrix in the area of the Achilles tendon zone.

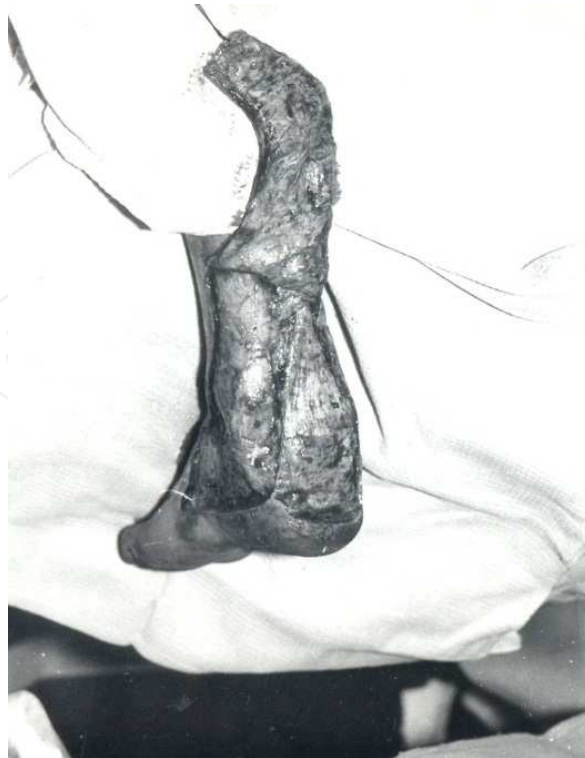

Fig. 7. L-form skin- fascial graft from the inferior third of the crus and foot has been mobilized.

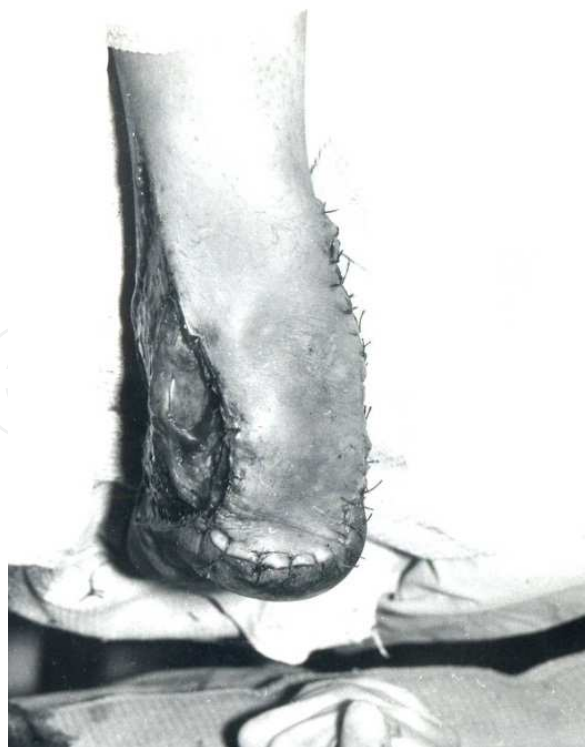

Fig. 8. After ulcerating cicatrices dissection the wound was covered by mobilized skin-fascial graft

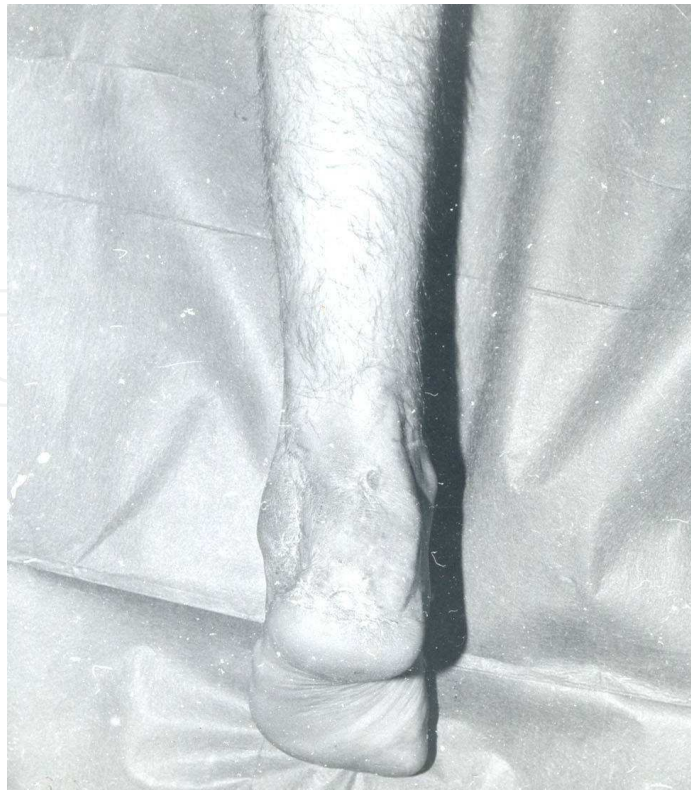

Fig. 9. Result

3. Results

We observed a good result with no complications. The grafts were viable, sensibility was preserved and no marginal necrosis was noticed. Gradually the operation efficacy improved as the cicatrices became softer, and the fossa behind the external talus (donor site) healed. A marginal necrosis was noted on the part of external talus adjoining the ulcer because of the tissue changes only one patient. The necrotized area was removed and the wound was closed by split skin without influencing the good result of the operation.

4. Conclusion

Trophic ulcer is common complication seen in (describe patient population here again) patients and all treatment modalities have significant recurrence rates. In spite of a large number of treatment methods used, the problem of elimination of defects in the area of Achilles tendon has not been solved. As a rule, it is impossible to eliminate them by means of local tissues plasty. Some authors prefer Blair-Brown graft plasty does not ensure good functional and cosmetic results, because the transplanted graft is thin, without tactile or pain sensitivity.

It often undergoes cicatrix formation with trophic ulcer recurrence. Employing plastic surgery in the area of the Achilles tendon, the use of distant-area tissues presents a good effect by means of Italian plastics (crus of the other leg or buttocks) as well as the Filatov's stem; however, these methods are concerned with the inconveniences of the forced position, have many stages and displaced, denervated tissues and have blood supply for the account of traumatic zone.

In L-form skin-fatty graft, produced grafts that were viable and preserved sensibility and saves displacement from mechanical trauma in the natural way. The patients may resume their work in 1.5 months after the operation. However, complete graft adaptation and acclimatization to the place of graft occurs in 2-3 months. During this period, patient must not wear common shoes that press onto the graft.

5. Acknowledgement

We thank K.R. Tagaev for support of this work, Lidia Arkadevna, Nela Ahmedganovna, May Anatollevna and Vladimir Tsibulsky for correcting the English of this manuscript.

6. References

- Amarante J, Costa H, Reis J, et al. New distally based fasciocutaneous flap of the leg. *Br J Plast Surg* 1986; 39:338-40.
- Barsley TL, Sharp DT, Chischolm EM. Cross-leg fasciocutaneousm flaps. *Plast Reconstruct Surg.* 1983; 72:843-52.
- Elshahy N.J. The usage of graft on 2 cuttings for the ulcers closing not bearius the load in the area of heel. *Acta Chir Plast* 1978; 20:30-6.
- Grabb W.C, Argenta LC Ibid. 1981. 68. pp. 723-730.
- Holmes J, Rauner CR. Lateral calcaneal Artery Island flaps. *Br J. Plast Surg* 1984; 37:402-5.
- Price E.W. 1964. The problem of plantar ulcer. *Lepr Rev.* 1964; 35:267-72.
- Shakirov B.M. Sandal Burns and their Treatment in Children // *J. Burn Care Rehabilitation.* 2004; 25; 501-505.
- Shakirov B.M., K.R Tagaev, B.S. Tursunov, D.A. Achtamov. L- form plastic in the treatment of post-burn trophic ulcers and cicatrices of the foot calcaneal area. *J. Plastic, Reconstructive Aesthetic Surgery* (2009) 62, e 59-63.
- Shakirov B.M., Tursunov B.S. Treatment of severe foot burns in children // *J. Burns*, 2005; Vol.31, №7: 901-905.
- Vihriev B.C, Belonogov LI. Plastic's skin-grafts wound of defects. *Herald of surgery*; 1984: 89-91.



Skin Grafts - Indications, Applications and Current Research

Edited by Dr. Marcia Spear

ISBN 978-953-307-509-9

Hard cover, 368 pages

Publisher InTech

Published online 29, August, 2011

Published in print edition August, 2011

The procedure of skin grafting has been performed since 3000BC and with the aid of modern technology has evolved through the years. While the development of new techniques and devices has significantly improved the functional as well as the aesthetic results from skin grafting, the fundamentals of skin grafting have remained the same, a healthy vascular granulating wound bed free of infection. Adherence to the recipient bed is the most important factor in skin graft survival and research continues introducing new techniques that promote this process. Biological and synthetic skin substitutes have also provided better treatment options as well as HLA tissue typing and the use of growth factors. Even today, skin grafts remain the most common and least invasive procedure for the closure of soft tissue defects but the quest for perfection continues.

How to reference

In order to correctly reference this scholarly work, feel free to copy and paste the following:

Babur M. Shakirov (2011). Surgical Treatment of Post-Burn Trophic Ulcers and Cicatrices of the Foot Calcaneal Area, Skin Grafts - Indications, Applications and Current Research, Dr. Marcia Spear (Ed.), ISBN: 978-953-307-509-9, InTech, Available from: <http://www.intechopen.com/books/skin-grafts-indications-applications-and-current-research/surgical-treatment-of-post-burn-trophic-ulcers-and-cicatrices-of-the-foot-calcaneal-area>

INTECH
open science | open minds

InTech Europe

University Campus STeP Ri
Slavka Krautzeka 83/A
51000 Rijeka, Croatia
Phone: +385 (51) 770 447
Fax: +385 (51) 686 166
www.intechopen.com

InTech China

Unit 405, Office Block, Hotel Equatorial Shanghai
No.65, Yan An Road (West), Shanghai, 200040, China
中国上海市延安西路65号上海国际贵都大饭店办公楼405单元
Phone: +86-21-62489820
Fax: +86-21-62489821

© 2011 The Author(s). Licensee IntechOpen. This chapter is distributed under the terms of the [Creative Commons Attribution-NonCommercial-ShareAlike-3.0 License](https://creativecommons.org/licenses/by-nc-sa/3.0/), which permits use, distribution and reproduction for non-commercial purposes, provided the original is properly cited and derivative works building on this content are distributed under the same license.

IntechOpen

IntechOpen