

We are IntechOpen, the world's leading publisher of Open Access books Built by scientists, for scientists

6,900

Open access books available

186,000

International authors and editors

200M

Downloads

Our authors are among the

154

Countries delivered to

TOP 1%

most cited scientists

12.2%

Contributors from top 500 universities



WEB OF SCIENCE™

Selection of our books indexed in the Book Citation Index
in Web of Science™ Core Collection (BKCI)

Interested in publishing with us?
Contact book.department@intechopen.com

Numbers displayed above are based on latest data collected.
For more information visit www.intechopen.com



Lower Third Nasal Skin Grafting

James F. Thornton and Emily D. Rapstine
*The University of Texas Southwestern
 Medical Center at Dallas
 United States of America*

1. Introduction

Lower third nasal defects present a special challenge to reconstructive surgeons.. The unique character of the lower third of the nose, with its interwoven concavities, convexities, and varying skin thicknesses, exacerbates the difficult reconstruction of this region.

Specific flap algorithms are available for reconstruction of full-subunit alar or full-subunit tip defects (Hill, 1987). The lower third nasal defects or defects larger than 1.5 cm in diameter can be reliably reconstructed and repaired with nasolabial or forehead flaps using either a subunit or defect-only reconstruction (Barton, 1981). These techniques require multiple stages and allow for the replacement of cartilage and lining if missing.

Paradoxically, acceptable results are more difficult to achieve with smaller defects, most notably those smaller than 1 cm. Local flaps applied for these defects often result in violation of aesthetic subunits, worsening of the defect by alar notching, and frequent or unpredictable pincushioning. Likewise, the misapplication of skin grafts to large or deep lower third defects often yields a depressed patchwork with unsuitable results.

In many cases of lower third nasal reconstruction, particularly those arising from excision of neoplasms by means of Mohs' micrographic surgery, the defects are shallow and measure less than 1 cm in diameter. These defects rarely encompass greater than 50 percent of aesthetic subunits and are best treated as defect-only reconstructions (Dimitropolous et al., 2005). Such defects can be successfully and reliably treated with well-applied full-thickness skin grafting from the preauricular or more preferential forehead donor site.

The evolution of the demonstrated skin grafting techniques started with the recognition of the frustrating paradox in reconstructing small defects of the lower third. Larger defects could be easily and reliably reconstructed with the well-established algorithms (i.e., nasolabial or forehead flap reconstruction). The use of bilobed flaps from the upper third of the nose to recreate defects on the lower third commonly disappoints for two reasons. The inherent design flaw of the bilobed flap violates a second or third aesthetic unit and often completely distorts the alar groove. In addition, the final result is inherently unpredictable because of its tendency to pincushion. There is a common reluctance to advance skin from the nasal sidewall to reconstruct lower third defects, as this destroys the alar groove, an aesthetic subunit that is very difficult to reconstruct.

2. Anatomical considerations

The boundaries defining the lower third of the nose include the alar rims inferiorly, the nasolabial grooves laterally, and the alar groove, which forms the junction with the upper

two-thirds of the nose (Collins & Farber, 1984; Leibovitch et al., 2006). Any distortion of the alar rim or obliteration of the nasolabial groove is exceedingly noticeable to the naked eye and difficult, if not impossible, to correct secondarily. The lower third of the nose is classically composed of six subunits: bilateral ala and soft triangles, the central tip, and columella (Baker & Swanson, 1995) (Fig. 1). Importantly, the ala and tip are biconvex structures, and maintaining and restoring the contour of these structures is essential to aesthetic nasal reconstruction. The unique nature of the lower third skin, which is often thick and richly populated with sebaceous glands, complicates reconstructions, often rendering the skin stiff and difficult to rotate and form into local flaps.

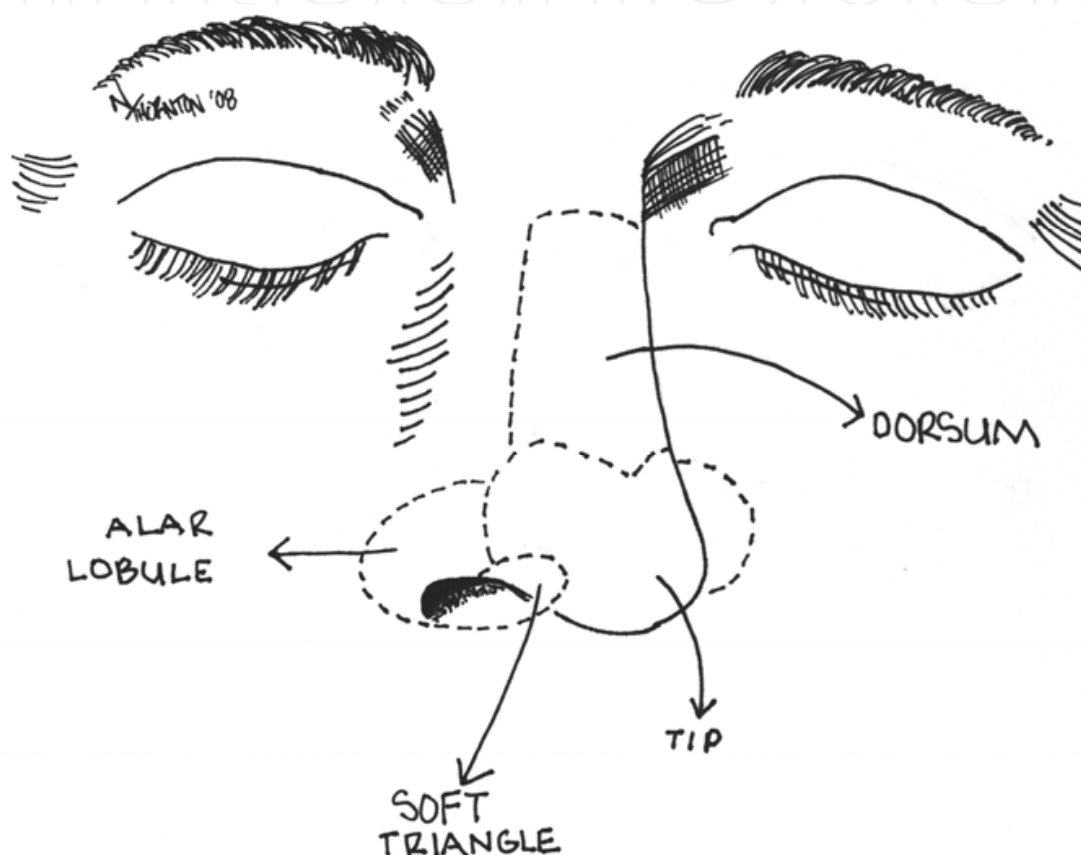


Fig. 1. Illustration of the nasal subunits of the lower third, including the dorsum, tip, and paired soft triangles and alar lobules. The columella is not shown.

3. Results

Average defect size among patients eligible for this type of grafting procedure ranges from 5 to 17 mm. Patients typically undergo one dermabrasion treatment after their procedure, with two or more dermabrasion treatments being prescribed or preferred less frequently. The aesthetic standard of a normal appearance with endpoints of good contour and color match, rather than simply a healed wound, should be used (Figs. 2 through 7). Based on postoperative photographs, some patients may present with minor contour or color defects, although a few may have more pronounced color/contour changes (Figs. 8 and 9). Active smokers are several times more likely to experience graft failure (Fig. 10).

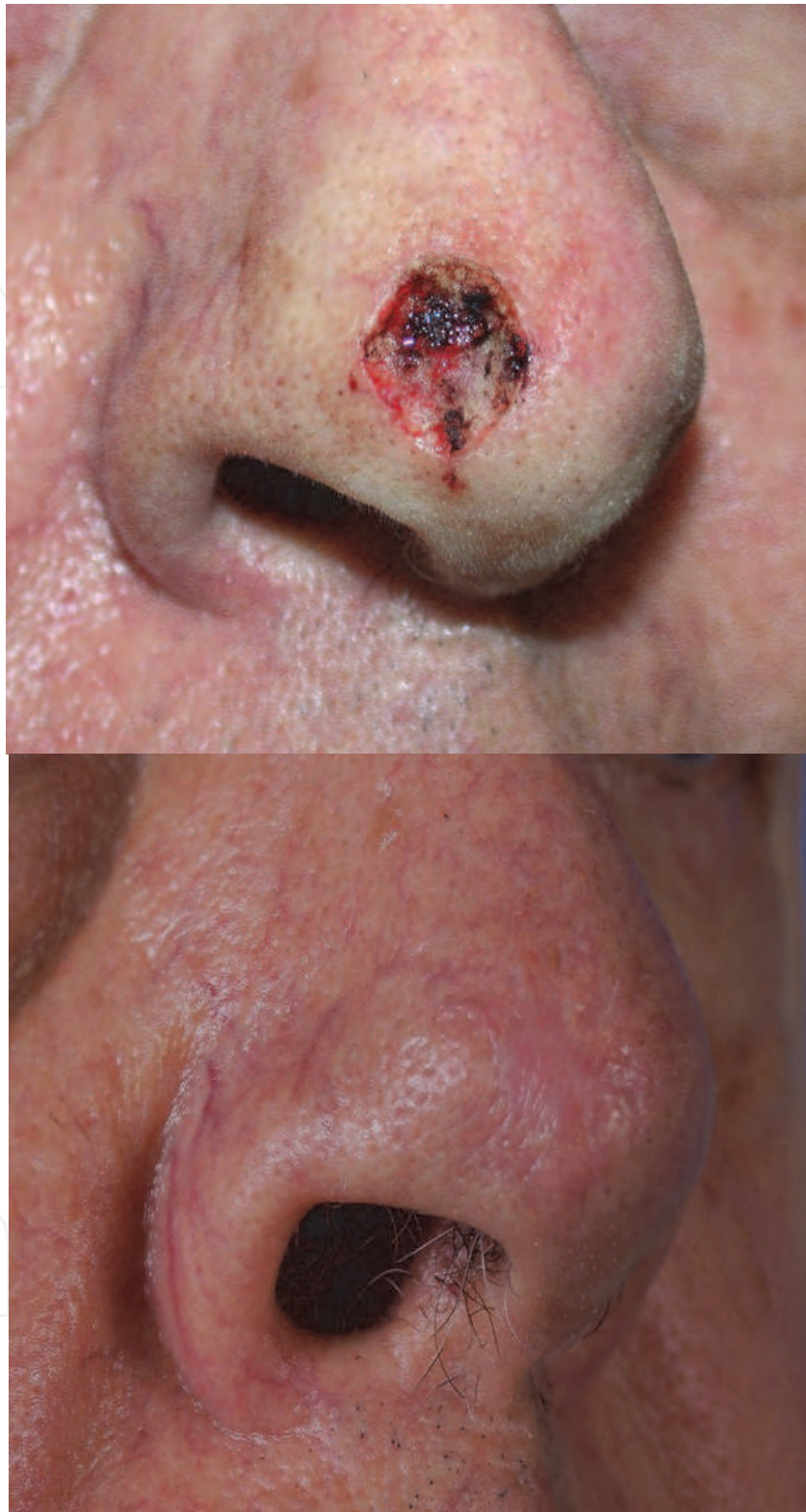

Fig. 2. A 64-year-old man presented with an 8-mm nasal defect following Mohs' excision of a basal cell carcinoma (*top*). There was exposed perichondrium in the base of the wound, although it was a relatively thin defect. Two rounds of dermabrasion were performed after the graft, which was taken from a forehead donor site, was placed. The appearance at a 3-month follow up is shown below.

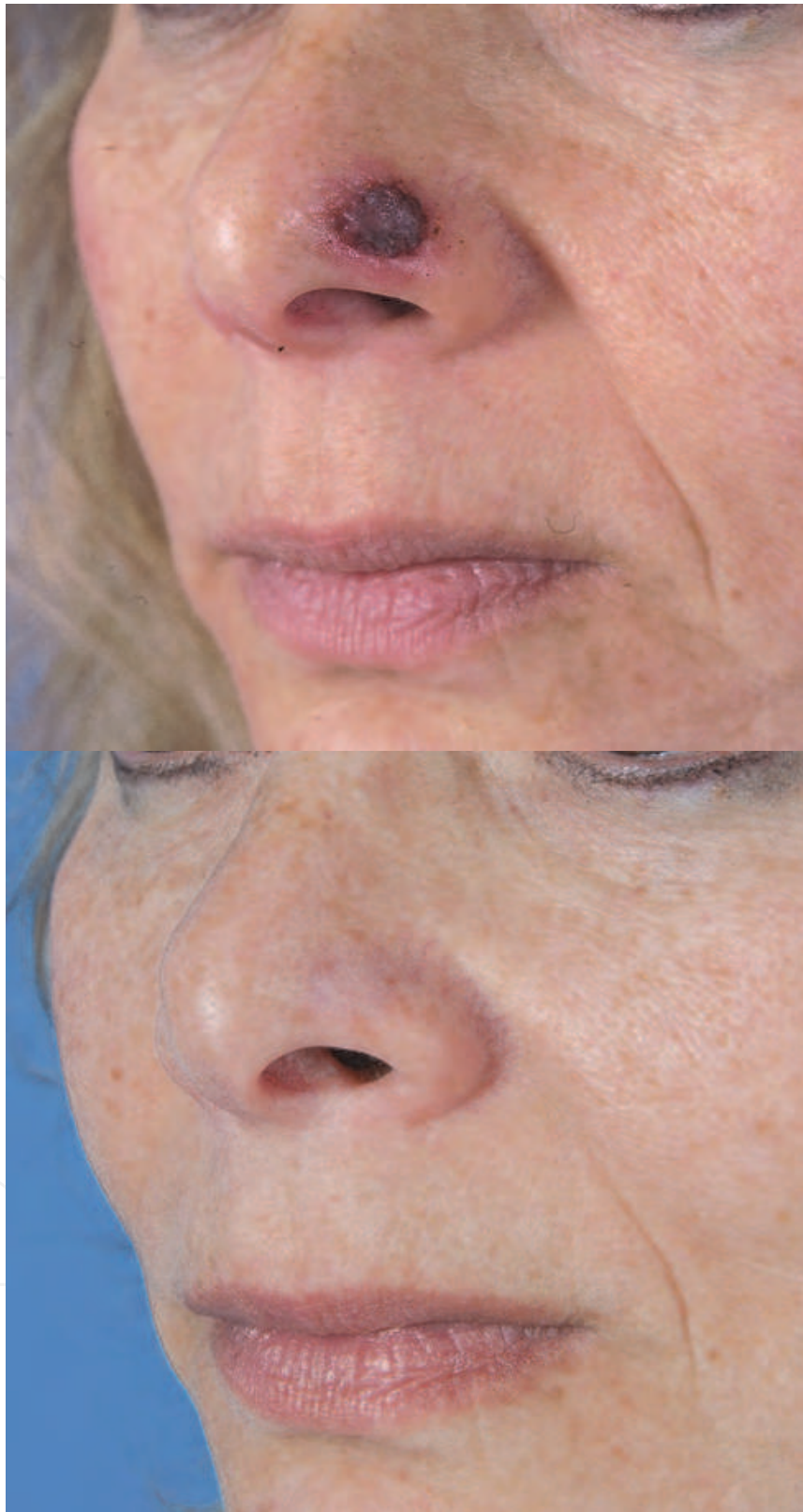

Fig. 3. A 43-year-old woman presented with a 7-mm alar defect, abutting but not crossing the alar rim. The appearance of the patient 1 week after skin grafting from a forehead donor site is shown on top. The graft appears dusky despite good take. The patient 3 months postoperatively and after two dermabrasion treatments is shown below.

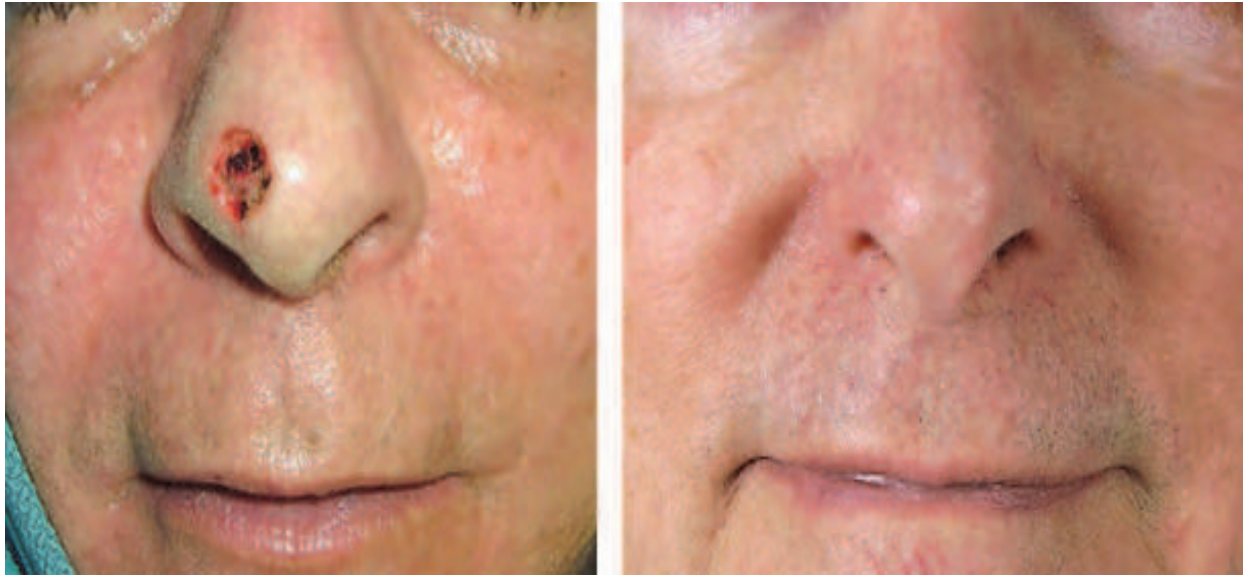

Fig. 4. A 57-year-old man with thin nasal skin underwent Mohs' excision of a basal cell carcinoma on his nasal tip (*left*). The patient's 3-month follow-up photo after full-thickness skin grafting from forehead skin and one in-office dermabrasion treatment is pictured on the right.

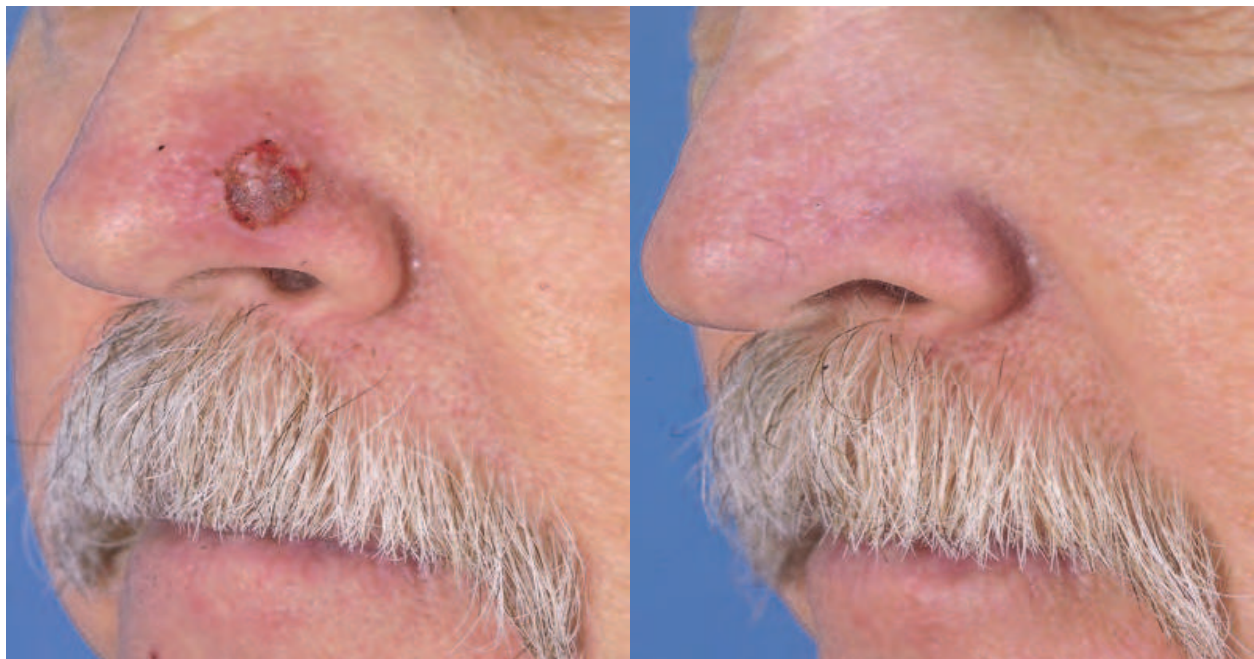

Fig. 5. A 54-year-old man had a 7-mm alar defect after excision of a basal cell carcinoma (*left*). The patient at the 3-month follow-up visit following preauricular skin grafting and one dermabrasion treatment is pictured on the right.

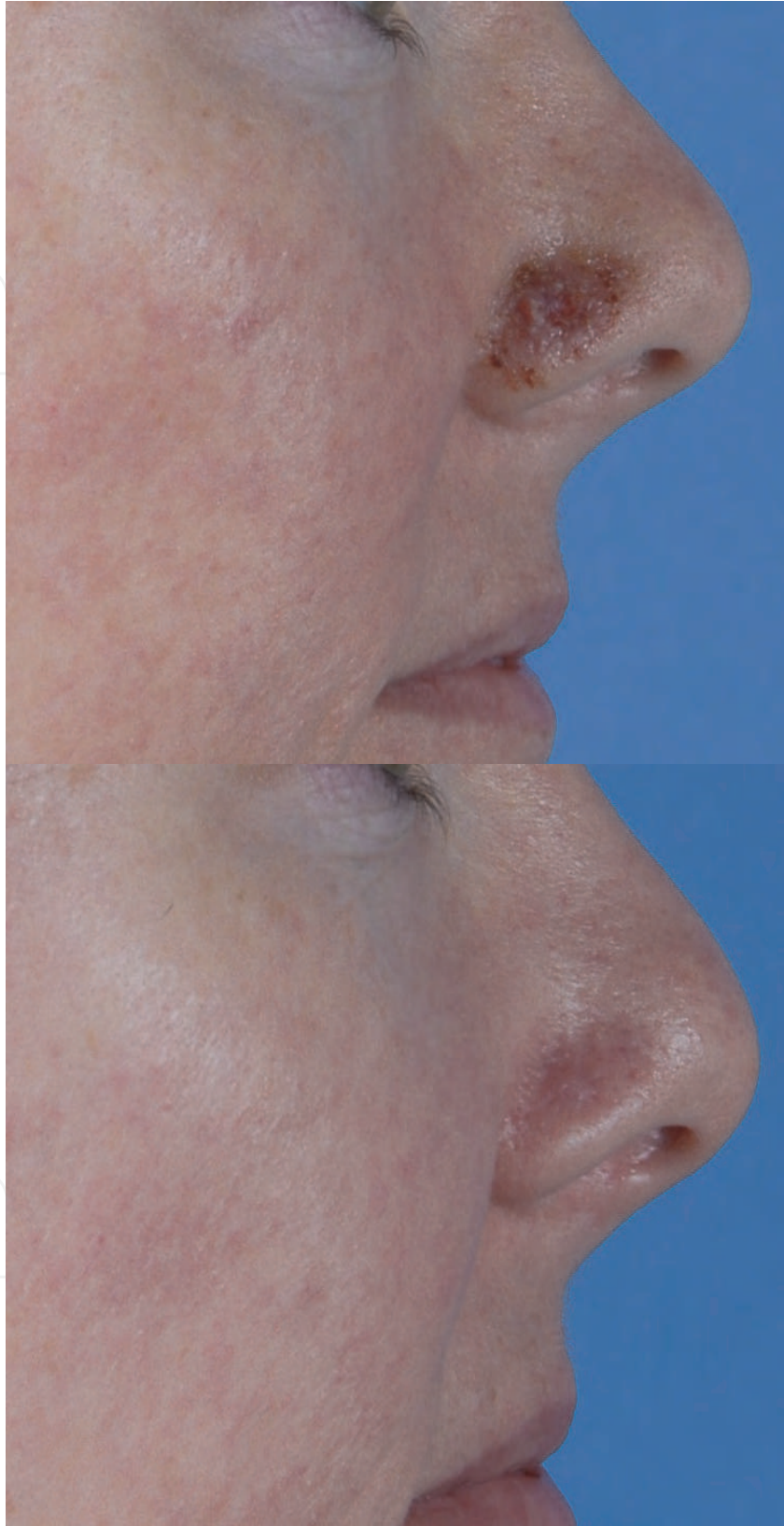

Fig. 6. A 1-cm superficial alar defect was reconstructed with a full-thickness skin graft from a forehead donor site in this 37-year-old woman (*top*). After two dermabrasion treatments, her contour and pigmentation at 3 months show a good result (*bottom*).

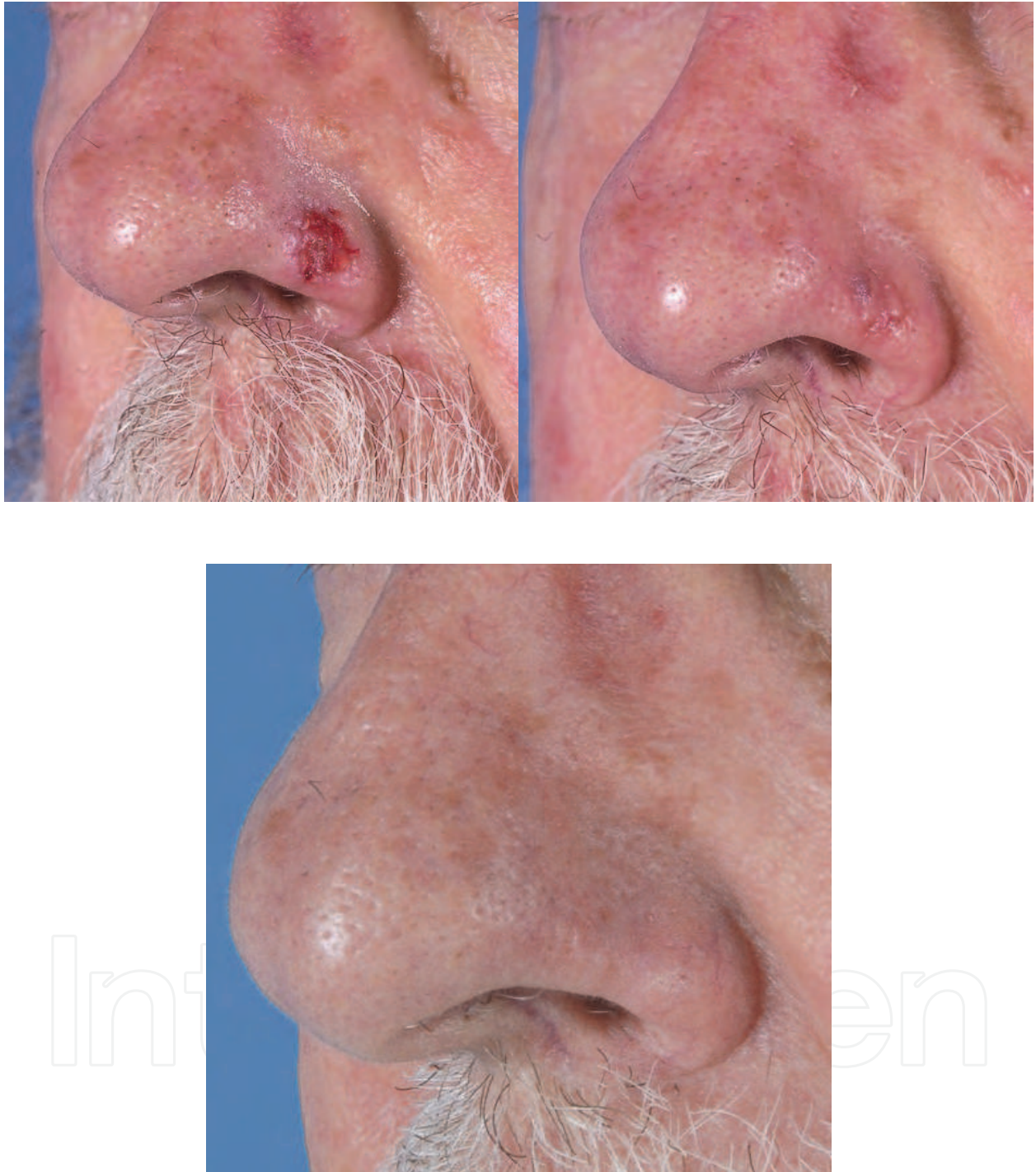


Fig. 7. The 5-mm alar rim defect was reconstructed with a full-thickness skin graft using preauricular skin (*upper left*). The degree of healing at 1-month postoperatively is pictured in the upper right. After two dermabrasion treatments, no contour or color irregularities are visible (*lower center*).

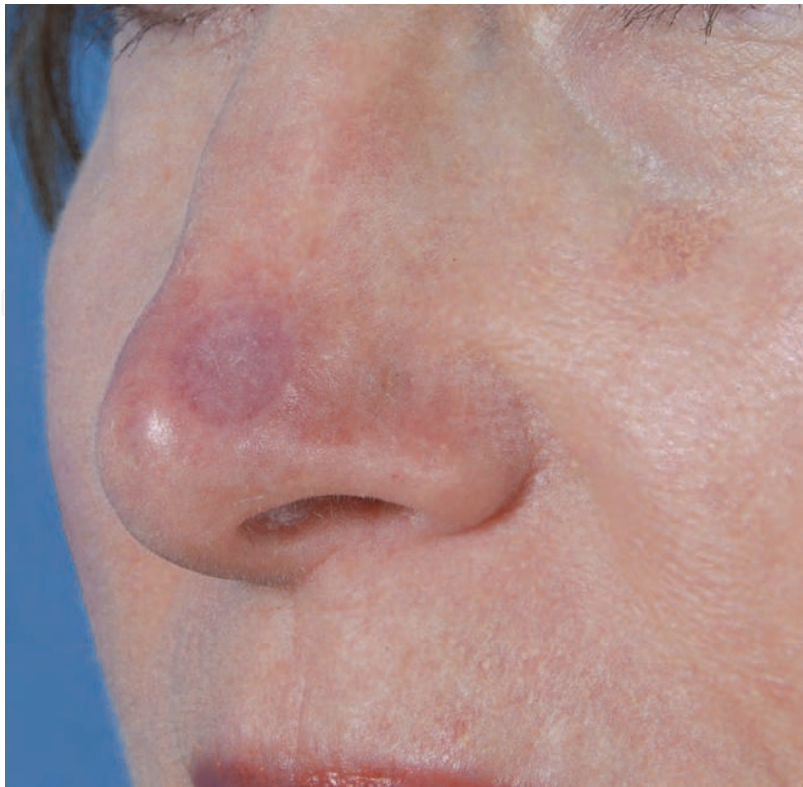

Fig. 8. A patient with a hypopigmented scar after full-thickness skin grafting from preauricular skin to the nasal tip with postoperative dermabrasion.

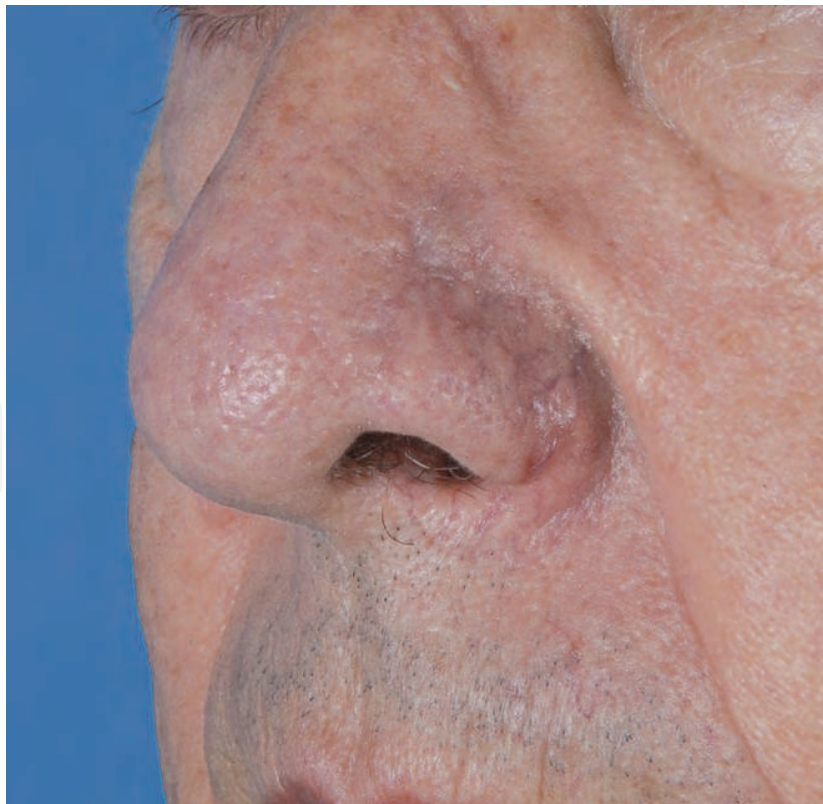

Fig. 9. This patient received a full-thickness skin graft from a preauricular donor site to his ala with postoperative dermabrasion. He has a persistent contour defect at this site.

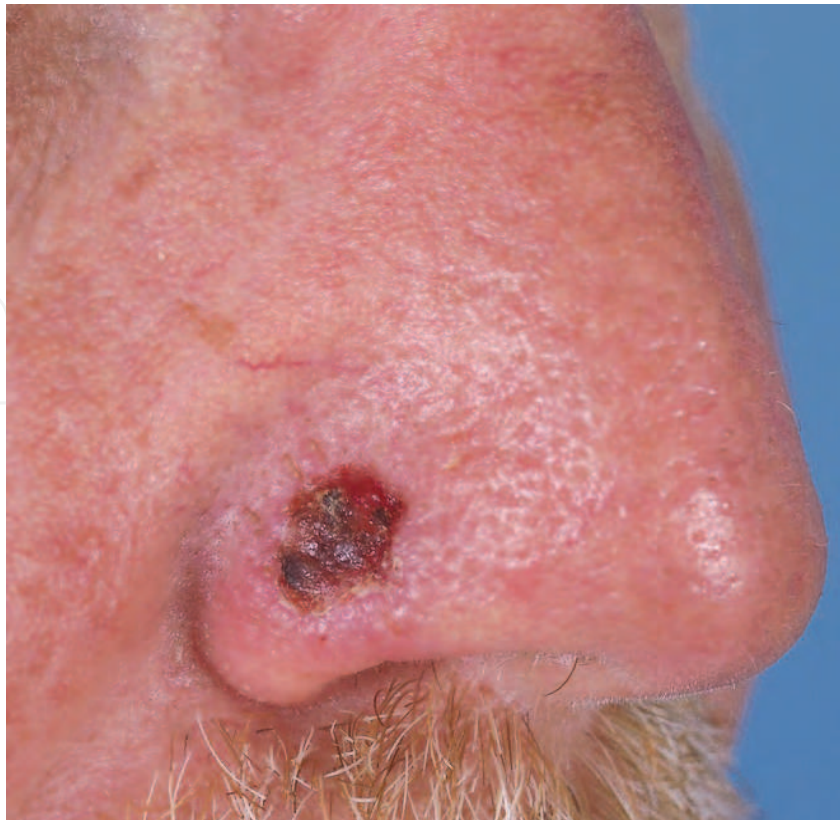

Fig. 10. An example of a failed alar graft from forehead skin in a smoker. This was successfully regrafted after the wound was débrided.

4. Technique

Procedures are performed under local anesthesia with or without intravenous sedation in an operating room setting. A 1:1 mixture of 0.25% Marcaine (Hospira, Inc., Lake Forest, Ill.) with 1% lidocaine with epinephrine (mixed 1:1000 in 30 cc of lidocaine) is used for local anesthesia, vasoconstriction, and postoperative analgesia. This mixture is injected subdermally at the site of the defect and the graft donor site. Each defect repair begins with reverticalization of the wound edges and sharp débridement of any fibrinous tissue or debris in the base of the defect. This initial step is critical for normalizing any contour abnormalities in the defect and is performed under loupe magnification with a straight, double-edged beaver blade. Further excisions are performed if required to place the borders within aesthetic subunits; however, there is not a strict adherence to aesthetic subunit reconstruction since this procedure is considered to be a defect-only reconstruction.

After reverticalization of the wound edges and normalization of the contour, a foil pattern template is used. This template should be treated as a three-dimensional construct, accounting for the relative concavity or convexity of the tissue surrounding the defect. A full-thickness skin graft from the preauricular or the preferred forehead donor site is harvested based on the foil template. The donor sites should be closed in a multilayer fashion with buried interrupted and continuous suture. The donor sites are frequently placed at the junction of the hair-bearing and non-hair-bearing scalp following the relaxed skin tension lines. Great care must be taken to ensure that the grafts harvested are matched to the identical size of the donor site. This is accomplished by using the foil pattern template

and sharply scoring the harvested graft within the ellipse of the donor site to accurately reflect the size before harvesting the graft. This eliminates the distortion caused by blurry ink lines while harvesting the graft. Therefore, scoring the template before harvest represents a critical step in accurately designing the graft to be the exact size of the defect. The graft should be handled atraumatically and with great care throughout its harvest and inset.

Due to unsatisfactory inflammatory response from 4-0 or 5-0 chromic gut suture, the preferred suture material is 5-0 fast-absorbing gut. The grafts are precisely sewn into place with continuous opposing 4-0 or 5-0 plain gut sutures that run in a continuous fashion in opposite directions around the graft and are tied at the opposite side. This precisely insets the graft, providing a stable inset with no bunching or distortion, and is very time saving (Fig. 11).

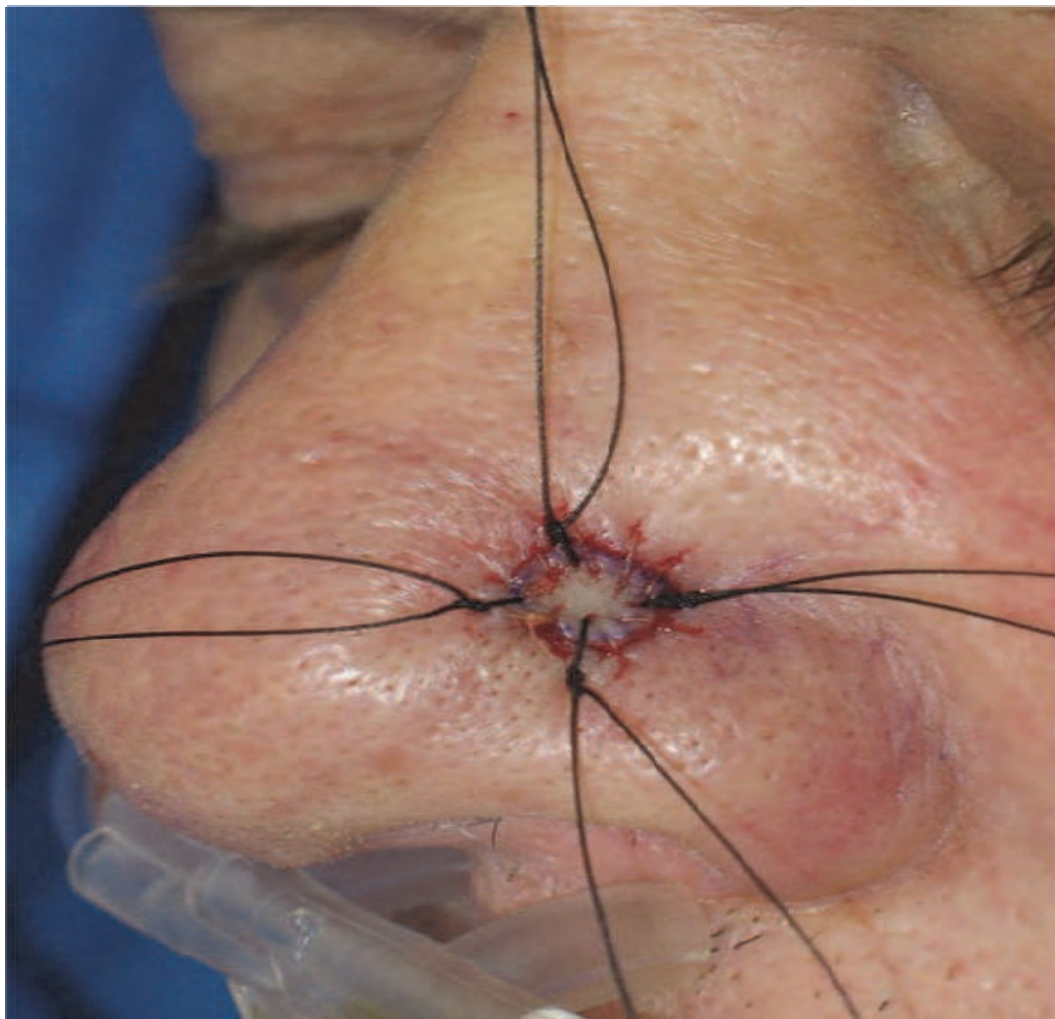

Fig. 11. An example of the fast-absorbing running suture at the graft margin, and four-corner bolster sutures.

Fabrication of the skin graft bolster completes the procedure. In the majority of cases, a double-armed 3-0 or 4-0 Prolene suture (Ethicon, Inc., Somerville, N.J.) is placed at the center through the underlying tissue and then through the center of the graft. Both arms of

the suture are placed in a similar fashion and then left untied and sewn directly into the bolster (Fig. 12). Bolsters are fashioned from dry surgical preparation sponges that have been gas sterilized preoperatively and coated with antibiotic ointment away from the operative field. The surgical preparation sponge material provides adequate rebound and support. The through-and-through 3-0 Prolene sutures are placed in juxtaposition through the bolster and tied in place (Fig. 13). This technique obliterates central dead space and optimizes graft adherence. The remainder of the bolster is then secured with 5-0 silk bolster sutures placed through the graft and native skin edge, then tied at four to eight points around the graft, depending on graft size. The closed donor-site incision and the edges and exterior of the bolster should also be coated with antibiotic ointment. Donor sites are dressed with Xeroform gauze (Sherwood Medical, St. Louis, Mo.), and a set of written wound care instructions is given to the patient. The patient may begin showering on the second postoperative day with the provision that they cover the graft bolsters with a vigorous coating of antibiotic ointment before showering.

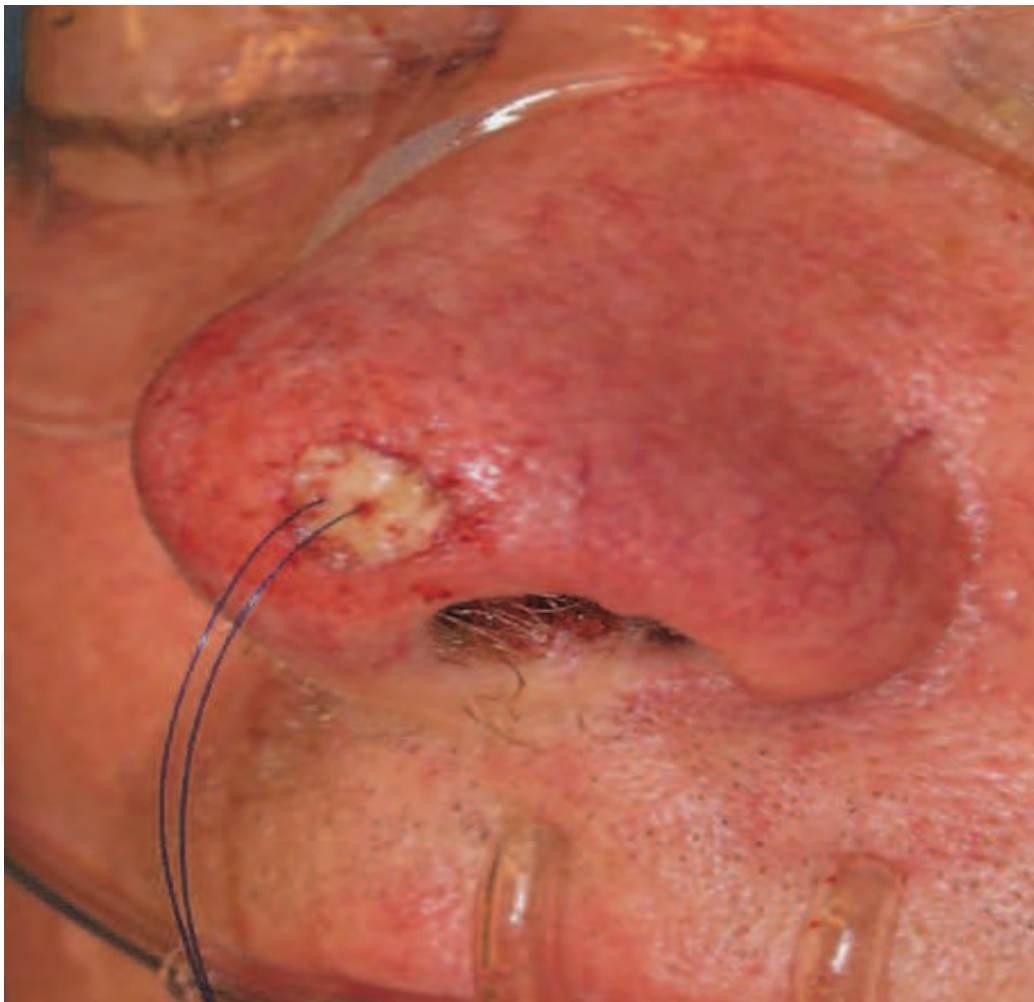


Fig. 12. The through-and-through monofilament suture used to provide additional stability and compression to the skin graft bolster. Both needles on the double-ended suture are then passed through the center of the piece of surgical sponge and tied down.

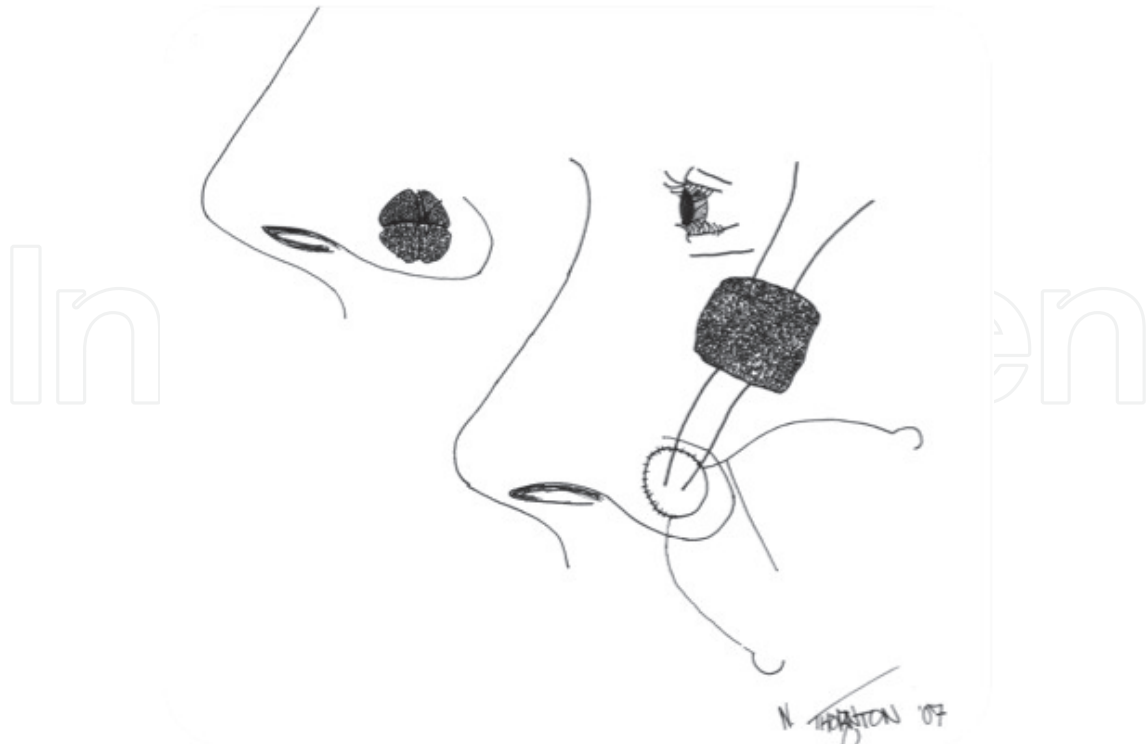

Fig. 13. Illustration of the bolster technique used by the author. Through-and-through 3-0 Prolene sutures are placed in juxtaposition through the bolster and tied in place. This technique obliterates central dead space and optimizes graft adherence.

It is not unusual for the most superficial portion of the graft to initially undergo a period of partial slough given the thickness of the forehead skin. Treatment for this is continued application of antibiotic ointment and patient reassurance. Patients should be seen at weekly intervals until full graft survival is ensured. At this point, daily application of antibiotic ointment may be discontinued and the opportunity to begin topical scar cream therapy with Mederma (Merz Pharmaceuticals, Greensboro, N.C.), Scar Zone (CCA Industries, East Rutherford, N.J.), or more recently, Transdermis scar therapy (NFI Consumer Products, Fayetteville, N.C.) is offered to patients. No clinical science supports the use of one scar cream over another; however, it has been our experience that the patients strongly prefer applying a scar care product. The Transdermis scar therapy subjectively results in a fairly rapid reduction in the inflammatory response. The opportunity to apply silicone sheeting to both the skin graft and donor-site areas could also be offered to patients.

That the postoperative recommendations for scar therapy are based not on science but on an evolving clinical practice with lessons learned from failures in scar therapy from the beginning of practice. Patients should be offered dermabrasion beginning at 6 weeks after grafting. Based on the behavior and appearance of the scar, up to three postoperative dermabrasion treatments may be offered at 6-week intervals. The dermabrasion can be carried out in the office setting with a topical tetracaine cream as an anesthetic and a rotary dermabrader using the diamond cylinder wheel. The endpoint of the dermabrasion is deep punctate bleeding. The goals of the dermabrasion procedure are to both improve the graft color and to blur or diminish the patch effect of the graft on the surrounding nasal skin by essentially improving the appearance of the surrounding scar. The procedure is confined to the graft and immediate surrounding skin. Although dermabrading entire subunits has

been advocated to provide an even contour over the subunit, we have found this practice largely unnecessary for smaller defects (Adams & Ramsey, 2005). Entire subunit dermabrasion is not frequently offered except for larger defects that encompass a majority of the subunit (Kuijpers et al., 2006). An illustration of the effects of dermabrasion is provided in sequential photographs in Figure 6.

5. Discussion

Skin grafting of defects of the lower third of the nose has historically, and often correctly, been considered to yield an inferior aesthetic result. The inappropriate placement of large, poorly color-matched supraclavicular or postauricular skin grafts to replace the thick, often convex defects of the lower third can yield results that are poor and frequently impossible to correct. Achieving a well contoured, aesthetically pleasing result begins with meticulous preoperative analysis of the nasal defect. Criteria for selecting lower third nasal defects that can be acceptably treated with full-thickness grafts include defect location, size smaller than 1 cm, and a partial-thickness defect with underlying dermis, subcutaneous tissue, or perichondrium.

The patchwork appearance caused by color mismatch and contour defects is the basic concern with using a full-thickness skin graft. Adhering to the concept of subunit reconstruction alleviates concerns for a resultant patchwork appearance, regardless of the reconstructive method. A defect-only approach is preferred to nasal reconstruction when using full-thickness skin grafts. Acceptable results are typically achieved using full-thickness skin grafts to reconstruct lower third defects smaller than 1 cm in diameter, without the need to excise an entire subunit. The decision to limit described reconstructions to less than 1 cm is not based on the inability to reconstruct larger defects; however, defects larger than 1 cm, in our experience, are reconstructed more successfully with entire subunit reconstructions using more standard reconstruction techniques (local or adjacent flap techniques). Contrasting defect-only versus subunit nasal reconstruction is beyond the scope of this discussion; however, these concepts are an important component of defect analysis and must always be considered. Again, a principle-based reconstruction, beginning with careful and meticulous defect analysis and selection, will yield an acceptable result regardless of the reconstructive method (Rohrich et al., 2004).

Adhering to the concept of replacing like with like, the individual characteristics of skin graft donor sites must be considered. After analyzing the defect and creating a like-sized template, the appropriate donor site must be selected based on texture, thickness, color, and tendency toward hyperpigmentation or hypopigmentation. Much of our current knowledge of donor-site characteristics comes from the dermatology literature (Dimitropoulos et al., 2005). Preauricular and, more preferably, forehead skin are the favored candidates for lower third nasal reconstruction. Forehead sites offer thicker skin, with a relatively sebaceous, oily texture, and they suffer the same degree of daily sun exposure and actinic damage as the lower third of the nose. Other donor sites available to the reconstructive surgeon include the nasolabial fold, postauricular skin, and supraclavicular skin. Postauricular donor sites suffer very little, if any, daily sun exposure and have much thinner skin than the nasal lobule. Therefore, postauricular donor sites are prone to pigmentation changes and do not provide a good contour match for reconstructing the lower third of the nose. Likewise, the skin of the supraclavicular region contains very few sebaceous elements and is often

hyperpigmented before harvest. The preauricular and forehead donor site grafts should be harvested without including terminal hairs and designed along relaxed skin tension lines, allowing for primary closure. Good results can be achieved without distorting the anterior hairline or sideburn.

Hubbard wrote a provocative article describing 33 patients who had lower third defects reconstructed with nasolabial fat and/or partially defatted skin grafts harvested from the nasolabial fold (Hubbard, 2004). The illustrated results demonstrated perfectly acceptable reconstructions, and this work serves as a useful description of a different technique using the nasolabial donor site. Although a departure from commonly preferred techniques, Hubbard's results are a testament to the concept that a skin graft can survive without being completely defatted. While the results Hubbard attained are aesthetically acceptable and associated with very few graft losses, most authors argue that leaving this fat impedes the processes of imbibition and inosculation necessary for graft survival, thereby risking high rates of graft loss. Establishing neovascularization requires contact between the graft dermis and the recipient bed. Therefore, we regard careful defatting of the graft and use of a bolster indispensable technical components to ensure survival or "take" of the full-thickness graft.

If a defect is of sufficient depth to require a graft that includes subcutaneous fat, using a full-thickness skin graft for such a defect represents a break from principle-based reconstruction. Likewise, when considering defects along or near the alar rim, one must carefully account for the potential for alar notching. Given appropriate defect analysis, reconstructing a superficial alar defect with a full-thickness skin graft may yield an acceptable result without resultant notching. Skin grafting for defects that abut the alar rim must be used with great caution. Preferentially, skin grafts on the posterior aspect of the ala or defects in male patients with very thick sebaceous skin could be grafted more safely without the risk of alar retraction secondary to the inherent stability of anatomical position on the ala (Rohrich et al., 2004). Deeper defects that extend into the subcutaneous tissue or to the perichondrium of the lateral crura demand a local flap or nasolabial flap with a nonanatomical alar contour graft.

Both the dermatologic and plastic surgery literature frequently debate whether to harvest a graft of identical size to the defect or to correct for anticipated contraction and harvest a larger graft. The technique described earlier in this discussion involves creation of a template of equal size to the defect. As previously mentioned, this template is designed in three dimensions, taking concavity or convexity into consideration. Full-thickness skin grafts primarily contract 10 to 15 percent after excision; however, inseting the graft under appropriate tension readily resolves this problem. Harvesting a larger graft to account for primary contraction presents a number of issues. First, the donor site must be larger, and in keeping with an elliptical design, increasing the diameter of the donor site necessitates an extension of its axial length. The larger donor graft, which represents an estimation of size to account for contraction, often requires trimming before inset and leads to an inexact size and shape that no longer resembles the template or the defect. Harvesting a larger graft does not improve these results but instead, presents the confounding morbidity of a larger donor site. Graft loss is always a concern, and although results are improved by careful defatting and bolster placement with through-and-through buttress sutures, other factors such as a history of smoking come into play. It is impossible to develop and maintain a comprehensive reconstructive practice without operating on smokers; however, these patients must understand that they are at significantly higher risk of graft loss or flap necrosis, and may

ultimately be left with an unacceptable result. The effect of nicotine is well documented as a potent vasoconstrictor that reduces blood flow, leading to a hypoxic cascade that impairs healing and increases platelet aggregation and adhesion. In the multicenter study of recipient-site complications of full-thickness skin grafts, authors of the Australian Mohs Database showed that “although the number of smokers was small, they had a mean graft survival of 2% on the second visit compared with 75.9% in the nonsmoking group” (Leibovitch et al., 2006). If the patients are seen preoperatively, substantial benefit has been shown in people who are able to abstain from smoking for at least 4 weeks before reconstruction.

Patients are typically well informed and understand the possibility of graft loss, as well as being highly attuned to changes in graft appearance, often presenting in the early postoperative period with concerns over a pale or overly dark graft. Indeed, full-thickness skin grafts are less predictable than nasolabial or local flaps. The healing period involves color and texture changes that can raise alarm before arriving at the final, aesthetically acceptable result. The graft is initially ischemic, appearing white and pale. As it evolves through the stages of revascularization, it will become edematous and then darken, resulting in a cyanotic or hyperemic appearance. These color changes vary from patient to patient, graft sites, and sizes in an unpredictable manner, but over weeks to months, the living graft will approximate a normal color. In some cases, especially with a thick graft, the epidermis will darken and slough. This tissue will reepithelialize, given the presence of dermal appendages, but both the patient and physician will have a justified concern that the graft has failed. Patients should be counseled to anticipate these changes in color and texture.

In keeping with the principles asserted by Rohrich et al., good contour is the aesthetic endpoint to all nasal reconstructions (Rohrich et al., 2004). To achieve this, the authors describe “complementary ablative procedures” to enhance final results. These procedures include dermabrasion, thinning of flaps, breaking up trapdoor scar lines, and steroid injections at sites of pincushioning. Primary dermabrasion is not typically performed for full-thickness skin grafts because of the risk of trauma to the delicate graft and because of the unpredictable course of healing that the graft will follow. Dermabrasion of skin grafts is instead performed at approximately 6 weeks postoperatively. Depending on the size of the graft, dermabrasion can be limited to the graft margins or can include an entire subunit(s).

6. Conclusions

The following principles make skin grafting of lower third subunits a viable reconstruction option.

1. Rigorous defect selection to include only superficial and size-limited defects. Defects larger than 1 cm will be better treated with alternative reconstructions. Defects that involve cartilage or deeper are by definition complex nasal defects that will require onlay cartilage grafting for satisfactory reconstruction. Skin grafting is not offered for these defects.
2. Caution in skin grafting defects abutting the alar rim.
3. Meticulous graft donor-site selection using the thicker and better color-matched forehead skin in the majority of cases.
4. Meticulous size matching of the graft, using a foil pattern template, and development of a bolster material from a surgical sponge that provides ideal compression and handling

qualities used in conjunction with a through-and-through central Prolene suture to minimize graft dead space.

5. Liberal use of postoperative dermabrasion to optimize the final color match.

Provided that these constraints are followed, skin grafting of the lower third of the nose is an appropriate part of the reconstructive algorithm.

7. References

- Adams, D., Ramsey, M. (2005). Grafts in dermatologic surgery: Review and update on full- and split-thickness skin grafts, free cartilage grafts, and composite grafts. *J Dermatol Surg*, Vol.32, No.8 Pt 2, (August 2005), pp. (1055-1067)
- Baker, S., Swanson, N. (1995). *Local Flaps in Facial Reconstruction* (1st ed.), Mosby, 0801669251, St. Louis
- Barton, Jr., F. (1981). Aesthetic aspects of partial nasal reconstruction. *Clin Plast Surg*, Vol.9, No.2, (April 1981), pp. (177-191)
- Collins, P., Farber, G. (1984). Postsurgical dermabrasion of the nose. *J Dermatol Surg Oncol*, Vol.10, No.6, (June 1984), pp. (476-477)
- Dimitropoulos, V., Bichakjian, C., Johnson, T. (2005). Forehead donor site full-thickness skin graft. *Dermatol Surg*, Vol.31, No.3, (March 2005), pp. (324-326)
- Hill, T. (1987). Contouring of donor skin in full-thickness skin grafting. *J Dermatol Surg Oncol*, Vol.13, No.8, (August 1987), pp. (883-886)
- Hubbard, T. (2004). Leave the fat, skip the bolster: Thinking outside the box in lower third nasal reconstruction. *Plast Reconstr Surg*, Vol.114, No.6, (November 2004), pp. (1427-1435)
- Kuijpers, D., Smeets, N., Lapière, K., Thissen, M., Krekels, G., Nuemann, H. (2006). Do systemic antibiotics increase the survival of a full-thickness graft of the nose? *J Eur Acad Dermatol Venereol*, Vol.20, No.10, (November 2006), pp. (1296-1301)
- Leibovitch, I., Huilgol, S., Richards, S., Paver, R., Selva, D. (2006). The Australian Mohs database: Short term recipient-site complication in full-thickness skin grafts. *Dermatol Surg*, Vol.32, No.11, (November 2006), pp. (1364-1368)
- Rohrich, R., Griffin, J., Ansari, M., Beran, S., Potter, J. (2004). Nasal reconstruction--beyond aesthetic subunits: A 15 year review of 1334 cases. *Plast Reconstr Surg*, Vol.114, No.6, (November 2004), pp. (1405-1416); discussion pp. (1417-1419)



Skin Grafts - Indications, Applications and Current Research

Edited by Dr. Marcia Spear

ISBN 978-953-307-509-9

Hard cover, 368 pages

Publisher InTech

Published online 29, August, 2011

Published in print edition August, 2011

The procedure of skin grafting has been performed since 3000BC and with the aid of modern technology has evolved through the years. While the development of new techniques and devices has significantly improved the functional as well as the aesthetic results from skin grafting, the fundamentals of skin grafting have remained the same, a healthy vascular granulating wound bed free of infection. Adherence to the recipient bed is the most important factor in skin graft survival and research continues introducing new techniques that promote this process. Biological and synthetic skin substitutes have also provided better treatment options as well as HLA tissue typing and the use of growth factors. Even today, skin grafts remain the most common and least invasive procedure for the closure of soft tissue defects but the quest for perfection continues.

How to reference

In order to correctly reference this scholarly work, feel free to copy and paste the following:

James F. Thornton and Emily D. Rapstine (2011). Lower Third Nasal Skin Grafting, Skin Grafts - Indications, Applications and Current Research, Dr. Marcia Spear (Ed.), ISBN: 978-953-307-509-9, InTech, Available from: <http://www.intechopen.com/books/skin-grafts-indications-applications-and-current-research/lower-third-nasal-skin-grafting>

INTECH
open science | open minds

InTech Europe

University Campus STeP Ri
Slavka Krautzeka 83/A
51000 Rijeka, Croatia
Phone: +385 (51) 770 447
Fax: +385 (51) 686 166
www.intechopen.com

InTech China

Unit 405, Office Block, Hotel Equatorial Shanghai
No.65, Yan An Road (West), Shanghai, 200040, China
中国上海市延安西路65号上海国际贵都大饭店办公楼405单元
Phone: +86-21-62489820
Fax: +86-21-62489821

© 2011 The Author(s). Licensee IntechOpen. This chapter is distributed under the terms of the [Creative Commons Attribution-NonCommercial-ShareAlike-3.0 License](https://creativecommons.org/licenses/by-nc-sa/3.0/), which permits use, distribution and reproduction for non-commercial purposes, provided the original is properly cited and derivative works building on this content are distributed under the same license.

IntechOpen

IntechOpen