

# We are IntechOpen, the world's leading publisher of Open Access books Built by scientists, for scientists

6,900

Open access books available

186,000

International authors and editors

200M

Downloads

Our authors are among the

154

Countries delivered to

TOP 1%

most cited scientists

12.2%

Contributors from top 500 universities



WEB OF SCIENCE™

Selection of our books indexed in the Book Citation Index  
in Web of Science™ Core Collection (BKCI)

Interested in publishing with us?  
Contact [book.department@intechopen.com](mailto:book.department@intechopen.com)

Numbers displayed above are based on latest data collected.  
For more information visit [www.intechopen.com](http://www.intechopen.com)



## Fournier's Gangrene

Ndubuisi Eke and John E. Raphael

*Urology Unit, Department of Surgery,  
University of Port Harcourt Teaching Hospital, Port Harcourt,  
Nigeria*

### 1. Introduction

Fournier's gangrene (FG) is an acute, rapidly progressive and potentially fatal, infective necrotizing fasciitis affecting the external genitalia, perineal or perianal regions<sup>1</sup>. The definition of FG changed more often than the treatment over the years. Professor Jean-Alfred Fournier (1832-1914), first defined FG as an 'acute idiopathic gangrene of the scrotum in the young male<sup>2</sup>. The frequent isolation of causative organisms led to the first modification. Observation that the elderly with certain co-morbidities are more often affected along with reports in women went a long way in modifying the description of FG<sup>3</sup>. FG is a disease of antiquity. King Herod of Judea was suspected to have suffered from genital gangrene in association with diabetes mellitus<sup>4</sup>. Over the decades, FG has proved to be an enigma to the physician and an embarrassment to the patient. In 1764, Baurienne originally described an idiopathic, rapidly progressive soft-tissue necrotizing process that led to gangrene of the male genitalia. However, Jean-Alfred Fournier, a Parisian venereologist, is more commonly associated with this disease, which bears his name. In one of Fournier's clinical lectures in 1883, he presented a case of perineal gangrene in an otherwise healthy young man<sup>5</sup>. Since Fournier's description, subsequent experience has shown that, in most cases, Fournier gangrene has an identifiable cause and that it frequently manifests more indolently. Trauma to the genitalia continues to be a frequently recognized vector for the introduction of bacteria that initiate the infectious process<sup>5</sup>. The disease carries a significant mortality. The mortality from FG has shown no correlation with advancement in medical services. An unpublished report indicates a paradoxically higher mortality rate in developed countries compared to developing ones.

### 2. Epidemiology

Fournier's gangrene is relatively uncommon. The true incidence of the disease is unknown. However, the incidence appears to be rising. In a retrospective study of cases reported in the English literature from 1950-1999, 1726 cases were documented<sup>6</sup>. A continuing study on Fournier's gangrene, yet to be published, revealed 1571 cases from 2000 to 2007. This rise may partly be attributed to the exploitation of the internet to disseminate information<sup>7</sup>. Most reported cases occur in patients aged 30-60 years. A literature review found only 56 paediatric cases, with 66% of those in infants younger than 3 months.

Earlier reports excluded women, probably because Fournier's original report, from which the disease got its eponym, excluded women and children. The male-to-female ratio is

approximately 10:1. Lower incidence in females may not be unrelated to better drainage of the perineal region through vaginal secretions. Male homosexuals may be at higher risk, especially to drug resistant strains<sup>8</sup>.

3. Relevant anatomy

The corpora, urethra, testes, and cord structures are usually not involved in Fournier’s gangrene, while the superficial and deep fascia and the skin are destroyed. The complex anatomy of the male external genitalia influences the initiation and progression of Fournier’s gangrene. This infectious process involves the superficial and deep fascial planes of the genitalia. As the microorganisms responsible for the infection multiply, infection spreads along the anatomical fascial planes, often sparing the deep muscular structures and, to variable degrees, the overlying skin. The knowledge of the peculiar anatomy of the male lower urinary tract and external genitalia is critical for the clinician treating a man with Fournier’s gangrene.

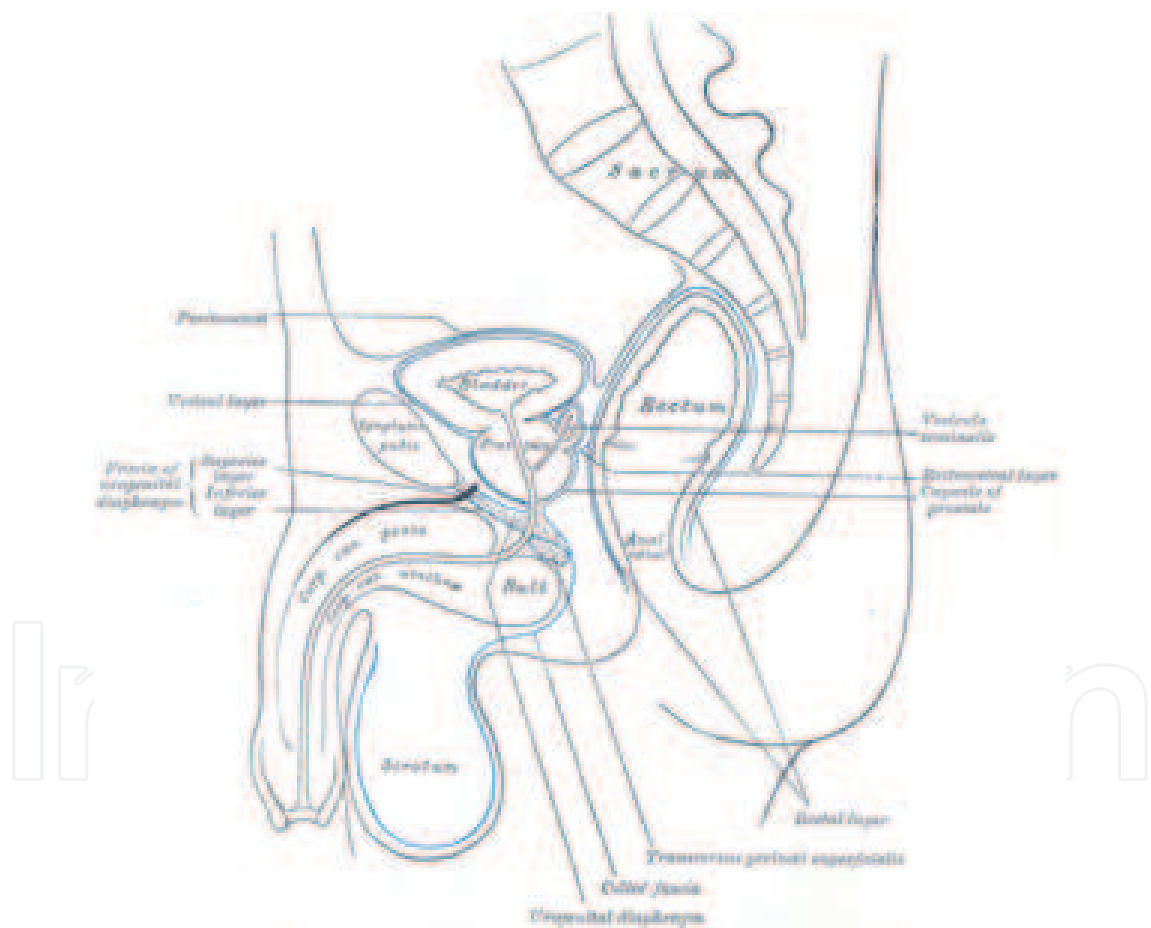


Fig. 1. Fascial arrangement of the scrotum and perineum<sup>9</sup>

Colles’ fascia completely envelops the scrotum and penis, continuing cephalad to the level of the clavicles. In the inguinal region, this fascial layer is known as Scarpa’s fascia. Understanding the tendency of necrotizing fasciitis to spread along fascial planes and the fascial anatomy, one can see how a process that initiates in the perineum can spread to the abdominal wall, the flank, and even the chest wall.

#### 4. Skin and superficial fascia

Because Fournier's gangrene is predominantly an infectious process of the superficial and deep fascial planes, appreciating the anatomic relationship of the skin and subcutaneous structures of the perineum and abdominal wall is vital.

The skin cephalad to the inguinal ligament is backed by Camper's fascia, which is a layer of fat-containing tissue of varying thickness and the superficial vessels to the skin that run through it. Scarpa's fascia forms another distinct layer deep to Camper fascia. In the perineum, Scarpa's fascia blends into Colles' fascia (superficial perineal fascia), and continuous with Dartos fascia of the penis and scrotum.

Several important anatomic relationships should be considered. A potential space between the Scarpa's fascia and the deep fascia of the anterior wall (external abdominal oblique) allows for the extension of a perineal infection into the anterior abdominal wall. Superiorly, Scarpa's and Camper's fasciae coalesce and attach to the clavicles, ultimately limiting the cephalad extension of an infection that may have originated in the perineum. Colles's fascia is attached to the pubic arch and the base of the perineal membrane, and it is continuous with the superficial Dartos fascia of the scrotal wall. The perineal membrane is also known as the inferior fascia of the urogenital diaphragm and, together with Colles' fascia, defines the superficial perineal space.

This space contains the membranous urethra, bulbar urethra, and bulbourethral glands. In addition, this space is adjacent to the anterior anal wall and ischiorectal fossae. Infectious disease of the male urethra, bulbourethral glands, perineal structures, or rectum can drain into the superficial perineal space and can extend into the scrotum or into the anterior abdominal wall up to the level of the clavicles.

#### 5. Blood supply

Branches from the inferior epigastric and deep circumflex iliac arteries supply the lower aspect of the anterior abdominal wall. Branches of the external and internal pudendal arteries supply the scrotal wall. With the exception of the internal pudendal artery, each of these vessels travels within Camper's fascia and can therefore become thrombosed in the pathogenesis of Fournier gangrene.

In the male, the testis receives its blood supply primarily from the testicular artery, a branch of the abdominal aorta. This explains the sparing of the testis in Fournier's gangrene.

Thrombosis jeopardizes the viability of the skin of the scrotum and perineum. Often, the posterior aspect of the scrotal wall supplied by the internal pudendal artery remains viable and can be used in the reconstruction following resolution of the infection.

#### 6. Penis and scrotum

The contents of the scrotum, namely the testes, epididymides and cord structures, are invested by several fascial layers distinct from the Dartos fascia of the scrotal wall.

The most superficial layer of the testis and cord is the external spermatic fascia, which is continuous with the external oblique aponeurosis of the superficial inguinal ring. The next deeper layer is the internal spermatic fascia, which is continuous with the transversalis fascia. The Buck fascia covers the erectile bodies of the penis, the corpora cavernosa, and the anterior urethra. The Buck fascia fuses to the dense tunica albuginea of the corpora cavernosa, deep in the pelvis. These fascial layers do not become involved with an infection

of the superficial perineal space and can limit the depth of tissue destruction in a necrotizing infection of the genitalia.

## 7. Aetiology

Although originally described as idiopathic gangrene of the genitalia, Fournier gangrene has an identifiable cause in approximately 95% of cases. The necrotizing process commonly originates from an infection in the anorectum, urogenital tract, or skin of the genitalia<sup>10</sup>. Trauma, recent surgery, and the presence of foreign bodies may also lead to the disease. Perianal, perirectal and ischioirectal abscesses, anal fissures; colonic perforations, urethral strictures with urinary extravasations; epididymo-orchitis or hidradenitis may lead to the disease. Urethral instrumentation, prosthetic penile implants, superficial soft-tissue injuries, intramuscular injections, genital piercings, steroid enemas (used for the treatment of radiation proctitis), blunt thoracic trauma, and penile self-injection with cocaine have been reported in the literature as causative factors.

In women, septic abortions, vulva or Bartholin gland abscesses, hysterectomy, and episiotomy are documented sources of sepsis. In men, anal intercourse may increase risk of perineal infection, either from blunt trauma to the area or by spread of rectally carried microbes.

In children, strangulated inguinal hernia, circumcision, omphalitis, insect bites, trauma, urethral instrumentation, peri-rectal abscesses, systemic infections, and burns have led to the disease.

Poor perineal hygiene or the presence of chronically indwelling catheters, such as in paraplegic patients, poses an increased risk.

Wound cultures from patients with Fournier gangrene reveal that it is a polymicrobial infection with an average of four isolates per case. *Escherichia coli* is the predominant aerobe, and *Bacteroides* species the predominant anaerobe. Other common microflora includes *Proteus*, *Staphylococcus*, *Enterococcus*, aerobic and anaerobic *Streptococcus*, *Pseudomonas*, *Klebsiella*, and *Clostridium*. Incidence of methicillin-resistant *Staphylococcus aureus* (MRSA) may be increasing<sup>7</sup>.

Any condition that leads to depressed cellular immunity may predispose a patient to the development of Fournier gangrene. Examples include the following: diabetes mellitus (present in as many as 60% of cases), alcoholism, extremes of age, malignancy, chronic steroid use, cytotoxic drugs, lymphoproliferative diseases, malnutrition and HIV infection.

## 8. Pathophysiology

The following are pathognomonic findings of Fournier gangrene upon pathologic evaluation of the involved tissue:

Necrosis of the superficial and deep fascial planes,

Fibrinoid coagulation of the nutrient arterioles,

Polymorphonuclear cell infiltration and

Microorganisms identified within the involved tissues

In necrotizing fasciitis as opposed to cellulitis, the location of the inflammation involves the subcutaneous fat, fascia, and muscle in addition to the dermis. A photomicrograph may show the presence of ulcerated epidermis and the presence of thrombosed blood vessel

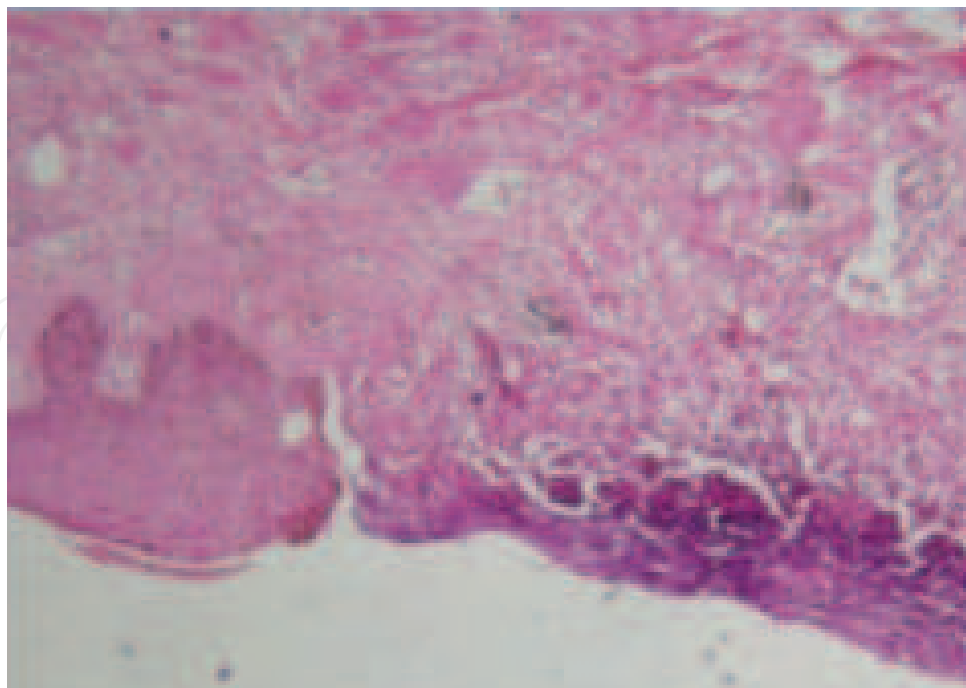


Fig. 2. Ulcerated epidermis and dermis with thrombosed blood vessel and bacterial colonies

Infection represents an imbalance between host immunity and the virulence of the causative microorganisms. The aetiological factors allow the portal of entry of the microorganism into the perineum. The compromised immunity provides a favourable environment to initiate the infection, and the virulence of the microorganism promotes the rapid spread of the disease. Microorganism virulence results from the production of toxins or enzymes that create an environment conducive to rapid microbial multiplication<sup>11</sup>. In a 1924 series of Chinese men with necrotizing infections, Meleney reported that streptococcal species were the predominant organisms recovered from cultures<sup>12</sup>. Meleney attributed the FG to this sole genus. Subsequent clinical series however stress the polymicrobial nature of most cases of necrotizing infection including Fournier's gangrene<sup>13,14</sup>.

Presently, recovering only streptococcal spp is unusual<sup>15</sup>. Rather, streptococcal organisms are culture along with as many as five other organisms. The commonest causative organisms are *Streptococcus* spp, *Staphylococcus* spp., Genera of Enterobacteriaceae family, anaerobic organisms and fungi.

Most authorities believe the polymicrobial nature of Fournier gangrene is necessary to create the synergy of enzyme production that promotes rapid multiplication and spread of the infection<sup>11</sup>. For example, one microorganism might produce the enzymes necessary to cause coagulation of the nutrient vessels. Thrombosis of these nutrient vessels reduces local blood supply. Thus, tissue oxygen tension falls. The resultant tissue hypoxia allows growth of facultative anaerobes and microaerophilic organisms. These latter microorganisms, in turn, may produce enzymes (e.g., lecithinase, collagenase), which lead to digestion of fascial barriers, thus fueling the rapid extension of the infection.

The fascial necrosis and digestion are hallmarks of FG. Knowledge of this provides the surgeon with a clinical marker of the extent of tissue affection. Severe or fulminant Fournier's gangrene can spread from the fascial envelopment of the genitalia throughout the perineum, along the trunk, occasionally, into the thighs and very rarely, to the chest.



## 9. Clinical presentation

A thorough review of systems, including history of diabetes, alcohol abuse, cancer, colorectal or urogenital disease or surgery, steroid use, sexual history, and HIV status is important. Fournier's gangrene usually begins with an insidious onset of pruritus and discomfort of the external genitalia. Early in the course of the disease, pain may be out of proportion to physical findings. Swelling and erythema of the region follow pain, and a patient may complain of systemic symptoms such as fever or chills. As gangrene develops, pain may subside as nerve tissue becomes necrotic.

Skin overlying the affected region may be normal, erythematous, edematous, cyanotic, bronzed, indurated, blistered, and/or frankly gangrenous. Skin appearance often underestimates the degree of underlying disease. A faeculent odor may be present secondary to infection with anaerobic bacteria. Crepitus may be present, but its absence does not exclude the presence of *Clostridium* species or other gas-producing organisms. Systemic symptoms (e.g. fever, tachycardia, and hypotension) may be present. A thorough genital and perianal examination is required to detect potential portal of entry.

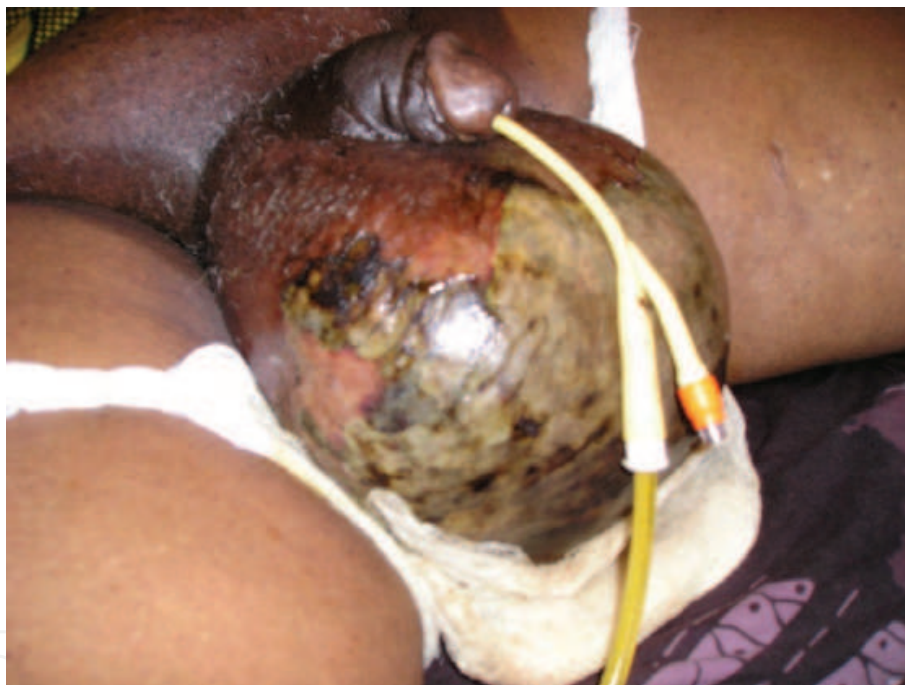

Fig. 3. Fournier's gangrene of the scrotum

## 10. Investigations

The diagnosis of Fournier's gangrene is clinical and includes the history and physical examination findings, especially the anatomical involvement in the external genitalia and perineum. Urinalysis and blood sugar measurements give evidence of metabolic derangements such as diabetes mellitus. Considering that FG is a urological emergency, treatment should not be delayed for these investigative tools. Other investigations are essential to identify co-morbid factors as well as causative factors. Appropriate bacteriological evaluation of pus from the gangrene, full blood count, renal and hepatic function studies are essential. Diagnostic investigations, which may also help to determine

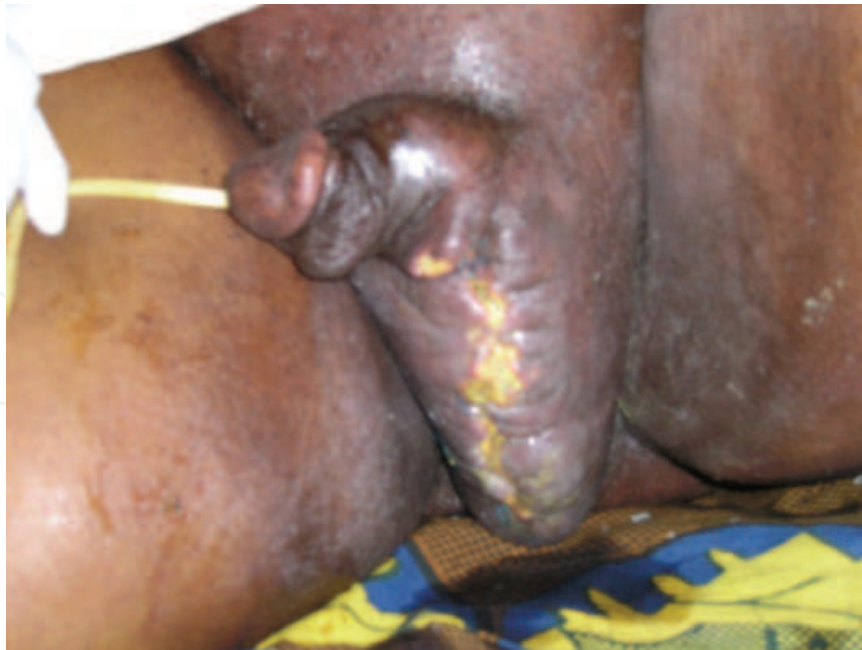

Fig. 4. Fournier's gangrene of scrotum following orchidectomy for prostate cancer. (Note fungal infection of perineal skin)

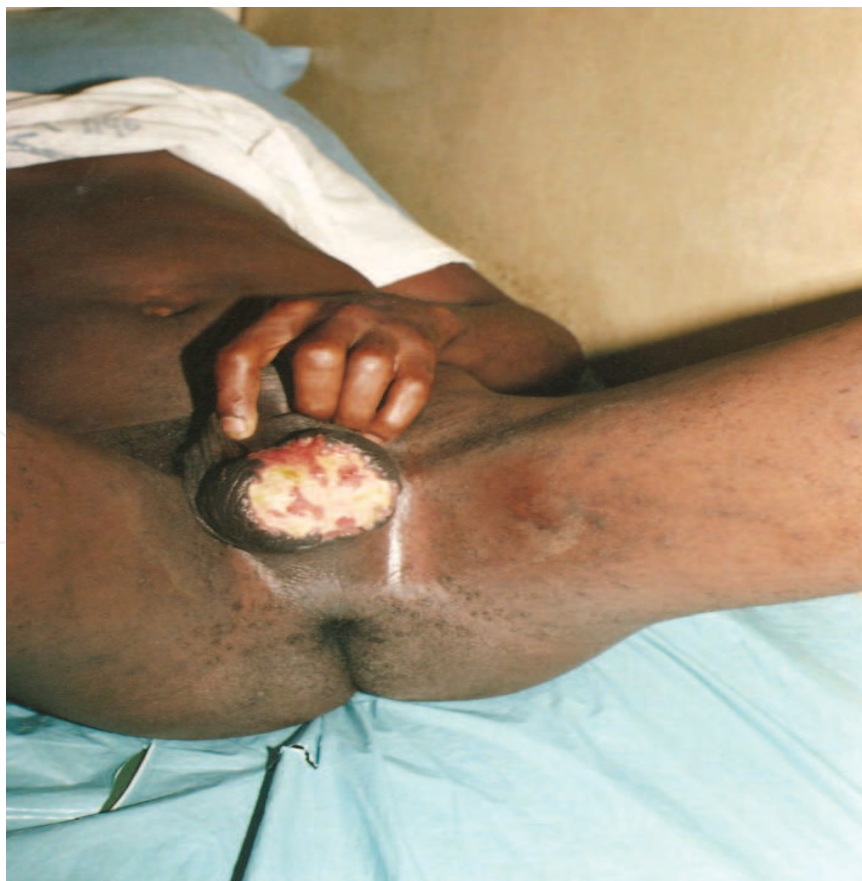

Fig. 5. Fournier's gangrene of scrotum in a young man



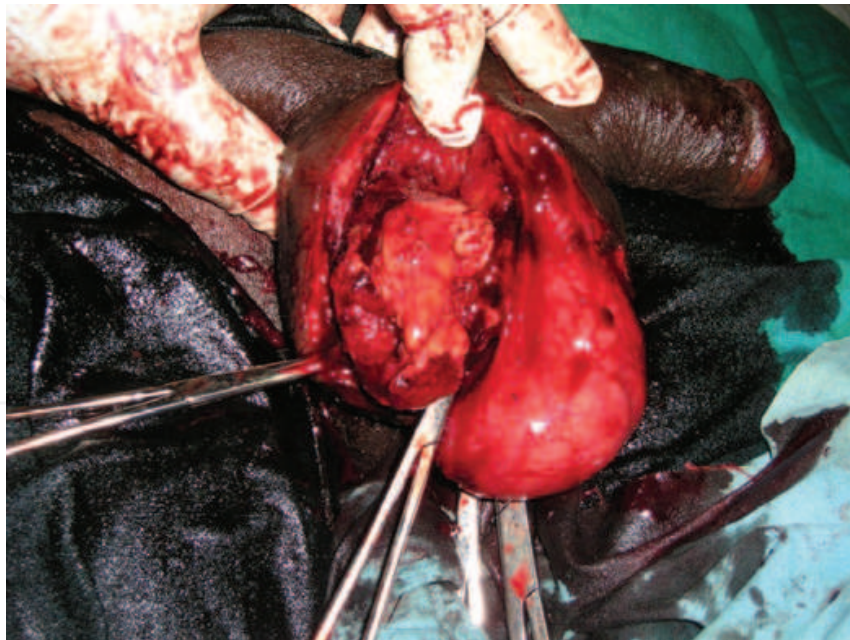


Fig. 6. Debridement for Fournier's gangrene showing healthy testes

the extent of the disease employ radiological tools such as ultra-sound scan (USS), computerised tomographic (CT) scan and magnetic resonance imaging (MRI) <sup>16</sup>. The hallmark in all imaging modalities is the demonstration of air in the soft tissue planes <sup>17</sup>. These tools may be employed when they are available. Histopathology assessment has been reported by authors but describes pathological consequences of the disease. Marjolin's ulcer has been reported to arise from the scar of a FG many years after successful treatment <sup>18,19</sup>. Follow up and biopsy when indicated are necessary.

Some investigations are necessary to identify the source of sepsis in FG. Thus, there may be need for cystoscopy, colonoscopy and biopsies <sup>20</sup>.

## 11. Treatment

The treatment of FG depends on the status of the patient at presentation. Immediate treatment following diagnosis or suspicion includes resuscitative measures such as rehydration, blood transfusion, electrolyte replacements, multiple therapy antimicrobial agents, Oxygen and adequate analgesia <sup>21</sup>.

Triple antimicrobial therapy is started empirically to cover aerobes and anaerobes as well as gram-negative and gram-positive organisms pending the result of microbial microscopy, culture and sensitivity from pus and or blood specimens. The organisms invariably cultured from FG include staphylococci and streptococci, coliforms, pseudomonas, bacteroides and clostridia <sup>22</sup>. Penicillin is used to cover streptococci while metronidazole is given against anaerobes such as bacteroides. A broad spectrum antimicrobial agent, preferably the cephalosporins combined with gentamicin is used against gram negative organisms such as the coliforms.

Sepsis leading to multiple organ failure is thought to be the leading cause of death in Fournier's gangrene <sup>23-25</sup>.

Some authors<sup>10,26</sup> have doubted whether antimicrobial agents are responsible for the reduction in mortality.

The use of unprocessed honey has been advocated by clinicians reporting good outcome<sup>27,28</sup>. Honey inhibits bacterial growth due to its low pH, high viscosity, the hygroscopic effect and presence of inhibine and anti-oxidants<sup>29</sup>.

Hyperbaric oxygen (HBO) was used in the erroneous belief that the crepitus in FG was of clostridial aetiology<sup>30</sup>. The efficacy of hyperbaric oxygen is applicable in clostridial and nonclostridial infections<sup>30,31</sup>. HBO increases the oxygen tension in tissues to a level that is inhibitory and lethal to anaerobic bacteria, while limiting necrosis and enhancing demarcation of gangrene<sup>30-33</sup>. However in a review of 42 patients with FG and in whom half were given HBO and another half not given, there was a higher mortality among the HBO patients<sup>34</sup>. This had been observed 10 years earlier<sup>35</sup>.

Adequate nutrition is an essential part of treatment of FG. Enteral feeding is preferred to parenteral feeding.

Patients with co-morbid or predisposing factors need these factors controlled. In one study, the authors concluded that diabetes control was an important prognostic measure<sup>36</sup>.

Surgical treatment is the cornerstone of the treatment of FG. A mortality of 100% has been recorded in patients with necrotizing fascitis treated without surgery<sup>24,37,38</sup>. Surgical treatment includes excision of all necrotic tissues. This may be repeated as necrosis is observed.

Orchidectomy may be required for testicular gangrene, a rare complication of FG. It has also been done when there was not enough scrotum to house the testis.

Reconstruction may be required to restore function and cosmetic appearance. Procedures that have been carried out vary from secondary closure of well granulated wound to flap procedures to create a neo-scrotum. The testis may be buried in inner aspect of thighs or inguinal regions temporarily, to prevent desiccation until the wound becomes clean.

In a report of FG in 10 women, the authors concluded that colostomy was an integral part of the management of FG patients requiring extensive debridement<sup>39</sup>.

Urinary diversion via a suprapubic cystostomy is indicated in FG of the penis.

The consensus appears to be that the use of catheterization or colostomy should be pragmatic and should be decided on individual merit<sup>28,37</sup>.

## 12. Complications

An uncomplicated Fournier's gangrene is one which is localized and resolves with the basic treatments of debridement, dressings and antimicrobial agents.

Morbidity includes variable periods of hospitalization with its attendant problems such as deep vein thrombosis and pulmonary embolism.

Complicated FG is found in those patients with systemic involvement including renal, pulmonary and cardiac derangements. Complicated FG may require urgent and vigorous resuscitation in the intensive care unit and reconstructive procedures. Specific complications include auto-amputation of the penis<sup>20</sup>, fatal overwhelming sepsis, tetanus<sup>40</sup> and Marjolin's ulcer long after the wound has healed<sup>41</sup>. The testis may become gangrenous from FG in which sepsis has originated from the retroperitoneal space or the abdomen<sup>42,43</sup>. Scrotal skin loss may be severe not to accommodate the testis. Orchidectomy has been done for this reason<sup>44,45</sup>. Infertility is a rare complication of Fournier's gangrene<sup>46</sup>.

## 13. Treatment outcome

Although more patients survive from FG than die from it, the mortality in FG remains high ranging from 3 to 45%<sup>28,47</sup>. In a review of 1726 cases from 1950 to 1999 worldwide, reported

in the English literature, the mortality rate was 16 per cent <sup>6</sup>. In a subsequent unpublished study of 3297 cases of FG from 1950 to 2007, the mortality rate rose to 21.1%. This is in spite of advances in technology and medical practice. It was paradoxically observed in both studies the mortality was higher in the advanced countries of America, Canada and Europe than in the underdeveloped countries.

Factors associated with high mortality include an anorectal source, advanced age, diabetes mellitus, extensive disease (involving abdominal wall or thighs), shock or sepsis at presentation, renal failure, and hepatic dysfunction <sup>5</sup>. Death usually results from systemic illnesses, such as sepsis, coagulopathy, diabetic ketoacidosis, acute renal failure or multiple organ failure.

#### 14. Prognosis

Many factors impact on the prognosis in FG. Early presentation in good functional status together with adequate and prompt treatment lead to a good outcome. Co-morbid factors include older age, poorly controlled diabetes mellitus <sup>24,48</sup>, and colorectal source of infection. Locally involved FG is associated with reduced mortality. Involvement extending beyond 5% of the body surface area portends a poor prognosis <sup>49</sup>. There is currently no consensus on the use of indices for predicting mortality. However, if there has been lower limb or abdominal wall involvement there is a noticeable increase in mortality rate.

There have been efforts to assess the risk of death in the disease. Laor et al. developed the Fournier's Gangrene Severity Index (FGSI) for prognostication in order to assist physicians in predicting mortality probability in FG. A severity index above 9 indicates a 75% mortality probability while under 9 indicates a 78% survival probability <sup>50</sup>.

Other efforts to assess the risk of death in the disease have been reported <sup>46,51</sup>. Villanueva Saenz *et al* 2002 <sup>52</sup> employed APACHE II and found that patients with scores of 20 or more had a higher mortality than those with a lower score. The addition of platelet count and BSA to the variables to modify Laor's FGSIS has been claimed to improve the predictive value of FGSIS <sup>72</sup>.

#### 15. References

- [1] Smith GL, Bunker CB, Dinneen MD. Fournier's gangrene. *Br J Urol* 1998; 81:347-55.
- [2] Wilson B. Necrotizing fasciitis. *Am Surg* 1952; 18:416-431.
- [3] Stephens BJ, Lathrop JC, Rice WT, Gruenberg JC. Fournier's gangrene: Historic (1764-1978) versus contemporary (1979-1988) differences in etiology and clinical importance. *Am Surg* 1993; 59: 149-154.
- [4] Corman JM. Classic articles in colonic and rectal surgery. *Dis Colon Rectum* 1988; 31: 984-988.
- [5] Eke N. Fournier's gangrene: a review of 1726 cases. *Br J Surg* 2000; 87:718-728.
- [6] Paty R, Smith AD. Gangrene and Fournier's gangrene. *Urol Clin North Am* 1992; 19:149-162.
- [7] Ndirika SC, Melville R, Green J. Fournier's gangrene in a man who was HIV-positive with a high CD4 count: an unusual presentation of a complex recto-scrotal fistula. *Uro Today Int J* 2010;10:3834.
- [8] The muscles and fasciae of the pelvis. Bartleby.com edition of Gray's Anatomy of the human body Chapter 6.

- [9] Clayton MD, Fowler JE Jr, Sharifi R, Pearl RK. Causes, presentation and survival of fifty-seven patients with necrotizing fasciitis of the male genitalia. *Surg Gynecol Obstet* 1990 ; 170: 49-55.
- [10] Mergenhagen SE, Thonard JC, Scherp HW. Studies on synergistic infections. Experimental infections with anaerobic streptococci. *J Infect Dis* 1958 ; 103:33-44.
- [11] Meleney FL. Hemolytic Streptococcus gangrene. *Arch Surg* 1924; 9:317-321.
- [12] Ben-Aharon U, Borenstein A, Eisenkraft S, Lifschitz O, Leviav A. Extensive necrotizing soft tissue infection of the perineum. *Isr J Med Sci* 1996; 32:745-749.
- [13] Basoglu M, Gül O, Yildirgan I, Balik AA, Ozbey I, Oren D. Fournier's gangrene: review of fifteen cases. *Am Surg* 1997; 63:1019-1021.
- [14] Goyette M. Group A streptococcal necrotizing fasciitis Fournier's gangrene - Quebec *Can Commun Dis Rep* 1997; 23:101-103.
- [15] Yoneda A, Fujita F, Tokai H, Ito Y, Haraguchi M, Tajima Y, Kanematsu T. MRI can determine the adequate area for debridement in the case of Fournier's gangrene. *Int Surg* 2010; 95:76-79.
- [16] Levenson RB, Singh AK, Novelline RA. Fournier gangrene: role of imaging. *Radiographics*. 2008; 28:519-528.
- [17] Schneider PR, Russele RC, Zoog EG. Fournier's gangrene: a general surgery problem. *World J Surg* 1983; 7: 288-294.
- [18] Chintamani, Shankar M, Singhal V, Singh JP, Bansal A, Saxena S. Squamous cell carcinoma developing in the scar of Fournier's gangrene Case report. *BMC Cancer*. 2004; 4:16.
- [19] Eke N, Onwuchekwa AC. Fournier's gangrene of the penis associated with adenocarcinoma of the rectum and diabetes mellitus. *Acta Urologica Italica* 1999; 13:207-209.
- [20] Ong HS, Ho YH. Genitoperineal gangrene: experience in Singapore. *Aust N Z J Surg* 1996; 66:291-293.
- [21] Laucks SS II. Fournier's gangrene. *Surg Clin North Am* 1994; 74:1339 -1352.
- [22] Cohen M, Tamir E, Abu-Abid S, Galili Y, Giladi M, Avital S, Shafir R, Klausner Y. [The diagnosis and treatment of Fournier's gangrene]. *Harefuah* 1998; 135: 360 -363, 407
- [23] Yanar H, Taviloglu K, Ertekin C, Guloglu R, Zorba U, Cabioglu N, Baspinar I. Fournier's gangrene: risk factors and strategies for management. *World J Surg* 2006; 30:1750-1754.
- [24] Adinolfi MF, Voros DC, Moustouskas NM, Hardin WD, Nichols RL. Severe systemic sepsis resulting from neglected perineal infections. *South Med J* 1983; 76: 746-749.
- [25] Adams JR Jr, Mata JA, Venable DD, Culkin DJ, Bocchini JA Jr. Fournier's gangrene in children. *Urology* 1990; 35:439-441.
- [26] Effem SE. Recent advances in the management of Fournier' gangrene: preliminary observations. *Surgery* 1993; 113:2000-2004.
- [27] Hejase MJ, Simonin JE, Bihle R, Coogan CL. Fournier's gangrene: experience with 38 patients. *Urology* 1996; 47: 734-739.
- [28] Moore OA, Smith LA, Campbell F, Seers K, McQuay HJ, Moore RA. Systematic review of the use of honey as a wound dressing. *BMC Complement Alternat Med* 2001; 1:2-8.
- [29] Korhonen K, Hirn M, Niinikoski J. Hyperbaric oxygen in the treatment of Fournier's gangrene. *Eur J Surg* 1998; 164:251-255.
- [30] Hollabaugh RS Jr, Dmochowski RR, Hickerson WL, Cox CE. Fournier's gangrene: therapeutic impact of hyperbaric oxygen. *Plast Reconstr Surg* 1998; 101:94-100.
- [31] Benizri E, Fabiani P, Migliori G. Gangrene of the perineum. *Urology* 1996; 47:935-939.



- [32] Ziser A, Girski Z, Gozal D, Melamed Y, Adler M. Hyperbaric oxygen therapy for Fournier's gangrene. *Crit Care Med* 1985;13:773-774.
- [33] Mindrup SR, Kealey GP, Fallon B. Hyperbaric oxygen for the treatment of Fournier's gangrene. *J Urol* 2005; 173:1975-1977.
- [34] Shupak A, Shoshani O, Goldenberg I, et al. Necrotizing fasciitis: an indication for hyperbaric oxygenation. *Surgery* 1995; 118:873-878.
- [35] Malik AM, Sheikh S, Pathan R, Khan A, Sheikh U. The spectrum of presentation and management of Fournier's gangrene-an experience of 73 cases. *J Pak Med Assoc* 2010; 60:617-619.
- [36] Flanigan RC, Kursch FD, Mc Dougal WS, Persky L. Synergistic gangrene of the scrotum and penis secondary to colorectal disease. *J Urol* 1978; 119:369.
- [37] Okeke LI. Fournier's gangrene in Ibadan. *Afr J Med Med Sci* 2000; 29:323-324.
- [38] Hasdemir AO, Büyükaşık O, Cöl C. The clinical characteristics of female patients with Fournier's gangrene. *Int Urogynecol J Pelvic Floor Dysfunct.* 2009; 20:1439-1443.
- [39] Omotoso AB, Aderibigbe A. Fournier's gangrene complicated by tetanus: case report. *Orient J Med* 1990; 2: 207-208.
- [40] Schneider PR, Russell RC, Zook EG. Fournier's gangrene of the penis: a report of two cases. *Ann Plast Surg* 1986; 17:87-90.
- [41] Gerber MP, Peterson NE. Scrotal gangrene. *Urology* 1973; 1:466-469.
- [42] Klutke CG, Miles BJ, Obeid E. Unusual presentation of sigmoid diverticulitis as an acute scrotum. *J Urol* 1988; 139:380-381.
- [43] Tripathi FM, Khanna NN, Venkateshwarlu V, Sinha JK. Gangrene of the scrotum: a series of 20 cases. *Br J Plast Surg* 1978; 31:242-243.
- [44] Patel A, Ramsay JW, Whitfield HN. Fournier's gangrene of the scrotum following day care vasectomy. *J R Soc Med* 1991; 84:49-50.
- [45] Baskin LS, Carroll PR, Cattolica EV, McAnninch JW. Necrotising soft tissue infections of the perineum and genitalia. Bacteriology, treatment and risk assessment. *Br J Urol* 1990; 65:524-529.
- [46] Spirnak JP, Resnick MI, Hampel N, Persky L. Fournier's gangrene: report of 20 patients. *J Urol* 1984; 131:289-291.
- [47] Moorthy K, Rao PP, Supe AN. Necrotising perineal infection: a fatal outcome of ischioanal fossa abscesses. *J R Coll Surg Edinb* 2000; 45:281-284.
- [48] Palmer LS, Winter HI, Tolia BM, Reid RE, Laor E. Surgical debridement on survival in Fournier's gangrene. *Br J Urol* 1995; 76: 208-212.
- [49] Laor E, Palmer LS, Tolia BM, Reid RE, Winter HI. Outcome prediction in patients with Fournier's gangrene. *J Urol* 1995; 154:89-92.
- [50] Asci R, Sarikaya S, Buyukalpelli R, Yilmaz AF, Yildiz S. Fournier's gangrene: risk assessment and enzymatic debridement with lyophilized collagenase application. *Eur Urol* 1998; 34: 411-418.
- [51] Villanueva-Saenz E, Martinez Hernandez-Magro P, Valdes Ovalle M, Montes Vega J, Alvarez-Tostado F JF. Experience in management of Fournier's gangrene. *Tech Coloproctol* 2002; 6: 5-13.
- [52] Samad A. Predictive value of modified severity index for Fournier's gangrene. *J Liaquat Uni Med Health Sci* 2007; 6: 16-20.





## **Gangrene - Current Concepts and Management Options**

Edited by Dr. Alexander Vitin

ISBN 978-953-307-386-6

Hard cover, 178 pages

**Publisher** InTech

**Published online** 29, August, 2011

**Published in print edition** August, 2011

Gangrene is the term used to describe the necrosis or death of soft tissue due to obstructed circulation, usually followed by decomposition and putrefaction, a serious, potentially fatal complication. The presented book discusses different aspects of this condition, such as etiology, predisposing factors, demography, pathologic anatomy and mechanisms of development, molecular biology, immunology, microbiology and more. A variety of management strategies, including pharmacological treatment options, surgical and non-surgical solutions and auxiliary methods, are also extensively discussed in the book's chapters. The purpose of the book is not only to provide a reader with an updated information on the discussed problem, but also to give an opportunity for expert opinions exchange and experience sharing. The book contains a collection of 13 articles, contributed by experts, who have conducted a research in the selected area, and also possesses a vast experience in practical management of gangrene and necrosis of different locations.

### **How to reference**

In order to correctly reference this scholarly work, feel free to copy and paste the following:

Ndubuisi Eke and John E. Raphael (2011). Fournier's Gangrene, Gangrene - Current Concepts and Management Options, Dr. Alexander Vitin (Ed.), ISBN: 978-953-307-386-6, InTech, Available from: <http://www.intechopen.com/books/gangrene-current-concepts-and-management-options/fournier-s-gangrene>

**INTECH**  
open science | open minds

### **InTech Europe**

University Campus STeP Ri  
Slavka Krautzeka 83/A  
51000 Rijeka, Croatia  
Phone: +385 (51) 770 447  
Fax: +385 (51) 686 166  
[www.intechopen.com](http://www.intechopen.com)

### **InTech China**

Unit 405, Office Block, Hotel Equatorial Shanghai  
No.65, Yan An Road (West), Shanghai, 200040, China  
中国上海市延安西路65号上海国际贵都大饭店办公楼405单元  
Phone: +86-21-62489820  
Fax: +86-21-62489821

© 2011 The Author(s). Licensee IntechOpen. This chapter is distributed under the terms of the [Creative Commons Attribution-NonCommercial-ShareAlike-3.0 License](https://creativecommons.org/licenses/by-nc-sa/3.0/), which permits use, distribution and reproduction for non-commercial purposes, provided the original is properly cited and derivative works building on this content are distributed under the same license.

IntechOpen

IntechOpen