

We are IntechOpen, the world's leading publisher of Open Access books Built by scientists, for scientists

6,900

Open access books available

186,000

International authors and editors

200M

Downloads

Our authors are among the

154

Countries delivered to

TOP 1%

most cited scientists

12.2%

Contributors from top 500 universities



WEB OF SCIENCE™

Selection of our books indexed in the Book Citation Index
in Web of Science™ Core Collection (BKCI)

Interested in publishing with us?
Contact book.department@intechopen.com

Numbers displayed above are based on latest data collected.
For more information visit www.intechopen.com



Yamamoto New Scalp Acupuncture (YNSA): Development, Principles, Safety, Effectiveness and Clinical Applications

Thomas Schockert
Witten/Herdecke Private University
Germany

1. Introduction

In the nineteen sixties, the Japanese physician and scientist Toshikatsu Yamamoto discovered an independent acupuncture system. Dr. Yamamoto presented this method, which originally consisted of five points, for the first time at a Japanese Ryodoraku Congress in Japan in 1973. For twelve years, using these highly effective points, which he termed basic points, he successfully treated stroke patients suffering from pain and paralysis. Taking second place only to ear acupuncture, YNSA (Yamamoto et al., 2010) is today the most widely and frequently used form of acupuncture and is gaining increasing significance.

Since 1973, in addition to the basic points, several other points have been discovered namely sensory point, brain points, Y points, extra points, treatment points on the thorax and in the region of the pubic bone, dorsal treatment points and additional peripheral points as well as various diagnostic points. Hardly any other acupuncture system can be described as so fertile since Dr. Yamamoto is untiring in his search for new methods of treatment, points and somatopes in his daily work. In Japan, acupuncture was largely practised by masseurs, which meant that it was not highly regarded in classical medicine nor, in particular, at university medical schools. Interest in and receptiveness to acupuncture is gradually increasing, also at some Japanese universities. YNSA has been the subject of numerous studies and publications. YNSA is also used very successfully in veterinary medicine, for example to treat cats and dogs. A number of research projects and publications on YNSA are eagerly awaited in the near future.

2. Principles of YNSA

The basic points are still used successfully in daily practice. Acupuncture needles are applied ipsilaterally at these basic points for pain therapy while for the treatment of central paresis they are applied contralaterally to the paretic side.

YNSA is a special form of traditional acupuncture. The method is based on a somatotope on the scalp. In the same way as with ear or mouth acupuncture, the entire organism is projected here on a defined area of the scalp. The locomotor system is at the boundary of the forehead and hair, whereas the internal organs are represented via Ypsilon points on both temples. Scalp acupuncture distinguishes a yin somatotope at the front of the scalp and a yang

somatotope at the back of the scalp. With the aid of the special Japanese neck diagnostics, the associated Ypsilon therapy points in the temples or the corresponding cranial nerve points are revealed via pressure-sensitive points in the neck region. As a representative of each meridian, there is a pressure point on the neck and an associated treatment point in the region of the temples. If, for example, the kidney point on the neck is sensitive to pressure the needle is applied to the corresponding Ypsilon point in the temple. If the needle has been correctly positioned in the temple region then the pressure sensitivity in the neck disappears consecutively and thus provides immediate verification for correct positioning of the needle.

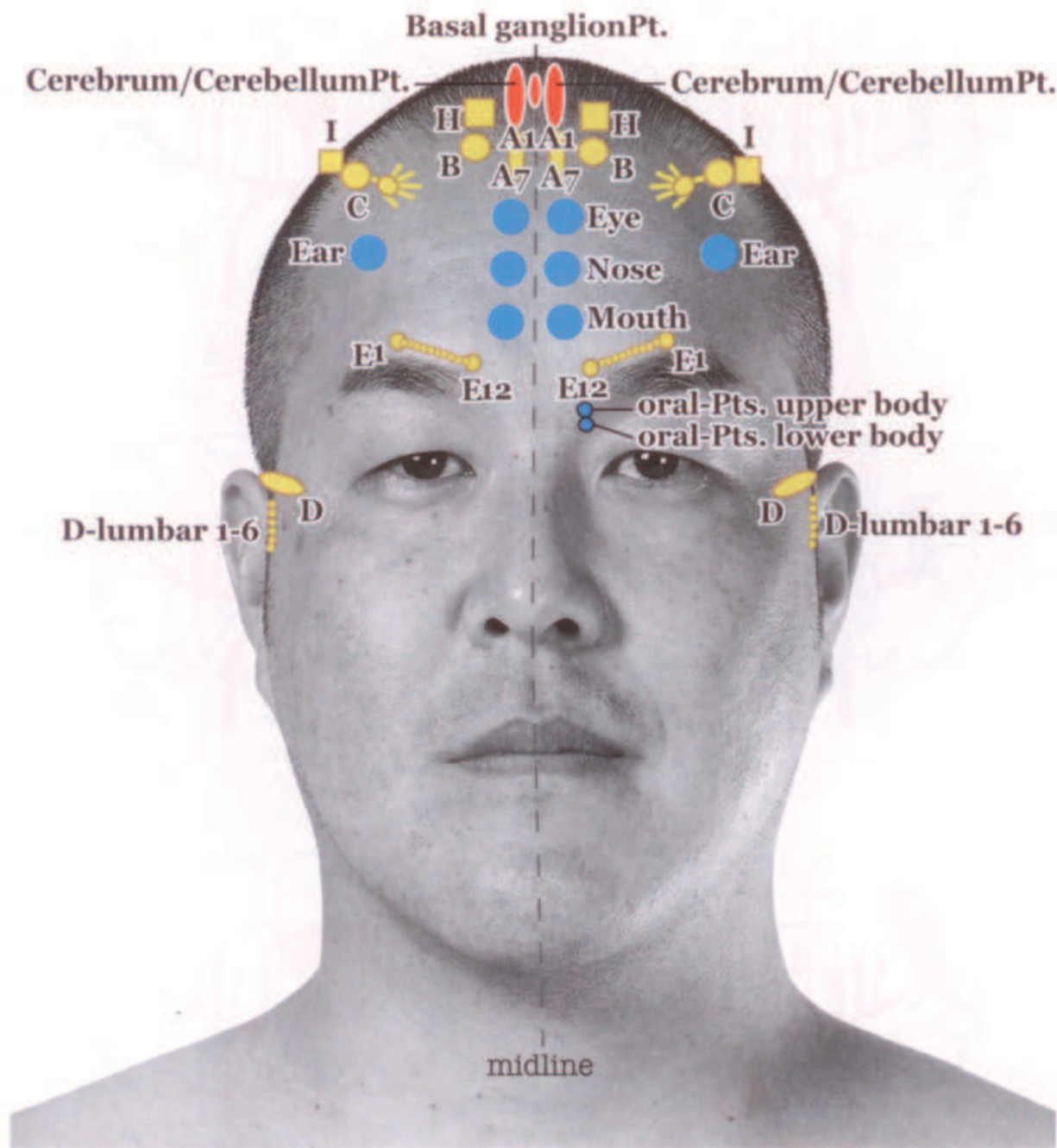


Fig. 1. Schematic representation of the frontal YNSA basic points. Needles are applied ipsilaterally for the treatment of pain and contralaterally for the treatment of paralysis.

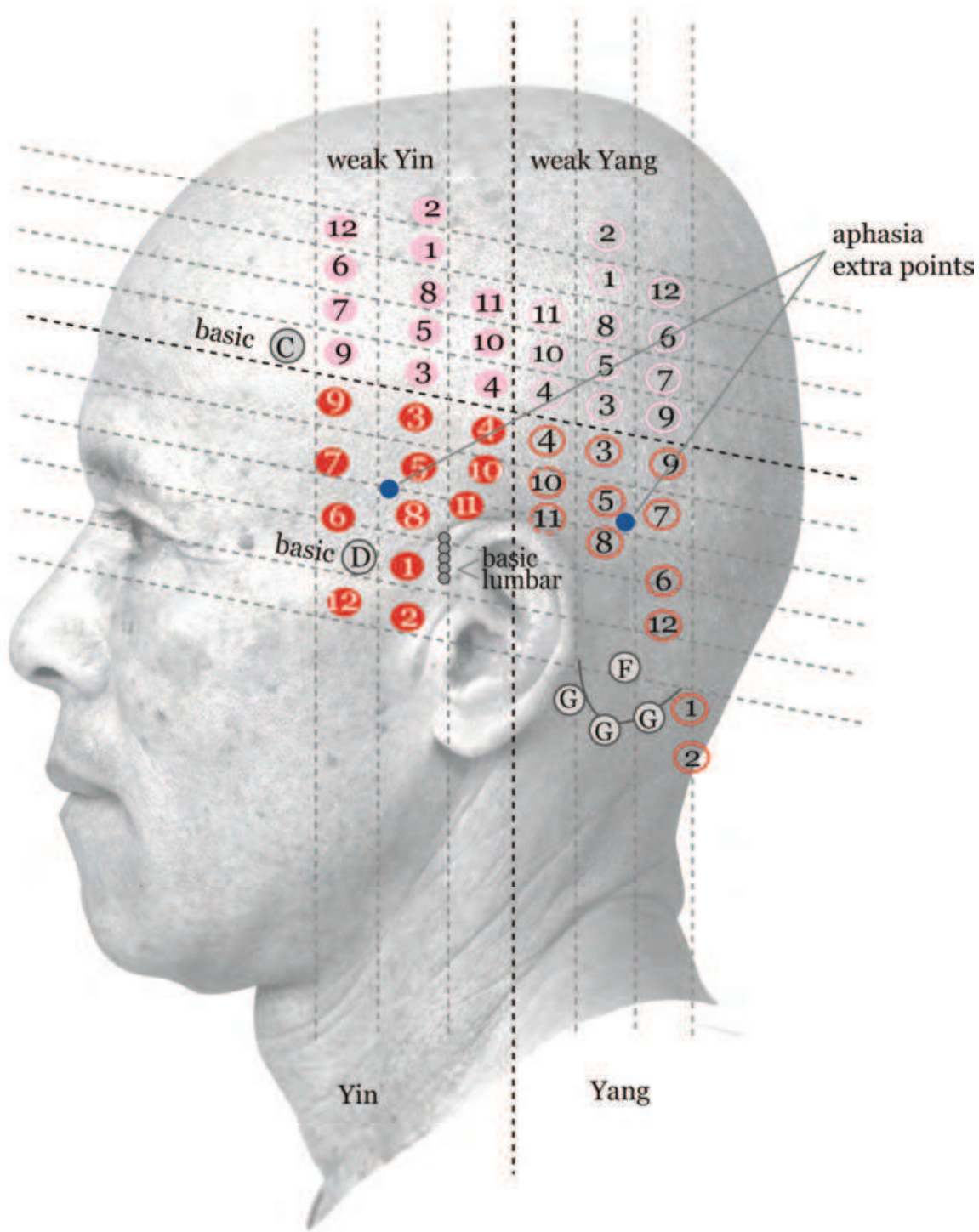


Fig. 2. Ypsilon points. Abdominal or neck diagnosis leads to the selection of the Ypsilon points in a treatment session

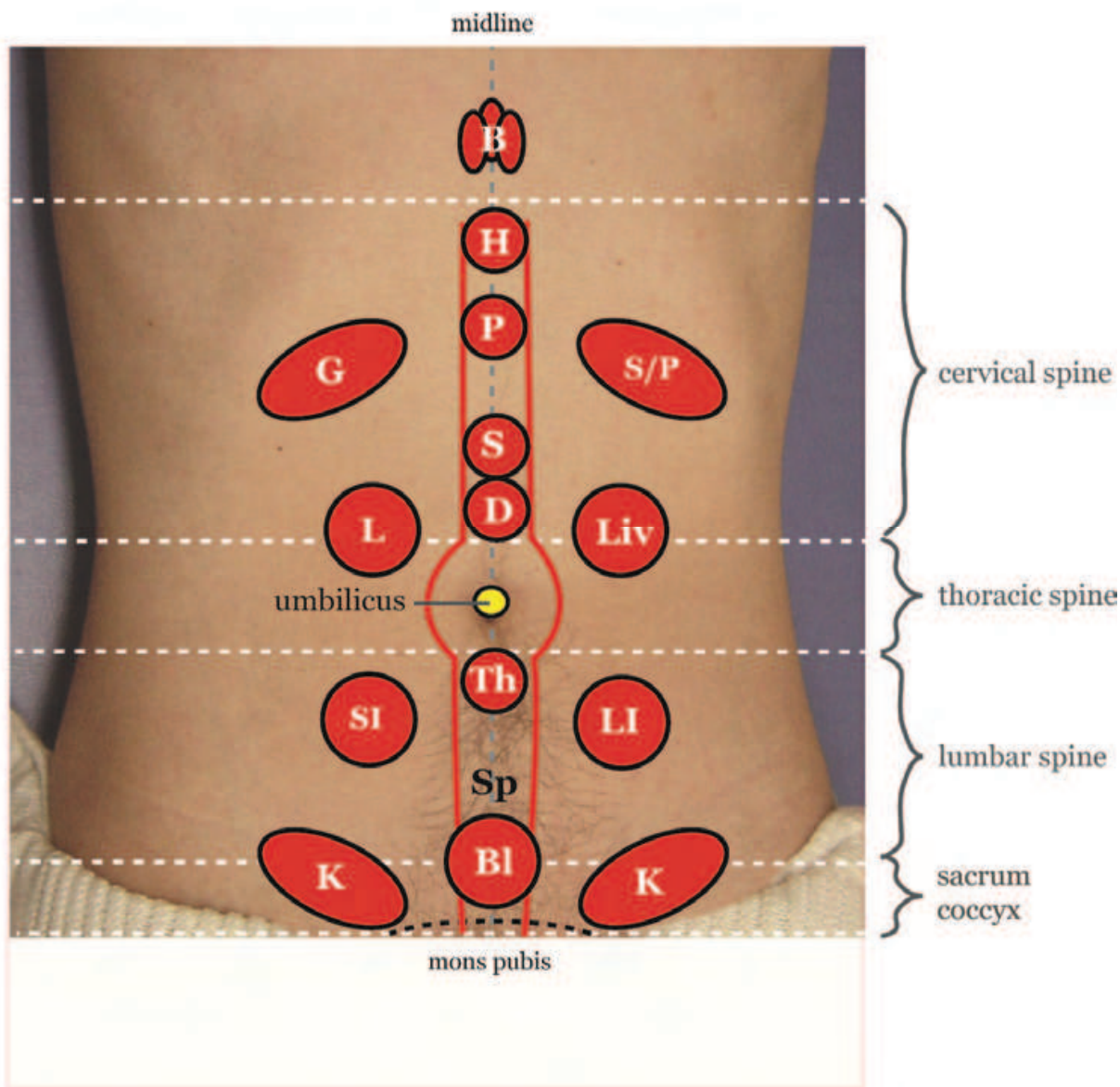


Fig. 3. The abdominal diagnosis leads to the Ypsilon or cranial nerve points

In contrast to the pulse and tongue diagnosis of traditional Chinese medicine, Yamamoto New Scalp Acupuncture (YNSA) is characterized by the special feature abdominal wall and neck diagnostics. These diagnostic procedures enable the acupuncture points to be identified individually in each treatment situation indicating where the needles are to be applied for each individual person in the respective treatment situation. When the needle is correctly positioned, the sensitivity to pressure felt by the physician and patient disappears. This check makes it possible to discover whether the needle is correctly positioned. It is important to investigate the diagnostic points on the arm and neck by shifting the pressure to the side. In doing so, the points are palpated with the tip of the thumb. Applying pressure solely to the points may falsify the results of the examination. In the case of abdominal wall diagnostics, the examination is performed by palpation using the index, middle and ring fingers with gently circling movements.

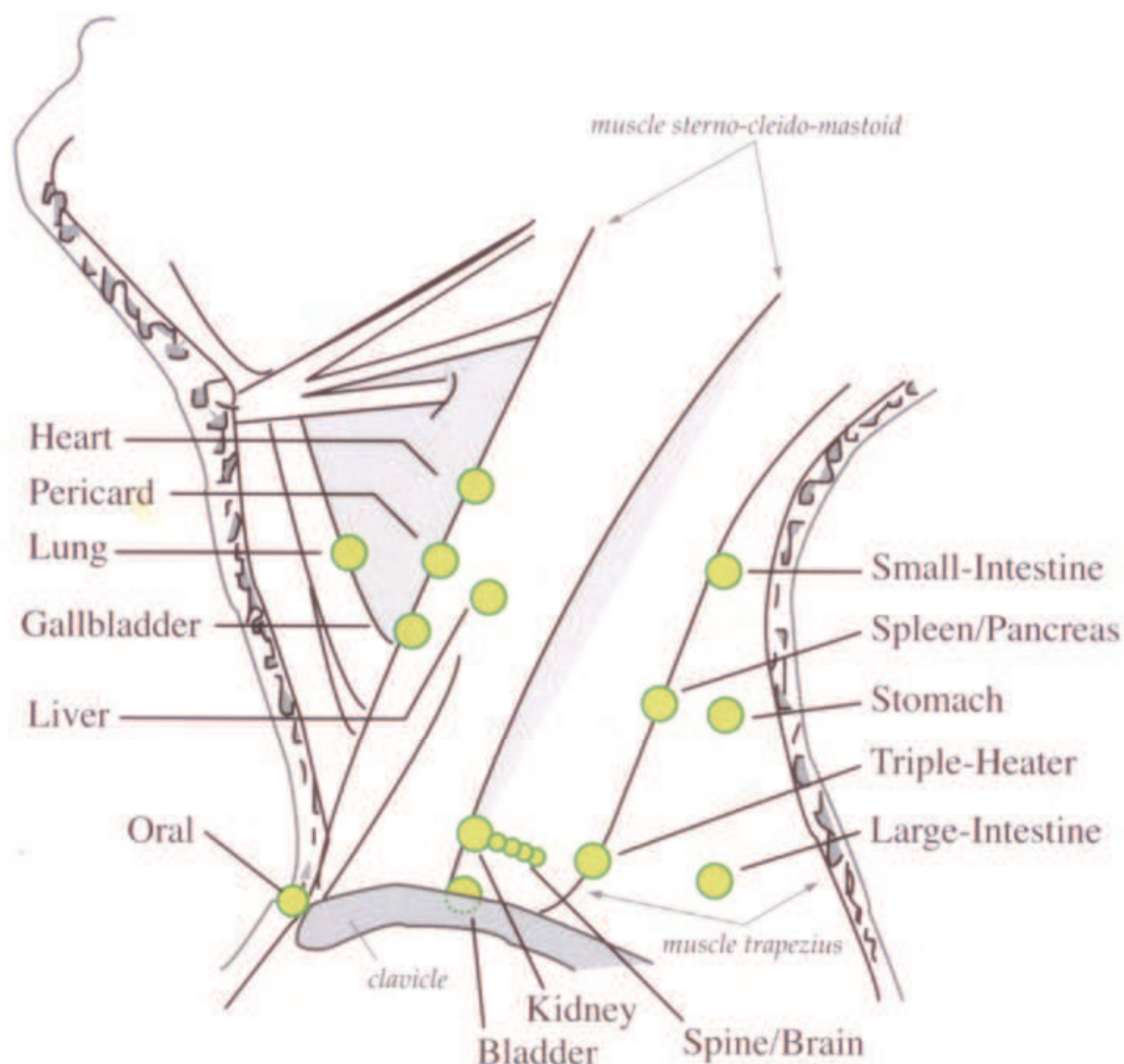


Fig. 4. Neck diagnosis is used to find the treatment points of the patient

2.1 Relevance of the YNSA cranial nerve points

The cranial nerve points are highly active acupuncture points on the frontal scalp. Using these points, disorders of the corresponding meridians and the cranial nerves can be treated. For example, the lung cranial nerve point, the glossopharyngeal point is used for the treatment of the swallowing disorders after stroke as well as pulmonary disorders of different origin. Based on the YNSA-Yin basic point A, 12 cranial nerve points are located in a row in the dorsal direction up to DuMai20 for approximately 6-8 cm. For the practical use, the cranial nerve points are identified by the abdominal or neck palpation technique. The painful abdominal or neck points show the way to the corresponding cranial nerve points. After correct acupuncture of the relevant cranial nerve points, the pain intensity of the abdominal or neck sites should be reduced, similar to the Ypsylon points. Similar to the other YNSA points, the cranial nerve points display small treatment areas, which are

identified using careful palpitation. Acupuncture is then performed at the point with the highest pain intensity. Similar to the basic, brain and Ypsilon points, a careful palpitation is necessary and important for the localization of the cranial nerve points. The known Ypsilon and cranial nerve points can be used alone and in combination. It is important that the treated acupuncture point is reported as painful by the patient. A site which is not painful should not be treated. The cranial nerve points have shown to be very suitable for treatment of motor and other neurological symptoms.

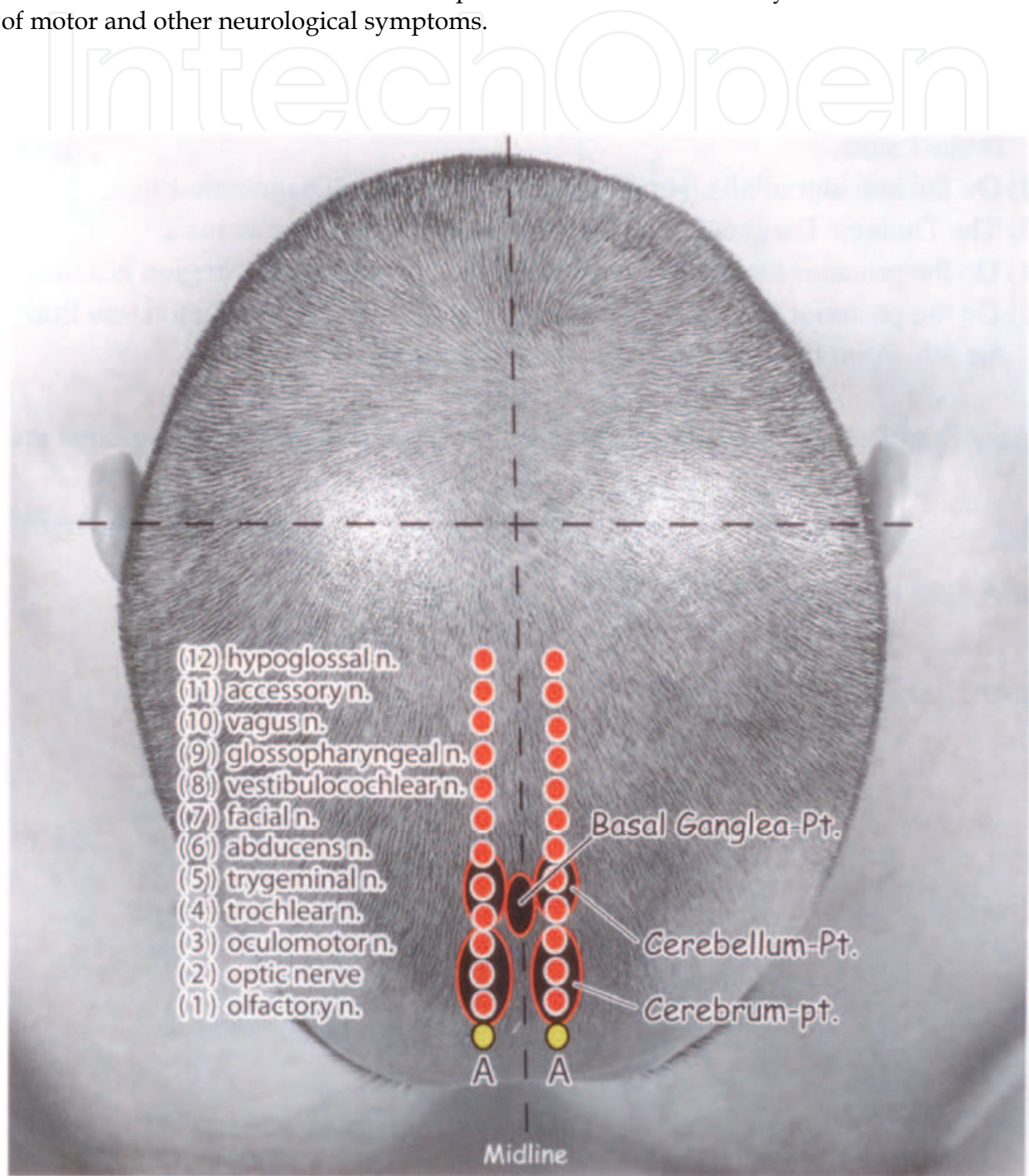


Fig. 5. The cranial nerve points and brain points with Yin-basic-point A

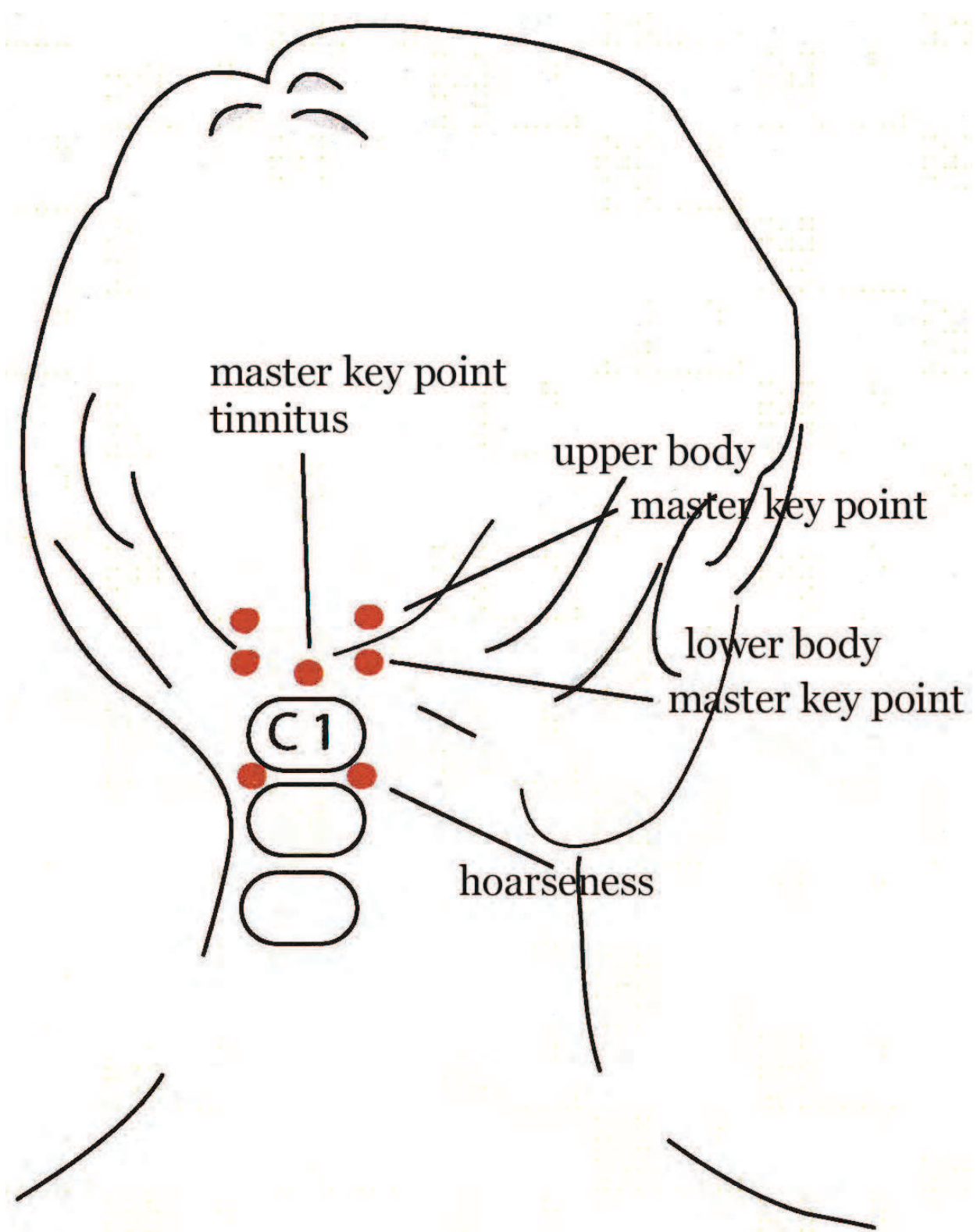


Fig. 6. Master key points for tinnitus, upper and lower body with hoarseness points

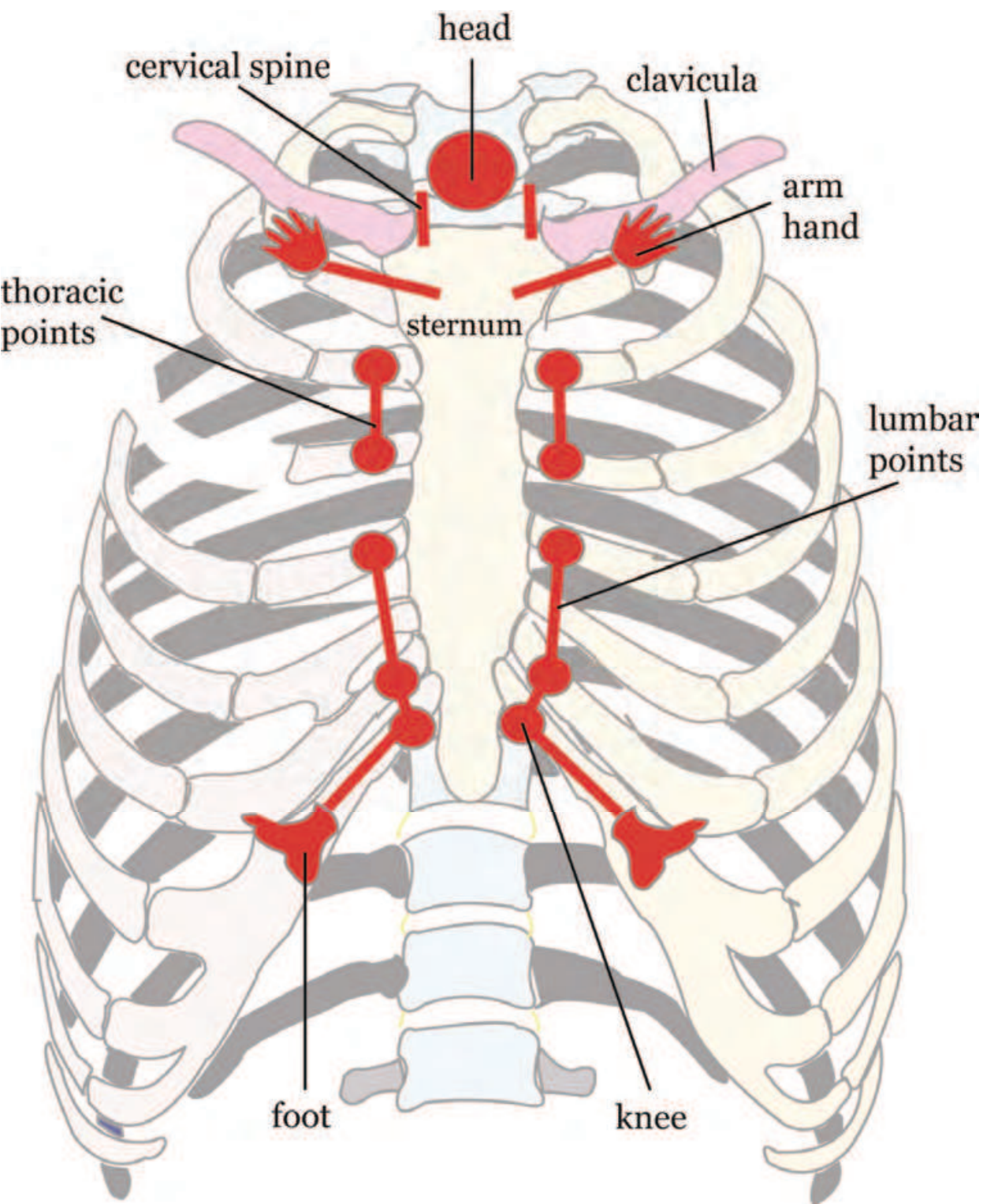


Fig. 7. Yamamoto New Chest Acupuncture

In the Yamamoto New Chest Acupuncture pain is treated ipsilaterally, hemiparesis contralaterally. Very effective is especially the treatment of disturbances of the locomotor system.

3. On the safety of acupuncture in the Thoracic region

Numerous references to side effects caused by acupuncture treatment can be found in medline. The investigation presented here was motivated in particular by reports of pneumothorax after acupuncture. After an autopsy on a corpse, the depth of various acupuncture needles penetrated into the thorax was investigated. The study was performed on a female corpse. For unknown reasons, the patient had been subjected to resuscitation and due to this measure had suffered a series of fractured ribs on the right-hand side. Issue investigated: Is it possible to apply acupuncture treatment safely in the thoracic region, in particular intercostally? Observations: Acupuncture in the thoracic region involves a greater or lesser degree of risk depending on the thickness of the subcutaneous fatty tissue. The longer the needle, the greater is the risk. In view of the fact that in some places the intercostals muscles are only 2 to 3 mm thick, the ribs themselves in the present case are 3 to 4 mm thick and the skin is 1 to 2 mm thick, in the case of a slim or cachectic person an acupuncture needle 1 cm in length can potentially lead to pneumothorax if applied intercostally. In order to ensure the greatest possible safety in acupuncture, it is necessary to choose needles that are as short and thin as possible and to apply them tangentially at the flattest possible angle. Additional safety can be achieved by moving the tip of the needle towards the rib or corpus sterni. If, as for example in the case of thoracic Yamamoto New Chest Acupuncture, the needles are to remain in position in the patient so that further physiotherapy measures can be applied, then they must be secured by a good adhesive plaster. It appears safest to apply the needles above the ribs and only above the xiphoid process, the corpus and manubrium sterni.

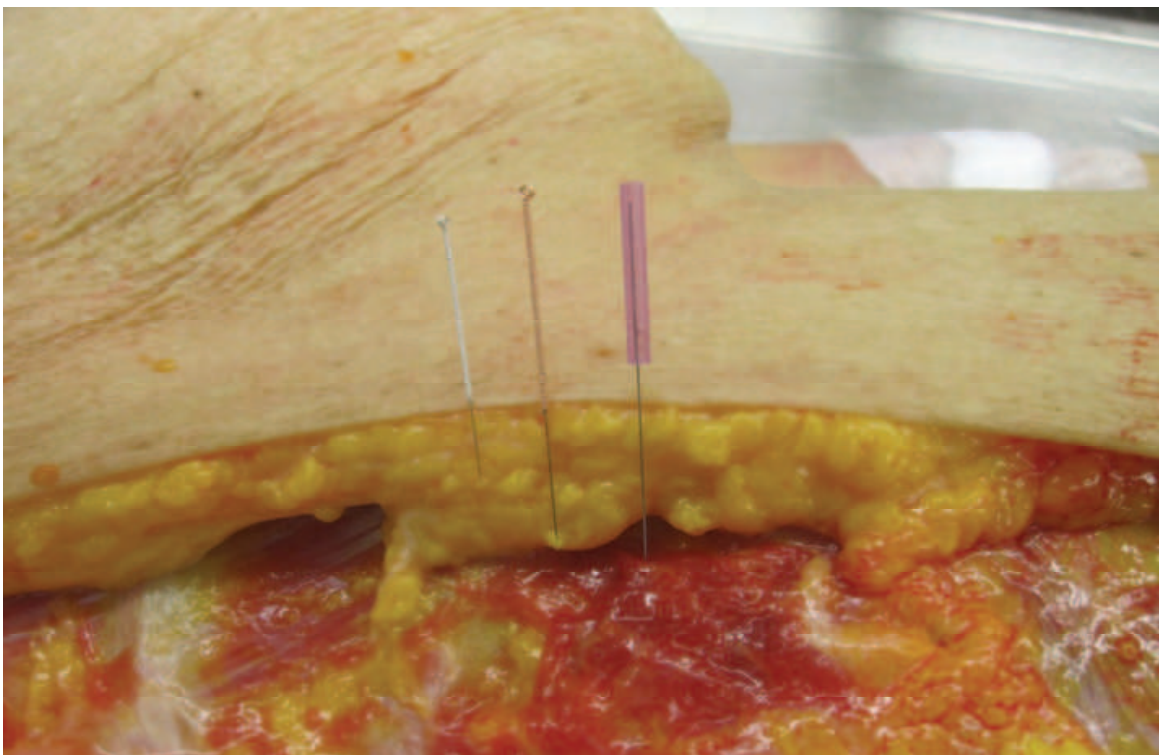


Fig. 8. Acupuncture needles of various lengths. In comparison: The depth of penetration into the subcutaneous fatty tissue can be seen. Penetration depth of the needles with respective lengths of 10, 15 and 25 mm in relation to skin and subcutaneous tissue.

Conclusions: The safety of acupuncture in the front thoracic region depends on the length of the needle and the angle at which the needle is inserted. The greatest possible safety can be achieved by applying short, thin needles above the ribs or towards the ribs or the corpus sterni.

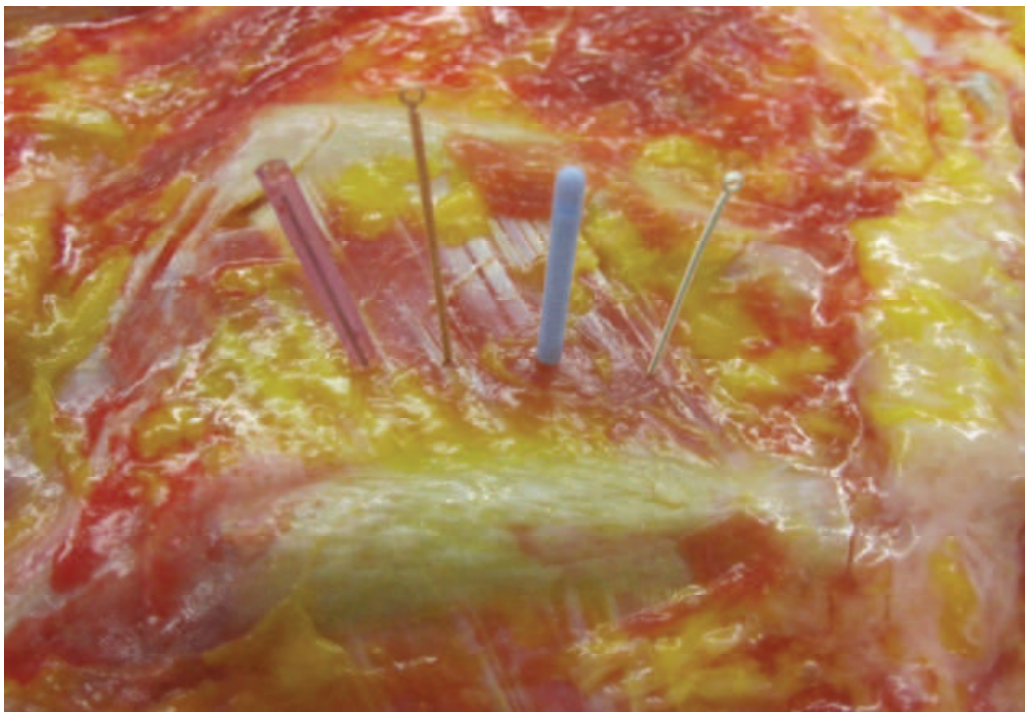


Fig. 9. Intercostal acupuncture with 4 different types and lengths of needles

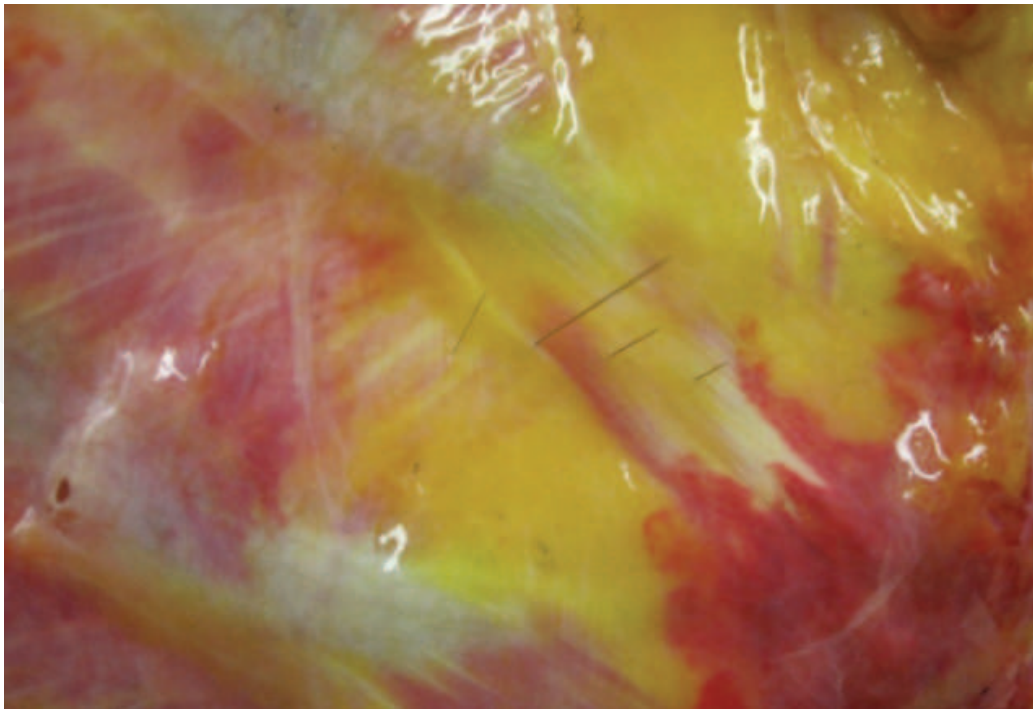


Fig. 10. These acupuncture needles penetrating through the intercostal muscles and into the thorax.

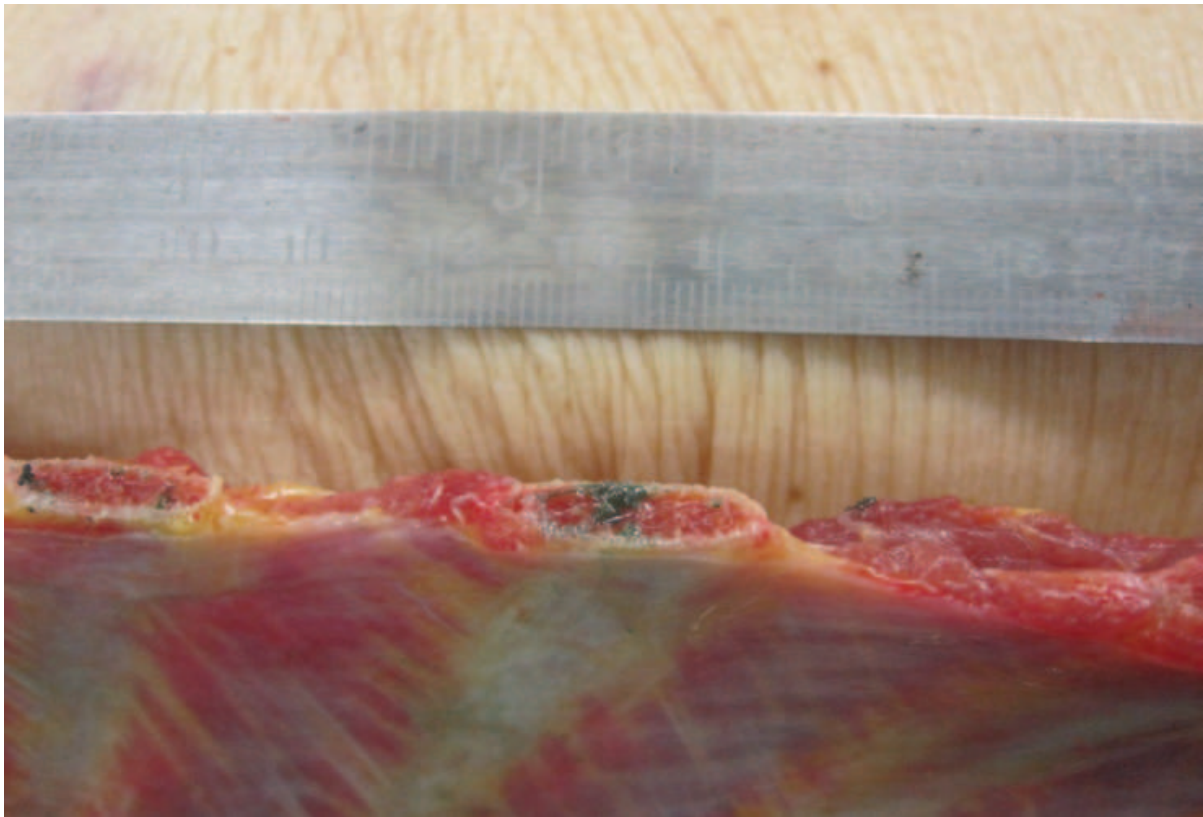


Fig. 11. The thickness of the ribs and the intercostal muscles

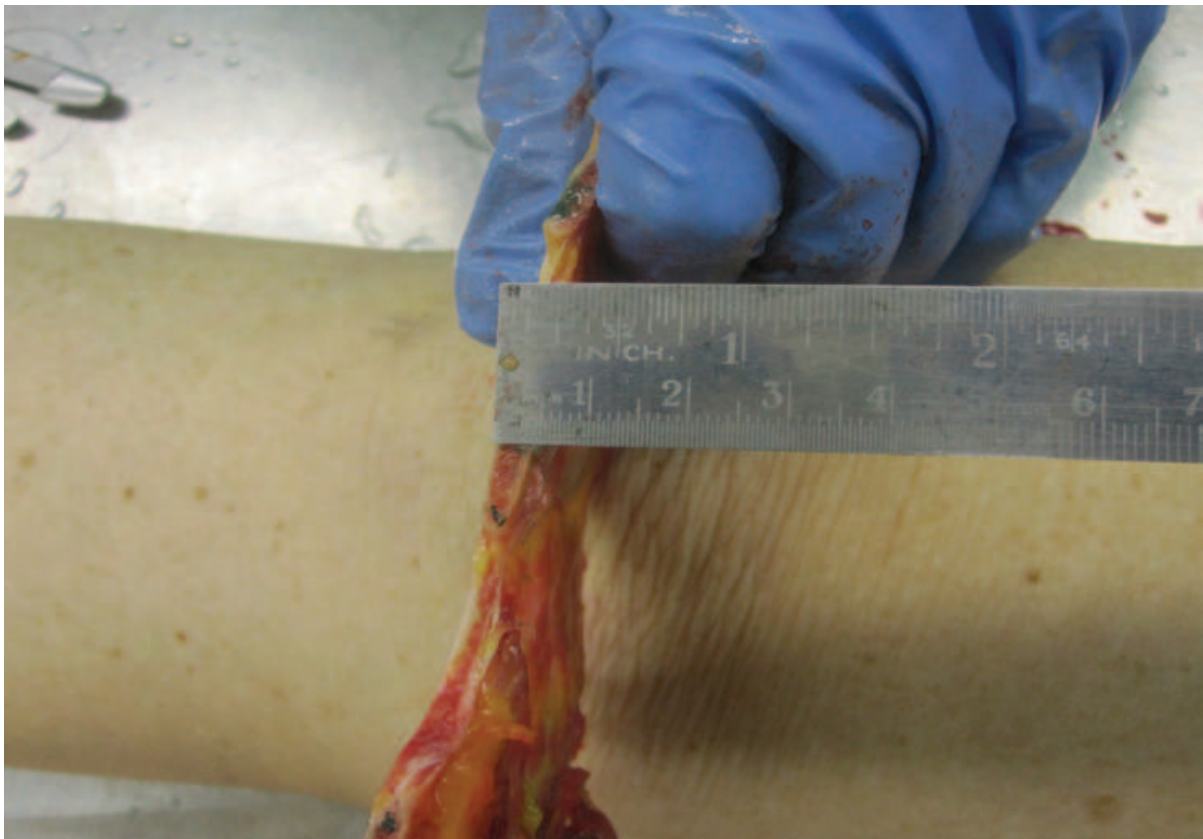


Fig. 12 The rib is 4 mm thick

4. Effectiveness and clinical applications

4.1 Functional Magnetic Resonance Imaging (fMRI)

With the aid of functional magnetic resonance imaging (fMRI), it was possible to demonstrate the good effectiveness of YNSA for stroke patients. In this study, a new metal-free acupuncture needle developed by the author was applied. Benefits associated with YNSA have been shown in studies in patients after stroke, in patients with musculoskeletal pain and in emergency medicine. In the Western world stroke is still the leading cause of disability in adults, often in the form of hemiparesis. The goal of the investigation introduced here was to correlate the effect of YNSA in hemiparetic stroke patients to cortical activation visualized in fMRI. The neurological correlates of YNSA were studied in 17 patients with ischaemic stroke in the right hemisphere suffering from residual paresis of the left hand and in 19 healthy volunteers. A new acupuncture needle for magnetic resonance imaging developed by Schockert was used in this study. Similar to the principle of an indwelling venous cannula, the needle is positioned in the acupoint, the steel cylinder removed, and the remaining plastic part is fixed in the acupoint by a plaster. The size of the plastic part remaining in the acupoint corresponds approximately to an acupuncture needle of the dimensions 0.30 x 30 mm (Schockert et al., 2010).

According to the ethical vote all participants have signed a consent before the treatment.

The fMRI study was performed in a 1.5 tesla Philips MRI system (TR 3000 ms, TE 50 ms, FA 90 °) in a box-car design. Patients were treated lying down and were instructed via video goggles to open or close their left hand. The fMRI paradigm was: five conditions with 120 sec duration each: 3sec closing of the fist, 2sec opening of the fist, 30 sec break. Three runs of fMRI were performed: no acupuncture, sham acupuncture (patient is blinded: acupressure without insertion of a needle), real acupuncture. The data were analyzed using an SPM2 evaluation program. All patients and volunteers were first subjected to sham acupuncture and then to YNSA. The sham acupuncture consisted of a single application of pressure by a finger nail in the centre of an imaginary line between TE23 and GB14. In the genuine YNSA, needles were applied to the Yin points of the Basal Ganglia, Cerebellum, and Basic point C. Of the 17 investigated patients, only five could be evaluated due to motion artefacts. On account of inhomogeneous lesions no group analysis was performed as cortical activation was different in each patient. Generally, in contrast to the sham acupuncture, genuine acupuncture was accompanied by significant cortical activation in the motor, premotor and supplemental motor cortex.

Eight of 17 patients felt subjectively better after the YNSA. The patients experienced a reduction of spasm and an improvement of the movement of the paralysed upper extremities. The 5 patients from whom the data were evaluated all showed subjectively clinical benefit after the YNSA treatment. Data from 13 healthy volunteers could be analysed without artefacts. In these subjects it was possible to perform a group analysis. In contrast to the patients, the volunteers displayed a decrease in cortical activation during YNSA. Without acupuncture: Cortical activation was shown in the motor cortex, cingulate gyrus and occipital lobe. Sham acupuncture: Cortical activation identical to that in subjects without acupuncture. Genuine acupuncture: No activation in the cingulate gyrus. The cingulate gyrus is part of the limbic system, a multimodal area with important afferent and efferent connections which is involved in planning of complex and difficult movements. Theoretically, a lack of activation in the cingulate gyrus could be a training effect or the result of selective inhibition of this area by

YNSA. Without acupuncture or with sham acupuncture cortical activation was observed close to the region of the vertex of the scalp, where GV20 is situated. This activation is not seen after genuine acupuncture. So it is conceivable that this is a specific YNSA effect. The effects look promising but could be the result of generalised stimulation. The reliability of the data analysis must also be verified. The design of the study shows methodological deficits. For studies in the future the documentation has to be done even more thoroughly with objective methods of measurement. The following practical problems were seen during the conduct of this study: Patients were lying down still in the scanner for about one hour. This was very tiring and difficult for the patients. In addition, it is conceivable that patients had major concentration problems during the third block (genuine acupuncture). We assume the results of this study could potentially support the use of YNSA as an adjunctive measure in stroke rehabilitation. In view of the fact that eight patients felt subjectively better after the treatment and in view of the changes in the cortical activations in the motor, premotor and supplemental motor cortex we assume that this benefit justifies the hypothesis that the YNSA treatment itself had this positive influence and is the cause of the positive effects described by the patients. As stroke is the leading cause of disability in the western world we assume that it is justified to suggest further larger controlled clinical trials and fMRI studies with more participants to investigate the phenomenon we have seen in this investigation (Schockert et al., 2010).

4.2 YNSA in PET-CT

4.2.1 YNSA activates cortical nociceptive and motor centers in patients with chronic pain of the locomotory system

The clinical application of Yamamoto New Scalp Acupuncture (YNSA) often shows immediate and long lasting effects in patients with locomotor disturbances such as pain syndromes, chronic stroke and Parkinson's disease. However, little is known about the underlying mechanisms of YNSA.

The aim of the study was to investigate potential areas of the central nervous system influenced by YNSA in the treatment of such patients. To this end, changes in the cerebral glucose metabolism were measured by PET-CT. We measured three subjects that were treated with YNSA for chronic pain syndromes in their lower extremities. Each patient was measured twice. The first measurement served as a baseline scan to assess the basic brain activity of the patient. The second measurement was acquired four to five days later, and the patient was treated with YNSA shortly before the beginning of the scan. Points were selected individually after YNSA neck diagnosis. A visual analogue scale (0-10) was used to assess pain reduction. Each subject's PET data were spatially coregistered to correct for differences in head position between the two scans. Consequently, the data were normalized to a template brain and smoothed with a 12 mm isotropic kernel in order to account for anatomical differences between the subjects. Finally, demeaning was applied to correct for global changes of signal intensity. All these steps were carried out using SPM 8 (Wellcome Trust Center for Neuroimaging, London) and FSL 4.1 (FMRIB, Oxford), respectively. After these pre-processing steps, data from the two measurements could be directly compared to each other. An increase in glucose metabolism (and thus of cortical activity) of more than 10% was considered significant. An average pain reduction of 4.4 ± 2.7 points was achieved with YNSA. PET data showed increased activity in the following cortical and subcortical areas: thalamus, lateral frontal- und dorsolateral prefrontal cortex (DLPFC), insula, medial and ventromedial prefrontal cortex, posterior cingulate cortex (PCC), cerebellum, basal ganglia and periaqueductal grey (PAG).

The reported activations could all be assigned to either the nociceptive (thalamus, insula, DLPFC, PAG), motor (cerebellum, basal ganglia) or attention networks (PCC, lateral frontal cortices). As changes in the level of attention were not monitored in this study, they cannot be ruled out. Thus we do not consider the observed activations in the attention network (PCC, lateral frontal cortices) a direct effect of YNSA. The average reduction in pain scale score and corresponding change in nociception system activation can be considered a direct effect of acupuncture. As VAS values were lower under YNSA as compared to baseline, these activations cannot simply be a result of the painful needle manipulation. The activation of the motor system, especially in the basal ganglia, offers a possible explanation for the efficacy of YNSA in general locomotor disorders. In this context, it is interesting to note that the YNSA point “basal ganglia” was used for treatment in two of the three subjects.

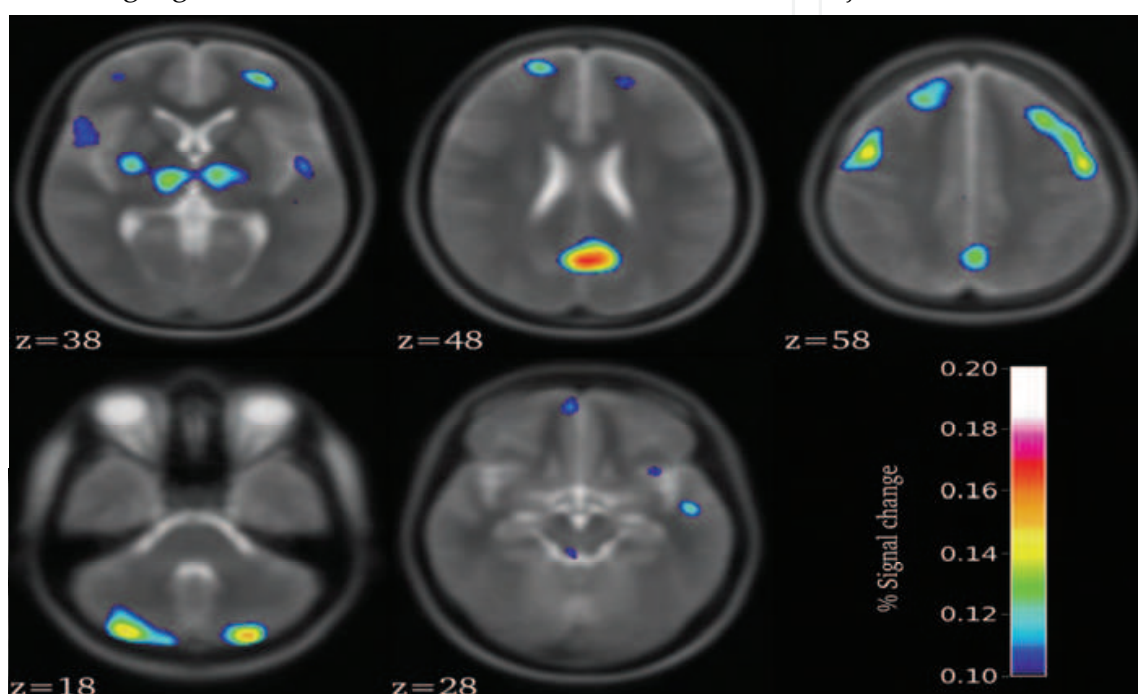


Fig. 13. Group results of the PET measurement. Contrast: Scan with YNSA needles in place > Baseline scan. Only signal changes of 10% and more are shown.

4.3 YNSA in emergency medicine

Due to the good effectiveness of YNSA, especially since YNSA takes effect very rapidly, I would like to propose that YNSA and other acupuncture methods could be applied as supportive measures both in emergency medicine and by the emergency services. YNSA has already been successfully employed by the emergency services. Acupuncture has also been used in military applications. There is thus an urgent need for further extensive studies on the application of acupuncture by the emergency services (Chen et al., 2010).

4.3.1 YNSA in emergency medicine – a case report

Various acupuncture methods are successfully applied in emergency medicine throughout the world and have also been studied scientifically. I myself regularly apply acupuncture in my daily practice and in emergency medical work. In the case history described here, I would like to present YNSA and show that I have employed YNSA to support emergency medical measures during pregnancy. The patient herself described YNSA as extremely

effective and soothing. On 23 April 2007, an emergency call was passed on to the rescue vehicle from the control centre at 19:15 concerning a pregnant patient who was experiencing severe back pain, dyspnoea and pain in the thorax. In a thorough physical examination of the 41-year-old patient an auscultation revealed that all sections of the lungs were free without any rattling noise or spasticity, after the immediate administration of oxygen the oxygen saturation was 99 %, blood pressure was 150/90 and pulse 100. An ECG did not show any pathological abnormalities. After a venous cannula had been inserted into the bend of the left arm and lactated Ringer's solution had been administered to the patient, a decision was taken to apply Yamamoto New Scalp Acupuncture as an analgesic. Upon closer questioning, the patient said that she had severe thoracic and back pain, and that the back pain, which did not radiate into the legs, was the most problematic for her. She said she had not felt well all day, but she did not want to take any painkillers. The patient agreed to be treated by acupuncture as pain therapy. According to the current procedures for YNSA, a neck diagnosis was first applied. The neck diagnosis led to the identification of the correct acupuncture points for this patient. The following 8 points were applied: basic points A right and left, basic points D and E right, parietally situated Y point kidney and brain points cerebrum, cerebellum and basalganglia. All needles have been inserted for about 5 millimeters into the scalp. Then the pressure sensitivity in the neck disappeared. There has been no stimulation or rotation of the needles in this treatment. The patient had already been treated by acupuncture on previous occasions and also experienced rapid relief of her symptoms by the scalp acupuncture applied under emergency conditions. Upon arrival in hospital, the patient had a complete relief from her symptoms.

In his book on acupuncture in emergency medicine that appeared in 1994, Richard Umlauf describes the points for body acupuncture and the points of various microsystems for their use in difficult and life-threatening illnesses. He considers these methods very efficacious and recommends their application. Acupuncture could be of great benefit in emergency medicine, especially for analgesic purposes since acupuncture may also be regarded as evidence-based medicine. Since the GERAC study this is particularly true of the treatment of knee and back pain. Although acupuncture research is under way throughout the world and acupuncture is also used in the emergency services, acupuncture cannot yet be described as evidence-based emergency medicine (EBEM). Like many other measures in complementary medicine, acupuncture offers a valuable, efficient and reliable adjuvant therapy option for all existing orthodox emergency treatments. Both for ethical and quite particularly for cost-saving reasons, the application of acupuncture and complementary medicine could also establish a permanent place in emergency medicine. Larger clinical trials are warranted to investigate the YNSA effects in emergency patients. In recent years, I have applied YNSA as a supportive measure or as a sole therapy for the relief of pain in a wide range of cases, for example acute renal colic and also for dyspnoea caused by asthma, in the emergency rescue service and also for emergency public health services. YNSA makes it possible to provide efficient therapy by applying needles to just a few points. The international literature describes a wide range of applications of various forms of acupuncture – also including acupressure – for use in emergency medicine, but also side effects due to body acupuncture that has not been applied correctly. As yet there are no articles on YNSA for emergency medicine in the international literature. I would like to encourage a discussion on increasingly including YNSA and other acupuncture methods in emergency public health services and also in emergency medical services as a complement to and in support of orthodox medicine. This will require extensive studies on the application of acupuncture by the emergency services. I hope for the sake of all affected emergency patients that acupuncture will be increasingly applied as an adjuvant and supportive method in the emergency services.

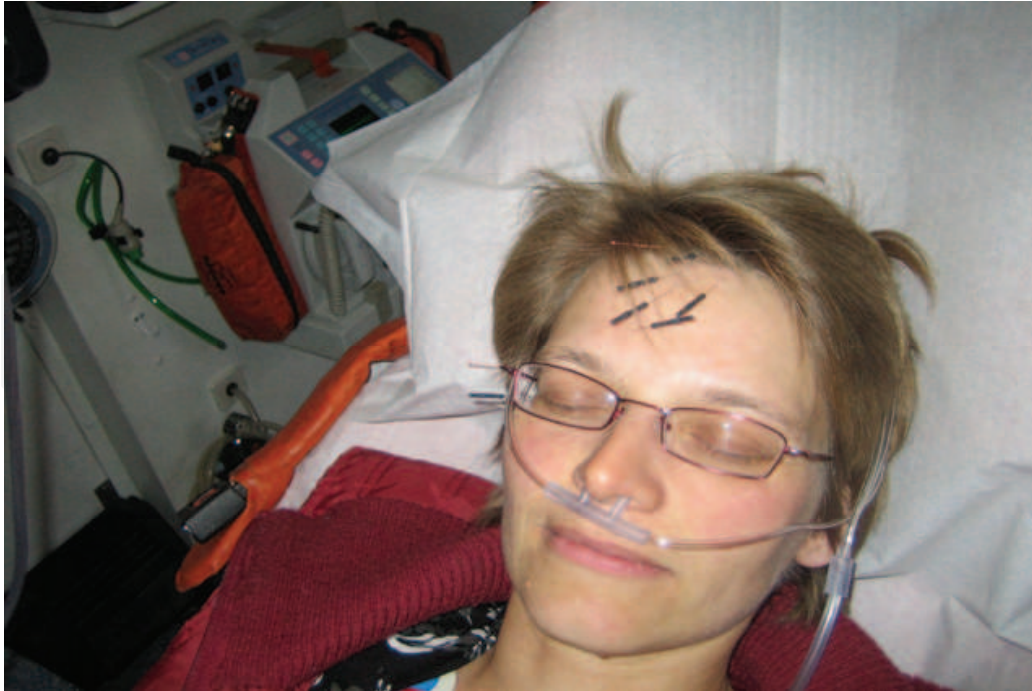

Fig. 14. Patient ready for transport: patient treated by ECG, oxygen and YNSA. The patient experienced relief from all symptoms after treatment with just 8 needles.

5. Conclusion


Working with YNSA is very encouraging and satisfying due to the frequently occurring immediate effects and lightning effects. YNSA finds widespread acceptance amongst patients.

6. Acknowledgment

Dr. Toshikatsu Yamamoto, I thank you very much for teaching me your YNSA.

7. References

- Yamamoto T, Yamamoto H, Yamamoto MM. (2010) Yamamoto New Scalp Acupuncture, YNSA. Yamamoto Publishing Inc. Miyazaki, Japan
- Chen Y-L, Hou MC, Huang S-Y, Schockert T. Yamamoto New Scalp Acupuncture (YNSA) Use in Emergency Medicine. Journal of Chinese Medical Association of Acupuncture Taiwan 2010;13,2:1-8
- Schockert T. Integration of Yamamoto New Scalp Acupuncture (YNSA) into emergency medicine. Deutsch Zeitschr f Akup 2010;4,34-37
- Schockert T, Beissner F. Neurophysiological Correlates of the Effect of YNSA for Patients with Chronic Pain of the Locomotor System - Basic YNSA Research by Means of PET-CT. Deutsch Ztschr f Akup. 2010;2:8-13
- Schockert T, Schnitker R, Boroojerdi B, Vietzke K, Qua Smith I, Yamamoto T, Kastrau F. Cortical Activation by Yamamoto New Scalp Acupuncture (YNSA) in the Treatment of Stroke Patients - A Sham-controlled Study Using Functional Magnetic Resonance Imaging (fMRI). Acupunct Med 2010;4:212-4



Acupuncture - Clinical Practice, Particular Techniques and Special Issues

Edited by Prof. Marcelo Saad

ISBN 978-953-307-630-0

Hard cover, 138 pages

Publisher InTech

Published online 06, September, 2011

Published in print edition September, 2011

Acupuncture is growing in popularity world-wide. Acupuncture and related techniques are useful tools for treating a spectrum of diseases. However, there are still many areas of controversy connected to it due to the fact that mechanisms of action of acupuncture are not entirely clear. Another debilitating element is the absence of a convincing model of sham acupuncture for a control group in clinical trials. Therefore, there are still inappropriate prejudice and unfamiliarity regarding acupuncture. I hope this book can contribute to guide the advance of this ancient medical art. The reader will here find texts wrote by authors from different parts of the world. The chapters cover strategic areas to collaborate with the consolidation of the knowledge in acupuncture. The main objective is to share elements to make acupuncture more and better offered at health systems worldwide.

How to reference

In order to correctly reference this scholarly work, feel free to copy and paste the following:

Thomas Schockert (2011). Yamamoto New Scalp Acupuncture (YNSA): Development, Principles, Safety, Effectiveness and Clinical Applications, Acupuncture - Clinical Practice, Particular Techniques and Special Issues, Prof. Marcelo Saad (Ed.), ISBN: 978-953-307-630-0, InTech, Available from:
<http://www.intechopen.com/books/acupuncture-clinical-practice-particular-techniques-and-special-issues/yamamoto-new-scalp-acupuncture-ynsa-development-principles-safety-effectiveness-and-clinical-applica>

INTech
open science | open minds

InTech Europe

University Campus STeP Ri
Slavka Krautzeka 83/A
51000 Rijeka, Croatia
Phone: +385 (51) 770 447
Fax: +385 (51) 686 166
www.intechopen.com

InTech China

Unit 405, Office Block, Hotel Equatorial Shanghai
No.65, Yan An Road (West), Shanghai, 200040, China
中国上海市延安西路65号上海国际贵都大饭店办公楼405单元
Phone: +86-21-62489820
Fax: +86-21-62489821

© 2011 The Author(s). Licensee IntechOpen. This chapter is distributed under the terms of the [Creative Commons Attribution-NonCommercial-ShareAlike-3.0 License](https://creativecommons.org/licenses/by-nc-sa/3.0/), which permits use, distribution and reproduction for non-commercial purposes, provided the original is properly cited and derivative works building on this content are distributed under the same license.

IntechOpen

IntechOpen