

We are IntechOpen, the world's leading publisher of Open Access books Built by scientists, for scientists

6,900

Open access books available

186,000

International authors and editors

200M

Downloads

Our authors are among the

154

Countries delivered to

TOP 1%

most cited scientists

12.2%

Contributors from top 500 universities



WEB OF SCIENCE™

Selection of our books indexed in the Book Citation Index
in Web of Science™ Core Collection (BKCI)

Interested in publishing with us?
Contact book.department@intechopen.com

Numbers displayed above are based on latest data collected.
For more information visit www.intechopen.com



Noninvasive Alternatives for the Assessment of Liver Fibrosis

Lungen Lu and Kun Zhou

*Department of Gastroenterology, Shanghai First People's Hospital,
Shanghai Jiaotong University School of Medicine
China*

1. Introduction

Chronic liver diseases (CLD) are common and may lead to fibrosis, cirrhosis, and hepatic malignancy. Detection and staging of liver fibrosis is crucial for management of patients with CLD. At present, liver biopsy is the standard method for staging fibrosis, but biopsies are poorly tolerated because they are invasive and associated with some discomfort and complications. In addition, limitations of biopsy include intra- and inter-observer variation and sampling error^{1,2}. In recent years, a great interest and many studies have been dedicated to the development of noninvasive tests to substitute liver biopsy for fibrosis assessment and follow-up. Unfortunately, all of them have limitations and pitfalls. To discuss their advantages and deficiencies will be helpful in scientific research and clinical practice.

2. Invasive measurements

2.1 Liver biopsy

Liver biopsy has been considered as the gold standard to confirm the clinical diagnosis, to assess the severity of necro-inflammation and fibrosis, to identify cofactors and comorbidities, and to monitor the efficacy of treatments since the first liver biopsy was performed by Paul Ehrlich in 1883³. The procedure is particularly useful for diagnosing the earlier stages of fibrosis and identifying patients at high risk of progressing fibrosis, but it has also a number of limitations. The patient acceptance is pretty low because biopsy is expensive, invasive and associated with some discomfort and complications. Pain appears in about one fourth of patients, other complications including bleeding, biliary peritonitis, pneumothorax and a mortality rate about 0.01%⁴. Sampling error of at least 24% is reported usually because of specimen fragmentation or inadequate length. Colloredo *et al* concluded that an optimum specimen should be at least 20 mm in length with 11 complete portal tracts¹. Even with adequate-sized biopsies, the interpretation might be unreliable, because the distribution of necro-inflammation and fibrosis is not homogeneous, and liver biopsy samples only 1:50 000th of the mass of the liver.

Several semi-quantitative scoring systems have been proposed to describe and quantify the necro-inflammation, steatosis and fibrosis in the liver, particularly for chronic viral hepatitis. These include the Knodell histological activity index (HAI) first proposed in 1981, then modified to the Scheuer system, the METAVIR system and the Ishak modified HAI⁵. However, all the scoring systems could only provide qualitative descriptors to stage fibrosis,

and the staging of certain histopathological changes differ in different systems (Table 1). This could cause considerable intra- and inter-observer variation and difficulty in comparison ².

Pathologic Features	Knodell	Scheuer	METAVIR	Ishak
No fibrosis	0	0	0	0
Enlargement of some portal tracts	1	1	1	1
Enlargement of most portal tracts	1	1	1	2
Periportal septa	1	2	1	2
Occasional portal-portal septa	3	2	2	3
Numerous septa (portal-portal and/or portal-central)	3	3	3	4
Occasional nodules	4	4	4	5
Definite cirrhosis	4	4	4	6

Table 1. Scoring systems for staging fibrosis

Using computerized digital image analysis, the amount of fibrosis in liver biopsy specimens can be evaluated by a quantitative score ⁶⁻⁹. Though it is thought to be less reliable in determining early stage fibrosis, recent advances such as a higher resolution digital camera can improve discrimination between the varying stages of liver fibrosis, including mild fibrosis ⁸. It may be a more precise method than semi-quantitative histological stages for monitoring fibrosis progression or regression during clinical therapeutic trials ⁹. Considering the irregular shape of specimens, fractal and spectral dimension analysis can also be used to improve accuracy ¹⁰.

The detection of genes correlated with fibrosis from biopsy samples regains interest for liver biopsy. The changes in liver gene expression can indicate fibrosis progression precisely at an early stage ¹¹. Genetic studies have identified possible genetic polymorphisms that influence the progression of liver fibrosis ¹². The identification of panels of key genes correlating with differences in the progression of CLDs could lead to establishing excellent prognostic/diagnostic tools.

2.2 Hepatic venous pressure gradient

Hepatic venous pressure gradient (HVPG), as an expression of intrahepatic resistance, does not exceed 5 mmHg in absence of significant fibrotic evolution. The measurement of HVPG is a validated, safe and highly reproducible technique. It may be considered as a dynamic marker of disease progression in patients with HCV and an end point in antiviral therapy, irrespective of antiviral response ¹³. However, the technique is invasive, expensive, requires technical expertise, and has low patient acceptance.

3. Serological tests

The limitations of liver biopsy led to the searching of noninvasive tests for assessment of liver fibrosis. Afdhal and Nunes *et al* ¹⁴ suggest the following criteria for an ideal marker of liver fibrosis: it should be liver specific; should not be influenced by alterations in liver, renal, or reticuloendothelial function; should measure one or more of the processes related to fibrosis (stage of fibrosis, activity of matrix deposition, or activity of matrix removal); and should be easy to perform.

3.1 Direct serum markers

The key step in the pathophysiology of liver fibrosis is the balance between ECM deposition and removal. Accumulation of ECM results from both increased synthesis and decreased degradation. The principal ECM constituents are synthesized by activated HSCs, while broken down by a family of enzymes known as matrix metalloproteinases (MMPs). Many studies have been dedicated to find serum ECM markers for fibrosis assessment.

Hyaluronic acid (HA), a glycosaminoglycan distributed in the connective tissue, is a component of the liver extracellular matrix, which is synthesized and degraded in the liver sinusoidal cells. The high levels of HA observed in patients with chronic liver disease, have been related with a decreased function of the endothelial sinusoidal cells. Many studies showing a close relationship between liver fibrosis and HA levels.

These similar markers of fibrosis including: (1) collagens: N-terminal peptide of type III procollagen (PIIINP), type IV collagen 7s domain (IV-7S) ¹⁵, (2) proteoglycans: hyaluronic acid (HA) ¹⁶, (3) glycoproteins: laminin (LN) ¹⁷, human cartilage glycoprotein 39 (YKL-40) ¹⁸, (4) collagenases and their inhibitors: MMPs, tissue inhibitor of metalloproteinases (TIMPs) ¹⁹, (5) cytokines: transforming growth factor β 1 (TGF- β 1), platelet-derived growth factor (PDGF), tumor necrosis factor β (TNF- β).

The clinical applications of such markers appear innovative, they are useful to assess the speed of liver fibrogenesis and estimate the response to anti-viral therapies or anti-fibrotic drugs. But most of them are insensitive in milder fibrosis, and it must be stressed that these markers reflect fibrogenesis and fibrolysis more than fibrosis itself. In other words, there may be a highly active fibrotic process in the liver, although fibrotic tissue has not yet been developed, or there may be heavy fibrosis in the liver but fibrotic activity is temporarily discontinued.

3.2 Serum marker panels

Since present direct markers could not satisfy the clinical need of measuring the fibrosis yet, an alternative approach turns out to be combining a number of serum markers to generate algorithms capable of evaluating fibrosis. A large number of panels have been suggested by groups worldwide ²⁰⁻⁴⁹ (Table 2).

These panels are mainly based on two kinds of markers, direct and indirect. Direct markers are those directly linked to the modifications in ECM metabolism, such as HA and PIIINP. Indirect markers include a broad range of blood tests which have no direct link with liver fibrosis. They reflect liver dysfunction or other phenomena caused by fibrosis rather than fibrosis per se. Generally speaking, indexes including direct markers, such as the Fibrometer, may perform a higher accuracy, but indexes composed by only indirect markers are effective as well, and usually more useful because they are based on routine blood tests easy to be performed in a hospital general laboratory.

The diagnostic value of the models was assessed by calculating the area under the receiver operating characteristic curves (AUROC). Most studies reported an AUROC >0.80 in differentiating significant fibrosis (fibrosis spread out the portal tract with septa) from no/mild fibrosis (no fibrosis or portal fibrosis without septa), improved performance with a higher AUROC value was showed in differentiating between no cirrhosis and cirrhosis. But it must be underlined that the AUROC values in table 2 came from each different designed study and are not suitable to make a comparison.

Index, Author, year, reference	Patients no.	CLDs	markers in panel	AUROC(T-V) ^a
AAR, Williams, 1988 ²⁰	177	Mixed	AST/ALT-ratio (AAR)	n/a
PGA index, Poynard , 1991 ²¹	624	Alcohol	PT, GGT, apoA1	n/a
PGAA index, Naveau , 1994 ²²	525	Alcohol	PT, GGT, apoA1, A2M	n/a
CDS index, Bonacini, 1997 ²³	75	HCV	PLT, AAR, PT	n/a
AP index, Poynard 1997 ²⁴	620	HCV	Age, PLT	0.763-0.690
BAAT score, Ratziu 2000 ²⁵	93	NAFLD	Age, BMI, ALT, TG	0.84
Fortunato, 2001 ²⁶	103	HCV	Fibronectin, prothrombin, ALT, PCHE, Mn-SOD, β-NAG	n/a
Pohl, 2001 ²⁷	211	HCV	AAR, PLT	n/a
FibroTest, Imbert-Bismut, 2001 ²⁸	339	HCV	A2M, Hpt, GGT, ApoA1, bilirubin	0.836-0.870
Kaul 2002 ²⁹	264	HCV	PLT, AST, sex, spider naevi	n/a
Forns index, Forns, 2002 ³⁰	476	HCV	Age, GGT, cholesterol, PLT	0.86-0.81
APRI, Wai, 2003 ³¹	270	HCV	AST, PLT	0.80-0.88
ELF-score, Rosenberg, 2004 ³²	1021	Mixed	Age, HA, PIII ^{NP} , TIMP-1	0.804
FIBROSpect II, Patel, 2004 ³³	696	HCV	HA, TIMP-1, A2M	0.831-0.823
FPI, Sud, 2004 ³⁴	302	HCV	Age, AST, TC, HOMA-IR, past alcohol intake	0.84-0.77
MP3, Leroy, 2004 ³⁵	194	HCV	PIII ^{NP} , MMP-1	0.82
HALT-C, Lok, 2005 ³⁶	1141	HCV	PLT, AAR, INR	0.78-0.81 ^d
Hepascore, Adams, 2005 ³⁷	221	HCV	Bilirubin, GGT, HA, A2M, age, sex	0.85-0.82
Fibrometer, Cales, 2005 ³⁸	383	Mixed	PLT, PI, AST, A2M, HA, urea, age	0.883-0.892
SHASTA index, Kelleher, 2005 ³⁹	95	HCV/HIV	HA,AST and albumin	0.878
Sakugawa, 2005 ⁴⁰	112	NAFLD	IV-7S, HA	n/a
Hui,2005 ⁴¹	235	HBV	BMI, PLT, albumin, TB, ALP	0.803-0.765
SLFG, Zeng, 2005 ⁴²	372	HBV	A2M, age, GGT, HA	0.84-0.77
FIB-4, Sterling, 2006 ⁴³	832	HCV/HIV	Age, ast, ALT, PLT	0.765 ^b
Virahep-C, Fontana, 2006 ⁴⁴	399	HCV	age, AST, ALP,PLT	0.837-0.851
Mohamadnejad, 2006 ⁴⁵	276	HBV	HBV DNA levels, ALP, albumin, PLT,	0.91-0.85
FibroIndex, Koda, 2007 ⁴⁶	402	HCV	PLT, AST, γ- globulin	0.828-0.835
Alsatie, 2007 ⁴⁷	286	HCV	diabetes mellitus, PLT, AST, INR, bilirubin	0.79-0.75 ^c
Esmat, 2007 ⁴⁸	220	HCV	HA, age	0.84 ^b
NAFLD fibrosis score, Angulo, 2007 ⁴⁹	733	NAFLD	Age, BMI, PLT, albumin, AAR, hyperglycemia	0.88-0.82

^a The area under the receiver operating characteristic curves (AUROC) for the diagnosis of significant fibrosis (stage 2-4 by the METAVIR or Scheuer classification, 3-6 by the Ishak score). T-V means the AUROC values of training group and validation group.

^b Differentiation advanced fibrosis (Ishak 4-6) from mild to moderate fibrosis (Ishak 0-3).

^c Differentiation advanced hepatic fibrosis (defined as F3-F4 by METAVIR) from milder (F0-F2).

^d Differentiation cirrhosis from no cirrhosis.

Abbreviations used: CLD, Chronic liver disease; ROC, receiver operating characteristic; AUROC, area under the ROC curve; AAR, AST/ALT-ratio; AST, aspartate aminotransferase; ALT, alanine aminotransferase; PT, prothrombin time; GGT, γ-glutamyltransferase; apoA1, apolipoprotein A1; A2M, α2-macroglobulin; PLT, platelet count; TG, triglycerides; PCHE, pseudocholinesterase; Mn-SOD, manganese superoxide dismutase; β-NAG, N-acetyl β-glucosaminidase; Hpt, haptoglobin; HA, hyaluronic acid; PIII^{NP}, N-terminal peptide of type III pro-collagen; TIMP-1, tissue inhibitor of metalloproteinase 1; TC, total cholesterol; HOMA-IR, Homeostasis Model Assessment insulin resistance(fast glucose×plasma gluc/22.5); MMP-1, metalloproteinase 1; INR, international normalized ratio; PI, Prothrombin index; IV-7S, type IV collagen 7s domain; BMI, body mass index; TB, total bilirubin; ALP, alkaline phosphatase.

Table 2. Studies of serum markers panels for assessment of liver fibrosis

Chronic hepatitis B (CHB) is the most frequent infectious cause of CLD worldwide. More than 400 million people are chronically infected with HBV. The virus is responsible for more than 300,000 cases of liver cancer every year and for similar numbers of gastrointestinal haemorrhage and ascites ⁵⁰. Predictive models designed specially for CHB patients have been proposed by the Shanghai Liver Fibrosis Group (SLFG) ⁴², Hui et al ⁴¹ and Mohamadnejad et al ⁴⁵. But few of these models mentioned above has been widely validated and implemented in clinical practice. In our study of the S index ⁵¹, a simpler noninvasive model based on routine laboratory markers, we compare its diagnostic value with that of some typical models (Fig. 1). We noticed that the SLFG model and Hepascore performed better in identifying significant fibrosis than the Forns score and APRI, but the superiority was not so significant in identifying advanced fibrosis or cirrhosis. The result was similar to a validation study in CHC patients ⁵², indicating that such special tests might improve the sensitivity of a diagnostic model in predicting early fibrosis. But including tests unavailable in daily practice makes standardization, validation and routine bedside use difficult.

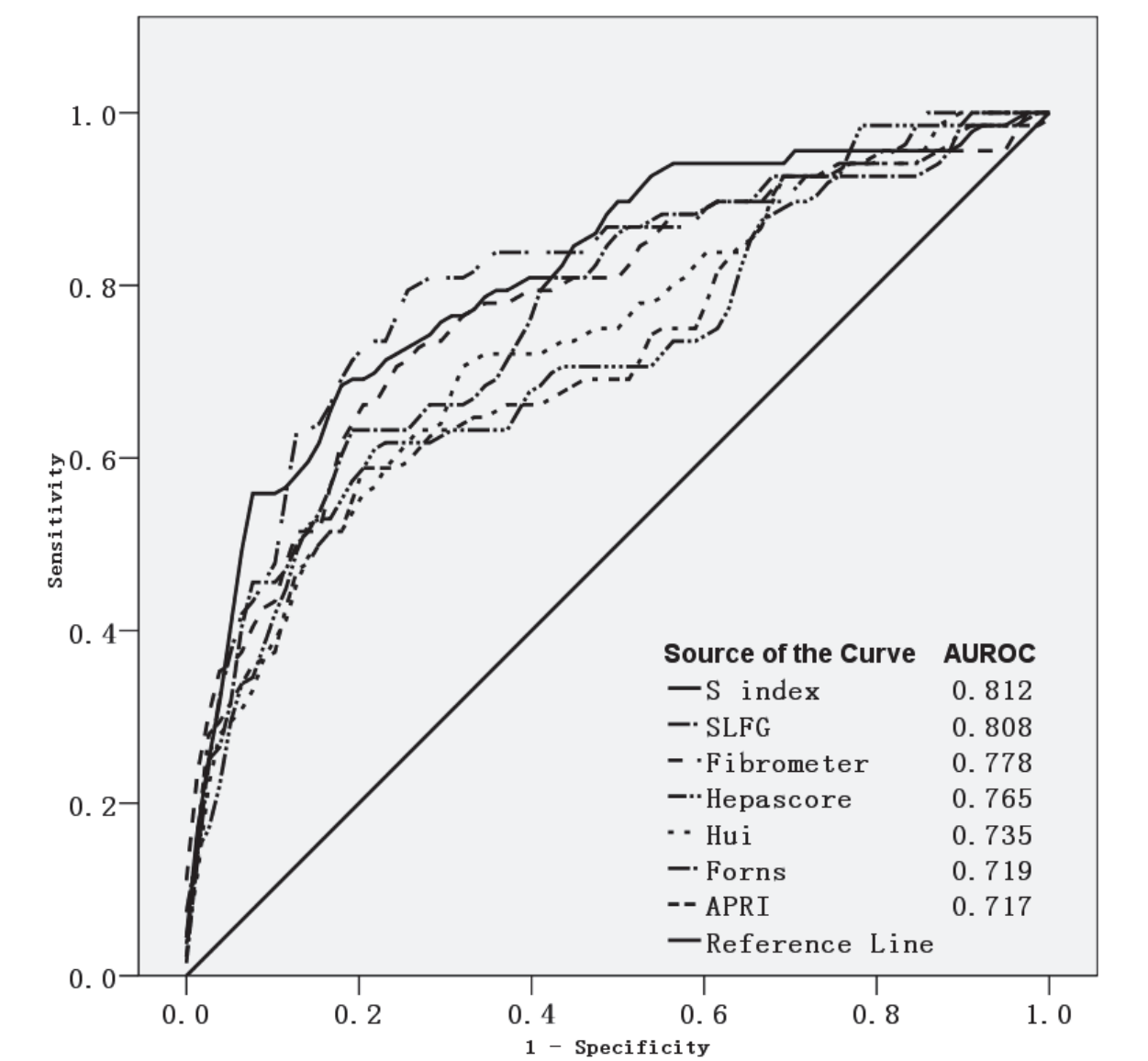


Fig. 1. ROC curves in the prediction of significant fibrosis

There are still some limitations of these marker panels to be considered. First, the design of every study differed in population characteristic, patient selection, significant fibrosis prevalence, blood test inclusion, biochemical measurement and liver histological assessment, resulted in various panels with different markers and parameters. The agreement among these indexes is poor and validation study is needed to choose a proper panel and cutoff value for clinical use. Second, none of the studies controlled for degree of necro-inflammatory activity, most of the panels include markers likely to reflect or be affected by inflammation in the liver, which is much more mobile than fibrosis stage. Third, the formulae are easy to fail because many markers included will be influenced by extrahepatic diseases or conditions such as inflammation, haemolysis, cholestasis, hypercholesterolaemia and renal failure. Finally, few of the studies include treated patients. It is not clear whether these indexes are suitable for assessing treatment response. However, a few studies by Poynard *et al* suggested that Fibrotest could also be used as surrogate markers of the histological impact of treatments in patients infected by HCV and HBV^{53, 54}. These indexes, in their current form, are not able to give us the exact stage of fibrosis in most studies. Their main value is to reduce the need for liver biopsy by distinguishing significant fibrosis from no/mild fibrosis, and telling the presence of cirrhosis. It does not seem appropriate to completely replace liver biopsy with serum marker panels at the present time, but it can be anticipated that these indexes will become very useful in the clinical management of CLDs by offering an attractive alternative to liver biopsy, as they are noninvasive, convenient, inexpensive, and may allow dynamic assessment of fibrosis. Validation in larger cohorts of patients with different CLDs is needed before an index will be proposed for extensive clinical use.

3.3 Proteomics and glycomics

Over the last 5-6 years, it was reported that the use of proteomic patterns in serum to distinguish individual stages of fibrosis could achieve perfect diagnostic sensitivity and specificity. Using a proteome-based fingerprinting model generated by surface-enhanced laser desorption/ionization time-of-flight (SELDI-TOF) ProteinChip arrays, Poon *et al*⁵⁵ achieved an AUROC of 0.93 in identifying significant fibrosis. Another proteomic index combining eight peaks established by Morra *et al*⁵⁶ could diagnosis advanced fibrosis with an AUROC of 0.88, significantly greater than the FibroTest AUROC of 0.81. Besides, The SELDI-TOF ProteinChip technology is useful for the early detection and prediction of HCC in patients with chronic HCV infection⁵⁷. Similar technologies were also used to generate profiles of serum N-glycan profile for identifying liver fibrosis^{58, 59}. Further studies identifying the altered peaks in these models to understand their origins may help to find new biomarkers for fibrosis, or even improve our understanding in the mechanism of liver fibrosis.

4. Radiological tests

Since significant structural changes are present only in advanced CLDs, the routine examinations by Ultrasound (US), computed tomography (CT) and magnetic resonance imaging (MRI) could bring specific findings, but with very limited sensitivity. Thus, persistent efforts were made to search for technological developments.

4.1 Perfusion examinations

MR and Doppler US techniques are studied to find sensitive perfusion changes in the progression of fibrosis⁶⁰. For example, the circulatory changes will result in a decrease of

hepatic vein transit time (HVTT), which can be measured by microbubble-enhanced US ⁶¹. Using HVTT measurements, Lim *et al* achieved 100% sensitivity and 80% specificity for diagnosis of cirrhosis, and 95% sensitivity and 86% specificity for differentiation of mild hepatitis from more severe liver disease ⁶². Progressive liver fibrosis gradually obliterates normal intrahepatic vessels and sinusoids and slows passage of blood through the parenchyma. In addition, as portal hypertension develops, portal venous flow to the liver decreases, hepatic arterial flow increases, and intrahepatic shunts form. These physiologic alterations can be detected with kinetic models of dynamic image data sets acquired rapidly after bolus intravenous injection of paramagnetic extracellular contrast agents. Several perfusion parameters can be estimated by MR perfusion imaging, a recent study applied a dual-input kinetic model for the noninvasive assessment of liver fibrosis. The dual-input approach models two sources of blood flow into the liver, via the hepatic artery and portal vein, and assumes a single tissue compartment. Significant differences were found in several perfusion parameters between patients with and without advanced fibrosis ⁶³.

4.2 Liver stiffness measurement

In chronic liver disease, progressive deposition of interconnecting collagen fibers throughout the liver produces a lattice-like framework that increases parenchymal rigidity. Because liver stiffness cannot be reliably assessed with external physical palpation, an imaging approach is required. There are two main imaging methods for measuring hepatic stiffness. One is US-based transient elastography; the other is MR elastography.

The FibroScan, a new medical device based on one-dimensional transient elastography ⁶⁴, which assesses fibrosis through liver stiffness measurement (LSM). A special probe generates an elastic shear wave propagating through the liver tissue, the harder the tissue, the faster the shear wave propagates. Transient elastography could accurately predict different stages of fibrosis or cirrhosis (AUROC: 0.79 for $F \geq 2$, 0.91 for $F \geq 3$, and 0.97 for $F = 4$, by the METAVIR scoring system) ⁶⁵.

The major advantage of transient elastography compared with serum markers and marker panels is that it measures directly on the liver and there is no interference from extrahepatic diseases or conditions. Further more, the test is standardized and completely noninvasive. Though assessing earlier fibrosis is the common shortcoming of various noninvasive tests, Colletta *et al* reported that the agreement between transient elastography and liver biopsy was much better than FibroTest in normal transaminases HCV carriers with early stages of fibrosis⁶⁶. Compared to liver biopsy, transient elastography is painless, rapid, has no risk of complications, and is therefore very well accepted. Transient elastography measures liver stiffness of a volume which is 100 times bigger than the biopsy specimen. The high reproducibility (intra- and inter-observer agreement intraclass correlation coefficient was 0.98 ⁶⁷) and acceptance of transient elastography makes it an attractive alternative to biopsy for individual follow-up.

There are also some physical limitations of transient elastography. The signal penetrates only 25–65 mm, makes obesity (particularly the fatness of the chest wall) the most important cause of failure⁶⁸. But new technological developments may overcome the limitation. Additional limitations include a narrow intercostal space and ascites. The main reason that transient elastography can not totally replace liver biopsy is that it is only a means to stage disease. It is unable to diagnose liver disease by distinguishing subtle diagnostic differences. Nor can transient elastography identify cofactors and comorbidities or grade necro-inflammation and steatosis. But it represents a totally different approach to assess fibrosis

and therefore could be combined with other noninvasive modalities to better assess liver fibrosis. The combined use of transient elastography and FibroTest to evaluate liver fibrosis could avoid a biopsy procedure in most patients with chronic hepatitis C ⁶⁹.

Magnetic resonance elastography (MRE) is a technique using a modified phase-contrast magnetic resonance imaging sequence to image propagating shear waves in tissue ⁷⁰. The technique has been previously applied to quantitatively assess the viscoelastic properties of the breast, brain, and muscle in humans. Several recent studies showed that MRE is also a feasible method to assess the stage of liver fibrosis. Liver stiffness as measured with MR elastography increases as the stage of fibrosis advances. The differences in stiffness between patients with early stages of fibrosis (F0 vs F1 vs F2) are small and there is overlap between groups, but the differences between groups with higher stages (F2 vs F3 vs F4) are large, with little overlap between groups⁷¹. MRE has several potential advantages compared with ultrasound transient elastography. It can be performed in obesity patients. It can assess larger volumes and provide full three-dimensional information about the viscoelastic parameters of tissues. With MR techniques, a comprehensive examination of the liver can be performed, including MRE, contrast-enhanced MRI to detect hepatocellular carcinomas and perfusion MRI to assess liver function.

4.3 Real-time elastography

Real-time elastography is another ultrasound technique developed by Hitachi Medical Systems that can reveal the physical property of tissue using conventional ultrasound probes during a routine sonography examination. In the first study assessing real-time elastography for the detection of liver fibrosis ⁷², the AUROC was 0.75 for the diagnosis of significant fibrosis. Much higher diagnostic accuracy (AUROC = 0.93) was obtained by a mathematic combination of the elasticity score and two routine laboratory values (platelet count and GGT), which provided a more superior way to combine serological and radiological tests together.

4.4 Double contrast material-enhanced magnetic resonance imaging

The conspicuity of gadolinium-enhanced lesions is increased in the setting of decreased signal intensity from the uninvolved liver parenchyma following superparamagnetic iron oxide (SPIO) injection. This MRI technique has been used to improve detection of focal hepatic lesion and hepatocellular carcinoma ^{73, 74}. Recently, Aguirre *et al* ⁷⁵ examined 101 CLD patients who underwent double-enhanced MR imaging to detect hyperintense reticulations, which are postulated to represent septal fibrosis. They achieved an accuracy of greater than 90% for the diagnosis of advanced hepatic fibrosis compared with histopathological analysis. Clinical trials are currently under way to prospectively assess fibrosis staging with this technique.

4.5 Diffusion weighted magnetic resonance imaging

Diffusion weighted magnetic resonance imaging (DWMRI) has been widely used in brain imaging for the evaluation of acute ischemic stroke. With the advent of the echo-planar MRI technique, it became possible to be applied in the abdomen for characterization of focal hepatic lesions ⁷⁶. Recently, using DWMRI to measure the apparent diffusion coefficient (ADC) of water, a parameter that is dependent on the tissue structure, is introduced in the assessment of liver fibrosis ⁷⁷. The ADC value is lower in livers with heavier fibrosis because of the restriction of water diffusion in fibrotic tissue. Lewin *et al* assessed the performance of

DWMRI in 54 patients with chronic HCV infection with reference to several other noninvasive methods⁷⁸. In discriminating significant fibrosis patients, the AUC values were 0.79 for DWMRI, 0.87 for transient elastography, 0.68 for FibroTest, 0.81 for APRI, 0.72 for the Forns index, and 0.77 for hyaluronate. DWMRI performed better in discriminating patients staged F3-F4, the AUC value increased to 0.92, the same as transient elastography. But besides fibrosis, it seems that ADC values might also reflect the intensity of inflammation, necrosis and steatosis. Because technical factors lead to differences in estimated ADC, reported ADCs are variable, with considerable overlap between normal and abnormal ranges. Thus, there is a need to develop site- and technique-specific normal ranges and to standardize methods across imaging centers.

Several other MR techniques have also been introduced in the area of fibrosis assessment, such as ultrashort echo time (UTE) MRI⁷⁹ and magnetic resonance spectroscopy (MRS)⁸⁰. New MR imaging contrast agents that specifically target collagen or other extracellular matrix macromolecules may be developed. A collagen-specific MR imaging contrast agent could act as a fibrosis-imaging agent, and these agents may have higher efficacy for fibrosis assessment than the current methods⁸¹. All such data may provide valuable information for guiding antifibrotic therapy development and monitoring patients in clinical trials.

5. Conclusion

The increasing of potentially effective managements for CLDs such as antiviral and antifibrotic therapies has led to an urgent need for a rapid, safe and repeatable tool to assess fibrosis of CLDs and to follow-up progression or regression of fibrosis during treatment. Liver biopsy has been the gold standard for the assessment of hepatic fibrosis, but the invasive procedure has considerable limitations and fails to satisfy the current needs. Many noninvasive methods have been proposed with the aim of substituting liver biopsy. The numerous advances in serological, radiological techniques and their combinations have allowed to satisfactorily identify patients without a liver biopsy. But each of them has some deficiencies and the liver biopsy will still have an important role to play. Applying new techniques for the detection of fibrosis may potentially circumvent the pitfalls and deficiencies of the existing surrogates mentioned above. These include serum proteomics, glycomics and new imaging techniques such as molecular imaging technique for the imaging of cellular biochemical processes⁸², diffraction-enhanced imaging technique for the imaging of soft tissues⁸³, photonic imaging technique for three-dimensional whole-body images⁸⁴. However, further studies are needed to develop or validate noninvasive tests that can accurately reflect the full spectrum of hepatic fibrosis in CLDs. But an incorrigible defect in our studies will be the questionable gold standard we have to use. More errors are due to the histological staging⁸⁵. Mathematical modeling suggested that assuming either 80% or 90% diagnostic accuracy of liver biopsy, noninvasive tests cannot achieve an AUROC better than 0.9 and are likely to perform between 0.75 and 0.9⁸⁶, exactly where they are today. We may find a better surrogate for liver biopsy, but how can we prove it will be a question. Laparoscopic biopsy can decrease sampling error and increases the reliability of histopathologic assessment⁸⁷. Using automated image analysis to assess texture features and shape representation of the fibrosis structural expansion can turn the current semiquantitative methods of liver fibrosis assessment into real quantitative ones with significant reduction in variability and subjectivity⁸⁸. Validating noninvasive tests against not only histological stage scores but also digital image analysis and clinical outcomes may also be a better choice.

6. References

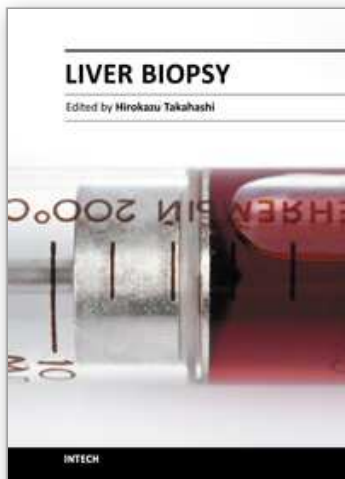
- [1] Colloredo G, Guido M, Sonzogni A, Leandro G. Impact of liver biopsy size on histological evaluation of chronic viral hepatitis: the smaller the sample, the milder the disease. *J Hepatol.* 2003; 39: 239-44.
- [2] The French METAVIR Cooperative Study Group. Intraobserver and interobserver variations in liver biopsy interpretation in patients with chronic hepatitis C. *Hepatology.* 1994; 20: 15-20.
- [3] Bravo AA, Sheth SG, Chopra S. Liver biopsy. *N Engl J Med.* 2001; 344: 495-500.
- [4] McGill DB, Rakela J, Zinsmeister AR, Ott BJ. A 21-year experience with major hemorrhage after percutaneous liver biopsy. *Gastroenterology.* 1990; 99: 1396-400.
- [5] Brunt EM. Grading and staging the histopathological lesions of chronic hepatitis: the Knodell histology activity index and beyond. *Hepatology.* 2000; 31: 241-6.
- [6] Chevallier M, Guerret S, Chossegros P, Gerard F, Grimaud JA. A histological semiquantitative scoring system for evaluation of hepatic fibrosis in needle liver biopsy specimens: comparison with morphometric studies. *Hepatology.* 1994; 20: 349-55.
- [7] Pilette C, Rousselet MC, Bedossa P, *et al.* Histopathological evaluation of liver fibrosis: quantitative image analysis vs semi-quantitative scores. Comparison with serum markers. *J Hepatol.* 1998; 28: 439-46.
- [8] Lazzarini AL, Levine RA, Ploutz-Snyder RJ, Sanderson SO. Advances in digital quantification technique enhance discrimination between mild and advanced liver fibrosis in chronic hepatitis C. *Liver Int.* 2005; 25: 1142-9.
- [9] Goodman ZD, Becker RL, Jr., Pockros PJ, Afdhal NH. Progression of fibrosis in advanced chronic hepatitis C: evaluation by morphometric image analysis. *Hepatology.* 2007; 45: 886-94.
- [10] Dioguardi N, Franceschini B, Aletti G, Russo C, Grizzi F. Fractal dimension rectified meter for quantification of liver fibrosis and other irregular microscopic objects. *Anal Quant Cytol Histol.* 2003; 25: 312-20.
- [11] Asselah T, Bieche I, Laurendeau I, *et al.* Liver gene expression signature of mild fibrosis in patients with chronic hepatitis C. *Gastroenterology.* 2005; 129: 2064-75.
- [12] Bataller R, North KE, Brenner DA. Genetic polymorphisms and the progression of liver fibrosis: a critical appraisal. *Hepatology.* 2003; 37: 493-503.
- [13] Burroughs AK, Groszmann R, Bosch J, *et al.* Assessment of therapeutic benefit of antiviral therapy in chronic hepatitis C: is hepatic venous pressure gradient a better end point? *Gut.* 2002; 50: 425-7.
- [14] Afdhal NH, Nunes D. Evaluation of liver fibrosis: a concise review. *Am J Gastroenterol.* 2004; 99: 1160-74.
- [15] Murawaki Y, Ikuta Y, Koda M, Kawasaki H. Serum type III procollagen peptide, type IV collagen 7S domain, central triple-helix of type IV collagen and tissue inhibitor of metalloproteinases in patients with chronic viral liver disease: relationship to liver histology. *Hepatology.* 1994; 20: 780-7.
- [16] Pares A, Deulofeu R, Gimenez A, *et al.* Serum hyaluronate reflects hepatic fibrogenesis in alcoholic liver disease and is useful as a marker of fibrosis. *Hepatology.* 1996; 24: 1399-403.
- [17] Walsh KM, Fletcher A, MacSween RN, Morris AJ. Basement membrane peptides as markers of liver disease in chronic hepatitis C. *J Hepatol.* 2000; 32: 325-30.

- [18] Saitou Y, Shiraki K, Yamanaka Y, *et al.* Noninvasive estimation of liver fibrosis and response to interferon therapy by a serum fibrogenesis marker, YKL-40, in patients with HCV-associated liver disease. *World J Gastroenterol.* 2005; 11: 476-81.
- [19] Kasahara A, Hayashi N, Mochizuki K, *et al.* Circulating matrix metalloproteinase-2 and tissue inhibitor of metalloproteinase-1 as serum markers of fibrosis in patients with chronic hepatitis C. Relationship to interferon response. *J Hepatol.* 1997; 26: 574-83.
- [20] Williams AL, Hoofnagle JH. Ratio of serum aspartate to alanine aminotransferase in chronic hepatitis. Relationship to cirrhosis. *Gastroenterology.* 1988; 95: 734-9.
- [21] Poynard T, Aubert A, Bedossa P, *et al.* A simple biological index for detection of alcoholic liver disease in drinkers. *Gastroenterology.* 1991; 100: 1397-402.
- [22] Naveau S, Poynard T, Benattar C, Bedossa P, Chaput JC. Alpha-2-macroglobulin and hepatic fibrosis. Diagnostic interest. *Dig Dis Sci.* 1994; 39: 2426-32.
- [23] Bonacini M, Hadi G, Govindarajan S, Lindsay KL. Utility of a discriminant score for diagnosing advanced fibrosis or cirrhosis in patients with chronic hepatitis C virus infection. *Am J Gastroenterol.* 1997; 92: 1302-4.
- [24] Poynard T, Bedossa P. Age and platelet count: a simple index for predicting the presence of histological lesions in patients with antibodies to hepatitis C virus. METAVIR and CLINIVIR Cooperative Study Groups. *J Viral Hepat.* 1997; 4: 199-208.
- [25] Ratziu V, Giral P, Charlotte F, *et al.* Liver fibrosis in overweight patients. *Gastroenterology.* 2000; 118: 1117-23.
- [26] Fortunato G, Castaldo G, Oriani G, *et al.* Multivariate discriminant function based on six biochemical markers in blood can predict the cirrhotic evolution of chronic hepatitis. *Clin Chem.* 2001; 47: 1696-700.
- [27] Pohl A, Behling C, Oliver D, Kilani M, Monson P, Hassanein T. Serum aminotransferase levels and platelet counts as predictors of degree of fibrosis in chronic hepatitis C virus infection. *Am J Gastroenterol.* 2001; 96: 3142-6.
- [28] Imbert-Bismut F, Ratziu V, Pieroni L, Charlotte F, Benhamou Y, Poynard T. Biochemical markers of liver fibrosis in patients with hepatitis C virus infection: a prospective study. *Lancet.* 2001; 357: 1069-75.
- [29] Kaul V, Friedenberg FK, Braitman LE, *et al.* Development and validation of a model to diagnose cirrhosis in patients with hepatitis C. *Am J Gastroenterol.* 2002; 97: 2623-8.
- [30] Forns X, Ampurdanes S, Llovet JM, *et al.* Identification of chronic hepatitis C patients without hepatic fibrosis by a simple predictive model. *Hepatology.* 2002; 36: 986-92.
- [31] Wai CT, Greenson JK, Fontana RJ, *et al.* A simple noninvasive index can predict both significant fibrosis and cirrhosis in patients with chronic hepatitis C. *Hepatology.* 2003; 38: 518-26.
- [32] Rosenberg WM, Voelker M, Thiel R, *et al.* Serum markers detect the presence of liver fibrosis: a cohort study. *Gastroenterology.* 2004; 127: 1704-13.
- [33] Patel K, Gordon SC, Jacobson I, *et al.* Evaluation of a panel of non-invasive serum markers to differentiate mild from moderate-to-advanced liver fibrosis in chronic hepatitis C patients. *J Hepatol.* 2004; 41: 935-42.
- [34] Sud A, Hui JM, Farrell GC, *et al.* Improved prediction of fibrosis in chronic hepatitis C using measures of insulin resistance in a probability index. *Hepatology.* 2004; 39: 1239-47.
- [35] Leroy V, Monier F, Bottari S, *et al.* Circulating matrix metalloproteinases 1, 2, 9 and their inhibitors TIMP-1 and TIMP-2 as serum markers of liver fibrosis in patients with chronic hepatitis C: comparison with PIIINP and hyaluronic acid. *Am J Gastroenterol.* 2004; 99: 271-9.

- [36] Lok AS, Ghany MG, Goodman ZD, *et al.* Predicting cirrhosis in patients with hepatitis C based on standard laboratory tests: results of the HALT-C cohort. *Hepatology*. 2005; 42: 282-92.
- [37] Adams LA, Bulsara M, Rossi E, *et al.* Hepascore: an accurate validated predictor of liver fibrosis in chronic hepatitis C infection. *Clin Chem*. 2005; 51: 1867-73.
- [38] Cales P, Oberti F, Michalak S, *et al.* A novel panel of blood markers to assess the degree of liver fibrosis. *Hepatology*. 2005; 42: 1373-81.
- [39] Kelleher TB, Mehta SH, Bhaskar R, *et al.* Prediction of hepatic fibrosis in HIV/HCV co-infected patients using serum fibrosis markers: the SHASTA index. *J Hepatol*. 2005; 43: 78-84.
- [40] Sakugawa H, Nakayoshi T, Kobashigawa K, *et al.* Clinical usefulness of biochemical markers of liver fibrosis in patients with nonalcoholic fatty liver disease. *World J Gastroenterol*. 2005; 11: 255-9.
- [41] Hui AY, Chan HL, Wong VW, *et al.* Identification of chronic hepatitis B patients without significant liver fibrosis by a simple noninvasive predictive model. *Am J Gastroenterol*. 2005; 100: 616-23.
- [42] Zeng MD, Lu LG, Mao YM, *et al.* Prediction of significant fibrosis in HBeAg-positive patients with chronic hepatitis B by a noninvasive model. *Hepatology*. 2005; 42: 1437-45.
- [43] Sterling RK, Lissen E, Clumeck N, *et al.* Development of a simple noninvasive index to predict significant fibrosis in patients with HIV/HCV coinfection. *Hepatology*. 2006; 43: 1317-25.
- [44] Fontana RJ, Kleiner DE, Bilonick R, *et al.* Modeling hepatic fibrosis in African American and Caucasian American patients with chronic hepatitis C virus infection. *Hepatology*. 2006; 44: 925-35.
- [45] Mohamadnejad M, Montazeri G, Fazlollahi A, *et al.* Noninvasive markers of liver fibrosis and inflammation in chronic hepatitis B-virus related liver disease. *Am J Gastroenterol*. 2006; 101: 2537-45.
- [46] Koda M, Matunaga Y, Kawakami M, Kishimoto Y, Suou T, Murawaki Y. FibroIndex, a practical index for predicting significant fibrosis in patients with chronic hepatitis C. *Hepatology*. 2007; 45: 297-306.
- [47] Alsatie M, Kwo PY, Gingerich JR, *et al.* A multivariable model of clinical variables predicts advanced fibrosis in chronic hepatitis C. *J Clin Gastroenterol*. 2007; 41: 416-21.
- [48] Esmat G, Metwally M, Zalata KR, *et al.* Evaluation of serum biomarkers of fibrosis and injury in Egyptian patients with chronic hepatitis C. *J Hepatol*. 2007; 46: 620-7.
- [49] Angulo P, Hui JM, Marchesini G, *et al.* The NAFLD fibrosis score: a noninvasive system that identifies liver fibrosis in patients with NAFLD. *Hepatology*. 2007; 45: 846-54.
- [50] Lai CL, Ratziu V, Yuen MF, Poynard T. Viral hepatitis B. *Lancet*. 2003; 362: 2089-94.
- [51] Zhou K, Gao CF, Zhao YP, *et al.* Simpler score of routine laboratory tests predicts liver fibrosis in patients with chronic hepatitis B. *Journal of Gastroenterology and Hepatology*. 2010; 25: 1569-77.
- [52] Bourliere M, Penaranda G, Renou C, *et al.* Validation and comparison of indexes for fibrosis and cirrhosis prediction in chronic hepatitis C patients: proposal for a pragmatic approach classification without liver biopsies. *J Viral Hepat*. 2006; 13: 659-70.
- [53] Poynard T, McHutchison J, Manns M, Myers RP, Albrecht J. Biochemical surrogate markers of liver fibrosis and activity in a randomized trial of peginterferon alfa-2b and ribavirin. *Hepatology*. 2003; 38: 481-92.

- [54] Poynard T, Zoulim F, Ratziau V, *et al.* Longitudinal assessment of histology surrogate markers (FibroTest-ActiTest) during lamivudine therapy in patients with chronic hepatitis B infection. *Am J Gastroenterol.* 2005; 100: 1970-80.
- [55] Poon TC, Hui AY, Chan HL, *et al.* Prediction of liver fibrosis and cirrhosis in chronic hepatitis B infection by serum proteomic fingerprinting: a pilot study. *Clin Chem.* 2005; 51: 328-35.
- [56] Morra R, Munteanu M, Bedossa P, *et al.* Diagnostic value of serum protein profiling by SELDI-TOF ProteinChip compared with a biochemical marker, FibroTest, for the diagnosis of advanced fibrosis in patients with chronic hepatitis C. *Aliment Pharmacol Ther.* 2007; 26: 847-58.
- [57] Kanmura S, Uto H, Kusumoto K, *et al.* Early diagnostic potential for hepatocellular carcinoma using the SELDI ProteinChip system. *Hepatology.* 2007; 45: 948-56.
- [58] Callewaert N, Van Vlierberghe H, Van Hecke A, Laroy W, Delanghe J, Contreras R. Noninvasive diagnosis of liver cirrhosis using DNA sequencer-based total serum protein glycomics. *Nat Med.* 2004; 10: 429-34.
- [59] Kam RK, Poon TC, Chan HL, Wong N, Hui AY, Sung JJ. High-throughput quantitative profiling of serum N-glycome by MALDI-TOF mass spectrometry and N-glycomic fingerprint of liver fibrosis. *Clin Chem.* 2007; 53: 1254-63.
- [60] Annet L, Materne R, Danse E, Jamart J, Horsmans Y, Van Beers BE. Hepatic flow parameters measured with MR imaging and Doppler US: correlations with degree of cirrhosis and portal hypertension. *Radiology.* 2003; 229: 409-14.
- [61] Albrecht T, Blomley MJ, Cosgrove DO, *et al.* Non-invasive diagnosis of hepatic cirrhosis by transit-time analysis of an ultrasound contrast agent. *Lancet.* 1999; 353: 1579-83.
- [62] Lim AK, Taylor-Robinson SD, Patel N, *et al.* Hepatic vein transit times using a microbubble agent can predict disease severity non-invasively in patients with hepatitis C. *Gut.* 2005; 54: 128-33.
- [63] Miyazaki S, Yamazaki Y, Murase K. Error analysis of the quantification of hepatic perfusion using a dual-input single-compartment model. *Physics in Medicine and Biology.* 2008; 53: 5927-46.
- [64] Sandrin L, Fourquet B, Hasquenoph JM, *et al.* Transient elastography: a new noninvasive method for assessment of hepatic fibrosis. *Ultrasound Med Biol.* 2003; 29: 1705-13.
- [65] Ziol M, Handra-Luca A, Kettaneh A, *et al.* Noninvasive assessment of liver fibrosis by measurement of stiffness in patients with chronic hepatitis C. *Hepatology.* 2005; 41: 48-54.
- [66] Colletta C, Smirne C, Fabris C, *et al.* Value of two noninvasive methods to detect progression of fibrosis among HCV carriers with normal aminotransferases. *Hepatology.* 2005; 42: 838-45.
- [67] Fraquelli M, Rigamonti C, Casazza G, *et al.* Reproducibility of transient elastography in the evaluation of liver fibrosis in patients with chronic liver disease. *Gut.* 2007; 56: 968-73.
- [68] Foucher J, Castera L, Bernard PH, *et al.* Prevalence and factors associated with failure of liver stiffness measurement using FibroScan in a prospective study of 2114 examinations. *Eur J Gastroenterol Hepatol.* 2006; 18: 411-2.
- [69] Castera L, Vergniol J, Foucher J, *et al.* Prospective comparison of transient elastography, Fibrotest, APRI, and liver biopsy for the assessment of fibrosis in chronic hepatitis C. *Gastroenterology.* 2005; 128: 343-50.
- [70] Muthupillai R, Lomas DJ, Rossman PJ, Greenleaf JF, Manduca A, Ehman RL. Magnetic resonance elastography by direct visualization of propagating acoustic strain waves. *Science.* 1995; 269: 1854-7.

- [71] Yin M, Talwalkar JA, Glaser KJ, *et al.* Assessment of Hepatic Fibrosis With Magnetic Resonance Elastography. *Clinical Gastroenterology and Hepatology*. 2007; 5: 1207-13.e2.
- [72] Friedrich-Rust M, Ong MF, Herrmann E, *et al.* Real-time elastography for noninvasive assessment of liver fibrosis in chronic viral hepatitis. *AJR Am J Roentgenol*. 2007; 188: 758-64.
- [73] Kim MJ, Kim JH, Chung JJ, Park MS, Lim JS, Oh YT. Focal hepatic lesions: detection and characterization with combination gadolinium- and superparamagnetic iron oxide-enhanced MR imaging. *Radiology*. 2003; 228: 719-26.
- [74] Kwak HS, Lee JM, Kim CS. Preoperative detection of hepatocellular carcinoma: comparison of combined contrast-enhanced MR imaging and combined CT during arterial portography and CT hepatic arteriography. *Eur Radiol*. 2004; 14: 447-57.
- [75] Aguirre DA, Behling CA, Alpert E, Hassanein TI, Sirlin CB. Liver fibrosis: noninvasive diagnosis with double contrast material-enhanced MR imaging. *Radiology*. 2006; 239: 425-37.
- [76] Ichikawa T, Haradome H, Hachiya J, Nitatori T, Araki T. Diffusion-weighted MR imaging with a single-shot echoplanar sequence: detection and characterization of focal hepatic lesions. *AJR Am J Roentgenol*. 1998; 170: 397-402.
- [77] Koinuma M, Ohashi I, Hanafusa K, Shibuya H. Apparent diffusion coefficient measurements with diffusion-weighted magnetic resonance imaging for evaluation of hepatic fibrosis. *J Magn Reson Imaging*. 2005; 22: 80-5.
- [78] Lewin M, Poujol-Robert A, Boelle PY, *et al.* Diffusion-weighted magnetic resonance imaging for the assessment of fibrosis in chronic hepatitis C. *Hepatology*. 2007; 46: 658-65.
- [79] Chappell KE, Patel N, Gatehouse PD, *et al.* Magnetic resonance imaging of the liver with ultrashort TE (UTE) pulse sequences. *J Magn Reson Imaging*. 2003; 18: 709-13.
- [80] Lim AK, Patel N, Hamilton G, Hajnal JV, Goldin RD, Taylor-Robinson SD. The relationship of in vivo ³¹P MR spectroscopy to histology in chronic hepatitis C. *Hepatology*. 2003; 37: 788-94.
- [81] Caravan P. Protein-targeted gadolinium-based magnetic resonance imaging (MRI) contrast agents: Design and mechanism of action. *Accounts of Chemical Research*. 2009; 42: 851-62.
- [82] Margolis DJ, Hoffman JM, Herfkens RJ, Jeffrey RB, Quon A, Gambhir SS. Molecular imaging techniques in body imaging. *Radiology*. 2007; 245: 333-56.
- [83] Meuli R, Hwu Y, Je JH, Margaritondo G. Synchrotron radiation in radiology: radiology techniques based on synchrotron sources. *Eur Radiol*. 2004; 14: 1550-60.
- [84] Ntziachristos V, Ripoll J, Wang LV, Weissleder R. Looking and listening to light: the evolution of whole-body photonic imaging. *Nat Biotechnol*. 2005; 23: 313-20.
- [85] Poynard T, Munteanu M, Imbert-Bismut F, *et al.* Prospective analysis of discordant results between biochemical markers and biopsy in patients with chronic hepatitis C. *Clin Chem*. 2004; 50: 1344-55.
- [86] Afdhal NH, Curry M. Technology evaluation: a critical step in the clinical utilization of novel diagnostic tests for liver fibrosis. *J Hepatol*. 2007; 46: 543-5.
- [87] Pagliaro L, Rinaldi F, Craxi A, *et al.* Percutaneous blind biopsy versus laparoscopy with guided biopsy in diagnosis of cirrhosis. A prospective, randomized trial. *Dig Dis Sci*. 1983; 28: 39-43.
- [88] Matalka, II, Al-Jarrah OM, Manasrah TM. Quantitative assessment of liver fibrosis: a novel automated image analysis method. *Liver Int*. 2006; 26: 1054-64.



Liver Biopsy

Edited by Dr Hirokazu Takahashi

ISBN 978-953-307-644-7

Hard cover, 404 pages

Publisher InTech

Published online 06, September, 2011

Published in print edition September, 2011

Liver biopsy is recommended as the gold standard method to determine diagnosis, fibrosis staging, prognosis and therapeutic indications in patients with chronic liver disease. However, liver biopsy is an invasive procedure with a risk of complications which can be serious. This book provides the management of the complications in liver biopsy. Additionally, this book provides also the references for the new technology of liver biopsy including the non-invasive elastography, imaging methods and blood panels which could be the alternatives to liver biopsy. The non-invasive methods, especially the elastography, which is the new procedure in hot topics, which were frequently reported in these years. In this book, the professionals of elastography show the mechanism, availability and how to use this technology in a clinical field of elastography. The comprehension of elastography could be a great help for better dealing and for understanding of liver biopsy.

How to reference

In order to correctly reference this scholarly work, feel free to copy and paste the following:

Lungen Lu and Kun Zhou (2011). Noninvasive Alternatives for the Assessment of Liver Fibrosis, Liver Biopsy, Dr Hirokazu Takahashi (Ed.), ISBN: 978-953-307-644-7, InTech, Available from:

<http://www.intechopen.com/books/liver-biopsy/noninvasive-alternatives-for-the-assessment-of-liver-fibrosis>

INTECH
open science | open minds

InTech Europe

University Campus STeP Ri
Slavka Krautzeka 83/A
51000 Rijeka, Croatia
Phone: +385 (51) 770 447
Fax: +385 (51) 686 166
www.intechopen.com

InTech China

Unit 405, Office Block, Hotel Equatorial Shanghai
No.65, Yan An Road (West), Shanghai, 200040, China
中国上海市延安西路65号上海国际贵都大饭店办公楼405单元
Phone: +86-21-62489820
Fax: +86-21-62489821

© 2011 The Author(s). Licensee IntechOpen. This chapter is distributed under the terms of the [Creative Commons Attribution-NonCommercial-ShareAlike-3.0 License](https://creativecommons.org/licenses/by-nc-sa/3.0/), which permits use, distribution and reproduction for non-commercial purposes, provided the original is properly cited and derivative works building on this content are distributed under the same license.

IntechOpen

IntechOpen