

We are IntechOpen, the world's leading publisher of Open Access books Built by scientists, for scientists

6,900

Open access books available

185,000

International authors and editors

200M

Downloads

Our authors are among the

154

Countries delivered to

TOP 1%

most cited scientists

12.2%

Contributors from top 500 universities



WEB OF SCIENCE™

Selection of our books indexed in the Book Citation Index
in Web of Science™ Core Collection (BKCI)

Interested in publishing with us?
Contact book.department@intechopen.com

Numbers displayed above are based on latest data collected.
For more information visit www.intechopen.com



Transgastric Liver Biopsy Using the NOTES Technique: An Animal Study

Nobumi Tagaya and Masatoshi Oya

*First Department of Surgery,
Dokkyo Medical University Koshigaya Hospital,
Koshigaya, Saitama,
Japan*

1. Introduction

Liver biopsy (LB) is an important procedure in the diagnosis and treatment of liver diseases. At present, there are two minimally invasive techniques for liver tissue sampling: image-guided percutaneous liver biopsy (PLB) and transjugular liver biopsy (TJLB) [1-4]. Both techniques have several disadvantages, such as the risk of bleeding and subcapsular hematoma in the former, and the small sample size, longer procedure time and the need for considerable interventional skill in the latter. Recently, innovative intra-abdominal procedures that require no incision of the anterior abdominal wall have become possible by accessing the peritoneal cavity through natural orifices [5,6]. Natural orifice transluminal endoscopic surgery (NOTES) for access to the peritoneal cavity was first reported by Kalloo et al. [7]. To develop a new strategy for minimally invasive LB in humans, we have investigated a novel procedure for transgastric liver biopsy (TGLB) using the NOTES technique in experimental animals.

2. Materials and methods

The aim of this study was to determine the technical feasibility of peroral TGLB using a flexible endoscope. This experimental study was approved by the animal care institutional review board at the Dokkyo Medical University. The utility of transgastric peritoneoscopy was evaluated in three 15-kg farm pigs and five 8-kg dogs.

Under general anesthesia with an endotracheal intubation, a forward-viewing, double-channel endoscope (GIF-2T-240, Olympus, Tokyo) was advanced into the esophagus and stomach. Puncture of the gastric wall was performed with a 3-mm cutting-wire needle knife (KD-10Q-1, Olympus). The puncture site was enlarged to 8mm with a balloon dilator (CRE W.G. esophageal balloon 5839, Boston Scientific) and the endoscope was advanced into the peritoneal cavity. The peritoneal cavity was inflated with air through the endoscope. The liver was easily visualized by retroflexion of the endoscope (Fig.1).

LB was performed using routine biopsy forceps (FB-230K, Olympus) from the edge of the liver (Fig.2) and hemostasis of biopsy sites was achieved using electrocautery with the

biopsy forceps (Fig.3). A gastric orifice was closed by endoscopic clips (HX-610-135, HX-610-090L, Olympus). The animals were sacrificed and necropsy was performed.

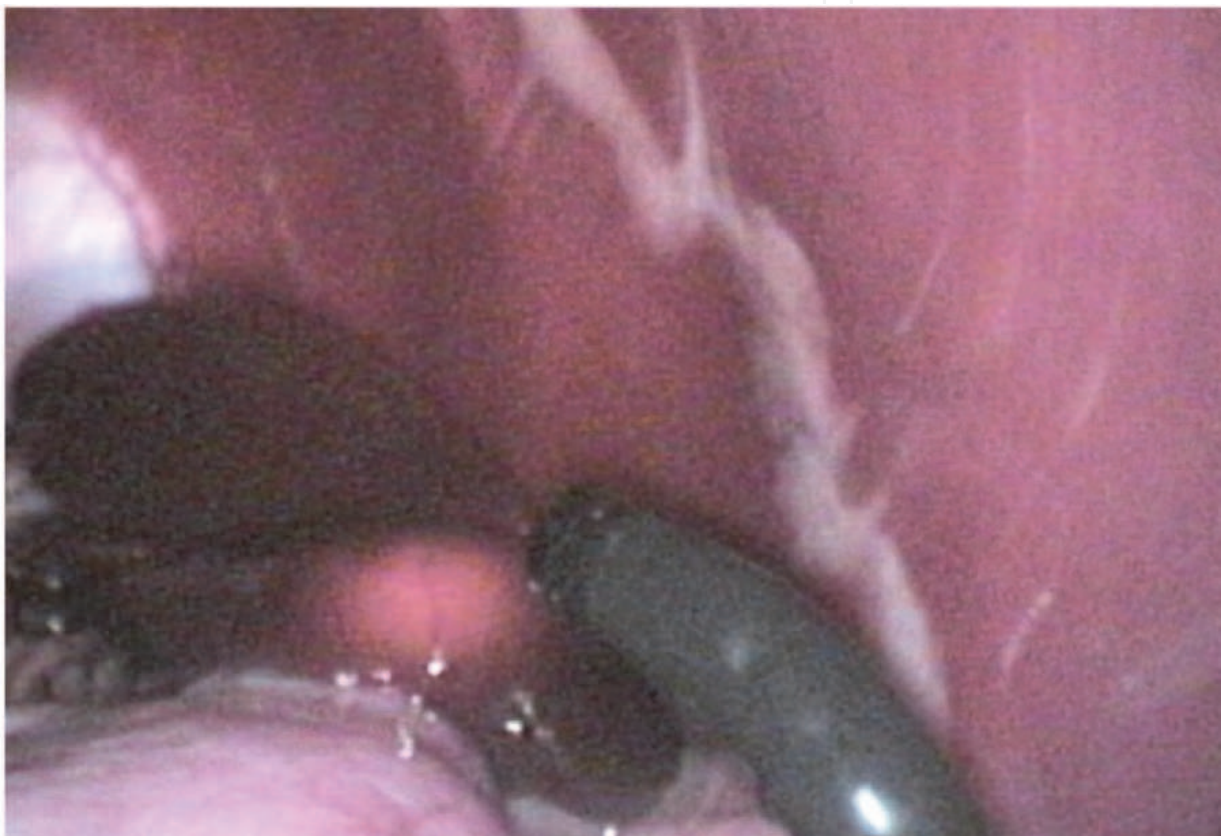

Fig. 1. Retroflexion of the endoscope easily visualized the liver

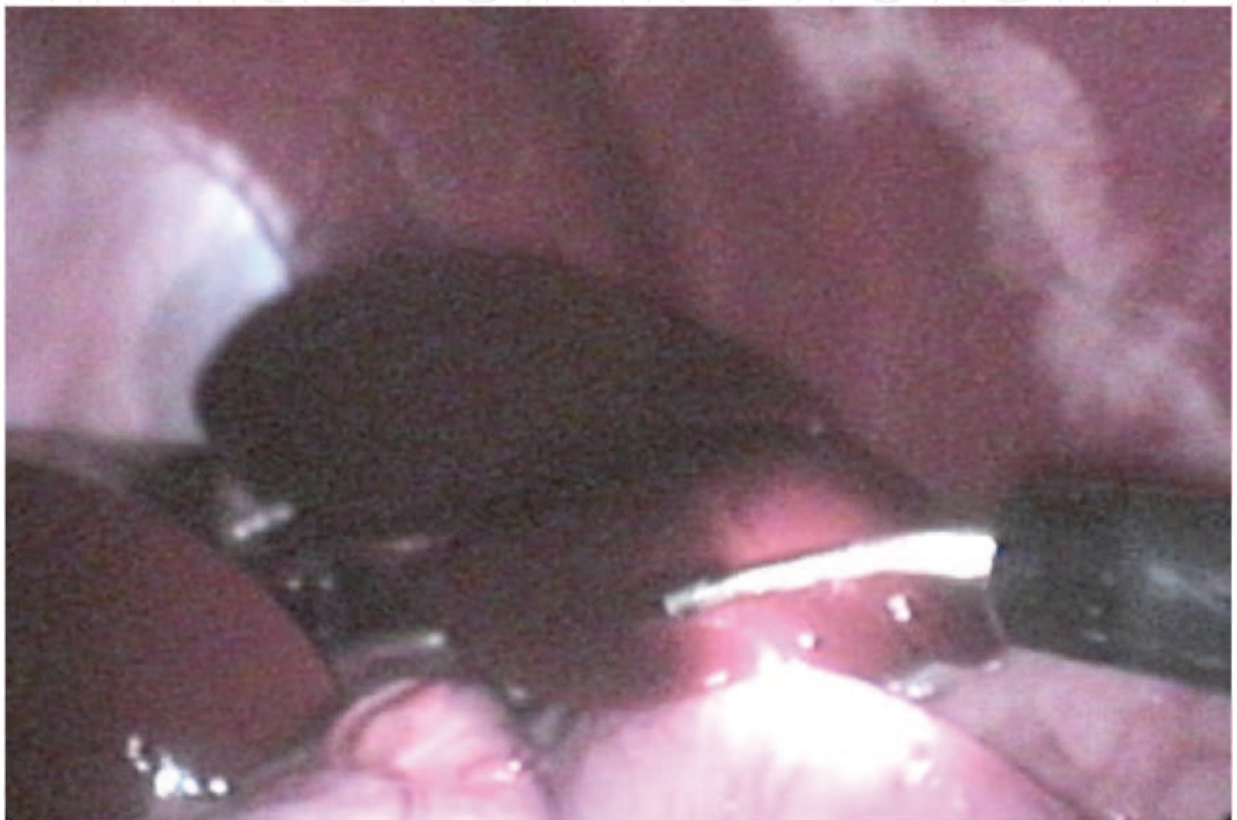


Fig. 2. Liver biopsy was performed using routine biopsy forceps from the edge of the liver.



Fig. 3. An adequate sample was retrieved by biopsy forceps.

3. Results

None of the eight animals developed complications, including adjacent organ injury or bleeding, during incision of the gastric wall, entry into the peritoneal cavity, and the closure of the gastric wall. Visualization of the intraperitoneal organs through the endoscope using standard endoscopic techniques had no problems. Peritoneoscopy revealed a good operative view of abdominal cavity in all possible directions. LB was successfully performed without any trouble bleedings and yielded adequate samples for histopathologic examination in all cases. Minor bleeding occurred in three cases and was stopped by an endoscopic electrocoagulation (Fig 4).

Necropsy revealed no particular damages to other intraperitoneal organs related with this transgastric procedure. The acute experiments demonstrated the technical feasibility of this approach.

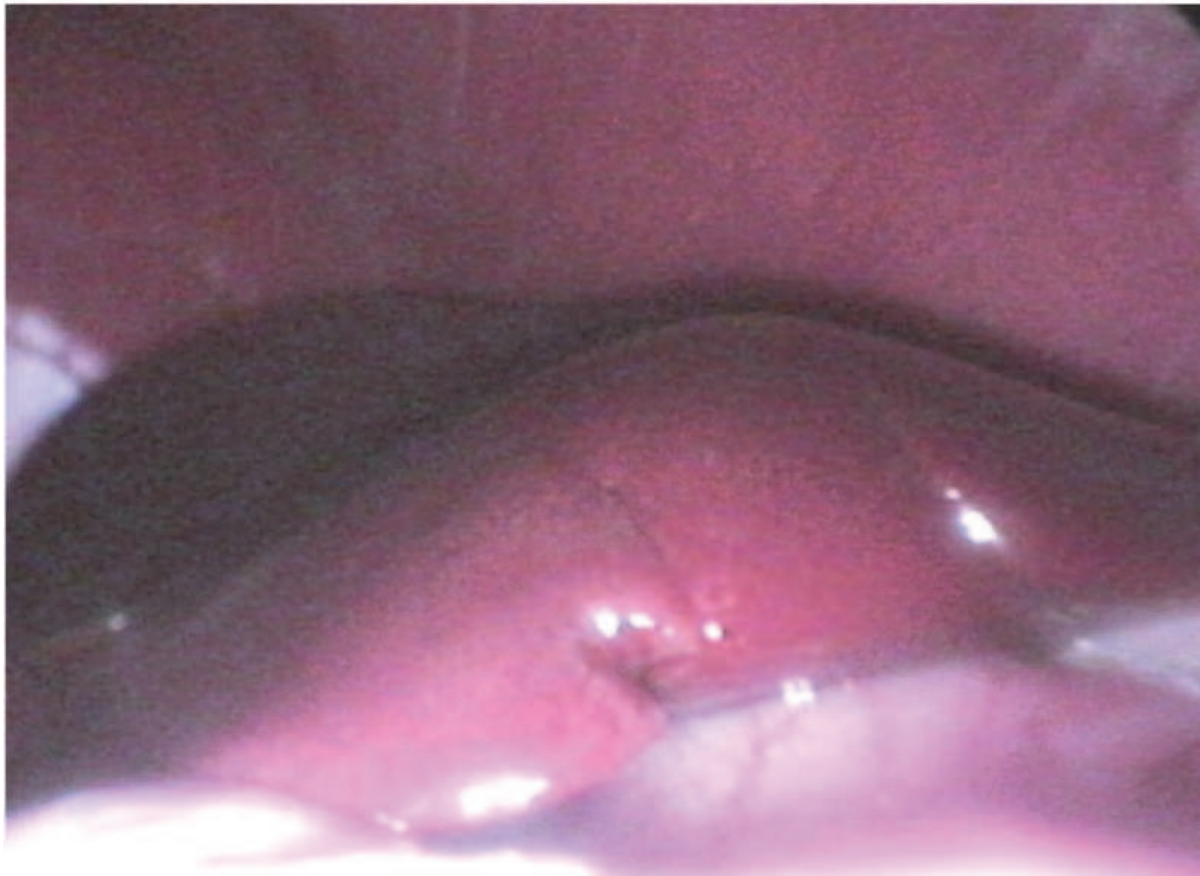


Fig. 4. Hemostasis was confirmed at the site of liver biopsy.

4. Discussion

In general, LB is a necessary procedure to evaluate the chronic liver disease, and a standard one to diagnose liver tumors pathologically. In performing LB, there are two procedures consisting of percutaneous and transjugular routes. However, those procedures revealed several disadvantages including post procedural hemorrhage, small sample size for diagnosis, the differences of the severity of fibrosis in the sites of LB, and so on [2]. We have to resolve or minimize those issues in this era. Recently, endoscopic approach in LB became attractive with minimally invasiveness to human bodies and no skin damage. We introduced TGLB by NOTES [5-7] as an endoscopic approach, and reported the evaluation of TGLB in diagnostic and therapeutic aspects for liver diseases.

The method of PLB is divided into blind, ultrasound (US) or computed tomographic guidance. Those results greatly depend on the skills of the gastroenterologist, hepatologist or radiologist as an operator and the technical possibilities including the quality of the ultrasonography itself. However, the most careful event is complications after PLB. Piccinino et al. [8] reported that 61% of the complications appeared in the first 2 hours after the biopsy, 82% in the first 10 hours, and 96% in the first 24 hours. We should have the strict observation for the first 24 hours after PLB. Several large studies showed that the rate of major complication after PLB ranged from 0.09% to 2.3%, severe complications appeared in 0.57%, and mortality ranged from 0.03% to 0.11% [9-11]. And the complications of blind PLB

are significant high rates compared with those of US-guided one [12-14], PLB under US guidance is recommended as a reasonable and cost-efficient procedure [1, 13, 15]. In fact, morbidity and mortality rates are not high. Furthermore, regarding bleeding after PLB, Alotaibi et al. [4] described that the positive color Doppler sign in US indicated bleeding along a biopsy tract and US-guided compression was effective in achieving appropriate hemostasis, and tract-plugging means that the biopsy tract is filled with Gelfoam or other thrombotic agents, it is an important procedure to decrease the risk of bleeding and subcapsular hematoma in PLB [2]. Nevertheless, in patients with ascites, abnormal coagulation profiles, another procedure is considered because of the high risk due to bleeding complications.

The TJLB via the internal jugular vein approach using the method described by McAfee et al. [16] is thought to be a safer biopsy option in patients with ascites, coagulopathy, thrombocytopenia or medical conditions with bleeding disorders such as hemophilia being considered as contraindications for PLB [17,18] because the patients will “bleed” back into the vein rather than into the abdomen. However, TJLB is a limited technique as a result of small sample size and caliber, longer procedure time, and the need for a skilled interventional radiologist [18]. Furthermore, it is also not without complications, which arise when the liver capsule or capsular veins are perforated, and does not prevent this risk, and it actually seems to increase risk in ascitic patients [3]. Therefore, the TJLB still needs a further study to evaluate indication, technique and complications.

The attractive points of LB by NOTES technique consist of no skin damage in the outside of the body and the direct observation of biopsy site in the inside of the body against PLB or TJLB. In clinically, the introduction of NOTES is required to resolve the identification of safe access to the peritoneal cavity, the complete closure of access route, the prevention of infection, the intra-abdominal orientation, the development of a multitasking platform, the management for the accidental complications, the outlining physiologic unanticipated events and the training of NOTES as White paper from American Society for Gastrointestinal Endoscopy and Society of American Gastrointestinal and Endoscopic Surgeons declared, [5,6]. In particular, infection or bacterial contamination in the abdomen due to the open of the digestive tract is a great concern in NOTES. However, transgastric peritoneoscopy being developed by Kalloo et al. [7, 19] showed no association with serious infection or other complications in the peritoneal cavity during their long-term survival experiments. Furthermore, Hazey et al. [20] reported that although contamination in the abdomen was documented, no clinically significant episode of the peritoneal cavity was observed without abscess formation or infectious complications during laparoscopic Roux-en-Y gastric bypass. From those findings, although the peroral TGLB required to add the artificial injury for normal organs, it will become one of alternatives to another LB methods.

In fact, there are several successful experimental reports of liver biopsy using a pig model [19, 21-23]. Mintz et al. [22] reported that LB can be performed safely and obtained from the edge of the liver using routine endoscopic punch biopsy forceps, and adequate hemostasis also obtained by an electrocautery. This report was similar to our procedure and results. In clinical, Hazey et al. [20] reported that LB was uneventfully performed from the transgastric access route in a patient who underwent a diagnostic laparoscopic evaluation of pancreatic mass. Steele et al. [24] also reported that LB from segments II, III, or IVb under flexible transgastric peritoneoscopy during Roux-en-Y gastric bypass for morbid obesity was

performed in 3 patients with only minor bleeding from the liver biopsy sites. Exploration of the peritoneal cavity with a flexible endoscope and a LB took 2.1 min to 6.0 with a mean of 4.1 min. The postoperative period in all patients was uneventful without any local or systemic complications. Above those findings revealed that LB could be a feasible and safe procedure without any critical complications even in humans.

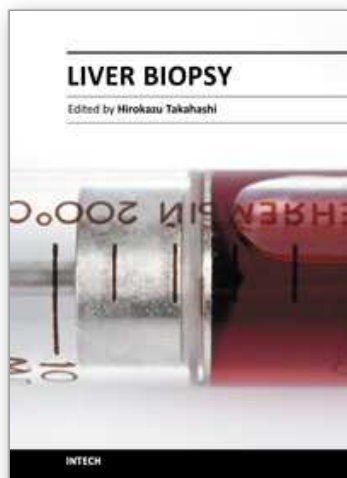
In conclusion, this approach to peritoneal cavity is technically feasible and has the potential to be an alternative to routine LB. Transgastric endoscopic approach has a wide range of diagnostic and therapeutic interventions.

5. References

- [1] Lindor KD et al. (1996). The role of ultrasonography and automatic-needle biopsy in outpatient percutaneous liver biopsy. *Hepatology*, 23, pp.1079-1983
- [2] Sporea I et al. (2008). Why, who and how should perform liver biopsy in chronic liver disease. *World J Gastroenterol*, 14, pp.3396-3402.
- [3] Hardman RL et al. (2010). Single-institution results of image-guided nonplugged percutaneous versus transjugular liver biopsy. *Cardiovasc Intervent Radiol*, [DOI 10.1007/s00270-010-9924-9].
- [4] Alotaibi M et al. (2010). The positive color Doppler sign post biopsy: effectiveness of US-directed compression in achieving hemostasis. *Pediatr Radiol*, [DOI 10.1007/s00247-010-1848-7]
- [5] ASGE & SAGES. (2006). ASGE/SAGES working group on natural orifice transluminal endoscopic surgery: White paper October 2005. *Gastrointest Endosc*, 63, pp.199-203.
- [6] Rattner D & Kalloo A: ASGE/SAGES Working Group. (2006). ASGE/SAGES working group on natural orifice transluminal endoscopic surgery. October 2005. *Surg Endosc*, 20, pp.329-33.
- [7] Kalloo AN et al. (2000). Flexible transgastric peritoneoscopy: a novel approach to diagnostic and therapeutic interventions in the peritoneal cavity [abstract]. *Gastroenterology*, 118, pp.A1039.
- [8] Piccinino F et al. (1986). Complications following percutaneous liver biopsy. A multicentre retrospective study on 68,276 biopsies. *J Hepatol*, 2, pp.165-173.
- [9] Poynard T et al. (2000). Appropriateness of liver biopsy. *Can J Gastroenterol*, 14, pp.543-548.
- [10] McGill DB et al. (1990). A 21-year experience with major hemorrhage after percutaneous liver biopsy. *Gastroenterology*, 99, pp.1396-1400.
- [11] Cadranet JF et al. (2000). Practices of liver biopsy in France: results of a prospective nationwide survey. For the Group of Epidemiology of the French Association for the Study of the Liver (AFEFL). *Hepatology*, 32, pp.477-481.
- [12] Pasha T et al. (1998). Cost-effectiveness of ultrasound-guided liver biopsy. *Hepatology*, 27, pp.1220-1226.
- [13] Younossi ZM et al. (1998). Ultrasound-guided liver biopsy for parenchymal liver disease: an economic analysis. *Dig Dis Sci*, 43, pp.46-50.
- [14] Farrell RJ et al. (1999). Guided versus blind liver biopsy for chronic hepatitis C; clinical benefits and costs. *J Hepatol*, 30, pp.580-587.

- [15] Adam T & Lewis JH. (2002). Percutaneous liver biopsy. Clin Perspectives Gastroenterol: 117-121.
- [16] McAfee JH et al. (1992). Transjugular liver biopsy. Hepatology, 15, pp.726-732.
- [17] Bravo AA et al. (2001). Liver biopsy. N Engl J Med, 344, pp.495-500.
- [18] Rockey D et al. (2009). American Association for the study of Liver Diseases. Liver biopsy. Hepatology, 49, pp.1017-1044.
- [19] Kalloo AN et al. (2004). Flexible transgastric peritoneoscopy: a novel approach to diagnostic and therapeutic interventions in the peritoneal cavity. Gastrointest Endosc, 60, pp.114-117.
- [20] Hazey JW et al. (2008). Natural-orifice transgastric endoscopic peritoneoscopy in humans: Initial clinical trial. Surg Endosc, 22, pp.16-20.
- [21] Lima E et al. (2006). Transvesical endoscopic peritoneoscopy: a novel 5 mm port for intra-abdominal scarless surgery. J Urol, 176, pp.802-805.
- [22] Mintz Y et al. (2007). NOTES: The hybrid technique. J Laparoendosc Adv Surg Tech, 17, pp.402-406.
- [23] Mintz Y et al. (2008). NOTES: A review of the technical problems encountered and their solutions. J Laparoendosc Adv Surg Tech, 18, pp.583-587.
- [24] Steele K et al. (2008). Flexible transgastric peritoneoscopy and liver biopsy: a feasibility study in human beings (with video). Gastrointest Endosc, 68, pp.61-66.

IntechOpen



Liver Biopsy

Edited by Dr Hirokazu Takahashi

ISBN 978-953-307-644-7

Hard cover, 404 pages

Publisher InTech

Published online 06, September, 2011

Published in print edition September, 2011

Liver biopsy is recommended as the gold standard method to determine diagnosis, fibrosis staging, prognosis and therapeutic indications in patients with chronic liver disease. However, liver biopsy is an invasive procedure with a risk of complications which can be serious. This book provides the management of the complications in liver biopsy. Additionally, this book provides also the references for the new technology of liver biopsy including the non-invasive elastography, imaging methods and blood panels which could be the alternatives to liver biopsy. The non-invasive methods, especially the elastography, which is the new procedure in hot topics, which were frequently reported in these years. In this book, the professionals of elastography show the mechanism, availability and how to use this technology in a clinical field of elastography. The comprehension of elastography could be a great help for better dealing and for understanding of liver biopsy.

How to reference

In order to correctly reference this scholarly work, feel free to copy and paste the following:

Nobumi Tagaya and Masatoshi Oya (2011). Transgastric Liver Biopsy Using the NOTES Technique: An Animal Study, Liver Biopsy, Dr Hirokazu Takahashi (Ed.), ISBN: 978-953-307-644-7, InTech, Available from: <http://www.intechopen.com/books/liver-biopsy/transgastric-liver-biopsy-using-the-notes-technique-an-animal-study>

INTECH
open science | open minds

InTech Europe

University Campus STeP Ri
Slavka Krautzeka 83/A
51000 Rijeka, Croatia
Phone: +385 (51) 770 447
Fax: +385 (51) 686 166
www.intechopen.com

InTech China

Unit 405, Office Block, Hotel Equatorial Shanghai
No.65, Yan An Road (West), Shanghai, 200040, China
中国上海市延安西路65号上海国际贵都大饭店办公楼405单元
Phone: +86-21-62489820
Fax: +86-21-62489821

© 2011 The Author(s). Licensee IntechOpen. This chapter is distributed under the terms of the [Creative Commons Attribution-NonCommercial-ShareAlike-3.0 License](https://creativecommons.org/licenses/by-nc-sa/3.0/), which permits use, distribution and reproduction for non-commercial purposes, provided the original is properly cited and derivative works building on this content are distributed under the same license.

IntechOpen

IntechOpen