

We are IntechOpen, the world's leading publisher of Open Access books Built by scientists, for scientists

6,900

Open access books available

186,000

International authors and editors

200M

Downloads

Our authors are among the

154

Countries delivered to

TOP 1%

most cited scientists

12.2%

Contributors from top 500 universities



WEB OF SCIENCE™

Selection of our books indexed in the Book Citation Index
in Web of Science™ Core Collection (BKCI)

Interested in publishing with us?
Contact book.department@intechopen.com

Numbers displayed above are based on latest data collected.
For more information visit www.intechopen.com



Immunological Analysis of Liver Diseases with Liver Biopsy Specimens

Kazuto Tajiri¹ and Yukihiro Shimizu²

¹*The Third Department of Internal Medicine, University of Toyama, Toyama*

²*Gastroenterology Unit, Takaoka City Hospital, Toyama
Japan*

1. Introduction

Most liver diseases are caused by host immune responses, and there have been many studies on the analysis of circulating lymphocyte subsets and their production of cytokines in patients with liver diseases. Although circulating lymphocytes are relatively easy to obtain and analyze, analysis of intrahepatic lymphocytes would be more important for understanding the immunopathogenesis of liver diseases, especially, viral hepatitis and autoimmune liver diseases.

Two approaches are currently available to analyze intrahepatic lymphocytes in liver biopsy specimens, an immunohistochemical approach and a flow cytometric analysis of isolated lymphocytes from liver tissues. Although use of an immunohistochemical approach would allow the distribution of particular lymphocyte subsets to be determined, quantitative estimation of infiltrating lymphocyte populations may be incorrect. In contrast, flow cytometry can determine the precise percentages of each lymphocyte population, but it does not provide any information on their intrahepatic distribution. The use of multiple antibodies to identify lymphocyte subsets can enable multi-color flow cytometric analysis, revealing the precise percentages of each subset, even those constituting an extremely minor subset of lymphocytes. Moreover, molecular biological approaches have been used to analyze the immunopathogenesis of liver diseases.

This chapter summarizes findings obtained from the immunological analyses of biopsied liver tissues and how immunological analyses of liver biopsy specimens have contributed to the understanding of the immunopathogenesis of liver diseases. We also describe recent technical advances in the immunological analyses of liver biopsy specimens that can further enhance our understanding of the pathogenesis of liver diseases.

2. Methods for analyzing immunological responses in the liver

2.1 Immunohistochemical approach (Luttmann et al., 2006)

Immunohistochemical methods can be used to characterize and localize liver-infiltrating cells and proteins such as cytokines, as well as quantitate their degree of infiltration, information essential for the analysis of local immune responses. Paraffin-fixed and frozen liver biopsy specimens, as well as specimens fixed by other methods, can be analyzed, although the immunogenicity of some antigens can be usually better preserved by cryofixation than by

chemical fixation. The underlying principle of the immunohistochemical approach is the binding of an antigen by a specific antibody (the first antibody). The first antibody is usually labeled with a fluorochrome, enzyme, or particle. If an unlabeled antibody is used, the secondary antibody must be labeled. Staining with labeled primary antibodies results in better detection of antigens, with less nonspecific background staining. Although high concentrations of antibodies can detect small amounts of antigens, higher antibody concentrations are associated with increased nonspecific binding. Therefore, the specific detection of each antigen requires the optimal dilution of each antibody as well as an optimal incubation period and temperature. As an example, we describe the immunohistochemical detection of antigen, using both a primary and a secondary antibody, in paraffin-fixed tissue samples.

Paraffin-fixed tissue samples must firstly be deparaffinized and rehydrated. Sections are then immersed in 10 mM citrate buffer, pH 6.0, and heated in a microwave oven for antigen retrieval. Alternatively, sections can be heated in a water bath, autoclave, or steam pot, or incubated with proteolytic enzymes, for antigen retrieval. After quenching endogenous peroxidase activity with 0.3% H₂O₂ in methanol, the sections are incubated with non-specific proteins, such as normal horse serum or bovine serum albumin, to inhibit non-specific finding. The sections are subsequently incubated with primary antibodies, either for 30 min at room temperature or overnight at 4°C, with shorter incubation periods usually effective for the detection of specific antigen-antibody binding. After rinsing in PBS three times, the sections are incubated with biotinylated secondary antibody for 60 min at room temperature, followed by treatment with peroxidase-labeled streptavidin for 20 min. Peroxidase activity is developed with 0.25 mg/ml 3,3'-diaminobenzidine tetrahydrochloride in the presence of 0.003% hydrogen peroxide in 0.05 M Tris-buffered saline, pH 7.4, and the sections are counterstained for nuclei in hematoxylin.

2.2 Gene expression associated with immune responses in liver biopsy specimen

In situ hybridization can be used to analyze the expression of specific genes in liver biopsy specimens. In addition, the distribution of expression of specific genes in these samples can be analyzed by in situ hybridization followed by counter staining for cells and organelles.

In situ hybridization can be performed using both isotope-labeled and non-isotope-labeled probes. We briefly describe a non-isotope-labeled method. Tissue samples are digested with proteinase and incubated overnight with digoxigenin-labeled riboprobes at 55°C. The slides are then washed in sodium dodecyl sulphate in saline sodium citrate and finally in Tris buffered saline containing 0.1% Tween 20 and 1% fetal calf serum (FCS). The tissue samples are subsequently incubated with an alkaline phosphatase conjugated antibody against digoxigenin. Signal is detected using 5-bromo-4-chloro-3-indoyl phosphatase as a substrate and nitro blue tetrazolium as a coupler.

2.3 Characterization of the phenotypes of isolated intrahepatic lymphocytes (IHLs)

IHLs can be isolated from liver biopsy specimens by enzymatic digestion and density gradient centrifugation (Hata et al., 1990, Doherty et al., 1999). Briefly, tissue samples are minced into 1 mm² pieces and incubated while rotating for 20 min at 37°C in Hank's Balanced Salt Solution (HBSS) containing 0.5 mg/ml collagenase, 0.02 mg/ml DNase, 2% FCS and 0.6% bovine serum albumin (BSA). Undigested tissue is removed by filtration

through a 100 μm diameter mesh and the cells are washed twice with HBSS. Hepatocytes are removed by centrifugation at $30 \times g$ for 1 min and the remaining cells are collected and resuspended in RPMI medium containing 10% FCS. Cell yields and viabilities are determined by microscopic examination of ethidium bromide/acridine orange stained preparations. Yields are usually about $1\text{--}2 \times 10^6$ mononuclear cells per 200 mg tissue sample, a sufficient number of cells for further analyses.

The phenotype, cytotoxicity (Hata et al., 1990) and cytokine production (Doherty et al., 1999) of isolated IHLs can be analyzed by flow cytometry. Moreover, multi-color flow cytometric analyses can identify minor populations of lymphocytes and intracytoplasmic cytokines. The function of IHLs present in liver biopsy specimens can therefore be analyzed in detail, resulting in a comprehensive understanding of intrahepatic immune responses in liver diseases.

2.4 Further application of immunological analysis

RNA and DNA in liver biopsy specimens can be isolated using commercial kits, followed by PCR or RT-PCR for the quantitative evaluation of DNA or RNA encoding proteins associated with the immune system.

Recent advances in microarray technology can be also applied to liver biopsy samples. Tissue microarrays are constructed by transferring cores of paraffin-embedded tissue to precored holes in a recipient paraffin block (Kononen et al., 1998). Microarray analysis enables the evaluation of the expression of multiple genes in liver biopsy specimens in a high throughput manner.

3. Immunological analysis in liver diseases

Intrahepatic immune responses have been analyzed in liver biopsy specimens, enhancing our understanding of the immunopathogenesis of liver diseases.

3.1 Acute viral hepatitis

Immunological analysis has been extensively performed in transgenic mouse and chimpanzee models of acute infection. In one model, transgenic mice, in which infectious HBV virions replicate in the livers with all HBV-related antigens expressed, were injected with HBsAg-specific cytotoxic T lymphocytes (CTLs) that had been induced in nontransgenic mice. The transgenic mice produced interferon (IFN)- γ and tumor necrosis factor (TNF)- α , which purged viral RNA and DNA without destroying infected hepatocytes (Guidotti et al., 1996, Chisari, 1997, Guidotti et al., 2001). Importantly, this noncytolytic clearance of intracellular HBV is more efficient at controlling HBV replication than the killing of infected hepatocytes. In this sense, hepatitis is not only a harmful event but also represents an effective mechanism by which CTLs suppress HBV. Noncytolytic viral eradication can account for recovery from acute HBV infection, in that most HBV is cleared from hepatocytes with only a fraction of the hepatocytes being destroyed. This phenomenon was confirmed using a chimpanzee infection model. HBV-DNA was profoundly decreased in the liver and blood of acutely infected chimpanzees before peak serum alanine aminotransferase (ALT) concentrations were reached (Guidotti et al., 1999), suggesting that this noncytopathic T cell effector mechanism results in early viral inhibition or eradication, whereas a cytopathic T cell effector mechanism would be required to eliminate the remaining virus by destroying infected hepatocytes.

There have been a limited number of immunological analyses of local immune responses in the liver of patients with acute viral hepatitis, due primarily to relative contraindications for liver biopsy in these patients. Moreover, the kinetics of local immune response cannot be analyzed in humans, because repeated liver biopsies are not usually required and are ethically not allowed during the course of acute hepatitis.

The CD4/CD8 ratio of liver-derived T cell clones was found to be 0.3-0.5 during the acute phase of HAV infection, indicating a CD8+ T cell predominance, but 1.2 during the recovery phase, indicating a CD4+ T cell predominance (Fleischer et al., 1990). Half of the T cell clones showed cytotoxicity against HAV-infected autologous fibroblasts, further suggesting that the intrahepatic HAV-specific T cell response has an important role in the pathogenesis of acute hepatitis A and in viral eradication.

Immunohistochemical analysis of intrahepatic lymphocyte populations in patients with acute hepatitis A, B and C showed that CD45RO+ memory T cells were the most prominent cell population in all 3 types of acute hepatitis, and that the numbers of these cells were significantly higher in portal areas of patients with acute hepatitis C than in those with acute hepatitis B (Hashimoto et al., 1996). In addition, the ratio of CD20+ B cells to CD45RO+ memory T cells was significantly lower in acute hepatitis B than in the two other types of acute hepatitis (Hashimoto et al., 1996). These data indicate that memory T cells are involved in the immunopathogenesis of all types of acute viral hepatitis. However, the clinical significance of the differences among acute hepatitis A, B and C remains unclear.

Recently, the signal delivered by a CD28 superfamily, programmed death-1 (PD-1) protein, was shown to impair virus-specific CD8+ T-cell responses during chronic viral infection (Watanabe et al., 2010), suggesting that this protein plays an important role in insufficient T cell responses against hepatitis viral antigen, leading to persistent viral infection. In patients with acute hepatitis C, PD-1 expression was higher on CD4+ than on CD8+ T cells in the liver, with expression more prominent on intrahepatic than on peripheral blood lymphocytes. However, no correlation was observed between PD-1 expression on T cells and clinical outcomes in patients with acute viral hepatitis (Kasprowicz et al., 2008).

PD-1 expression is thought to be regulated during acute hepatitis, with PD-1 up-regulated on CD8+ T cells during the early phase of acute hepatitis B (Zhang et al., 2008). Successful viral clearance correlated with a subsequent decrease in PD-1 expression, and the delayed PD-1 expression on HBV-specific CD8+ T cells was associated with acute liver failure (Zhang et al., 2008), suggesting that impaired regulation of PD-1 expression may lead to enhanced immune response and severe hepatitis.

In summary, intrahepatic viral-specific memory T cells are directly involved in the immunopathogenesis of acute viral hepatitis, and the kinetics of PD-1 expression in the liver may determine patient outcomes. However, there is limited information on the characterization of intrahepatic lymphocytes and on local immune responses in the liver in patients with acute viral hepatitis.

3.2 Chronic hepatitis

There are few animal models of chronic hepatitis, and most of our knowledge regarding its immunopathogenesis is derived from analyses of human liver tissues. Because local immune responses cannot be analyzed over time in patients, however, findings obtained from animal models may help enhance our understanding of the kinetics of immune responses in the liver.

Many studies have analyzed intrahepatic lymphocytes in patients with chronic hepatitis, both immunohistochemically and by flow cytometry. Most of these studies analyzed the makeup of infiltrating cells, the expression of costimulatory molecules in the liver and the antigen specificity of infiltrating T cells. These results have greatly contributed to understanding the immunopathogenesis of various chronic liver diseases.

3.2.1 Composition of infiltrating cells

Chronic hepatitis is characterized by lymphoid cell infiltration mainly in portal tracts. Most infiltrating cells are CD3+ T cells, with most of the latter being CD45RO+ memory cells. The CD4/CD8 ratio is similar in patients with hepatitis B and C; 50-60% of infiltrating cells are CD4+ helper T lymphocytes, around 25% are CD8+ CTLs and 15% are B lymphocytes. CD8+ T lymphocytes are located in the peripheral part of portal tracts and intralobular necrotic foci (Walewska-Zielecka et al., 2008). Natural killer cells are also involved in the immunopathogenesis of chronic hepatitis, with CD3-CD56^{bright}NKG2A+ cells associated with necroinflammation of the liver and CD3-CD56^{dim}NKG2A+ cells associated with low viral load (Bonorino et al., 2009).

The percentages of virus-specific T lymphocytes in the liver have been clarified by immunohistochemical staining with peptide-MHC tetramer. The proportion of CD8+T lymphocytes in the livers of patients with chronic HBV specific for HBc18-27, a major HBV epitope, has been found to range from 0.18% to 1.28% (Shimada et al., 2003). In patients with chronic hepatitis C, 1-2% of CTLs in the liver were found to be HCV NS3-specific, compared with 0.01% to 1.2% of PBLs (He et al., 1999). Due to the low percentages of lymphocyte populations specific for viral epitopes, most intrahepatic lymphocytes are thought to be antigen-nonspecific. The contribution of virus-specific and -nonspecific cells to hepatocyte damage and viral control in chronic viral hepatitis in humans remains unclear. However, in the HBV transgenic mouse model of acute hepatitis, administration of antibodies against the chemokines, IFN-gamma inducible protein (IP-10) and monokine induced by interferon-gamma (Mig) reduced the recruitment of mostly Ag-nonspecific mononuclear cells into the liver that had been induced by cytokines and chemokines produced by injected CTLs, leading to a reduction in the severity of hepatitis without affecting the antiviral activity of the CTLs (Kakimi et al., 2001). The findings indicate that CTLs can suppress virus without damaging hepatocytes, whereas secondarily recruited mononuclear cells, with little antiviral activity, destroy hepatocytes in an Ag-nonspecific manner.

In humans, several cytokines and chemokines are thought to be involved in the recruitment of T lymphocytes into the liver. For example, intrahepatic levels of IP-10/CXCL10 and Mig/CXCL19 have been reported to correlate with liver inflammation and fibrosis in the livers of patients with chronic hepatitis C (Zeremski et al., 2008). Moreover, their receptor, CXCR3, is expressed on most intrahepatic T lymphocytes, indicating that chemokine/receptor systems have an important role in T cell recruitment into inflamed livers. We have reported that Mip3 α produced by DCs after phagocytosis of apoptotic cells is chemotactic for CCR6-expressing CD4+ T lymphocytes, but not for CD8+ T lymphocytes (Shimizu et al., 2001). A complex chemokine/chemokine receptor network is therefore present in the livers of patients with chronic hepatitis, and manipulation of this network may control the magnitude of liver inflammation.

3.2.2 Chronic hepatitis B

Several studies have characterized CD4+ T lymphocytes in patients with chronic hepatitis B. For example, these livers have been found to contain Th0 cells, which produce not only IFN-

γ , but also IL-4 and IL-5, thus differing from cells in the livers of patients with chronic hepatitis C, which are mostly Th1 cells (Bertoletti et al., 1997). CD4⁺ T lymphocytes that produce TNF- α and IL-17 infiltrate into the livers of patients with chronic hepatitis B and are involved in liver inflammation (Zhang et al., 2010). IL-17 producing CD4⁺ T lymphocytes, called Th17 cells, are a third distinct subset of T helper cells and play an important role in innate and adoptive immunity and in autoimmunity. In a transgenic mouse model, CD4⁺ T lymphocytes, as well as CD8⁺ T lymphocytes, have been shown effective for noncytolytic viral purge by secreting TNF- α and IFN- γ (Franco et al., 1997).

Although noncytolytic antiviral mechanism mediated by T lymphocytes was first described in a transgenic mouse model (Guidotti et al., 1996), a similar phenomenon was recently observed in the livers of patients with chronic hepatitis B.

The natural history of chronic HBV infection is somewhat complex. Most people infected at birth are asymptomatic during their first 20-30 years, called the immune tolerant phase. This tolerant phase later breaks down, resulting in ALT flare-ups due to activation of the immune response against HBV. After an ALT flare, 80-90% of chronically infected patients experience a great reduction, but not a diminishing, of HBV replication, these patients seroconvert, from HBeAg to anti-HBe antibody, and become inactive carriers. In the other 10-20% of chronically infected patients, ALT remains elevated and active HBV replication persists, resulting in disease progression to chronic hepatitis, liver cirrhosis and hepatocellular carcinoma. Although the precise pathogenetic mechanisms differentiating inactive carriers from chronic hepatitis patients are unclear, recent immunological analyses have provided new insights into the understanding of these mechanisms.

Livers of patients with low HBV replication contain intralobular CD8⁺ T lymphocytes (Tang et al., 2003), suggesting that the host immune system recognizes viral antigens and may carry out immune surveillance in the livers of inactive carriers. Moreover, the same numbers of HBcAg-specific CD8⁺ T lymphocytes are present in the livers of individuals with high viral replication/elevated serum ALT and low viral load/normal ALT (Maini et al., 2000), suggesting that HBV-specific CD8⁺ T cells effectively control viral replication without damaging infected hepatocytes in inactive carriers, but fails to do so in patients with chronic hepatitis. Although the mechanism underlying this failure of viral control remains unclear, two possible mechanisms have been hypothesized, one involving regulatory T cells and the other involving the costimulatory molecule, PD-1. Regulatory T cells (Tregs) expressing the transcription factor Foxp3 are specialized cells that exert negative control on a variety of physiological and pathological immune responses, resulting in maintenance of immunological self-tolerance (Miyara et al., 2011). Circulating and intrahepatic Tregs are involved in persistent infection by hepatitis virus. CD4⁺CD25⁺ cells and Foxp3⁺ cells are increased in the livers of patients with chronic hepatitis B (Xu et al., 2006), and patients with high viral load have a higher proportion of Tregs in the liver (Stoop et al., 2008), suggesting that intrahepatic Tregs suppress antiviral immune responses in the liver.

PD-1 is a surface receptor critical for the regulation of T cell function (Francisco et al., 2010, Fife BT et al., 2011). The binding to PD-1 by its ligands PD-L1 and PD-L2 results in the antigen-specific inhibition of T-cell proliferation, cytokine production, and cytolytic function. In the liver, PD-1 is expressed on lymphocytes; PD-L1 is expressed on lymphocytes, hepatocytes and sinusoidal endothelial cell; and PD-L2 is expressed on Kupffer cells and DCs (Chen et al., 2010). Intrahepatic HBV-specific CD8⁺ T cells express higher levels of PD-1, and upregulation of intrahepatic PD-1/PD-L1 is associated with liver inflammation and ALT elevation (Fisicaro et al., 2010, Xie et al., 2009). Although the

mechanism underlying the upregulation of PD-1 on CD8⁺ T cells in inflamed livers is unknown, signals from PD-1 inhibit HBV-specific T cells, resulting in insufficient antiviral responses and liver inflammation. Importantly, PD-1/PD-L1 blockade increased CD8⁺ T cell proliferation and enhanced IFN- γ and IL-2 production by intrahepatic lymphocytes (Fisicaro et al., 2010). These findings suggest that inhibiting PD-1/PD-L1 may have therapeutic potential for the control of hepatitis B.

Local immune response is also regarded as important during the treatment of hepatitis B. The numbers of pretreatment intrahepatic CD8⁺ T cells has been shown to predict better responses to IFN- α and lamivudine (Tang et al., 2004, 2005).

3.2.3 Chronic hepatitis C

The local immune response occurring in the livers of patients with chronic hepatitis C is similar to that in chronic hepatitis B. Intrahepatic CD4⁺ T cells, most of which are Th1 cells producing IFN- γ but not IL-4 and IL-5 (Bertoletti et al., 1997), are located in portal and periportal areas, with the proportions of these cells correlating with histological activity index (Fiore et al., 1997). However, no correlation has been found between the proportion of intrahepatic CD4⁺ T cells and viremia or serum ALT levels (Tran et al., 1997). Most intrahepatic CD4⁺ T cells in the livers of patients with chronic hepatitis C are CD45RO⁺, but the percentages of CD4⁺CD27⁺ and CD4⁺CD28⁺ T cells are lower (Wang et al., 2006), suggesting that memory T cells at relatively early stages of differentiation are involved in liver inflammation.

In patients with chronic hepatitis C, CD8⁺ T cells are located in the lobules within areas of inflammation and spotty necrosis, with the proportion correlating with histological activity index (Fiore et al., 1997). Intrahepatic CD8⁺ T cells show higher percentages of CCR7⁺L-selectin⁺ cells, which are distinct from central memory and effector memory cells (Heydtmann et al., 2006). The CCR7 ligands CCL19 and CCL21 are expressed on sinusoidal endothelial cells, suggesting a mechanism of CD8⁺ T cell recruitment to the inflamed liver. Other chemokine receptors that mediate T cell recruitment are CCR5 and CXCR3 (Larrubia et al., 2007). Although the numbers of intrahepatic CD8⁺ T cells were reported to correlate with serum enzyme concentrations, and intralobular CD8⁺ T cells showed weak correlation with serum ALT concentrations (Freeman et al., 2003), intrahepatic HCV-specific CD8⁺ T cells do not secrete IFN- γ but secrete IL-10, an immunosuppressive cytokine (Spangenberg et al., 2005). The presence of these IL-10 secreting T cells is associated with low levels of hepatocyte apoptosis, ALT and fibrosis (Abel et al., 2006). Increased production of IL-10, but not IFN- γ , may result in an insufficient anti-HCV response in the liver.

Similar to intrahepatic T cells in patients with chronic hepatitis B, intrahepatic HCV-specific cells were found to express high levels of PD-1 (Radziejewicz et al. 2007), which may be responsible for the absence of IFN- γ production, as well as poor proliferation and low cytolytic activity. Moreover, large numbers of Foxp3⁺ cells, mostly CD4⁺ T cells, are present in the portal tracts of the livers of patients with chronic hepatitis C (Ward et al., 2007, Claassen et al., 2010, Sturm et al., 2010). These cells are also in contact with CD8⁺ T cells in necro-inflammatory areas, suggesting that CD8⁺ T cells are inhibited by cell-cell contact with Tregs (Sturm et al., 2010). These immunosuppressive mechanisms present in the livers of patients with chronic hepatitis C may be responsible for persistent HCV infection despite the presence of HCV-specific T cells in the liver.

In addition to T cells, livers of patients with chronic hepatitis C often contain lymphoid follicles in portal tracts, a characteristic of HCV-infected livers. We previously reported that functional and clonal expansion of B cells occurs in lymphoid follicles with germinal centers in HCV-infected livers (Murakami et al., 1999), although the antigen specificity of these B cells is unclear.

Local immune responses may be involved in viral eradication during patient treatment with IFN. The numbers of pretreatment CD8⁺ T cells in portal tracts and intrahepatic HCV-specific CD8⁺ CTLs have been reported associated with a better response to IFN- α or a sustained virological response (Nelson et al., 1998, Vrolijk et al., 2003). Therefore, upregulation of intrahepatic T cell response may enhance the effectiveness of antiviral treatment.

3.3 Autoimmune liver disease

The dominant population of intrahepatic T cells in patients with primary biliary cirrhosis has been reported to be CD4⁺TCR $\alpha\beta$ ⁺ T cells, whereas the dominant population in patients with chronic hepatitis B and C has been reported to be CD8⁺TCR $\alpha\beta$ ⁺ T cells (Löhr et al., 1994). This finding, however, remains controversial and it does not help distinguish autoimmune liver disease from viral hepatitis.

3.3.1 Primary biliary cirrhosis (PBC) and primary sclerosing cholangitis (PSC)

The liver histology of patients with PBC has been extensively analyzed. A characteristic early stage histologic feature in these patients is nonsuppurative destructive cholangitis. Although the biliary epithelium is thought to be the target for host immune responses, the mechanism underlying epithelial destruction is unclear. CD8⁺ T cells are present within the bile duct epithelial layer of patients with chronic nonsuppurative destructive cholangitis, suggesting that CTLs destroy the bile duct epithelium. B7-2 (CD86), but not B7-1 (CD80), expression has been observed in bile duct epithelium during early stages of PBC and PSC (Tsuneyama et al., 1998), suggesting that bile duct epithelium may act as antigen-presenting cells. Immunopathologically important target antigens have not been determined. Although the generation of anti-mitochondrial antibodies is important for the diagnosis of PBC, mitochondrial antigens are not thought to be the pathogenetic target for immune cells. Livers of patients with PBC have been reported to contain more Tregs than livers of patients with autoimmune hepatitis (Sasaki et al., 2008), with Tregs infiltrating into the biliary epithelial layer during chronic nonsuppurative destructive cholangitis (Sasaki et al., 2007). Moreover, the numbers of Foxp3⁺ Tregs were found to parallel the degree of portal inflammation. These results, showing the presence of Tregs in the livers of patients with PBC and that their regulatory functions are not reduced in the livers of patients with PBC and PSC, suggest that autoimmunity in PBC is not due to a reduction in Treg function.

PD-1 expression has also been assayed in livers of patients with PBC. PD-1 is expressed on more than 50% of intrahepatic T lymphocytes in the portal tracts, but their levels of expression are lower than in patients with autoimmune hepatitis (Oikawa et al., 2007).

3.3.2 Autoimmune hepatitis (AIH)

CD4⁺ T cells and CD20⁺ B cells have been reported to be located in the center of portal areas, with CD8⁺ T cells at the periphery of the portal area (De Biasio et al., 2006). Although

CD4⁺ T cells constitute the major population of intrahepatic lymphocytes, many CD80⁺, CD86⁺ and CD152⁺ cells are present in the livers of patients with autoimmune hepatitis (Kurokuchi et al., 2006). Moreover, patients with high levels of intrahepatic CD86⁺ cells showed good responses to corticosteroids (Kurokuchi et al., 2006).

One of the putative target antigens in the immunopathogenesis of autoimmune hepatitis is asialoglycoprotein receptor, and antibodies against this receptor are often present in patients with autoimmune hepatitis. Although the mechanism of antibody production is unknown, intrahepatic T helper cells in patients with autoimmune hepatitis can stimulate the production of the autoantibody. Few Tregs are observed in these livers, with those present having impaired function (Longhi et al., 2010), suggesting that decreased functional activity of Tregs may predispose to enhanced autoimmune reactions.

3.4 Nonalcoholic fatty liver disease

Nonalcoholic fatty liver disease (NAFLD) is a frequently occurring chronic liver disease and can range in intensity from simple steatosis to nonalcoholic steatohepatitis (NASH). Due to chronic necro-inflammatory changes, patients with NASH may develop cirrhosis or hepatocellular carcinoma, although these are rare in patients with simple steatosis. Histologically, steatosis (usually >5% per liver tissue section), cellular injury such as ballooned hepatocytes or Mallory-Denk bodies, and accompanying lobular inflammation are observed in the livers of patients with NAFLD. Inflammatory infiltrates in these livers consist predominantly of lymphocytes, as well as plasma cells and polymorphonuclear leucocytes in portal tracts of the liver (Brunt et al., 2010). The 'two-hit theory' is widely accepted in the pathogenesis of NAFLD, and patients with simple steatosis are regarded as not showing disease progression because of the absence of the second hit (Day et al., 1998). Adipocytokines from adipose tissue and gut-derived factors (i.e. endotoxin) are regarded as the principal pathogenetic factors, the second hits, in the disease progression of NAFLD (Tilg et al., 2010), but recent reports have revealed that immunological mechanisms are directly involved in its pathogenesis. An immunohistochemical analysis of liver biopsy specimens showed that cells of the innate immune system, including neutrophils, macrophages (Kupffer cells) and NKT cells, are involved in the pathogenesis of NAFLD. Livers of patients with NASH showed increased hepatic neutrophil infiltration and increased hepatic expression of mRNAs coding for proinflammatory cytokines, as determined by quantitative RT-PCR. Furthermore, activation of the complement system in the liver is associated with the severity of NAFLD (Rensen et al., 2009). In rodent models of NAFLD, activation of Kupffer cells and proinflammatory cytokines are involved in disease progression (Maher et al., 2008, Syn et al., 2009). Kupffer cells are thought to be activated by gut-derived factors, adipocytokines and apoptotic cells, and to produce proinflammatory cytokines and reactive oxygen species (ROS). Proinflammatory cytokines and ROS may induce insulin resistance, which is regarded as important in the development of NAFLD. In addition, recent studies by our group and others have found that accumulation of NKT cells in the liver is associated with disease progression to NASH (Fig. 1), suggesting that NKT cells may contribute to disease progression in NAFLD (Tajiri et al., 2009, Syn et al., 2010). CD1d, a molecule essential for the activation and maintenance of NKT cells (Godfrey et al., 2004), is highly expressed on activated macrophages in the livers of NASH patients (Tajiri et al., 2009), suggesting that NKT and Kupffer cells may interact during the pathogenesis of NAFLD (Fig. 2).

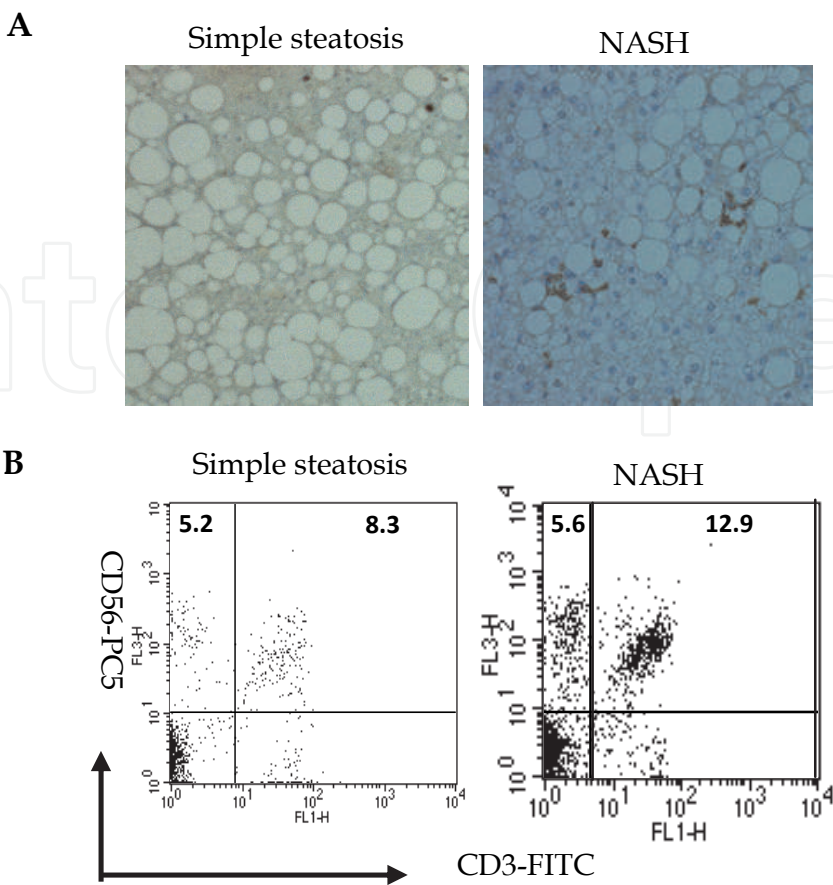
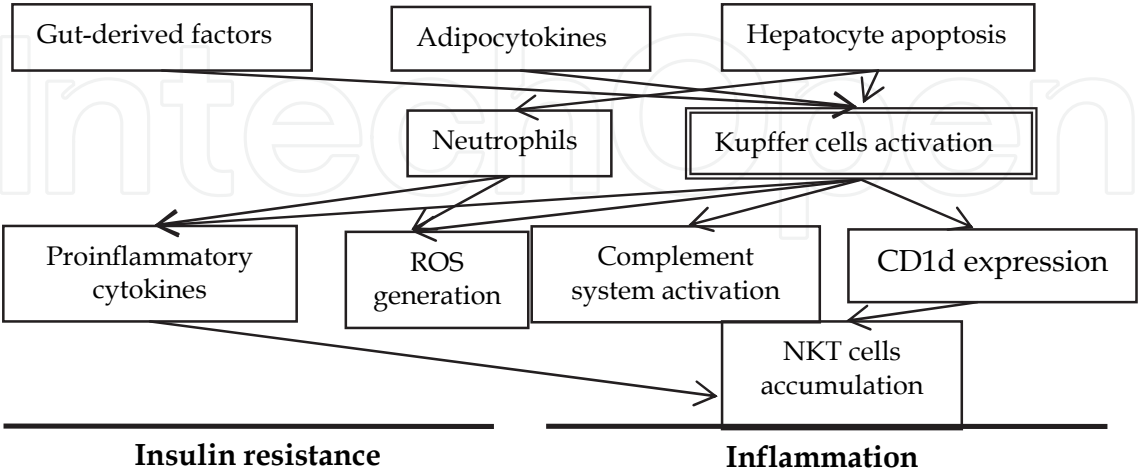


Fig. 1. Immunological analysis of liver biopsy specimens in patients with NAFLD. (A) Samples were stained with monoclonal antibody against CD56 in patients with (left panel) simple steatosis and (right panel) NASH. (B) Flow cytometric analysis of mononuclear cells isolated from livers of patients with (left panel) simple steatosis and (right panel) NASH. The numbers in each quadrant represent the percentages of mononuclear cells. Right-upper quadrant represents NKT (CD3+CD56+) cells.



ROS: reactive oxygen species

Fig. 2. Hypothesis of the pathogenesis of NAFLD.

4. Conclusion

Although analysis of intrahepatic immune response is difficult to be performed, valuable information on the immunopathogenesis of liver diseases could be obtained. Accumulation of the findings would finally lead to a novel immunotherapeutic approach for the management of various liver diseases.

5. References

- Abel, M; Sène, D; Pol, S; Bourlière, M; Poynard, T; Charlotte, F; Cacoub, P & Caillat-Zucman, S. (2006). Intrahepatic virus-specific IL-10-producing CD8 T cells prevent liver damage during chronic hepatitis C virus infection. *Hepatology*, Vol.44, No.6, (December 2006), pp. 1607-1616.
- Bertoletti, A; D'Elia, MM; Boni, C; De Carli, M; Zignego, AL; Durazzo, M; Missale, G; Penna, A; Fiaccadori, F; Del Prete, G & Ferrari, C. (1997). Different cytokine profiles of intrahepatic T cells in chronic hepatitis B and hepatitis C virus infections. *Gastroenterology*, Vol.112, No.1, (January 1997), pp. 193-199.
- Bonorino, P; Ramzan, M; Camous, X; Dufeu-Duchesne, T; Thélou, MA; Sturm, N; Dariz, A; Guillermet, C; Pernollet, M; Zarski, JP; Marche, PN; Leroy, V & Jouvin-Marche, E. (2009). Fine characterization of intrahepatic NK cells expressing natural killer receptors in chronic hepatitis B and C. *J Hepatol*, Vol.51, No.3, (June 2009), pp. 458-467.
- Brunt, EM & Tiniakos, DG. Histopathology of nonalcoholic fatty liver disease. (2010). *World J Gastroenterol*, Vol.16, No.42, (November 2010), pp. 5286-5496.
- Chen, J; Wang, XM; Wu, XJ; Wang, Y; Zhao, H; Shen, B & Wang, GQ. (2010). Intrahepatic levels of PD-1/PD-L correlate with liver inflammation in chronic hepatitis B. *Inflamm Res*, 2010 Jul 27. [Epub ahead of print]
- Chisari FV. (1997). Cytotoxic T cells and viral hepatitis. *J Clin Invest*, Vol.99, No.7, (April 1997), pp. 1472-1477.
- Claassen, MA; de Knecht, RJ; Tilanus, HW; Janssen, HL & Boonstra, A. (2010). Abundant numbers of regulatory T cells localize to the liver of chronic hepatitis C infected patients and limit the extent of fibrosis. *J Hepatol*, Vol.52, No.3, (December 2009), pp. 315-321.
- Day, CP & James, OF. (1998). Steatohepatitis: a tale of two "hit"? *Gastroenterology*, Vol.114, No.4, (April 1998), pp. 842-845.
- De Biasio, MB; Periolo, N; Avagnina, A; García de Dávila, MT; Ciocca, M; Goñi, J; de Matteo, E; Galoppo, C; Cañero-Velasco, MC; Fainboim, H; Muñoz, AE; Fainboim, L & Chernavsky, AC. (2006). Liver infiltrating mononuclear cells in children with type 1 autoimmune hepatitis. *J Clin Pathol*, Vol.59, No.4, (February 2006), pp. 417-423.
- Doherty, DG; Norris, S; Madrigal-Estebas, L; McEntee, G; Traynor, O; Hegarty, JE, & O'Farrelly, C. (1999). The human liver contains multiple populations of NK cells, T cells, and CD3+CD56+ natural T cells with distinct cytotoxic activities and Th1, Th2, and Th0 cytokine secretion patterns. *J Immunol*, Vol.163, No.4, (August 1999), pp. 2314-2321.
- Fife, BT & Pauken, KE. (2011). The role of the PD-1 pathway in autoimmunity and peripheral tolerance. *Ann N Y Acad Sci*, Vol.1217, (January 2011), pp. 45-59.

- Fiore, G; Angarano, I; Caccetta, L; Serrone, M; Jirillo, E; Schiraldi, O & Antonaci, S. (1997). In-situ immunophenotyping study of hepatic-infiltrating cytotoxic cells in chronic active hepatitis C. *Eur J Gastroenterol Hepatol*, Vol.9, No.5, (May 1997), pp. 491-496.
- Fisicaro, P; Valdatta, C; Massari, M; Loggi, E; Biasini, E; Sacchelli, L; Cavallo, MC; Silini, EM; Andreone, P; Missale, G & Ferrari, C. (2010). Antiviral intrahepatic T-cell responses can be restored by blocking programmed death-1 pathway in chronic hepatitis B. *Gastroenterology*. Vol.138, No.2, (September 2009), pp. 682-693, 693.e1-4.
- Fleischer, B; Fleischer, S; Maier, K; Wiedmann, KH; Sacher, M; Thaler, H & Vallbracht, A. (1990). Clonal analysis of infiltrating T lymphocytes in liver tissue in viral hepatitis A. *Immunology*, Vol.69, No.1, (January 1990), pp. 14-19.
- Francisco, LM; Sage, PT & Sharpe, AH. (2010). The PD-1 pathway in tolerance and autoimmunity. *Immunol Rev*, Vol.236, (July 2010), pp. 219-242.
- Franco, A; Guidotti, LG; Hobbs, MV; Pasquetto, V & Chisari, FV. (1997). Pathogenetic effector function of CD4-positive T helper 1 cells in hepatitis B virus transgenic mice. *J Immunol*, Vol.159, No.4, (August 1997), pp. 2001-2008.
- Freeman, A; Pan, Y; Harvey, CE; Post, JJ; Law, MG; White, PA; Rawlinson, WD; Lloyd, AR; Marinos, G & Ffrench, RA. (2003). The presence of an intrahepatic cytotoxic T lymphocyte response is associated with low viral load in patients with chronic hepatitis C virus infection. *J Hepatol*, Vol.38, No.3, (March 2003), pp. 349-356.
- Godfrey, DI & Kronenberg, M. (2004). Going both ways: immune regulation via CD1d-dependent NKT cells. *J Clin Invest*, Vol.114, No.10, (November 2004), pp. 1379-1388.
- Guidotti, LG; Ishikawa, T; Hobbs, MV; Matzke, B; Schreiber, R & Chisari, FV. (1996). Intracellular inactivation of the hepatitis B virus by cytotoxic T lymphocytes. *Immunity*, Vol.4, No.1, (January 1996), pp. 25-36.
- Guidotti, LG; Rochford, R; Chung, J; Shapiro, M; Purcell, R & Chisari, FV. (1999). Viral clearance without destruction of infected cells during acute HBV infection. *Science*, Vol.284, No.5415, (April 1999), pp. 825-829.
- Guidotti, LG & Chisari, FV. (2001). Noncytolytic control of viral infections by the innate and adaptive immune response. *Annu Rev Immunol*, Vol.19, pp. 65-91.
- Hashimoto, E; Kojimahara, N; Noguchi, S; Taniai, M; Ishiguro, N & Hayashi, N. (1996). Immunohistochemical characterization of hepatic lymphocytes in acute hepatitis A, B, and C. *J Clin Gastroenterol*, Vol.23, No.3, (October 1996), pp. 199-202.
- Hata, K; Zhang, XR; Iwatsuki, S; Van Thiel, DH; Herberman, RB & Whiteside, TL. (1990). Isolation, phenotyping, and functional analysis of lymphocytes from human liver. *Clin Immunol Immunopathol*, Vol.56, No.3, (September 1990), pp. 401-419.
- He, XS; Rehmann, B; López-Labrador, FX; Boisvert, J; Cheung, R; Mumm, J; Wedemeyer, H; Berenguer, M; Wright, TL; Davis, MM & Greenberg, HB. (1999). Quantitative analysis of hepatitis C virus-specific CD8(+) T cells in peripheral blood and liver using peptide-MHC tetramers. *Proc Natl Acad Sci U S A*, Vol.96, No.10, (May 1999), pp. 5692-5697.
- Heydtmann, M; Hardie, D; Shields, PL; Faint, J; Buckley, CD; Campbell, JJ; Salmon, M & Adams, DH. (2006). Detailed analysis of intrahepatic CD8 T cells in the normal and hepatitis C-infected liver reveals differences in specific populations of memory cells with distinct homing phenotypes. *J Immunol*, Vol.177, No.1, (July 2006), pp. 729-738.
- Kakimi, K; Lane, TE; Wieland, S; Asensio, VC; Campbell, IL; Chisari, FV & Guidotti, LG. (2001). Blocking chemokine responsive to gamma-2/interferon (IFN)-gamma

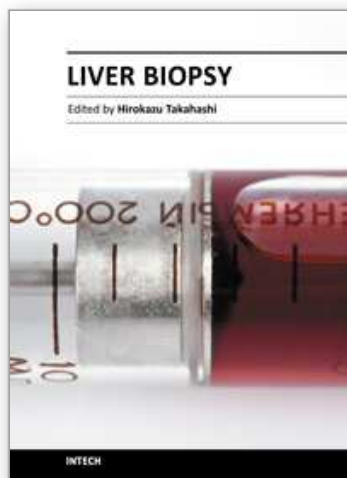
- inducible protein and monokine induced by IFN-gamma activity in vivo reduces the pathogenetic but not the antiviral potential of hepatitis B virus-specific cytotoxic T lymphocytes. *J Exp Med*, Vol.194, No.12, (December 2001), pp. 1755-1766.
- Kasprowicz, V; Schulze Zur Wiesch, J; Kuntzen, T; Nolan, BE; Longworth, S; Berical, A; Blum, J; McMahon, C; Reyor, LL; Elias, N; Kwok, WW; McGovern, BG; Freeman, G; Chung, RT; Klenerman, P; Lewis-Ximenez, L; Walker, BD; Allen, TM; Kim, AY & Lauer, GM. (2008). High level of PD-1 expression on hepatitis C virus (HCV)-specific CD8+ and CD4+ T cells during acute HCV infection, irrespective of clinical outcome. *J Virol*, Vol.82, No.6, (December 2007), pp. 3154-3160.
- Kononen, J; Bubendorf, L; Kallioniemi, A; Bärklund, M; Schraml, P; Leighton, J; Torhorst, J; Mihatsch, MJ; Sauter, G & Kallioniemi, OP. (1998) Tissue microarrays for high-throughput molecular profiling of tumor specimens. *Nat Med*, Vol.4, No.7, (July 1998), pp. 844-847.
- Kurokohchi, K; Masaki, T; Himoto, T; Deguchi, A; Nakai, S; Morishita, A; Yoneyama, H; Kimura, Y; Watanabe, S & Kuriyama, S. (2006). Usefulness of liver infiltrating CD86-positive mononuclear cells for diagnosis of autoimmune hepatitis. *World J Gastroenterol*, Vol.12, No.16, (April 2006), pp. 2523-2529.
- Larrubia, JR; Calvino, M; Benito, S; Sanz-de-Villalobos, E; Perna, C; Pérez-Hornedo, J; González-Mateos, F; García-Garzón, S; Bienvenido, A & Parra, T. (2007). The role of CCR5/CXCR3 expressing CD8+ cells in liver damage and viral control during persistent hepatitis C virus infection. *J Hepatol*, Vol.47, No.5, (May 2007), pp. 632-641.
- Löhr, HF; Schlaak, JF; Gerken, G; Fleischer, B; Dienes, HP & Meyer zum Büschenfelde, KH. (1994). Phenotypical analysis and cytokine release of liver-infiltrating and peripheral blood T lymphocytes from patients with chronic hepatitis of different etiology. *Liver*, Vol.14, No.3, (June 1994), pp. 161-166.
- Longhi, MS; Ma, Y; Mieli-Vergani, G; & Vergani, D. (2010). Aetiopathogenesis of autoimmune hepatitis. *J Autoimmun.* Vol. 34, No. 1, (September 2009), pp.7-14.
- Luttmann, W; Bratke, K; Kupper, M & Mytrek, D. (2006). *Immunology*. In situ Immunolocalization pp. 127-151, Elsevier.
- Maher, JJ; Leon, P & Ryan, JC. (2008). Beyond insulin resistance: innate immunity in nonalcoholic steatohepatitis. *Hepatology*, Vol.48, No.2, (August 2008), pp. 670-678.
- Maini, MK; Boni, C; Lee, CK; Larrubia, JR; Reignat, S; Ogg, GS; King, AS; Herberg, J; Gilson, R; Alisa, A; Williams, R; Vergani, D; Naoumov, NV; Ferrari, C & Bertolotti, A. (2000). The role of virus-specific CD8(+) cells in liver damage and viral control during persistent hepatitis B virus infection. *J Exp Med*, Vol.191, No.8, (April 2000), pp. 1269-1280.
- Miyara, M & Sakaguchi, S. (2011). Human FoxP3(+)CD4(+) regulatory T cells: their knowns and unknowns. *Immunol Cell Biol*, Vol.89, No.3, (February 2011), pp. 346-351.
- Murakami, J; Shimizu, Y; Kashii, Y; Kato, T; Minemura, M; Okada, K; Nambu, S; Takahara, T; Higuchi, K; Maeda, Y; Kumada, T & Watanabe, A. (1999). Functional B-cell response in intrahepatic lymphoid follicles in chronic hepatitis C. *Hepatology*, Vol.30, No.1, (July 1999), pp. 143-150.

- Nelson, DR; Marousis, CG; Ohno, T; Davis, GL & Lau, JY. (1998). Intrahepatic hepatitis C virus-specific cytotoxic T lymphocyte activity and response to interferon alfa therapy in chronic hepatitis C. *Hepatology*, Vol.28, No.1, (July 1998), pp. 225-230.
- Oikawa, T; Takahashi, H; Ishikawa, T; Hokari, A; Otsuki, N; Azuma, M; Zeniya, M & Tajiri H. (2007). Intrahepatic expression of the co-stimulatory molecules programmed death-1, and its ligands in autoimmune liver disease. *Pathol Int*, Vol.57, No.8, (August 2007), pp. 485-492.
- Radziewicz, H; Ibegbu, CC; Fernandez, ML; Workowski, KA; Obideen, K; Wehbi, M; Hanson, HL; Steinberg, JP; Masopust, D; Wherry, EJ; Altman, JD; Rouse, BT; Freeman, GJ; Ahmed, R & Grakoui, A. (2007). Liver-infiltrating lymphocytes in chronic human hepatitis C virus infection display an exhausted phenotype with high levels of PD-1 and low levels of CD127 expression. *J Virol*, Vol.81, No.6, (December 2006), pp. 2545-2553.
- Rensen, SS; Slaats, Y; Driessen, A; Peutz-Kootstra, CJ; Nijhuis, J; Steffensen, R; Greve, JW & Buurman, WA. (2009). Activation of the complement system in human nonalcoholic fatty liver disease. *Hepatology*, Vol.50, No.6, (December 2009), pp. 1809-1817.
- Sasaki M; Ikeda, H; Sawada, S; Sato, Y & Nakanuma, Y. (2007). Naturally-occurring regulatory T cells are increased in inflamed portal tracts with cholangiopathy in primary biliary cirrhosis. *J Clin Pathol*, Vol.60, No.19, (December 2006), pp. 1102-1107.
- Sakaki, M; Hiroishi, K; Baba, T; Ito, T; Hirayama, Y; Saito, K; Tonoike, T; Kushima, M & Imawari, M. (2008). Intrahepatic status of regulatory T cells in autoimmune liver diseases and chronic viral hepatitis. *Hepatol Res*, Vol.38, No.4, (November 2007), pp. 354-361.
- Shimizu, Y; Murata, H; Kashii, Y; Hirano, K; Kunitani, H; Higuchi, K & Watanabe, A. (2001). CC-chemokine receptor 6 and its ligand macrophage inflammatory protein 3alpha might be involved in the amplification of local necroinflammatory response in the liver. *Hepatology*, Vol.34, No.2, (August 2001), pp. 311-319.
- Spangenberg, HC; Viazov, S; Kersting, N; Neumann-Haefelin, C; McKinney, D; Roggendorf, M; von Weizsäcker, F; Blum, HE & Thimme, R. (2005). Intrahepatic CD8+ T-cell failure during chronic hepatitis C virus infection. *Hepatology*, Vol.42, No.4, (October 2005), pp. 828-837.
- Sturm, N; Thélu, MA; Camous, X; Dimitrov, G; Ramzan, M; Dufeu-Duchesne, T; Bonorino, P; Guillermet, C; Brambilla, E; Arvers, P; Pernollet, M; Leroy, V; Zarski, JP; Marche, PN & Jouvin-Marche, E. (2010). Characterization and role of intra-hepatic regulatory T cells in chronic hepatitis C pathogenesis. *J Hepatol*, Vol.53, No.1, (April 2010), pp. 25-35.
- Stoop, JN; Claassen, MA; Woltman, AM; Binda, RS; Kuipers, EJ; Janssen, HL; van der Molen, RG & Boonstra, A. (2008) Intrahepatic regulatory T cells are phenotypically distinct from their peripheral counterparts in chronic HBV patients. *Clin Immunol*, Vol.129, No.3, (September 2008), pp. 419-427.
- Syn, WK; Oo, YH; Pereira, TA; Karaca, GF; Jung, Y; Omenetti, A; Witek, RP; Choi, SS; Guy, CD; Fearing, CM; Teaberry, V; Pereira, FE; Adams, DH & Diehl, AM. (2010). Accumulation of natural killer T cells in progressive nonalcoholic fatty liver disease. *Hepatology*, Vol.51, No.1, (June 2010), pp. 1998-2007.

- Syn, WK; Choi, SS & Diehl, AM. (2009). Apoptosis and cytokines in nonalcoholic steatohepatitis. *Clin Liver Dis*, Vol.13, No.4, (November 2009), pp. 565-580.
- Tang, TJ; Kwekkeboom, J; Laman, JD; Niesters, HG; Zondervan, PE; de Man, RA; Schalm, SW & Janssen, HL. (2003). The role of intrahepatic immune effector cells in inflammatory liver injury and viral control during chronic hepatitis B infection. *J Viral Hepat*, Vol.10, No.3, (May 2003), pp. 159-167.
- Tang, TJ; de Man, RA; Kusters, JG; Kwekkeboom, J; Hop, WC; van der Molen, RG; Schalm, SW & Janssen, HL. (2004). Intrahepatic CD8 T-lymphocytes and HBV core expression in relation to response to antiviral therapy for chronic hepatitis B patients. *J Med Virol*, Vol.72, No.2, (February 2004), pp. 215-222.
- Tang, TJ; Kwekkeboom, J; Mancham, S; Binda, RS; de Man, RA; Schalm, SW; Kusters, JG & Janssen, HL. (2005). Intrahepatic CD8+ T-lymphocyte response is important for therapy-induced viral clearance in chronic hepatitis B infection. *J Hepatol*, Vol.43, No.1, (April 2005), pp. 45-52.
- Tajiri, K; Shimizu, Y; Tsuneyama, K & Sugiyama, T. (2009). The role of liver-infiltrating CD3+CD56+ NKT cells in the pathogenesis of nonalcoholic fatty liver disease. *Eur J Gastroenterol Hepatol*, Vol.21, No.6, (June 2009), pp. 673-680.
- Tilg, H & Moschen, AR. (2010). Evolution of inflammation in nonalcoholic fatty liver disease: the multiple parallel hits hypothesis. *Hepatology*, Vol. 52, No.5, (November 2010), pp. 1836-1846.
- Tsuneyama, K; Harada, K; Yasoshima, M; Kaji, K; Gershwin, ME & Nakanuma, Y. (1998). Expression of co-stimulatory factor B7-2 on the intrahepatic bile ducts in primary biliary cirrhosis and primary sclerosing cholangitis: an immunohistochemical study. *J Pathol*, Vol.186, No.2, (October 1998), pp. 126-130.
- Tran, A; Yang, G; Doglio, A; Ticchioni, M; Laffont, C; Durant, J; Bernard, JL; Gugenheim, J; Saint-Paul, MC; Bernard, A; Rampal, P & Benzaken, S. (1997). Phenotyping of intrahepatic and peripheral blood lymphocytes in patients with chronic hepatitis C. *Dig Dis Sci*, Vol.42, No.12, (December 1997), pp. 2495-2500.
- Vrolijk, JM; Kwekkeboom, J; Janssen, HL; Hansen, BE; Zondervan, PE; Osterhaus, AD; Schalm, SW & Haagmans, BL. (2003). Pretreatment intrahepatic CD8+ cell count correlates with virological response to antiviral therapy in chronic hepatitis C virus infection. *J Infect Dis*, Vol.188, No.15, (October 2003), pp. 1528-1532.
- Walewska-Zielecka, B; Madalinski, K; Jablonska, J; Godzik, P; Cielecka-Kuszyk, J & Litwinska, B. (2008). Composition of inflammatory infiltrate and its correlation with HBV/HCV antigen expression. *World J Gastroenterol*, Vol.14, No.7, (July 2008), pp. 4040-4046.
- Watanabe, T; Bertoletti, A & Tanoto, TA. (2010). PD-1/PD-L1 pathway and T-cell exhaustion in chronic hepatitis virus infection. *J Viral Hepat*, Vol.17, No.7, (July 2010), pp. 453-458.
- Xie, Z; Chen, Y; Zhao, S; Yang, Z; Yao, X; Guo, S; Yang, C; Fei, L; Zeng, X; Ni, B & Wu, Y. (2009). Intrahepatic PD-1/PD-L1 up-regulation closely correlates with inflammation and virus replication in patients with chronic HBV infection. *Immunol Invest*, Vol.38, No.7, pp. 624-638.
- Xu, D; Fu, J; Jin, L; Zhang, H; Zhou, C; Zou, Z; Zhao, JM; Zhang, B; Shi, M; Ding, X; Tang, Z; Fu, YX & Wang, FS. (2006). Circulating and liver resident CD4+CD25+ regulatory T

- cells actively influence the antiviral immune response and disease progression in patients with hepatitis B. *J Immunol*, Vol.177, No.1, (July 2006), pp. 739-747.
- Ward, SM; Fox, BC; Brown, PJ; Worthington, J; Fox, SB; Chapman, RW; Fleming, KA; Banham, AH & Klenerman, P. (2007). Quantification and localisation of FOXP3+ T lymphocytes and relation to hepatic inflammation during chronic HCV infection. *J Hepatol*, Vol.47, No.3, (April 2007), pp. 316-324.
- Zeremski, M; Petrovic, LM; Chiriboga, L; Brown, QB; Yee, HT; Kinkhabwala, M; Jacobson, IM; Dimova, R; Markatou, M & Talal, AH. (2008). Intrahepatic levels of CXCR3-associated chemokines correlate with liver inflammation and fibrosis in chronic hepatitis C. *Hepatology*, Vol.48, No.5, (November 2008), pp. 1440-1450.
- Zhang, Z; Zhang, JY; Wherry, EJ; Jin, B; Xu, B; Zou, ZS; Zhang, SY; Li, BS; Wang, HF; Wu, H; Lau, GK; Fu, YX & Wang, FS. (2008). Dynamic programmed death 1 expression by virus-specific CD8 T cells correlates with the outcome of acute hepatitis B. *Gastroenterology*, Vol.134, No.7, (March 2008), pp. 1938-1949.
- Zhang, JY; Zhang, Z; Lin, F; Zou, ZS; Xu, RN; Jin, L; Fu, JL; Shi, F; Shi, M; Wang, HF & Wang, FS. (2010). Interleukin-17-producing CD4(+) T cells increase with severity of liver damage in patients with chronic hepatitis B. *Hepatology*, Vol.51, No.1, (January 2010), pp. 81-91.

IntechOpen



Liver Biopsy

Edited by Dr Hirokazu Takahashi

ISBN 978-953-307-644-7

Hard cover, 404 pages

Publisher InTech

Published online 06, September, 2011

Published in print edition September, 2011

Liver biopsy is recommended as the gold standard method to determine diagnosis, fibrosis staging, prognosis and therapeutic indications in patients with chronic liver disease. However, liver biopsy is an invasive procedure with a risk of complications which can be serious. This book provides the management of the complications in liver biopsy. Additionally, this book provides also the references for the new technology of liver biopsy including the non-invasive elastography, imaging methods and blood panels which could be the alternatives to liver biopsy. The non-invasive methods, especially the elastography, which is the new procedure in hot topics, which were frequently reported in these years. In this book, the professionals of elastography show the mechanism, availability and how to use this technology in a clinical field of elastography. The comprehension of elastography could be a great help for better dealing and for understanding of liver biopsy.

How to reference

In order to correctly reference this scholarly work, feel free to copy and paste the following:

Kazuto Tajiri and Yukihiro Shimizu (2011). Immunological Analysis of Liver Diseases with Liver Biopsy Specimens, Liver Biopsy, Dr Hirokazu Takahashi (Ed.), ISBN: 978-953-307-644-7, InTech, Available from: <http://www.intechopen.com/books/liver-biopsy/immunological-analysis-of-liver-diseases-with-liver-biopsy-specimens>

INTECH
open science | open minds

InTech Europe

University Campus STeP Ri
Slavka Krautzeka 83/A
51000 Rijeka, Croatia
Phone: +385 (51) 770 447
Fax: +385 (51) 686 166
www.intechopen.com

InTech China

Unit 405, Office Block, Hotel Equatorial Shanghai
No.65, Yan An Road (West), Shanghai, 200040, China
中国上海市延安西路65号上海国际贵都大饭店办公楼405单元
Phone: +86-21-62489820
Fax: +86-21-62489821

© 2011 The Author(s). Licensee IntechOpen. This chapter is distributed under the terms of the [Creative Commons Attribution-NonCommercial-ShareAlike-3.0 License](https://creativecommons.org/licenses/by-nc-sa/3.0/), which permits use, distribution and reproduction for non-commercial purposes, provided the original is properly cited and derivative works building on this content are distributed under the same license.

IntechOpen

IntechOpen