

# We are IntechOpen, the world's leading publisher of Open Access books Built by scientists, for scientists

6,900

Open access books available

185,000

International authors and editors

200M

Downloads

Our authors are among the

154

Countries delivered to

TOP 1%

most cited scientists

12.2%

Contributors from top 500 universities



WEB OF SCIENCE™

Selection of our books indexed in the Book Citation Index  
in Web of Science™ Core Collection (BKCI)

Interested in publishing with us?  
Contact [book.department@intechopen.com](mailto:book.department@intechopen.com)

Numbers displayed above are based on latest data collected.  
For more information visit [www.intechopen.com](http://www.intechopen.com)



## Principles of the Biopsy Procedure

Anna Piekarska  
Medical University of Łódź  
Poland

### 1. Introduction

A liver biopsy is a procedure where a small piece of liver tissue or liver cells are removed for microscopic examination. Taking a liver biopsy specimen for a microscopic examination can be performed in two ways: blind and guided liver biopsy.

#### 2.1 Blind biopsy

The first, most common type of biopsy is a **core-needle, blind biopsy**.

In this procedure a small piece of liver tissue is taken from the organ with the use of needle which diameter is 1.2 - 1.6 mm. The principle of this procedure is that the morphology of the liver specimen is the same as the morphology of whole organ. The size of the tissue sample taken from the liver enables the pathologist to evaluate the cell composition and to describe the location of particular cells in relation to other cells.

Indications for a core-needle liver biopsy are presented in Table 1.

A core-biopsy can be performed as: a percutaneous core -needle biopsy, a transvenous (transjugular) core-needle biopsy, laparoscopic liver biopsy, open wedge (surgical) biopsy.

##### 2.1.1 A percutaneous core -needle biopsy

This type of biopsy is the most frequent. Indications are presented in Table 1. Percutaneous core-needle biopsy can be performed relatively easy. It can be performed in local anesthesia with the use of basic equipment.

##### 2.1.2 A transvenous (transjugular) core-needle biopsy

This technique of performing a liver biopsy is indicated in patients with the increased risk of bleeding (e.g. thrombocytopenia), since in case of bleeding from biopsy site, liver blood directly flows to the lumen of hepatic vein and therefore it does not cause a subcapsular hematoma or bleeding into body cavities. However, the transvenous biopsy is a more invasive technique than the percutaneous biopsy. It requires technical resources (imaging equipment) and is more expensive.

##### 2.1.3 Laparoscopic liver biopsy

The laparoscopic surgery in the upper abdomen enables to take a liver tissue for pathological examination. However, the necessity to make a liver biopsy is hardly ever an indication for performing a laparoscopic surgery. Liver biopsy made with the use of this technique most frequently accompanies other medical procedures (e.g. cholecystectomy).

Disease entity	Reason for performing biopsy	Comments
Chronic viral hepatitis B and C	1. Confirmation of clinical diagnosis 2. Assessment of grading of inflammation and staging of fibrosis	In many cases - necessary to qualify a patient for antiviral treatment
Alcoholic hepatitis Non-alcoholic fatty liver disease Autoimmune hepatitis	1. Confirmation of clinical diagnosis 2. Assessment of progression of disease	Most often it serves as a tool for differential diagnosis
Hemochromatosis	1.Setting a diagnosis 2. Quantitative evaluation of liver iron level	
Wilson’s disease		
Primary biliary cirrhosis	1. Confirmation of clinical diagnosis 2. Assessment of progression of disease	
Primary sclerosing cholangitis	1.Setting a diagnosis 2. Differential diagnosis of cholestasis	Liver biopsy is indicated when diagnosis is not possible on the basis of imaging
Drug-induced liver disease	1. Confirmation of clinical diagnosis 2. Assessment of progression of disease	
Evaluation of transplanted liver in a recipient	1. Diagnosis of acute or chronic transplant rejection 2. Post – transplant viral hepatitis	
Fever of unknown origin	1.Setting a diagnosis	
Anomalous levels of liver enzymes of unknown origin	1.Setting a diagnosis	

Table 1. Indications for a core-needle blind liver biopsy

2.1.4 Open wedge (surgical) liver biopsy

A small piece of subcapsular liver tissue can be obtained during laparotomy. The piece of tissue taken during open surgery is usually bigger than the specimen taken percutaneously. However, the tissue is often damaged due to the technique of excision and handling of specimen during surgery. Moreover the subcapsular specimen may not be fully representative for morphology of liver disease.

## 2.2 Guided liver biopsy

The second type of biopsy is a core-needle or fine-needle-aspiration biopsy.

Guided biopsy is aimed at diagnostics of focal lesions in liver and must be performed under visual control. In most cases ultrasonography is used for this purpose. Computed tomography is used less frequently.

The use of a fine needle allows for aspiration of liver cells only. The obtained biological material consists of liver cell which are not bound to each other and immersed in liquid material. This type of biopsy is used for diagnostics of focal changes in liver – filled with liquid or hypoechogenic (e.g. cysts).

However, for diagnostics of solid focal changes in liver (tumour metastasis, hepato-cellular carcinoma) core needle biopsy is recommended. This technique allows for obtaining a tumour tissue, which considerably facilitates setting a diagnosis.

## 3. A place of liver biopsy in diagnostic workup in liver disease

It should be underlined that a decision to make a biopsy is one of the last steps taken in diagnostics of liver diseases. In view of the fact that the method is invasive and has its limitations, it should be performed only when it is supposed to provide information necessary for treatment of the patient. Below there is a list of information about the patient and additional examinations which should be made before taking a decision of performing a biopsy.

### 3.1 Hepatological diagnostics before taking a liver biopsy

Before performing a biopsy one should try to establish the cause of the liver disease on the basis of non-invasive examinations so as to gather as much information as possible for the pathologist examining the specimen referring to etiology, progression of the liver disease. Following tests should be made in each patient:

- blood cell count (pancytopenia might imply portal hypertension)
- biochemical (ALT, AST, ALP, GTP, bilirubin), indicating the presence of hepatocyte necrosis and cholestasis
- viral markers (anti-HAV IgM, HBsAg, HBeAg, anti-HBc-total, anti-HCV, anti-delta)
- molecular examinations – depending on the results received above. (HBV-DNA quantitatively, HCV-RNA quantitatively)
- antibody analysis (ANA, AMA, ASMA, anti-LKM, anti-SLA)
- proteinogram
- *in justified cases* – examination for presence of Wilson's disease (plasma ceruloplasmin level, plasma copper level, copper excretion via urine), hemochromatosis (plasma ferritin level, plasma iron level, possibly analysis of mutation of C282Y and H63D genes)
- ultrasonography examination of a liver and evaluation with the use of Doppler analysis of potential presence of portal hypertension

**The age of the patient** is often a determining factor as for the decision about performing a liver biopsy and the way in which it should be performed. In case of children and young adults (younger than 16 years old) parents often do not give consent to a liver biopsy and they demand less invasive diagnostic methods. Moreover, children who are subjected to a percutaneous biopsy, should undergo a short-term general anesthesia. In the case of elderly

patients the doctor should decide whether the information gathered after taking a liver biopsy specimen will considerably influence further treatment. For example: elderly patients suffering from chronic hepatitis C very often have numerous contraindications for interferon and ribavirin therapy. Therefore, a liver biopsy as a tool for qualification to antiviral treatment is useless in this setting.

**A free consent** to liver biopsy.

In every case the written consent for the procedure should be obtained from the patient or his committee. The patient should achieve complete information about indications for the procedure, diagnostic benefits and potential complications.

**Cooperation of the patient** is a crucial element qualifying him for liver biopsy.

The procedure performed in local anesthesia involves inserting a needle when the patient has exhaled the air. Inhaling or moving the body when the doctor inserts a needle might lead to liver rupture and massive hemorrhage. The patient must be informed about such possibility and should be taught to control his breathing. If, in the doctor's opinion, it is not possible (small children, patients with mental or behavioral disorders), the patient should be given short-term general anesthesia. Otherwise the procedure should be abandoned. Moreover, the patient is then asked to stay in bed for 3 hours following the procedure.

**Body mass (BMI).** In obese patients (>30 BMI) it might be difficult to take a liver biopsy specimen percutaneously because of thick subcutaneous fatty tissue.

**Concomitant diseases** (e.g. circulatory insufficiency, scoliosis) might hamper performing a liver biopsy as it might be difficult to put the patient in the appropriate position and make him stay in that position for more than 10 minutes. Those suffering from hemophilia are usually disqualified from this kind of procedure because of the increased risk of bleeding.

**Allergy to medicaments** used for local anesthesia (e.g. lidocaine) might make the percutaneous biopsy impossible to perform.

The information on **medicaments taken** by the patient for a longer period, especially anticoagulant medications (salicylic acid, acenocumarol) is crucial when the liver biopsy is planned. Patient should stop taking salicylic acid for one week before the liver biopsy. Administering of acenocumarol should be stopped two days before the liver biopsy. If it is not possible the doctor should perform transvenous biopsy or should not perform the biopsy at all.

**Menstrual cycle** phase should be considered in female patients. Biopsy should not be made during menstruation (1 – 5 day) because of the increased risk of liver bleeding.

#### 4. Answers a liver biopsy can give

- In majority cases of acute viral hepatitis liver biopsy is not performed. The diagnosis can be set on the base of biochemical and serologic examinations. The exceptions are the patients in whom on the base of other examinations and anamnesis it is not possible to determine whether they suffer from chronic or acute hepatitis. Since pathomorphological findings in these two kinds of hepatitis are different, liver biopsy might be helpful in setting the right diagnosis and qualifying for treatment. It is important as the treatment of these diseases differ a lot.
- In case of chronic viral hepatitis B and C morphological evaluation of a liver biopsy specimen helps to assess the grade and stage of the disease (according to one of

assessment scales). In routine diagnostics the pathological examination of specimen does not help to discover etiology. The results of assessment of grade of inflammation and stage of fibrosis serve as a tool for qualification for treatment. Besides, morphological analysis facilitates diagnosing other liver diseases which accompany viral hepatitis (fatty liver disease, alcoholic liver disease, autoimmune hepatitis). Morphological analysis also helps to evaluate remission of changes after antiviral treatment.

- Alcoholic liver disease (ALD) can be diagnosed without an analysis of the specimen in most cases. In any doubts, biopsy helps to set the right diagnosis, evaluate the fibrosis and presence of other inflammatory processes (e.g. AIH).
- Biopsy specimen analysis is crucial in the case of non-alcoholic fatty liver disease (NAFLD) since additional analysis (biochemical and serologic) allow to exclude existence of other liver diseases. Morphological analysis helps to differentiate NAFLD and non-alcoholic steatohepatitis (NASH), evaluate accumulation of fat in hepatocytes in Dixon's scale as well as consequences of the disease manifested by progression of fibrosis.
- Suspicion of the presence of autoimmune hepatitis (AIH) is an indication for liver biopsy. Morphological analysis helps to set a diagnosis in the case of unclear results of autoantibodies, differentiate e.g. AIH and ALD and evaluate the progression of the disease and its consequences – fibrosis and cirrhosis. Morphological analysis also proves how effective the applied treatment is.
- Diagnosing liver metabolic diseases (Wilson's disease, hemochromatosis) without morphological analysis might be impossible to do. Morphological analysis not only enables to set the right diagnosis and differentiate with other liver diseases but also helps to make a quantitative evaluation of iron in the liver biopsy specimen, which is significant for further therapy.

## 5. Answers a liver biopsy cannot give

Liver biopsy should not be made:

- if the diagnosis can be established with the use of non-invasive methods,
- if the information gathered does not change decisions as for the therapy,
- if biopsy might be a health hazard.

Therefore, the biopsy should not be performed in patients with decompensated liver cirrhosis. When the clinical diagnosis is obvious (ascites, oedema, jaundice, symptoms of portal hypertension) the liver biopsy will not give more diagnostic information and will not influence on the choice of treatment method. Besides, in the case of hemorrhagic diathesis which accompanies cirrhosis, the liver biopsy may lead to hemorrhage. As medical practice shows, in patients suffering from cirrhosis, it is difficult or even impossible to obtain a representative liver biopsy specimen. Moreover, the specimen is often small and dismembered, which makes the pathologic examination almost impossible.

## 6. Diagnostic workup before commencing a liver biopsy

Set of tests which should be performed during last 24 hours before core biopsy is presented in Table 2.



Analysis	Comments
Blood cell count	The number of platelets should exceed 60,000/ $\mu$ l, to avoid bleeding
Blood group	Identifying blood group before the biopsy allows for faster blood transfusion in the event of possible hemorrhage
Coagulological analysis	Prothrombin time should not exceed the reference value by more than 4 seconds (INR>1.4) Activated partial thromboplastic time (APTT) should not exceed the reference value by 1.5 times
Image examination (e.g. USG, CT)	Excluding focal lesions in the liver

Table 2. Set of tests which should be made directly before blind liver biopsy.

7. The choice of type of liver biopsy

Focal changes discovered in ultrasound examination or computed tomography are indications for an image-controlled biopsy.  
In patient with chronic hepatitis in whom a solid focal change is diagnosed two USG-guided core biopsies should be made. The first specimen should be obtain from the solid lesion. The other should be obtained from other part of liver (with the avoidance of lesion volume).

8. How to prepare a patient to liver biopsy

On the day of biopsy the patients is advised to remain fast. He should be examined by the physician performing the procedure. Fever, cough, bleeding or circulatory insufficiency diagnosed prior to the biopsy should be temporary contraindications for it. Thirty minutes before the surgery the patient is sedated with 5 mg of diazepam administered intramuscularly.

9. Anesthesia

In adults and children who can cooperate during the procedure (usually above 15 years of age) liver biopsy is made in local anesthesia. To do it one should use 8-10 ml of 1% lidocaine solution. The technique of anesthesia is described below (Point 10). When the patient is not willing to cooperate, the procedure should be performed in short-term general anesthesia.

10. Technique of core biopsy

10.1 The position of the patient

The patient should be in supine position, with his right upper limb placed behind the head, the left one – along the body. Intercostals spaces should be as wide as possible (middle armpit line should be in the shape of arch).

### 10.2 Determining the area of biopsy

Upper and lower limits of liver dullness should be established with the use of percussion. Next, the physician should mark the area of biopsy in the intercostals space, in the middle of liver dullness, on the middle armpit line or anterior armpit line.

### 10.3 Antiseptics

After putting on sterile gloves the area of biopsy should be cleansed twice with antiseptic substance and the skin should be left to dry.

### 10.4 Local anesthesia

The anesthesia should be done in the place selected beforehand. Lidocaine solution should be injected subcutaneously and later on, the needle must be inserted deeper, inside the intercostals space, continuously injecting a solution. Once the needle touches the capsule the needle should be slowly withdrawn and the solution – administered.

### 10.5 Liver biopsy

After application of anesthetic, the assisting nurse opens a set for liver biopsy. It consists of a blockage controlled syringe, a biopsy needle, a hypodermic needle and a blade.

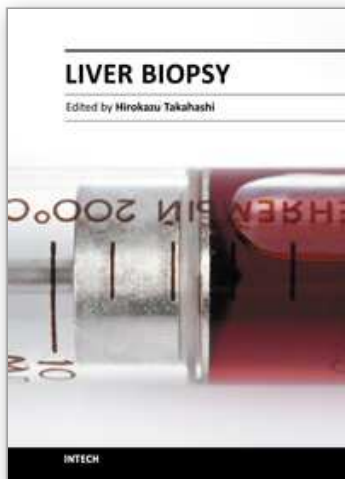
The first activity involves putting a hypodermic needle for on the blockage controlled syringe and then aspiration of 4 ml of aseptic solution of isotonic salt in such a way that the “brake” in the syringe remains in the unblocked position. Next, the hypodermic needle should be taken off and replaced with the biopsy needle. The syringe with the biopsy needle should be put aside in a sterile place and with the use of scalpel the doctor should make an incision – 2 to 3 mm long - in the intercostals space skin. Then the needle biopsy should be placed inside the incision as deep as to the liver capsule. At this moment the needle should be moved a few millimetres backwards. The patient should inhale air, exhale it to the end and then hold his breath. At the moment the patients does not breathe the doctor should inject about 2 ml of isotonic salt and then, pull the piston to block the “brake” and quickly move the needle in the direction of liver to the depth of about 3 cm and take it out immediately. After removing the needle from the intercostals space the patient should be allowed to breathe freely. With a sterile gauze pad one should press the area where the liver specimen has been taken since the skin might start bleeding a little. After putting a sterile dressing on the biopsy area the biopsy needle should be emptied , which should be done by unblocking the “brake” of the syringe. The content of the needle should be put in a prepared container with formalin solution. Then the doctor performing the biopsy should macroscopically evaluate the size of the taken specimen. If it is too small or dismembered too much, the procedure should be repeated.

## 11. References

- [1] Scheuer PJ & Lefkowitz JH. *Liver Biopsy Interpretation*. 7th Edition. Edinburgh: Elsevier
- [2] Sherlock S & Dooley J. (2002). *Diseases of the Liver and Biliary System*. 11th ed. Oxford: Blackwell Science



- [3] Bruno MA, Rodríguez Fuchs C, Gallo J, González Boix J. (1990) *Percutaneous hepatic biopsy puncture in patients with hemostasis disorders. A new technique. Acta Gastroenterol Latinoam*, Vol.20, No1, pp. 25-30
- [4] M Horejsová & F Koukolík (1989). *Thin-needle aspiration biopsy under ultrasonic control. The examination technic. Casopis Lekarů Ceských*, Volume: 128, Issue: 49.
- [5] Gutkowski K. *Percutaneous liver biopsy – indications, contraindications and possible complications*. (2004) *Nether J Med*, Vol. 62, pp. 441-5



## **Liver Biopsy**

Edited by Dr Hirokazu Takahashi

ISBN 978-953-307-644-7

Hard cover, 404 pages

**Publisher** InTech

**Published online** 06, September, 2011

**Published in print edition** September, 2011

Liver biopsy is recommended as the gold standard method to determine diagnosis, fibrosis staging, prognosis and therapeutic indications in patients with chronic liver disease. However, liver biopsy is an invasive procedure with a risk of complications which can be serious. This book provides the management of the complications in liver biopsy. Additionally, this book provides also the references for the new technology of liver biopsy including the non-invasive elastography, imaging methods and blood panels which could be the alternatives to liver biopsy. The non-invasive methods, especially the elastography, which is the new procedure in hot topics, which were frequently reported in these years. In this book, the professionals of elastography show the mechanism, availability and how to use this technology in a clinical field of elastography. The comprehension of elastography could be a great help for better dealing and for understanding of liver biopsy.

### **How to reference**

In order to correctly reference this scholarly work, feel free to copy and paste the following:

Anna Piekarska (2011). Principles of the Biopsy Procedure, Liver Biopsy, Dr Hirokazu Takahashi (Ed.), ISBN: 978-953-307-644-7, InTech, Available from: <http://www.intechopen.com/books/liver-biopsy/principles-of-the-biopsy-procedure>

**INTECH**  
open science | open minds

### **InTech Europe**

University Campus STeP Ri  
Slavka Krautzeka 83/A  
51000 Rijeka, Croatia  
Phone: +385 (51) 770 447  
Fax: +385 (51) 686 166  
[www.intechopen.com](http://www.intechopen.com)

### **InTech China**

Unit 405, Office Block, Hotel Equatorial Shanghai  
No.65, Yan An Road (West), Shanghai, 200040, China  
中国上海市延安西路65号上海国际贵都大饭店办公楼405单元  
Phone: +86-21-62489820  
Fax: +86-21-62489821

© 2011 The Author(s). Licensee IntechOpen. This chapter is distributed under the terms of the [Creative Commons Attribution-NonCommercial-ShareAlike-3.0 License](https://creativecommons.org/licenses/by-nc-sa/3.0/), which permits use, distribution and reproduction for non-commercial purposes, provided the original is properly cited and derivative works building on this content are distributed under the same license.

IntechOpen

IntechOpen