

We are IntechOpen, the world's leading publisher of Open Access books Built by scientists, for scientists

6,900

Open access books available

185,000

International authors and editors

200M

Downloads

Our authors are among the

154

Countries delivered to

TOP 1%

most cited scientists

12.2%

Contributors from top 500 universities



WEB OF SCIENCE™

Selection of our books indexed in the Book Citation Index
in Web of Science™ Core Collection (BKCI)

Interested in publishing with us?
Contact book.department@intechopen.com

Numbers displayed above are based on latest data collected.
For more information visit www.intechopen.com



Male Circumcision: An Appraisal of Current Instrumentation

Brian J. Morris¹ and Chris Eley²

¹*School of Medical Sciences, The University of Sydney, Sydney,*

²*Editor, www.circlist.com, London,*

¹*Australia*

²*United Kingdom*

1. Introduction

The topic of male circumcision (MC) is of considerable current interest, largely because of widespread publicity generated by research findings attesting to its ability to prevent HIV infection during heterosexual intercourse. In addition, its long-recognized ability to protect against other sexually transmitted infections (STIs) has also been well publicized in recent times, especially now that support has been provided by large randomized controlled trials (RCTs).

While MC can be performed at any age, the ease with which circumcision can be performed in infancy makes this time of life preferable to intervention later in childhood or in adulthood. As well as the issue of safety, convenience, simplicity and consequent cost reductions, circumcision in infancy provides greater net benefits over the lifetime of the individual.

It provides immediate 10-fold protection against urinary tract infections and thus kidney damage in baby boys, and greater protection against penile cancer than circumcision later in life, virtually eliminating the risk of this disease with its high morbidity and mortality (Morris, 2007; Morris, 2010; Tobian *et al.*, 2010; Morris *et al.*, 2011). Another benefit is prevention of phimosis, a common cause of sexual problems in adolescent boys and men, and a major risk factor for penile cancer. It also lowers the risk of inflammatory skin conditions such as balanoposthitis. Circumcised men have superior hygiene (O'Farrell *et al.*, 2005) and half the prevalence of thrush (Richters *et al.*, 2006). As far as protection against STIs is concerned, the most notable is human papillomavirus (HPV), the pathogen not only responsible for most cervical cancers in women, but also a proportion of penile cancers in men (Morris *et al.*, 2011). MC also reduces the incidence of ulcerative STIs, including syphilis, chancroid, *Trichomonas vaginalis*, and herpes simplex virus type 2 (HSV-2) (Weiss *et al.*, 2006; Morris & Castellsague, 2010; Tobian *et al.*, 2010). Circumcised men have lower genital ulcer disease as a result of this and the reduction in penile injury arising from tearing of the foreskin and frenulum during sexual activity (Bailey & Mehta, 2009). MC reduces sexual problems with age and diabetes (Morris, 2007; Morris, 2010; Tobian *et al.*, 2010; Morris *et al.*, 2011), and has no adverse effect on sexual function, sensation or acceptability (Morris, 2007; Tobian *et al.*, 2010), if anything the reverse (Krieger *et al.*, 2008). MC provides a public health benefit to women by lowering their risk of various STIs, including high-risk HPV types that cause cervical cancer, HSV-2,

Chlamydia trachomatis that can cause pelvic inflammatory disease, ectopic pregnancy and infertility, as well reducing the risk of bacterial vaginosis (Morris, 2007; Morris, 2010; Tobian et al., 2010; Morris et al., 2011; Wawer et al., 2011).

If one tallies up all of the conditions listed above, 1 in 3 uncircumcised men will require medical attention from a condition stemming from their uncircumcised state (Morris, 2007). Moreover, such an analysis shows that the benefits exceed the risks by over 100 to 1, and far more if one factors in the severity of the consequences, including mortality and morbidity, that can occur in uncircumcised males and their sexual partners in adulthood.

MC is, without doubt, a multi-benefit procedure. Yet many analyses of its benefits make the mistake of addressing its effect with respect to just one medical condition. For a true assessment of its value it is necessary to carry out a summation of all the benefits, quoting the total inclusive of spin-offs every time.

Because of the current focus on efficient and effective MC in regions of the world where HIV prevalence is high, in the present chapter we will begin by summarizing the HIV findings. In the context of biomedical engineering, we will then examine the devices that have been devised for the surgical procedure itself. The intention of these devices has been to help reduce risk to delicate penile structures during surgery and also to ensure a favourable cosmetic outcome of the circumcision procedure.

2. Male circumcision for HIV prevention

In 2007 MC was endorsed by the World Health Organization (WHO) and the Joint United Nations Programme on HIV/AIDS (World Health Organisation and UNAIDS, 2007a) as being an important, proven strategy for prevention of heterosexually-transmitted HIV in high prevalence settings. Such advice was the culmination of 20 years of research that led to the findings of three large randomized controlled trials in different parts of sub-Saharan Africa (Auvert et al., 2005; Bailey et al., 2007; Gray et al., 2007). After rigorous examination of the data, the Cochrane committee concluded that “inclusion of male circumcision into current HIV prevention guidelines is warranted” and that “No further trials are required” (Siegfried et al., 2009; Siegfried et al., 2010). A recent analysis of data from 18 sub-Saharan African countries found the protective effect after adjustment for number of lifetime sexual partners and socio-demographic variables was 5-fold (Gebremedhin, 2010). As a result, large-scale MC programmes are being rolled out across sub-Saharan Africa in societies where traditional circumcision has not in recent times been the norm.

Therefore, whilst the long-term goal should be one of circumcising in infancy, the immediate need in settings where life-threatening HIV prevalence is high is to circumcise uninfected heterosexually-active adult and adolescent males.

Critics of this approach cite the "ABC" policy (Abstinence, Behaviour, Condoms) (Coates et al., 2008) as being sufficient. While condoms are 80–90% effective if always used properly (Halperin et al., 2004), including during foreplay, the reality is that for a host of reasons such as passion over-riding common sense, dislike for condoms, reckless behaviour often fuelled by inebriation, and/or not having a condom available, many people either do not use them consistently or at all (Donovan & Ross, 2000; Szabo & Short, 2000; Caballero-Hoyos & Villasenor-Sierra, 2001; Ferrante et al., 2005; Jadack et al., 2006; Kang et al., 2006; Sanchez et al., 2006; Yahya-Malima et al., 2007; Munro et al., 2008; Wawer et al., 2009). This research included RCTs in which men were given counselling and free condoms (Wawer et al., 2009). A review of 10 studies from Africa found that overall there was no association between

condom use and reduced HIV infection, with two studies actually showing a positive association between use of a condom and HIV infection (Slaymaker, 2004; Lopman *et al.*, 2008). Part of the reason, however, is that condom use is likely to be higher when one person knows they are HIV-positive and does not want to infect their partner. Circumcision can thus be regarded as providing backup protection. It is much like seatbelts and airbags used in combination to reduce the road toll (Cooper *et al.*, 2010). Buckling up the seatbelt has to be done, whereas the airbag is always there. Imperfect though it is, once circumcised a male enjoys a guaranteed degree of protection for life. The widespread acceptance of MC as an important HIV prevention measure has led to a new “ABC” now being advocated: Antivirals, Barriers and Circumcision. Not instead of the original ABC, but additionally. This clearly recognizes that MC is part of a package of prevention measures.

An as-treated meta-analysis of the initial findings from the three RCTs found that the protective effect was 65% (Weiss *et al.*, 2008). This was identical to the summary risk ratio for the 15 observational studies that adjusted for potential confounders. Follow-up analyses have indicated an increase in the 60% protective effect seen in the Kenyan trial to 65% at 3.5 years (Bailey *et al.*, 2008) and 4.5 years (Bailey *et al.*, 2010). In the Ugandan trial by 5 years the protective effect had increased to 73% (Kong *et al.*, 2011). Such a level of protection is similar to that afforded by influenza vaccines (Fiore *et al.*, 2007; Kelly *et al.*, 2009). Even higher protection (80%) was found in the analysis of data from 18 sub-Saharan African countries (Gebremedhin, 2010).

The high protective effect of MC should not detract from the need to adopt the other ABC measures as well.

MC also reduces HIV infection in women by 20–46% (Baeten *et al.*, 2009; Weiss *et al.*, 2009; Baeten *et al.*, 2010; Hallett *et al.*, 2010). Economic analyses have estimated enormous savings in lives and cost by adoption of widespread MC in high risk settings (Williams *et al.*, 2006) and has the potential to abate the epidemic over the next 10–20 years (Gray *et al.*, 2008). Even in low prevalence settings such as the USA, infant MC was shown to be cost-saving for HIV prevention (Sansom *et al.*, 2010).

Several different partial remedies can act cumulatively, each contributing not just towards a reduction in infection rates but also towards the ultimate public health goal of herd immunity. It is here, rather than in the realms of individual healthcare, that the true value of MC lies. Not surprisingly, MC is now regarded as a “surgical vaccine” (Morris, 2007; Schoen, 2007b; Ben *et al.*, 2009). It provides a behaviour-independent secure foundation upon which other forms of protection can build.

As a prelude to the discussion of MC technique and the various devices for achieving foreskin removal, it is important to emphasize the biological evidence that has now accumulated that indicates the vulnerability of the inner lining of the foreskin to infection of the man by HIV.

During an erection the foreskin can either retract fully or only partially. Either way, during intercourse the thin, mucosal inner surface of the foreskin is exposed to the partner's body fluids (Szabo & Short, 2000). The foreskin then traps the infectious inoculum when the penis becomes flaccid again (Cameron *et al.*, 1989). The mucosal inner lining is only lightly keratinized (Patterson *et al.*, 2002; McCoombe & Short, 2006; Ganor *et al.*, 2010) and is rich in Langerhans cells (Patterson *et al.*, 2002). Dendrites from these project to just under the surface (McCoombe & Short, 2006). The higher susceptibility of the inner lining to infection by live, tagged HIV has been demonstrated in cultured tissue (Patterson *et al.*, 2002). Internalization of HIV involves the presence on Langerhans cells of the c-type lectin,

Langerin, that can bind HIV and internalize it (Turville *et al.*, 2002). The Langerin is then involved in its transport to regional lymph nodes (Turville *et al.*, 2002). In the inner (but not the outer) foreskin, tumor necrosis factor- α can activate Langerhan's cells; stimulatory cytokines then cause an influx of CD4+ T-cells into the epithelial layer (Fahrbach *et al.*, 2010). The higher permeability of the inner foreskin is associated with increased interaction of HIV target cells with external factors, such as HIV. HIV can, moreover, infect T-cells independently of Langerhans cells (Boggiano & Littman, 2007). HIV's success in establishing a systemic infection might nevertheless depend on its early interaction with Langerhans cells (Boggiano & Littman, 2007; Hladik *et al.*, 2007). At low viral levels Langerin is able to clear HIV, shunting it to intracellular granules for degradation, but this mechanism becomes overwhelmed at higher viral loads (de Witte *et al.*, 2007; Schwartz, 2007). By confocal imaging microscopy and mRNA quantification, the demonstration of abundant and superficially present potential HIV target cells (CD3+ and CD4+ T-cells, Langerhans cells, macrophages and submucosal dendritic cells) has provided anatomical support for the protective effect of circumcision (Hirbod *et al.*, 2010). There was no difference between positive and negative HSV-2 serostatus.

In 2010 it was found that HIV infected cells, but not free HIV, form viral synapses with apical foreskin keratinocytes, followed by rapid internalization by Langerhans cells, whose projections (dendrites) weave up between the keratinocytes in the inner foreskin, the infection occurring within 1 hour (Ganor & Bomsel, 2010; Ganor *et al.*, 2010). The Langerhans cells then formed conjugates with T-cells thereby transferring the HIV. The thick keratin layers in the outer foreskin prevent infection (Ganor & Bomsel, 2010).

Ulcerative disease and tearing are more common in uncircumcised men, adding to the risk of HIV entry (Alanis & Lucidi, 2004). A large 2-year RCT found significantly lower penile coital injuries amongst men in the circumcised arm of the trial, adjusted odds ratio being 0.71 for soreness, 0.52 for scratches/abrasions/cuts, and 0.62 for bleeding (Mehta *et al.*, 2010). HSV-2 infection increases HIV risk in men and women by 3-fold (Freeman *et al.*, 2006). Men with a higher foreskin surface area appear more likely to be infected with HIV (Kigozi *et al.*, 2009b). Inflammation of the epithelium of the foreskin is another factor that can increase infection risk and has been noted in 4.2% of men with neither HIV nor HSV-2, 7.8% of men with HSV-2 only, 19% of men with just HIV, and 32% of men with both (Johnson *et al.*, 2009). For stromal inflammation, the figures were 14%, 30%, 33% and 61%. Both epithelial and stromal inflammation were more common in men with accumulations of smegma. Even in the absence of visible lesions the mucosal tissue can show histological signs of inflammation (Hirbod *et al.*, 2010). Wetness under the foreskin is an indicator of poor hygiene and is associated with a 40% increase in risk of HIV infection (O'Farrell *et al.*, 2006). A wet penis may enhance attachment of infectious virions for longer, reduce healing after trauma, or may lead to balanitis under the foreskin and consequent micro-ulcerations (O'Farrell *et al.*, 2006).

In high HIV prevalence settings, MC has been shown to be cost-effective for prevention of this virus (Williams *et al.*, 2006; Uthman *et al.*, 2011). In sub-Saharan Africa the cost of MC is always lower than the cost of anti-retroviral treatment; by how much depends on the method of circumcision used. Prevention is of enhanced importance here, because no outright cure currently exists for HIV infection.

As mentioned earlier, even in settings in which HIV prevalence is low – such as the USA – calculations by the Centers for Disease Control and Prevention (CDC) have indicated that circumcision of infants would be cost-saving for HIV prevention (Sansom *et al.*, 2010). The CDC has been giving favourable consideration, based on the wide-ranging benefits, to encouraging

infant MC in the USA (Smith *et al.*, 2010). Earlier analyses, based on just some of the benefits, were favourable (Schoen *et al.*, 2006). These did not consider the benefits to women such as reduction in cervical cancer and various STIs besides oncogenic HPV (Morris *et al.*, 2006).

The ongoing penetration of HIV into the heterosexual community and rise in the number and proportion of new diagnoses from heterosexually-acquired infection in previously low HIV prevalence settings has led to calls for MC to be encouraged strongly in infancy (Cooper *et al.*, 2010).

3. Rates of circumcision

Worldwide 30–32% of males are circumcised (World Health Organization, 2008b). Most are a consequence of Muslim tradition that mandates MC. Religion dictates MC at day 8 for Jewish infants. In much of sub-Saharan Africa and other parts of the world such as indigenous peoples of Australia and the Pacific islands, MC is performed as part of coming of age ceremonies for boys. In the 1800s MC became popular in Britain and countries with an Anglo-Celtic heritage such as the USA and Australia. While a decline took place in the UK starting in the 1930s and in Australia and New Zealand in the 1970s, rates in the USA have remained high amongst Anglo-Celtic whites and Afro-American blacks (Xu *et al.*, 2007). Hospital discharge data that suggest a decline do not take into account earlier discharge from maternity wards shifting the procedure from hospitals (where circumcisions are recorded in official statistics) to doctor's offices (where they are not), and the fact that not all hospitals record infant MC after delivery. The campaigning by MC opponents that led to withdrawal of Medicaid funding for MC in 17 states has had an adverse effect on the ability of the poor to access MC services for their children (Leibowitz *et al.*, 2009; Morris *et al.*, 2009). In a 2008 report, hospital discharge data in Maryland found 75.3% of 96,457 male infants were circumcised after birth and survey data from 4,273 mothers showed a rate of 82.3% (Cheng *et al.*, 2008). Rate was higher in white and Afro-American blacks and lower amongst Hispanic and Asian infants. The continued influx of migrants, mostly Hispanic, in whom MC is culturally foreign, has been a major factor in the declining prevalence of MC in the US population as a whole. Subsequent generations are, however, more likely to adopt local US customs by having their baby boys circumcised. In Australia a reversal of the downward trend has become evident, no doubt fuelled by widespread news media publicity of the many benefits, especially in HIV prevention.

4. Circumcision style: Terminology

Excision of the foreskin can adopt various styles. These can be divided into what is referred to commonly as either a “high” or a “low” style (Fig. 1).

There is no published evidence as to whether one style or the other offers greater protection from HIV. The RCTs of MC for HIV prevention used either the forceps-guided method (which is “moderately high and loose”: <http://www.circlist.com/instrstechs/forcepsguide.html>) (Auvert *et al.*, 2005; Bailey *et al.*, 2007) or the sleeve technique (which is “high” and either “tight” or “loose”: <http://www.circlist.com/instrstechs/doublecirc.html>) (Gray *et al.*, 2007). Proponents of the “low” style argue that the antigen receptor cells responsible for admitting HIV to the uncircumcised male are concentrated in the frenulum and inner foreskin, implying that this tissue should be removed completely in order to obtain maximum benefit from the circumcision. Opponents consider that post-circumcision changes in residual mucosal tissue (changes that are loosely termed “keratinization”) render its removal unnecessary. The authors'

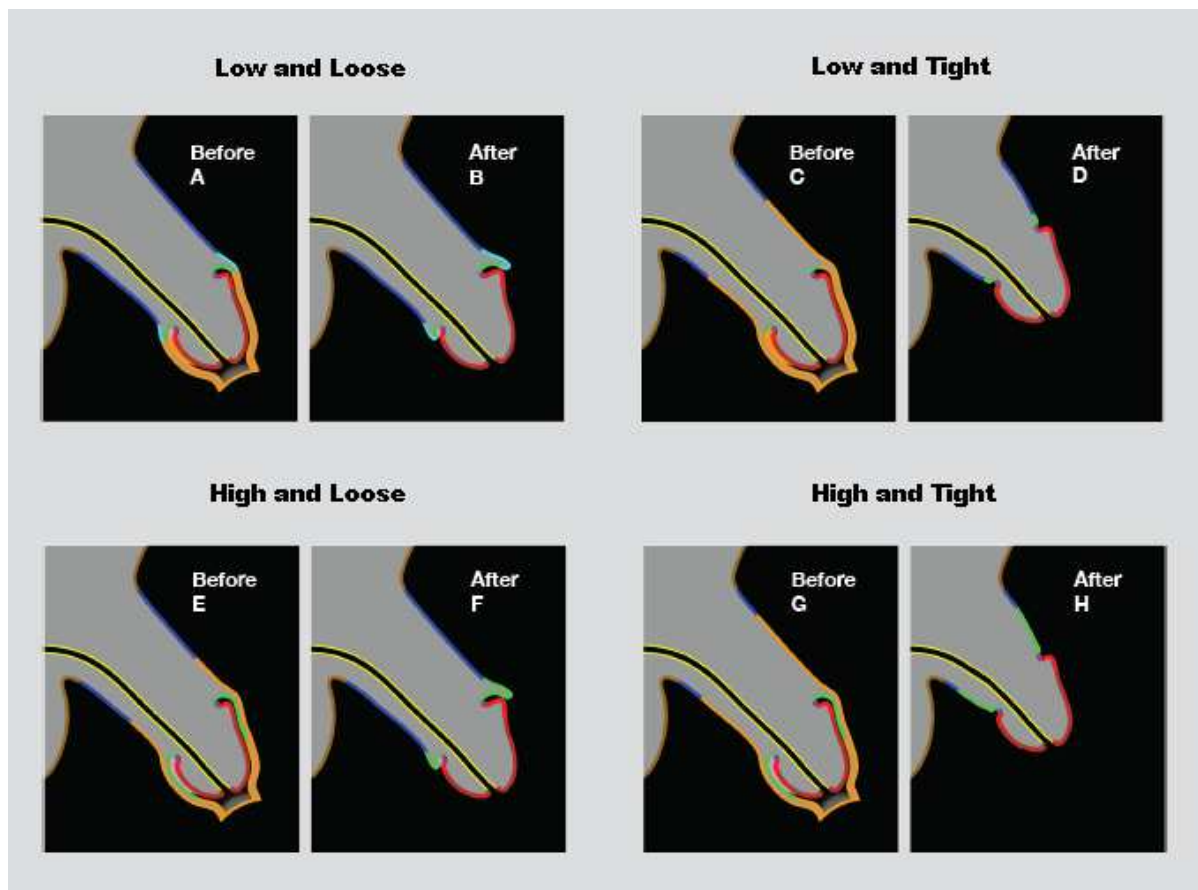


Fig. 1. Depiction of flaccid penis before and after circumcision showing what gets removed for extremes of style; in each case the tissue to be removed is shown in orange. (A) before and (B) after for the “low and loose” style: Almost all the inner foreskin has been removed along with an equal amount of outer foreskin. No tension has been placed in the shaft skin, with the result that the flaccid penis droops and the sulcus is not held fully open. Thus, despite circumcision, it remains possible for smegma to accumulate. (C) before and (D) after for the “low and tight” style: The maximum possible amount of inner foreskin has been removed along with the whole of the outer foreskin *plus* a considerable portion of shaft skin. This has placed the residual shaft skin under tension, with the result that the flaccid penis appears to be short and semi-erect. The sulcus is held fully open; therefore it is not possible for smegma to accumulate. (E) before and (F) after for the “high and loose” style: Much of the of inner foreskin has been retained, folded back on itself to face outwards and assume the role of shaft skin. The outer foreskin has been removed along with some shaft skin, but not enough to place the residue under tension. Thus the flaccid penis still droops as it did before circumcision. The sulcus is not held fully open; therefore it is still possible for smegma to accumulate. (G) before and (H) after for the “high and tight” style: Much of the inner foreskin has been retained, folded back on itself to face outwards and assume the role of shaft skin. The outer foreskin has been removed, as has a considerable amount of shaft skin. This has placed the residual shaft skin under tension, with the result that the flaccid penis appears to be short and semi-erect. The sulcus is held fully open; therefore it is not possible for smegma to accumulate. Diagrams from:

<http://www.circlist.com/styles/page1.html#terminology>

view is that, unless or until proof positive emerges to the effect that a “high” style confers as great a degree of prophylaxis as a “low” style, the Precautionary Principle should be applied and circumcisions should be done in the “low” style.

Traditional circumcisions done using "tug-&-chop" methods (Fig. 2) already provide us with ample examples of residual inner foreskin. There appears to be scope for a population study here, comparing HIV infection rates amongst groups with “high” and “low” styles of circumcision.

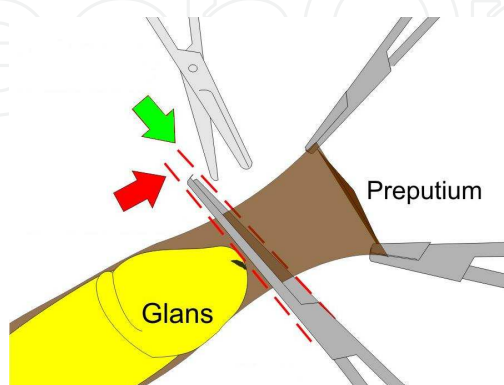


Fig. 2. The “tug-and-chop” method of circumcision.

Another somewhat contentious style issue is the matter of tightness. Often, tightness is considered to be nothing more than a cosmetic matter. However, theoretical models of STI transmission tend to suggest that benefit is gained from the sulcus being dry. This implies that circumcisions should be sufficiently tight to hold the sulcus open, such that no moisture will accumulate there.

The third style issue to be resolved relates to removal or retention of the frenulum. As well as having high concentrations of antigen receptor cells targeted by HIV, the highly vascular frenulum is particularly susceptible to tearing or other damage during intercourse, as well as being a frequent site of lesions produced by other STIs (Szabo & Short, 2000). Persistent debate relates to resulting changes in sexual sensitivity; anecdotal evidence from those who have had their frenulum surgically removed suggest that no loss of sensitivity occurs. It is also worthy of note that the frenulum can be lost as a result of tearing; such loss does not appear to give rise to complaint about effects long-term.

In the light of all of the above, there appears to be a good cause not just to circumcise but to circumcise in a particular way. It seems appropriate for the surgery to specifically target certain classes of cells for removal, at the same time achieving a result that holds the sulcus open so that it remains dry and clean, unable to harbour a viral payload either in smegma or in residues of erogenously triggered body fluids.

5. Methods of circumcision

We will now present information on current approaches to circumcision, mostly stemming from experience in developed nation settings, the USA in particular. We will start with infants and then move on to adults and older boys. We will end with speculation about what is needed for low-resource settings in terms of devising novel devices.

There is no standard circumcision procedure and the issue of standards has been a rallying call for years. At the Western Section American Urological meeting in 2007 Dr Sam Kunin,

who practices in Los Angeles, compared and contrasted clamps and discussed what he considered should be the minimal standards for circumcision (Kunin, 2007a).

The postnatal period provides an ideal window of opportunity for circumcision (Schoen, 2007a). The newborn, having recently experienced the considerable trauma of birth, has elevated levels of normal stress-resistance hormones. Neonates heal quickly, are resilient, and use of local anaesthesia means little or no pain. Since the inner and outer foreskin layers readily adhere to each other afterwards, sutures are rarely needed in this age group.



Fig. 3. Photo of a baby boy having a circumcision.

There is no evidence of any long-term psychological harm arising from circumcision. The risk of damage to the penis is extremely rare and avoidable by using a competent, experienced doctor. Unfortunately, because it is such a simple, low-risk procedure, it had once been the practice to assign this job to junior medical staff, with occasional devastating results. Anecdotes of such rare events from the past should be viewed in perspective. Parents or patients nevertheless need to have some re-assurance about the competence of the operator. Also the teaching of circumcision to medical students and practitioners needs to be given greater attention because it is performed so commonly and needs to be done well. Models to teach interns and others have, moreover, been produced (Erikson, 1999; Cohen, 2002).

6. Traditional circumcision of infants

Surgical methods often use a procedure that protects the penis during excision of the foreskin.

Safe implementation of the Jewish tradition of circumcision on the eighth day of life led to the development of what is termed the "Traditional Jewish Shield". At one time made from silver (a material chosen for its natural aseptic qualities), the identical method is now to be found in conjunction with single-use disposable equipment. The objective of the device is to prevent accidental injury to the glans.

The traditional Jewish equipment typifies the "Tug-&-Chop" method. Similar shielding can equally be achieved with forceps or a haemostat, whereupon it becomes known as the forceps-guided technique. Cutting can be done with scissors, a scalpel or an electrocautery device. In all instances the mucosal skin that is stretched between the sulcus and the distal

face of the shield remains intact. Given the current state of knowledge, such a style of circumcision must be regarded as sub-optimal.

Wholly freehand circumcisions did occur, but at theoretically greater risk of injury to the glans.

None of the traditional devices automatically result in removal of the frenulum. If that is required, it must be done as a separate procedure.

7. Medical circumcision of infants and very young boys

In the 1930s in the United States, the search for a means of bloodless circumcision of infants began. Yellen set out the principles involved (Yellen, 1935), but it fell to others (Goldstein, 1939; Ross, 1939; Bronstein, 1955; Kariher & Smith, 1955) to produce workable devices to implement the concept. Numerous patent applications for circumcision instruments were filed during this period, especially in the United States as can be seen by referring to the US Patent and Trademark Office database (USPTO), but few of the inventions passed into mass production and routine use. Meantime, in Europe, a similar but apparently unpatented device known as the Winkelmann Clamp was gaining favour (untraced in the European Patent Office database).

Such devices can be divided into two categories: Those that rely on ischaemic necrosis and those that do not. Ischaemic necrosis involves the deliberate killing-off of tissue by strangulation of its blood supply for a period of days, as in the Ross Ring and the Plastibell® (the trade name given to Kariher and Smith's device). The other devices first crush the blood vessels, typically for a period of some minutes, and then provide protection for the glans when the foreskin is severed. Conventional wound healing follows. In infants, the crushing action is sufficient to seal the wound such that sutures are not normally needed.

In consequence of the design fundamentals of the Gomco (GOLDSTEIN MEDICAL COMPANY) clamp (the trade name given to Goldstein's device) and the Winkelmann Clamp, these two clamps have the potential to remove almost all inner foreskin. The inner, "bell" component reaches beneath the prepuce in a way that places the cut near to the coronal rim of the glans. In consequence, as regards HIV prophylaxis, the resulting style of a circumcision done with these clamps is preferable to any "Tug-&-Chop" method.

In the USA the most commonly used devices are the Gomco clamp (67%), the Mogen clamp (10%) and the Plastibell (19%) (Stang & Snellman, 1998). Pictures of these appear later and can also be found in references: (Langer & Coplen, 1998; Alanis & Lucidi, 2004). The latter article in particular discusses the procedure, as well as contraindications. A technique that uses the Plastibell as a template for paediatric circumcision has been developed (Peterson *et al.*, 2001). Rather than waiting for the bell to slough off days later, sutures are made at the time and the bell is removed. A similar "adult circumcision template" was later created for use in men, with good results (Decastro *et al.*, 2010).

The various devices serve to protect the penis when excising the prepuce. The type of clamp used affects the time taken for the procedure, being on average 81 seconds for the Mogen clamp and 209 seconds for the Gomco clamp (Kurtis *et al.*, 1999). In a head-to-head trial of length of procedure the Mogen took 12 minutes, compared with 20 minutes for the Plastibell (Taeusch *et al.*, 2002). The latter time is far greater than others generally achieve (see 8.2.4 below). Although simpler to use and more pain-free than the other two (Kurtis *et al.*, 1999; Kaufman *et al.*, 2002; Taeusch *et al.*, 2002), the Mogen clamp removes less foreskin. The Gomco is the oldest and is the most refined instrument (Wan, 2002). Its use is widespread, a study in Togo confirming its superiority to grips-only circumcision (Gnassingbé *et al.*, 2010).

Since some of these more elaborate methods can take up to 30 minutes to perform they therefore expose the baby to a greater period of discomfort. In contrast, a circumcision can be completed in 15–30 seconds by a competent practitioner using methods that are part of traditional cultures.

Interestingly, strict sterile conditions were reported not to be necessary to prevent infection in ritual neonatal circumcision in Israel (Naimer & Trattner, 2000).

Rather than tightly strapping the baby down, swaddling and a pacifier has been suggested (Herschel *et al.*, 1998; Howard *et al.*, 1998; Howard *et al.*, 1999). A special padded, “physiological” restraint chair has moreover been devised and shown to reduce distress scores by more than 50% (Stang *et al.*, 1997). Exposure to a familiar odour (the mother’s milk or vanilla) reduces distress after common painful procedures in newborns (Goubet *et al.*, 2003; Rattaz *et al.*, 2005; Goubet *et al.*, 2007).

Dr Tom Wiswell and other experts strongly advocate the neonatal period as being the best time to perform circumcision, pointing out that the child will not need sutures (owing to the thinness of the foreskin (Schoen, 2005)) nor general anaesthesia, or additional hospitalization (Wiswell & Geschke, 1989; Wiswell & Hachey, 1993; Wiswell, 1995; Wiswell, 1997; Wiswell, 2000). Wiswell pointed out (personal email communication in Apr 2009) that “starting in the 1970s there was a movement away from delivery room circumcisions at minutes of life until several hours to several days of life. This was mainly because of the recognition of the transition period to extrauterine life that babies go through. ‘Stresses’ can have an adverse effect on this process, particularly on the heart and lungs. In an otherwise healthy infant, though, there is no need to delay until 2 weeks of age.”

All circumcisions should involve adequate anaesthesia, using either EMLA cream, dorsal penile nerve block, penile ring block, or a combination of these prior to the operation (<http://www.circinfo.net/anaesthesia.html>). Without an anaesthetic the child experiences pain, during the procedure and for a maximum of 12–24 hours afterwards. That the baby could remember for a *short* time was suggested by a greater responsiveness to subsequent injection for routine immunization (Taddio *et al.*, 1997). The child does not, however, have any long-term memory of having had a circumcision performed and there are no other long-term adverse effects (Fergusson *et al.*, 2008). Local anaesthesia is therefore advocated.

Whatever the method, post-operative care, as advised by the doctor, must be undertaken, usually by the parents. Cosmetic results have met with unanimous parental acceptance (Duncan *et al.*, 2004).

Healing is rapid in infancy (Schoen, 2005), complication rate is very low (0.2%–0.6%) (Wiswell & Geschke, 1989; Cilento *et al.*, 1999; Christakis *et al.*, 2000; Ben Chaim *et al.*, 2005), and cost is much lower than when performed later in life (Schoen *et al.*, 2006).

For males with haemophilia, special pre-operative treatment is required (Balkan *et al.*, 2010; Yilmaz *et al.*, 2010). A satisfactory outcome can be achieved with a specialized cost-effective device (Karaman *et al.*, 2004; Sewefy, 2004). Just as for healthy individuals (see below), cyanoacrylate tissue adhesives (Glubran and Glubran 2) have been found to be effective for circumcision of haemophilia patients (Haghpanah *et al.*, 2011).

8. Circumcision of adults and boys post-infancy

8.1 Freehand methods

Circumcision is more traumatic, disruptive and expensive for men and older boys than it is for infants (Schoen, 2007a). For those aged 4 months to 15 years some authorities advocate a

general anaesthetic. Others strongly disagree, saying that since a general anaesthetic carries a small risk, a local anaesthetic, often with a mild sedative, is what should be used for all children (Schoen, 2007a).

Unlike infant circumcisions, sutures/stitches or wound staples are usually needed for men and older children, although use of synthetic tissue adhesives such as 2-octyl-cyanoacrylate (Dermabond) (Cheng & Saing, 1997; Subramaniam & Jacobsen, 2004; Ozkan *et al.*, 2005; Elmore *et al.*, 2007; Elemen *et al.*, 2010; Lane *et al.*, 2010; D'Arcy & Jaffry, 2011) have proven to be effective alternatives. These are safe, easy to use, reduce operating time, lower postoperative pain and give a better cosmetic appearance (Ozkan *et al.*, 2005; Elmore *et al.*, 2007).

Excellent cosmetic results were reported for all of 346 patients aged 14 to 38 months using electro-surgery, which presents a bloodless operative field (Peters & Kass, 1997). Metal of any kind (such as the Gomco clamp that is used commonly in infant MC) has to of course be avoided in this procedure.

Laser surgery is gaining popularity, but requires both specialized equipment and training. The method has its own associated shields (Chekmarev, 1989; Zhenyuan, 1989; Gao & Ni, 1999).

Gentle tissue dissection with simultaneous haemostasis has been achieved using an ultrasound dissection scalpel for circumcision (Fette *et al.*, 2000).

A randomized trial found that a bipolar diathermy scissors circumcision technique led to less blood loss (0.2 versus 2.1 ml), shorter operating time (11 versus 19 min) and lower early and late postoperative morbidity as compared with a standard freehand scalpel procedure (Méndez-Gallart *et al.*, 2009). Bipolar scissors also appear to offer a method of bloodless removal of the frenulum prior to application of any one of a number of circumcision clamps for the remainder of the procedure.

Unless combined with other surgery, circumcision later obviously requires a separate (occasionally overnight) visit to hospital. Healing is slower than in newborns and the rate of complications is greater, but still low: 1–4% (Auvert *et al.*, 2005; Cathcart *et al.*, 2006; Bailey *et al.*, 2007; Gray *et al.*, 2007; Krieger *et al.*, 2007). Most common is postoperative bleeding (0.4–0.8%), infection (0.2–0.4%), wound disruptions (0.3%), problems with appearance (0.6%), damage to the penis (0.3%), insufficient skin removed (0.3%), delayed wound healing (0.1%), delayed healing (0.2%), swelling at the incision site or haematoma (0.1–0.6%) or need to return to the theatre (0.5%). An average of 3.8% adverse events has been seen for the first 1–100 circumcisions a clinician does (Krieger *et al.*, 2007). For the next 100 this decreases to 2.1% and by the time they have done 200–400 it drops to less than 1%. Beyond 400 it is 0.7%. The incidence of penile adhesions after a circumcision decreases with age, but at any age they often resolve spontaneously (Ponsky *et al.*, 2000). Pain sometimes can last for days afterwards and those older than 1 to 2 years may remember.

Cost is also much greater than for neonatal circumcision. Cost can be reduced by having the surgery performed on an outpatient basis.

A local anaesthetic is all that is needed for MC, so reducing anaesthetists' charges which can be quite high for a general anaesthetic. The WHO has produced a manual for circumcision of men under local anaesthesia (World Health Organisation, 2006). Various methods can be used for local anaesthesia, including dorsal penile nerve block and ring block. Recently, a no-needle jet of 0.1 ml 2% lidocaine solution sprayed at high pressure directly on to the penile skin circumferentially around the proximal third of the penis has proven to be quick and effective, and has obvious appeal (Peng *et al.*, 2010a).

Conventional surgery under general anaesthetic normally uses the sleeve-resection technique, described in a series of diagrams with technical details by Elder (2007). This method takes longer and for this reason many surgeons will insist on using a general anaesthetic. By its nature sleeve resection removes mainly shaft skin, not foreskin, so having potential implications for HIV infection. An alternative is the Dissection Method. These two methods are often confused. Illustrated by Mousa (Mousa, 2007), the Dissection Method separates inner and outer foreskin in a manner similar to a very loose "tug and chop" circumcision, but then proceeds to excise most of the inner and all of the outer foreskin along with some shaft skin. The amount of shaft skin removed depends on the tightness required; inner foreskin is left only as necessary to provide an anchorage for sutures reconnecting the shaft skin to the sulcus.

Interestingly, genital surgery in women often involves a course of topical estrogen in advance in order to increase thickening, cornification and keratinization of the vaginal epithelium (Short, 2006). This helps surgical outcome and has led to the suggestion that similar pre-treatment be carried out prior to circumcision in men.

Pain from conventional surgery can last for up to a week or longer afterwards, during which time absence from work may be required. Some men, however, report no pain, just minor discomfort from the stitches. A large RCT found that at the 3-day post-circumcision follow-up, 48% reported no pain, 52% very mild pain, and none moderate or severe pain (Bailey et al., 2007). By 8 days, 89% had no pain and 11% mild pain. Vasectomy in men circumcised previously as adults (and who can thus attest to the difference) is said to be much more painful.

8.2 Instruments developed over earlier years

The following devices were in common use for male circumcision prior to the start of the HIV epidemic. The patent information quoted relates to the country of residence of the inventor(s). In many instances other patents exist, especially in the USA, the European Union and, since its formation in 1967, the records of the World Intellectual Property Organisation (WIPO).

8.2.1 Traditional Jewish shield

Inventor:	Unknown
Primary patent:	None: historic
Patent priority date:	Not applicable
Patient age range:	Full-term neonate to adult
Category:	Tug-&-Chop shield



Fig. 4. The traditional Jewish shield.

Procedure: The foreskin is pulled forward and the shield slipped over it. The excess prepuce is then excised by running a scalpel or similar knife across the distal face of the device.

8.2.2 Gomco Clamp

Inventor: Goldstein, A.A.
Primary patent: United States Design Patent USD119180 (no Utility Patent has been traced)
Patent priority date: 16 Mar 1939
Patient age range: Full-term neonate to adult
Category: Bell clamp / scalpel guide

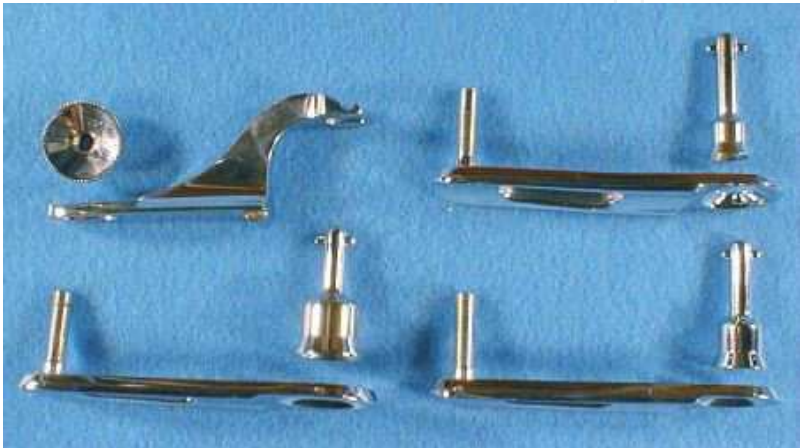

Fig. 5. The Gomco Clamp showing components, in a range of sizes, that are assembled during the procedure described in the text.

Procedure: First of all, a dorsal slit is made in the foreskin and the foreskin is separated from the glans. The bell of the Gomco clamp is then placed over the glans, and the foreskin is pulled over the bell. The base of the Gomco clamp is placed over the bell, and the Gomco clamp's arm is fitted. After the surgeon confirms correct fitting and placement (and the amount of foreskin to be excised), the nut on the Gomco clamp is tightened, causing the clamping of nerves and blood flow to the foreskin. The Gomco clamp is left in place for about 5 minutes to allow clotting of blood to occur, then the foreskin is dissected off using a scalpel. The Gomco's base and bell are then removed, and the penis is bandaged. It is a fairly bloodless circumcision technique. The circumcision is relatively quick compared to the Plastibell. It was the most popular method for circumcisions between 1950 and 1980 and is still common today, especially in the USA. A training video of a neonatal Gomco circumcision using dorsal penile nerve block and a sucrose pacifier, conducted by Dr Richard Green, Stanford University School of Medicine, is available at <http://newborns.stanford.edu/Gomco.html>
Dr Sam Kunin, an experienced urological surgeon in Los Angeles, has developed a clever, and very effective, method in which local anaesthetic is injected into the distal foreskin (Kunin, 2007b). Doing so separates the inner and outer foreskin therefore allowing the inner layer to be pulled against the bell of the Gomco clamp, and results in a maximum amount of inner layer being removed (<http://www.samkuninmd.com>). He points out that the inner lining is the area most prone to adhesions, irritations, yeast and bacterial infections, particularly in diabetics.
Gomco clamps exist in sizes from neonatal to adult. Suturing is required post-infancy.

8.2.3 Winkelmann Clamp

Inventor:	Provisionally attributed to the German urological surgeon Karl Winkelmann (1863–1925).
Primary patent:	None traced
Patent priority date:	None traced
Patient age range:	Infant to mid-puberty, according to manufacturer.
Category:	Bell clamp / scalpel guide



Fig. 6. The Winkelmann Clamp.

Procedure: Nominally the same as the Gomco clamp described above. Despite its ready availability, the Winkelmann Clamp appears not to have been trialled in connection with the search for devices suitable for campaigns of mass circumcision.

8.2.4 Plastibell

Inventors:	Kariher, D.H. and Smith, T.W.
Primary patent:	US3056407
Patent priority date:	18 May 1955
Patient age range:	Full-term neonate to onset of puberty
Category:	Ischaemic necrosis device using string ligature

Procedure: The Plastibell is a clear plastic ring with handle and has a deep groove running circumferentially. The adhesions between glans and foreskin are divided with a haemostat (artery forceps) or similar probe. Then the foreskin is cut longitudinally starting at the distal end dorsally to allow it to be retracted so that the glans (the head of penis) is exposed (Elder, 2007). The appropriately sized device is chosen and applied to the exposed glans. The ring is then covered over by the foreskin. A ligature is tied firmly around the foreskin, crushing the skin against the groove in the Plastibell. Then the excess skin protruding beyond the ring is trimmed off, something that is possible using surgical scissors rather than a scalpel. Finally, the handle is broken off. The entire procedure takes 5 to 10 minutes, depending on the experience and skill of the operator. The compression against the underlying plastic shield causes the foreskin tissue to necrotize. The ring falls off in 3 to 7 days leaving a circumferential wound that will heal over the following week. Typically, the glans will appear red or yellow until it has cornified (Gee & Ansell, 1976; Holman *et al.*, 1995).

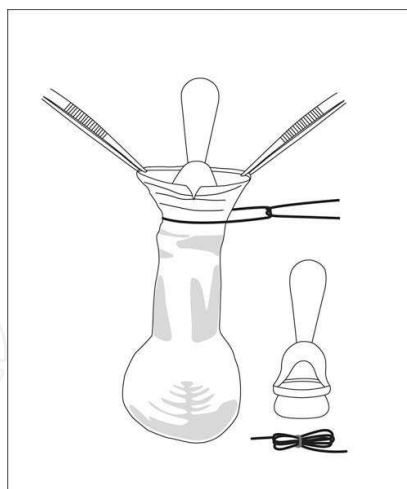


Fig. 7. The Plastibell device is a clear plastic ring with handle and has a deep groove running circumferentially. Upper diagram: How it is used for an infant circumcision (diagram modified from Elder (2007)). Lower image: Dr Terry Russell, Brisbane, Australia, displaying the range of sizes available.

The Plastibell continues to be available in sizes applicable from newborn to early puberty. The metallic precursor, the Ross Ring (Ross, 1939), also came in adult sizes, but adult Plastibell circumcision appears to be unknown. The metallic ring is long discontinued, rendered obsolete by its disposable plastic equivalent. Cosmetic results have met with unanimous parental acceptance (Duncan et al., 2004).

Dr Terry Russell in Brisbane, Australia, developed in 1993 a simple, pain-free method involving 2 hours EMLA cream with the penis wrapped in cling wrap (done by the parents prior to arrival at the clinic), followed by a modified Plastibell circumcision (Russell & Chaseling, 1996). The technique is described in detail on his website (<http://www.circumcision.com.au>). Dr Russell has used it in 30,000 circumcisions on boys of all ages from neonate to puberty, including 400 older boys every year. More recently he has obtained excellent results with another topically applied anaesthetic cream, LMX4 (4% lidocaine) that is faster acting, more effective and has fewer side effects (C.T. Russell, personal communication). Because complete local anaesthesia is achieved by EMLA or LMX4 cream, Dr Russell reports that no pain is experienced for 5 hours after the Plastibell is applied, so claims the circumcision is completely pain free at all stages. The only major complication in 30,000 circumcisions was one boy who developed mild

methemoglobinaemia (from the EMLA cream) that, after immediate hospital admission, resolved spontaneously overnight, with no medical intervention required.

Prof Roger Short orchestrated the production of a video that teaches the Russell method. Dr Russell featured in this "no scalpel circumcision" video. Also featured was one of Prof Short's students from Botswana, who took it there for teaching purposes. Another, filmed in Vanuatu of a traditional circumcision using a sharpened bamboo, was produced for use in Papua New Guinea (PNG) where, unlike most Pacific Islands, circumcision is uncommon. These were aimed primarily to reduce HIV/AIDS in Botswana and PNG.

Since the simple plastic Plastibell device is now off patent it can be produced at very low cost, but parallel production cannot use the name Plastibell, which remains to this day a Registered Trade Mark. Nevertheless, the device has the potential to help reduce HIV in poor countries (Short, 2004).

Dr. Sam Kunin points out, however, that "the [Plasti]bell techniques leave too much inner skin. Besides the inherent problems of this method with later adhesions and buried penis, allows for possible migration of the bell down the shaft, with ensuing potential damage to the penile skin" (personal communication). A Nigerian study also noted that incorrect technique can lead to proximal migration of the Plastibell in neonatal boys (Bode *et al.*, 2009). Correct training in this method is thus essential. An Iranian study involving 7,510 term neonates found that Plastibell circumcision incorporating thermal cautery of the frenulum reduces bleeding (0.4% versus 0.05%), but led to greater urinary retention (0.03% versus 0.9%) (Kazem *et al.*, 2009). Modifications to the standard procedure by authors in the UK have improved outcomes, particularly the risk of bleeding (Mahomed *et al.*, 2009).

A study in Pakistan found that for babies under 3 months of age, the time taken for the Plastibell to fall off was 8.7 days (Samad *et al.*, 2009). This increased gradually to 16.8 days for children over 5 years.

8.2.5 Mogen Clamp

Inventor:	Bronstein, H.
Primary patent:	US2747576
Patent priority date:	3 Feb 1955
Patient age range:	Full-term neonate to adult
Category:	Tug-&-Chop shield with inbuilt crushing action



Fig. 8. The Mogen Clamp.

Procedure: Firstly, adhesions between glans and foreskin are divided and a haemostat is placed along the dorsal midline with its tip about 3 mm short of the corona before being locked into place. The Mogen clamp is opened fully. A key step in Mogen circumcision is the safe placement of the clamp. To push the glans out of the way, the surgeon's thumb and index finger pinch the foreskin below the dorsal haemostat. The Mogen clamp is then slid across the foreskin from dorsal to ventral following along the same angle as the corona. The hollow side of the clamp faces the glans. Before locking the clamp shut, the glans is manipulated to be sure it is free of the clamp's jaw. If it is, the clamp is locked. Once locked the foreskin is excised flush with the flat surface of the clamp with a 10 inch blade scalpel. The clamp is left on for a few moments to ensure haemostasis. It is then unlocked and removed. The glans is liberated by thumb-traction at the 3 and 4 o'clock positions that pull the crush line apart.

This device can be and has been used across the whole age range. However, recent safety issues involving the glans being drawn into the clamp are reported to have brought about the bankruptcy of the original manufacturer (Tagami, 2010).

9. Objectives and constraints relating to a campaign of mass circumcision

With the possible exception of the Plastibell, the traditional devices appear not to be well suited to field use by personnel not fully trained as medical professionals. This has led to the development of a number of new designs. Before moving on to consider each in detail, we first address the issue of the design objectives.

Over 30% of the world's male population enters adulthood already circumcised, their foreskins having been removed in infancy, childhood or around puberty, either as a prophylactic measure for prevention of disease, for hygiene reasons, family tradition, cultural reasons, religious requirements, or treatment of foreskin-related medical conditions (World Health Organisation, 2007b). That still leaves hundreds of millions of uncircumcised males who are (or later in life will become) sexually active, but lack the baseline protection provided by MC against a wide range of STIs and other adverse medical conditions.

Valiant MC scale-up efforts are in progress in sub-Saharan Africa. It is, however, unrealistic to expect existing surgical resources to be diverted to the task of circumcising these millions of men worldwide. Such expertise is already fully committed elsewhere. What is required is an *ad hoc* contingent of circumcisers, a cohort of people with sufficient training to carry out circumcisions safely, effectively, with a good cosmetic outcome and minimum disturbance to lifestyle. Given the vast numbers involved, recruitment from outside the pre-existing medical profession is inevitable. Such a need has, moreover, been recognized by those "on the ground" in sub-Saharan Africa (Sahasrabuddhe & Vermund, 2007; Sharlip, 2008; Wamai *et al.*, 2008; World Health Organization, 2008b).

Herein lies the justification for introducing newer methods of circumcision reliant on advances in biomedical engineering. What is needed is a device and method that de-skills the surgical process to the point where it can be safely and effectively undertaken by people whose prior educational achievement would not otherwise have admitted them to the medical profession. Then, and only then, can a campaign of mass circumcision take place without major poaching of skilled personnel from other healthcare programmes.

Prudent planning nevertheless envisages a fully qualified person to be nearby, acting as supervisor and capable of completing by conventional surgery any circumcision that goes wrong when attempted by ordinary members of the task force using de-skilled

methodology. Dispensing totally with such supervision and backup would, in the authors' opinions, be too risky.

No matter what method is used, adequate training in technique is crucial. To this end a low-cost penile model has been developed as a teaching aid for use in low-resource settings (Kigozi *et al.*, 2011).

As with previous global public health campaigns such as the one that successfully achieved the eradication of smallpox, it is imperative to bring MC services to the people rather than expect the people to visit distant facilities. Take the example of the peasant farmer. He cannot leave his livestock and his family unattended for days on end whilst he travels, probably on foot, to a clinic many miles away. Hence our second requirement for the ideal new MC device: It must be suitable for use in conditions of limited asepsis. A clean consulting room in a village health clinic would be a luxury, as would a mobile facility built into a shipping container and driven around by truck. Think more in terms of a clean cloth draped over a table in a bamboo or mud hut, with village elders in attendance waving their ceremonial fly whisks and the circumciser arriving on foot with all necessary equipment in a small rucksack. No roads, no electricity, no running water. The 2nd author, Chris Eley, saw exactly this at a religiously-motivated circumcision in Seram, Indonesia, in 1987 (Operation Raleigh expedition 11E, led by the late Major Wandy Swales TD). On that occasion the surgery was done freehand by a well-qualified and highly proficient Egyptian doctor, using injected local anaesthesia, forceps, surgical scissors and sutures.

One obvious consequence of such remoteness is that facilities for re-sterilizing equipment are non-existent. Therefore the ideal device should be single-use. That applies not only to the clamp itself, but also to all ancillary equipment such as any tool needed to close it, plus syringes, forceps and so on. Think here of a whole single-use kit packaged as one, not just a clamping device on its own.

Against this outline of medical objectives, social and logistical background, we can begin to construct a checklist of the design parameters to be met by candidate devices.

Already mentioned:

- Suitable for use by persons without recognised medical qualifications, with limited supervision.
- Suitable for field use; no requirement for an aseptic environment.
- Single use / disposable.

To this list must be added:

- *Cost*: Rather obviously this needs to be minimized, but the raw cost of the device is only a small part of the total financial commitment. Staffing, provisioning and transport in remote areas can dwarf the cost of the circumcision device that the team intends to fit. The design of the device nevertheless remains crucial. For example, does it need a trained attendant to remove it? If so, staffing costs may straight away have escalated in comparison with a rival device not routinely requiring such follow-up.
- *Simplicity*: The ideal device should be easy to comprehend. Not only does that simplify training, it also simplifies the obtaining of each prospective patient's informed consent. Simplicity also reduces the possibility of user error. This implies minimizing the number of components, avoiding all possibility of mis-assembly (such as getting something the wrong way round) and misuse (such as making a scalpel cut on the wrong side of a clamping ring). Enter what we politely refer to here as "The Law of the Inevitable Cussidness of Inanimate Objects", better known as Sod's (or Murphy's) Law

(http://en.wikipedia.org/wiki/Murphy's_law). If something possibly can go wrong, it will. Botched circumcisions cause immense psychological distress. The duty of care owed is of the highest order. One good measure of simplicity is the number of components in a device, the lower that number the better.

- *Size range:* Where the intent is to produce a single design for the whole male population, the smallest device should fit a full-term neonate and the largest should fit the most well-endowed male. But what about those in-between? There is a balance to be struck here between, on the one hand, having a device that is precisely sized so that it is correct for each patient and, on the other hand, needing to carry a vast stock of different sizes. A certain latitude in sizing is needed, such that an acceptable circumcision results even if the device is a few millimetres off the ideal. This is not merely a matter of stockholding; critical sizing invites increased error due to the use of mis-selected devices and it also increases waste arising when an incorrect size is selected and removed from its sterile packaging but discarded before use.
- *Sterility:* Delivery to remote locations requires robust packaging, but that is only half the story. Not all sterilization processes can be applied to all materials. There are known pitfalls with many plastics. Cobalt-60 exposure (gamma irradiation) is a very effective way of sterilizing, but is totally unsuited to a number of plastics; many discolour and become brittle when irradiated. Full consideration of this materials science issue is beyond the scope of the present chapter; just note and beware! The present alternative is the environmentally questionable Ethylene Oxide method. In time, it may become possible to use ultra-high voltage electrostatic fields on an industrial scale, but that is still in the future (Wang *et al.*, 1992; Meijer, 2008).
- *Suitable materials:* Devices that are intended to remain in contact with body tissue for an extended period must be hypoallergenic. Factors such as contact time and plasticizer residues must be scrutinized. The device supply chain should be secure against pirate copies and adulteration of the original specification.
- *Disposability:* Waste disposal must be managed, not just in respect of the usual medical sharps, but also in respect of sloughed-off clamps and associated necrotic tissue. In some societies the payment of a bounty for the return of the spent device might be appropriate as a way of bringing about proper disposal.
- *No fraudulent re-use:* Single-use devices should be exactly that. A key question might be "Does the device self-destruct at the end of the procedure?"
- *Avoidance of wound dehiscence:* "Clip-&-Wear" clamps with an exceptionally narrow clamping ring can bring about wound dehiscence, especially when the circumcision style is tight such that the shaft skin is significantly stretched. What was intended merely to grip takes on the potential to cut, doing so proximally to the intended scar line and thus forcing remedial action that results in a tighter circumcision than originally envisaged. This problem appears to be age-related and gives rise to some criticism of the widespread use of ischaemic necrosis techniques in adults (Vernon Quaintance, The Gilgal Society, personal communication). There may be good cause for separating out older sexually-active adults and providing them with conventional surgery. Local factors appear to intrude here, especially nutritional status, a well-known determinant of wound healing capacity.
- *Even and adequate clamping pressure:* Devices using the process of ischaemic necrosis need to apply their strangulation pressure evenly right around the intended scar line.

Unless effective counter-measures are taken, pressure discontinuities can arise, especially at hinge positions and/or latch positions. This gives rise to the possibility of continued marginal blood flow at these points. In terms of infection, such marginal leaking is exceptionally dangerous. A good design for an ischaemic necrosis clamp is one that has no discontinuity in the clamping ring and which, throughout the wear period, maintains an absolutely even pressure sufficient to bring about total cessation of blood flow across the whole of the intended scar line.

- *Resistance to premature removal by a meddlesome patient:* Premature removal of an ischaemic necrosis clamp can precipitate a clinical emergency. Therefore it is vital that the latching mechanism of the clamp should be secure against tampering. The risk of such tampering is greatest when dealing with post-infancy paediatric patients.
- *Minimum requirement for pre-treatment:* In the world of veterinary medicine, immunization against tetanus is recommended when ischaemic necrosis is used for procedures such as tail docking of lambs by means of the Elastrator device (Thedford, 1983). We commend the idea of similar pre-treatment before any ischaemic necrosis procedure is used for MC.
- *Cultural acceptability:* A whole raft of issues can arise here, any one of which might scupper a proposal to use a particular design of clamp in a particular area. For example, is a device invented in Israel assured of acceptance in Islamic Republics that do not even acknowledge the existence of the Jewish state? Will circumcision ever be accepted by Hindus, many of whom value their foreskins as evidence of not being Muslim? During the partition of India in 1947, strangers suspected of being of the opposite faith were disrobed and put to death on no more evidence than their circumcision status (Kamra, 2002). Rather less dramatically, there is the question of whether a clip-&-wear clamp protrudes beyond the end of the penis during the wear period. Not a problem in societies where loose, flowing robes are normal attire, but an entirely different matter when the male is habitually dressed in tight jeans.

10. Resulting new designs for circumcision devices

The authors are aware of eight products designed to fulfil the demand for a field-use device, all being either in full production or in the final stages of development and testing. These are now considered individually, in alphabetical order of trade name. Only the original patents or patent applications *in the inventor's country of residence* are listed; increments may exist in the same country as well as there being patents elsewhere.

It should be noted that some clamps have been the subject of ongoing development after their initial market launch. Care is needed when reading reports of field trial results. Early criticisms may have been rendered obsolete by subsequent design changes.

10.1 AccuCirc

Inventor:	Tomlinson, D.R.
Primary patent:	US2005/022404
Patent priority date:	25 Jun 2004
Patient age range:	Full-term neonate only
Website:	http://www.accucirc.com
Category:	Automated cutter

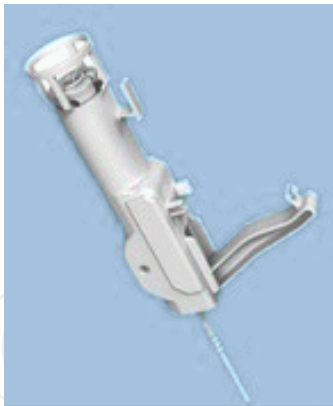

Fig. 9. The AccuCirc device.

Procedure: The AccuCirc uses two innovative components, a Foreskin Probe/Shielding Ring that ensures the glans is protected with the foreskin properly aligned and a Single-Action Clamp that ensures adequate haemostasis and the precise delivery of the protected, circular blade. These work together to protect the infant from injury. This device simplifies the circumcision procedure and eliminates the need for a dorsal slit, as well as removing potential for mismatching of parts. It comes in a self-contained kit. This is completely disposable and no part is retained on the infant.

10.2 Ali's Klamp

Inventor:	Canoğlu, V.A.
Primary patent:	TR2003/00403
Patent priority date:	28 Mar 2003
Patient age range:	Full-term neonate to adult (experimental in adult sizes)
Website:	http://www.alisklamp.com
Category:	Ischaemic necrosis device



Fig. 10. Ali's clamp.

Procedure: The Ali's Klamp (a.k.a. "Alisklamp" and "Ali's clamp"; Telif Haklari ABAGROUP Ltd) is a single-use ischaemic necrosis device; the foreskin is crushed between two plastic surfaces. The recommended procedure includes severing of the excess tissue. During that process, the tube protects the glans from accidental injury. Note that the final scar line forms at the position of the clamping ring, not at the position of the scalpel cut. In theory the user

could dispense with the scalpel cut, leaving the whole foreskin to necrotise. The procedure is illustrated in a two-part video available on the manufacturer's website.

The Ali's Klamp differs from the SmartKlamp (below) only in one significant respect: The clamping ring is angled to match the typical slant of the coronal rim of the glans. In theory this achieves better capture of inner foreskin ventrally. The Ali's clamp apparently shares with the SmartKlamp one notable design weakness. An unwilling or meddlesome patient could, in theory, open the clamp by placing a flat object such as a table knife between the tube and the locking arms and then twisting. Additionally, such action would render the device liable to unscrupulous re-use several times over, until such time as the nominally single-use latching mechanism wore out.

A review of 7,500 boys who underwent circumcision with this device under local anaesthesia concluded that cosmetic appearance was better than conventional circumcision of 5,700 boys (Senel *et al.*, 2010). Duration was 4.5 ± 1.5 minutes versus 23 ± 4 minutes, respectively. Complications were seen in 2% of Ali's clamp versus 10.4% for conventional circumcision, the most common for the Ali's clamp being buried penis (1.04%), followed by infection (0.6%), bleeding (0.4%). A mass circumcision of 2,013 male infants, children, adolescents and adults (mean age 7.8 ± 2.5 years) over a 7-day period, noted a duration of 3.6 ± 1.2 minutes and complication rate of 2.93% in those < 2 years of age, mostly from buried penis (0.98%) and excessive foreskin (0.98%) (Senel *et al.*, 2011). In older children, adolescents and adults complication rate was 2.39%, 2.51% and 2.40%, respectively. Overall, excessive foreskin (0.7%) was the most common complication, followed by bleeding (0.60%), infection (0.55%), wound dehiscence (0.25%), buried penis (0.25%), and urine retention (0.10%). There was no effect on erectile function and libido, and a 96% satisfaction rate was recorded.

Originally available only for children, adult sizes reportedly now exist for use on a trial basis. Correspondence received mid-February 2011 from Dr. Ali Canoğlu claims a successful field trial in Africa. At the time of writing official independent reports have not yet been published.

10.3 Ismail Klamp

Inventor:	Salleh, I.
Primary patent:	MY2008/000195
Patent priority date:	16 Jan 2008
Patient age range:	Full-term neonate to puberty
Website:	http://www.ismailclamp.com/
Category:	Ischaemic necrosis device



Fig. 11. The Ismail Klamp.

Procedure: The Ismail Klamp is another single-use ischaemic necrosis device, functioning in the same way as the Ali's Klamp, SmartKlamp and Tara KLamp. The distinguishing feature of Dr. Ismail Salleh's device is that the clamping ring can be loosened as well as tightened during the process of application. This the manufacturer describes as "Reversible Clamping". Such a feature is undoubtedly an advantage if a tight style of circumcision is required; it gives greater scope for clamp adjustment. Against that advantage must be offset two risks: A meddlesome patient might loosen the clamp during the healing period and the clamp might be re-used unscrupulously.

10.4 PrePex

Inventors: Fuerst, O., Kilemnick, I. and Shohat, S.
Primary patent: (Application:) IL2010/000568
Patent priority date: 16 Jul 2009
Patient age range: Adult only at present
Website: <http://www.prepex.com/>
Category: Ischaemic necrosis device



Patent Pending PrePex device: prototype photo. Circ MedTech ©2011.

Fig. 12. The PrePex device. (Photo supplied by Circ MedTech ©2011)

Developed in 2009/10 by Dr. Oren and Tzameret Fuerst, Ido Kilemnick & Shaul Shohat (Fuerst *et al.*, 2009) and marketed by a company called Circ MedTech Limited (incorporated in the British Virgin Islands), this device is designed for use in non-sterile environments by minimally trained healthcare professionals.

Possibly unique for modern clamps, publicized abstracts of safety and efficacy trials held in Rwanda found it to be suitable for use without anaesthesia. Four hundred milligrams of oral Brufen is routinely offered 30 minutes after placement of the clamp, but no other drug use is involved. Whilst the surplus foreskin can be severed, in these trials the foreskin was left to necrotize intact thus facilitating a quick and bloodless procedure that can be handled by minimally trained healthcare professionals in non-sterile settings. The company affirms that there have been no complications to the urine stream as a result of the necrotized foreskin being left *in situ*.

In common with other ischaemic necrosis clamps, the PrePex device requires no sutures.

Procedure: After sizing and marking of the circumcision line based on the circumcision style desired (high/low), the Elastic Ring, loaded on to the Delivery Ring, is placed at “deploy-ready” position on the penis base (proximal). The foreskin tip is stretched open to allow insertion of the Inner Ring, directly under the coronal sulcus. The Elastic Ring is then deployed within the Inner Ring groove, initiating the ischaemic process and the Delivery Ring is removed. The patient resumes his activities with only the Elastic Ring visible. After 7 days, the device is removed by flicking the Elastic Ring out of the groove and extracting the inner ring with fingers or a standard medical spatula.

Regulatory issues (as declared by the manufacturer): "The device has a CE mark and is manufactured using USP Class VI biocompatible elastomeric materials compliant to ISO_13485 Medical Devices (Quality Management systems) and FDA, 21_CFR177.2600."

Declared contra-indication: The device is contraindicated for patients with phimosis if the chosen procedure leaves the foreskin intact.

Once evidence of the style of circumcision achieved by this device is made public, this latecomer to the design contest is expected to show significant advantages over its competitors – especially if the claim of suitability for routine use without anaesthesia is validated in more extensive trials.

10.5 Shang Ring

Inventor:	Shang, J.
Primary patent:	CN2003/000903
Patent priority date:	20 Oct 2003
Patient age range:	Full-term neonate to adult
Website:	http://www.snnda.com/enindex.asp
Category:	Ischaemic necrosis device

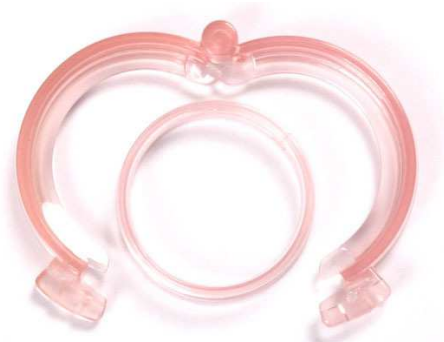

Fig. 13. The Shang Ring device.

Procedure: The "Shenghuan Disposable Minimally Invasive Circumcision Anastomosis Device", developed in China by Jianzhong Shang, involves minimal tissue manipulation and is said to give a simpler, quicker and safer circumcision than conventional techniques (Masson *et al.*, 2010). It consists of two concentric plastic rings that sandwich the foreskin of the penis, allowing circumcision without stitches or notable bleeding. As well as substantially reduced operating times, MC using this device is associated with a low complication rate, and the technique can easily be taught to both physicians and non-physicians. The Shang Ring is produced by Wuhu Snnda Medical Treatment Appliance Technology Co. Ltd, Wuhu City, China.

When tested on 1,200 patients aged 5 to 95 years operating time was 2.5 minutes for patients with excessive foreskin and 3.5 minutes for those with phimosis (Peng *et al.*, 2008). After application it is worn for a week, with no incidents of device dislocation or damage to the frenulum. Peng *et al.* describe the use of oral diethylstilbestrol (at a dosage of 2 mg/night) as a way to prevent nocturnal erections during the wear period. We do not find favour with this, due to the known environmental persistence of DES and the long-term effects of this synthetic oestrogen (Newbold *et al.*, 2006). In this study by Peng *et al.* the incision healed in 96.3%, leaving minimal inner foreskin, with no scarring and good cosmetic results. Antibiotics were not used, and only 0.67% got an infection. After removal, of the device 0.58% had some minimal bleeding around the incision and 2.4% had wound dehiscence of the incision caused by nocturnal erection, but this could be prevented by continuation of diethylstilbestrol for 3 days. It was treated by simply closing the incised rim with a butterfly adhesive plaster, followed by topical disinfectant; no stitches were required. Patients reported less pain than occurs for conventional methods.

Use of the Shang Ring has become a method of choice in the People's Republic of China. Evaluation of a standardized surgical protocol for its use, involving 328 men, showed an operating time of 4.7 ± 1.3 minutes, pain scores of 0.2 ± 0.6 during the surgery, 1.6 ± 1.0 24 hours postoperatively, 1.7 ± 1.1 twenty four hours prior to ring removal, and 2.7 ± 1.4 during ring removal (Cheng *et al.*, 2009). In this study, complications included infection in 0.6%, bleeding in 0.6% and wound dehiscence in 0.6%; none of the latter required suturing. Penile oedema occurred in 4.9%. The time for complete wound healing was 20.3 ± 6.7 days. Satisfaction was 99.7%.

A study in 824 boys with phimosis or redundant foreskin found duration was 2.6 ± 1.2 minutes (Yan *et al.*, 2010). Wounds healed and rings were removed at 13.4 ± 5.8 days revealing a well-smoothed incision and good cosmetic results. Complications were low and included infection in 0.6%, oedema in 3.2%, delayed removal of the ring in 1.5%, and redundant and asymmetric mucosa attributable to performance in 0.9%.

Another study in China, of 402 patients, found duration (4.7 ± 1.3) minutes, blood loss (2.6 ± 1.8 ml), and postoperative satisfaction (99.5%) for Shang Ring circumcision were significantly better than conventional circumcision, and International Index of Erectile Dysfunction (IIEF-5; not "IIRF-5" as stated in the paper) was no different (Li *et al.*, 2010). In 351 males aged 4 to 58 (mean 31) circumcised for phimosis or redundant foreskin using the Shang Ring, infection was seen in 1.4%, mild oedema in 2.6%, moderate oedema in 1.4%, and wound dishescence in 1.7%, with no postoperative bleeding being observed (Peng *et al.*, 2010b).

A proof of concept study in Kenya for the roll-out of MC for HIV prevention found a time of 4.8 ± 2.0 minutes for the procedure and 3.9 ± 2.6 minutes for device removal, with 6 mild adverse events in the 40 men who underwent Shang Ring circumcision (Barone *et al.*, 2011). These included 3 penile skin injuries, 2 cases of oedema and one infection, all of which resolved with conservative management. Partial ring detachment occurred in 3 between days 2 to 7, none of which required treatment or ring removal. Erections with the ring were well tolerated. By day 2, eighty percent of the men had returned to work, and at 42 days all said they were very satisfied with their circumcision and would recommend it to others.

Aside from the matter of diethylstilbestrol use, without which there appears to be a danger of an erection displacing the device, possible further criticisms relate to the discontinuity of the clamping ring at both the hinge and clasp. It should also be noted that it gives no protection whatsoever to the glans during the severing of the prepuce.

The same inventor has also obtained a patent in respect of another, more recent but very different design. The relevant patent is CN2009/000406. It is unclear whether the later design is intended to supersede the original, or compete with it.

10.6 SmartKlamp

Inventor:	Ten Have, H.F.
Primary patent:	MY0100375
Patent priority date:	30 Jan 2001
Patient age range:	Full-term neonate to mid-puberty
Website:	http://smartcircumcision.com/index.html
Category:	Ischaemic necrosis device




Fig. 14. The SmartKlamp.

Procedure: The SmartKlamp is an ischaemic necrosis device functioning in broadly the same way as the Ali's Klamp, Ismail Klamp and Tara KLamp.

Since its invention by Henri Ferdinand Ten Have, the commercial history of the SmartKlamp has to some extent interfered with its development and availability. Originally produced only in child sizes by the Dutch company Circumvent BV (Hengelo, The Netherlands), supply ceased when Circumvent BV went into liquidation, having apparently over-spent on research and development of the adult model. It should perhaps be noted that Circumvent's experimental adult device had an angled clamping ring similar in principle to that now found in the Ali's Klamp.

The apparently identical product in child sizes has now appeared in Malaysia, marketed by a supplier called Smartcircumcision. Aldemir and co-workers described the device thus: "This fits on the penis much as the others do. After 4 days the connection between its inner tube and casing is cut and removed. The inner tube is then left to fall off spontaneously in time. Median operative time is 8 minutes, compared with 18 minutes for conventional dissection, and cosmetic result, judged blinded by a urologist, was better. Parents' satisfaction scores were the same" (Aldemir *et al.*, 2008).

The SmartKlamp differs from the Ali's Klamp only in one significant respect: The clamping ring is not angled to match the typical slant of the coronal rim of the glans. In theory this achieves less satisfactory capture of inner foreskin ventrally, but the original manufacturer claimed it is possible to adjust the foreskin to compensate. The SmartKlamp apparently shares with the Ali's Klamp one notable design weakness. An unwilling or meddlesome patient could, in theory, open the clamp by placing a flat object such as a table knife between the tube and the locking arms and then twisting. Additionally, such action would render the

device liable to unscrupulous reuse several times over, until such time as the nominally single-use latching mechanism wore out.

A training video is available for purchase from the current supplier's website.

10.7 Sunathrone

Inventor: Surat, T.b.
Primary patent: (Application:) MY2006/000281
Patent priority date: 23 Jan 2006
Patient age range: Full-term neonate to adult
Website: <http://www.sunathrone.com/>
Category: Ischaemic necrosis device

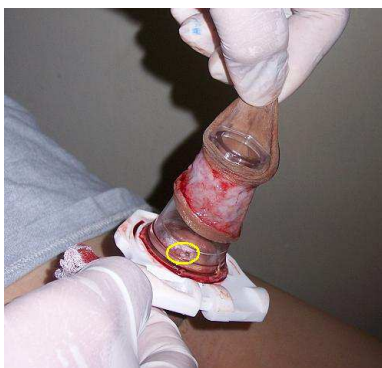

Fig. 15. The Sunathrone device.

Procedure: The Sunathrone clamp differs markedly from the other ischaemic necrosis devices considered here, in that the crushing action is achieved by means of a wrap-around "cuff" rather than concentric rings. Nominally this introduces a problem of pressure discontinuity at the hinge and latch, but Dr. Tasron bin Surat's design overcomes that by means of springy cuff extensions that bridge these gaps.

In order to achieve sufficient pressure between the cuff and the tube, a special tool called a "Sunalever" is required to close the Sunathrone clamp. This is a large item, sized according to the device being applied to the patient. It can be seen in use on the web page <http://www.circlist.com/instrstechs/sunathrone.html>. In the absence of on-site sterilization facilities, one Sunalever would have to be packaged with each clamp. This has implications in terms of cost, package size and waste disposal.

Two points in favour of this design are that the latching mechanism is highly tamper-resistant and, once the bayonet joint of the tube (ringed in yellow in the image above) is unplugged, nothing protrudes beyond the tip of the glans. The manufacturers claim suitability for use in cases of buried penis, the relatively large diameter of the cuff preventing the glans from withdrawing into the abdomen and forming adhesions during the healing period.

10.8 Tara KLamp

Inventor: Singh, G.S.T.
Primary patent: US5649933
Patent priority date: 20 Apr 1992
Patient age range: Full-term neonate to adult

Website: Tara Medic does not have its own website. See instead:
<http://www.circlist.com/instrstechs/taraklamp.html>
Category: Ischaemic necrosis device

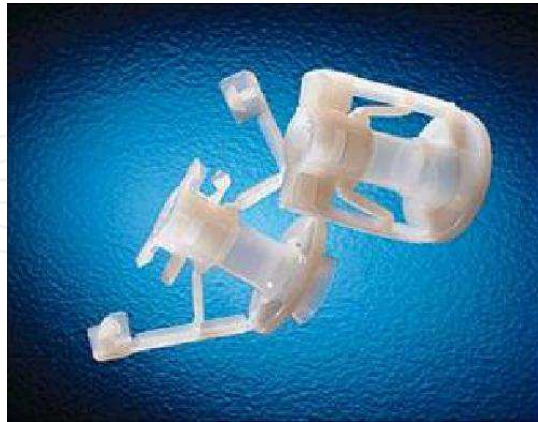

Fig. 16. The Tara KLamp.

Procedure: The Tara KLamp is the original single-use “clip-&-wear” ischaemic necrosis device to have gone into commercial production. Procedure for use is substantially the same as for the Ali's Klamp, Ismail Klamp and SmartKlamp. Since its invention nearly 20 years ago by Gurchran Singh Tara Singh, the Tara KLamp has undergone a number of design changes the most notable of which relates to its size, which has reduced considerably, thus making the current version more convenient to wear than the original.

The latching mechanism of the Tara KLamp is especially secure, making this design suitable for use on unwilling, meddlesome or autistic boys.

Considerable criticism of the Tara KLamp has arisen in consequence of a paper published by Lagarde and associates (Lagarde *et al.*, 2009). The authors of the present chapter are in possession of documentary evidence apparently proving that Lagarde's team did not attend Tara Medic's training course relating to use of the Tara KLamp. Furthermore, these documents also appear to show that Lagarde's team departed from the procedure set down in the package insert. If true, we suggest the resulting criticism of the Tara KLamp to be unfair and possibly unwarranted. Unpublished studies by the Health Department of KwaZulu-Natal apparently failed to replicate the problems and the Tara KLamp has now been accepted as the “preferred device” for use in Kwa-Zulu Natal.

We suggest that, at the very least, Lagarde's findings should be set aside pending further investigation. Safety and efficacy trials of the Tara KLamp should be repeated by a different team. Such a trial might usefully address one further issue: Whether or not the Tara KLamp can be successfully used without the foreskin being severed, instead leaving it to necrotise *in situ* as is done with the PrePex device.

11. World Health Organisation's preference?

Early in 2011 the World Health Organisation formed a Technical Advisory Group (TAG) with a remit to look at evidence and make recommendations to WHO regarding choice of circumcision clamp, but to date the TAG has not published any recommendations (Personal correspondence between co-author C. Eley and the co-Chairman on 21 Feb 2011). It is to be hoped that, when they do, it will be a shortlist for local consideration rather than a

recommendation favouring one particular device globally. It is the considered opinion of the present authors that it would be inappropriate for there to be a single winner in this contest. The best clamp in any given situation is likely to be a function of local factors.

12. Conclusions

MC can be performed at any age, but infancy is the ideal time for reasons of safety, procedural simplicity, convenience, minimal risk and cost (Wiswell & Geschke, 1989; Wiswell & Hachey, 1993; Wiswell, 1995; Wiswell, 1997; Wiswell, 2000). The benefits in respect of UTIs and penile cancer are, moreover, maximized if circumcision takes place in infancy. Circumcising prior to onset of sexual activity rather than later also means a completely healed penis, so that risk of infection, such as by HIV, during the healing period is reduced.

Thus the present campaigns to circumcise adults should be seen as a mere catching-up exercise, making good past omissions to circumcise pre-puberty. The ultimate aim should be to make infant MC a global norm, the health rewards being too great to overlook (Morris, 2007; World Health Organisation, 2007a,b; Tobian *et al.*, 2009; Cooper *et al.*, 2010).

MC has no long-term adverse consequences (Morris, 2007; Smith *et al.*, 2010; Tobian *et al.*, 2010). Good quality research studies that include thermal imaging show similar sensation during arousal for the circumcised and uncircumcised penis (Payne *et al.*, 2007). The lack of any diminution in sexual function, satisfaction or sensation is now backed up by evidence from large RCTs (Bailey *et al.*, 2007; Krieger *et al.*, 2008). In fact 64% of the men in one of the trials reported an increase in their penile sensitivity and 54% reported greater ease in reaching orgasm (Krieger *et al.*, 2008). This did not mean an increase in premature ejaculation. The fact that circumcision does not impair, and for many may enhance, a man's sensation and sexual pleasure, should reassure men considering whether to get circumcised (Sharlip, 2008). MC is preferred by most women for reasons of hygiene, sexual activity, reduced STI risk, and greater enjoyment of intercourse (Williamson & Williamson, 1988; Badger, 1989a,b; Moses *et al.*, 1998; Nnko *et al.*, 2001; Kigozi *et al.*, 2009a).

Biomedical engineering clearly has its place in delivering MC, despite the existence of methods and traditions that are many thousands of years old. Recent progress in instrumentation design has resulted in devices that have begun to address the need for circumcisions that are quick, safe and convenient, and that can be used in "field" settings. Such advances in biomedical engineering are essential in ensuring a safe and practical way of dealing with the numbers of males of all ages in the modern world who need to be circumcised.

13. References

- Alanis, M.C. & Lucidi, R.S. (2004). Neonatal circumcision: A review of the world's oldest and most controversial operation. *Obstet Gynecol Surv* 59, 379-395.
- Aldemir, M., Cakan, M. & Burgu, B. (2008). Circumcision with a new disposable clamp: Is it really easier and more reliable? *Int Urol Nephrol* 40, 377-381.
- Auvert, B., Taljaard, D., Lagarde, E., Sobngwi-Tambekou, J., Sitta, R. & Puren, A. (2005). Randomized, controlled intervention trial of male Circumcision for reduction of HIV infection risk: The ANRS 1265 Trial. *PLoS Med* 2 (e298), 1112-1122.
- Badger, J. (1989a). The great circumcision report part 2. *Australian Forum* 2 (12), 4-13.

- Badger, J. (1989b). Circumcision. What you think. *Australian Forum* 2 (11), 10-29.
- Baeten, J.M., Donnell, D., Inambo, M., John-Stewart, G., Kapiga, S., Manongi, R., Ronald, A., Vwakila, B. & Celum, C. (2009). Male circumcision and risk of male-to-female HIV-1 transmission: A multinational prospective study. *5th International AIDS Society Conference, Cape Town, South Africa*, LBPEC06.
- Baeten, J.M., Donnell, D., Kapiga, S.H., Ronald, A., John-Stewart, G., Inambao, M., Manongi, R., Vwalika, B. & Celum, C. (2010). Male circumcision and risk of male-to-female HIV-1 transmission: a multinational prospective study in African HIV-1-serodiscordant couples. *AIDS* 24, 737-744.
- Bailey, R.C., Moses, S., Parker, C.B., Agot, K., Maclean, I., Krieger, J.N., Williams, C.F., Campbell, R.T. & Ndinya-Achola, J.O. (2007). Male circumcision for HIV prevention in young men in Kisumu, Kenya: a randomised controlled trial. *Lancet* 369, 643-656.
- Bailey, R.C., Moses, S., Parker, C.B., Agot, K., Maclean, I., Krieger, J.N., Williams, C.F. & Ndinya-Achola, J.O. (2008). The protective effect of male circumcision is sustained for at least 42 months: results from the Kisumu, Kenya Trial. *XVII International AIDS Conference, 2008*, THAC05.
- Bailey, R.C. & Mehta, S.D. (2009). Circumcision's place in the vicious cycle involving herpes simplex virus type 2 and HIV. *J Infect Dis* 199, 923-925.
- Bailey, R.C., S. Moses, S., C.B. Parker, C.B., Agot, K., MacLean, I., Krieger, J.N., Williams, C.F.M. & Ndinya-Achola, J.O. (2010). The protective effect of adult male circumcision against HIV acquisition is sustained for at least 54 months: results from the Kisumu, Kenya trial. *XVIII International AIDS Confernece, Jul 18-23, 2010, Vienna*, Abstract#FRLBC1.
- Balkan, C., Karapinar, D., Aydogdu, S., Ozcan, C., Ay, Y., Akin, M. & Kavakli, K. (2010). Surgery in patients with haemophilia and high responding inhibitors: Izmir experience. *Haemophilia* 16, 902-909.
- Barone, M.A., Ndede, F., Li, P.S., Masson, P., Awori, Q., Okech, J., Cherutich, P., Muraguri, N., Perchal, P., Lee, R., Kim, H.H. & Goldstein, M. (2011). The Shang Ring device for adult male circumcision: A proof of concept study in Kenya. *J Acquir Immune Defic Syndr.*, Feb 21 [Epub ahead of print].
- Ben Chaim, J., Livne, P.M., Binyamini, J., Hardak, B., Ben-Meir, D. & Mor, Y. (2005). Complications of circumcision in Israel: a one year multicenter survey. *Isr Med Assoc J* 7, 368-370.
- Ben, K.L., Xu, J.C., Lu, L., Lü, N.Q., Cheng, Y., Tao, J., Liu, D.K., Min, X.D., Cao, X.M. & Li, P.S. (2009). [Male circumcision is an effective "surgical vaccine" for HIV prevention and reproductive health](in Chinese). *Zhonghua Nan Ke Xue* 15, 395-402.
- Bode, C.O., Ikhisemojie, S. & Ademuyiwa, A.O. (2010). Penile injuries from proximal migration of the plastibell circumcision ring. *J Pediatr Urol* 6, 23-27
- Boggiano, C. & Littman, D.R. (2007). HIV's vagina travelogue. *Immunity* 26, 145-147.
- Bronstein, H. (1955). United States Patent US2747576 (Mogen clamp). (Priority date Feb 3,1955).
- Caballero-Hoyos, R. & Villasenor-Sierra, A. (2001). [Socioeconomic strata as a predictor factor for constant condom use among adolescents] (Spanish). *Rev Saude Publica* 35, 531-538.

- Cameron, B.E., Simonsen, J.N., D'Costa, L.J., Ronald, A.R., Maitha, G.M., Gakinya, M.N., Cheang, M., Dinya-Achola, J.O., Piot, P., Brunham, R.C. & Plummer, F.A. (1989). Female to male transmission of human immunodeficiency virus type 1: risk factors for seroconversion in men. *Lancet* ii, 403-407.
- Cathcart, P., Nuttall, M., van der Meulen, J., Emberton, M. & Kenny, S.E. (2006). Trends in paediatric circumcision and its complications in England between 1997 and 2003. *Br J Surg* 93, 885-890.
- Chekmarev, V.M. (1989). Union of Soviet Socialist Republics Patent SU1683702 (Laser Shield; Uzbek). (Priority date Jul 19,1989).
- Cheng, D., Hurt, L. & Horon, I.L. (2008). Neonatal circumcision in Maryland: a comparison of hospital discharge and maternal postpartum survey data. *J Pediatr Urol* 4, 448-451.
- Cheng, W. & Saing, H. (1997). A prospective randomized study of wound approximation with tissue glue in circumcision in children. *J Paediatr Child Health* 33, 515-516.
- Cheng, Y., Peng, Y.F., Liu, Y.D., Tian, L., Lü, N.Q., Su, X.J., Yan, Z.J., Hu, J.S., Lee, R., Kim, H.H., Sokal, D.C. & Li, P.S. (2009). [A recommendable standard protocol of adult male circumcision with the Chinese Shang Ring: outcomes of 328 cases in China] [Article in Chinese]. *Zhonghua Nan Ke Xue* 15, 584-592.
- Christakis, D.A., Harvey, E., Zerr, D.M., Feudtner, C., Wright, J.A. & Connell, F.A. (2000). A trade-off analysis of routine newborn circumcision. *Pediatrics* 105, 246-249.
- Cilento, B.G.J., Holmes, N.M. & Canning, D.A. (1999). Plastibell complications revisited. *Clin Pediatr* 38, 239-242.
- Coates, T.J., Richter, L. & Caceres, C. (2008). Behavioural strategies to reduce HIV transmission: how to make them work better. *Lancet* 372, 669-684.
- Cohen, B. (2002). United States Patent US7080984 (Circumcision training aid). (Priority date Apr 29, 2002).
- Cooper, D.A., Wodak, A.D. & Morris, B.J. (2010). The case for boosting infant male circumcision in the face of rising heterosexual transmission of HIV. *Med J Aust* 193, 318-319.
- D'Arcy, F.T. & Jaffry, S.Q. (2011). A review of 100 consecutive sutureless child and adult circumcisions. *Ir J Med Sci* 180, 51-53.
- de Witte, L., Nabatov, A., Pion, M., Fluitsma, D., de Jong, M.A., de Gruijl, T., Piguet, V., van Kooyk, Y. & Geijtenbeek, T.B. (2007). Langerin is a natural barrier to HIV-1 transmission by Langerhans cells. *Nat Med* 13, 367-371.
- Decastro, B., Gurski, J. & Peterson, A. (2010). Adult template circumcision: a prospective, randomized, patient-blinded, comparative study evaluating the safety and efficacy of a novel circumcision device. *Urology* 76, 810-814.
- Donovan, B. & Ross, M.W. (2000). Preventing HIV: determinants of sexual behaviour (review). *Lancet* 355, 1897-1901.
- Duncan, N.D., Dundas, S.E., Brown, B., Pinnock-Ramsaran, C. & Badal, G. (2004). Newborn circumcision using the Plastibell device: an audit of practice. *West Indian Med J* 53, 23-26.
- Elder, J.S. (2007). Surgery illustrated: circumcision. *BJU Int* 99, 1553-1564.
- Elemen, L., Seyidov, T.H. & Tugay, M. (2010). The advantages of cyanoacrylate wound closure in circumcision. *Pediatr Surg Int*, Oct 13 [Epub ahead of print].

- Elmore, J.M., Smith, E.A. & Kirsch, A.J. (2007). Sutureless circumcision using 2-octyl cyanoacrylate (Dermabond): appraisal after 18-month experience. *Urology* 70, 803-806.
- Erikson, S.S. (1999). A model for teaching newborn circumcision. *Obstet Gynecol* 93, 783-784.
- Fahrbach, K.M., Barry, S.M., Anderson, M.R. & Hope, T.J. (2010). Enhanced cellular responses and environmental sampling within inner foreskin explants: implications for the foreskin's role in HIV transmission. *Mucosal Immunol* 3, 410-418.
- Fergusson, D.M., Boden, J.M. & Horwood, L.J. (2008). Neonatal circumcision: Effects on breastfeeding and outcomes associated with breastfeeding. *J Paediatr Child Health* 44, 44-49.
- Ferrante, P., Delbue, S. & Mancuso, R. (2005). The manifestation of AIDS in Africa: an epidemiological overview. *J Neurovirol* 11 (suppl 1), 50-57.
- Fette, A., Schleaf, J., Haberlik, A. & Seebacher, U. (2000). Circumcision in paediatric surgery using an ultrasound dissection scalpel. *Technol Hlth Care* 8, 75-79.
- Fiore, A.E., David K. Shay, D.K., Penina Haber, P., Iskander, J.K., Uyeki, T.M., Mootrey, G., Bresee, J.S. & Cox, N.J. (2007). Prevention and Control of Influenza. Recommendations of the Advisory Committee on Immunization Practices (ACIP), 2007. *Centers for Disease Control and Prevention - Mortality and Morbidity Weekly Report* 56, 1-54.
- Freeman, E.E., Weiss, H.A., Glynn, J.R., Cross, P.L., Whitworth, J.A. & Hayes, R.J. (2006). Herpes simplex virus 2 infection increases HIV acquisition in men and women: systematic review and meta-analysis of longitudinal studies. *AIDS* 20, 73-83.
- Fuerst, O., Kilemnick & Shohat, S. (2010). Israel Patent Application IL2010/000568 (PrePex). (Priority date Jul 16, 2009).
- Ganor, Y., Zhou, Z., Tudor, D., Schmitt, A., Vacher-Lavenu, M.C., Gibault, L., Thiounn, N., Tomasini, J., Wolf, J.P. & Bomsel, M. (2010). Within 1 h, HIV-1 uses viral synapses to enter efficiently the inner, but not outer, foreskin mucosa and engages Langerhans-T cell conjugates. *Mucosal Immunol* 3, 506-522.
- Ganor, Y. & Bomsel, M. (2011). HIV-1 transmission in the male genital tract. *Am J Reprod Immunol*, 65, 284-291.
- Gao, X. & Ni, J. (1999). People's Republic of China Patent CN2351094 (Gao's Laser Shield). (Priority date Jan 16, 1999).
- Gebremedhin, S. (2010). Assessment of the protective effect of male circumcision from HIV infection and sexually transmitted diseases: evidence from 18 demographic and health surveys in sub-Saharan Africa. *Afr J Reprod Health* 14, 105-113.
- Gee, W.F. & Ansell, J.S. (1976). Neonatal circumcision: A ten-year overview, with comparison of the Gomco clamp and the Plastibell device. *Pediatrics* 58, 824-827.
- Gnassingbé, K., Akakpo-Numado, K.G., Anoukoum, T., Songne, B., Lamboni, D., Kokoroko, E.K. & Tékou, H.A. (2010). [The circumcision in newborn and infant in the operating room of the Lomé Teaching Hospital: technique using Gomco clamp versus technique using only the grips]. (Article in French). *Prog Urol* 20, 532-537.
- Goldstein, A.A. (1939). United States Design Patent USD119180 (Gomco Clamp). (Priority date Mar 16, 1939).
- Goubet, N., Rattaz, C., Pierrat, V., Bullinger, A. & Lequien, P. (2003). Olfactory experience mediates response to pain in preterm newborns. *Dev Psychobiol* 42, 171-180.

- Goubet, N., Strasbaugh, K. & Chesney, J. (2007). Familiarity breeds content? Soothing effect of a familiar odor on full-term newborns. *J Dev Behav Pediatr* 28, 189-194.
- Gray, R.H., Kigozi, G., Serwadda, D., Makumbi, F., Watya, S., Nalugoda, F., Kiwanuka, N., Moulton, L.H., Chaudhary, M.A., Chen, M.Z., Sewankambo, N.K., Wabwire-Mangen, F., Bacon, M.C., Williams, C.F., Opendi, P., Reynolds, S.J., Laeyendecker, O., Quinn, T.C. & Wawer, M.J. (2007). Male circumcision for HIV prevention in men in Rakai, Uganda: a randomised trial. *Lancet* 369, 657-666.
- Gray, R.H., Wawer, M.J., Kigozi, G. & Serwadda, D. (2008). Commentary: Disease modelling to inform policy on male circumcision for HIV prevention. *Int J Epidemiol* 37, 1253-1254.
- Haghpanah, S., Vafafar, A., Golzadeh, M.H., Ardeshtiri, R. & Karimi, M. (2011). Use of Glubran 2 and Glubran tissue skin adhesive in patients with hereditary bleeding disorders undergoing circumcision and dental extraction. *Ann Hematol* 90, 463-468.
- Hallett, T.B., Alsallaq, R.A., Baeten, J.M., Weiss, H., Celum, C., Gray, R. & Abu-Raddad, L. (2011). Will circumcision provide even more protection from HIV to women and men? New estimates of the population impact of circumcision interventions. *Sex Transm Infect*, 2010 87, 88-93
- Halperin, D.T., Steiner, M.J., Cassell, M.M., Green, E.C., Hearst, N., Kirby, D., Gayle, H.D. & Cates, W. (2004). The time has come for common ground on preventing sexual transmission of HIV. *Lancet* 364, 1913-1915.
- Herschel, M., Khoshnood, B., Ellman, C., Maydew, N. & Mittendorf, R. (1998). Neonatal circumcision. Randomized trial of a sucrose pacifier for pain control. *Arch Pediatr Adolesc Med* 152, 279-284.
- Hirbod, T., Bailey, R.C., Agot, K., Moses, S., Ndinya-Achola, J., Murugu, R., Andersson, J., Nilsson, J. & Broliden, K. (2010). Abundant expression of HIV target cells and C-type lectin receptors in the foreskin tissue of young Kenyan men. *Am J Pathol* 176, 2798-2805.
- Hladik, F., Sakchalathorn, P., Ballweber, L., Lentz, G., Fialkow, M., Eschenbach, D. & McElrath, M.J. (2007). Initial events in establishing vaginal entry and infection by human immunodeficiency virus type-1. *Immunity* 26, 257-270.
- Holman, J.R., Lewis, E.L. & Ringler, R.L. (1995). Neonatal circumcision techniques. *Am Fam Physician* 52, 511-520.
- Howard, C., Howard, F., Garfunkel, L., de, B. & Weitzman, M. (1998). Neonatal circumcision and pain relief: Current training practices. *Pediatrics* 101, 423-8.
- Howard, C.R., Howard, F.M., Fortune, K., Generalli, P., Zolnoun, D., ten Hoopen, C. & de Blieck, E. (1999). A randomized, controlled trial of a eutectic mixture of local anesthetic cream (lidocaine and prilocaine) versus penile nerve block for pain relief during circircumcision. *Am J Obstet Gynecol* 181, 1506-1511.
- Jadack, R.A., Yuenger, J., Ghanem, K.G. & Zenilman, J. (2006). Polymerase chain reaction detection of Y-chromosome sequences in vaginal fluid of women accessing a sexually transmitted disease clinic. *Sex Transm Dis* 33, 22-25.
- Johnson, K.E., Sherman, M.E., Ssempijja, V., Tobian, A.A., Zenilman, J.M., Duggan, M.A., Kigozi, G., Serwadda, D., Wawer, M.J., Quinn, T.C., Rabkin, C.S. & Gray, R.H. (2009). Foreskin inflammation is associated with HIV and herpes simplex virus type-2 infections in Rakai, Uganda. *AIDS* 23, 1807-1815.
- Kamra, S. (2002). *Bearing Witness*. Calgary, University of Calgary Press.

- Kang, M., Rochford, A., Johnston, V., Jackson, J., Freedman, E., Brown, K. & Mindel, A. (2006). Prevalence of Chlamydia trachomatis infection among 'high risk' young people in New South Wales. *Sex Health* 3, 253-254.
- Karaman, M.I., Zulfikar, B., Caskurlu, T. & Ergenekon, E. (2004). Circumcision in hemophilia: a cost-effective method using a novel device. *J Pediatr Surg* 39, 1562-1564.
- Kariher, D.H. & Smith, T.W. (1955). United States Patent US3056407 (Plastibell). (Priority date May 18, 1955).
- Kaufman, G.E., Cimo, S., Miller, L.W. & Blass, E.M. (2002). An evaluation of the effects of sucrose on neonatal pain with 2 commonly used circumcision methods. *Am J Obstet Gynecol* 186, 564-568.
- Kazem, M.M., Mehdi, A.Z., Golrasteh, K.Z. & Behzad, F.Z. (2010). Comparative evaluation of two techniques of hemostasis in neonatal circumcision using plastibell device. *J Pediatr Urol*, 6, 258-260
- Kelly, H., Carville, K., Grant, K., Jacoby, P., Tran, T. & Barr, I. (2009). Estimation of influenza vaccine effectiveness from routine surveillance data. *PLoS One* 4 (7 pages), e5079.
- Kigozi, G., Lukabwe, I., Kagaayi, J., Wawer, M.J., Nantume, B., Kigozi, G., Nalugoda, F., Kiwanuka, N., Wabwire-Mangen, F., Serwadda, D., Ridzon, R., Buwembo, D., Nabukenya, D., Watya, S., Lutalo, T., Nkale, J. & Gray, R.H. (2009a). Sexual satisfaction of women partners of circumcised men in a randomized trial of male circumcision in Rakai, Uganda. *BJU Int* 104, 1698-1701.
- Kigozi, G., Wawer, M., Ssettuba, A., Kagaayi, J., Nalugoda, F., Watya, S., Mangen, F.W., Kiwanuka, N., Bacon, M.C., Lutalo, T., Serwadda, D. & Gray, R.H. (2009b). Foreskin surface area and HIV acquisition in Rakai, Uganda (size matters). *AIDS* 23, 2209-2213.
- Kigozi, G., Nkale, J., Wawer, M., Anyokorit, M., Watya, S., Nalugoda, F., Kagaayi, J., Kiwanuka, N., Mwinike, J., Kighoma, N., Nalwoga, G.K., Nakigozi, G.F., Katwalo, H., Serwadda, D. & Gray, R.H. (2011). Designing and usage of a low-cost penile model for male medical circumcision skills training in Rakai, Uganda. *Urology*, Feb 4 [Epub ahead of print].
- Kong, X., Kigozi, G., Ssempija, V., Serwadda, D., Nalugoda, F., Makumbi, F., 2, T Lutalo, T., , Watya, S., Wawer, M. & R Gray, R. (2011). Longer-term effects of male circumcision on HIV incidence and risk behaviors during post-trial surveillance in Rakai, Uganda. *18th Conference on Retroviruses and Opportunistic Infections, Boston, Feb 27-Mar 2, 2011*, Abstract#36.
- Krieger, J.N., Bailey, R.C., Opeya, J.C., Ayieko, B.O., Opiyo, F.A., Omondi, D., Agot, K., Parker, C., Ndinya-Achola, J.O. & Moses, S. (2007). Adult male circumcision outcomes: experience in a developing country setting. *Urol Int* 78, 235-240.
- Krieger, J.N., Mehta, S.D., Bailey, R.C., Agot, K., Ndinya-Achola, J.O., Parker, C. & Moses, S. (2008). Adult male circumcision: Effects on sexual function and sexual satisfaction in Kisumu, Kenya. *J Sex Med* 5, 2610-2622.
- Kunin, S.A. (2007a). Improved newborn circumcision utilizing dorsal foreskin local anesthesia (DFLA) with Gomco clamp. *Western Section Urological meeting Oct 28-Nov 1, Scottsdale, Arizona*, http://www.samkuninmd.com/docinfo/Improved_GOMCO_Circumcision_abstract.pdf.

- Kunin, S.A. (2007b). Dorsal foreskin local anesthesia (DFLA), a new rapid and safe method for infant circumcision anesthesia. *Western Section Urological meeting Oct 28-Nov 1, Scottsdale, Arizona*, http://www.samkuninmd.com/docinfo/Dorsal_Foreskin_Local_Anesthesia.pdf.
- Kurtis, P.S., DeSilva, H.N., Bernstein, B.A., Malakh, L. & Schrechter, N.L. (1999). A comparison of the Mogen and Gomco clamps in combination with dorsal penile nerve block in minimizing the pain of neonatal circumcision. *Pediatrics* 103, E23.
- Lagarde, E., Taljaard, D., Puren, A. & Auvert, B. (2009). High rate of adverse events following circumcision of young male adults with the Tara KLamp technique: a randomised trial in South Africa. *S Afr Med J* 99, 163-169.
- Lane, V., Vajda, P. & Subramaniam, R. (2010). Paediatric sutureless circumcision: a systematic literature review. *Pediatr Surg Int* 26, 141-144.
- Langer, J.C. & Coplen, D.E. (1998). Circumcision and pediatric disorders of the penis. *Pediatr Clin N Am* 45, 801-812.
- Leibowitz, A.A., Desmond, K. & Belin, T. (2009). Determinants and policy implications of male circumcision in the United States. *Am J Public Health* 99, 138-145.
- Li, H.N., Xu, J. & Qu, L.M. (2010). [Shang Ring circumcision versus conventional surgical procedures: comparison of clinical effectiveness]. (Article in Chinese). *Zhonghua Nan Ke Xue* 16, 325-327.
- Lopman, B., Nyamukapa, C., Mushati, P., Mupambireyi, Z., Mason, P., Garnett, G.P. & Gregson, S. (2008). HIV incidence in 3 years of follow-up of a Zimbabwe cohort--1998-2000 to 2001-03: contributions of proximate and underlying determinants to transmission. *Int J Epidemiol* 37, 88-105.
- Mahomed, A., Zaparackaite, I. & Adam, S. (2009). Improving outcome from Plastibell circumcisions in infants. *Int Braz J Urol* 35, 310-313.
- Masson, P., Li, P.S., Barone, M.A. & Goldstein, M. (2010). The ShangRing device for simplified adult circumcision. *Nat Rev Urol* 7, 638-642.
- McCoombe, S.G. & Short, R.V. (2006). Potential HIV-1 target cells in the human penis. *AIDS* 20, 1491-1495.
- Mehta, S.D., Krieger, J.N., Agot, K., Moses, S., Ndinya-Achola, J.O., Parker, C. & Bailey, R.C. (2010). Circumcision and reduced risk of self-reported penile coital injuries: Results from a randomized controlled trial in Kisumu, Kenya. *J Urol* 184, 203-209.
- Meijer, J.M. (2008). New electrostatic sanitation method could have medical device sterilization uses, from <http://jmmeijer.wordpress.com/2008/12/17/electrostatic-sterilization-method/>.
- Méndez-Gallart, R., Estévez, E., Bautista, A., Rodríguez, P., Taboada, P., Armas, A.L., Pradillos, J.M. & Varela, R. (2009). Bipolar scissors circumcision is a safe, fast, and bloodless procedure in children. *J Pediatr Surg* 44, 2048-2053.
- Morris, B.J., Castellsague, X. & Bailis, S.A. (2006). Re: Cost analysis of neonatal circumcision in a large health maintenance organization. E. J. Schoen, C. J. Colby and T. T. To. *J Urol*, 175: 1111-1115, 2006. *J Urol* 176, 2315-2316.
- Morris, B.J. (2007). Why circumcision is a biomedical imperative for the 21st century. *BioEssays* 29, 1147-1158.
- Morris, B.J., Bailis, S.A., Waskett, J.H., Wiswell, T.E. & Halperin, D.T. (2009). Medicaid coverage of newborn circumcision: a health parity right of the poor. *Am J Public Health* 99, 969-971.


- Morris, B.J. (2010). Circumcision: an evidence-based appraisal - medical, health and sexual. [Review]. <http://www.circinfo.net> (over 1,000 references).
- Morris, B.J. & Castellsague, X. (2011). The role of circumcision in the prevention of sexually transmitted infections. *Sexually Transmitted Diseases*. Gross, G.E. & Tyring, S. Heidelberg, Springer: 715-739
- Morris, B.J., Gray, R.H., Castellsague, X., Bosch, F.X., Halperin, D.T., Waskett, J.H. & Hankins, C.A. (2011). The strong protection afforded by circumcision against cancer of the penis. (Invited Review). *Adv Urol*, (21 pages): in press.
- Moses, S., Bailey, R.C. & Ronald, A.R. (1998). Male circumcision: assessment of health benefits and risks. *Sex Transm Inf* 74, 368-373.
- Mousa, G.S. (2007). *Surgery training video "Circumcision: Dissection Method" made for the Faculty of Medicine, Tanta University, Egypt, Jan 16, 2007.*
- Munro, H.L., Pradeep, B.S., Jayachandran, A.A., Lowndes, C.M., Mahapatra, B., Ramesh, B.M., Washington, R., Jagannathan, L., Mendonca, K., Moses, S., Blanchard, J.F. & Alary, M. (2008). Prevalence and determinants of HIV and sexually transmitted infections in a general population-based sample in Mysore district, Karnataka state, southern India. *AIDS* 22 (suppl 5), S117-S125.
- Naimer, S.A. & Trattner, A. (2000). Are sterile conditions essential for all forms of cutaneous surgery? The case of ritual neonatal circumcision. *J Cutan Med Surg* 4, 177-180.
- Newbold, R.R., Padilla-Banks, E. & Jefferson, W.N. (2006). Adverse effects of the model environmental estrogen diethylstilbestrol are transmitted to subsequent generations. *Endocrinology* 147 (Suppl), S11-S17.
- Nnko, S., Washija, R., Urassa, M. & Boerma, J.T. (2001). Dynamics of male circumcision practices in Northwest Tanzania. *Sex Transm Dis* 28, 214-218.
- O'Farrell, N., Quigley, M. & Fox, P. (2005). Association between the intact foreskin and inferior standards of male genital hygiene behaviour: a cross-sectional study. *Int J STD AIDS* 16, 556-559.
- O'Farrell, N., Morison, L., Moodley, P., Pillay, K., Vanmali, T., Quigley, M., Hayes, R. & Sturm, A.W. (2006). Association between HIV and subpreputial penile wetness in uncircumcised men in South Africa. *J Acquir Immune Defic Syndr* 43, 69-77.
- Ozkan, K.U., Gonen, M., Sahinkanat, T., Resim, S. & Celik, M. (2005). Wound approximation with tissue glue in circumcision. *Int J Urol* 12, 374-377.
- Patterson, B.K., Landy, A., Siegel, J.N., Flener, Z., Pessis, D., Chaviano, A. & Bailey, R.C. (2002). Susceptibility to human immunodeficiency virus-1 infection of human foreskin and cervical tissue grown in explant culture. *Am J Pathol* 161, 867-873.
- Payne, K., Thaler, L., Kukkonen, T., Carrier, S. & Binik, Y. (2007). Sensation and sexual arousal in circumcised and uncircumcised men. *J Sex Med* 4, 667-674.
- Peng, Y., Masson, P., Li, P.S., Chang, Y., Tian, L., Lee, R., Kim, H., Sokal, D.C. & Goldstein, M. (2010a). No-needle local anesthesia for adult male circumcision. *J Urol* 184, 978-983.
- Peng, Y.F., Cheng, Y., Wang, G.Y., Wang, S.Q., Jia, C., Yang, B.H., Zhu, R., Jian, S.C., Li, Q.W. & Geng, D.W. (2008). Clinical application of a new device for minimally invasive circumcision. *Asian J Androl* 10, 447-454.
- Peng, Y.F., Yang, B.H., Jia, C. & Jiang, J. (2010b). [Standardized male circumcision with Shang Ring reduces postoperative complications: a report of 351 cases]. (Article in Chinese). *Zhonghua Nan Ke Xue* 16, 963-966.

- Peters, K.M. & Kass, E.J. (1997). Electrosurgery for routine pediatric penile procedures. *J Urol* 157, 1453-1455.
- Peterson, A.C., Joyner, B.D. & Allen, R.C., Jr. (2001). Plastibell template circumcision: a new technique. *Urology* 58, 603-604.
- Ponsky, L.E., Ross, J.H., Knipper, N. & Kay, R. (2000). Penile adhesions after neonatal circumcision. *J Urol* 164, 495-496.
- Rattaz, C., Goubet, N. & Bullinger, A. (2005). The calming effect of a familiar odor on full-term newborns. *J Dev Behav Pediatr* 26, 86-92.
- Richters, J., Smith, A.M., de Visser, R.O., Grulich, A.E. & Rissel, C.E. (2006). Circumcision in Australia: prevalence and effects on sexual health. *Int J STD AIDS* 17, 547-554.
- Ross, C.J. (1939). United States Patent US2272072 (Ross Ring). (Priority date May 22, 1939).
- Russell, C.T. & Chaseling, J. (1996). Topical anaesthesia in neonatal circumcision: a study of 208 consecutive cases. *Aust Fam Physician* 25 (suppl 1), 30-34.
- Sahasrabuddhe, V.V. & Vermund, S.H. (2007). The future of HIV prevention: control of sexually transmitted infections and circumcision interventions. *Infect Dis Clin North Am* 21, 241-257.
- Samad, A., Khanzada, T.W. & Kumar, B. (2010). Plastibell circumcision: A minor surgical procedure of major importance. *J Pediatr Urol* 6, 28-31
- Sanchez, T., Finlayson, T., Drake, A., Behel, S., Cribbin, M., Dinunno, E., Hall, T., Kramer, S. & Lansky, A. (2006). Human immunodeficiency virus (HIV) risk, prevention, and testing behaviors--United States, National HIV Behavioral Surveillance System: men who have sex with men, November 2003-April 2005. *MMWR Surveill Summ* 55, 1-16.
- Sansom, S.L., Prabhu, V.S., Hutchinson, A.B., An, Q., Hall, H.I., Shrestha, R.K., Lasry, A. & Taylor, A.W. (2010). Cost-effectiveness of newborn circumcision in reducing lifetime HIV risk among U.S. males. *PLoS One* 5, e8723.
- Schoen, E.J. (2005). Circumcision for preventing urinary tract infections in boys: North American view. *Arch Dis Child* 90, 772-773.
- Schoen, E.J., Colby, C.J. & To, T.T. (2006). Cost analysis of neonatal circumcision in a large health maintenance organization. *J Urol* 175, 1111-1115.
- Schoen, E.J. (2007a). Male circumcision. *Male Sexual Dysfunction. Pathophysiology and Treatment*. Kandeel, F.R.Lue, T.F.Pryor, J.L. & Swerdloff, R.S. New York, Informa: 95-107.
- Schoen, E.J. (2007b). Circumcision as a lifetime vaccination with many benefits. *J Men's Hlth Gender* 382, 306-311.
- Schwartz, O. (2007). Langerhans cells lap up HIV-1. *Nat Med* 13, 245-246.
- Senel, F.M., Demirelli, M. & Oztek, S. (2010). Minimally invasive circumcision with a novel plastic clamp technique: a review of 7,500 cases. *Pediatr Surg Int*, 739-745.
- Senel, F.M., Demirelli, M. & Pekcan, H. (2011). Mass circumcision with a novel plastic clamp technique. *Urology*, Feb 8 [Epub ahead of print].
- Sewefy, A.M.H. (2004). Egyptian Patent EG2004/000050 (Haemophilic Circumcisor). (Priority date Apr 18, 2004).
- Sharlip, I. (2008). Circumcision and the risk of HIV transmission in Africa. *J Sex Med* 5, 2481-2484.
- Short, R.V. (2004). Male circumcision: a scientific perspective. *J Med Ethics* 30, 241.

- Short, R.V. (2006). New ways of preventing HIV infection: thinking simply, simply thinking. (Review). *Philos Trans R Soc Lond B Biol Sci* 361, 811-820.
- Siegfried, N., Muller, M., Deeks, J.J. & Volmink, J. (2009). Male circumcision for prevention of heterosexual acquisition of HIV in men. *Cochrane Database Syst Rev* CD003362 (38 pp).
- Siegfried, N., Muller, M., Deeks, J.J. & Volmink, J. (2010). Male circumcision for preventing heterosexual acquisition of HIV in men. *Int J Epidemiol* 39, 968-972.
- Slaymaker, E. (2004). A critique of international indicators of sexual risk behaviour. *Sex Transm Infect* 80 (Suppl 2), ii13-ii21.
- Smith, D.K., Taylor, A., Kilmarx, P.H., Sullivan, P., Warner, L., Kamb, M., Bock, N., Kohmescher, B. & Mastro, T.D. (2010). Male circumcision in the United States for the prevention of HIV infection and other adverse health outcomes: Report from a CDC consultation. *Public Health Reports* 125 (Suppl 1), 72-82.
- Stang, H., Snellman, L., Condon, L., Conroy, M., Liebo, R., Brodersen, L. & Gunnar, M. (1997). Beyond dorsal penile nerve block: A more humane circumcision. *Pediatrics* 100, <http://www.pediatrics.org/cgi/content/full/100/2/e3>.
- Stang, H.J. & Snellman, L.W. (1998). Circumcision practice patterns in the United States. *Pediatrics* 101, E51-E56.
- Subramaniam, R. & Jacobsen, A.S. (2004). Sutureless circumcision: a prospective randomised controlled study. *Pediatr Surg Int* 20, 783-785.
- Szabo, R. & Short, R.V. (2000). How does male circumcision protect against HIV infection? *Brit Med J* 320, 1592-1594.
- Taddio, A., Stevens, B., Craig, K., Rastogi, P., Bendavid, S., Shennan, A., Mulligan, P. & Koren, G. (1997). Efficacy and safety of lidocaine-prilocaine cream for pain during circumcision. *N Engl J Med* 336, 1197-1201.
- Taeusch, H.W., Martinez, A.M., Partridge, J.C., Sniderman, S., Armstrong-Wells, J. & Fuentes-Afflick, E. (2002). Pain during Mogen or PlastiBell circumcision. *J Perinatol* 22, 214-218.
- Tagami, T. (2010). Atlanta lawyer wins \$11 million lawsuit for family in botched circumcision. *The Atlanta Journal-Constitution* (<http://www.ajc.com/news/nation-world/atlanta-lawyer-wins-11-573890.html>).
- Theford, T.R. (1983). *Sheep Health Handbook. A Field Guide for Producers with Limited Veterinary Services*. Little Rock Arkansas, Winrock International.
- Tobian, A.A., Gray, R.H. & Quinn, T.C. (2010). Male circumcision for the prevention of acquisition and transmission of sexually transmitted infections: the case for neonatal circumcision. *Arch Pediatr Adolesc Med* 164, 78-84.
- Tobian, A.A.R., Serwadda, D., Quinn, T.C., Kigozi, G., Gravitt, P.E., Laeyendecker, O., Charvat, B., Sempijja, V., Riedesel, M., Oliver, A.E., Nowak, R.G., Moulton, L.H., Chen, M.Z., Reynolds, S.J., Wawer, M.J. & Gray, R.H. (2009). Male circumcision for the prevention of HSV-2 and HPV infections and syphilis. *N Engl J Med* 360, 1298-1309.
- Turville, S.G., Cameron, P.U., Handley, A., Lin, G., Pohlmann, S., Doms, R.W. & Cunningham, A.L. (2002). Diversity of receptors binding HIV on dendritic cell subsets. *Nat Immunol* 3, 975-983.
- USPTO. United States Patent and Trademark Office database category 606/118. From <http://www.uspto.gov>.

- Uthman, O.A., Popoola, T.A., Yahaya, I., Uthman, M.M. & Aremu, O. (2011). The cost-utility analysis of adult male circumcision for prevention of heterosexual acquisition of HIV in men in sub-Saharan Africa: a probabilistic decision model. *Value Health* 14, 70-79.
- Wamai, R.G., Weiss, H.A., Hankins, C., Agot, K., Karim, Q.A., Shisana, O., Bailey, R.C., Betukumesu, B., Bongaarts, J., Bowa, K., Cash, R., Cates, W., Diallo, M.O., Dlodlu, S., Geffen, N., Heywood, M., Jackson, H., Kayembe, P.K., Kapiga, S., Kebaabetswe, P., Kintaudi, L., Klausner, J.D., Leclerc-Madlala, S., Mabuza, K., Makhubele, M.B., Miceni, K., Morris, B.J., de Moya, A., Ncala, J., Ntaganira, I., Nyamucherera, O.F., Otolorin, E.O., Pape, J.W., Phiri, M., Rees, H., Ruiz, M., Sanchez, J., Sawires, S., Seloilwe, E.S., Serwadda, D.M., Setswe, G., Sewankambo, N., Simelane, D., Venter, F., Wilson, D., Woelk, G., Zungu, N. & Halperin, D.T. (2008). Male circumcision is an efficacious, lasting and cost-effective strategy for combating HIV in high-prevalence AIDS epidemics: Time to move beyond debating the science. *Future HIV Ther* 2, 399-405.
- Wan, J. (2002). GOMCO circumcision clamp; an enduring and unexpected success. *Urology* 59, 790-794.
- Wang, X., Wu, Y., Ni, X., Xia, B., Xu, J. & Du, Q. (1992). [Research on sterilization of pathogens by high electrostatic voltage method]. (Article in Chinese). *Zhongguo Zhong Yao Za Zhi (China J Chinese Materia Medica)* 17, 604-606.
- Wawer, M.J., Makumbi, F., Kigozi, G., Serwadda, D., Watya, S., Nalugoda, F., Buwembo, D., Ssempijja, V., Kiwanuka, N., Moulton, L.H., Sewankambo, N.K., Reynolds, S.J., Quinn, T.C., Opendi, P., Iga, B., Ridzon, R., Laeyendecker, O. & Gray, R.H. (2009). Circumcision in HIV-infected men and its effect on HIV transmission to female partners in Rakai, Uganda: a randomised controlled trial. *Lancet* 374, 229-237.
- Wawer, M.J., Tobian, A.A.R., Kigozi, G., Kong, X., Gravitt, P.E., Serwadda, D., Nalugoda, F., Makumbi, F., Ssempijja, V., Sewankambo, N., Watya, S., Eaton, K.P., Oliver, A.E., Chen, M.Z., Reynolds, S.J., Quinn, T.C. & Gray, R.H. (2011). Effect of circumcision of HIV-negative men on transmission of human papillomavirus to HIV-negative women: a randomised trial in Rakai, Uganda. *Lancet* 377, 209-218.
- Weiss, H.A., Thomas, S.L., Munabi, S.K. & Hayes, R.J. (2006). Male circumcision and risk of syphilis, chancroid, and genital herpes: a systematic review and meta-analysis. *Sex Transm Infect* 82, 101-109.
- Weiss, H.A., Halperin, D., Bailey, R.C., Hayes, R.J., Schmid, G. & Hankins, C.A. (2008). Male circumcision for HIV prevention: from evidence to action? (Review). *AIDS* 22, 567-574.
- Weiss, H.A., Hankins, C.A. & Dickson, K. (2009). Male circumcision and risk of HIV infection in women: a systematic review and meta-analysis. *Lancet Infect Dis* 9, 669-677.
- Williams, B.G., Lloyd-Smith, J.O., Gouws, E., Hankins, C., Getz, W.M., Hargrove, J., de Zoysa, I. & Dye, C. (2006). The potential impact of male circumcision on HIV in Sub-Saharan Africa. *PLoS Med* 3, e262: 1032-1040.
- Williamson, M.L. & Williamson, P.S. (1988). Women's preferences for penile circumcision in sexual partners. *J Sex Educ Ther* 14, 8-12.
- Wiswell, T.E. & Geschke, D.W. (1989). Risks from circumcision during the first month of life compared with those for uncircumcised boys. *Pediatrics* 83, 1011-1015.

- Wiswell, T.E. & Hachey, W.E. (1993). Urinary tract infections and the circumcision state: An update. *Clin Pediat* 32, 130-134.
- Wiswell, T.E. (1995). Neonatal circumcision: a current appraisal. *Focus Opin Pediat* 1, 93-99.
- Wiswell, T.E. (1997). Circumcision circumspection. *N Engl J Med* 36, 1244-1245.
- Wiswell, T.E. (2000). The prepuce, urinary tract infections, and the consequences. *Pediatrics* 105, 8602.
- World Health Organisation and UNAIDS. (2007a). New data on male circumcision and HIV prevention: policy and programme implications., http://who.int/hiv/mediacentre/MCrecommendations_en.pdf.
- World Health Organisation and UNAIDS. (2007b). Male circumcision: Global trends and determinants of prevalence, safety and acceptability. http://whqlibdoc.who.int/publications/2007/9789241596169_eng.pdf. Geneva, World Health Organization.
- WHO/UNAIDS/JHPIEGO. (2008). Manual for male circumcision under local anaesthesia. http://www.malecircumcision.org/programs/documents/WHO_MC_Manual_Local_Anaesthesia_v2-5C_Jan08.pdf
- Xu, F., Markowitz, L.E., Sternberg, M.R. & Aral, S.O. (2007). Prevalence of circumcision and herpes simplex virus type 2 infection in men in the United States: the National Health and Nutrition Examination Survey (NHANES), 1999-2004. *Sex Transm Dis* 34, 479-484.
- Yahya-Malima, K.I., Matee, M.I., Evjen-Olsen, B. & Fylkesnes, K. (2007). High potential of escalating HIV transmission in a low prevalence setting in rural Tanzania. *BMC Public Health* 7, 103 (10 pages).
- Yan, B., You, H., Zhang, K., Tang, H.Y., Mao, W., He, G.H. & Yin, Z.G. (2010). [Circumcision with the Chinese Shang Ring in children: outcomes of 824 cases]. (in Chinese). *Zhonghua Nan Ke Xue* 16, 250-253.
- Yellen, H.S. (1935). Bloodless circumcision of the newborn. *Am J Obstet Gynecol* 30, 1.
- Yilmaz, D., Akin, M., Ay, Y., Balkan, C., Celik, A., Ergün, O. & Kavakli, K. (2010). A single centre experience in circumcision of haemophilia patients: Izmir protocol. *Haemophilia* 16, 888-889.
- Zhenyuan, L. (1989). People's Republic of China Patent CN2045993 (Laser Shield (Chinese)). (Priority date Mar 21, 1989).



Biomedical Engineering - From Theory to Applications

Edited by Prof. Reza Fazel

ISBN 978-953-307-637-9

Hard cover, 486 pages

Publisher InTech

Published online 06, September, 2011

Published in print edition September, 2011

In all different areas in biomedical engineering, the ultimate objectives in research and education are to improve the quality life, reduce the impact of disease on the everyday life of individuals, and provide an appropriate infrastructure to promote and enhance the interaction of biomedical engineering researchers. This book is prepared in two volumes to introduce a recent advances in different areas of biomedical engineering such as biomaterials, cellular engineering, biomedical devices, nanotechnology, and biomechanics. It is hoped that both of the volumes will bring more awareness about the biomedical engineering field and help in completing or establishing new research areas in biomedical engineering.

How to reference

In order to correctly reference this scholarly work, feel free to copy and paste the following:

Brian J. Morris and Chris Eley (2011). Male Circumcision: An Appraisal of Current Instrumentation, Biomedical Engineering - From Theory to Applications, Prof. Reza Fazel (Ed.), ISBN: 978-953-307-637-9, InTech, Available from: <http://www.intechopen.com/books/biomedical-engineering-from-theory-to-applications/male-circumcision-an-appraisal-of-current-instrumentation>

INTECH
open science | open minds

InTech Europe

University Campus STeP Ri
Slavka Krautzeka 83/A
51000 Rijeka, Croatia
Phone: +385 (51) 770 447
Fax: +385 (51) 686 166
www.intechopen.com

InTech China

Unit 405, Office Block, Hotel Equatorial Shanghai
No.65, Yan An Road (West), Shanghai, 200040, China
中国上海市延安西路65号上海国际贵都大饭店办公楼405单元
Phone: +86-21-62489820
Fax: +86-21-62489821

© 2011 The Author(s). Licensee IntechOpen. This chapter is distributed under the terms of the [Creative Commons Attribution-NonCommercial-ShareAlike-3.0 License](https://creativecommons.org/licenses/by-nc-sa/3.0/), which permits use, distribution and reproduction for non-commercial purposes, provided the original is properly cited and derivative works building on this content are distributed under the same license.

IntechOpen

IntechOpen