

We are IntechOpen, the world's leading publisher of Open Access books Built by scientists, for scientists

6,900

Open access books available

186,000

International authors and editors

200M

Downloads

Our authors are among the

154

Countries delivered to

TOP 1%

most cited scientists

12.2%

Contributors from top 500 universities



WEB OF SCIENCE™

Selection of our books indexed in the Book Citation Index
in Web of Science™ Core Collection (BKCI)

Interested in publishing with us?
Contact book.department@intechopen.com

Numbers displayed above are based on latest data collected.
For more information visit www.intechopen.com



State-of-the-Art Technology in Implant Dentistry: CAD/CAM

Ilser Turkeyilmaz and Roxanna J. Nicoll
*Department of Comprehensive Dentistry
 University of Texas Health Science Center
 San Antonio, Texas
 United States of America*

1. Introduction

Implant dentistry has come a long way since 1982 when Per-Ingvar Branemark first presented his work on osseointegration of endosseous dental implants (Branemark & Albrektsson, 1982). In the last three decades, the use of dental implants has increased exponentially (Friberg B & Jemt T, 2010; Turkeyilmaz et al., 2010). Initially, very few specialists were trained in surgical placement and subsequent restoration. As the treatment became more predictable, the benefits of therapy became evident. The tremendous demand for implants has fueled a rapid expansion of the market. Presently, general dentists and multiple specialists offer implants as a solution to partial and complete edentulism. The field is evolving and expanding, from surgical techniques to types of restorations available. Whereas early implant restorations were primarily indicated for rehabilitation of function, increasing consideration is being placed on esthetics in modern implant dentistry.

1.1 Role of CAD/CAM in dental technology

Presently, there is a trend toward decreasing numbers of dental laboratory technicians in the United States. The number of dental technology programs in the U.S. has decreased by half since 1990 (Christensen, 2005). Conventional implant restorations are time and labor intensive, due to the multiple steps in fabrication, such as casting and fitting. Simultaneously, there is an increasing demand for efficient treatment that can be completed in minimal time— the “drive-thru” mentality of modern society. Fortunately, technology has kept up with this demand, and the application of CAD/CAM in implant dentistry is a promising solution (Valente et al., 2009; Van Assche et al., 2010).

Computer-aided design and computer-aided manufacturing (CAD/CAM) is being utilized in many fields besides dentistry. In the manufacturing industry, rapid prototyping using SLA modeling, which is a crisp, highly detailed CAM method, is used to produce prototypes (Jacobs, 1992; Ozan et al., 2009). Frequent applications of SLA technology are highly detailed and accurate medical models, master patterns for casting and even soft tissue facial prostheses. Several authors have suggested that CAD/CAM may improve the accuracy of dental implant planning and placement (Sarment, 2003; Tardieu, 2003; Van Assche et al., 2010; Arisan et al., 2010; Mandelaris et al., 2010). An extension of this application is the ability to prefabricate dental prosthesis prior to the implant surgery.

1.2 Range of implant-supported restorations

Dental implants can support many types of dental restorations, ranging from a single tooth to a full-arch fixed bridge. The prosthetic design must take into consideration many factors, including number of teeth to be replaced, biomechanical considerations regarding how many implants are necessary to support the restoration, functional considerations such as the occlusal scheme and opposing dentition or restoration, and relative cost of the restorative materials. Implant based restorations can be either fixed or removable, depending on the patient's desires, ability to perform adequate hygiene, and whether adequate support can be achieved by the implants alone, without additional support of the soft tissue. The final prosthetic design must account for all the individual patient variables, take into consideration the best available evidence regarding long-term prognosis, and ideally meet the patient's expectations for both esthetics and function.

1.3 Edentulism and role of implant-based restorations

Considering the range of restorations available, implants can serve the greatest utility when considering complete dentures. Conventional dentures have significant functional limitations when compared to natural teeth. Masticatory performance of people wearing complete dentures is less than 20% of those with natural dentition (Kapur & Soman, 1964). Patients commonly report pain, areas of discomfort, poor denture stability and difficulties eating as reasons for dissatisfaction with conventional dentures (Allen & McMillan, 2003). However, there are many clinical factors that may affect the overall function and patient satisfaction with conventional complete dentures, such as residual ridge height, salivary flow, and technical quality of the dentures (Turkyilmaz et al., 2010). It is therefore essential that a thorough clinical examination of the patient and any existing prostheses be coupled with a detailed patient interview about masticatory performance of the existing prostheses and impact on quality of life. This information is vital to proper treatment planning and consideration of one of the many possible implant-based restorations including a two-implant overdenture with ball or locator attachments, a bar overdenture supported by two or four implants, or a completely implant supported fixed hybrid denture.

Many authors have investigated the impact of implant supported dentures compared to conventional dentures. A clinical study by Awad et al. (2003), included 104 edentulous adults, aged 35 to 65 years. Patients were randomly assigned to one of two groups that received either a mandibular conventional denture or a two-implant bar overdenture. Patients rated their general satisfaction and specific factors of both their previous dentures, as well as their new prosthesis at 2 months post-delivery. Oral health-related quality of life was also evaluated pre- and post-treatment. The mean general satisfaction of the implant-overdenture group was significantly higher than the conventional denture group. The implant-overdenture group also rated comfort, stability, and ease of chewing better than the conventional group. The conclusion of this study was that a mandibular implant-supported overdenture opposing a maxillary complete denture was more satisfactory than conventional dentures.

Heydecke et al. (2005), studies the impact of mandibular two-implant overdentures compared to conventional complete dentures on leisure and sexual activities. This study of 102 patients found social activity was improved with implant-supported overdentures compared to conventional dentures. Implant-supported dentures including either complete overdentures or a hybrid prosthesis significantly improve the quality of life for edentulous patients compared with conventional complete removable complete dentures.

It is true that people are keeping their teeth longer than in the past. Measures such as oral hygiene, access to care and water fluoridation are having a positive impact on oral health in this country. The decrease in percentage of edentulous adults over the past 20 years has prompted some educators to propose that complete dentures be removed from the dental curriculum (Turkyilmaz et al., 2010). However, it appears that the decrease in rates of edentulism among older adults is insufficient to offset the growing US population.

Several trends are apparent when relating the US Census data from 1991-2020. The population projections from the 1996 Statistical Abstracts of the United States illustrate these trends. The total adult population will increase significantly from 187,020,000 to 245,139,000 people. The number of adults aged from 55 to 74 years will increase by 86%. The number of adults aged 75 and older will increase by 61%. Thus the US population of older adults will grow dramatically over the next 12 years. Estimated decreases in the percentage of edentulism for maxillary and mandibular arches for each age group of 10% for year 2000, 20% for year 2010, and 30% for year 2020 (Weintraub & Burt, 1985). Even if a decrease in edentulism is assumed, an increase in the actual number of adults will result in an increase in the number of dentures needed over the next 12 years. Actually, the 2010 US Census reported 308,745,538 residents, which indicates a significant increase compared to the predicted number (245,139,000).

We can conclude that there will be a significant need for denture therapy, and that implant dentistry has the potential to dramatically improve the quality of life for those edentulous patients. Further, a range of treatment is available for improving the function, from two-implant overdenture with mechanical attachments to a fully fixed-detachable hybrid prosthesis.

1.4 Patient demand and knowledge regarding implant therapy

The number of implants placed has been increasing significantly each year, (about 18% in the USA) (Turkyilmaz et al., 2010). Improved implant surfaces and surgical techniques have led to a marked increase in predictability. This has resulted in a tremendous demand. The demand for implant therapy has fueled growth of the industry, and now many clinicians offer implant therapy, not just specialists. Problems with implants have been raising as more clinicians who do not have advanced training and skills have been involved in implant placement. Unfortunately, little quantitative data regarding implant complications related to level of training are available.

Consecutive surveys of the Australian population showed that patient awareness of implant dentistry is increasing (Pommer et al., 2011). Most patient's trust their general dentist for information regarding implant therapy, while one quarter turn to the media. Overall, the level of knowledge is satisfactory. The exception is patient's unrealistic expectations. Patient's demand for high-quality restorations has increased, and the majority felt that practice of implant dentistry should be limited to specialists.

Similar trends regarding increasing patient awareness in the United States have been observed. However, due to the increasing prevalence of direct marketing, more patients are relying on media and internet sources for information regarding implant therapy. Advertisement has contributed to patient's unrealistic expectations regarding treatment times, and led to significant confusion regarding the range of treatment options available. Few resources are available to assist patient's in understanding of the variety of implant restorations along with the advantages and disadvantages of each.

1.5 Success criteria for implant therapy

Objective evaluation of the treatment outcome is paramount in order to ensure predictability and excellent long-term prognosis. The first criteria for success were proposed by Albrektsson et. al., in 1986. However, success and failure lie at opposite ends of a spectrum. In order to better elucidate the actual condition of an implant, not just its presence in the mouth, the Health Scale for Dental Implants was developed (Misch et al., 2008). This scale consists of four categories: success with optimum health, satisfactory survival, compromised survival, and failure. The clinical indices evaluated in this scale include pain, mobility, radiographic bone loss, probing depths, and peri-implant disease. Optimum health is defined as the absence of pain or tenderness on function, zero mobility, less than 2 mm of radiographic bone loss from time of placement, and no history of exudate. At the other end of the spectrum is absolute or clinical failure, in which any of the following are present: pain on function, mobility, radiographic bone loss greater than 1/2 the length of the implant, uncontrolled exudate, or the implant is no longer in the mouth.

1.6 Treatment planning for implant-based restorations

The first phase of implant dentistry is planning. It is insufficient to identify an edentulous space, or missing tooth, and simply initiate surgery. First, a diagnostic wax-up of the proposed tooth form and ideal location must be achieved. From this, a radiographic guide is fabricated that simulates the wax-up. Next, diagnostic imaging must be done in order to determine the alveolar bone available for implant placement. Traditional radiographs including periapical films and panoramic films are helpful, but limited in application due to their two dimensional nature and potential distortion. In 1972, the invention of computed tomography revolutionized medical and dental imaging. It became possible to obtain 3-dimensional digital images, thus an accurate assessment of the height and width of alveolar bone available for implant placement.

This 3-dimensional image is the basis of establishing the treatment plan. It allows a practitioner to identify potential implant sites, measure the height and width of the available bone, and the necessary restorative space for the planned prosthesis and the components. If bone grafting, such as sinus augmentation, is necessary in order to position implants properly for a given prosthetic design, the necessary procedures can be incorporated into the treatment plan. Basically, this 3-dimensional image gives both the clinician and the patient a better idea of the limitations that will be encountered at the time of surgery, ensuring better predictability of both the surgery and the final prosthetic outcome.

2. CAD/CAM technology- surgical guides

CAD/CAM technology takes implant planning a step further, and enables fabrication of a surgical guide (Figure 1). The surgical guide directs the surgeon in the exact location and angulation to place the implant. There is a growing number of software programs that allow viewing and analysis of the 3D images and subsequent fabrication of a surgical guide.

In the youth of implant dentistry, the treatment was surgically driven, meaning that the implant was placed according to the bone available at the time of surgery. This approach eventually proved erroneous, because many implants were placed in locations and angulations that made them difficult or impossible to restore. The evolution of the field has led to a restoratively-driven approach, where the restorative dentist communicates the desired position and angulation via a surgical guide. Conventional surgical guides, however, have some significant limitations.



Fig. 1. Example of CAD/CAM surgical guide for implant placement.

2.1 Surgical guides for implant placement

Computer-assisted planning and use of CAM surgical guides dramatically increases the accuracy of implant placement, which directly improves the outcome of the final restoration. These surgical guides help the surgeon avoid vital structures, and may decrease the length of the surgery. Furthermore, it assures the restorative dentist and dental technician a functional, esthetic, and predictable outcome. Equally important, CAD/CAM design and fabrication of guides improves the patient's experience with implants. CAD/CAM allows the possibility of flapless surgery, which entails less bleeding, less swelling, decreased healing time and post-operative pain (Fortin et al., 2006).

There are three broad categories of surgical guides: conventional, SLA fabricated, and cast-fabricated. Conventional implies it was the method employed prior to CAD/CAM, but with the rapid evolution of the field, the term conventional is unclear, and encompasses a large variety of techniques. One specific conventional technique for surgical guide fabrication entails fabricating a scanning template or radiographic guide, usually tooth-borne. Then, according to the findings of the CBCT, identifying reference points that allow orientation of the radiographic guide on a surveyor table in conjunction with a drill press to create the pilot hole that will guide the surgeon. This technique, since it is the opposite of digital, is coined "analog".

The major distinction between the two types of CAD/CAM surgical guides lies in the fabrication. SLA guides are purely CAD/CAM, whereas cast-fabricated are initially made on a stone model, then a computerized version of the surveyor and drill press create the pilot holes based on the digitally planned implant placement. Each has its advantages and disadvantages. The SLA process leaves topographic seams, which may not fit the occlusal

and axial anatomy of a tooth. If the surgical guide does not fit precisely and accurately, the surgical result may be compromised. A surgical guide that is fabricated on a stone model, however, can be tried in intra-orally and verified prior to the CBCT scan and subsequent conversion into a surgical guide.

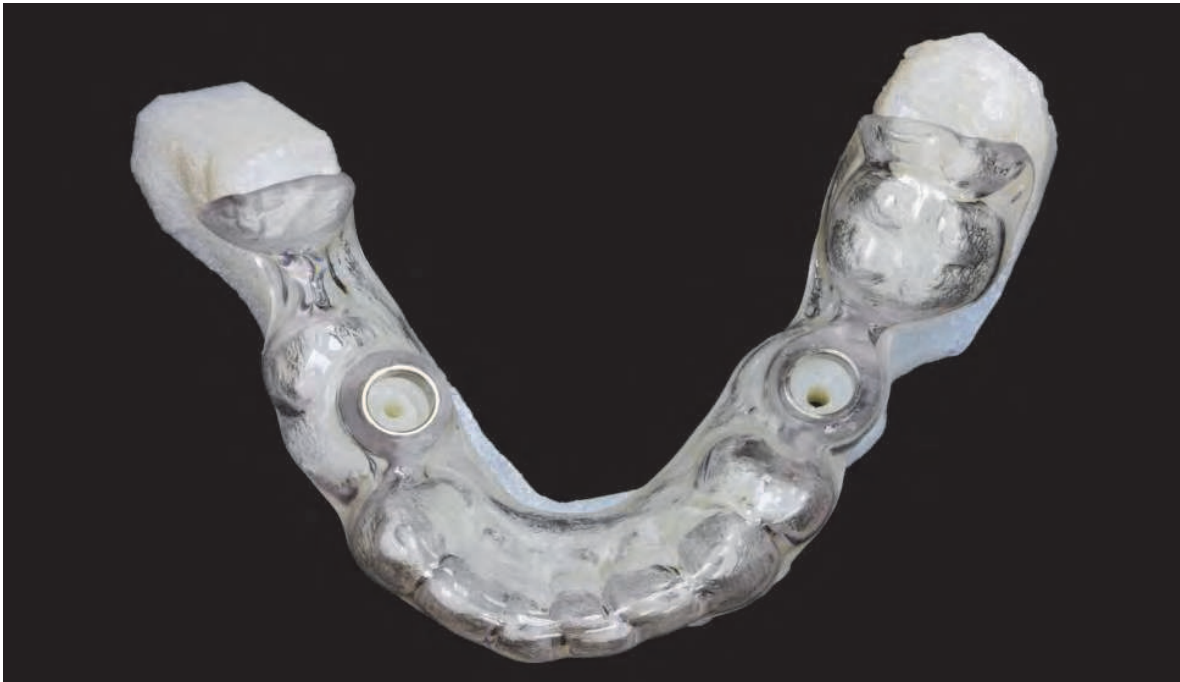

Fig. 2. A tooth-supported CAD/CAM surgical guide on the cast.

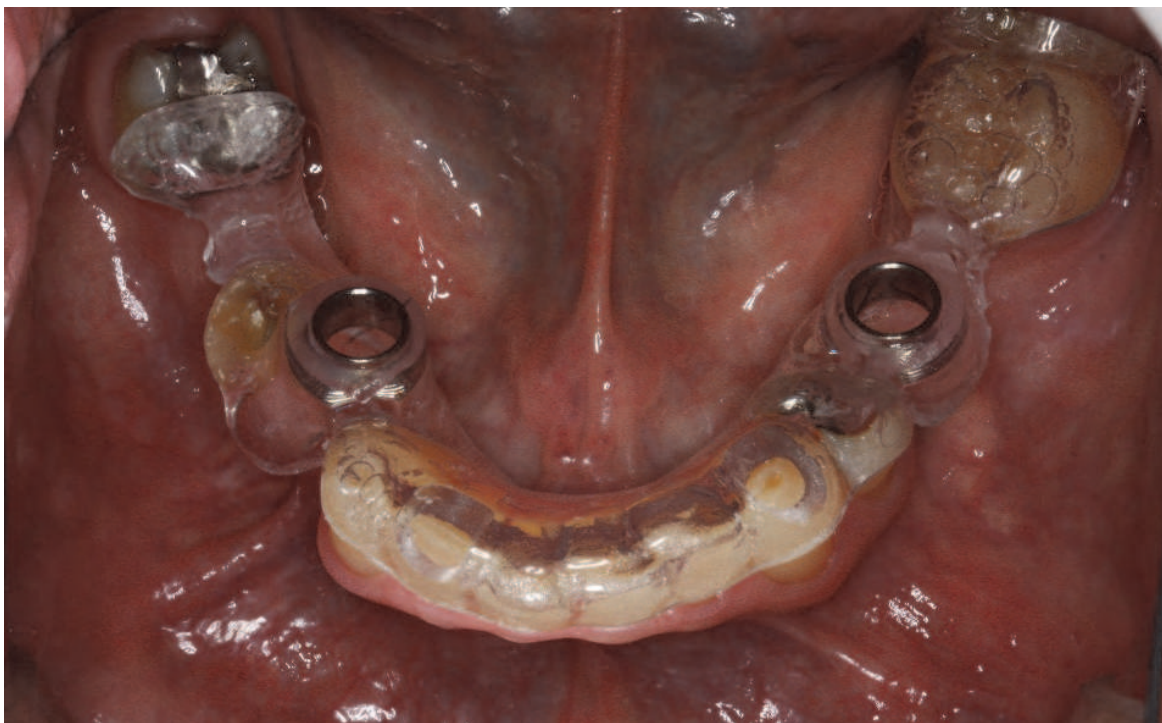

Fig. 3. A tooth-supported CAD/CAM surgical guide seated on the teeth.

2.2 Type of support for implant surgical guides

Surgical guides can also be classified according to the type of support: bone, mucosa, tooth (Figures 2,3), or combination tooth-mucosa. The choice of which type of support depends on many factors, such as the number of teeth remaining in the arch, whether the mandibular or maxillary arch is being treated, and the anatomy of the edentulous or partially edentulous ridge. Teeth offer a very stable support for a surgical guide, but the complex topography of the occlusal surface may make increase the time required to fit the surgical guide to the mouth. Soft tissue, is by definition compressible and displaceable to varying degrees. Extra measures must be taken to ensure that a mucosa-supported surgical guide is positioned accurately to ensure surgical success.

2.3 Software for implant planning and surgical guide fabrication

Presently, there are a multitude of software programs for virtual placement of implants and subsequent fabrication of surgical guides. The most well-known are Procera from Nobel Biocare and Simplant by Materialise, but many more have recently been introduced to the market. Each software platform varies in the types of guides available and which implant system it is compatible with. Procera NobelGuide includes mucosa and tooth based guides and is strictly compatible with Nobel Biocare implants. Simplant offers bone, tooth, or mucosa based guides and is can be employed with virtually any implant system. Each software presents it's own limitations and challenges; cost is also a consideration for the clinician. All of the current software programs are based on algorithms for medical CT, not CBCT, which may influence interpretation of the data. In addition, the corresponding surgical kit for each implant system may or may not offer depth control, which will ultimately influence the surgical outcome.

2.4 Accuracy of guided implant surgery

The accuracy of CAD/CAM surgical guides has been investigated with in vitro, human cadaver, and clinical studies. The available research supports the hypothesis that guided surgery is accurate, with certain limitations. Ersoy et. al.(2008), placed 94 implants using SLA surgical guides generated from CT. CT images were obtained with radiographic templates in place, and implants were placed virtually. SLA surgical guides including bone-based, mucosa-support, and tooth-support were then fabricated and used for implant surgery. Following implant placement, a new CT scan was taken. Special software was employed to overlay the planned placement with the post-surgical outcome, matching anatomical markers. This allows analysis of the outcome in three dimensions. The mean linear deviation was 1.22 ± 0.85 mm at the implant neck and 1.51 ± 1 mm at the implant apex. In general, a greater distance between simulated and actual implants was observed at the implant apex than at the implant neck. The mean angular deviation in long axis between the planned and placed implants was 4.9 ± 2.36 degrees.

Careful consideration must be given to the mean error, versus actual error for an individual patient. In the previous study, the mean angular deviation was 4.9 degrees, but the actual error for one patient was 9 degrees. Depending on the available height and width of the alveolus, this error could result in dehiscence of the bone and eventual failure of the implant.

In vitro studies such as Besimo et al. (2005), aimed to determine the magnitude of error in transferring the planned position of implants from CT scans to a surgical guide. The deviation between the positions of the apex of the proposed implants in cross-sectional CT images and on the corresponding study cast was measured in 77 prospective sites in five maxillae and nine mandibles. The transfer error was 0.6 ± 0.4 mm in the maxilla and 0.3 ± 0.4 mm in the mandible. However, they concluded that the transfer errors found in their study were not clinically relevant as their study was an in vitro study. They also stated that other factors involved in transferring positional and angular measurements from CT images to the surgical area may result in greater errors.

Little evidence is available regarding the accuracy of guided surgery compared to conventional implant placement, using the analog technique for guide fabrication. Sarment et al. (2003), placed 50 implants into five epoxy edentulous mandibles. Each epoxy mandible received five implants in each side. On the right side, five implants were placed using a conventional surgical guide (control side), while on the left side, five implants were placed using a stereolithographic surgical guide (test side). They found a statistically significant improvement in all measurements when SLA surgical guides were used compared to conventional guides and suggested that the clinical significance of this result may be relevant when multiple parallel distant implants are placed, and where the degree of accuracy is critical to obtain a single prosthetic path of insertion. They also reported, when the control surgical guide was used, the center of the osteotomy was 1.5 ± 0.7 mm away from the center of the planned implant at coronal end and 2.1 ± 0.97 mm at the apex. When the test appliance was used, these distances were 0.9 ± 0.5 mm at the implant head and 1 ± 0.6 mm at the apex.

The available evidence suggests that CAD/CAM surgical guides are relatively accurate, but more research is needed in this area. Better data on the possible error will ultimately improve clinical judgement and case selection. This could potentially reduce or even eliminate error.

2.5 Guidelines for CAD/CAM guided surgery

Currently there are no published guidelines regarding indications for flapless surgery versus a conventional open-flap surgery. It is clear from Sarment's study (2003) that the use of a CAD/CAM guide can increase the accuracy of implant placement, and when used in an open-flap surgery, the surgeon has the capacity to intercept potential error by visualizing the bone and implant directly. Thus, in an open-flap surgery, CAD/CAM surgical guides are superior to conventional guides.

The decision of whether to perform a flapless surgery depends on many factors. Patient comfort, decreased healing time, maintenance of blood supply, and decreased surgical time are all advantages of flapless surgery. The accuracy of implant placement required depends in large part on the type of restoration planned. For example, an implant-overdenture has a medium level of accuracy necessary, in that linear and angular deviations can be accommodated by the attachment system. A fixed restoration, on the other hand, has a significantly lower degree of freedom, and may indicate CAD/CAM guided surgery in order to maximize the precision of implant placement.

The type of template support is also an important consideration. Flapless surgery can be accomplished with a tooth-borne guide, a tooth-tissue borne guide, or a purely tissue-

supported guide. The number of teeth, condition of the tissue, and morphology of the residual ridge will all affect the overall stability of the guide and the accuracy of placement, which directly impact the accuracy of implant placement. A good rule of thumb for an edentulous arch is if the denture has reasonable stability and resistance to lateral dislodging forces, a tissue-supported surgical guide will have the same degree of stability. In general, a maxillary denture is more stable than a mandibular denture. In addition, the opposing dentition or prosthesis can aid in predictable placement which will increase the accuracy.

It is reasonable to incorporate the mean accuracy of guided systems into a set of guidelines, particularly for flapless surgery. For example, if the average linear deviation is 1.22-1.51 mm, and 1 mm of bone is necessary buccal and lingual to the implant, one can conclude that the alveolar ridge must be wide enough to accommodate both the implant and the potential error. This window of safety may vary based on the stability of surgical guide, which relates back to the type of support and the stability of the scanned template from which the surgical guide is patterned. Establishing guidelines based on the available is imperative, but ultimately clinical judgement must be the final determinate.

Immediate loading and pre-fabricated provisional restorations are other advantages of CAD/CAM surgical guides. By using a CAD/CAM surgical guide, a pre-fabricated provisional restoration can be delivered immediately after implant placement, which increases the patients' self-confidence dramatically. The pictures of one of our patients using NobelGuide and a maxillary provisional restoration (screw-retained fixed dental prosthesis) have been presented below (Figures 4-13).

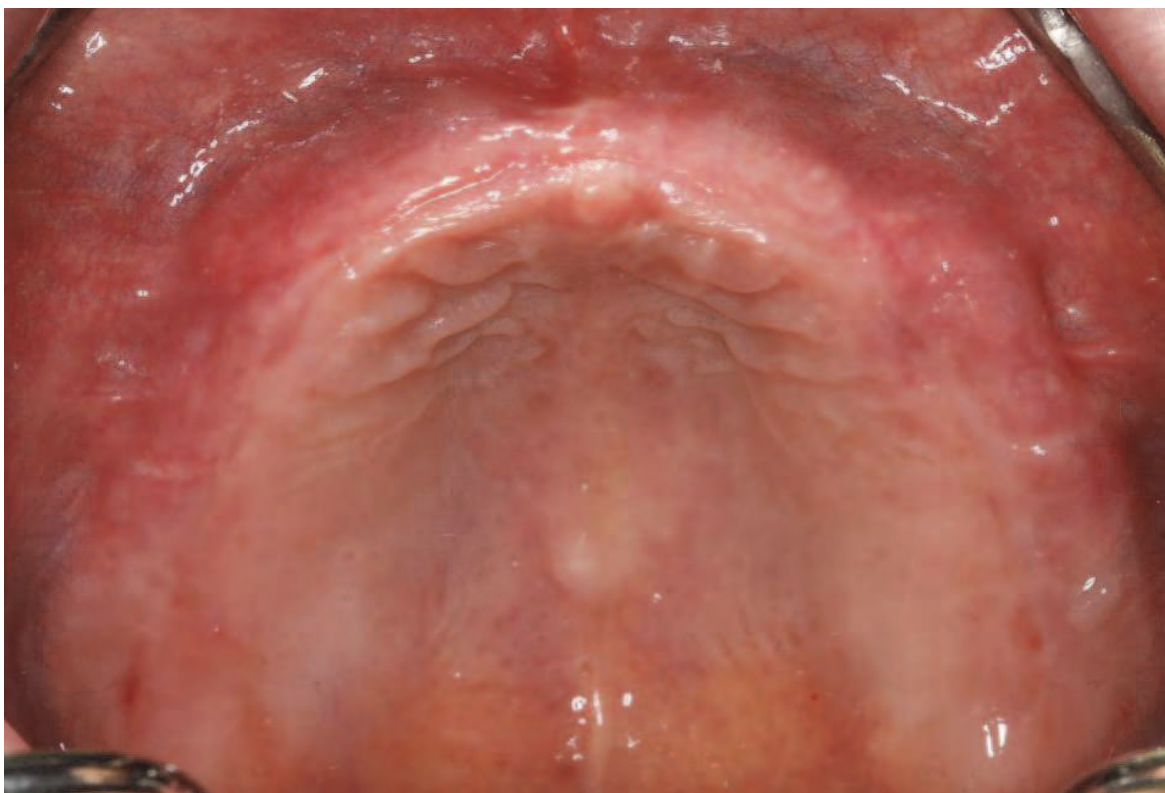

Fig. 4. Occlusal view of edentulous maxilla.

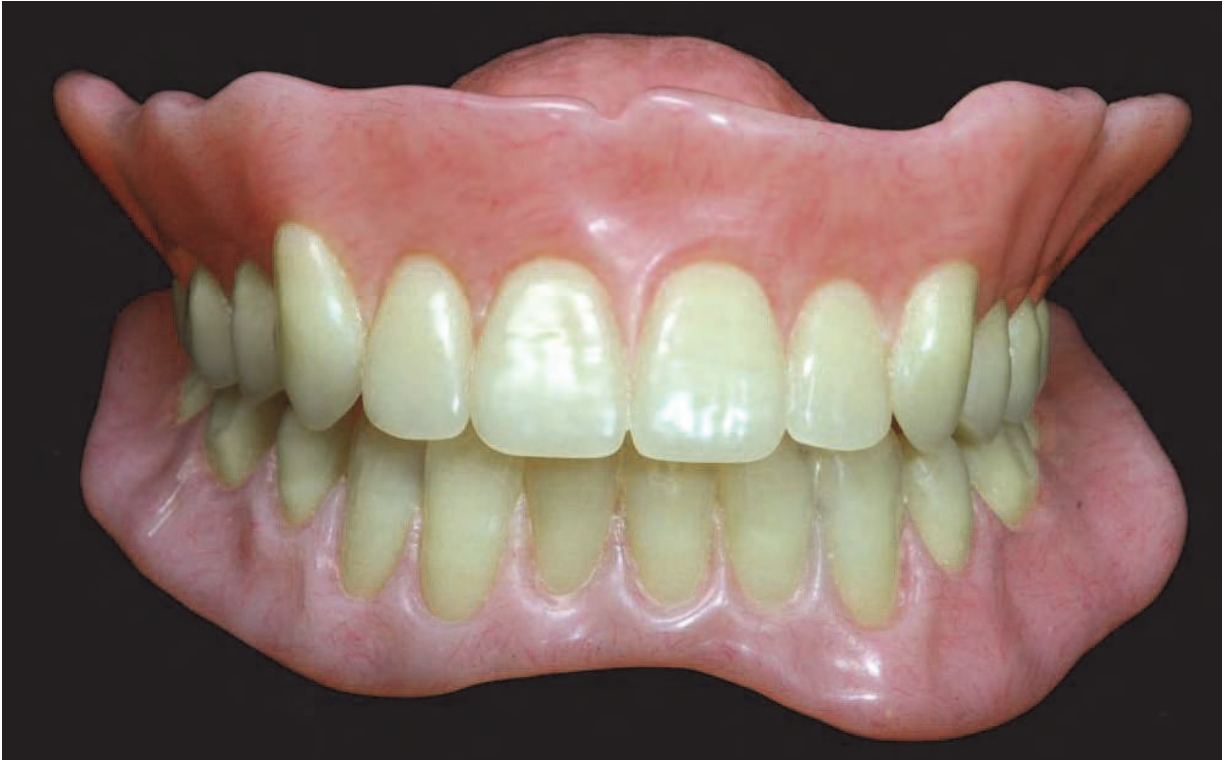

Fig. 5. Implant diagnostic dentures to serve as radiographic template for implant planning and surgical guide fabrication.



Fig. 6. NobelGuide: steriolithographic surgical guide for flapless implant placement.

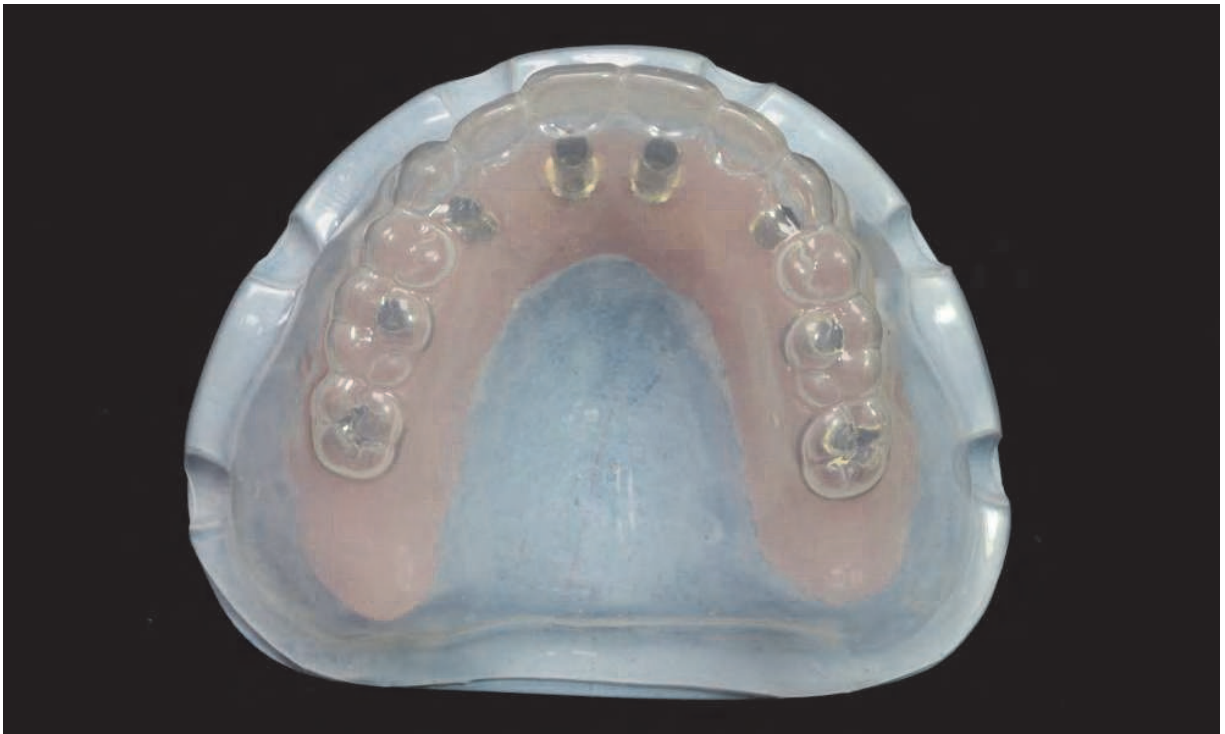

Fig. 7. Pre-surgical fabrication of cast with implant analogs, temporary abutments, and clear matrix of diagnostic tooth arrangement.

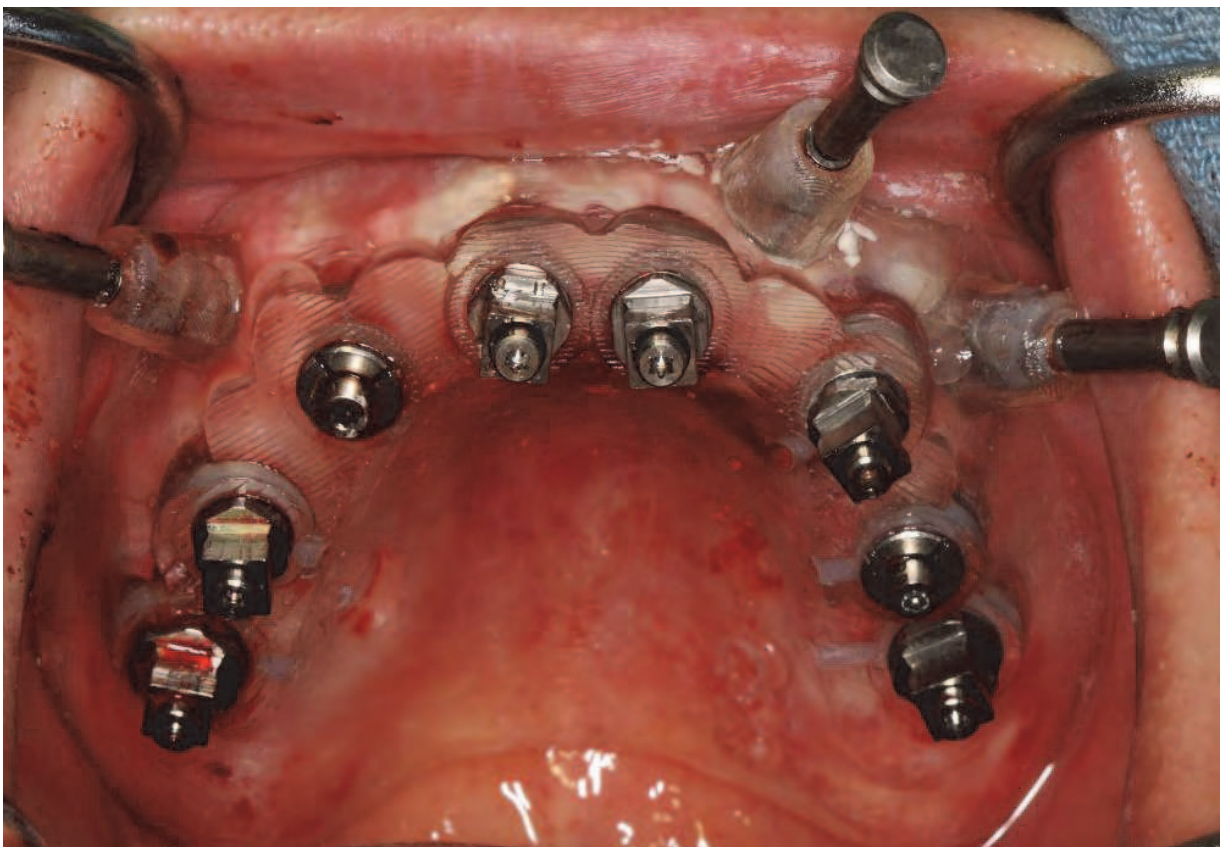


Fig. 8. NobelGuide and fixation pins at time of surgery.

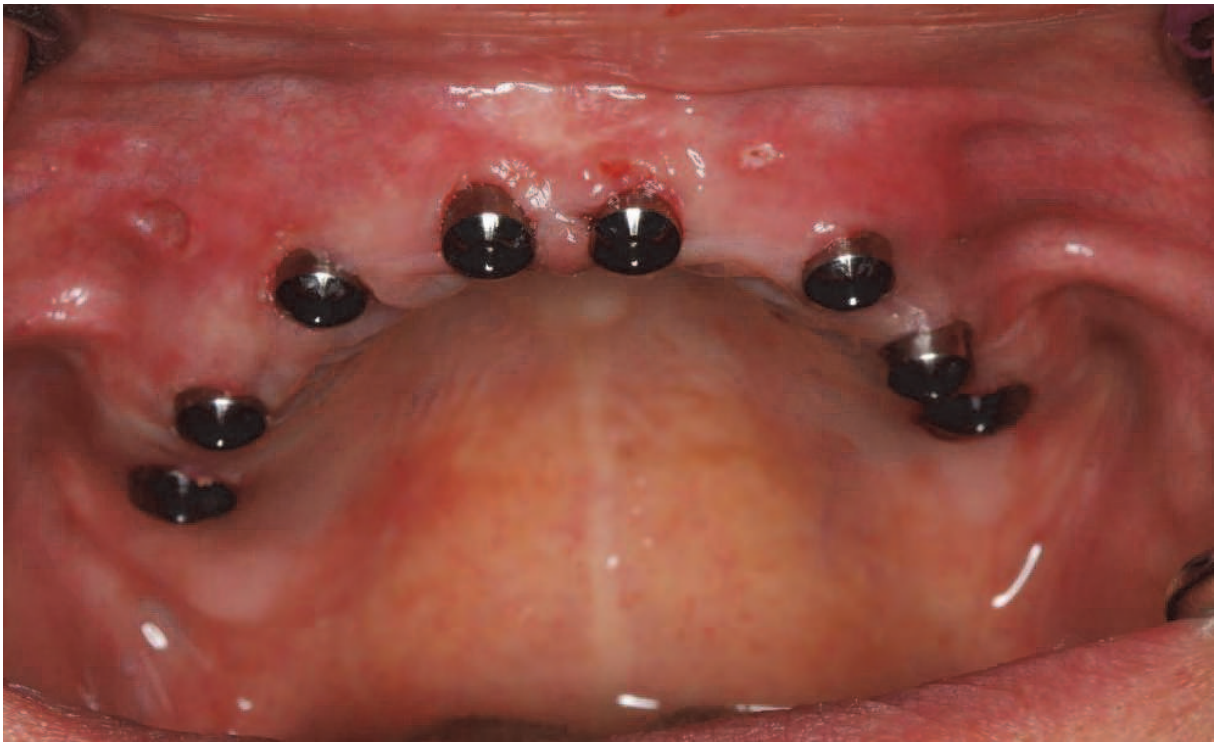


Fig. 9. Immediately post-op following flapless guided implant placement using NobelGuide.

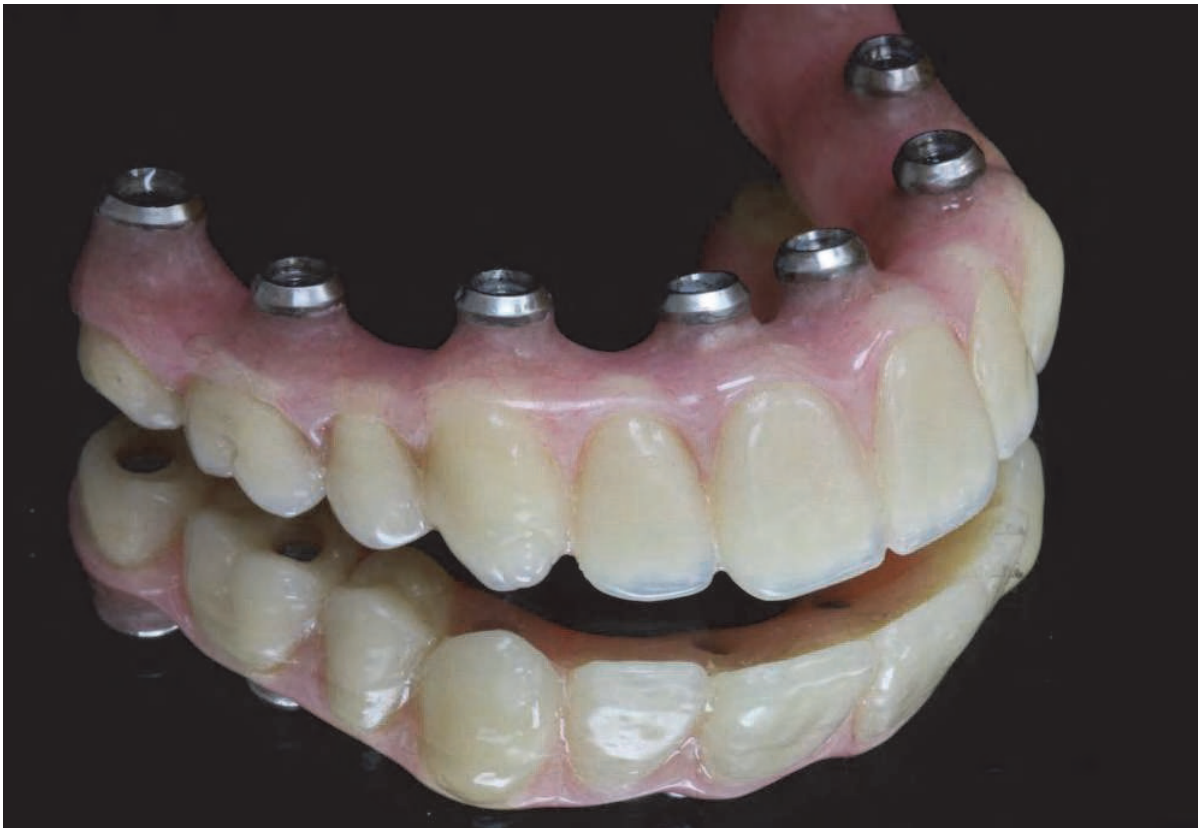

Fig. 10. Diagnostic denture converted into immediate fixed provisional for immediate loading.

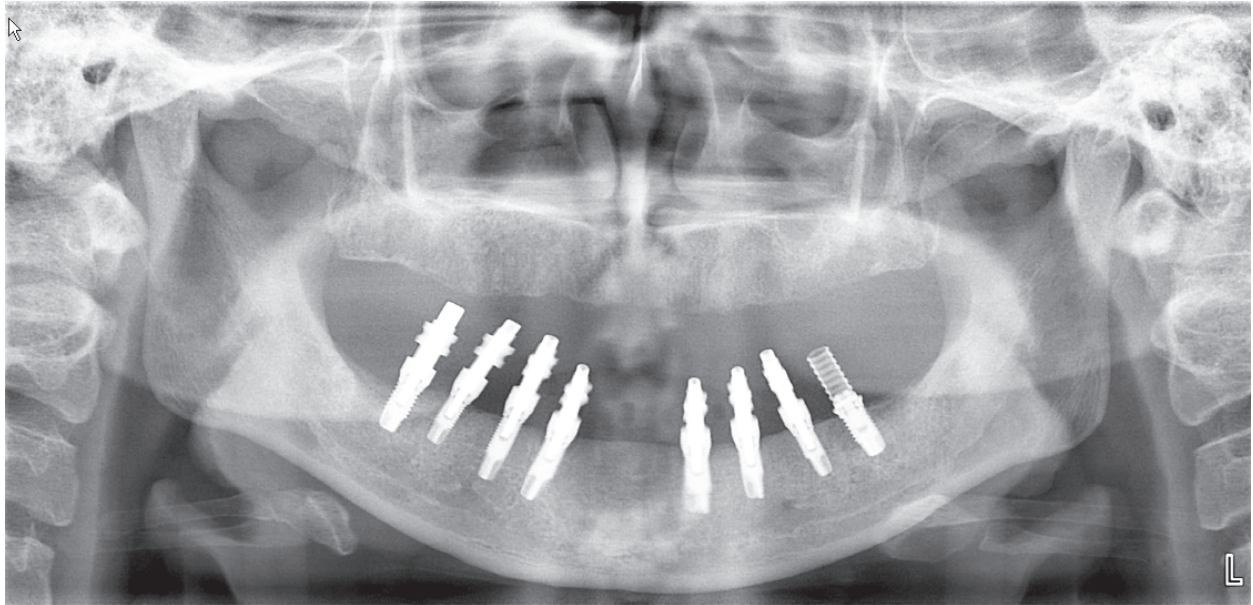


Fig. 11. Pre-operative panoramic image of edentulous maxilla.

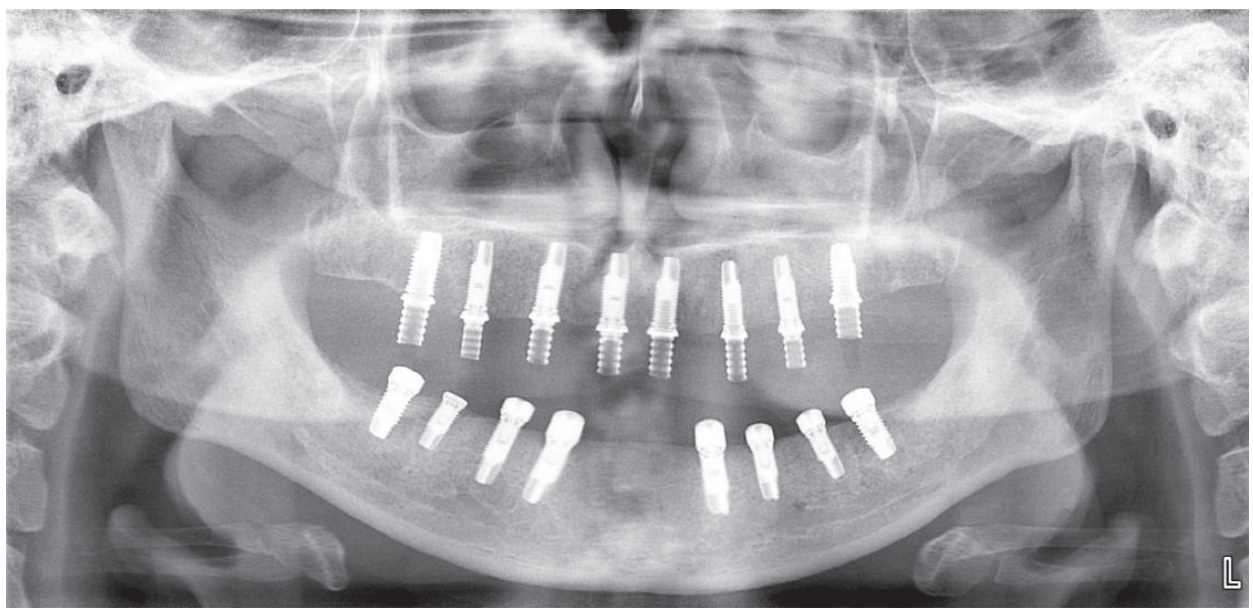


Fig. 12. Post-operative panoramic image following guided implant placement and immediate provisionalization.

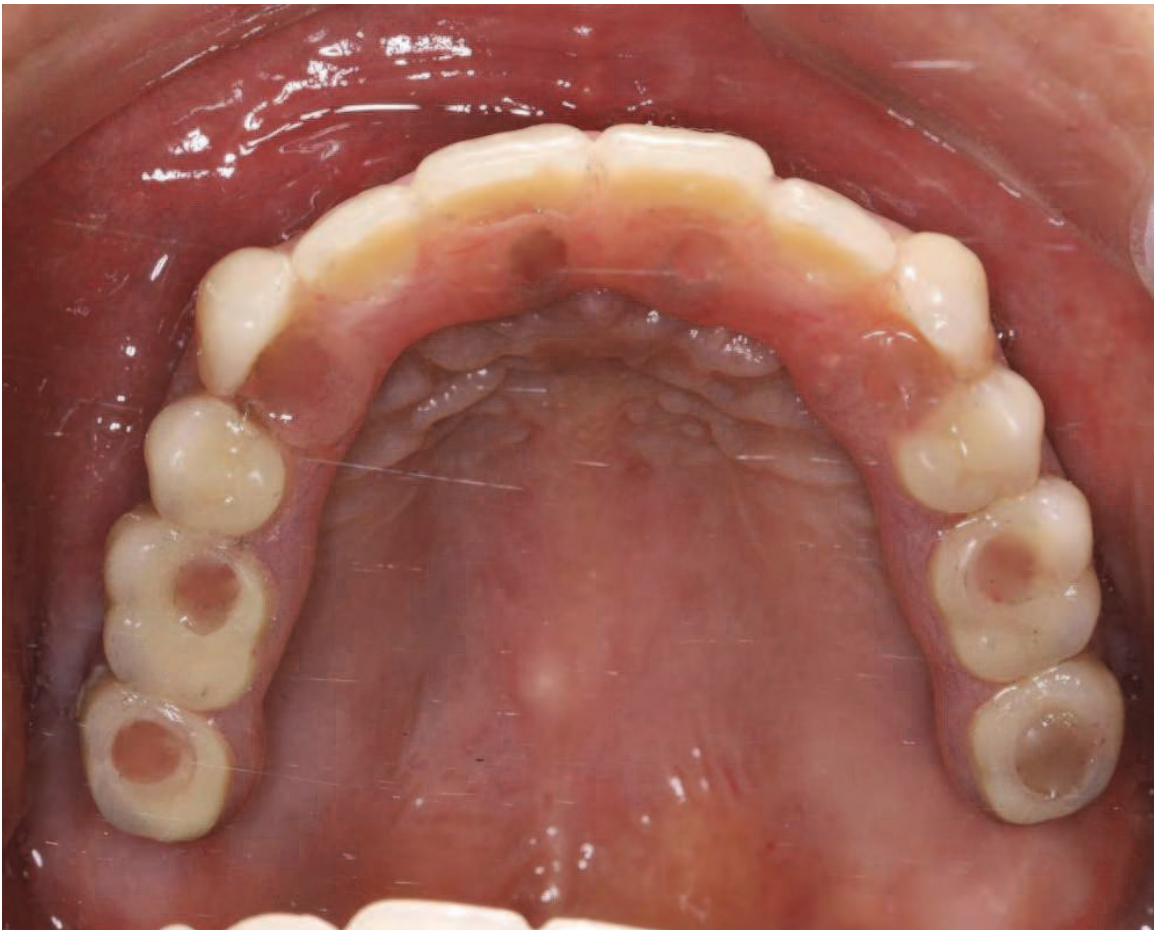


Fig. 13. Occlusal view of immediately loaded maxillary implants.

3. CAD/CAM technology- bars & frameworks

CAD/CAM technology has significantly improved the restorative aspects of implant dentistry as well. Implant restorations can be supported or retained by individual attachments, splinted with a bar for an overdenture, or splinted by a framework that supports a fixed restoration such as a hybrid. Prior to CAD/CAM, bars and frameworks had to be cast from gold alloy.

3.1 Conventional framework fabrication

Traditional castings have a major limitation inherent in the process, which is distortion of the casting with increasing size of the pattern (Takahashi & Gunne, 2003; Al-Fadda et al., 2007). Osseointegrated implants lack a periodontal ligament, thus tolerance of fit is greatly reduced when comparing tooth-supported cast restorations to implant-supported restorations. Single and two implant restorations can be cast within this tolerance, because the distortion is limited based on size. Full arch restorations, however, are difficult to cast successfully. Over the years, a multitude of casting corrective procedures have been employed, including sectioning and soldering, laser welding, and electric discharge machining.

CAD/CAM fabrication of bars and frameworks has resulted in elimination of distortion, better fit, fewer fabrication steps, and faster turn-around (Ortorp & Jemt, 2000; Takahashi &

Gunne, 2003; Al-Fadda et al., 2007). The workflow for creating a CAD/CAM bar starts with an accurate impression and model including the implant analogs. The model containing the implant analogs is then scanned, and then the CAD portion begins. Currently, bars and frameworks can be milled from titanium or zirconium. Titanium is abundant on Earth and offers a significant cost savings relative to gold.

3.2 Prosthetic designs and space allocation

There are several prosthetics designs with dental implants (Figure 14). Overdentures, whether supported by a conventional cast gold bar or a CAD/CAM titanium bar, are space intensive, due to the multiple components involved. Careful planning is necessary to ensure that the implants are placed in the correct position, and there is adequate restorative space for the soft tissue, the implant-supported bar, attachment system, overcasting or prosthetic framework, artificial teeth and pink acrylic base.

The exact amount of restorative space depends on the specific prosthetic design and the restorative materials employed. The issue of space allocation can be addressed in the planning stage for implant placement, utilizing the scan template in order to calculate the distance between the alveolar crest and the occlusal surface. Some authors have advocated 8-12 mm of crown-height space for fixed restorations and greater than 12 mm for removable prostheses (Misch et al., 2005). More specific recommendations based on the specific prosthetic design are 6-8 mm for single implant crown, 8-12 mm for locator retained overdentures, 10-14 mm for acrylic hybrid restoration, and 12-14 mm for a bar-supported overdenture. In actuality, the various prosthetic components exist in three-dimensions, thus linear measurements can only serve as guidelines to ensure adequate restorative space.

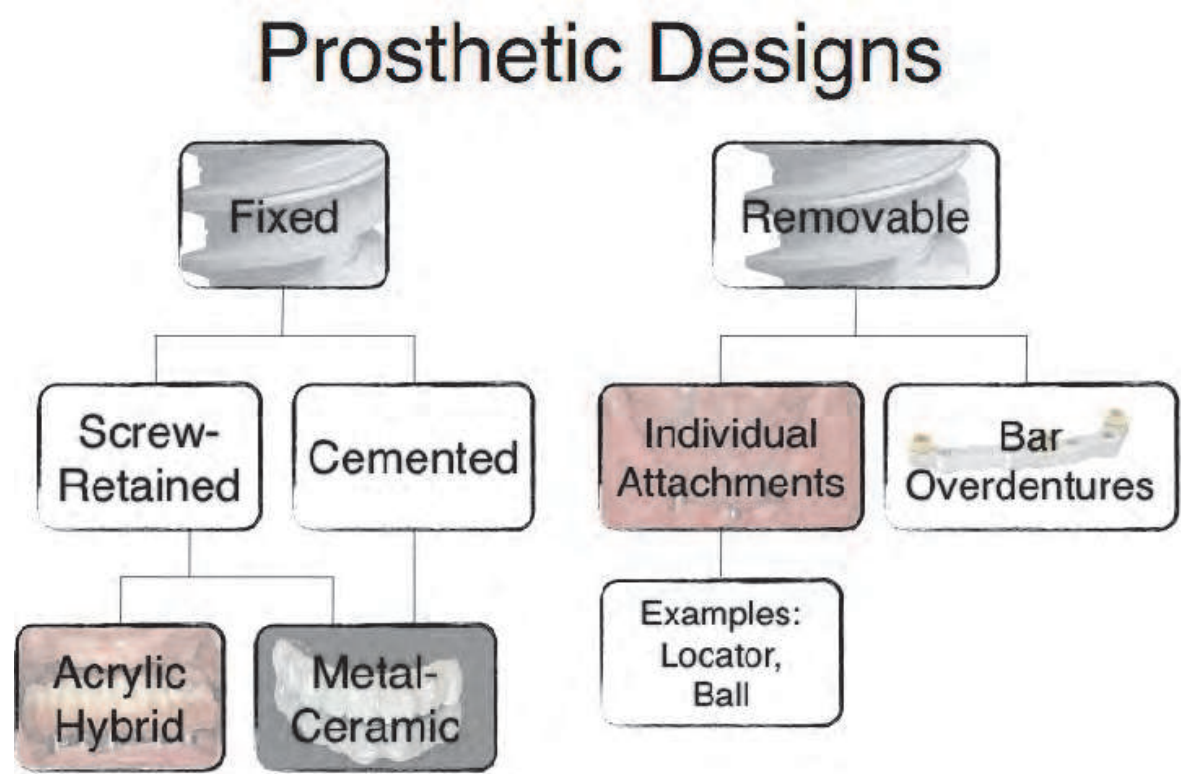


Fig. 14. Classification of prosthetic designs.

Many of the newer software platforms are incorporating virtual abutments so that components can be pre-selected and ordered at the same time as the surgical guide.

Prosthetic design is also influenced by material compatibility. Certain materials are conducive to CAD/CAM while others are not. Titanium and zirconia are well suited for CAM techniques, whereas gold is not. Conversely, porcelain systems developed for gold alloys have been used for many years with a high degree of success, whereas the newer porcelain systems developed for veneering titanium and zirconia lack long term clinical data. For example, a 6 year follow-up on porcelain fused to titanium fixed dental prostheses revealed that titanium PFMs had a 84% survival after six years, compared to a 98% survival for gold alloy PFMs (Walter et al., 1999). As porcelain systems continue to be improved, the applicability of CAD/CAM in implant dentistry will increase.

3.3 Passive fit

Critical to the long term success of implant based restorations is careful consideration of the biomechanics involved. Following osseointegration and placement of a final restoration, both functional and parafunctional loads can be transferred to the implants that may affect remodeling of the bone-implant interface. In the case of splinted implant restorations, it is possible that the restoration itself may transmit strain to the bone-implant interface. Ideally, the restoration would fit passively on the supporting implants, thus minimizing strain and the concomitant biological response.

The concept of passive fit was considered even in early applications of implant-based restorations. The original Branemark design consisted of five implants placed in the anterior mandible, a cast framework supported by five standard abutments and acrylic resin teeth and gingiva processed onto the framework (Figure 15). Branemark considered passive fit to exist when the gap between the framework and the abutment was 10 microns (Abduo et al., 2010). Several authors have proposed definitions of passive fit, however all definitions are theoretical, and difficult to assess clinically.

It has been suggested that absolute passive fit cannot be achieved, nor is there concrete evidence that passive fit ensures the long term prognosis of the implants and restoration (Sahin & Cehreli, 2001). It is, however, reasonable to expect fewer mechanical complications, such as screw loosening and porcelain fracture, when the components fit more accurately. The concept of clinically acceptable fit incorporates the goal of minimizing both biologic complications and mechanical complications. Clinically acceptable fit in combination with control over the occlusal forces is a practical approach to ensuring success of the implants and the restoration.

Framework fit can be assessed by a variety of methods. Clinical methods for assessing framework fit include finger pressure, visual inspection, radiographs, tactile sensation, Sheffield test, disclosing materials, and the screw resistance test (Abduo et al., 2010). Each method has both advantages, disadvantages, and relative accuracy. In general, the intra-oral methods such as visual inspection, finger pressure, and disclosing agents are of limited value with subgingival margins. The screw resistance test (Jorneus et al., 1992) is based on the thread pitch of the original gold prosthetic screws, thus has limited application to newer systems and alloys. The Sheffield test, also known as the single screw test, combined with radiographic evaluation, is an efficient technique, especially for long span frameworks. If a single screw placed in a distal abutment does not create a vertical gap on the opposite end of the framework, the framework is said to have clinically acceptable fit.

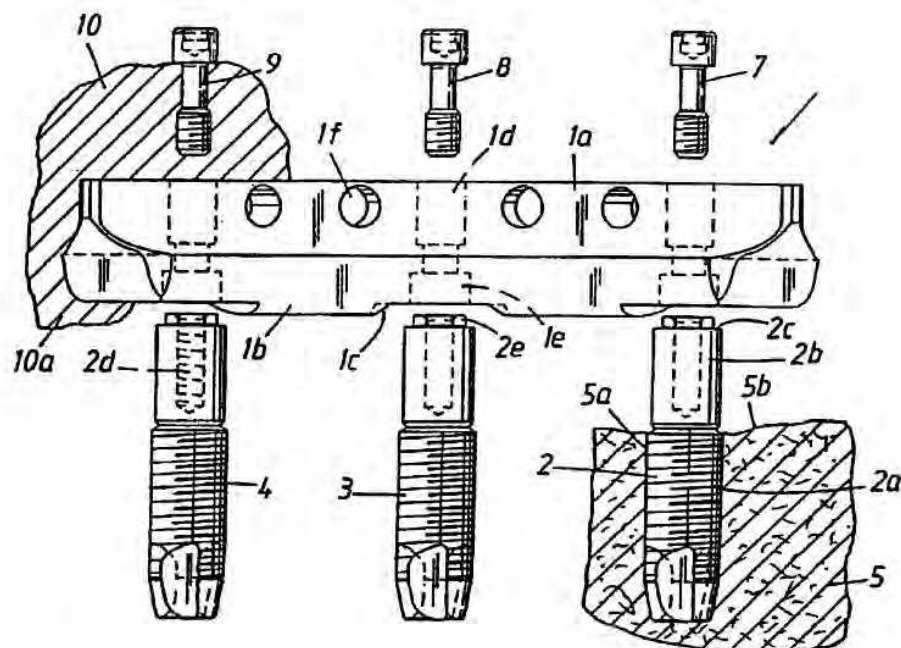


Fig. 15. Illustration of Branemark's original design for restoration of the completely edentulous mandible. (1) Cast gold framework. (2b) Standard Abutment. (2d) Abutment screw. (4) Implant fixture. (9) Prosthetic Screw. (10) Acrylic teeth and gingiva.

Multiple *in vitro* methods to assess framework fit can be utilized to compare the relative accuracy of various methods of fabrication. *In vitro* methods include photoelastic, strain gauge analysis, finite element analysis, microscopic, photogrammetric, and coordinate measuring machine (Abduo et al., 2010). These methods can be qualitative, quantitative, 2-dimensional or 3-dimensional. For example, strain gauge analysis is both quantitative and 2-dimensional, yet depends on the location of the strain gauge, and the ability of the material to mimic natural tissues. At this time, none of the available methods for assessing accuracy of fit have been validated with clinically relevant parameters.

3.4 CAD/CAM Framework and bar fabrication

CAD/CAM applications have surged in the market over recent years. There are now multiple commercial sources that can produce purely CAD/CAM bars and frameworks, or copy-milled CAM structures for implant prostheses. Procera from Nobel Biocare, CAMStructure from Biomet 3i, and Vericore from Whip Mix are just a few examples. Most companies offer stock designs such as a Dolder bar or Hader bar that can be masked on a virtual master cast of the implant analogs and soft tissue contour. The stock design is then contoured to the arch form, and modifications can be made to idealize the bar design. A second scan of the wax denture can be overlaid in order to allocate adequate space for attachments and adequate thickness of the resin denture base. For ceramic frameworks, a scan of the full-contour wax-up can be matched to the virtual master cast, and a virtual cutback can be performed to allow adequate thickness for veneering porcelain. By using CAD/CAM frameworks, fixed partial (Figures 16-24) or full-arch (Figures 25-38) dental prostheses can be fabricated.

For more complicated designs, a resin pattern of the desired framework can be scanned and the structure can be CAMed via a process known as copy-milling. Zirkon Zahn, for example,

utilizes an optical scanner with computerized 5-axis copy-milling technology that allows fabrication of highly detailed zirconia frameworks.




Fig. 16. Procera copy-milled titanium framework from Nobel Biocare.

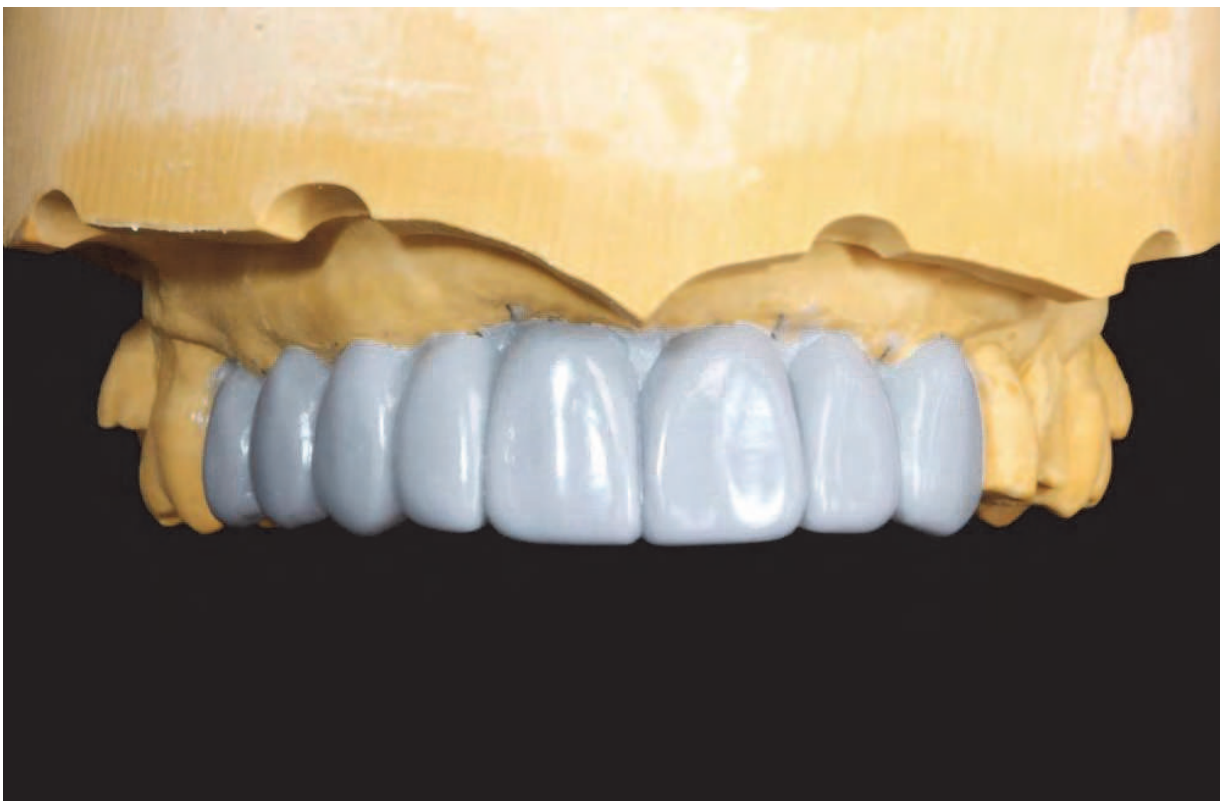

Fig. 17. Diagnostic wax-up for planning implant placement, prosthetic design, and space allocation.

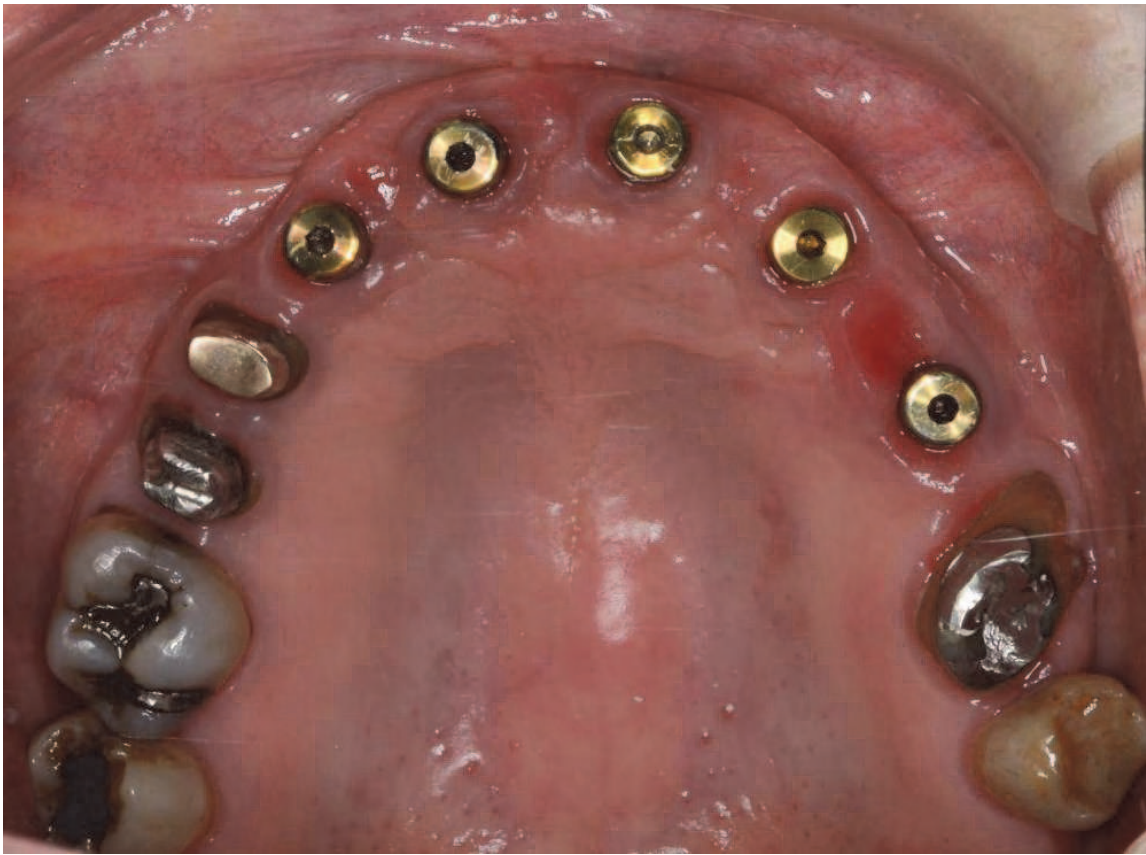

Fig. 18. Occlusal view of implants with healing abutments and tooth preparations.

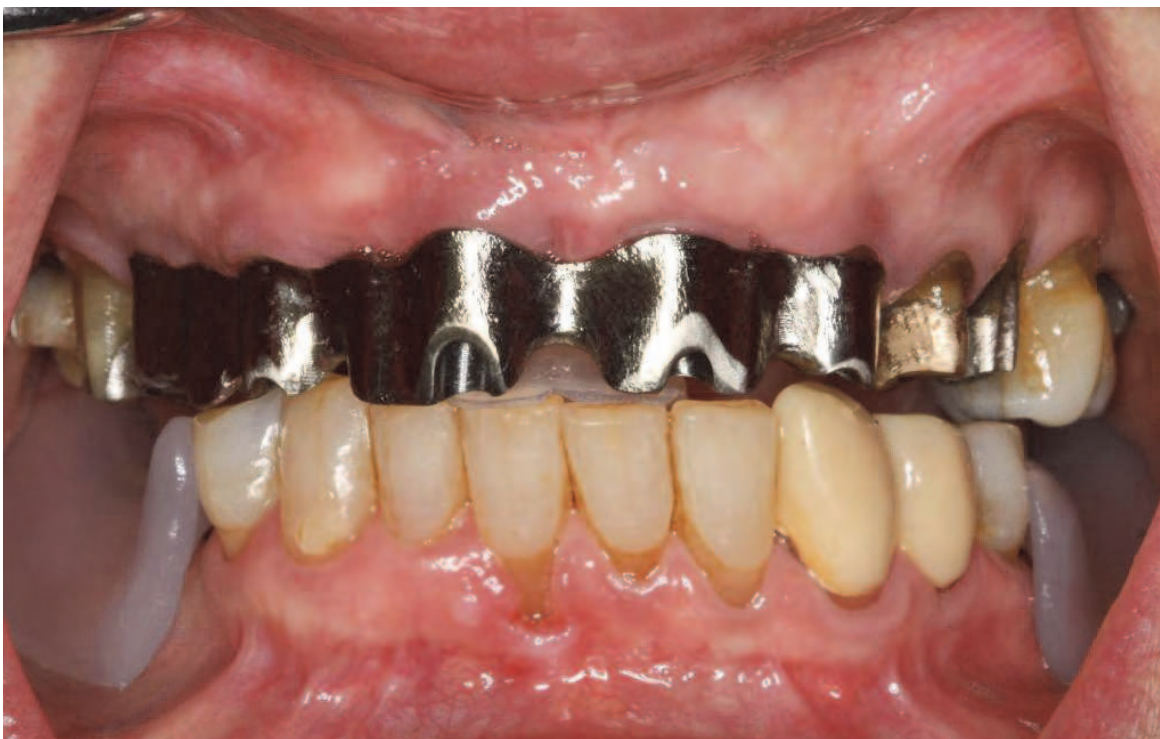

Fig. 19. Nobel Procera copy-milled titanium framework at time of try-in and making inter-occlusal records.

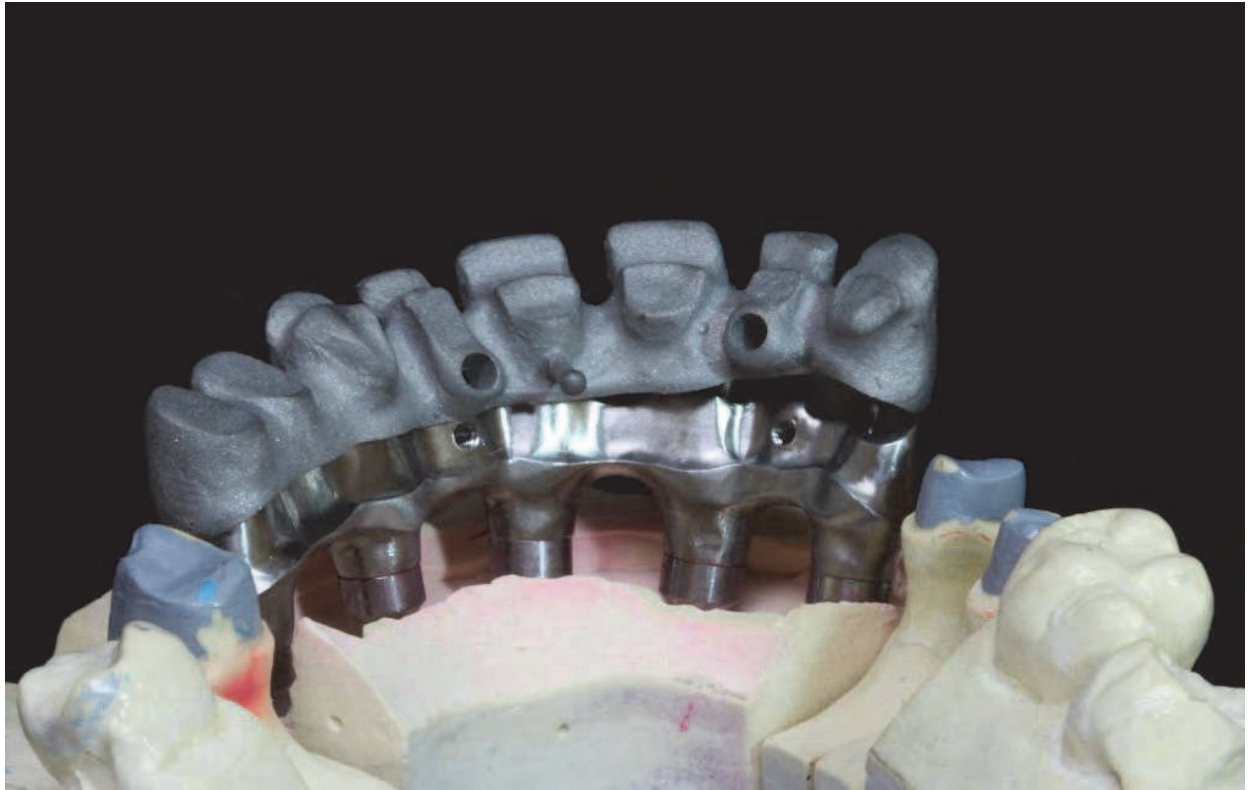


Fig. 20. Procera titanium framework with cast high-noble superstructure.

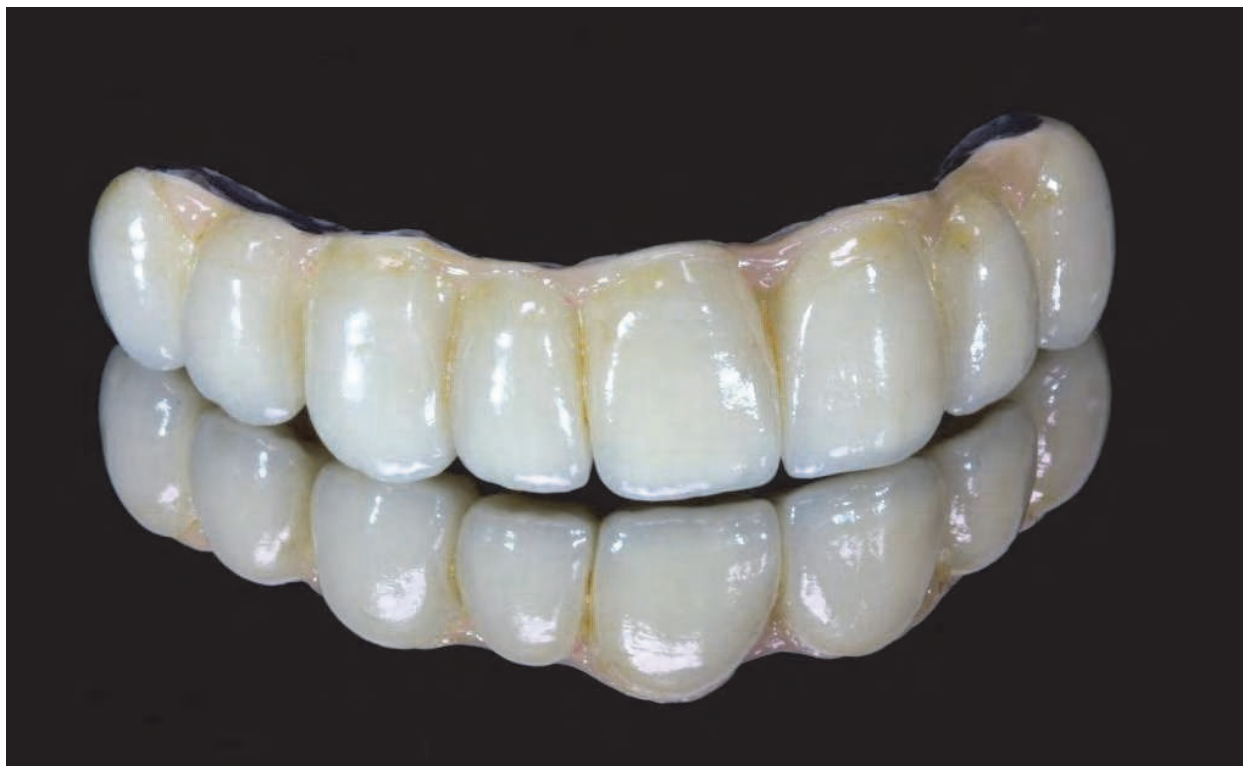

Fig. 21. Cast high-noble superstructure after porcelain application and firing.

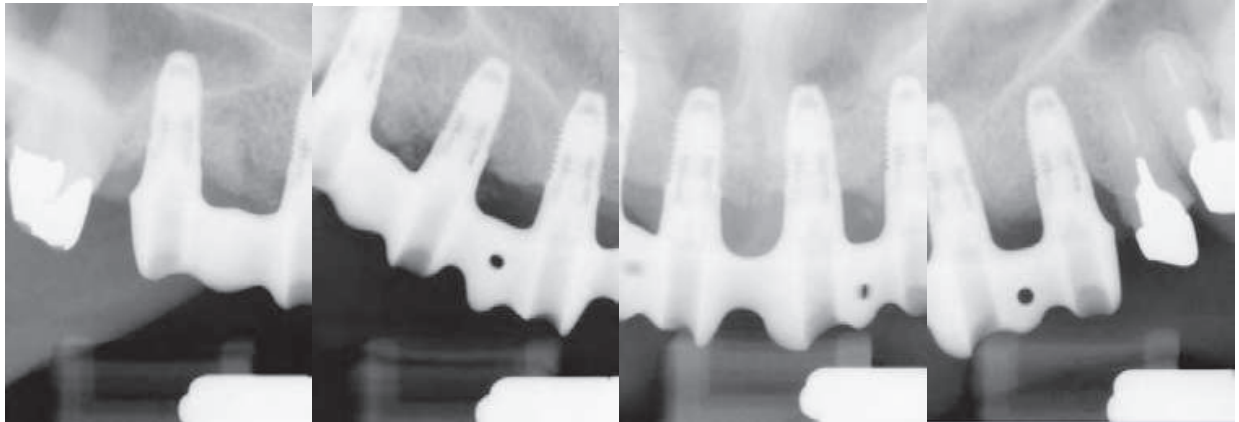


Fig. 22. Radiographic verification of framework fit prior to placement of superstructure.

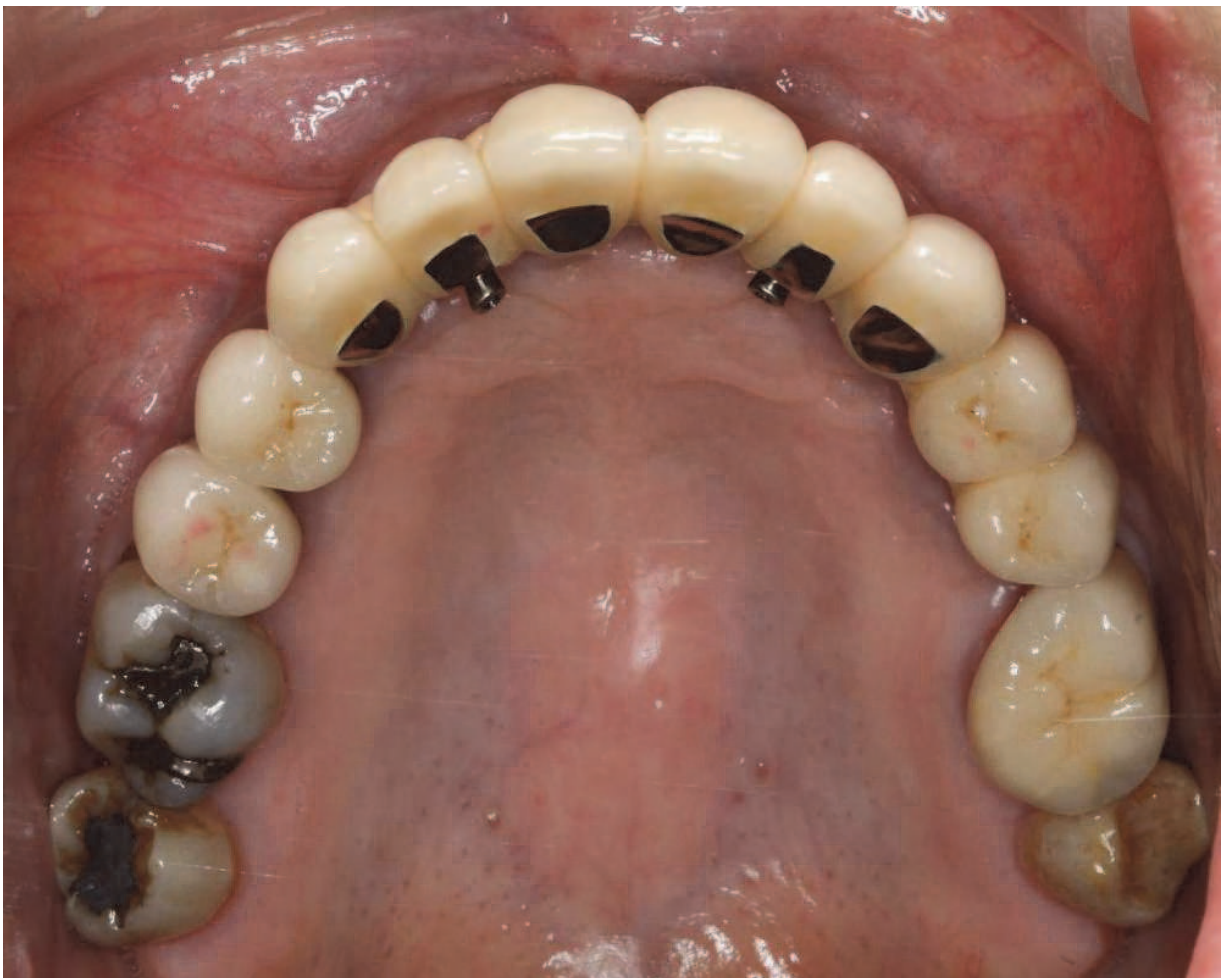

Fig. 23. Occlusal view of lingual set screws retaining metal-ceramic superstructure to CAM framework.

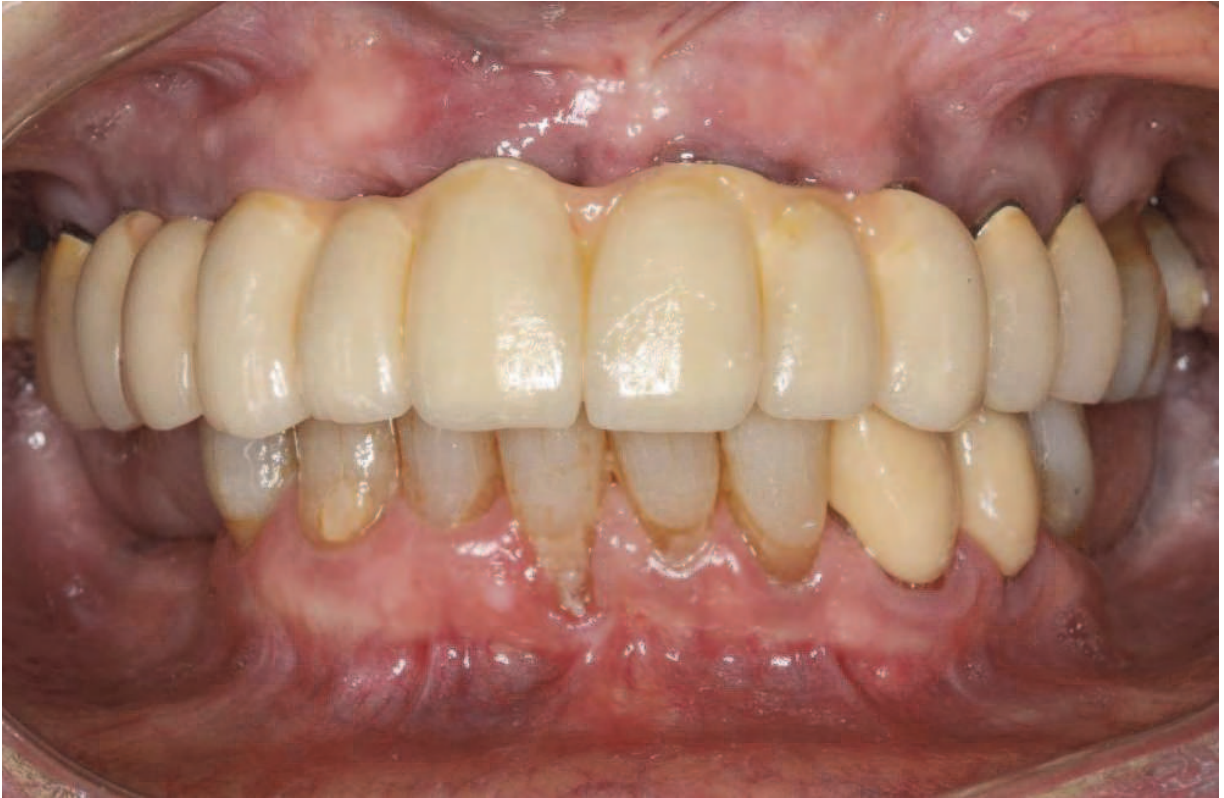

Fig. 24. Frontal view of completed prosthesis.

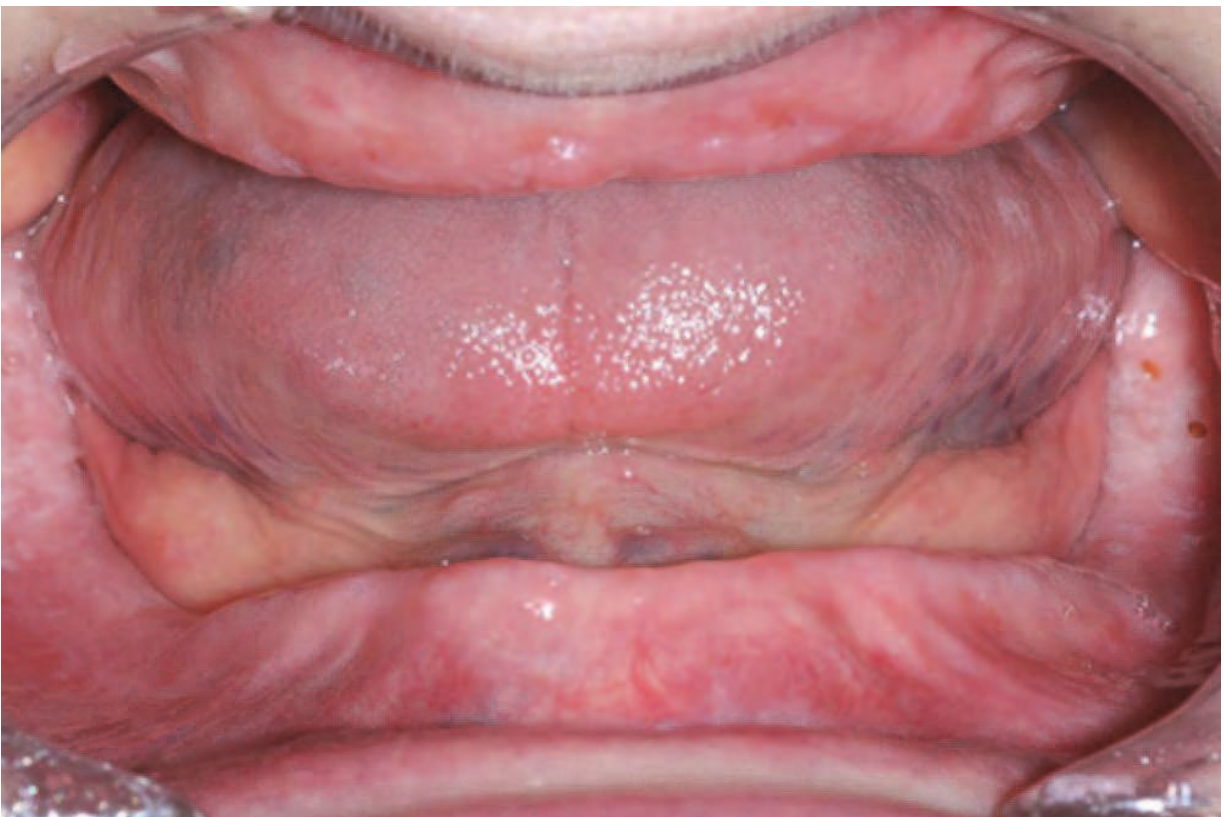

Fig. 25. Intra-oral view of an edentulous patient.

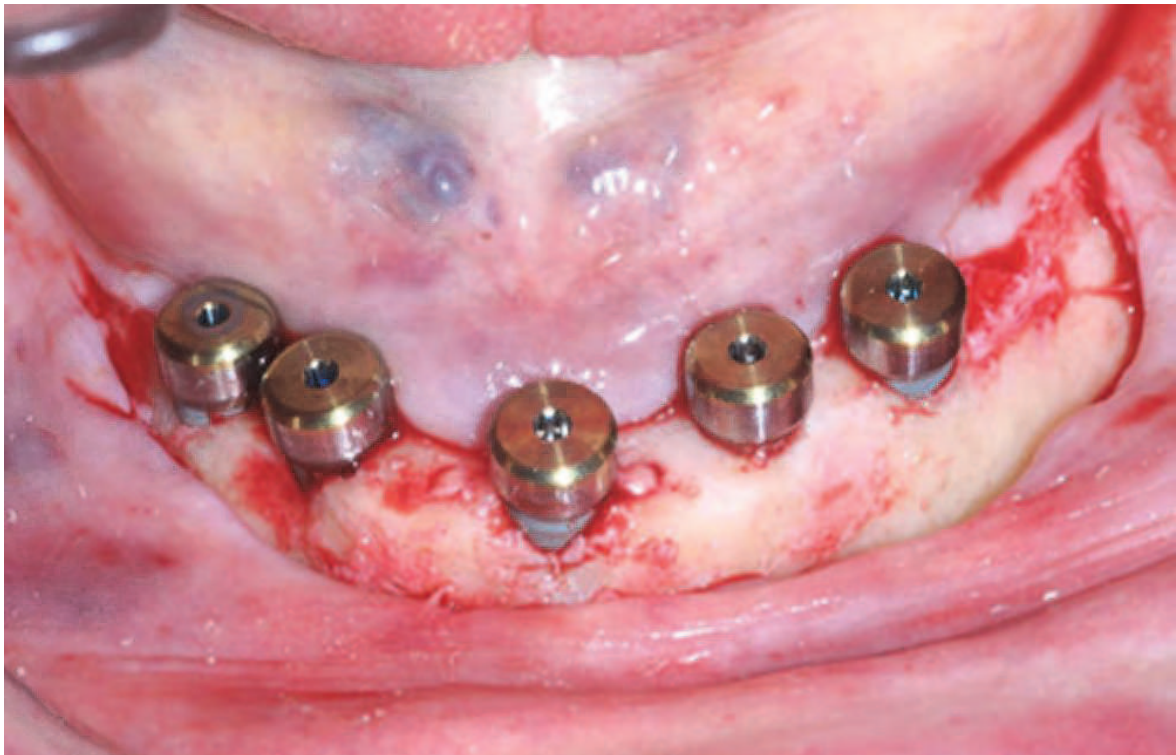


Fig. 26. Clinical view of the five healing abutments on the implants seated immediately after the implant placement.

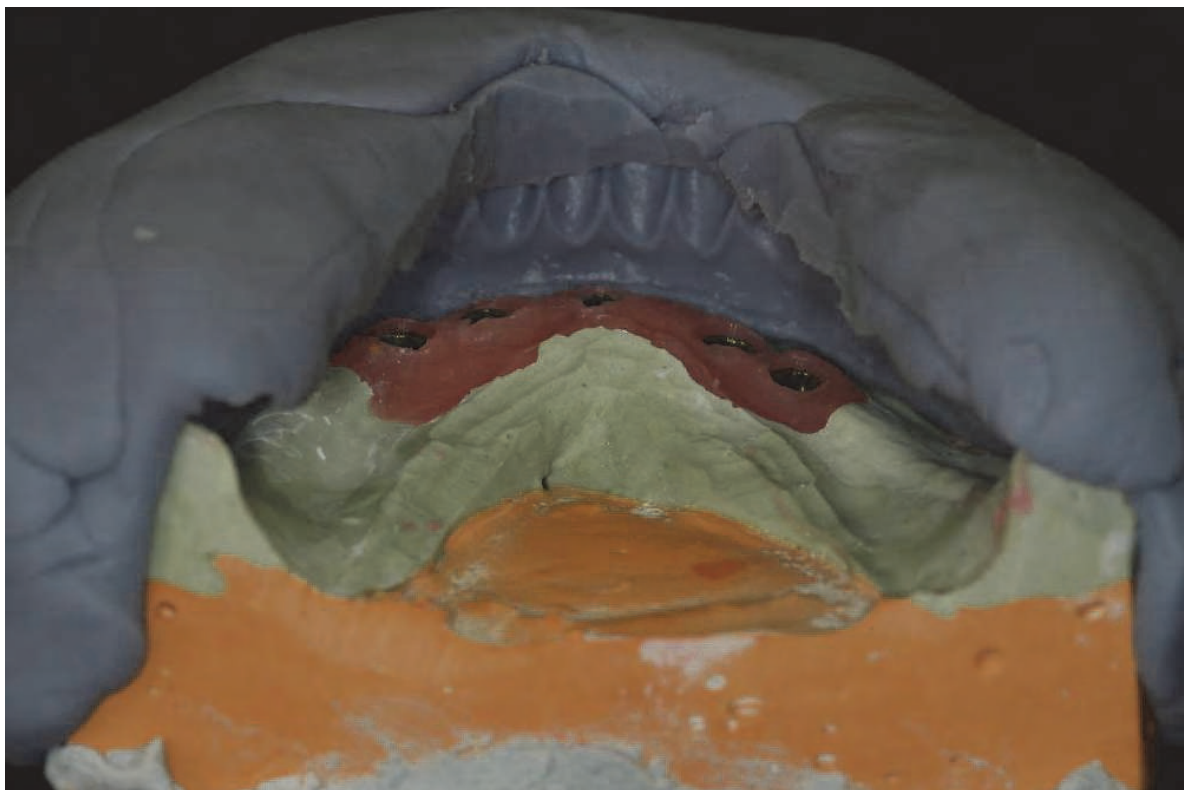


Fig. 27. The lingual view of the mandibular definitive cast with the tooth index, showing the room for the framework.

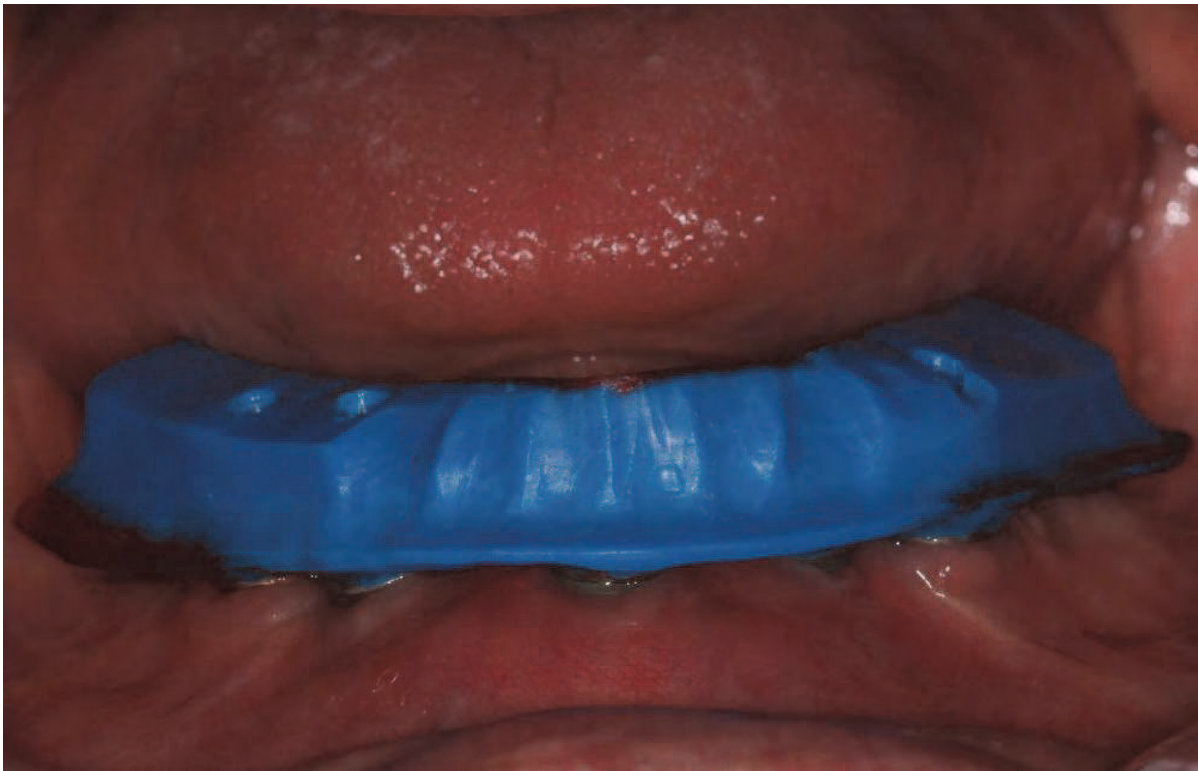


Fig. 28. The fit of the mandibular wax pattern was verified clinically.



Fig. 29. The scanning process of the implant replicas on the mandibular definitive cast in order to determine the position of the implant platforms using NobelProcera scanner.




Fig. 30. The scanning process of the implant replicas in the mandibular wax pattern in order to determine the position of the implant platforms using NobelProcera scanner.




Fig. 31. The scanning process of the gingival surface of the mandibular wax pattern using NobelProcera scanner.




Fig. 32. The scanning process of the occlusal surface of the mandibular wax pattern using NobelProcera scanner.

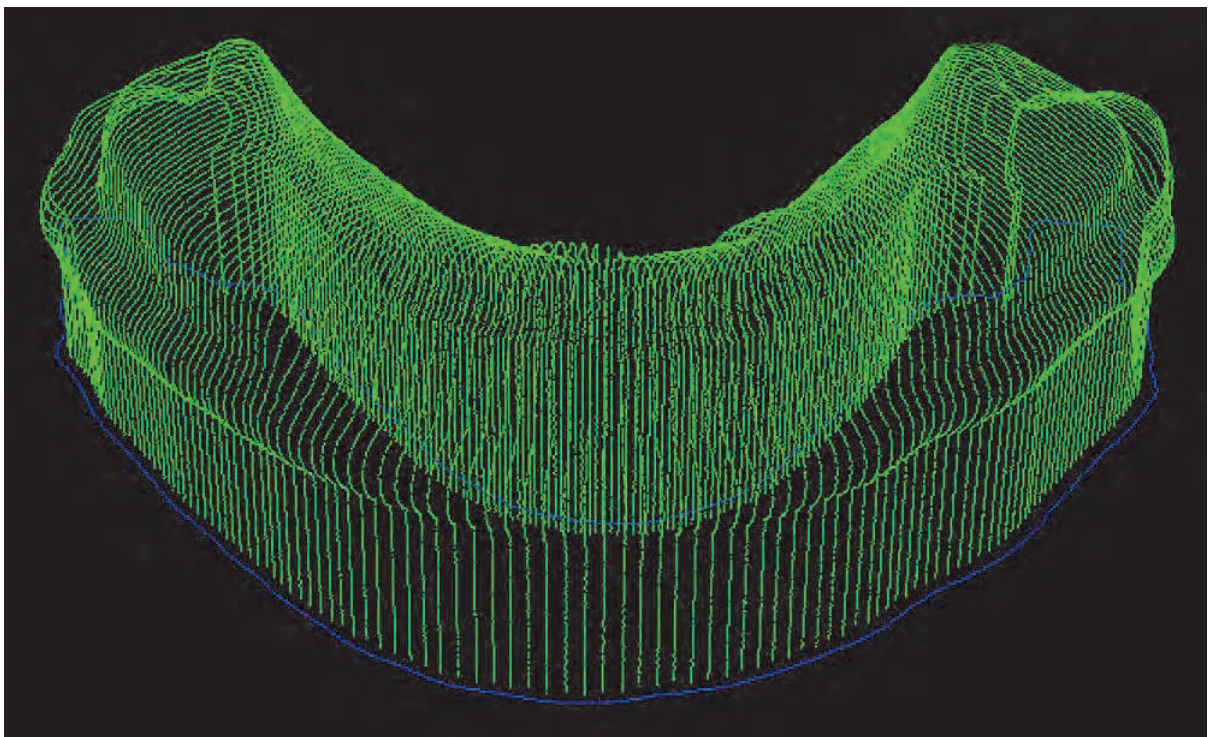


Fig. 33. The design of the occlusal surface of the mandibular framework using NobelProcera scanner.



Fig. 34. The final design of the mandibular framework using NobelProcera scanner.

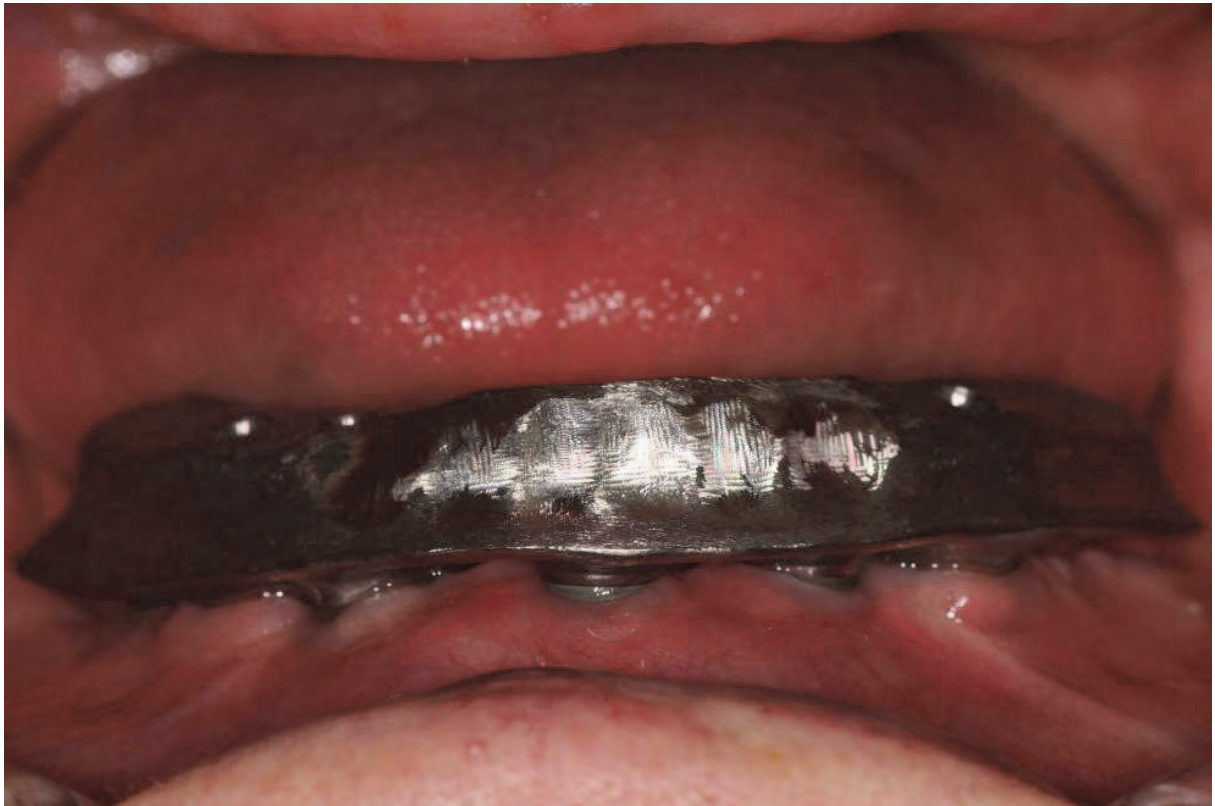

Fig. 35. Clinical fit of the final mandibular framework fabricated was verified.

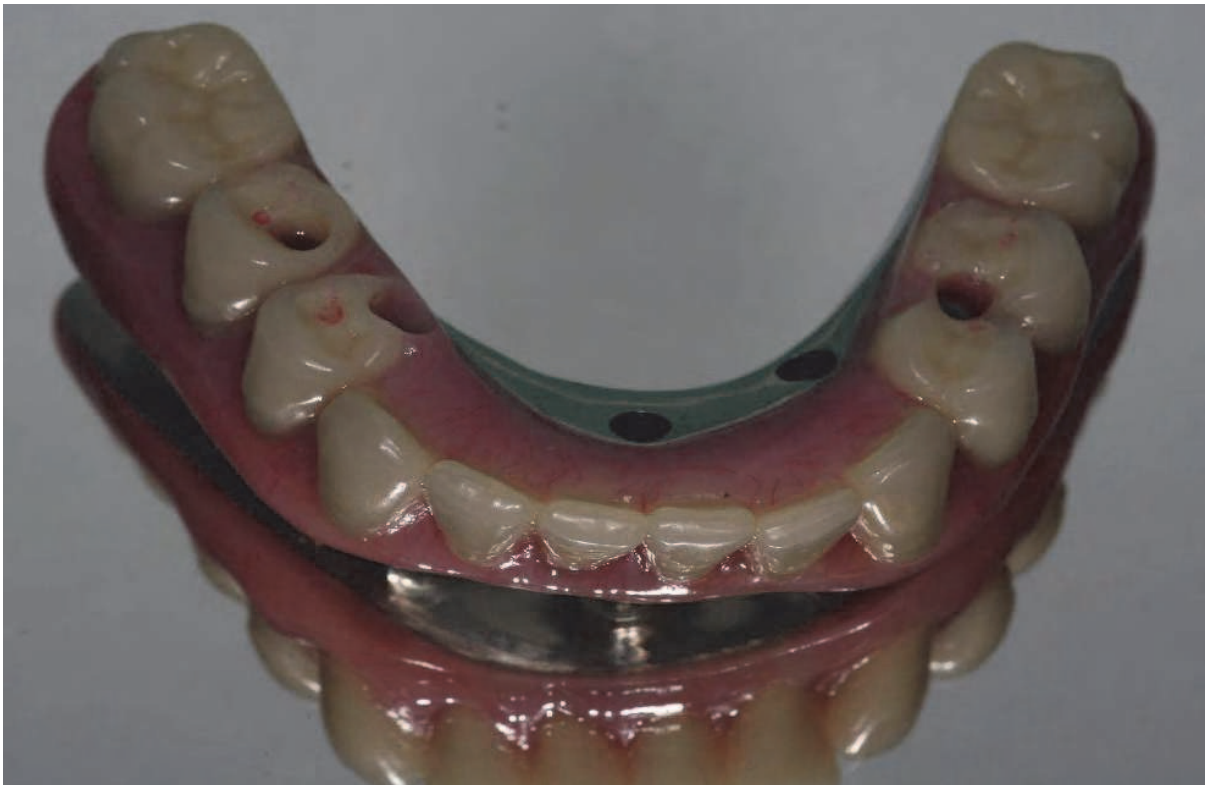

Fig. 36. The implant-supported screw-retained fixed dental prosthesis after processed.

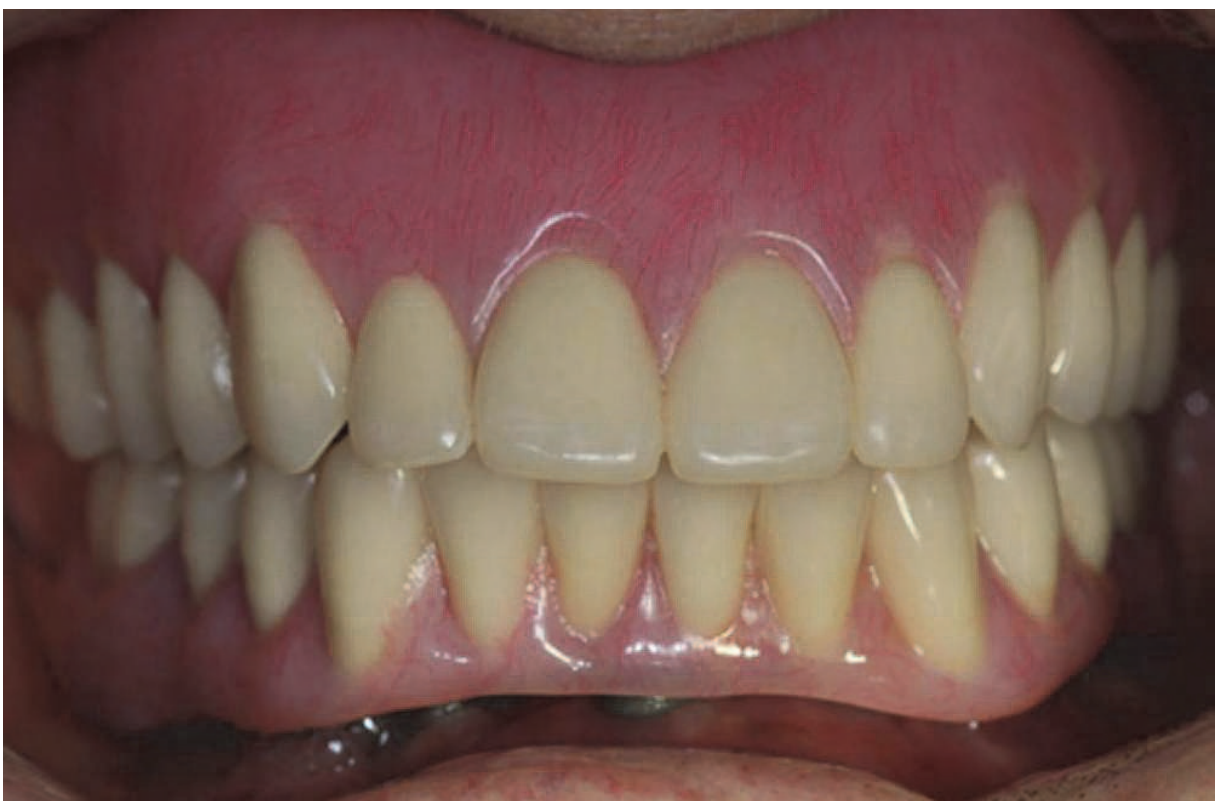

Fig. 37. Clinical view of both maxillary complete denture and mandibular implant-supported screw-retained fixed dental prosthesis.

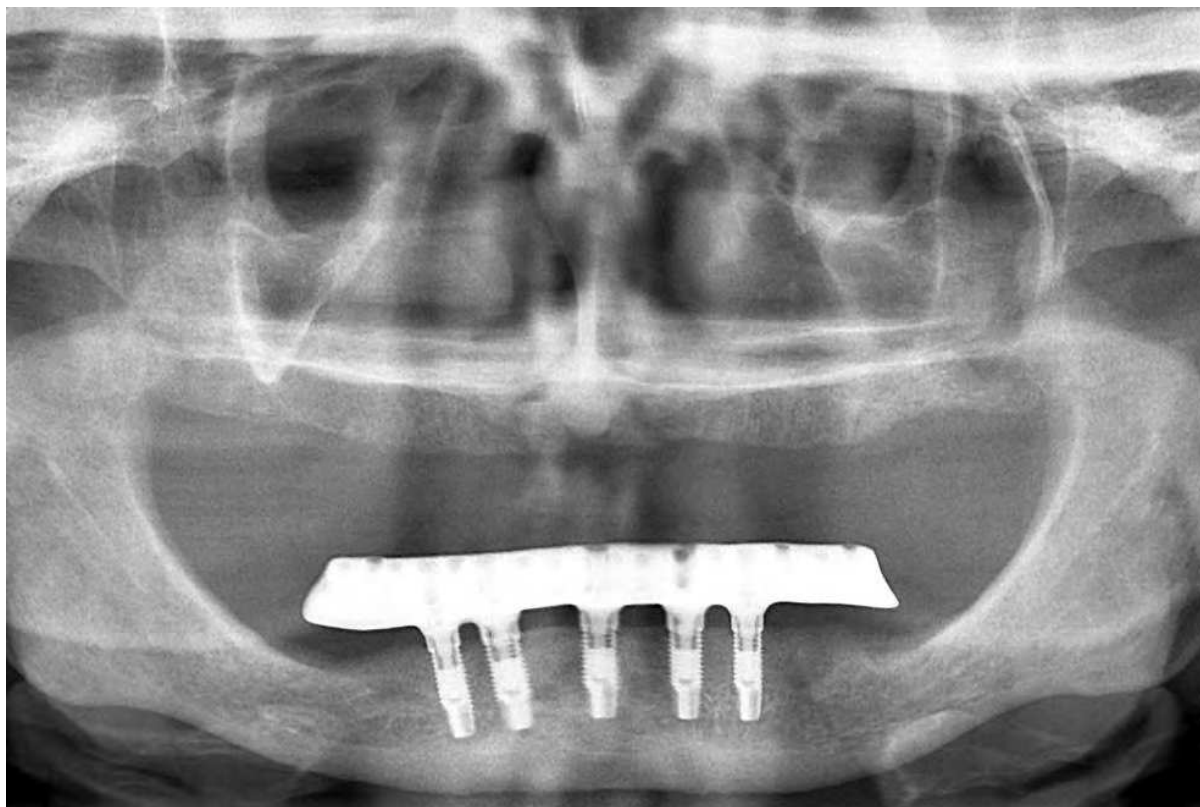


Fig. 38. Panoramic radiograph of the patient a year after the implant placement.

3.5 Comparison of fabrication techniques

An abundance of literature supports the improved accuracy of CAD/CAM over traditional casting, even when corrective procedures are included. A recent publication by Drago et al. (2010), evaluated volumetric misfit of CAM and cast 5-implant frameworks fabricated in three different laboratories. Thirty implant level impressions with verified implant indices were made from one master cast with five intra-foraminal mandibular implants. Fifteen verified master casts were scanned and CAD/CAM frameworks were fabricated. Another fifteen verified master casts served as the base for attachment of UCLA abutments and resin pattern fabrication for casting procedures. A volumetric analysis of fit based on single screw test and “best fit” of individual frameworks to respective master cast revealed that the CAD/CAM frameworks were significantly more accurate than the cast frameworks.

An earlier study by Riedy et al. (1997), showed similar results when comparing one piece cast frameworks to Procera CAD/CAM frameworks. They also found that sectioning and laser welding cast frameworks significantly improved the overall fit. These results are consistent with other studies comparing conventional casting to CAD/CAM techniques (Al-Fadda et al., 2007). Given the significant improvement of fit and decrease in laboratory time, CAD/CAM bars and frameworks, particularly for overdentures and hybrids, will soon be the standard.

4. Conclusion

CAD/CAM technology has revolutionized the field of implant dentistry. CAD/CAM surgical guides have greatly improved the predictability of implant surgery. CAD/CAM

bars and framework have proven more accurate, less expensive, and less time-consuming to produce. All of this results in improved experience for the patient, decreased treatment time, and greater accessibility.

The future of dentistry is quickly approaching. Digital impression systems and CAMed models for tooth born restorations are rapidly expanding in the market. Virtual tooth libraries allow CAD/CAM of both provisional and final tooth-born restorations. Numerous implant companies have already designed abutments for compatibility with digital impression systems. Just on the horizon is virtual articulation and virtual tooth arrangement, thus completing the virtual realm of dental technology. It is clear that CAD/CAM technology has transformed all aspects of dentistry, not just implant dentistry.


5. References

- Abduo, J., Bennani, V., Waddell, N., Lyons, K., Swain, M. (2010). Assessing the Fit of Implant Fixed Prostheses: A Critical Review. *Int J Oral Maxillofac Implants*, Vol. 25, No.3, pp.506-515.
- Albrektsson, T., Zarb, G., Worthington, P., Eriksson. AR. (1986). The long-term efficacy of currently used dental implants: a review and proposed criteria of success. *Int J Oral Maxillofac Implants*, Vol. 1, No. 1, pp:11-25
- Al-Fadda, SA., Zarb, GA., Finer, Y. (2007). A comparison of the accuracy of fit of 2 methods for fabricating implant-prosthetic frameworks. *Int J Prosthodont*, Vol. 20, No.2, pp.125-131.
- Allen, PF., McMillan, AS. (2003). A longitudinal study of quality of life outcomes in older adults requesting implant prostheses and complete removable dentures. *Clin Oral Impl Res*, Vol. 14, No. 2 , pp.173-179.
- Arisan, V., Karabuda, ZC., Ozdemir, T. (2010). Accuracy of two stereolithographic guide systems for computer-aided implant placement: a computed tomography-based clinical comparative study. *J Periodontol*, Vol. 81, No. 1, pp.43-51.
- Awad, MA., Lund, JP., Dufresne, E., Feine, JS. (2003). Comparing the efficacy of mandibular implant-retained overdentures and conventional dentures among middle-aged edentulous patients: satisfaction and functional assessment. *Int J Prosthodont*, Vol.16, No.2, pp.117-122.
- Besimo, CE., Rohner, HP. (2005). Three-dimensional treatment planning for prosthetic rehabilitation. *Int J Periodontics Restorative Dent.*, Vol. 25, No. 1, pp.81-87.
- Brånemark. PI., Albrektsson, T. (1982). Titanium implants permanently penetrating human skin. *Scand J Plast Reconstr Surg*, Vol. 16, No.1, pp:17-21.
- Christensen, GJ. (2005). Dental Laboratory Technology in Crisis: The Challenges Facing the Industry. *J Am Dent Assoc*, Vol. 136, No. 5, pp.653-655.
- Drago, C., Saldarriaga, RL., Domagala, D., Almasri, R. (2010). Volumetric determination of the amount of misfit in CAD/CAM and cast implant frameworks: a multicenter laboratory study. *Int J Oral Maxillofac Implants*, Vol. 25, No.5, pp.920-929.
- Ersoy, AE., Turkyilmaz, I., Ozan, O., McGlumphy, EA. (2008). Reliability of Implant Placement with Stereolithographic Surgical Guides Generated From Computed Tomography: Clinical Data From 94 Implants. *J Periodontol*, Vol.79, No. 8, pp.1339-1345.

- Fortin, T., Bosson, J.L., Isidori, M., Blanchet, E. (2006). Effect of flapless surgery on pain experienced in implant placement using an image-guided system. *Int J Oral Maxillofac Implants*, Vol. 21, No. 2, pp.298-304.
- Friberg, B., Jemt, T. (2010). Clinical experience of TiUnite implants: a 5-year cross-sectional, retrospective follow-up study. *Clin Implant Dent Relat Res*, Vol.12, No. Suppl 1, pp.e95-103.
- Heydecke, G., Thomason, J.M., Lund, J.P. (2005). The impact of conventional and implant supported prostheses on social and sexual activities in edentulous adults: Results from a randomized trial 2 months after treatment. *J Dent*, Vol. 33, No.8, pp. 649-657.
- Jacobs, P. (1992) *Rapid Prototyping and Manufacturing: Fundamentals of Stereolithography*. Vol. 1., Dearborn, MI: Society of Manufacturing Engineers. 434.
- Jorneus, L., Jemt, T., Carlsson, L. (1992). Loads and designs of screw joints for single crowns supported by osseointegrated implants. *Int J Oral Maxillofac Implants*, Vol. 7, No.3, pp.353-359.
- Kapur, K.K., Soman S. (1965) The effect of denture factors on masticatory performance. IV. Influence of occlusal patterns. *J Prosthet Dent*, Vol.15, pp.662-670
- Mandelaris, G.A., Rosenfeld, A.L., King, S.D., Nevins, M.L. (2010). Computer-guided implant dentistry for precise implant placement: combining specialized stereolithographically generated drilling guides and surgical implant instrumentation. *Int J Periodontics Restorative Dent* Vol. 30, No. 3, pp.275-281.
- Misch, C.E., Goodacre, C.J., Finley, J.M., Misch, C.M., Marinbach, M., Dabrowsky, T., English, C.E., Kois, J.C., Cronin, R.J. (2005). Consensus Conference Panel Report: Crown-Height Space Guidelines for Implant Dentistry--Part I. *Implant Dent*, Vol. 14, No.4, pp.312-318.
- Misch, C.E., Perel, M.L., Wang, H.L., Sammartino, G., et. al. (2008). Implant Success, Survival, and Failure: The International Congress of Oral Implantologists (ICOI) Pisa Consensus Conference. *Implant Dent*, Vol.17, No.1, pp.5-15.
- Ortorp, A., Jemt, T. (2000). Clinical experiences of CNC-milled titanium frameworks supported by implants in the edentulous jaw: 1-year prospective study. *Clin Implant Dent Relat Res*. Vol. 2, No.1, pp.2-9.
- Ozan, O., Turkyilmaz, I., Ersoy, A.E., McGlumphy, E.A., Rosenstiel, S.F. (2009). Clinical accuracy of 3 different types of computed tomography-derived stereolithographic surgical guides in implant placement. *J Oral Maxillofac Surg*, Vol. 67, No. 2, pp.394-401.
- Pommer, B., Zechner, W., Watzak, G., Ulm, C., Watzek, G., Tepper, G. (2011). Progress and trends in patient's mindset on dental implants. I: level of information, sources of information and need for patient information. *Clin Oral Impl Res*, Vol.22, No.2, pp.223-229.
- Riedy, S.J., Lang, B.R., Lang, B.E. (1997). Fit of Implant Frameworks Fabricated by Different Techniques. *J Prosthet Dent*, Vol. 78, No. 6, pp.596-604.
- Sahin, S., Cehreli, M. (2001). The Significance of Passive Framework Fit in Implant Prosthodontics: Current Status. *Implant Dent*, Vol. 10, No.2, pp.85-92.
- Sarment, D.P., Sukovic, P., Clinthorne, N. (2003). Accuracy of Implant Placement with a Stereolithographic Surgical Guide. *Int J Oral Maxillofac Implants*, Vol. 18, No. 4, pp.571-577.

- Takahashi, T., Gunne, J. (2003). Fit of implant frameworks: an in vitro comparison between two fabrication techniques. *J Prosthet Dent*, Vol. 89, No.3 ,pp.256-260.
- Tardieu, P., Vrielinck, I., Escolano, E. (2003). Computer-assisted implant placement. A case report: Treatment of the mandible. *Int J Oral Maxillofac Implants*, Vol. 18, No. 4, pp.599-604.
- Turkyilmaz, I., Aksoy, U., McGlumphy, EA. (2008). Two alternative surgical techniques for enhancing primary implant stability in the posterior maxilla: a clinical study including bone density, insertion torque, and resonance frequency analysis data. *Clin Implant Dent Relat Res*, Vol.10, No.4, pp.231-237.
- Turkyilmaz, I., Company AM., McGlumphy EA. (2010). Should edentulous patients be constrained to removable complete dentures? The use of dental implants to improve the quality of life for edentulous patients. *Gerodontology*, Vol.27, No.1, pp.3-10.
- Valente, F., Schiroli, G., Sbrenna, A. (2009). Accuracy of computer-aided oral implant surgery: a clinical and radiographic study. *Int J Oral Maxillofac Implants*, Vol.24, No.2, pp.234-242.
- Van Assche, N., van Steenberghe, D., Quirynen, M., Jacobs, R. (2010). Accuracy assessment of computer-assisted flapless implant placement in partial edentulism. *J Clin Periodontol*, Vol.37, No.4, pp.398-403.
- Walter, M., Reppel, PD., Boning, K., Freesmeyer, WB. (1999). Six-year follow-up of titanium and high-gold porcelain fused-to-metal fixed partial dentures. *Journal of Oral Rehabil*, Vol. 26, No.2, pp.91-96.
- Weintraub, JA., Burt, BA. (1985). Oral health status in the United States: tooth loss and edentulism. *J Dent Educ*, Vol.49, No.6, pp.368-378.

IntechOpen



Implant Dentistry - A Rapidly Evolving Practice

Edited by Prof. Ilser Turkyilmaz

ISBN 978-953-307-658-4

Hard cover, 544 pages

Publisher InTech

Published online 29, August, 2011

Published in print edition August, 2011

Implant dentistry has come a long way since Dr. Branemark introduced the osseointegration concept with endosseous implants. The use of dental implants has increased exponentially in the last three decades. As implant treatment became more predictable, the benefits of therapy became evident. The demand for dental implants has fueled a rapid expansion of the market. Presently, general dentists and a variety of specialists offer implants as a solution to partial and complete edentulism. Implant dentistry continues to evolve and expand with the development of new surgical and prosthodontic techniques. The aim of *Implant Dentistry - A Rapidly Evolving Practice*, is to provide a contemporary clinic resource for dentists who want to replace missing teeth with dental implants. It is a text that relates one chapter to every other chapter and integrates common threads among science, clinical experience and future concepts. This book consists of 23 chapters divided into five sections. We believe that, *Implant Dentistry: A Rapidly Evolving Practice*, will be a valuable source for dental students, post-graduate residents, general dentists and specialists who want to know more about dental implants.

How to reference

In order to correctly reference this scholarly work, feel free to copy and paste the following:

Ilser Turkyilmaz and Roxanna J. Nicoll (2011). State-of-the-Art Technology in Implant Dentistry: CAD/CAM, *Implant Dentistry - A Rapidly Evolving Practice*, Prof. Ilser Turkyilmaz (Ed.), ISBN: 978-953-307-658-4, InTech, Available from: <http://www.intechopen.com/books/implant-dentistry-a-rapidly-evolving-practice/state-of-the-art-technology-in-implant-dentistry-cad-cam>

INTech
open science | open minds

InTech Europe

University Campus STeP Ri
Slavka Krautzeka 83/A
51000 Rijeka, Croatia
Phone: +385 (51) 770 447
Fax: +385 (51) 686 166
www.intechopen.com

InTech China

Unit 405, Office Block, Hotel Equatorial Shanghai
No.65, Yan An Road (West), Shanghai, 200040, China
中国上海市延安西路65号上海国际贵都大饭店办公楼405单元
Phone: +86-21-62489820
Fax: +86-21-62489821

© 2011 The Author(s). Licensee IntechOpen. This chapter is distributed under the terms of the [Creative Commons Attribution-NonCommercial-ShareAlike-3.0 License](https://creativecommons.org/licenses/by-nc-sa/3.0/), which permits use, distribution and reproduction for non-commercial purposes, provided the original is properly cited and derivative works building on this content are distributed under the same license.

IntechOpen

IntechOpen