

We are IntechOpen, the world's leading publisher of Open Access books Built by scientists, for scientists

6,900

Open access books available

186,000

International authors and editors

200M

Downloads

Our authors are among the

154

Countries delivered to

TOP 1%

most cited scientists

12.2%

Contributors from top 500 universities



WEB OF SCIENCE™

Selection of our books indexed in the Book Citation Index
in Web of Science™ Core Collection (BKCI)

Interested in publishing with us?
Contact book.department@intechopen.com

Numbers displayed above are based on latest data collected.
For more information visit www.intechopen.com



Oral Territorial Neurovascular Considerations in Implant Surgery

Umit Karacayli¹ and Nuket Mas²

¹*Department of Oral and Maxillofacial Surgery,
Gulhane School of Medicine, Ankara*

²*Department of Anatomy, Faculty of Medicine,
Afyon Kocatepe University, Afyonkarahisar
Turkey*

1. Introduction

The anatomy of the intrabony course of the inferior alveolar nerve (IAN) is very important for dentists, neurologist, radiologists and pathologists to aid in diagnosis, treatment, planning surgery, and the application of local anesthesia (Polland et al., 2001).

IAN damage negatively affects the quality of facial sensibility and the patient's ability to translate patterns of altered nerve activity into functionally meaningful motor behaviors. The sensory alteration can be attributed to anatomical or functional changes within the nerve after resolution of inflammation and edema in and surrounding the nerve (Essick, 2004; Becerra et al., 2006).

Standardization of assessment methods would facilitate the identification of diagnostic criteria for different types of neurosensory impairment. Assessment of sensory changes can be evaluated using three types of measures: (i) objective electrophysiological measures of nerve conduction, (ii) sensory testing measures and (iii) patient report (Takazakura et al., 2007).

The request of replacing missing teeth with dental implants is increasing, and as a result, incidence of postoperative complications is increasing concomitantly (Kim et al., 2009). When the height of bone between alveolar crest and inferior alveolar canal is insufficient, implant placement in the posterior mandible is limited. One of the most difficult surgical challenges to the implant surgery is severe resorption of the posterior mandible processes (Ardekian et al., 2001). Understanding of the intrabony distribution of the IAN is important in the accurate preoperative planning for the placement of mandibular implants (Kieser et al., 2002). There are several treatment options for patients with inadequate bone height superior to the inferior alveolar canal. There are lots of alternative reconstruction methods of atrophic dental arch: use of autogenous bone grafting, allografts, xenogenic, or alloplastic materials with or without guided bone regeneration, distraction osteogenesis, IAN lateralization (McAllister & Haghighat 2007; Hashemi 2010). Placing the implants to the buccal side of the IAN or lateralization of it are the two of them (Misch & Resnik 2010). An ideal alveolar ridge with adequate bone height and width is essential for a successful dental rehabilitation (McAllister & Haghighat, 2007).

The placement of dental implants to the posterior mandible with severe resorption can cause damage to the IAN. The technique of nerve repositioning has been used to create the

opportunity of insertion dental implants of adequately length in those cases. In cases with atrophic posterior mandibular ridges, the IAN repositioning technique is an acceptable alternative to augmentation procedure prior to dental implants placement (Ardekian et al., 2001).

Patients often desire fixed dental implant restoration of missing posterior teeth in the mandible, defined for the present report as the region posterior to the mental foramen. Placement of implants in the posterior mandible is limited by the height of bone between the alveolar crest and IAN transposition or lateralization is a treatment option for patients with an edentulous posterior mandible with inadequate bone height superior to the IAN (Scarano et al., 2011).

Nevre lateralization carries a risk of epineurial damage or ischemic stretching. Implant compression can cause neuropathy and drill punctures can result in neuroma formation of all types. In some cases it can cause centralized pain syndrome. Two patterns of neuropathy can be seen as a result; hypoaesthesias with impaired sensory function, often seen with phantom pain, and hyperaesthesias with minimal sensory impairment but presence of much-evoked pain phenomena (Gregg, 2000).

Damage to the alveolar nevre is largely due to insufficient information about the location of the mandibular canal and it is one of the most frequent complications. Such damage can also occur in the absence of knowledge about the traveling courses of the IAN, artery, and vein within the mandibular canal (Kim et al., 2009).

Neuropathic pain associated with implant placement is rare in literature. In the implantology literature, complications related to nevre are mentioned as 'sensory disturbances', focusing on the occurrence of paresthesia and dysesthesia, eventually accompanied by transitory pain sensations during bone drilling or implant placement (Hashemi, 2010).

The first published report of IAN replacement for the insertion of dental implants appeared in 1987. In that study, , sensory function of the IAN returned to normal 5 weeks after surgery according to subjective criteria (Jensen & Nock, 1987).

2. Anatomy of the mandibular nerve

The trigeminal nerve, which is the largest cranial nerve, is the sensory supply to the face, greater part of the scalp, the teeth, the nasal and oral cavity, the dura mater, the blood vessels of cerebrum. Additionally it gives the motor supply to the masticator muscles, and the mylohyoid and the anterior belly of digastric muscles. It has three divisions as ophthalmic, maxillary and mandibular nerves. It has been reviewed the functions of the widespread peripheral connections between the facial and trigeminal and facial nerves. The trigeminal nerve arises from the anterior surface of the pons, near its upper margin, as a large sensory and a small motor root, the latter lying ventromedial to former. On entering the pons, the fibers of the sensory root run posteromedially towards the principal sensory nucleus situated at this level before reaching the nucleus about %50 of fibers divide into ascending and descending branches. Fibers from the ophthalmic root lie posterolaterally, those from the mandibular lie posteromedially, and the maxillary fibers lie between them.

In Wallenberg's syndrome, plug of posterior inferior cerebellar branch of cranial the vertebral artery leads to loss of pain and temperature sensation in the ipsilateral half of the face with retention of common sensation. Symptomatic trigeminal neuralgia is caused by a

demonstrable structural lesion other than vascular compression, typically posterior fossa tumors or multiple sclerosis (Standring et al., 2005; Ordas et al., 2011).

Fibers of sensory root are principally axons of cells in the semilunar (trigeminal) ganglion, which occupies a recess in the trigeminal cave of Meckel, in the trigeminal impression near the apex of the petrous part of temporal bone. The ganglion placed on a depth of nearly 5 cm from lateral surface of the head deep to posterior end of the zygomatic arch. Axons of unipolar cells in the trigeminal ganglion divide into central and peripheral branches, the former being grouped to form ophthalmic and maxillary nerves and the sensory part of the mandibular nerve. The central branches composed the fibers of the sensory root (Standring et al., 2005). The motor nucleus of trigeminal nerve contains characteristic large multipolar cells interspersed with smaller multipolar cells. It lies in the superior part of pons medial to the principal sensory nucleus, separated from it by fibers of the trigeminal nerve. The motor nucleus receives fibers from both corticonuclear tracts. It also receives afferents from the sensory nuclei, reticular formation, red nucleus and tectum, the medial longitudinal fasciculus and locus coeruleus.

The detailed anatomy of the trigeminal nerve and its three branches and also their course excited early clinical interest since it was known that dissociated sensory loss could occur in trigeminal region. The superior and smallest trigeminal division is the ophthalmic nerve, which is the first branch of the trigeminal, is wholly sensory. It supplies the eyeball, conjunctiva and lacrimal gland, part of nasal mucosa, skin of nose, eyelids, forehead and part of scalp. It originates from the ventromedial end of trigeminal ganglion. It divides into lachrymal, frontal and nasociliary branches. The maxillary nerve, the intermediate division of the trigeminal, is also wholly sensory. It gives off two large branches to pterygopalatine ganglion, then gives off the branches, which distribute nose, palate and pharynx. It gives off zygomatic and posterior superior alveolar branches nearly outside the orbital periosteum. About halfway between the orbital apex and the orbital rim, the nerve enters the infraorbital canal as the infraorbital nerve.

The mandibular nerve, the third and the largest branch of the trigeminal nerve which supplies the teeth and gums of mandible, the lower lip, the lower part of face and the muscles of mastication, the mucosa of both presulcal parts of tongue and oral cavity, skin of the temporal region, part of the auricle including the external meatus and tympanum. It has a large sensory root, which proceeds from lateral part of trigeminal ganglion to emerge almost at once from the foramen ovale, and a small motor root, which passes under the ganglion to unit with the sensory root just outside the skull. The nerve immediately passes between the tensor veli palatini muscle and the lateral pterygoid. Just beyond this junction a meningeal branch and the nerve to the medial pterygoid leaves the medial side of the nerve, which then divides into a small ventral and large dorsal trunk. As it descends from the foramen ovale, the nerve is about four cm from the surface and little anterior to neck of the mandible. The ventral trunk of the mandibular nerve gives rise to the buccal nerve, which is sensory, and the masseteric, deep temporal and lateral pterygoid nerves, which are all motor. The dorsal and larger mandibular trunk is mainly sensory but receives a few filaments from the motor root to mylohyoid muscle. It divides into auriculotemporal, lingual and inferior alveolar (dental) nerves (Standring et al., 2005).

The topographic anatomic landmarks, course and the surface making of the IAN from the inside of the oral cavity is particularly significant in giving nerve blocks for maxillofacial surgeons. Dentists frequently give anesthesia to the nerve before repairing or removing the premolar or molar teeth of the mandible. The IAN might be damaged during the extraction

of impacted lower third molar tooth. The roots of such teeth are commonly grooved and, very rarely, perforated by the nerve. It is also frequently damaged in fractures of the posterior tooth-bearing part of the mandible (Standring et al., 2005; Snell, 2011). So, it is important to know course of the nerve and its relation to adjacent anatomical landmarks in detailed.

The nerve descends medial to the lateral pterygoid muscle and then, at its lower margin, passes between the sphenomandibular ligament and the mandibular ramus to enter mandibular canal by the mandibular foramen.

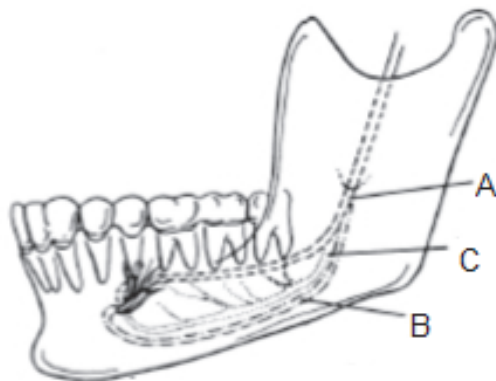


Fig. 1. Classification of the topography of the IAN. (A = the nerve has a course near the apices of the teeth, B = the main trunk is low down in the body, C = the main trunk is low down in the body of the mandible with several smaller trunks to the molar teeth.

Below the lateral pterygoid muscle it is accompanied by the inferior alveolar artery, a branch of maxillary. The artery also enters the canal. In the canal the IAN lies downward and forward, usually below the tip of the teeth until below the first and second premolars, at this point it divides into incisive and mental branches as the terminal branches. It continues forward in the canal or in a plexiform distribution and giving off branches to the first premolar, canine and incisor teeth, and associated labial gingiva. Just before entering the mandibular canal the IAN gives off mylohyoid branch which pierces the sphenomandibular ligament and occurs a shallow groove on the medial surface of the mandible. It passes below the origin of mylohyoid muscle to lie on the surface of the muscle (Standring et al., 2005; Snell, 2011). The mandibular foramen opens into the mandibular canal, which carries the IAN. The mandibular foramen placed on midway between the ventral and dorsal margin of ascending ramus of mandible nearly 1 cm above the occlusal surface of the lower teeth. The small triangular lingula guards the anterior border of the mandibular foramen and provides attachments for the sphenomandibular ligament from which the mandible swings. The mylohyoid groove, immediately inferior to the lingula and lying just inferior to the mylohyoid line, carries the mylohyoid branch of the IAN. The ascending ramus diverges from the sagittal plane from front to back, once the needle engages the medial surface at this level it should be diverted laterally. At a higher level, near the base of coronoid process, the nerve is sufficiently medial to be accessible to a needle in the sagittal plane. With method the buccal and lingual nerves can be blocked (Standring et al., 2005; April, 1990; Snell, 2011). Variations in nerve architecture like these are of importance to clinicians who deal with surgery of the facial skeleton. Morphological changes of mandibular or mental foramen and variations of the nerve have also been described by many authors (Ramadhan et al., 2010;

Prado et al., 2010; Manikandhan et al., 2010; Siéssere et al., 2009; Oktem et al., 2008; Levine et al., 2007).

In many cases there is a single nerve which runs a few millimeters below the roots of teeth, nearly equal number of the nerve lies much lower in the mandible to continue near the lower border of the bone, or sometimes it is plexiform. The nerve can lie on the lingual or buccal side of the mandible (Standring et al., 2005; Snell, 2011). The MN, a branch of the IAN, when emerges through the mental foramen and then divides into three branches that supply the skin of the chin and mucous membrane of the lower lip and gum. Two of them pass upward and forward nearby the mucosal surface of the lower lip. The third one passes through the intermingled fibers of platysma and depressor anguli oris muscles to harvest the skin of the lower lip and chin. As the MN is one of the two terminal branches of the IAN, it is understandable why one's chin and lower lip on the affected side lose sensation, as well. (Standring et al., 2005; Snell, 2011).

Sensory fibers of mandibular nerve and its inferior alveolar branch transmit impulses from the teeth and gums of the lower jaw, skin of the chin and mylohyoid muscle via its mylohyoid branch (Van de Graaff, 1998).

There are numerous congenital anomalous, trauma or cancers of the oral region may affect the IAN throughout its trace. Mandibular fractures through the mandibular canal almost always produce paralysis of inferior alveolar or MNs, as well as numbness of the teeth. Injuries to the inferior alveolar or MNs can also occur during the elevation of skin or mucosal flaps in the region (Cummings et al., 1993). The tumors should be evaluated before surgical procedure or performing anesthesia with regard to size and degree of infiltration and particularly in defining the relationship to the nerve. The trigeminal nerve is the principle nerve relating to the practice of dentistry. Before teeth are filled or extracted, anesthetic is injected near the appropriate nerve to block sensation. A mandibular nerve block desensitized the lower teeth, which was performed by injecting anesthetic near the IAN as it enters the mandible through the mandibular foramen. Important complications may include damage to IAN and its branches during operation or injecting anesthetic. (Paparella et al., 1991; Van de Graaff, 1998).

An entrapment neuropathy is a nerve lesion caused by pressure or mechanical irritation from anatomic structures next to the nerve. This can occur where the nerve passes through a fibro-osseous canal or foramen like mental foramen and is relatively fixed, from impingement by an anatomic structure, or from entrapment of the nerve between the soft and hard tissues. Thus, it is important to know the anatomy of inferior alveolar nerve and its major branches with relation to their vulnerability to entrapment (Piagkou et al., 2011).

The IAN normally descends medial to the lateral pterygoid muscle passes between the sphenomandibular ligament and the mandibular ramus, and then enters the mandibular canal through the mandibular foramen. In the mandibular canal it runs downward and forward, generally below the apices of the teeth until below the first and second premolars, where it divides into the terminal incisive and mental branches (Khan et al., 2010; Krmpotic-Nemanic et al., 2001).

The mylohyoid nerve branches from the IAN, as the latter descends between the sphenomandibular ligament and the mandibular ramus. The mylohyoid nerve passes forward in a groove to reach the mylohyoid muscle and the anterior belly of the digastric muscle. (Loughner et al., 1990).

Topographically, the IAN may pass close to the medial part of the condyle. As such, a medially displaced disc could interfere mechanically with this nerve. This could explain the

sharp, shooting pain felt locally in the joint with jaw movements as well as the pain and other sensations projecting to the terminal area of distribution of the nerve branches near the temporomandibular joint, such as the ear, temple, cheek, tongue, and teeth (Piagkou et al., 2011; Johansson et al., 1990).

The MN exits the mandible through the mental foramen, divides into three branches deep to the depressor anguli, oris muscle, and supplies the skin and mucous membrane of the lower lip, the skin of the chin, and the vestibular gingiva of the mandibular incisor (Standring et al., 2005; Moore, 1983; April, 1990; Woodburne & Burkel 1994).

The MN is significant during surgical procedures of the chin area such as genioplasty and mandibular anterior segmented osteotomy (Westermarck et al., 1998; Seo et al., 2005; Gilbert & Dickerson 1981), and it can also be damaged during dental procedures such as dental implant surgery, orthodontic treatment, and endodontic treatment.

Mental neuropathy also may be caused by systemic diseases and tumors (Bodner et al., 1989; Klokkevold et al., 1989; Chand et al., 1997). Severe pain or sensation disturbance may occur when the MN is entirely or partially injured after such applications. A relatively common problem is the use of an inappropriate attachment depth or path during the insertion of dental implant fixtures, which may injury the IAN and MN. The incidence of permanent sensory disturbance to the lower lip after dental implant insertion in the mental foramen region is reportedly 7% to 10%. (Wismeijer et al., 1997; Mardinger et al., 2000). Complications such as loss of lip and chin sensation may result in lip biting, impaired speech, and diminished salivary retention, deficits that have a significant impact on a cases' activities of daily living (Deeb et al., 2000; Smiler, 1993). The MN can be preserved during dental implant or flap surgeries by repositioning the IAN or ridge augmentation (Hu et al., 2007).

Anatomical anomalies of the mandibular canal may have clinical implications, such as an increased risk of injury to the IAN in case of removing a mandibular third molar and inadequate local anesthetics such as bifid and trifid mandibular canal (Mizbah et al., 2010).

The IAN can be damaged secondary to the injection of a local anesthetic into the pterygomandibular space or the MN when injecting in the region of the mental foramen. Although the exact pathophysiology of this injury remains unknown, there are three possible causes as firstly direct intraneural injection with mechanical injury to the nerve such as severance of axons, partial or total, scar tissue or neuroma formation, Wallerian degeneration, and so forth, secondly interruption of vessels of the mesoneurium with perineural and intraneural hemorrhage and secondary scar formation, and thirdly chemical toxicity of the anesthetic solution from a sterilizing solution in a leaky carpule. Regardless of its cause, it is recommended that aspiration be done before all local anesthetic injections. If there is a bloody aspirate or the patient complains of a paresthesia as typically, an electric shock-like sensation, the needle is withdrawn a few millimeters and aspiration is repeated. If there is now no bloody aspirate, it can be assumed that the needle tip is no longer in contact with a blood vessel or nerve, and the injection is completed. A note of such an occurrence should be routinely entered in the cases' chart. This method may prevent direct injection into a vascular space, but does not necessarily prevent deposition of the anesthetic within the epineurium. Because the diameter of the IAN is 4–5 times greater than the associated inferior alveolar artery or vein. Nerve injury secondary to local anesthetic injection is not common. It may be difficult to differentiate from damage related to the placement of the dental implants, particularly if the case was under sedation or general anesthesia and, therefore, unable to report a paresthesia at the time of the injections (Meyer & Bagheri, 2011).

Damage to the IAN as a consequence of bone preparation or implant placement may be caused by errors in radiographic planning, drilling, or direct contact of the implant with the nerve. Drill injuries to the IAN may be difficult to diagnose. Damage caused by drilling, the extent of injury of the IAN caused by the implant itself is related to the degree of encroachment of the implant into the IAC or its direct contact with the IAN. Nerve injury caused by implant placement may occur, despite correct osseous preparation, when the implant is inserted beyond the vertical confines of the prepared bone, compressing or breaching the superior wall of the IAC and forcing bone into the canal. Consecutive, extension of drilling into the IAC may favor over insertion of the implant cylinder beyond its intended depth and into the IAC, making direct contact with the IAN (Meyer & Bagheri 2011).

The MN ranges in the mandibular buccal soft tissue and is at risk of injury during incisions. Recognition of the changing anatomy of the edentulous mandible is especially helpful in minimizing risk of damage to the MN. As the cases ages, the alveolar bone in an edentulous area resorbs, and the position of the mental foramen becomes closer to the crest of the alveolar ridge. In some cases there is actual rupture of the IAN and the MN come to lie on the alveolar ridge crest. Placement of an incision must, therefore, take these anatomic changes into gravity. During the retraction of a mucoperiosteal flap it is potential to exert continuous improper pressure on the underlying IAN and MN. Gentle soft tissue retraction with frequent short relaxation of retraction pressure is advised nerve (Meyer & Bagheri 2011).

For reconstruction of an atrophied posterior mandible, different therapeutic options have been proposed, such as autologous bone grafting, guided bone regeneration for vertical ridge augmentation, and IAN mobilization with simultaneous implant placement. The possible dehiscence of soft tissues covering the surgical zone makes the first and second techniques unpredictable. Moreover, two surgical sites are necessary and a long treatment time as nearly 12 months is required. With IAN mobilization, only one surgical intervention is required and the total treatment time is shorter as about about 6 months. However, this method risks irreversible damage to the IAN, with consequent functional alterations. Recent studies have shown extreme variability in the examination of functionality of the neurovascular bundle after its mobilization. This variability can be attributed both to the methodology used for the tests, which evoke subjective answers from the case, and to the surgical procedure, which is highly dependent on surgeon method. Nerve injury may be the result of an overstretched mucoperiosteal flap in the premolar region to achieve optimal visibility of the operative zone (Bovi, 2005).

Less common causes of nerve damage are related to placement of autologous or allogenic or also xenogenic bone grafts during simultaneous implant placement. In cases of complex implant reconstruction, the bone graft material may be placed into the donor site with additional force, thus severely compressing or even crushing the IAN. The authors have decelerated several cases of particulate bone graft material within the IAC that caused important nerve compression, and other cases of severe scarring, similar in clinical configuration to a chemical burn, when calcium hydroxyapatite came in direct contact with the nerve (Meyer & Bagheri, 2011; Ferrera & Chandler, 1994).

During surgical resection of tumors of the oral cavity, head and neck surgeons are often faced with the challenge of achieving complete resection margins while preserving a functional and anatomical features to avoid nerve injury. Injuries to peripheral branches like IAN during the removal of third molar teeth are known and accepted risks in oral and

maxillofacial surgery practice. These risks might be reduced by modifications of evaluation or surgical methods depending on the operators' judgment in individual cases. If a nerve damages, prompt recognition, subjective and objective valuing, and forming a treatment plan, if the sensory deficit fails to resolve in a rational period and is not acceptable to the case, give the case the best chance of achieving recovery of sensory function in the distribution of the damaged nerve. Microneurosurgery may produce return of useful sensory function or complete sensory improvement if done in a timely fashion by an experienced operator, in greater than 80% of cases who prevent nerve damages during the removal of the third molar teeth (Meyer & Bagheri, 2011).

3. Mechanisms of nerve injury

3.1 Nerve morphology

The nerve trunk is surrounded of four connective tissue sheaths. These are the mesoneurium, epineurium, perineurium, and endoneurium from the outside inward (Polland et al., 2001). The mesoneurium is a connective tissue sheath which is analogous to the mesentery of the intestine. It encloses the nerve trunk within the soft tissue, contains the segmental blood supply of the nerve, it continues with the epineurium. The epineurium is the loose connective tissue sheath which protects the nerve trunk against mechanical stress. Fascicles are marked out by the perineurium, which surrounds the axons and endoneurial sheaths. The fascicular pattern can be monofascicular (one large fascicle), oligofascicular (2-10 rather large fascicles) or polyfascicular (more than 10 fascicles of different sizes). Individual nerve fibers and their Schwann cells are surrounded by the endoneurium. The perineurium and endoneurium provide elasticity together. Polyfascicular nerves with many small fascicles such as the IAN resist stretch more than monofascicular or oligofascicular nerves (Sunderland, 1951). The nerve fiber is the functional component of the peripheral nerve and it is responsible for transmitting stimuli. The nerve fiber consists of axon, a Schwann cell, and a myelin sheath in myelinated nerve fibers. The axon is a segment of a neuron and can be characterized by morphology, conduction velocity and function.

A-alpha fibers are the largest myelinated fibers. They are encoded for the transmission of muscle spindle and tendon organ afferents and skeletal muscle efferents. The A-beta fibers are the second largest myelinated axons. The sensation of touch is transmitted to these axons. The A-delta fibers are the smallest of the myelinated fibers, which transmit stimuli encoded for temperature and pain. The smallest axons are the unmyelinated C-fibers. They transmit stimuli encoded for slow or second pain, temperature, and efferent sympathetic fibers (LaBanc, 1992).

In 1943, Seddon described a triple classification of mechanical nerve injuries to characterize the morphophysiologic types. Seddon's classification includes neuropraxia, axonotmesis and neurotmesis and is based on the time course and completeness of sensory recovery (Seddon, 1943).

3.1.1 Neuropraxia

Neuropraxia represents the mildest form of nerve injury. It is characterized by a conduction block, almost complete return of sensation or function, and no degeneration of the axon. The continuity of the epineural sheath and the axons is lasts and morphologic alterations are minor. Trauma to the endoneurial capillaries causes intrafascicular edema, resulting in a conduction block. The sensation or function returns to normal within 1 to 2 days following

the resolution of intrafascicular edema, generally within 1 week following nerve injury. The function deficit recovers spontaneously and usually complete within 3 to 4 weeks (LaBanc, 1992).

3.1.2 Axonotmesis

Axonotmesis is a more severe nerve injury with disruption of the neuronal axon but with maintenance of the myelin sheath. This type of nerve damage may cause paralysis of the motor, sensory, and autonomic functions.

It involves loss of the relative continuity of the axon and its covering of myelin, but preservation of the connective tissue framework of the nerve (the encapsulating tissue, the epineurium and perineurium, are preserved). Because of the loss of axonal continuity, wallerian degeneration occurs. An axonotmesis is characterized by axonal injury and continues with degeneration or regeneration. Traction and compression are the usual mechanisms of this type of injury. This may cause severe ischemia, intrafascicular edema, or demyelination. Although the axons are damaged, there is no disruption of the endoneurial sheath, perineurium, or epineurium. Complete recovery takes place in 2 to 4 months, but improvement leading to complete recovery may take as long as 12 months.

It is important to know that within 2 to 4 months following injury, signs of sensation or function begin and continue to improve over the next 8 to 10 months. Anesthesia followed by a paresthesia is the psychophysical response to an axonotmesis as recovery begins (LaBanc, 1992).

3.1.3 Neurotmesis

Neurotmesis is the most severe lesion with potential of recovering. A neurotmesis is characterized by severe disruption of the connective tissue components of the nerve trunk. The etiology of nerve injury is traction, compression, injection injury, chemical injury, local anesthetic toxicity or in a complete disruption of the nerve trunk laceration and avulsion. In this type of nerve injury, sensory and functional recovery is never complete.

The psychophysical response to these injuries is an immediate anesthesia. This may be followed by paresthesia or possibly neuropathic responses such as allodynia, hyperpathia, hyperalgesia, or chronic pain. This type of nerve injury has a high probability of development of a central neuroma (LaBanc, 1992).

4. Inferior alveolar nerve lateralisation

4.1 Surgical procedure

IAN lateralisation is a new technique. In the literature of implantology, the techniques described are partial and located at the anterior part of the nerve, near the foramen mentalis. Total lateralisation technique can be used in dental prosthesis in mandibular posterior edentulism when the alveolar bone is reduced and when the prosthesis compresses the nerve in the foramen region. This technique can also be used in implantology when terminal implant restitution is needed. On patients with benign tumors when the horizontal branch of the mandible is resected total lateralisation technique is a choice.

The procedure starts with the soft tissue incision slightly buccal to the crest of the residual alveolar ridge. The incision begins at the retromolar region and continues forward to the mesial portion of the cuspid tooth area, where a vertical relaxing incision is made. A full thickness mucoperiosteal flap is elevated to the inferior border of the mandible. For

performing IAN lateralization, the corticotomy starts usually 3–4 mm distal to the mental foramen. Corticotomy should be extended 4–5 mm distal to the most distal implant position. To remove the trabecular bone and gain access to the neurovascular bundle, only hand instruments such as small curettes are used. The MN is mobilized from its position. After the nerve is completely released from the canal, half a rubber piston from a dental anaesthetic cartridge or a piece of aluminum foil is inserted between the nerve bundle and the bone.

Once the drilling is completed, the implant is inserted while the nerve bundle remains retracted in situ ensuring that the apical ends of the implants are positioned inferior to the canal. Once the implants are in position, the nerve is repositioned over the lateral aspect of the implants. The surgical protocol for IAN transposition, followed by implant placement, presented excellent results, with complete recovery of the sensitivity within 6 months after the surgical procedure.

4.2 Case report

45 year-old female patient applied to Gulhane Scholl of Medicine, Department of Oral and Maxillofacial Surgery, with missing teeth in the mandibula. As she couldn't use removable partial denture, we evaluated posterior mandibular area. But mandibular posterior bone height was inadequate for implant placement. A preoperative panoramic radiograph (Fig 2) and computerized tomographic (CT) scan revealed only 5 mm. of bone between the alveolar crest and the inferior alveolar canal.

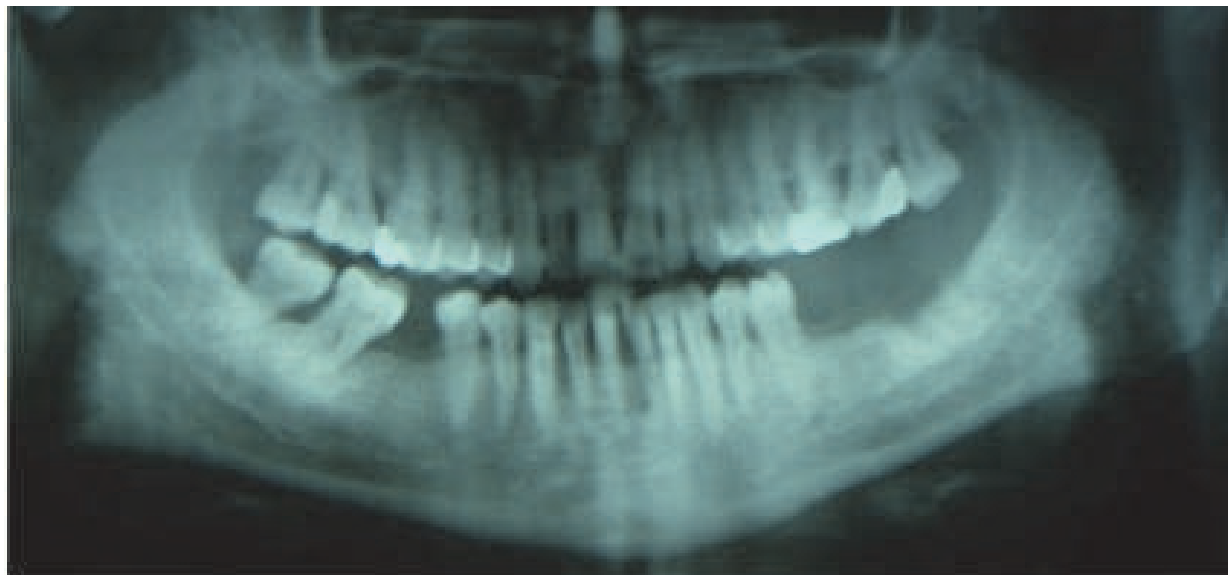

Fig. 2. Preoperatif panoramic radiograph.

We planned alternative methods including IAN lateralization technique at this place. The surgical procedure was performed under local anesthesia. A full thickness mucoperiosteal flap was elevated to the inferior border of the mandible. For performing inferior alveolar nerve lateralization, the corticotomy started 4 mm distal to the mental foramen. A small round bur in a straight hand piece with high torque and copious amount of water irrigation was used to prepare the corticotomy site. To remove the trabecular bone and gain access to the neurovascular bundle, only hand instruments (small curettes) were used. The IAN was

mobilized from its position. After the nerve was completely released from the canal and before starting to drill, half a rubber piston from a dental anaesthetic cartridge or a piece of membrane was inserted between the nerve bundle and the bone where the drill was expected to reach (Fig 3). At second premolar and second molar region, we placed 3.5x12 mm. MIS implant (Fig 4).

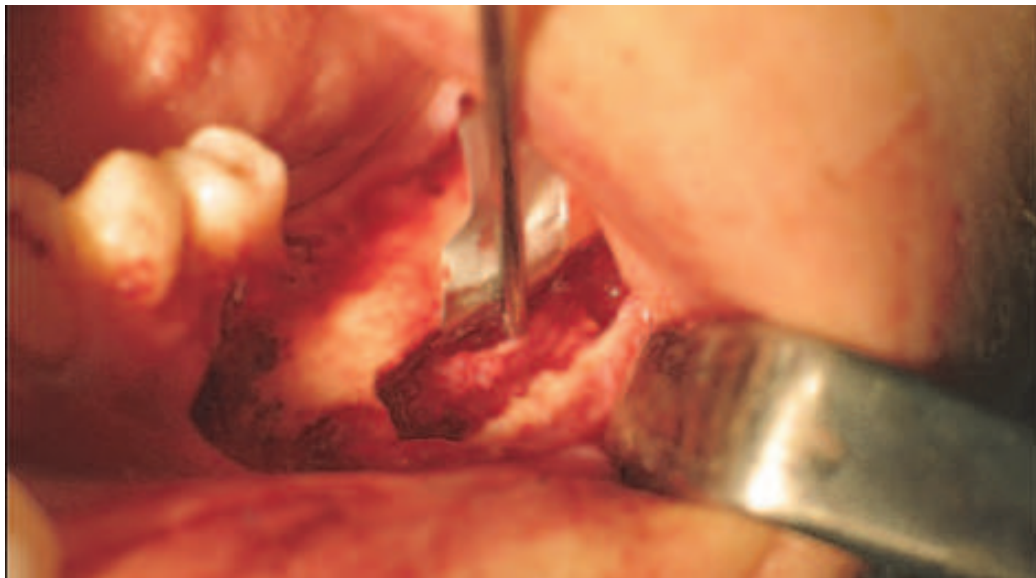

Fig. 3. Nerve retraction with a retractor.

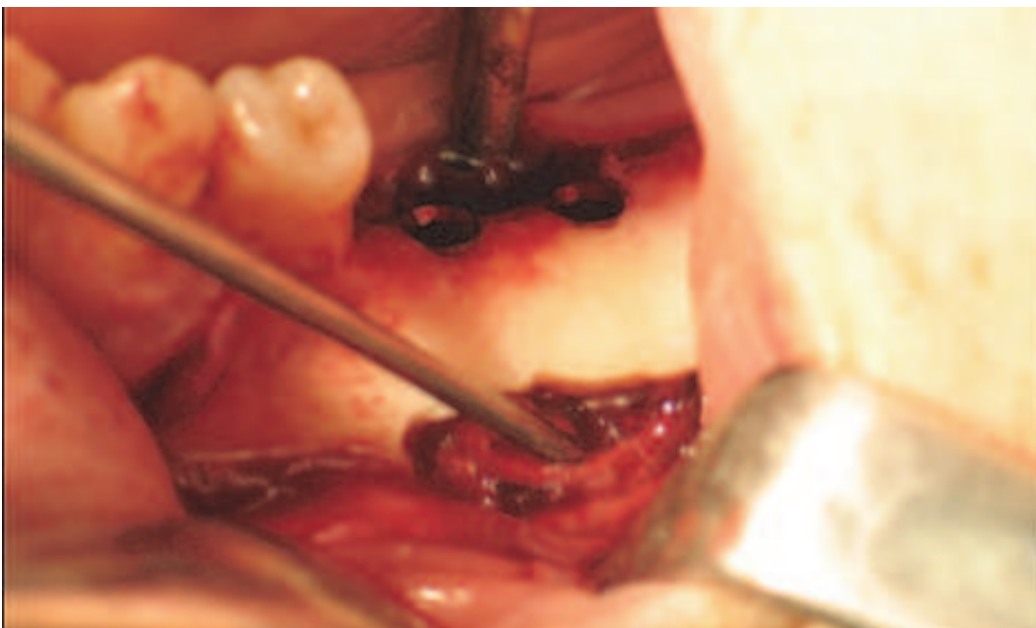

Fig. 4. Two implants was placed after nerve retractions.

The releasing incisions were carried out and mucoperiosteal flap were sutured by using 3.0 silk. CT scan and panoramic radiograph (Fig 5) were taken after placing the endosseous implants. Surgical exposure and moving the nerve laterally results in a high incidence of sensory nerve disturbance and an excessive crown-to-root ratio of the prosthesis.

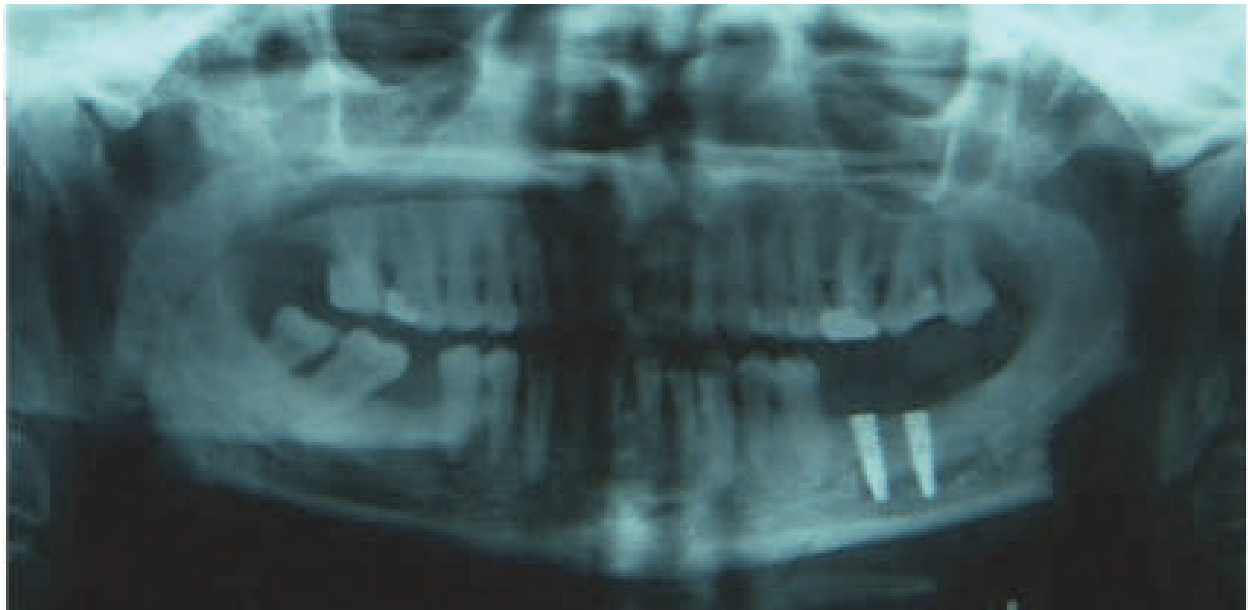


Fig. 5. The ends of the implants are positioned inferior to the canal.

We didn't examine any neurologic disturbance at postoperative controls. The present study investigated neurosensorial disturbances related to IAN lateralization for up to 6 month follow-up. Subjective criteria, sensory function of the IAN returned to normal 6 weeks after surgery. IAN lateralization is a precise technique requiring high clinical competence, which should only be carried out by specialists. IAN lateralization is a useful method for managing the atrophic posterior mandible with dental implants. The risk of permanent damage of the IAN appears to be small.

5. References


- Ardekian, L., Salnea, J., Abu el-Naaj, I., Gutmacher, T., & Peled, M. (2001). "Inferior alveolar nerve repositioning in implant surgery." *Refuat Hapeh Vehashinaym* 18(2): 39-41, 62.
- Aldskogius, H., Arvidsson, J. & Grant, G. (1985). "The reaction of primary sensory neurons to peripheral nerve injury with particular emphasis on transganglionic changes." *Brain Res* 357(1): 27-46.
- Anderson, LC., Kosinski, TF., & Mentag, PJ. (1991). "A review of the intraosseous course of the nerves of the mandible." *J Oral Implantol* 17(4): 394-403.
- April, EW. (1990). Clinical anatomy. *The National Medical Series for Independent Study*. 2nd ed. Harwal Publishing Company, USA.
- Babbush, CA. (1998). "Transpositioning and repositioning the inferior alveolar and mental nerves in conjunction with endosteal implant reconstruction." *Periodontology* 2000 17: 183-90.
- Becerra, L., Morris, S., Bazes, S., Gostic R., Sherman, S., Gostic J., Pendse G., Moulton, E., Scrivani, S., Keith D., Chizh B., & Borsook D. (2006). "Trigeminal neuropathic pain alters responses in CNS circuits to mechanical (brush) and thermal (cold and heat) stimuli." *J Neurosci* 26: 10646-57.
- Bodner, L., Oberman, M., & Shteyer, A. (1989). "Mental nerve neuropathy associated with compound odontoma." *Oral Surg Oral Med Oral Pathol* 63(6): 658-60.

- Bovi M. (2005) "Mobilization of the inferior alveolar nerve with simultaneous implant insertion: a new technique. Case report." *Int J Periodontics Restorative Dent* 25(4): 375-83.
- Chand, V., Sweeney, C., & Agger, WA. (1997). "Mental neuropathy in patients with AIDS-associated malignant lymphoma." *Clin Infect Dis* 24(3): 521-2.
- Chrcanovic, BR., & Custodio, AL. (2009). "Inferior alveolar nerve lateral transposition." *Oral Maxillofac Surg* 13(4): 213-9.
- Cummings, CW., Fredrickson, JM., Harker, LA., Krause, CJ., & Schuller, DE. (1993). *Otolaryngology-Head and Neck Surgery*. 2nd ed. Vol I, Mosby Year Book, , pp312.
- Deeb, GR., Dierks, E., So, YT. (2000). "Sensory nerve conduction study of the mental nerve." *Muscle Nerve* 23(7):1121-4.
- Di Lenarda, R., Cadenaro, M., & Stacchi, C. (2000). "Paresthesia of the mental nerve induced by periapical infection: A case report." *Oral Surg Oral Med Oral Pathol Oral Radiol Endod* 90(6):746-9.
- Essick, G. (2004). "Psychophysical assessment of patients with post- traumatic neuropathic trigeminal pain." *J Orofac Pain* 18: 345-54.
- Ferrera, PC., & Chandler, R. (1994). Anesthesia in the emergency setting: Part II. Head and neck, eye and rib injuries. *Am Fam Physician* 15;50(4):797-800.
- Gary, G., & Dennis, T. (2006). "The mental foramen and nerve: clinical and anatomical factors related to dental implant placement: a literature review." *J Periodontol* 77(12): 1933-43.
- Gilbert, BO., & Dickerson, AW 2nd. (1981). "Paresthesia of the mental nerve after an acute exacerbation of chronic apical periodontitis." *J Am Dent Assoc* 103(4):588-90.
- Greenstein, G., & Tarnow, D. (2006). "The mental foramen and nerve: clinical and anatomical factors related to dental implant placement: a literature review." *J Periodontol* 77(12): 1933-43.
- Gregg, JM. (2000). Neuropathic complications of mandibular implant surgery: review and case presentations. *Ann R Australas Coll Dent Surg* 15:176-80.
- Grover, PS., & Lorton, L. (1983). "Bifid mandibular nerve as a possible cause of inadequate anesthesia in the mandible." *J Oral Maxillofac Surg* 41(3): 177-9.
- Jensen, O. & Nock, D. (1987). "Inferior alveolar nerve repositioning in conjunction with placement of osseointegrated implants: a case report." *Oral Surg Oral Med Oral Pathol* 63(3): 263-8.
- Johansson AS, Isberg A, & Isacsson G. (1990). "A radiographic and histologic study of the topographic relations in the temporomandibular joint region: Implications for a nerve entrapment mechanism." *J Oral Maxillofac Surg* 48: 953-61.
- Haghighat, K. (2007). "Bone augmentation techniques." *J Periodontol* 78(3): 377-96.
- Hashemi, HM. (2010). "Neurosensory function following mandibular nerve lateralization for placement of implants." *Int J Oral Maxillofac Surg* 39(5): 452-6.
- Hilu, RE., & Zmener, O. (1999). "Mental nerve paresthesia associated with an amalgam filling: A case report." *Endod Dent Traumatol* 15(6): 291-3.
- Hu, KS., Yun, HS., Hur, MS., Kwon, HJ., Abe, S., & Kim, HJ. (2007). "Branching patterns and intraosseous course of the mental nerve." *J Oral Maxillofac Surg* 65(11): 2288-94.

- Kieser, J., Kuzmanovic, D., Payne A, Dennison J., & Herbison P. (2002). "Patterns of emergence of the human mental nerve." *Arch Oral Biol* 47(10): 743-7.
- Khan, MM., Darwish, HH., & Zaher, WA. (2010). "Perforation of the inferior alveolar nerve by the maxillary artery: An anatomical study." *Br J Oral Maxillofac Surg* 48(8): 645-7.
- Kim, ST., Hu, KS., Song, WC., Kang, MK., Park HD. & Kim HJ. (2009). "Location of the mandibular canal and the tomography of its neurovascular structures." *J Craniofac Surg* 20(3):936-9.
- Klokkevold PR, Miller DA, & Friedlander AH. (1989). "Mental nerve neuropathy: A symptom of Waldenström's acroglobulinemia." *Oral Surg Oral Med Oral Pathol* 67(6):689-93.
- Krmpotic-Nemanic, J., Vinter, I., & Jalsovec, D. (2001). "Accessory oval foramen." *Ann Anat* 183:293-5.
- Krogstad O, & Omland G. (1997). "Temporary paresthesia of the lower lip: A complication of orthodontic treatment. A case report." *Br J Orthod* 24(1): 13-5.
- LaBanc JP. (1992). "Reconstructive microneurosurgery of the trigeminal nerve." In: Bell WH. editors. *Modern practice in orthognathic and reconstructive surgery*. Philadelphia: W. B. Saunders Cop. p: 1083-89.
- Labanc, JP. (1988). "Diagnostic evaluation and management of inferior alveolar and lingual nerve injuries." *Fla Dent J* 59(4): 50-4.
- Langlais, RP., Broadus, R., & Glass BJ. (1985). "Bifid mandibular canals in panoramic radiographs." *J Am Dent Assoc* 110(6): 923-6.
- Levine, MH., Goddard, AL., & Dodson, TB. (2007). "Inferior alveolar nerve canal position: a clinical and radiographic study." *J Oral Maxillofac Surg* 65(3): 470-4.
- Loughner, BA., Larkin, LH., & Mahan, PE. (1990). "Nerve entrapment in the lateral pterygoid muscle." *Oral Surg Oral Med Oral Pathol* 69(3):299-306.
- Lundborg, G. (1988). "Intraneural microcirculation." *Orthop Clin North Am* 19(1): 1-12.
- Manikandhan, R., Mathew, PC., Naveenkumar, J., Anantanarayanan, P. (2010). "A rare variation in the course of the inferior alveolar nerve." *Int J Oral Maxillofac Surg* 39(2): 185-7.
- Mardinger O, Chaushu G, Arensburg B, Taicher S, & Kaffe I. (2000). "Anterior loop of the mental canal: An anatomical-radiologic study." *Implant Dentistry* 9(2):120-5.
- Metzger, MC., Bormann, KH., Schoen, R., Gellrich, NC., & Schmelzeisen, R. (2006). "Inferior alveolar nerve transposition an in vitro comparison between piezosurgery and conventional bur use." *J Oral Implantol* 32(1): 19-25.
- Meyer, RA., Bagheri, SC. (2011) "Nerve injuries from mandibular third molar removal." *Atlas Oral Maxillofac Surg Clin North Am* 19(1):63-78.
- Misch, CE., & Resnik, R. (2010). "Mandibular nerve neurosensory impairment after dental implant surgery: management and protocol." *Implant Dent* 19(5): 378-86.
- Mizbah, K., Gerlach, N., Maal, TJ., Bergé, SJ., & Meijer GJ. (2010). "Bifid and trifid mandibular canal. A coincidental finding." *Ned Tijdschr Tandheelkd* 117(12): 616-8.
- Morrison, A, Chiarot, M, & Kirby, S. (2002). "Mental nerve function after inferior alveolar nerve transposition for placement of dental implants." *J Can Dent Assoc* 68:46-50.
- Moore, KL. (1983). *Clinically orientated anatomy*. The Williams and Wilkind Company USA.

- Nortjé, CJ., Farman, AG., & de V Joubert JJ. (1977). "The radiographic appearance of the inferior dental canal: an additional variation." *Br J Oral Surg* 15(2): 171-2.
- Oktem H., Oktem F., Sanli E., Menevse GT., & Tellioğlu AT. (2008). "An anatomic variation of mental nerve." *J Plast Reconstr Aesthet Surg* 61(11):1408-9;
- Ordás, CM., Cuadrado, ML., Simal, P., Barahona, R., Casas, J., Matías-Guiu Antem, J., & Porta-Etessam, J. (2011). "Wallenberg's syndrome and symptomatic trigeminal neuralgia." *J Headache Pain* Feb 10. [Epub ahead of print].
- Paparella, MM., Shumrick, DA., Gluckman, JL., & Meyerhoff, WL. (1991). *Otolaryngology, Vol I,II,III*. 3rd ed. WB. Saunders Company, pp123, 2958,2050;
- Piagkou, M., Demesticha, T., Skandalakis, P., & Johnson, EO. (2011). "Functional anatomy of the mandibular nerve: Consequences of nerve injury and entrapment." *Clin Anat* 24(2):143-50.
- Polland, KE., Munro, S., Reford, G., Lockhart, A., Logan, G., Brocklebank, L., & McDonald SW. (2001). "The mandibular canal of the edentulous jaw." *Clin Anat* 14(6): 445-52.
- Prado, FB., Groppo, FC., Volpato, MC., & Caria, PH. (2010). "Morphological changes in the position of the mandibular foramen in dentate and edentate Brazilian subjects." *Clin Anat* 23(4):394-8;
- Ramadhan, A., Messo, E., & Hirsch, JM. (2010). "Anatomical variation of mental foramen. A case report." *Stomatologija* 12(3):93-6.
- Scarano, A., Carinci, F., Assenza, B., Piattelli, M., Murmura, G., & Piatelli, A., (2011). "Vertical ridge augmentation of atrophic posterior mandible using an inlay technique with a xenograft without miniscrews and miniplates: case series." *Clin Oral Implants Res*
- Seddon, HJ. (1943). "Three types of nerve injuries." *Brain* 66: 237-43.
- Seo, K., Tanaka, Y., Terumitsu, M., & Someya, G. (2005). "Characterization of different paresthesias following orthognathic surgery of the mandible." *J Oral Maxillofac Surg* 63(3):298-303.
- Siéssere, S., Hallak Regalo, SC., Semprini, M., Honorato De Oliveira, R., Vitti, M., Mizusaki Iyomasa, M., Mardegan Issa, JP., & De Sousa, LG. (2009). "Anatomical variations of the mandibular nerve and its branches correlated to clinical situations." *Minerva Stomatol* 58(5):209-15;
- Smiler, DG. (1993). "Repositioning the inferior alveolar nerve for placement of endosseous implants: Technical note." *Int J Oral Maxillofac Implants* 8(2): 145-50.
- Snell, RS. (2011). *Clinical Anatomy*. Williams and Wilkins 8th ed. Walters Kluwer, USA.
- Standring, S., Ellis, H., Healy, JC., Johnson, D., Williams, A. & Collins, P. (2005). *Gray's Anatomy* (ed 39). London, Churchill Livingstone, p 513;
- Sunderland, S., (1951) "A Classification of Peripheral Nerve Injuries Producing Loss of Function." *Brain* 74(4): 491-516.
- Takazakura, D., Ueki, K., Nakagawa, K., Maruka, K., Shimada, M., Shamiul, A., & Yamamoto, E. (2007). "A comparison of postoperative hypoesthesia between two types of sagittal split ramus osteotomy and intraoral vertical ramus osteotomy, using the trigeminal somatosensory-evoked potential method." *Int J Oral Maxillofac Surg* 36: 11-4.
- Van de, Graaff. (1998). *Human Anatomy* 5th ed. WBC McGraw-Hill Companies, USA, pp395

- Westermarck, A., Bystedt, H., & von Konow, L. (1998). "Inferior alveolar nerve function after mandibular osteotomies." *Br J Oral Maxillofac Surg* 36(6):425-8.
- Wismeijer, D., van Waas, MA., Vermeeren, JL., & Kalk W. (1997). "Patients' perception of sensory disturbances of the mental nerve before and after implant surgery: A prospective study of 110 patients." *Br J Oral Maxillofac Surg* 35:254-9
- Woodburne, RT, & Burkel, WE. *Essentials of Human Anatomy* (ed 9). New York, Oxford University Press, 1994, p 268.



Implant Dentistry - A Rapidly Evolving Practice

Edited by Prof. Ilser Turkyilmaz

ISBN 978-953-307-658-4

Hard cover, 544 pages

Publisher InTech

Published online 29, August, 2011

Published in print edition August, 2011

Implant dentistry has come a long way since Dr. Branemark introduced the osseointegration concept with endosseous implants. The use of dental implants has increased exponentially in the last three decades. As implant treatment became more predictable, the benefits of therapy became evident. The demand for dental implants has fueled a rapid expansion of the market. Presently, general dentists and a variety of specialists offer implants as a solution to partial and complete edentulism. Implant dentistry continues to evolve and expand with the development of new surgical and prosthodontic techniques. The aim of *Implant Dentistry - A Rapidly Evolving Practice*, is to provide a contemporary clinic resource for dentists who want to replace missing teeth with dental implants. It is a text that relates one chapter to every other chapter and integrates common threads among science, clinical experience and future concepts. This book consists of 23 chapters divided into five sections. We believe that, *Implant Dentistry: A Rapidly Evolving Practice*, will be a valuable source for dental students, post-graduate residents, general dentists and specialists who want to know more about dental implants.

How to reference

In order to correctly reference this scholarly work, feel free to copy and paste the following:

Umit Karacayli and Nuket Mas (2011). Oral Territorial Neurovascular Considerations in Implant Surgery, *Implant Dentistry - A Rapidly Evolving Practice*, Prof. Ilser Turkyilmaz (Ed.), ISBN: 978-953-307-658-4, InTech, Available from: <http://www.intechopen.com/books/implant-dentistry-a-rapidly-evolving-practice/oral-territorial-neurovascular-considerations-in-implant-surgery>

INTECH
open science | open minds

InTech Europe

University Campus STeP Ri
Slavka Krautzeka 83/A
51000 Rijeka, Croatia
Phone: +385 (51) 770 447
Fax: +385 (51) 686 166
www.intechopen.com

InTech China

Unit 405, Office Block, Hotel Equatorial Shanghai
No.65, Yan An Road (West), Shanghai, 200040, China
中国上海市延安西路65号上海国际贵都大饭店办公楼405单元
Phone: +86-21-62489820
Fax: +86-21-62489821

© 2011 The Author(s). Licensee IntechOpen. This chapter is distributed under the terms of the [Creative Commons Attribution-NonCommercial-ShareAlike-3.0 License](https://creativecommons.org/licenses/by-nc-sa/3.0/), which permits use, distribution and reproduction for non-commercial purposes, provided the original is properly cited and derivative works building on this content are distributed under the same license.

IntechOpen

IntechOpen