

We are IntechOpen, the world's leading publisher of Open Access books Built by scientists, for scientists

6,900

Open access books available

185,000

International authors and editors

200M

Downloads

Our authors are among the

154

Countries delivered to

TOP 1%

most cited scientists

12.2%

Contributors from top 500 universities



WEB OF SCIENCE™

Selection of our books indexed in the Book Citation Index
in Web of Science™ Core Collection (BKCI)

Interested in publishing with us?
Contact book.department@intechopen.com

Numbers displayed above are based on latest data collected.
For more information visit www.intechopen.com



Diagnostic and Therapeutic Transvaginal Hydrolaparoscopy

Hiroaki Shibahara, Tatsuya Suzuki and Mitsuaki Suzuki
*Department of Obstetrics and Gynecology,
 School of Medicine Jichi Medical University, Tochigi,
 Japan*

1. Introduction

Laparoscopy is the gold-standard procedure for the diagnosis of tubo-peritoneal infertility. However, transabdominal access in laparoscopy is not without major risks, including gastrointestinal injuries¹ and major vascular injuries.² In 1998, to minimize the invasiveness of laparoscopy for diagnostic purposes, transvaginal hydrolaparoscopy (THL) was introduced as the first line procedure in the exploration of the adnexal structures in infertile women.^{3,4} Demonstration of the advantages of THL, such as the ability to accurately inspect adnexal structures without manipulation, has made it clear that THL is a less traumatic and more suitable outpatient procedure than transabdominal laparoscopy. THL can be performed under local anesthesia of the posterior vaginal fornix. A rigid scope is inserted transvaginally through the pouch of Douglas, saline is injected for distension, and a field of vision thereby becomes available. Unlike minimally invasive endoscopic procedures, the natural office surgery is recently called natural office transluminal endoscopic surgery (NOTES).⁵

There are some reports that described the usefulness and prognostic value of diagnostic THL in infertile women.⁶⁻⁸ Moreover, operative THL such as ovarian drilling for unovulatory women with polycystic ovarian syndrome (PCOS) to induce ovulation has also appeared to be as effective as that by the conventional laparoscopy.^{5, 9-13} This procedure is named transvaginal hydrolaparoscopic ovarian drilling (THLOD). THL has also been expected to be useful for adhesiolysis in some limited lesions.

The risk of bowel injury and sepsis by transvaginal access with culdoscopy was higher than that with laparoscopy in old reports.¹⁴ However, the value of direct access to the posterior pelvis at culdoscopy for infertility investigation is well recognized. Although the new technique of THL differs in the use of the dorsal decubitus position for the patient, a small diameter endoscope, and saline solution for peritoneal distension, the principle of THL is similar to that of culdoscopy in that its access is through the posterior fornix.

2. Indication and surgical procedure of THL and THLOD

We have been performing THL for the following five indications: diagnostic THL^{7,8} for (i) tubal obstruction and/or peritubal adhesion are suggested by hysterosalpingography (HSG), (ii) serum antibody against *C. trachomatis* is positive, (iii) diagnosis of early-stage endometriosis, (iv) unexplained infertility, and operative THL^{10,12-13} for (v) ovarian drilling

using Nd:YAG or Holmium laser in infertile women with polycystic ovary syndrome (PCOS). However, to avoid the major risks of THL, any of the followings are contraindications: i) retroflexed uterus, ii) the past history of pelvic surgery, iii) obstruction of the pouch of Douglas by the rectum or a prolapsed tumor, and iv) acute pelvic inflammatory disease.

THL and THLOD were performed in the lithotomy position as we described previously.^{7-8, 10, 12-13, 15-18} Briefly, after premedication, a Hys-cath (Sumitomo Bakelite Co. Ltd., Tokyo, Japan) was inserted into the uterine cavity for use in chromotubation. The uterine cervix was lifted with a tenaculum placed on the posterior lip. Under local anesthesia or general anesthesia, a Veress needle was introduced 1.5 cm below the cervix and inserted into the pelvic cavity (Figure 1a). Approximately 100 ml of normal saline solution is instilled through the cannula in the pouch of Douglas (Figure 1b, 1c). For THL, a 3-mm blunt trocar was inserted by a stab incision in the posterior fornix and a 2.7-mm diameter semirigid endoscope was used at an optical angle of 30° with a flow channel attached to a 3-CCD digital videocamera (Figure 1d). For THLOD, a 5.5-mm blunt trocar is inserted by a stab incision in the posterior fornix. Then a 5.0-mm diameter semirigid endoscope was used with the same technique. The saline irrigation was continued throughout the procedure to keep the bowel and tubo-ovarian structures afloat. The posterior region of the uterus and the bilateral tubo-ovarian structures were carefully observed, and tubal passage was confirmed using indigocarmine. In a few cases, the structure could not be observed due to severe adhesion.⁷

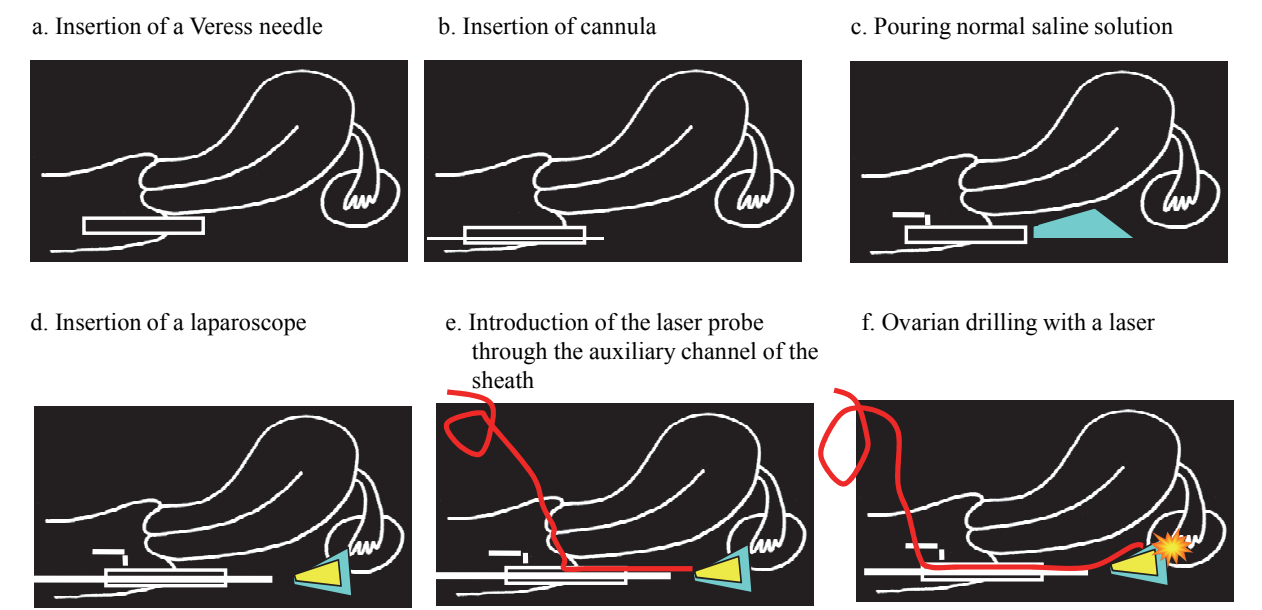


Fig. 1. Procedure for THL and THLOD
The procedure for THL and THLOD are described. a) A Veress needle is inserted into the pelvic cavity. b, c) Normal saline solution is instilled through the cannula in the pouch of Douglas. d) A blunt trocar is inserted by a stab incision in the posterior fornix. Then a semirigid endoscope is used with an optical angle of 30° and a flow channel attached to a 3-CCD digital videocatmera. Tubal passage is confirmed using indigo carmine. e, f) THLOD is performed using a laser to ablate portions of the ovarian cortex.

For THLOD, after careful observation as for diagnostic THL (Figure 2a), ovarian drilling was performed using an Nd:YAG laser (STAGE MY-100, LASER PERIPHERALS LLC, MN, USA) or Holmium laser (VersaPulse, Boston Scientific, MA, USA) to ablate portions of the ovarian cortex (Figure 1e, 1f). A sterile quartz glass fiber measuring 1 mm in core diameter was passed through the operating channel of the laparoscope using a special laser fiber steering device with a deflectable tip (Figure 2b, 2c). The power used ranges up to 10 W. The focused laser beam is used at a distance of 1.5 mm to 3.0 mm to create approximately 40 holes on the surface of each ovary (Figure 2d, 2e, 2f).

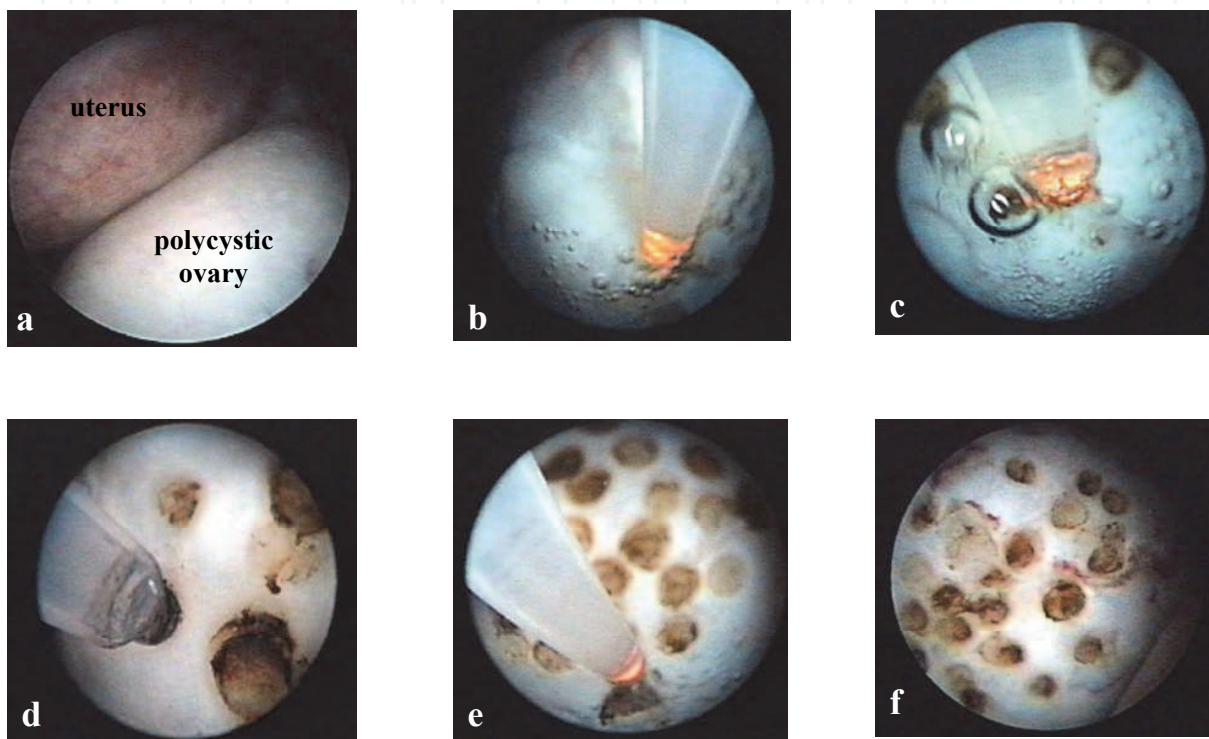


Fig. 2. Performance of THLOD using a laser a) A polycystic ovary behind the uterus is visible through THL. b) Introduction of the laser probe through the auxiliary channel of the sheath. The focused laser beam was used from a distance of 1.5 mm to 3.0 mm. c-e) Approximately 40 holes were made on the ovarian cortex. f) Final phase of ovarian drilling.

3. Visualization of tubo-ovarian structures and salpingoscopy

Assessment of the Fallopian tube represents an integral part for the evaluation of the infertile couple. Because the findings obtained at hysterosalpingography, laparoscopy, or laparotomy are indirect, salpingoscopy has been introduced as an endoscopic examination that can directly evaluate the ampullary tubal mucosa. The standard procedure is transfimbrial salpingoscopy performed at the time of laparoscopy.¹⁹ It is a microendoscopic approach for directly visualizing the tubal mucosa from the ampullary-isthmic junction to the fimbria. Clinical and morphological studies have shown a high correlation between the appearance of the tubal mucosa and the ultimate outcome in terms of pregnancies.¹⁹ Recently, it was suggested that performing salpingoscopy with laparoscopy could significantly increase accuracy in predicting short-term fertility outcome.²⁰ However, such salpingoscopy under trans-abdominal laparoscopy requires hospitalization and general anesthesia.

In some women, endoluminal examination by salpingoscopy can be simultaneously performed under THL. The transvaginal salpingoscopy under THL is less invasive to infertile women because it does not require hospitalization or general anesthesia. The procedure was first described by Gordts et al.²¹ They reported that the fimbriae were visualized in all patients with no obvious pelvic pathology, and cannulation of the distal tubal segment was achieved without manipulation of the tube in 20% before ovulation and 55% in the early luteal phase. Afterward Watrelot et al.²² reported that salpingoscopies were possible in 19% of women with post-PID lesions without the need to stabilize the tubes. However, salpingoscopies were possible in 41% of those women using a grasp forceps introduced in the operative channel.

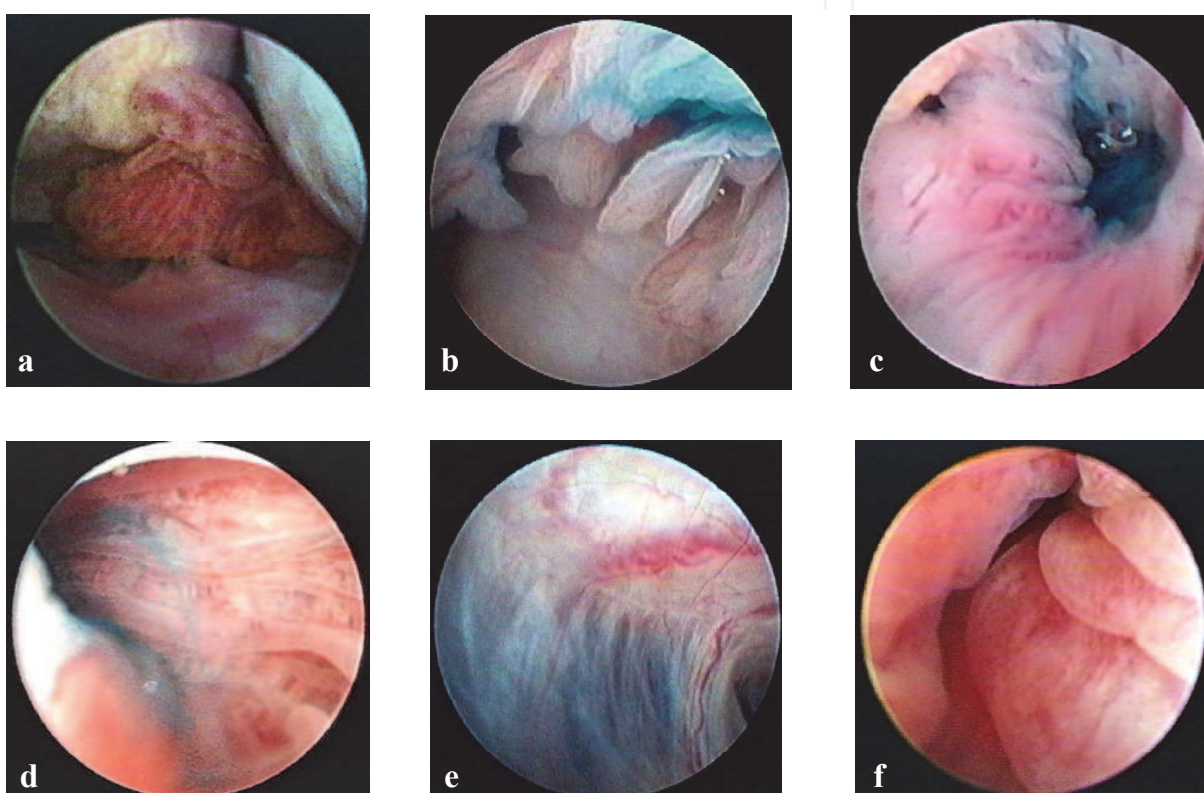


Fig. 3. Visualization of tubo-ovarian structures and salpingoscopy

a) The posterior of the uterus and the bilateral tubo-ovarian structures were carefully observed by THL. The ovary and fimbria are clearly visible. b) Tubal passage was confirmed using indigocarmine. A Hys-cath was inserted into the uterine cavity for the use of chromotubation. c) The endoscope was inserted into the ampulla by the guidance of chromotubation. d) The normal looking tubal mucosa under transvaginal salpingoscopy. e) Unsuccessful salpingoscopy in a case of extensive peritubal adhesion by past *C. trachomatis* infection. f) Endosalpingial edema caused by *C. trachomatis* infection.

We have also been performing salpingoscopy under THL. Consecutive series of 130 infertile women diagnosed tubo-ovarian structures and tubal passage using THL were retrospectively analyzed between May 1999 and November 2003.¹⁷ Access to the pouch of Douglas was achieved in 123 (94.6%) of 130 patients. Twenty-six tubes could not be visualized because of extensive adhesion. Two patients with a history of unilateral salpingectomy and a patient with unicorn uterus were excluded. Therefore, 217 adnexa

were clinically evaluated. The posterior of the uterus and the bilateral tubo-ovarian structures were carefully observed (Figure 3a), and tubal passage was confirmed using indigocarmine (Figure 3b).

In 89 (41.0%) of 217 tubes, a salpingoscopy could be performed. The endoscope was inserted from the fimbria by the guidance of chromotubation (Figure 3c) and the distal part of the tubal mucosa could be observed (Figure 3d). To increase the success of salpingoscopy rates, it may be necessary to stabilize the tubes using grasp forceps to introduce an operative channel demonstrated by Watrelot et al.²²

However, a past history of *C. trachomatis* infection did not seem to influence the success of a salpingoscopy because extensive peritubal adhesion by past *C. trachomatis* infection may disturb visualizing the tubes themselves (Figure 3e). Therefore, we speculate that the successful salpingoscopy rate was similar between women with and without past *C. trachomatis* infection. Typical tubal damages by *C. trachomatis* infection include verruca and atypical vessel formation, peritubal adhesion, and endosalpingial edema (Figure 3f).

4. Transvaginal Hydrolaparoscopic Ovarian Drilling (THLOD)

Polycystic ovary syndrome (PCOS) is a syndrome of ovarian dysfunction showing cardinal features of hyperandrogenism and polycystic ovarian morphology.²³ It is one of the most common reproductive endocrine disorders in young adult women, showing clinical signs of menstrual disorder, anovulation, hirsutism, acne, and obesity. Frequently, this group of patients present with infertility due to chronic oligoovulation or anovulation. Approximately 15 % of patients with PCOS remain anovulatory despite treatment with clomiphene citrate, and half of patients with PCOS who become ovulatory on this treatment fail to conceive.²⁴ The alternative of gonadotropin stimulation or surgical treatment is often the next step for the treatment of clomiphene citrate-resistant infertile women with PCOS.

Since Stein and Leventhal reported that all women menstruated regularly post ovarian wedge resection and some of them conceived,²⁵ ovarian surgery has been used to induce ovulation following unsuccessful medical induction of ovulation. Ovarian surgery has also been indicated in women who hyper-respond to gonadotropin therapy in order to avoid such complications as ovarian hyperstimulation syndrome (OHSS) or multiple gestations.

In recent years, however, because of the rapidly expanding use of techniques involving laparoscopy, surgical treatment has received renewed interest. Laparoscopic ovarian drilling (LOD) by the trans-abdominal approach has been widely used to induce ovulation in women with PCOS after failure of treatment with clomiphene citrate.²⁶ So far, it has been shown that LOD is effective for inducing ovulation, and the pregnancy rate following LOD seems to be acceptable.

Near the end of the 20th century, THL was developed and it was offered for the operative laparoscopy, especially in women with PCOS for ovarian drilling. This novel technique, THLOD using a laser or bipolar electrosurgery, appears to be an effective minimally invasive procedure to induce ovulation in women with PCOS.^{5, 9-13} Fernandez et al.^{9,11} have recently reported the feasibility of ovarian drilling by THL for PCOS. They reported the usefulness of THL for the treatment of PCOS by ovarian drilling. They performed ovarian drilling using bipolar electrosurgery by THL in 80 clomiphene citrate-resistant anovulatory women with PCOS. During a mean follow-up of 18.1 months, 73 (91 %) patients recovered

regular ovulatory cycles. The cumulative pregnancy rate was 60 % for spontaneous and stimulated cycles, with 40% imputed to drilling alone.¹¹ It was suggested that THLOD has the same effectiveness as trans-abdominal LOD. It was also reported that there were no complications.

Our group has also been performing THLOD using a laser.^{10, 12-13} THLOD has 3 advantages when it was compared with gonadotropin treatments for ovulation induction. Ovulation and pregnancy rates are the same as those for gonadotropin treatments. OHSS and multiple pregnancies are reduced. Furthermore, if ovulation is achieved, the frequency of visiting the outpatient clinic for monitoring the follicular status can be reduced. However, THLOD might have some disadvantages, including the risks of anesthetic and operative complications or possible recurrence of oligoovulatory cycles.

So far, 7 infertile women with PCOS, including 5 women with clomiphene citrate-resistant PCOS and 2 women with the risk of developing OHSS, have undergone THLOD. Except for one patient who dropped out of the study, 6 patients resumed having regular ovulatory cycles without developing OHSS. In 4 (67%) of 6 patients, pregnancies were established; one by timed intercourse during the spontaneous cycle, two by intra-uterine insemination following clomiphene-FSH-HCG treatment, and one by IVF-ET. The pregnancy courses in these patients have been uneventful to this point. There were no intra- or postoperative complications of THLOD.¹²

5. Complications

The risk and outcome of bowel injury during THL were previously reported by Gordts et al.²⁷ They carried out a multinational retrospective survey based on confidential, self-reported cases from 39 gynecologists in 18 different countries. In their 3667 procedures, a total of 24 bowel injuries were experienced, giving an incidence of 0.65 %.

In our experience, two cases of bowel injury were diagnosed during 168 diagnostic THL procedures. In both cases, the injuries were extraperitoneal and were treated conservatively with antibiotics without major consequences. No complication occurred during THLOD in 9 patients with PCOS. In total, 2 (1.1 %) of 177 cases were diagnosed with bowel injury.²⁸ In addition to the report by Gordts et al.,¹⁴ we reported our experiences with a review of another series of 549 patients from 9 reported studies published after the year of 2000.²⁸ Only our study reported bowel injury associated with diagnostic THL. Two (0.35 %) of 565 patients from the 9 studies published after the report of Gordts et al.²⁷ suffered bowel injury. There is no significant difference of the incidence (0.65 %) of bowel injuries reported by Gordts et al.²⁷ and that (0.35 %) in the other 9 reports ($P = 0.39$). They also reported that the site of injury involved the extraperitoneal rectum in 21 patients and the rectosigmoid in 3 cases. No leakage of bowel content was reported in their report. Twenty-two (92 %) of the cases were managed expectantly without consequences. These low incidences of major complications should be encouraging for clinicians who have already performed THL as well as those who are now considering introducing THL in their clinics.

As for perforation of the retroflexed uterus, only one case report was obtained.²⁹ The incidence of perforation of the retroflexed uterus was 0.02 %. In this era of wide use of transvaginal ultrasonography, it is likely that such a complication will seldom occur if clinicians carefully perform transvaginal ultrasonography before judging whether THL is indicated.

To avoid possible bowel injury during THL in patients with appropriate indication and without contraindication, prophylactic use of a laxative and/or enema before the procedure

should be considered. Theoretically, it seems that it would be easier to access the pouch of Douglas with less risk if the rectum were not full of stools. Moreover, clinicians should take care when they introduce or re-introduce the Veress needle toward the left pelvic cavity for the anatomical reasons.

6. Conclusion


The usefulness of THL for diagnostic and operative purposes is in no doubt. Moreover, endoluminal assessment by transvaginal salpingoscopy can be simultaneously performed in some infertile women, especially with patent tubes or with regular tubes undergoing THL. Ovarian surgery for the treatment of PCOS has been shown to be useful in anovulatory infertile women who do not respond to medical induction of ovulation. LOD by the trans-abdominal approach has been used to induce ovulation in women with PCOS after failure of treatment with clomiphene citrate. Following the introduction of THL as the first line procedure for the diagnostic laparoscopy, THLOD was developed as an alternative minimally invasive surgery for PCOS patients.

However, informed consent and careful procedure before and during THL/THLOD should be carried out although they can be done on an outpatient clinic basis.

7. References

- [1] Chapron C, Pieere F, Harchaoui Y, et al. Gastrointestinal injuries during gynaecological laparoscopy. *Hum Reprod.* 1999; 14: 333-337.
- [2] Chapron C, Pierre F, Lacroix S, et al. Major vascular injuries during gynecologic laparoscopy. *J Am Coll Surg.* 1997; 185: 461-465.
- [3] Gordts S, Campo R, Rombauts L, et al. Transvaginal hydrolaparoscopy as an outpatient procedure for infertility investigation. *Hum Reprod.* 1998; 13: 99-103.
- [4] Campo R, Gordts S, Rombauts L, et al. Diagnosis accuracy of transvaginal hydrolaparoscopy in infertility. *Fertil Steril.* 1999; 71: 1157-1160.
- [5] Gordts S, Gordts S, Puttemans P, et al. Transvaginal hydrolaparoscopy in the treatment of polycystic ovary syndrome. *Fertil Steril* 2009; 91: 2520-2526.
- [6] Darai E, Dessolle L, Lecuru F, et al. Transvaginal hydrolaparoscopy compared with laparoscopy for evaluation of infertile women: a prospective comparative blind study. *Hum Reprod.* 2000; 15: 2379-2382.
- [7] Shibahara H, Fujiwara H, Hirano Y, et al. Usefulness of transvaginal hydrolaparoscopy in investigating infertile women with Chlamydia trachomatis infection. *Hum Reprod.* 2001; 16: 1690-1693.
- [8] Fujiwara H, Shibahara H, Hirano Y, et al. Usefulness and prognostic value of transvaginal hydrolaparoscopy in infertile women. *Fertil Steril.* 2003; 79: 186-189.
- [9] Fernandez H, Alby J-D, Gervaise A, et al. Operative transvaginal hydrolaparoscopy for treatment of polycystic ovary syndrome: a new minimally invasive surgery. *Fertil Steril.* 2001; 75: 607-611.
- [10] Hirano Y, Shibahara H, Takamizawa S, et al. Application of transvaginal hydrolaparoscopy for ovarian drilling using Nd:YAG laser in infertile women with polycystic ovary syndrome. *Reprod Med Biol.* 2003; 2: 37-40.
- [11] Fernandez H, Watrelot A, Alby JD, et al. Fertility after ovarian drilling by transvaginal fertiloscopy for treatment of polycystic ovary syndrome. *J Am Assoc Gynecol Laparosc.* 2004; 11: 374-378.

- [12] Shibahara H, Hirano Y, Kikuchi K, et al. Postoperative endocrine alterations and clinical outcome of infertile women with polycystic ovary syndrome after transvaginal hydrolaparoscopic ovarian drilling. *Fertil Steril*. 2005; 85: 244-246.
- [13] Shibahara H, Hirano Y, Suzuki M. Transvaginal hydrolaparoscopic ovarian drilling for infertile women with polycystic ovary syndrome. *Cur Wom Health Rev*. 2006; 2: 91-95.
- [14] Diamond E. Diagnostic culdoscopy in infertility: a study of 4000 outpatient procedures. *J Reprod Med*. 1978; 21: 23-28.
- [15] Shibahara H, Hirano Y, Ayustawati, et al. Chemokine bioactivity of RANTES is elevated in the sera of infertile women with past Chlamydia trachomatis infection. *Am J Reprod Immunol*. 2003; 49: 169-173.
- [16] Shibahara H, Takamizawa S, Hirano Y, et al. Relationships between Chlamydia trachomatis antibody titers and tubal pathology assessed using transvaginal hydrolaparoscopy in infertile women. *Am J Reprod Immunol*. 2003; 50: 7-12.
- [17] Suzuki T, Shibahara H, Hirano Y, et al. Feasibility and clinical significance of endoluminal assessment by transvaginal hydrolaparoscopy in infertile women. *J Minim Invasive Gynecol*. 2005; 12: 420-425.
- [18] Shibahara H, Suzuki T, Takamizawa S, et al. Role of transvaginal salpingoscopy. (in) *Atlas of transvaginal endoscopy*. (Ed) Gordts S. Informa Healthcare,. London, UK. 2007, pp 77-84.
- [19] Brosens I, Boeckx W, Delattin P, et al. Salpingoscopy: a new pre-operative diagnostic tool in tubal infertility. *Br J Obstet Gynaecol* 1987; 94: 768-773
- [20] Marchino GL, Gigante V, Gennarelli G, et al. Salpingoscopic and laparoscopic investigations in relation to fertility outcome. *J Am Assoc Gynecol Laparosc* 2001 ; 8; 218-221
- [21] Gordts S, Campo R, Rombauts L, Brosens I. Transvaginal salpingoscopy: an office procedure for infertility investigation. *Fertil Steril* 1998; 70: 523-526
- [22] Watrelot A, Dreyfus JM, Andine JP. Evaluation of the performance of fertiloscopy in 160 consecutive infertile patients with no obvious pathology. *Hum Reprod* 1999; 14: 707-711
- [23] The Rotterdam ESHRE/ASRM-sponsored PCOS consensus workshop group: Revised 2003 consensus on diagnostic criteria and long-term health risks related to polycystic ovary syndrome (PCOS). *Hum Reprod* 2004, 19: 41-47.
- [24] Nugent D, Vandekerckhove P, Hughes E, Arnot M, Lilford R: Gonadotrophin therapy for ovulation induction in subfertility associated with polycystic ovary syndrome. *Cochrane Database Syst Rev* 2000; (4): CD000410.
- [25] Stein IF, Leventhal ML: Amenorrhea associated with bilateral polycystic ovaries. *Am J Obstet Gynecol* 1935; 29: 181-191.
- [26] Neuwirth RS: A method of bilateral ovarian biopsy at laparoscopy in infertility and chronic anovulation. *Fertil Steril* 1972; 23: 361-366.
- [27] Gordts S, Watrelot A, Campo R, et al. Risk and outcome of bowel injury during transvaginal pelvic endoscopy. *Fertil Steril*. 2001; 76: 1238-1241.
- [28] Shibahara H, Shimada K, Kikuchi K, et al. Major complications and outcome of diagnostic and operative transvaginal hydrolaparoscopy. *J Obstet Gynaecol Res* 2007; 33: 705-709.
- [29] Moore ML, Cohen M, Liu GY. Experience with 109 cases of transvaginal hydrolaparoscopy. *J Am Assoc Gynecol Laparosc*. 2003; 10: 282-285.



Advanced Gynecologic Endoscopy

Edited by Dr. Atef Darwish

ISBN 978-953-307-348-4

Hard cover, 332 pages

Publisher InTech

Published online 23, August, 2011

Published in print edition August, 2011

The main purpose of this book is to address some important issues related to gynecologic laparoscopy. Since the early breakthroughs by its pioneers, laparoscopic gynecologic surgery has gained popularity due to developments in illumination and instrumentation that led to the emergence of laparoscopy in the late 1980's as a credible diagnostic as well as therapeutic intervention. This book is unique in that it will review common, useful information about certain laparoscopic procedures, including technique and instruments, and then discuss common difficulties faced during each operation. We also discuss the uncommon and occasionally even anecdotal cases and the safest ways to deal with them. We are honored to have had a group of world experts in laparoscopic gynecologic surgery valuably contribute to our book.

How to reference

In order to correctly reference this scholarly work, feel free to copy and paste the following:

Hiroaki Shibahara, Tatsuya Suzuki and Mitsuaki Suzuki (2011). Diagnostic and Therapeutic Transvaginal Hydrolaparoscopy, Advanced Gynecologic Endoscopy, Dr. Atef Darwish (Ed.), ISBN: 978-953-307-348-4, InTech, Available from: <http://www.intechopen.com/books/advanced-gynecologic-endoscopy/diagnostic-and-therapeutic-transvaginal-hydrolaparoscopy>

INTech
open science | open minds

InTech Europe

University Campus STeP Ri
Slavka Krautzeka 83/A
51000 Rijeka, Croatia
Phone: +385 (51) 770 447
Fax: +385 (51) 686 166
www.intechopen.com

InTech China

Unit 405, Office Block, Hotel Equatorial Shanghai
No.65, Yan An Road (West), Shanghai, 200040, China
中国上海市延安西路65号上海国际贵都大饭店办公楼405单元
Phone: +86-21-62489820
Fax: +86-21-62489821

© 2011 The Author(s). Licensee IntechOpen. This chapter is distributed under the terms of the [Creative Commons Attribution-NonCommercial-ShareAlike-3.0 License](https://creativecommons.org/licenses/by-nc-sa/3.0/), which permits use, distribution and reproduction for non-commercial purposes, provided the original is properly cited and derivative works building on this content are distributed under the same license.

IntechOpen

IntechOpen