

# We are IntechOpen, the world's leading publisher of Open Access books Built by scientists, for scientists

6,900

Open access books available

186,000

International authors and editors

200M

Downloads

Our authors are among the

154

Countries delivered to

TOP 1%

most cited scientists

12.2%

Contributors from top 500 universities



WEB OF SCIENCE™

Selection of our books indexed in the Book Citation Index  
in Web of Science™ Core Collection (BKCI)

Interested in publishing with us?  
Contact [book.department@intechopen.com](mailto:book.department@intechopen.com)

Numbers displayed above are based on latest data collected.  
For more information visit [www.intechopen.com](http://www.intechopen.com)



## Dense Array EEG & Epilepsy

Mark D. Holmes

*Department of Neurology, Regional Epilepsy Center, University of Washington,  
Harborview Medical Center, Seattle  
USA*

### 1. Introduction

Electroencephalographic (EEG) signals derive from the action of neuronal activity in the cerebral cortex, through the action of synchronously occurring post-synaptic potentials of neuronal masses (De Munck et al., 1992). Forming reciprocal combinations of interacting excitatory and inhibitory populations, these neuronal masses are believed to be the sources of the macroscopic EEG signal recorded on the scalp (Freeman, 1975; Wilson & Cowan, 1973; Lopes da Silva & van Leeuwen, 1978). In individuals with epilepsy, seizures emerge from ongoing cortical activity through incompletely understood mechanisms, but are likely related to a wide variety of biochemical, anatomic, physiologic, or genetic aberrations (Avanzini & Franceschetti, 2003; Bragin et al., 2002; D'Ambrosio et al., 2004; D'Ambrosio et al., 2005; Nemani & Binder, 2005; Noebels, 2003; Shah et al., 2004; Stables et al., 2002; White 2002).

For over 50 years the paroxysmal EEG signals ("spikes" or "sharp waves") recorded on the scalp, reflecting the abnormal behavior of cortical neuronal populations, have remained the most important laboratory findings in the clinical evaluation of patients with epilepsy (Niedermeyer, 1999). However, despite the indispensable role of the EEG, the standard assessment has significant limitations. Typically, 16-21 electrodes are placed over the upper portions of the cranium, and under these circumstances distances between individual electrodes are several cm, resulting in inadequate spatial resolution, and an even poorer assessment of cortical activity in basal brain regions. Research on the spatial frequency spectrum suggests that to maximize spatial information of the human EEG ("spatial Nyquist"), interelectrode distances on the cortical surface must be within 1.25 mm (Freeman et al, 2000), and on the scalp, less than 10 mm (Freeman, 2003). As a consequence, analysis of standard EEG recordings yields poor spatial resolution, often results in failure to detect significant pathology, and provides only limited insight into the extent of the involved cortical network and patterns of discharge propagation. It is anticipated that when detailed knowledge of the specific cortical regions activated during epileptiform discharges becomes readily available, that such information will prove to be critical in understanding the nature of an individual subject's seizures and in improving therapy (Spencer, 2002).

Major technological advances are becoming available and will likely change the role and utility of scalp-recorded EEG. One of these advances is the capability for rapid application of a dense array of electrodes, a technique that may also now be employed in the context of

continuous longterm EEG video monitoring (LTM) (Thompson et al, 2008). Recording systems with up to 256 electrodes can provide coverage that includes face and neck, with the goal of “sampling” basal brain regions (e.g. inferior frontal and basal temporal areas), as well the convexity of the cerebrum. By increasing spatial sampling and decreasing the distance between electrodes, dense array EEG (dEEG) results in markedly improved spatial resolution from scalp EEG data (Lantz et al., 2003). Another important technological advance is in the development of physical models of head tissues that allow estimation of neural sources of the EEG (Michel et al., 2001). The combination of superior spatial resolution and sophisticated methods of source analysis, with results registered on realistic magnetic resonance imaging (MRI) models, results in more precise information on electrographic pathology that may be extracted from the scalp EEG (Phillips et al, 2002; Michel et al., 2004).

With this background in perspective, the purpose of this paper is to describe our research in dense array EEG as it applies to epilepsy. The review will include a discussion of the insight that this research has provided in understanding the nature of epileptic circuits, the potential role of dEEG in evaluating difficult seizures, and the direction of future technological developments.

## **2. Methodology**

### **2.1 DEEG recordings**

A 256-channel Geodesic Sensor Net (EGI, Inc, Eugene OR, USA) is applied to each person during the recordings, requiring 10-30 min for application and adjustment (Fig. 1). The net is constructed to include electrode coverage over the face and neck. For an average adult head, interelectrode distances are approximately 20-25 mm. The EEG-amplifier used in our research includes a bandpass of 0.1 to 400 Hz, sampling rate up to 1000 Hz, 16-bit analog-digital conversion, and noise levels engineered typically to 0.6 microvolts root-mean-square. Impedances are maintained at less than 50,000 ohms, consistent with the high input impedance amplifiers employed (Ferree et al., 2001). Continuous longterm EEG-video monitoring (LTM) with dEEG is also now feasible, and we have employed this technique to capture seizures in over 50 patients with medically refractory localization-related seizures, with continuous recordings up to 24-96 hours (Thompson et al., 2008). In our investigations on subjects with refractory generalized seizures, recordings are performed on an outpatient basis, with recording times of sufficient duration to record discharges (60-90 minutes) and with no reduction in subjects' antiseizure medications; these recordings include waking and, and in most cases, drowsy or sleep states.

The 256 channel dEEG is recorded with a common vertex reference, and re-referenced digitally to various montages for inspection, including the average reference. Because of the improved coverage of the inferior head surface, the average reference allows the potential at each index electrode to be examined with reference to an estimate of the zero potential of the head (Bertrand et al., 1985; Dien, 1998; Junghofer et al., 1999). The average-referenced EEG waveforms are examined with topographic waveform plots, a technique that allows inspection of geometric distribution of the potential fields. In addition, topographic maps are created with spherical spline interpolation (Perrin et al., 1987). Dynamic scalp topography of epileptiform discharges with animations can be created at variable time intervals (Tucker et al., 1994).

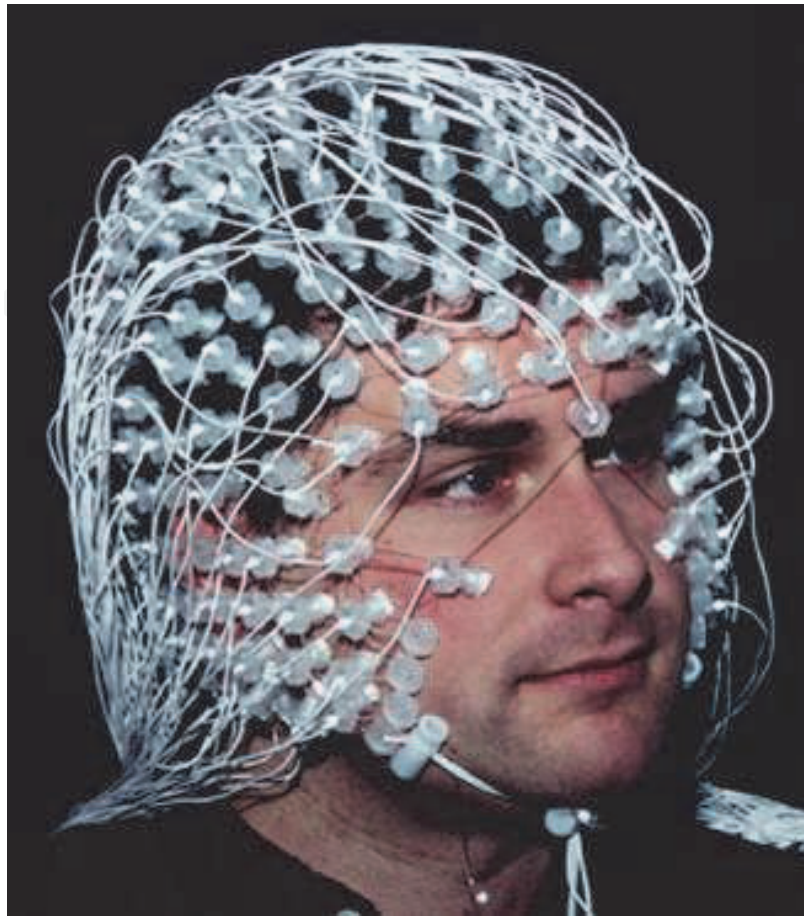


Fig. 1. This model is wearing the 256 channel dense array EEG net. Note the electrode coverage extending over the face and neck.

## 2.2 The “inverse problem”

The principal goal of our research efforts in dEEG is to noninvasively localize brain regions that are involved in the onset and distribution of epileptiform discharges. In other words, our efforts are aimed at solving the “inverse problem”, which in this case is to determine the location of electrical signals originating from the cerebral cortex from recordings obtained on the closed surface of the head. Since there is no unique solution to the inverse problem, achieving viable answers begins with the construction of a brain and head model (“forward model”), based on biologically realistic assumptions, such as the geometry and the electrical properties of head tissues and assuming the cortical origin of scalp-recorded brain signals (Nunez & Srinivasan, 2006). In brief, the method of solving the inverse problem involves use of an appropriate forward model used in conjunction with an inverse algorithm for source analysis. It is important to emphasize that, regardless of the sophistication of the source analysis, the final results may be misleading if the scalp data lacks adequate spatial resolution, or if the researcher fails to recognize or account for non-cerebral artifacts (such as eye movements and muscle potentials) that often contaminate scalp EEG.

## 2.3 DEEG source analysis

As first step in this analysis, one technique of constructing the forward model is specification of an ellipsoidal head with four homogeneous shells: brain, cerebrospinal fluid

(CSF), skull, and scalp. Conductivity ratios that may be used include 1.0 (CSF), .3300 (brain), .0042 (skull), and .3300 (scalp); tissue thicknesses may be specified as 1.0 mm (CSF), 7.0 mm (skull), and 6.0 mm (scalp), with head radius set to 92.5 mm (Berg & Scherg, 1994). An improvement in the forward model may be accomplished by inclusion of a realistic model of head conductivity with finite difference computations (Salman et al., 2005). To provide solutions that are consistent with source analysis techniques regional sources are selected (with dipole moments in three orthogonal directions of space) that are most adequate to describe the discharge complex. Dipole locations are visualized in relation to a standard brain MRI model, with electrodes positioned in relation to skull landmarks in accordance with the international (10-20) EEG system (nasion, periauricular points), and co-registered with the head conductivity model. The positions of the electrodes, with respect to the standard MRI model, are determined by fitting actual 256-channel locations used in the source localization software. These locations are the average cartesian coordinates of the digitized locations from five normal adult subjects.

Several independent methods have been employed in research in regard to the inverse algorithm component to identify electrographic sources, including linear inverse techniques (Pasqual-Marqui et al., 2002; Grave de Peralta Menendez et al., 2004) and equivalent dipole methods (Scherg & Ebersole, 1994; Scherg et al., 2002). Most of our research has utilized the linear inverse method of local autoregressive average (LAURA), which weights the solution distribution so that sources are continuous with nearby activity (Grave de Peralta Menendez et al., 2004). Because the vector fields of electrical sources fall off with the cube of distance (and the potential fields with the square of distance), the LAURA method constrains the solution with a weighting function that assumes the result will have a spatial smoothness with this physical property. The LAURA inverse solutions are implemented within the GeoSource software package used in our research (<http://www.egi.com>), using the head conductivity model and the probabilistic cortical gray matter locations from the Montreal Neurological Institute (MNI) probabilistic atlas ([www.bic.mni.mcgill.ca](http://www.bic.mni.mcgill.ca)) to constrain the location of 2400 source voxels on the standard MRI. Three orthogonal dipole moments (x,y,z) are defined and solved for each of the source voxels.

### 3. Studies of “localization-related” epilepsy

#### 3.1 Comparison with intracranial EEG recordings

One method to test the validity of dEEG is with direct comparison with intracranial EEG recordings performed in the same patients (Holmes et al., 2008; Holmes et al., 2010a). In order to accomplish this, seizures must be captured using dEEG LTM. We have studied 10 consecutive patients with medically refractory localization-related epilepsy, all surgical candidates, who underwent noninvasive evaluation with dEEG LTM studies prior to intracranial EEG recordings. At least twelve months of postoperative clinical outcome for each patient is available.

Standard methods in these 10 subjects, which included, as appropriate in each case, high resolution MRI examinations, standard scalp EEG LTM, single photon emission tomography (SPECT) imaging, positron emission tomography (PET) imaging, neuropsychological testing, and detailed neurological examination, failed to provide adequate ictal localization. For this reason, all individuals required invasive EEG studies to define ictal onsets. Patients with skull defects or previous brain surgery were not offered dEEG studies, since these

would affect source analysis methods. The subjects included 7 males and 3 females, with age range 12-49 years

Prior to intracranial monitoring, the subjects were hospitalized and underwent continuous video-EEG recording long enough to capture one or more habitual seizure, using the 256 channel EEG system, with the exception of one subject, who was studied with 128 channels. The hospital stay was generally shorter (24-96 hours), compared to standard LTM.

The first steps in evaluating the data include screening for artifacts, and removing or digitally interpolating channels degraded by artifact or poor contact (Perrin et al., 1987); from zero to 10 channels were interpolated in the typical 256 dEEG LTM recording in this series. The next phase of analysis typically includes the following: 1) Before actual EEG review, the video recordings are analyzed to determine ictal semiology and time of onset of clinical seizures. 2) The initial electrographic analysis consists of review of the continuous EEG data. Montages using the traditional clinical 10-20 electrode array (30 mm/sec) are first inspected for the purposes of orienting to the head topography and to obtain a general estimate when the ictal onset most likely occurs. 3) EEG characteristics that signify the onset of the seizure are then isolated. This part of the evaluation is complex and subjective because there are often multiple clues to the onset of the seizure, as with any clinical EEG evaluation. Such clues may take place across a considerable amount of time, ranging from milliseconds to seconds, to even minutes. It is not possible simply to select one sample for source localization and consistent findings across multiple seizures increase confidence in the results. The clinical neurophysiologist's interpretation is required to separate the electrographic signs of seizure onset from other EEG features, many of which may be pathological but not indicative of the seizure. For example, in some patients recurring spikes are observed prior to the fully developed seizure; often these early spikes are important for localizing the potential onset of the seizure. In other patients, the EEG may appear relatively "quiescent" prior to the onset of the seizure and more subtle clues are sought, such as slow oscillations (0.5-7 Hz), or focal rhythmic or arrhythmic slowing proximal to the fully developed seizure. 4) Review of the topographic EEG display (topographic waveform plot) of all 256 channels further aids in spatially isolating distinct epileptiform patterns that occur prior to and during the onset of the seizure. With an accurate average reference formed from 256 surface potential channels (approximating the zero sum of all cortical dipoles), the topographic waveform plot illustrates the phase reversals and thus approximate neural sources of epileptiform events. In many cases, ictal patterns emerge when all 256 channels are displayed that are not obvious using only subsampled, standard 10-20 chart views (Fig. 2). 5) Topographic mapping examinations of the electrical potentials at the surfaces of the brain are often aided by two-dimensional Laplacian (the spatial second derivative) computations, using the potentials with spherical splines, in order to estimate radial scalp current density (Tucker et al., 1994).

The invasive EEG recordings obtained in all 10 cases were necessitated by the fact that the initial standard noninvasive evaluation failed to reveal adequate information upon which surgical therapy could be planned. The indications, type of electrodes (subdural grid or strip electrodes), location of electrode placement, and duration of recordings were based on standard clinical criteria. The neurosurgeon was aware of the dense array recordings prior to placement of subdural arrays. However, interpretations of the invasive recordings were made without reference to the dense array predictions of seizure onset, and brain resections were based solely on the analysis of ictal onsets obtained from the invasive EEG recordings.

Of the nine subjects who underwent surgery, eight underwent resections, while one underwent multiple subpial transections (MST), since her seizures originated, in part, within hand motor cortex (Morrell et al., 1989). One subject, who had bitemporal epilepsy, was judged not to be a candidate for resective surgery.

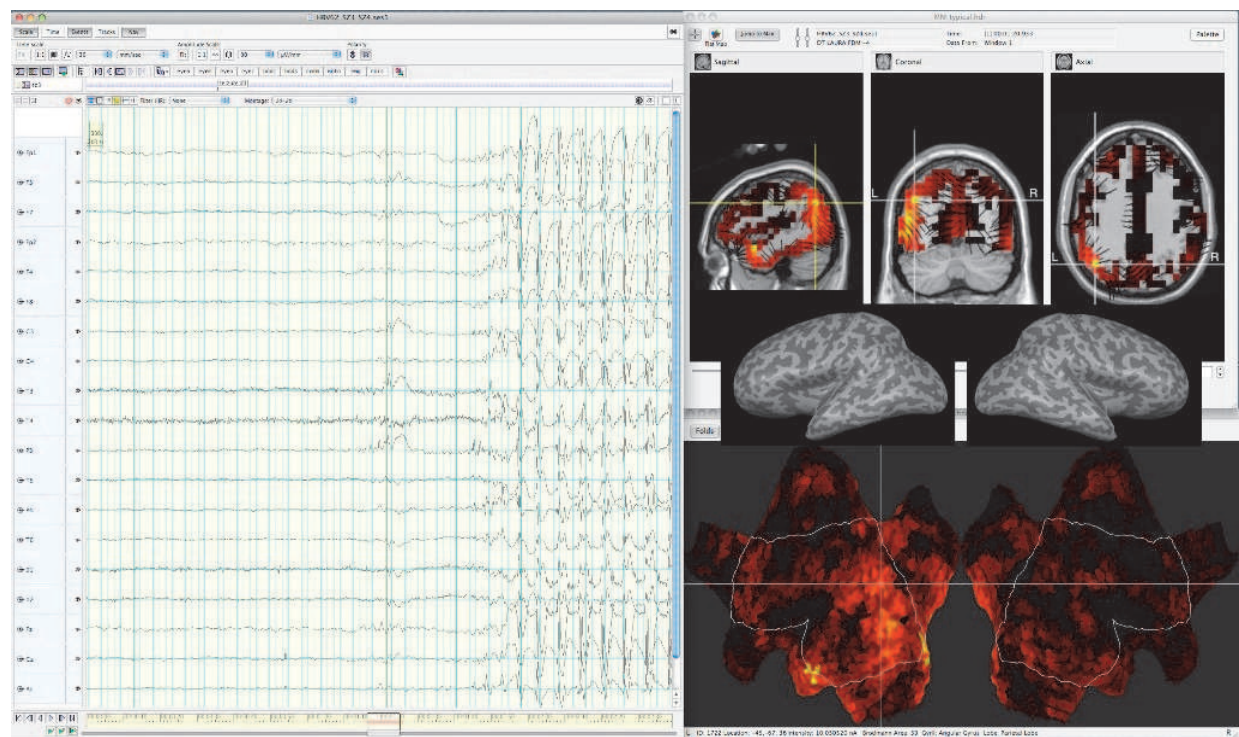


Fig. 2. This figure demonstrates the seizure onset of one subject. The standard EEG (left side) shows that the seizure is heralded by poorly localized discharges over left posterior quadrant. Source analysis of one dEEG-recorded seizure suggests that the onset is localized to left parietal cortex (top right). The “flatmap” of flattened cortical surface of standard MRI used in source analysis denotes regions of maximal intensity with crosshairs (bottom right). See also Fig. 3.

We found ictal localization, estimated from dense array EEG studies, convergent (within approximately 3 cm) in 8 of 10 patients with the intracranial data (Fig. 3). In the two cases where we found divergence of ictal localization, lateralization was the same using both modalities. In two subjects, we found more than one ictal focus with intracranial studies; one of the two foci for each of these two cases was found with dense array recordings. In all instances, the recording times for intracranial LTM (range 7-20 days) exceeded that of dense array LTM. More seizures were recorded during invasive studies compared to dense array recordings, as a result of the longer recording time for intracranial recordings, in nine of the 10 patients.

All patients in the series have been followed at least twelve months after surgery (range 12-40 months). Recorded outcomes are based on both an approximate percentage of seizure reduction and the corresponding Engel classification of postsurgical outcome (Engel et al., 1993). The nine patients who underwent resections or MST were either seizure-free (two patients) or had a clinically significant improvement in seizure frequency or severity at the time of most recent postoperative clinic visit (Engel class 1, 2, or 3). Nonspecific gliosis proved to be the most commonly observed pathological finding.

A detailed study of one case report in this series is illustrative (Holmes et al., 2008). A 13 y/o girl presented with medically refractory, daily complex partial seizures since age 5. Her attacks, each lasting 30-60 sec, consist of the onset of confusion with orofacial and upper extremity automatisms. Standard EEG studies disclosed left occipital and left parietal spikes. Ictal onsets from standard LTM were found to be of probable left posterior quadrant onset, but were poorly localized. MRI was normal. DEEG LTM studies captured one of her typical seizures and disclosed that the seizure originated from left posterior inferior occipital lobe. Within one sec, ictal propagation to right posterior temporal-occipital cortex, and then back to left parietal cortex was found. The patient subsequently underwent invasive LTM, with intracranial subdural grid electrodes placed over left posterior quadrant, and subdural strip electrodes placed bilaterally over posterior quadrants and basal temporal regions. Both ictal onsets and propagation patterns recorded from the invasive EEG studies corresponded closely to that found on the dEEG studies. Surgery was carried out, based on the results of the invasive studies, and the patient has been seizure-free 35 months after resection.

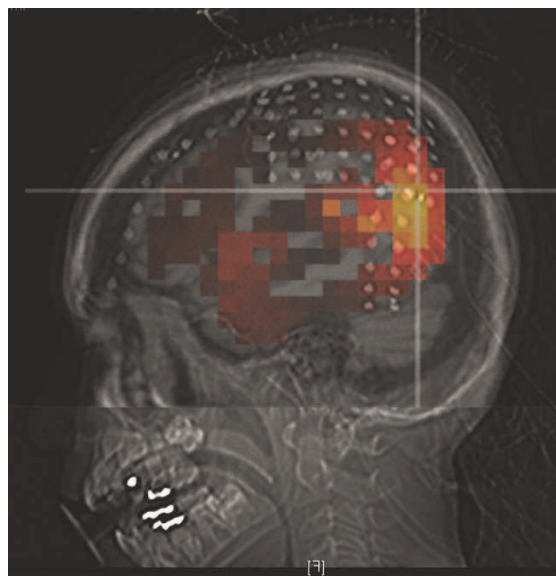


Fig. 3. Source analysis of onset of seizure of subject shown in Fig. 2, co-registered on standard MRI model suggests origin in left parietal cortex (yellow color, with maximal intensity at crosshairs). The figure is also co-registered with subsequent computed tomography showing intracranial electrode placement. Invasive studies revealed left parietal cortical origin of the subject's seizures.

### 3.2 Analysis of interictal spikes in localization-related epilepsy

Interictal dense array EEG studies may be conducted on a short-term, outpatient basis (Phillips et al., 2002; Holmes et al., 2005; Michel et al., 2004) to capture interictal epileptiform discharges. In a study (Holmes et al., 2005) of eight subjects, all surgical candidates, spikes were detected with Reveal software (<http://www.eeg-persyst.com>), and confirmed by visual analysis. For each patient spikes were clustered into populations and each spike population was subjected to source analysis at 10 msec intervals along the time course of the spike, utilizing the linear inverse method of LAURA. Although standard visual analysis suggested that all spike populations in all patients were confined to one temporal lobe region, more complex spatiotemporal patterns of spike propagation were often observed in

the dense array EEG data. In some cases, sources indeed remained confined to one temporal lobe throughout the duration of the spike. In other instances, however, propagation spread rapidly from basal temporal to lateral temporal lobe, to orbitofrontal cortex, and finally to the opposite temporal lobe. These findings may give credence to the concept that temporal lobe epilepsy may be a bilateral corticolimbic network disturbance in some patients (Spencer, 2002; Ebersole, 1997). A recent study that compared simultaneously dEEG with intracranial subdural recordings in subjects with temporal lobe epilepsy offers confirmatory evidence that dEEG, when used in conjunction with realistic source analysis and head model, accurately localizes interictal discharges to medial temporal structures (Yamazaki et al., 2010). This same study also shows that 47% of all intracranial-recorded spikes are detected by dEEG, with the average detectable dEEG spike approximately 1  $\mu$ V in amplitude. Furthermore, the findings in this comparative study suggests that dEEG provides more precise information regarding deep spike foci than either conventional EEG or magnetoencephalography. Future research is necessary to answer the question as to whether or not spike propagation patterns encapsulate the cortical network involved during clinical seizures.

## **4. Studies of “generalized” seizures**

### **4.1 Absence seizures**

The conventional classification of epileptic seizures is based on the International League Against Epilepsy dichotomy that epileptic seizures are either “partial” (localization-related) or “generalized” (Commission on Classification and Terminology of the International League Against Epilepsy, 1989). This scheme implies that partial seizures have discrete focal origins, while generalized seizures are assumed to occur without lateralizing or localizing features that include bilateral, global cortical activation at ictal onset (Panayiotopoulos, 2002). Experimental evidence that implicates thalamic and thalamocortical mechanisms in the pathophysiology of generalized seizures has been offered as an explanation for the apparently “generalized” nature of these seizures (Gloor, 1978; McCormick, 2002; Slaght et al., 2002).

The absence seizure is often considered the prototypic idiopathic generalized seizure. Although the concept of generalized seizures persists in clinical practice, traditional EEG visual analysis emphasized a frontal preponderance of the spike-wave complexes in absence (Niedermeyer, 1999) and early studies in source analysis suggested that, although bilateral at onset, the ictal patterns in absence localized to frontal cortex (Rodin et al., 1994). Research using dense array EEG provides further evidence that the traditional concept of “generalized” epilepsy may not be accurate. Recent studies of absence in five patients using 256 channel dEEG recordings showed that both at onset and during propagation, the discharges in absence are associated with activation of only discrete regions of mainly medial frontal and orbital frontal cortex (Holmes et al., 2004). Detailed studies of the ictal discharges in absence, the onsets of which develop rapidly, suggest that the waveforms may best be described as “wave-spike”, rather than “spike-wave”. Though individual variability between subjects may exist, typically the initial slow wave follows oscillations localized to medial frontal regions, then exhibits anterior propagation and abrupt transition over the frontal pole as a positive spike displaces the diffuse anterior negative slow wave, with the discharge then sweeping posteriorly along the orbital frontal cortex.

Separately, Tucker et al (Tucker et al., 2007) analyzed the same data collected for the Holmes et al., 2004 study, using the LAURA inverse, and an improved high resolution finite difference head conductivity model, that showed a “flatmap” display of the cortical surface using GeoSource software. Overall, the results were convergent with the earlier report. For each seizure in each patient the slow wave of the wave-spike cycle engaged networks of mainly medial frontal, and occasionally temporal, cortical networks. Invariably, this was followed by primary current source distribution in ventromedial frontal cortex during the abrupt wave-spike transition. Although differences were found between individual patients, particularly during in the slow wave and the oscillatory EEG changes in the second or so prior to ictal onset, each seizure rapidly progressed to a stereotyped pattern with major spike discharges localized to midline frontal networks.

#### 4.2 Studies in juvenile myoclonic epilepsy

We also evaluated epileptiform discharges in 10 patients with the idiopathic generalized epilepsy syndrome of juvenile myoclonic epilepsy (JME) (Holmes et al, 2010b). In this syndrome, seizures begin typically in adolescence, do not remit, and may be characterized by absence, myoclonic, or generalized tonic-clonic attacks. The neurological examination and magnetic resonance imaging studies are normal, and discharges (based on standard EEG) is classically shown to exhibit generalized 4-6 Hz spike or multiple spike-slow wave complexes. In this study, each subject underwent 1-2 hours of outpatient recording using a 256 channel dEEG system and epileptiform discharges were captured in all cases. Analysis of epileptiform patterns disclosed that in many cases the results were, not surprisingly, similar to absence, with activation of mesial frontal and orbital frontal regions found in all cases (Figs 4, 5). Involvement of other midline regions (anterior or posterior cingulum) was observed in 4/10 subjects. Importantly, in 6/10 (60%) of the patients, the epileptiform circuit included mesial temporal lobe. The common denominator in all cases of JME is engagement of orbitofrontal and medial frontal cortical regions. Independent research findings from other investigators who have examined JME and absence epilepsy with other modalities, including MRI volumetric analysis (Tae et al., 2008), diffuse tensor imaging (Deppe et al., 2006), magnetic resonance spectroscopy (Lin et al., 2009), and functional MRI (Bai et al, 2010) have all implicated focal cortical involvement in “generalized epilepsies”, particularly discrete regions of frontal and temporal lobe

Epileptic seizures may involve only specific cortical networks. Analysis of ictal patterns in both generalized and localization-related seizures with dense array EEG leads to an interpretation that all seizures, including those classified as “generalized”, involve only specific cortical networks. The standard classification of epileptic seizures is a reflection of the inadequacy of conventional EEG analysis, where spatial resolution is at best limited. Furthermore, consideration of the regions of cortical involvement at the onset and during propagation may also lead to the hypothesis that epileptic seizures may be considered as fundamentally corticothalamic or corticolimbic in nature. Discharges in absence seizures and in JME invariably involve discrete regions of orbital and medial frontal cortex, and by inference that is based on mammalian research, the thalamic reticular nucleus (TRN), with sparing of limbic circuits (Futatsugi & Riviello, 1998; Steriade, 2003). Absence may be the prototype of the corticothalamic (“generalized”) seizure in which corticothalamic mechanisms interact with TRN networks and therefore influence thalamocortical projections and widespread cortical regions (Zikopoulos & Barbas, 2006). In contrast, the temporal lobe

seizure may be the prototype of the corticolimbic (“localization-related” or “partial” seizure. However, some frontal lobe seizures may also show spread to ventomedial frontal cortex, in a manner similar to absence, and thus may also be considered as “corticothalamic” seizures. On the other hand, some extratemporal seizures show propagation to temporal lobe structures. Seizures classically considered to be localization-related may therefore exhibit patterns consistent with primary involvement of either corticothalamic or corticolimbic circuits. The detailed study of the specific networks involved in the major types of epileptic seizures may have broader implications as well. Close examination of how consciousness breaks down in epileptic seizures most certainly offers clues to the underlying mechanisms that bind consciousness within the large-scale networks of the cerebral cortex (Tucker & Holmes, 2011).




Fig. 4. Topographic display of onset of epileptiform discharges in subject with juvenile myoclonic epilepsy. Note that the discharges are not “generalized”, but rather are maximal in amplitude in anterior-midline regions, and slightly lateralized to the left side. See also Fig. 5.

## 5. The potential role of dense array EEG in the presurgical evaluation

In addition to suggesting new insights into anatomical mechanisms of epilepsy, dEEG may be useful in assisting in localizing the site of seizure onset. Ideally, this determination should be made noninvasively, but in practice, at least 30-50% of surgical candidates will require some form of intracranial EEG evaluation, including the majority of individuals with difficult extratemporal epilepsy (Holmes, 2006). DEEG may hold the promise to assist in ictal localization, when standard EEG methods fail, and may reduce the need for invasive studies. However, the present evidence is preliminary, as presented earlier in this chapter, and further research and validation studies are needed to establish the precise role of this technique in the presurgical evaluation; such research is necessary since complete concordance of dEEG and

intracranial EEG findings is not yet available. At the very least, however, it is likely that dEEG will eventually assist in guiding the placement of invasive electrodes in some cases. As a corollary, the method may also eventually assist in planning the intracranial placement of novel treatment devices (Motamedi & Lesser, 2006). Unique methods of analyzing interictal segments of dEEG may also prove useful in localizing the epileptogenic zone. A recent study that analyzed one-minute random, interictal segments of seizure and spike-free dEEG found that the intracranially proven epileptogenic zone corresponded closely to regions of focal increases in scalp dEEG 20-50 Hz synchronization and simultaneous decreases in coupling of theta and gamma frequencies (Fig. 6) (Ramon et al., 2008)

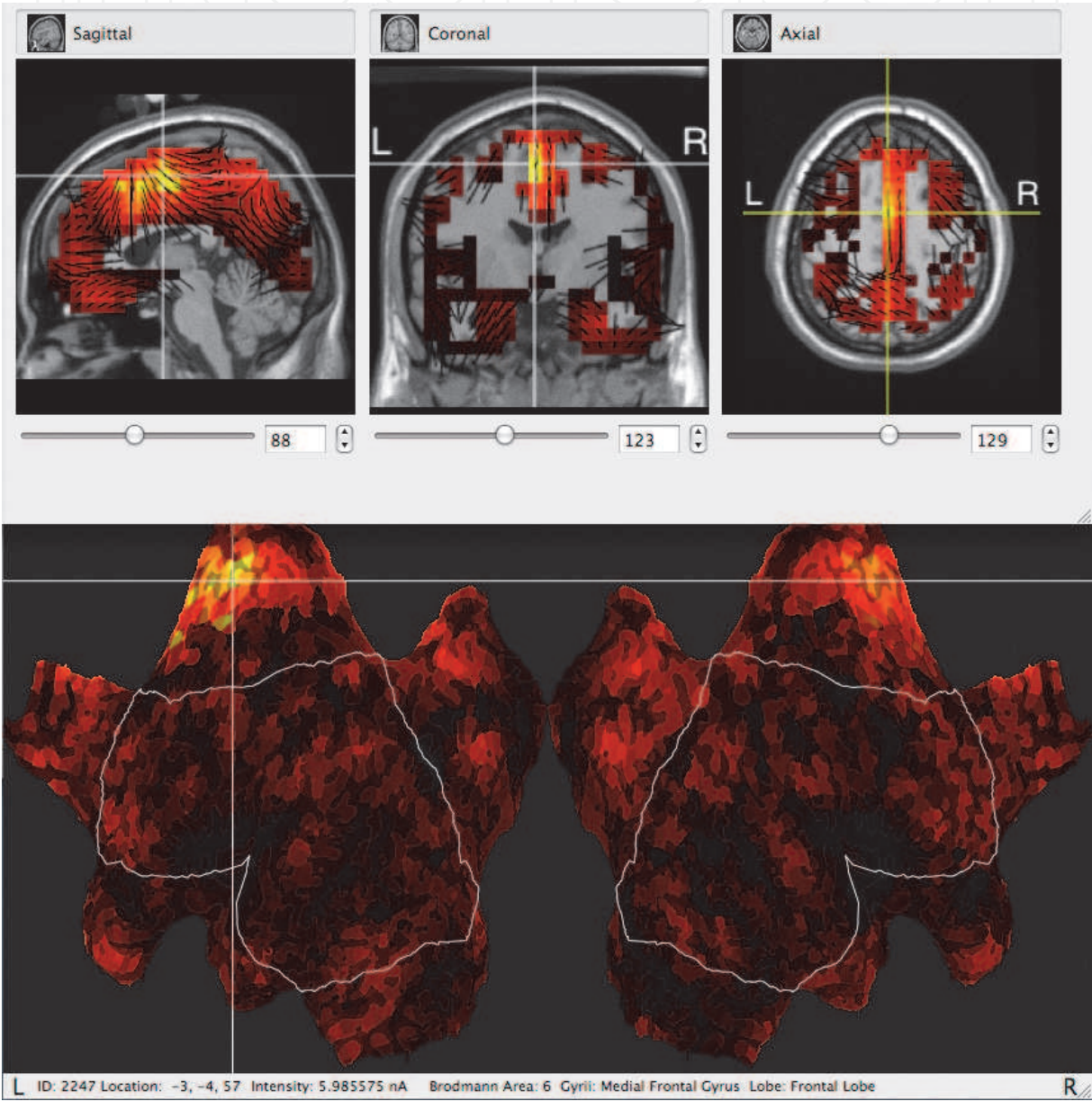


Fig. 5. Source analysis of onset of discharges in Fig. 4 (top) suggest localization of onset in medial frontal cortex. The flatmap (bottom) shows the flattened cortical surface of the standard MRI model used in source analysis, with regions of maximal intensity denoted by crosshairs.

In addition to the role that the method may play in assisting in defining the epileptogenic in the presurgical evaluation, dEEG may also prove useful in lateralizing, and even localizing, essential language regions and motor function. A recent study in surgical candidates that examined covert naming revealed that focal increases in power of 3-7 Hz and 20-50 Hz frequencies on dEEG lateralized to the same language-dominant side as predicted by the Wada test (Ramon et al., 2009a). These patterns are not apparent on standard EEG, again emphasizing the importance of improved spatial resolution provided by dEEG. Another study that examined motor mapping of thumb and little finger using subject-specific head models and simultaneous dEEG and fMRI demonstrated convergence between the two modalities (Luu & Tucker, 2010).

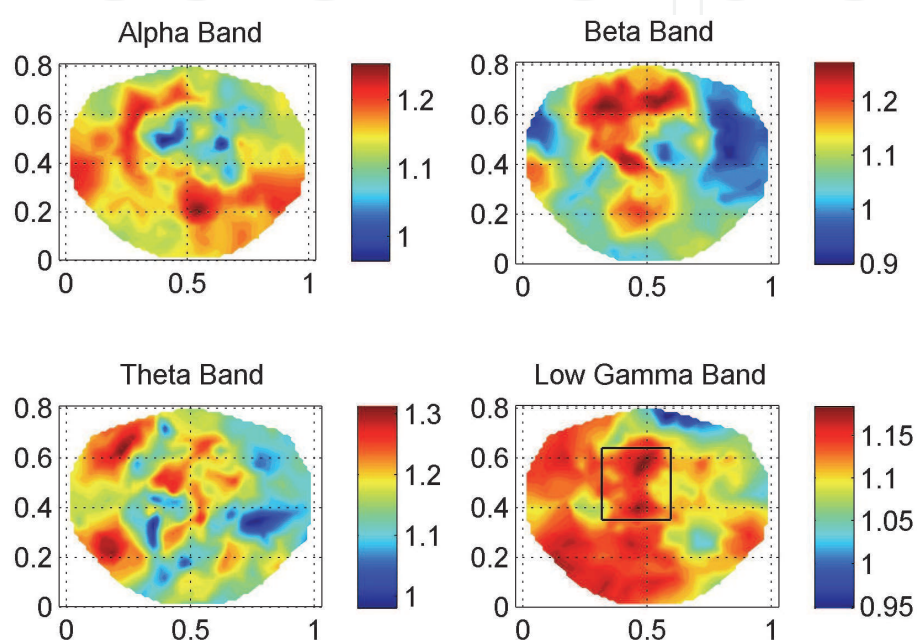


Fig. 6. Random segment of interictal dEEG free of visually apparent epileptiform discharges discloses focal increases in low gamma power (30-50 Hz) that corresponds to intracranially proven epileptogenic zone (in box, left medial frontal region) (Ramon et al, 2008).

## 6. Future research

Technological development in dense array EEG is anticipated in several areas with the aims of improving methodology and reliability. Firstly, the current forward model used in source analysis calculations, which utilizes a standard MRI or ellipsoidal multi-shell model, may be replaced by the individual patient's own MRI. Research is currently underway to feasibly incorporate patient-specific MRIs into source analysis algorithms. Secondly, more than 256 electrodes may eventually be recorded simultaneously from the scalp. Given that the spatial Nyquist of the human scalp EEG necessitates intersensor distances less than 3-5 mm (Freeman et al, 2003), as many as 1500 electrodes, or more, may be required to reduce interelectrode distances to achieve the ideal dimension. Furthermore, recent studies also suggest that when optimal scalp EEG spatial resolution is obtained, examination of spatial frequency patterns even make possible the extraction of details of the cortical surface anatomy, including gyral and sulcal patterns (Ramon et al., 2009b). Other future developments are likely to include the incorporation of advances in the quantitative

evaluation of the onset and propagation of ictal EEG patterns, including analysis of direct current (ultraslow) frequencies (Vanhatalo et al., 2003; Miller et al., 2007), high frequency EEG (Worrell et al., 2004), and coherence and spatial pattern analysis (Freeman et al., 2006). Finally, the utility of dense array EEG in source localization of cortical activity can be evaluated, and improved, through joint recordings with whole-head magnetoencephalography (Liu et al., 2002). Future research will establish the clinical utility and role of each of these newer methods in extending the information from scalp EEG recordings.

## 7. Disclosure statement

The author has received no financial support, consulting fees, or research funding for the work described in this manuscript. He has no conflict of interest, financial or otherwise, in regard to the research described in this report


## 8. References

- Avanzini G & Franceschetti S. (2003). Cellular biology of epileptogenesis. *Lancet Neurology* 2(1):33-42.
- Bai X, Vestal M, Berman R, Negishi M, Spann M, Vega C, Desalvo M, Novotny E, Constable R & Blumenthal H. (2010). Dynamic time course of typical absence seizures: EEG, behavior, and functional magnetic imaging. *J Neurosci* 30(17):5884-5893.
- Berg P & Scherg M. (1994). A fast method for forward computation of multiple-shellspherical head models. *Electroencephalogr Clin Neurophysiol* 90:58-64.
- Bertrand O, Perrin F & Pernier J. (1985). A theoretical justification of the average-reference in topographic evoked potential studies. *Electroencephalogr Clin Neurophysiol* 62:678-695.
- Bragin A, Mody I, Wilson C & Engel J Jr. (2002). Local generation of fast ripples in epileptic brain. *J Neurosci* 22:2012-2021.
- Commission on Classification and Terminology of the International League Against Epilepsy. (1989). Proposal for revised classification of epilepsies and epileptic syndromes. *Epilepsia* 30:389-99.
- D'Ambrosio R, Fairbanks J, Fender J, Born D, Doyle D & Miller J. (2004). Post-traumatic epilepsy following fluid percussion injury in the rat. *Brain* 127:304-314.
- D'Ambrosio R, Fender J, Fairbanks J, Simon E, Born D, Doyle D & Miller J. (2005). Progression from fronto-parietal to mesial-temporal epilepsy after fluid percussion injury in the rat. *Brain* 128(Pt 1):174-188.
- De Munck J, Vijn P & Lopes da Silva F. (1992). A random dipole model for spontaneous brain activity. *IEEE Biomed Eng* 39:791-804.
- Deppe M, Kellinghaus C, Duning T, Modell G, Mohammadi S, Deppe K, Schiffbauer H, Kugel H, Keller S, Ringelstein E & Knecht S. (2008). Nerve fiber impairment of anterior thalamic circuitry in juvenile myoclonic epilepsy. *Neurology* 71:1981-1986
- Dien J. (1998). Issues in the application of the average reference: review, critiques, and recommendations. *Behav Res Method Instrum Comput* 30:34-43.
- Ebersole J. (1997). Defining epileptogenic foci: past, present, and future. *J Clin Neurophysiol* 14(6):470-483.
- Engel J Jr, Van Ness P, Rasmussen T & Ojemann L. Outcome with respect to epileptic seizures. (1993) In: *Surgical Treatment of the Epilepsies*, Engel J Jr (ed), pp 609-621. Raven Press, New York.

- Ferree T, Luu P, Russell G & Tucker D. (2001) Scalp electrode impedance, infection risk, and EEG data quality. *Clin Neurophysiology* 112: 536-544.
- Freeman W. (1975). *Mass Action in the Nervous System*. Academic Press, New York.
- Freeman W, Rogers L, Holmes M & Silbergeld D. (2000). Spatial spectral analysis of human electrocorticograms including the alpha and gamma Bands. *J Neurosci Methods* 15; 95(2):1111-1121.
- Freeman W, Holmes M, Burke B & Vanhatalo S. (2003). Spatial spectra of scalp EEG and EMG from awake humans. *Clin Neurophysiol* 114:1053-1069.
- Freeman W, Holmes M, West G & Vanhatalo S. (2006). Fine-grain spatiotemporal infrastructure of phase in human intracranial EEG. *Clin Neurophysiol* 117:1228-1243.
- Grave de Peralta Menendez R, Murray M, Michel C, Martuzzi R & Gonzalez Andino S. (2004). Electrical neuroimaging based on biophysical constraints. *Neuroimage* 21:527-539.
- Futatsugi Y & Riviello J. (1998). Mechanisms of generalized absence epilepsy. *Brain & Development* 20:75-79.
- Gloor P. (1978). Generalized epilepsy with bilateral synchronous spike and wave discharges: new findings concerning its physiological mechanisms. *Electroencephalogr Clin Neurophysiol Suppl* 34:245-249.
- Holmes M, Brown M & Tucker D. (2004). Are “generalized” seizures truly generalized? Evidence of localized mesial frontal and frontopolar discharges in absence. *Epilepsia* 45(12):1568-1579.
- Holmes M, Brown M & Tucker D. (2005). Dense array EEG and source analysis reveal spatiotemporal dynamics of epileptiform discharges. *Epilepsia* 46 (Suppl 8):136 (abstract).
- Holmes M. (2006). Neurophysiological Studies. In: *Epilepsy Surgery: Principles & Controversies*, Miller J, Silbergeld D (eds). pp 247-269. Francis & Taylor, New York.
- Holmes M, Brown M, Tucker D, Saneto R, Miller K, Wig G & Ojemann J. (2008). Localization of extratemporal seizure with noninvasive dense array EEG. *Pediatric Neurosurgery* 44(6):474-479.
- Holmes M, Tucker D, Quiring J, Hakimian S, Miller J & Ojemann J. (2010a). Comparing dense array EEG and intracranial EEG for source localization of seizures. *Neurosurgery* 66 (2):354-362.
- Holmes M, Brown M & Tucker D. (2010b) Evidence that juvenile myoclonic epilepsy is disorder of frontothalamic corticothalamic networks. *Neuroimage* 49(1):80-93.
- Junghofer M, Elbert T, Tucker D & Braun C. (1999). The polar average reference effect: a bias in estimating the head surface integral in EEG recording. *Clin Neurophysiol* 110:1149-1155.
- Lantz G, Grave de Peralta R, Spinelli L, Seeck M & Michel C. (2003). Epileptic source localization with high density EEG: how many electrodes are needed? *Clin Neurophysiol* 114:63-69
- Lin K, Carrette H Jr, Lin J, Peruchi M, Filho G, Guaranha M, Guilhoto L, Sakamoto A & Yacubian E. (2009). Magnetic resonance spectroscopy reveals an epileptic network in juvenile myoclonic epilepsy. *Epilepsia* 50(5):1191-2000
- Liu A, Dale A & Belliveau J. (2002). Monte Carlo simulation studies of EEG and MEG localization accuracy. *Hum Brain Mapp* 16:47-62.
- Lopes da Silva F, Storm van Leeuwen W (1978). The cortical alpha rhythm in dog: The depth and surface profile of phase. In: *Architectonics of Cerebral Cortex*. Brazier M, Petsche H (eds). Raven Press, New York.

- Luu P & Tucker D. (2010). Simultaneous EEG-fMRI recordings of activity from primary motor cortex in a single subject. *Human Brain Mapping Conference*, June 5-10, Barcelona, Spain (abstract).
- McCormick D. (2002). Cortical and subcortical generators of normal and abnormal rhythmicity. *Int Rev Neurobiol* 49:99-114.
- Michel C, Thut G, Morand S, Khateb A, Pegna A, Grave de Peralta R, Gonzales S, Seeck M & Landis T. (2001). Electric source imaging of human brain function. *Brain Res Rev* 36:108-118.
- Michel C, Murray M, Lantz G, Gonzales S, Spinelli L & Grave de Peralta R. (2004). EEG source imaging. *Clin Neurophysiol* 115(10):2194-2222.
- Miller J, Kim W, Holmes M & Vanhatalo S. (2007). Ictal localization by source analysis: analysis of infraslow activity in DC-coupled scalp EEG recordings. *Neuroimage* 35(2):583-597.
- Morrell F, Whisler W, Bleck T. (1989) Multiple subpial transaction: a new approach to the surgical treatment of focal epilepsy. *J Neurosurg* 70:231-239.
- Motamedi G & Lesser R. (2006). Prospects for developing electrical stimulation of the cortex for treatment of intractable seizures. In: *Epilepsy Surgery: Principles & Controversies*, Miller J, Silbergeld D (eds). pp 810-819, Francis & Taylor, New York.
- Nemani V & Binder D. (2005). Emerging role of gap junctions in epilepsy. *Histol Histopathol* 20(1):253-259.
- Niedermeyer E. (1999). Abnormal EEG patterns: epileptic and paroxysmal. In: *Electroencephalography: Basic Principles, Clinical Applications, and Related Fields* (4<sup>th</sup> edition). Niedermeyer E, Lopes da Silva F (eds). pp 235-260, Williams & Wilkins, Baltimore.
- Noebels J. (2003). The biology of epilepsy genes. *Annu Rev Neurosci* 26:599-625.
- Nunez P, Srinivasan R. (2006). *Electric Fields of the Brain: Neurophysics of EEG* (2<sup>nd</sup> edition). Oxford University Press, New York.
- Pasqual-Marqui R, Essen M, Kochi K & Lehmann D. (2002). Functional imaging with low-resolution brain electromagnetic tomography (LORETA): a review. *Method Find Exp Clin Pharmacol* 24 Suppl C:91-95.
- Panayiotopoulos C. (2002). Idiopathic generalized epilepsies. In: *A Clinical Guide to Epileptic Syndromes and their Treatment*, Panayiotopoulos C. pp 114-160, Bladen Medical Publishing, Oxfordshire, UK.
- Perrin F, Pernier J, Bertrand O, Giard M & Echallier J (1987). Mapping of scalp potentials by surface spline interpolation. *Electroencephalogr Clin Neurophysiol* 66:75-81.
- Phillips C, Rugg M & Friston K. (2002). Anatomically informed basis functions for EEG source localization: Combining functional and anatomical constraints *Neuroimage* 16:678-695.
- Ramon C, Holmes M, Freeman W, McElroy R & Rezvanian E. (2008). Comparative analysis of temporal dynamics of EEG and phase synchronization of EEG to localize epileptic sites from high density scalp EEG interictal recordings. *30<sup>th</sup> Conf Proc IEEE Eng Med Biol Soc* 4538-4550.
- Ramon C, Holmes M, Freeman W, Gratkowski M, Eriksen J & Haueisen J. (2009a), Power spectral density changes and language lateralization during covert object naming tasks measured with high-density EEG recordings. *Epilepsy Behav* 14:54-59.
- Ramon C, Freeman W, Holmes M, Ishimaru A, Haueisen J, Schimpf P & Rezvanian E (2009b). Similarities between simulated spatial spectra of scalp EEG, MEG, and structural MRI. *Brain Topogr* 22:191-196.

- Rodin E, Rodin M & Thompson J. (1994). Source analysis of generalized spike-wave wave complexes. *Brain Topogr* 7:113-119.
- Salman A, Turovets S, Malony A, Eriksen J & Tucker D. (2005). Computational modeling of human head conductivity. Paper presented at *Computational Science-ICCS 5<sup>th</sup> International Conference*. Atlanta, GA, USA (abstract).
- Scherg M & Ebersole J. (1994). Brain source imaging of focal and multifocal epileptiform EEG activity. *Clin Neurophysiol* 24:51-60.
- Scherg M, Ille N, Bornfleth H & Berg P. (2002). Advanced tools for digital EEG review: virtual source montages, whole-head mapping, correlation, and phase analysis. *J Clin Neurophysiol* 19:91-112.
- Shah M, Anderson A, Leung V, Lin X, & Johnston D. (2004). Seizure-induced plasticity of *h* channels in entorhinal cortical layer III pyramidal neurons. *Neuron* 44(3):495-508.
- Slaght S, Leresche N, Deniau J, Crunelli V & Charpier S. (2002). Activity of thalamic reticular neurons during spontaneous genetically determined spike and wave discharges. *J Neurosci* 22:2323-2334.
- Spencer S. (2002). Neural networks in human epilepsy: evidence of and implications for treatment. *Epilepsia* 43(3):219-227.
- Stables J, Bertram E, White H, Coulter D, Dichter M, Jacobs M, Loscher W, Lowenstein D, Moshe S, Noebels J & Davis M (2002). Models for epilepsy and epileptogenesis: Report from the NIH workshop, Bethesda, Maryland. *Epilepsia* 43(11): 1410-1420.
- Steriade M (2003). *Neuronal Substrates of Sleep and Epilepsy*. New York: Cambridge University Press.
- Tae W, Kim S, Joo E, Han S, Kim I, Kim S, Lee J-M & Hong S. (2008). Cortical thickness abnormality in juvenile myoclonic epilepsy. *J Neurol* 255(4):561-566.
- Thompson P, Rae J, Weber L, Pearson C, Goldshtein Z & Holmes M. (2008). Long-term seizure monitoring using a 256 contact dense array system. *Am J ENDO Tech* 48:93-106.
- Tucker D, Liotti M, Potts G, Russell G & Posner M. (1994). Spatiotemporal analysis of brain electrical fields. *Hum Brain Mapp* 1:134-152.
- Tucker D, Brown M, Luu P & Holmes M. (2007). Discharges in ventromedial frontal cortex during absence spells. *Epilepsy Behav* 11 (4):546-557.
- Tucker D & Holmes M. (2011). Fractures and bindings of consciousness: studying how seizures impair awareness may yield clues to the way that conscious experience is organized within large-scale cerebral networks. *American Scientist* January-February: 32-39.
- Vanhatalo S, Holmes M, Tallgren P, Voipio J, Kaila K & Miller J. (2003). Very slow EEG responses lateralizes temporal lobe seizures: a noninvasive DC-EEG study. *Neurology* 60(7):1098-1103.
- White H. (2002). Animal models of epileptogenesis. *Neurology* 59(9) Suppl 5: S7-S14.
- Wilson H & Cowan J. (1973). A mathematical theory of the functional dynamics of cortical and thalamic nervous tissue. *Kybernetik* 13:55-80.
- Worrell G., Parish L, Cranstoun S, Jonas R, Baltuch G & Litt B. (2004). High-frequency oscillations and seizure generation in neocortical epilepsy. *Brain* 127(Pt7), 1496-1506.
- Yamazaki M, Tucker D, Fujimoto A, Yamazoe T, Okanishi Tohru T, Yokota T, Enoki H & Yamamoto T. (2010). Comparison of dense array EEG with simultaneous intracranial ECoG for interictal spike detection and localization. *American Epilepsy Society Annual Meeting*, San Antonio Tx, Dec 4-7 (abstract).
- Zikopoulos B & Barbas H. (2006). Prefrontal projections to the thalamic reticular nucleus from a unique circuit for attentional mechanisms. *J Neurosci* 26 (28):7348-7361.



## **Management of Epilepsy - Research, Results and Treatment**

Edited by Prof. Mintaze Kerem G nel

ISBN 978-953-307-680-5

Hard cover, 194 pages

**Publisher** InTech

**Published online** 15, September, 2011

**Published in print edition** September, 2011

Epilepsy is one of the most common neurological disorders, with a prevalence of 4-10/1000. The book contains the practical methods to approaching the classification and diagnosis of epilepsy, and provides information on management. Epilepsy is a comprehensive book which guides the reader through all aspects of epilepsy, both practical and academic, covering all aspects of diagnosis and management of children with epilepsy in a clear, concise, and practical fashion. The book is organized so that it can either be read cover to cover for a comprehensive tutorial or be kept desk side as a reference to the epilepsy. Each chapter introduces a number of related epilepsy and its diagnosis, treatment and co-morbidities supported by examples. Included chapters bring together valuable materials in the form of extended clinical knowledge from practice to clinic features.

### **How to reference**

In order to correctly reference this scholarly work, feel free to copy and paste the following:

Mark D. Holmes (2011). Dense Array EEG & Epilepsy, Management of Epilepsy - Research, Results and Treatment, Prof. Mintaze Kerem G nel (Ed.), ISBN: 978-953-307-680-5, InTech, Available from: <http://www.intechopen.com/books/management-of-epilepsy-research-results-and-treatment/dense-array-eeeg-epilepsy>

**INTECH**  
open science | open minds

### **InTech Europe**

University Campus STeP Ri  
Slavka Krautzeka 83/A  
51000 Rijeka, Croatia  
Phone: +385 (51) 770 447  
Fax: +385 (51) 686 166  
[www.intechopen.com](http://www.intechopen.com)

### **InTech China**

Unit 405, Office Block, Hotel Equatorial Shanghai  
No.65, Yan An Road (West), Shanghai, 200040, China  
中国上海市延安西路65号上海国际贵都大饭店办公楼405单元  
Phone: +86-21-62489820  
Fax: +86-21-62489821

© 2011 The Author(s). Licensee IntechOpen. This chapter is distributed under the terms of the [Creative Commons Attribution-NonCommercial-ShareAlike-3.0 License](https://creativecommons.org/licenses/by-nc-sa/3.0/), which permits use, distribution and reproduction for non-commercial purposes, provided the original is properly cited and derivative works building on this content are distributed under the same license.

IntechOpen

IntechOpen