

We are IntechOpen, the world's leading publisher of Open Access books Built by scientists, for scientists

6,900

Open access books available

186,000

International authors and editors

200M

Downloads

Our authors are among the

154

Countries delivered to

TOP 1%

most cited scientists

12.2%

Contributors from top 500 universities



WEB OF SCIENCE™

Selection of our books indexed in the Book Citation Index
in Web of Science™ Core Collection (BKCI)

Interested in publishing with us?
Contact book.department@intechopen.com

Numbers displayed above are based on latest data collected.
For more information visit www.intechopen.com



Objective Assessment of Local Retinal Function by Focal Macular and Multifocal Electroretinograms

Kei Shinoda^{1,2}, Celso Soiti Matsumoto¹ and Hisao Ohde^{2,3}

¹*Teikyo University*

²*Keio University*

³*Makuhari Ode Eye Clinic
Japan*

1. Introduction

There are two clinically methods to record electroretinographic (ERG) responses from focal areas of the retina; the focal macular ERGs (fmERGs) (Hirose et al., 1977; Miyake et al., 1989a; Miyake 1998) and multifocal ERGs (mfERGs). (Sutter & Tran 1992; Sutter et al., 1999; Hood & Greenstein 2003) Each technique has advantages and disadvantages. For example, fmERGs can be used to assess the function of different layers of localized areas of the retina, while mfERGs can be used to assess the function of different localized areas of the macula. These two techniques have been extensively investigated to determine their abilities to detect and assess functional alterations in different retinal areas in different retinal diseases. The results of these studies combined with the morphological findings of the same retinas determined by optical coherence tomography (OCT) have led to significant advances in the diagnosis and treatment of macular diseases. This chapter reviews the findings made by these two techniques, and show how they have advanced the diagnosis and therapy of macular diseases.

2. Focal macular electroretinograms (fmERGs)

Full-field scotopic and photopic ERGs are mass responses elicited by diffuse illumination of the entire retina. Because the total number of cones in the macula represents only 9% of the total cone population, (Crucio et al., 1990) full-field photopic ERGs are not suited for detecting focal lesions in the macular area or in determining the pathogenesis of macular diseases. Although the full-field ERGs can be normal in eyes with some types of macular diseases, it is often non-recordable when only the macular function is preserved such as in patients with retinitis pigmentosa (RP). Thus, the fmERG was developed to evaluate macular function in patients with similar conditions.

2.1 Principles of eliciting and recording fmERGs

fmERGs are elicited by presenting a small, 5° to 15°, stimulus on the macula and recording the response from the stimulated area. Background illumination is used to depress the sensitivity

of the area surrounding the stimulus and thus eliminate contamination from stray light responses. It is essential to monitor the location of the stimulus on the fundus during the recordings, particularly in eyes with poor fixation, to assure that only the macula is stimulated. Miyake et al developed the first stimulating and recording system for fmERGs in 1981, and thereafter extensive information has been collected on the physiological and pathological properties of the macula in both normal subjects and patients with different types of macular diseases.(Miyake 1998, 2006) Their recording system for fmERGs was based on a fundus camera into which a focal stimulus system was integrated. Another system to record fmERGs was developed by Matsumoto et al.(Choshi et al., 2003;Yamada et al., 2006) Their system is based on a slit-lamp microscope, and both the focal stimulus and fundus observation systems were integrated into the slit-lamp. With both systems, the examiner records the ERGs while monitoring the stimulus on the fundus either by an infrared television fundus camera or a slit-lamp-mounted infrared CCD camera. The optical system is designed to have the stimulus light and background illumination installed either into the fundus camera or the slit-lamp. The low amplitude fmERGs can be recorded by summing the responses with a computer with a signal averaging program.

2.2 Waveform of fmERGs

The waveform and components of the fmERGs are similar to those of the conventional full-field photopic ERGs. Thus, the same methods used to analyze full-field photopic ERGs can be used to analyze the different components of the fmERGs. By analyzing individual components of the fmERGs, a layer-by-layer analysis of the retina can be made in the macular area. fmERGs recorded from a normal subject displaying the different components are shown in Figures 1 and 2. The a- and b-waves, oscillatory potentials (OPs), photopic negative response (PhNR), on and off components elicited by the long duration stimuli, and 30 Hz flicker responses can be separately analyzed.

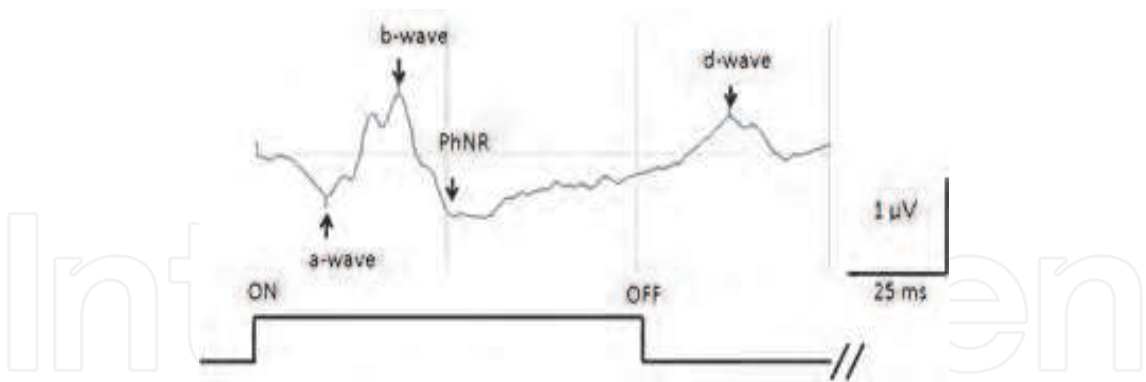


Fig. 1. Waveform of focal macular ERG elicited by a long duration stimulus.

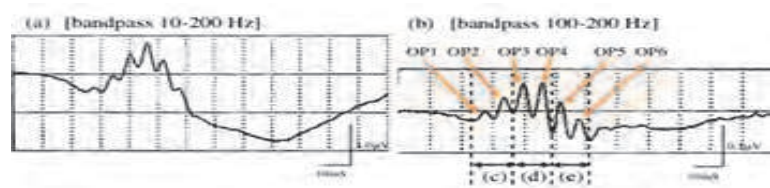


Fig. 2. Oscillatory potentials of focal macular ERGs elicited by a 10° diameter flash from a LED.

2.3 Focal rod ERGs

Although fmERGs are generally used to evaluate cone function, some techniques to record focal rod ERGs have been established. Because a background illumination to eliminate the responses elicited by stray light cannot be used, light scatter is a problem for eliciting focal responses. Sandberg et al showed that small rod responses could be elicited by a relatively large test spot of 30-40 degrees which was distinguishable from a larger but slower stray light response.(Sandberg et al., 1996) The ERGs elicited by stray light can also be eliminated by subtracting the response from a dimmer rod-matched full-field flash.

Another technique used to record focal rod responses is the use of double-flashes to stimulate a 40 degree area that can isolate focal rod a-waves (Nusinowitz et al., 1995) or by using a small blue light ($\lambda_{\max} = 470 \text{ nm}$) stimuli after dark-adaptation.(Choshi et al., 2003) Thus far, the clinical use of each technique to record scotopic responses from a focal area is limited.

2.4 Characteristics of fmERGs in normal subjects

Analyses of the fmERGs in normal humans showed several important characteristics. A nasal-temporal asymmetry was found in the OPs of the fmERGs (Fig. 3; Miyake et al., 1989a) When a semicircular stimulus is used to elicit fmERGs from the temporal and nasal sectors of the macula, no significant differences were observed in the amplitudes and implicit times of the a-waves and b-waves. However, the amplitudes of the OPs were significantly larger when the nasal retina was stimulated than when the temporal retina was stimulated. (Miyake et al., 1989a) The amplitude of the focal ERGs recorded with circular stimulus was approximately the same as the sum of the amplitudes of the temporal and nasal ERGs.

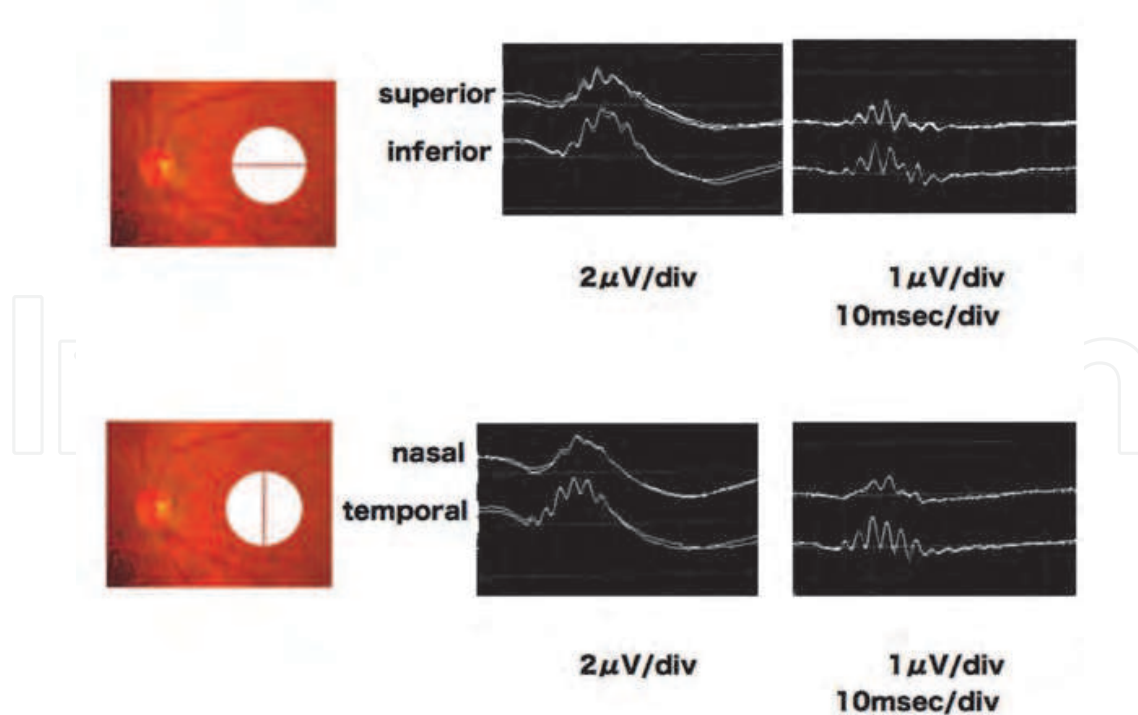


Fig. 3. Comparison of focal macular ERGs using semicircular stimuli on the superior and inferior (Upper), and on the nasal and temporal (Lower) macular areas. The OPs in the temporal macular sector are significantly larger than those in the nasal macula.

Another interesting feature of the fmERGs is that the implicit time of each component is relatively constant for different intensities (Figure 4).

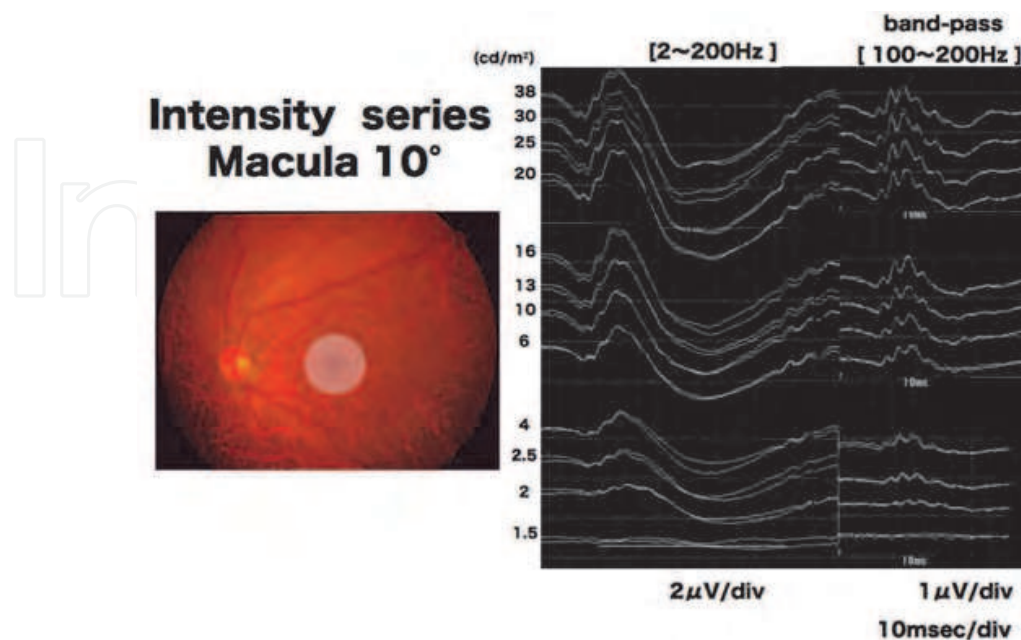


Fig. 4. Focal macular ERGs elicited by different stimulus intensities from a normal subject. The stimulus duration is 100 ms and the luminance of the constant background illumination is 3.0 cd/m². An increase in the amplitudes of each component is observed with increasing luminances but the implicit times appear to be constant.

3. Multifocal ERGs (mfERGs)

The second method to examine focal areas of the retina is by mfERGs. The techniques for recording and analyzing the mfERGs were developed by Sutter and Tran in 1992.(Sutter & Tran 1992) With this method, focal ERGs can be recorded simultaneously from multiple retinal locations during a single recording session using cross-correlation techniques. Unlike the fmERGs, there are still questions about how this method works and what it measures.

3.1 Principles of mfERGs

The principles, recording methods, and clinical applications of mfERGs are described in the International Society of Clinical Electrophysiology of Vision (ISCEV) guideline.(Hood et al., 2008) The recording methods for mfERGs are similar to that of full-field ERGs. Typically, the pupil is dilated and a ground electrode is attached to the forehead. A bipolar contact-lens electrode is used as the recording electrode although other electrodes such as the DTL electrode, gold-foil electrode, and other types can be used. The recordings are performed under light-adapted conditions to assess cone functions.

The stimuli are created on a video monitor and consist of a number of hexagonal elements driven at a 75-Hz frame rate (Fig. 5). The sizes of the hexagons are scaled with eccentricity to elicit focal retinal responses of approximately equal amplitude at all locations in normal subjects. At any given moment, about 50% of the hexagons are at a high luminance (white) and the other hexagons are at a low luminance (black). The pattern appears to be a random

flicker, but each element follows a fixed, predetermined maximum-length sequence (m-sequence) so that the overall luminance of the screen over time is relatively stable. Maintaining stable central fixation during the recordings is critical to ensure accuracy of the topographical ERG information. This is one of the disadvantages of mfERGs compared to fmERGs. A central fixation target such as a circle, cross, or "X", whose size can be changed according to the visual acuity, is created on the monitor. The recording time depends on the m-sequence and stimulation rate. Most investigators use a series of recording segments of approximately 30-s duration. Any segment containing a substantial artifact can be discarded and repeated.

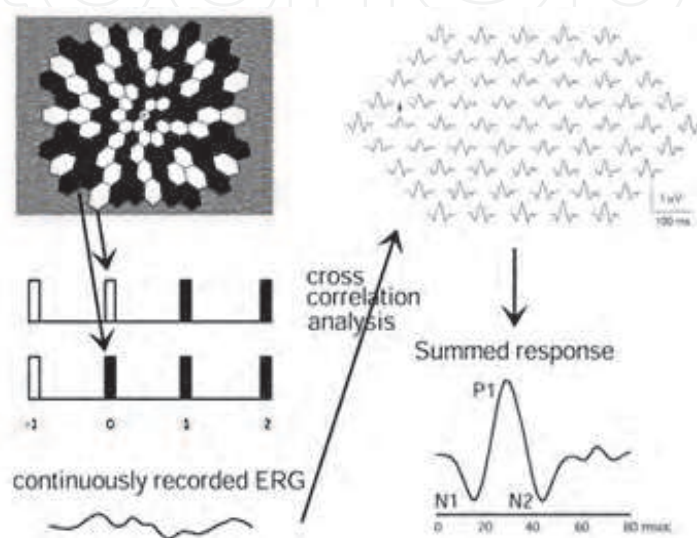


Fig. 5. First-order kernel responses from a normal eye. The mERGs were elicited by an array of black and white hexagons (Upper left). The hexagons go through a pseudo-random sequence of black and white as the frame changes (Middle left). Then a cross-correlation technique produces multiple ERGs (Lower left and upper right). For comparisons to full-field ERGs, 61 focal ERGs are summed (Lower right). Modified and reproduced from (Hood & Greenstein 2003) with permission from Elsevier.

3.2 Waveform of mfERGs

The local response elicited by each hexagon is computed as the cross correlation between the response cycle and the m-sequence. An example of this response is shown in Figure 5 and is called the first-order kernel. The derivation of the first- and second-order kernels as determined by Sutter et al. (Sutter et al., 1999) and Hood (Hood & Greenstein 2003) is shown in Figure 6. The first-order kernel can be thought of as the average response from a particular retinal area unaffected by stimulation of any other area, i.e., a linear approximation of the response from the small retinal area. It is obtained by adding all the records following presentation of a white hexagon and then subtracting all the records following a black hexagon (Fig. 5). The second-order kernel is a non-linear response, and is a measure of how the multifocal response is influenced by the adaptation of the retina to successive flashes. The first slice of the second-order kernel is calculated by comparing the two responses in Figure 6 (arrows). The upper large arrow points to the response to a preceding flash, and the lower large arrow points to the response to a flash of a preceding dark hexagon. If these two responses are not identical, the first slice of the second-order

kernel appears, and it is calculated by subtracting one response from the other. The first slice of the second-order kernel represents the effect of an immediately preceding flash; the second slice of the second-order is a measure of the effect of the flash two frames earlier. A similarity of the implicit times of full-field ERGs and that of mfERGs has been reported, and the two techniques can be compared. The waveforms and implicit times of the mfERGs vary with retinal position; however, individuals with retinal dysfunction can be differentiated from those with normal function.

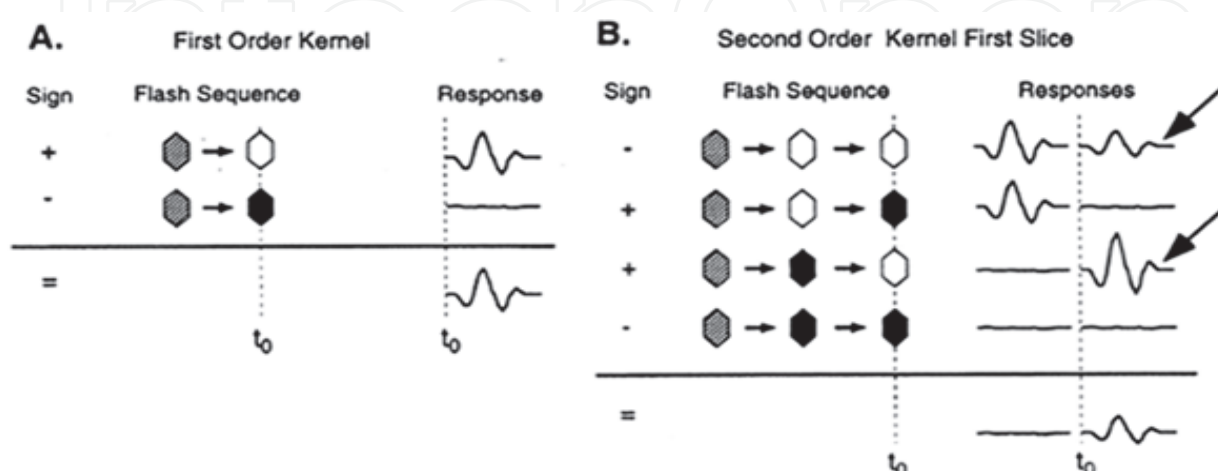


Fig. 6. Deviation of the first- and second-order kernels of mfERGs. White and black hexagons indicate whether the hexagon is bright (white) or when it is dark (black) during the recording. Hexagons with diagonal lines indicate a frame that could have been flash or non-flash. Modified and reproduced from (Hood & Greenstein 2003) with permission from Elsevier.

4. Clinical applications of fmERGs and mfERGs

4.1 Occult retinal lesions

Occult macular dystrophy (OMD) and acute zonal occult outer retinopathy (AZOOR) are representative disorders where the fmERGs and mfERGs findings were key in making a diagnosis. (Miyake et al., 1989b, 1996; Miyake 2006; Arai et al., 1998; Piao et al., 2000) OMD was discovered in 1989 by the fmERG findings of the Miyake group. It is a hereditary macular dystrophy characterized by a progressive decrease of the visual acuity, normal fundus, and normal fluorescein angiograms. OMD is an autosomal dominant disease, and the responsible mutation was recently identified as the retinitis pigmentosa 1-like 1 (*RP1L1*) gene. (Akahori et al., 2010) It was demonstrated that *RP1L1* plays important roles in the cone functions in humans, and disruption of *RP1L1* function leads to OMD. The cone and rod components of the full-field ERGs are normal but the fmERGs are reduced. A reduction of the visual acuity without visible fundus abnormalities can lead to a misdiagnosis of amblyopia, optic nerve disease, or a non-organic visual disorder.

The findings from a typical patient with OMD are shown in Figure 7. Although the fundus and fluorescein angiograms are normal, the OCT images show some mild abnormalities such as foveal thinning, irregular and discontinuous photoreceptor inner and outer segment (IS/OS) line, and abnormal cone outer segment tips (COSTs) line. (Park et al., 2010) It is noteworthy that it was Miyake and his co-workers who developed the technique to record fmERGs, who discovered and named patients with these findings as OMD. They

determined the clinical characteristics of OMD and identified the responsible gene mutation for OMD. Therefore, OMD has been referred to as Miyake’s disease.

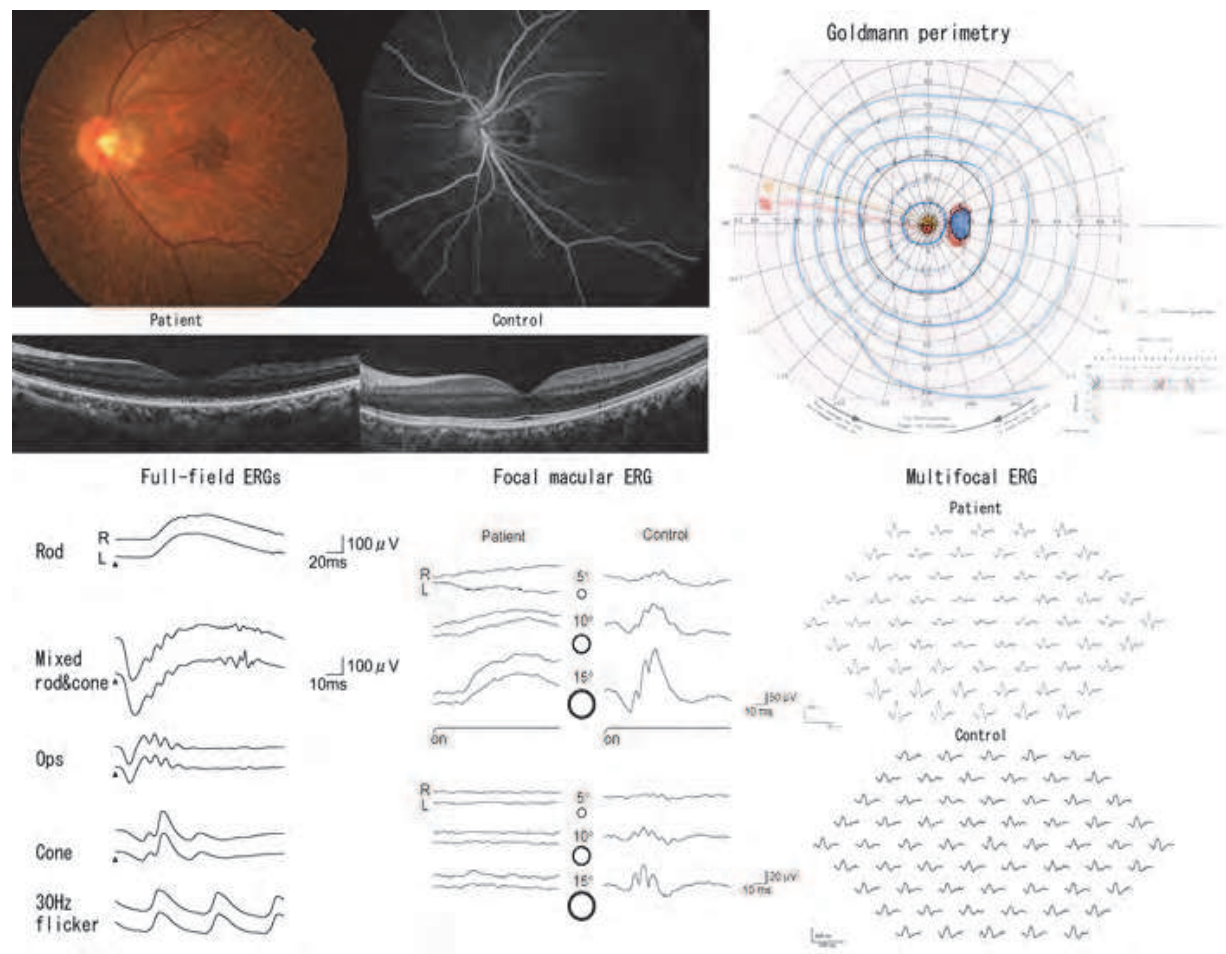


Fig. 7. Fundus photograph, fluorescein angiogram, visual field, full-fielr ERGs, mfERGs, and fmERGs of a typical OMD patient and a control subject. The macular function is selectively depressed. The findings from the fellow eye were almost the same. The fundus appearance, fluorescein fundus angiography, and full-field ERGs were completely normal. The a- and b-waves (upper), and the OPs (lower) of the fmERGs (right column) are reduced. Optical coherence tomographic image showing that the IS/OS line, the middle cone outer segment tip (COST) line between the IS/OS line and the retinal pigment epithelium (RPE) are discernible in the control subject, but the IS/OS line is relative obscure and the COST line is absent in the patient. Modified and reproduced from (Hanazono et al., 2011) with permission from Dove Medical Press Ltd.

Acute idiopathic blind spot enlargement (AIBSE) syndrome is a clinical entity in which the patients report sudden scintillations, and visual field tests show a temporal scotoma enlarging the blind spot. The fundus is otherwise normal, and it was recently reported that AIBSE belongs to the family of AZOOR and associated diseases called the AZOOR-complex. (Fletcher et al., 1988;Gass 2003) The pathological site for the visual field abnormalities is not the optic nerve but the retina, and the diagnosis is made from the mfERG findings (Figure 8).(Sugahara et al., 2011) The spectral domain OCT (SD-OCT) images showed abnormalities in the microstructures of the outer retina, e.g., disruption or loss of the external limiting

membrane (ELM), the IS/OS line, and/or an absence of the COST line in the areas of the visual field defects (Figure 9). (Spaide et al., 2008; Sugahara et al., 2011; Tsunoda et al., 2011) It is still under discussion whether fmERGs are better than OCT in detecting the early abnormalities in OMD and in monitoring the changes in the severity or stage of OMD and AZOOR-complex.

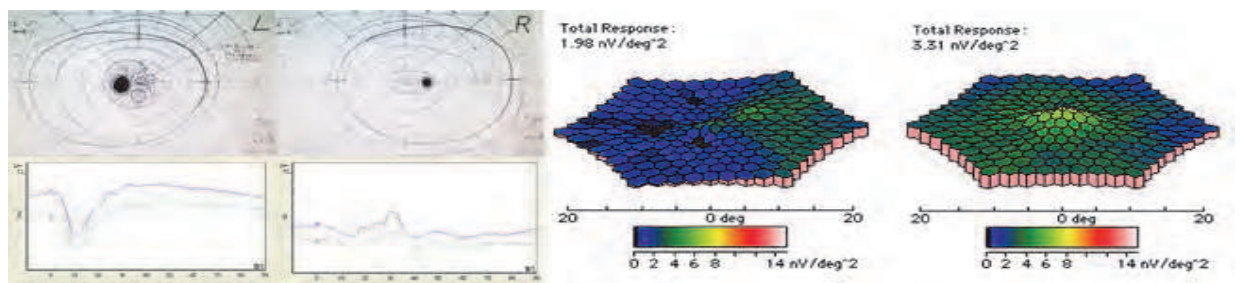


Fig. 8. Findings in a 44-year-old man with acute idiopathic blind spot enlargement (AIBSE) syndrome. (Left) Visual fields (top left) and full-field ERGs (bottom left) from a 44-year-old man who developed an arcuate scotoma connected to the physiological blind spot in the left eye. The amplitudes of the mfERGs (Right) are reduced in the area corresponding to the scotoma indicating that the visual field deficit was retinal in origin. Modified and reproduced from (Sugahara et al., 2011) with permission from S. Karger AG, Basel.

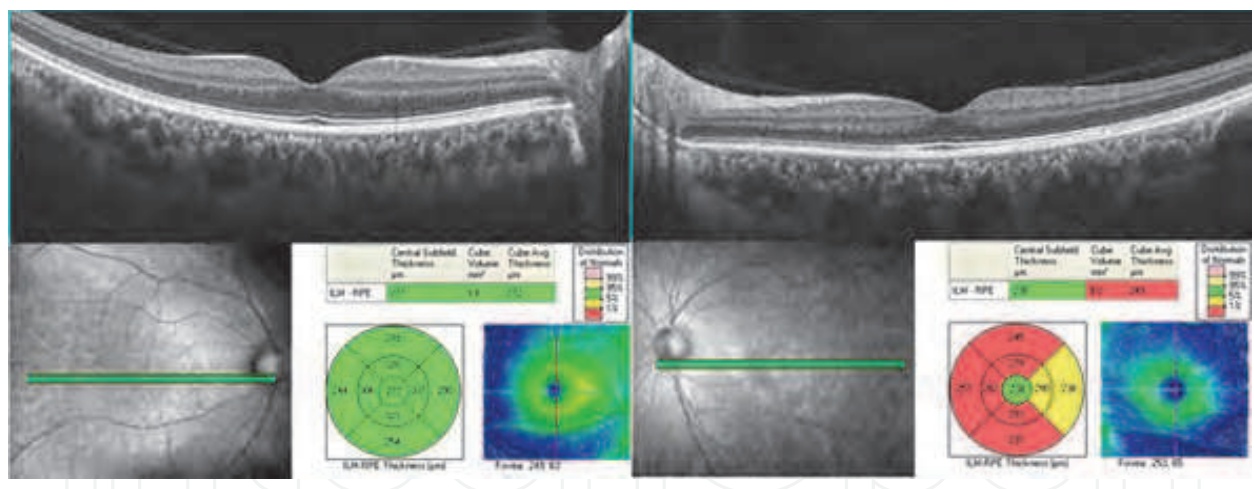


Fig. 9. Findings in the patient shown in Figure 8. (Top) Optical coherence tomographic image showing that both the external limiting membrane (ELM) and the IS/OS line are intact but the middle cone outer segment tip (COST) line between the IS/OS line and the retinal pigment epithelium (RPE) is absent in the nasal macula area of the left eye (top right). The ELM, IS/OS line, COST line, and RPE/Bruch membrane are intact in the right eye (top left). (Bottom) Mean retinal thickness was within normal limits in each of the 9 ETDRS areas in the right macula (bottom left) whereas it was significantly thinner in the corresponding area for the visual field defect in the left macula (bottom right). Modified and reproduced from (Sugahara et al., 2011) with permission from S. Karger AG, Basel.

4.2 Other retinal dystrophies

Electrophysiological studies have detected macular dysfunction in other retinal dystrophies. In Best vitelliform macular dystrophy (BMD), the full-field ERGs are normal but the mfERGs are reduced.(Falsini et al., 1996) The amplitudes of the central mfERGs are also reduced but the implicit times are relatively well preserved.(Palmowski et al., 2003)

Flicker mfERGs can be used to separate receptor and postreceptor activity in BMD and Stargardt macular dystrophy (STD).(Falsini et al., 1996) The mfERGs elicited by 8 and 32 Hz flicker stimuli were reported to have peak amplitudes at the fundamental and 2nd harmonic frequencies. The reduction of the amplitudes at both frequencies was found in both BMD and STD. The fundamental/2nd harmonic ratio is increased in BMD while it is normal in STD suggesting that receptor and postreceptor dysfunctions are present in BMD while a receptor dysfunction appears to be the primary alteration in STD. The amplitude at the fundamental frequency tended to decrease during the follow-up period suggesting a progressive receptor dysfunction in BMD but not in STD.

mfERGs have been used to compare the patterns of local cone and rod system impairments in patients with progressive cone dystrophy, and the findings clearly showed a pattern of eccentricity-related loss in the cone and rod systems.(Holopigian et al., 2002) Thus, the cone central responses were the most impaired, and the degree of impairment decreased with eccentricity, whereas the rod system was only mildly impaired and the degree of impairment did not change with increasing eccentricities. On the other hand, the peripheral responses were more impaired in patients with retinitis pigmentosa, and a relative sparing of either cone or rod system function was not observed.(Holopigian et al., 2001)

Peripheral cone dystrophy is rare and is an unusual form of cone dystrophy in which the peripheral cone system is more affected than the central cone system. The rod system is relatively normal. To diagnose this type of cone dystrophy accurately and to understand its pathophysiologic features, the findings of mfERGs or mfERGs combined with those of full-field ERGs are necessary.(Kondo et al., 2004)

Studies of the functional anatomy of the macula in albinism showed that the mfERGs were flat in the macular area, and the amplitudes were constant at all retinal eccentricities when the responses were scaled by the stimulated area (Figure 10).(Kelly&Weiss 2006; Nusinowitz & Sarraf, 2008)

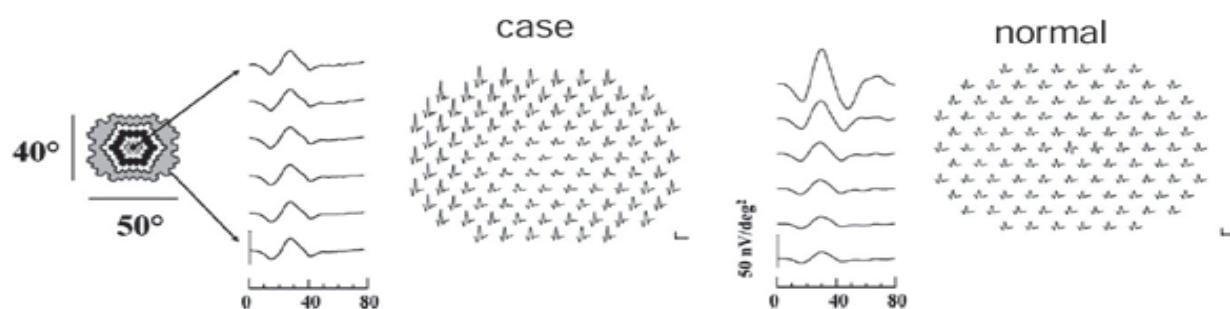


Fig. 10. Topographic map of mfERGs of patient with oculocutaneous albinism (left) compared to that of an adult normal subject (right). The patient has lower amplitude mfERGs at the macula, whereas normal eye has larger amplitude mfERGs at the macula. The mfERGs were averaged across six rings ranging from central retina to 20 degrees peripheral (Left), then scaled for stimulus area. The results show that the amplitude density is constant from the macula to the periphery whereas the normals showed a decrease with increasing eccentricity. Modified and reproduced from (Kelly&Weiss 2006) with permission from Elsevier.

Marmor et al made morphological and functional analyses by Fourier domain OCT (FD-OCT), adaptive optics, and mfERGs in two patients with albinism who lacked a foveal pit.(Marmor et al., 2008) The visual acuities of these two patients ranged from 0.4 to 1.0. They found a thickening of the outer nuclear layer and lengthening of the cone outer segments with normal cone diameters in the central 1° to 2°. Functional analyses showed that the single amplitudes and summed ring-response densities of the main positive peak were within the normal limits, and the response density in the foveal zone was larger, although still low borderline, than that in the peripheral rings. The normal mfERGs from the central macula without a foveal pit suggested that a lack of foveal pit does not always result in retinal dysfunction.

Macular function was assessed in eyes with x-linked retinoschisis by fmERGs (Miyake et al., 1993a) and mfERGs.(Piao et al., 2003) Both tests showed a dysfunction of the retina in the areas corresponding to the foveal schisis. In the early stage of x-linked retinoschisis, the ratio of the b-wave to a-wave (b/a ratio) amplitude of the fmERGs gradually decreased toward the fovea. This suggested that the retinal function in the middle and inner retinal layers were more affected in the central retina, and also that the on-bipolar cells may be more affected than the off-bipolar cells because the a-wave was better preserved than the b-wave. The amplitudes of the first-order kernel of the mfERGs were reduced in the central retina while they varied outside the foveal area. The implicit times were significantly delayed both in the central and extrafoveal regions.(Piao et al., 2003) These findings suggest that the pathology of XLRs affected the implicit times more than the amplitudes of the mfERGs. The amplitudes of the second-order kernels were also more reduced than those of the first-order kernels probably because of a widespread dysfunction of the proximal retina. Alternatively, the delayed implicit time of the first-order kernel may be due to a reduction of the second-order kernel.

Delays in the implicit times of the first-order kernel and reductions in the amplitude of the second-order kernel have been reported in eyes with diabetic retinopathy (Palmowski et al., 1997), retinal vascular disease (Hasegawa et al., 2001), and congenital stationary night blindness (Kondo et al., 2001).

4.3 Retinal vascular diseases

Because the first slice of the second order kernel represents the degree to which the retinal response is affected by an immediately preceding stimulus, this component represents the effects of the fast adaptive mechanisms of the retina. Analysis of this component showed that the recovery of sensitivity following a flash was abnormal in eyes of diabetic patients even before the development of diabetic retinopathy.(Palmowski et al., 1997) Shimada et al (Shimada et al., 2001) recorded mfERGs using a periodic “global” flash inserted between the multifocal stimuli that enhanced the fast adaptive mechanisms. Then, the periodic global flashes produced a greater reduction in the mfERGs in diabetic eyes without retinopathy than in age-matched normal subjects. This indicated an impairment of recovery from the bright preceding flash. The multifocal OPs were also reported to have prolonged latencies in the eyes of diabetic patients without retinopathy.(Kurtenbach et al., 2000)

The fmERGs can also be a sensitive indicator of macular function in eyes with diabetic maculopathy. In some eyes at the early stage of diabetic maculopathy, the macular OPs were selectively reduced leaving the a- and b-waves intact.(Yoon et al., 1990) This is in good agreement with early studies(Yonemura et al., 1962) with full-field ERGs that showed that

the full-field OPs were reduced with delayed implicit times during the early stage of diabetes mellitus.

mfERGs have been used to assess macular function in eyes with age-related macular degeneration (AMD).(Feigl et al., 2005) The mfERGs were used to monitor the changes in the function of parafoveal locations after photodynamic therapy (PDT). In the future, mfERGs can be used to document the effects of different treatments for AMD, e.g., PDT, anti-vascular endothelial growth factor therapies, and retinal pigment epithelial transplantation, and combination of some of these therapies.

The fmERGs have been used to differentiate macular dysfunction from optic nerve disease in cases of acute central scotoma. For example, we studied a 75-year-old man who presented with a unilateral acute decrease of vision and central scotoma (Figure 11).

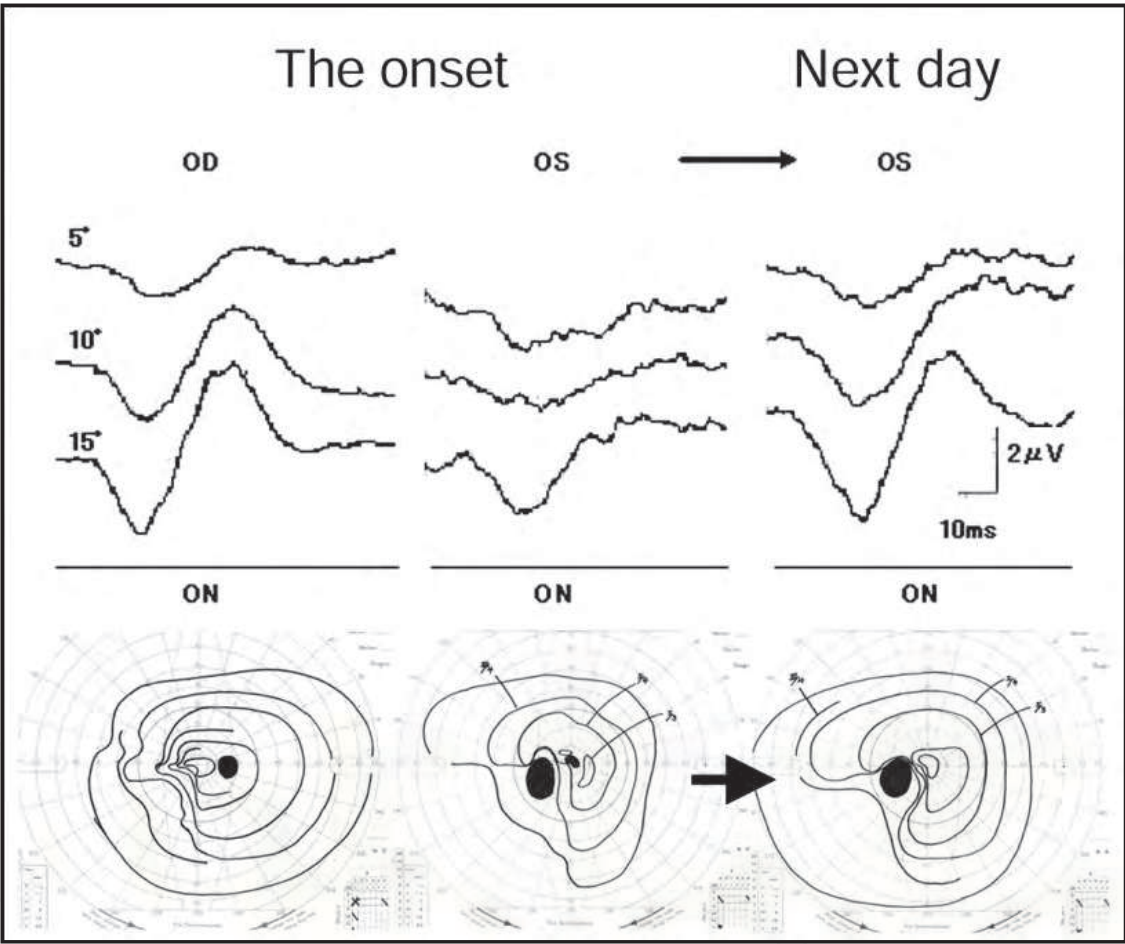


Fig. 11. Visual fields showing ipsilateral hemianopsia in both eyes due to an earlier cerebral infarction and central scotoma in the left eye coupled with an acute visual decrease to 0.01. The optic discs were normal except for enlarged optic disc cups due to glaucoma. Fluorescein angiograms were normal except for a relative prolonged arm-to-retina time of 20 seconds. These findings together with a relative afferent pupillary defect required a differential diagnosis between optic nerve disease and local retinal disease. The reduced fmERGs together with the rapid improvement led to a diagnosis of transient ischemia. Modified and reproduced from (Terauchi et al., 2007) with permission from BMJ Publishing Group Ltd.

A left relative afferent pupillary defect was present. His visual acuity was 0.01 in the left affected eye. The fundus was normal except for an enlarged optic disc cup in both eyes. Fluorescein angiography showed a delayed arm-to-retina circulation time of 20.0 seconds in the left eye. The mfERGs were decreased in the left eye suggesting that the visual dysfunction was of retinal origin. The following day, the visual acuity in the left eye improved to 0.7. The results of full-field ERGs and VEPs were within normal limits. We concluded that the acute decrease in the visual acuity resulted from a macular dysfunction due to a transient macular ischemia.(Terauchi et al., 2007)

Wide-field (WF)-mfERGs are used to assess focal areas of the retina in the far (out to 90°) periphery that might be dysfunctional. The WF-mfERGs have been compared to the full-field flicker ERGs in patients with central retinal vein occlusion (CRVO).(Dolan et al., 2003) In the affected eye, 98% of the central P1 implicit times and 91% of the peripheral P1 implicit times fell outside the normal limits as opposed to 35% of the 30-Hz flicker implicit times in the same eyes. The investigators suggested that this was because the WF-mfERGs were more sensitive than the standard full-field ERGs to detect the changes in the nonlinear dynamics of the eye because the stimulus used for the recordings of the WF-mfERG consisted of many frequencies (Dolan et al., 2003).

In the management of CRVO, it is important to determine whether the CRVO is the ischemic or non-ischemic type, and whether iris neovascularization (NVI) will develop. An earlier study showed that the b/a ratio of the full-field mixed rod and cone ERGs of the affected eyes were significantly lower in patients who developed NVI than that in individuals who did not develop NVI.(Sabates et al., 1983) More recently, it was reported that both the implicit times and amplitudes of the 30-Hz flicker, reflecting predominantly cone photoreceptor function, were good predictors of neovascular complications. (Lasson&Andreasson 2001) However, more useful parameters of the mfERGs are needed to predict neovascular complications in patients with CRVO.

The usefulness of mfERGs in evaluating macular function in eyes with a CRVO has recently been reported.(Ogino et al., 2011) The relative amplitudes (affected eye/fellow eye) of the a- and b-waves and the PhNR of the mfERGs were significantly correlated with the visual acuity. The relative amplitude of the PhNR was most strongly correlated with the central foveal thickness. The relative amplitudes were reduced more severely in eyes with ischemic CRVO than in eyes with nonischemic CRVO.

4.4 Optic nerve diseases

The photopic negative response (PhNR) is a negative-going wave of photopic full-field ERGs that appears immediately after the b-wave. This component is also present in the mfERGs, and intensive investigations on this component by Frishman and colleagues(Frishman 2006) have demonstrated its clinical value. Because all evidence indicated that this component arises from activity of the inner retinal neurons, viz., RGCs, IPL and NFL, the findings have stimulated investigators to find new applications of PhNRs.

Thus, the PhNRs of the mfERGs were significantly reduced in patients with open-angle glaucoma (Machida et al., 2011), optic neuritis(Nakamura et al., 2011), and macular edema associated with CRVO.(Ogino et al., 2011) The threshold for eliciting a focal PhNR was significantly higher than that for the full-field PhNR in eyes at early and intermediate stages of glaucoma. (Machida et al., 2011) The authors recorded from the macular area, and from the supero-temporal and infero-temporal areas of the macula to study regional functions and were able to do a layer-by-layer analyses as well as topographical analyses. In patients

with acute optic neuritis, (Nakamura et al., 2011) the focal PhNRs were reduced at the onset of symptoms of optic neuritis, but the full-field PhNRs were unchanged. With time, the PhNRs decreased as the retinal nerve fiber layer became thinner. (Gotoh et al., 2004) Interestingly, the a- and b-waves were also attenuated, and both recovered significantly at 6 months after the onset, but the PhNRs did not improve significantly.

4.5 Surgical or medical intervention

The PhNR of the fmERGs has been reported to be useful in evaluating new medical and surgical treatments for different retinal diseases. (Terasaki et al., 2001) In the evaluation of the effects of macular hole surgery, a selective delay in the recovery of the fmERG b-waves 6 months after surgery was reported. This suggested an alteration of retinal physiology in the macular region. The authors also reported a selective reduction in the amplitude of the PhNR of the full-field ERG after macular hole surgery. This suggested that the ganglion cells were damaged by the indocyanine green dye-assisted internal limiting membrane peeling and gas tamponade. (Ueno et al., 2006)

New treatments have been recently introduced for retinal diseases, e.g., macular edema, neovascular maculopathy, whose pathogenesis is related to the activation of VEGF. In these treatments, fmERGs and/or mfERGs can be used to evaluate the outcomes. Thus, intraocular triamcinolone acetonide (TA), (Moschos et al., 2007) intraocular bevacizumab, (Moschos et al., 2008), and PDT for exudative AMD (Palmowski et al., 2002; Mackay et al., 2007) have been studied by fmERGs and mfERGs. In most studies, the changes in the mfERGs were compared to that of the visual acuity, OCT images, and retinal sensitivities. One of the uses of mfERGs is to monitor the improvements of paramacular function. Consequently, mfERGs can play significant roles in the assessment of retinal function after many treatment trials.

4.6 Miscellaneous

A selective reduction of the OP amplitudes of the fmERGs was reported (Miyake 2006) in the early stage of macular edema, (Miyake et al., 1993b) epiretinal membrane (ERM), (Tanikawa et al., 1999; Niwa et al., 2003), and at the convalescent stage of central serous chorioretinopathy (CSC). (Miyake et al., 1988) The amplitudes of the OPs of the fmERGs were reduced and the implicit times delayed regardless of the visual acuity in aphakic eyes or pseudophakic cystoid macular edema (CME). (Salzman et al., 1986) A layer-by-layer analysis of the components of the fmERGs showed that the a- and b-waves and OPs were reduced in these eyes with CME. (Miyake et al., 1993b; Miyake 2006) With increasing severity of the CME, the OPs, the b-waves, and then the a-waves were reduced. Interestingly, the amplitudes of OPs of the full-field ERGs were significantly smaller in the affected eye than in the normal fellow eye although the a- and b-waves were not significantly different. (Terasaki et al., 2003) In addition, the degree of the reduction was significantly correlated with the visual acuity. These findings suggested that the abnormality was not limited to the macula although ophthalmoscopy and fluorescein angiography did not show any abnormalities of the retina. For the OPs, the contribution of the electrical signals from the macular area may be relative higher than that to the a- or b-waves, and fmERGs may be more sensitive than full-field ERGs in assessing the retinal function in eyes with a CME.

fmERGs were used to assess eyes with ERM before and after surgery, and the properties of the fmERGs were similar to that in eyes with CME. (Tanikawa et al., 1999; Niwa et al., 2003) The

results of these studies showed that the relative amplitudes (affected eye/fellow eye) of the a- and b-waves and the OPs before surgery were 75%, 69%, and 45%, respectively. The OPs were most affected and the b-wave was more affected than the a-wave, and a significant reduction of the b/a ratio was found in eyes with a relatively preserved a-wave. In contrast, the b/a ratio in the eyes with a greater reduction of the a-wave were not significantly different from that in the normal fellow eyes. Therefore, it was suggested that the reduction of the b-wave occurred first and was followed by the reduction of the a-wave as the disease progressed. The greater functional impairment of the inner retinal layers shown by fmERGs was correlated with the OCT-determined morphological changes. After surgery, the a-wave recovered first followed by the recovery of the b-waves as in eyes with aphakic CME (Miyake et al., 1993b) and CSC (Miyake et al., 1988). The postoperative visual acuity was significantly correlated with the preoperative relative a-wave amplitude.

The fmERGs findings indicated that there would be pathophysiological changes in eyes with CSC. It is possible that there was functional damage to the photoreceptors in the macular area. Actually, all of the components of the fmERGs were reduced with delayed implicit times indicating that the expectations were correct (Miyake et al., 1988). However, fmERG analyses revealed that the inner retinal layers were also damaged, and the recovery was delayed even after the serous retinal detachment (SRD) was resolved. Concomitant analyses with fmERGs and OCT provided good evidence for the cause of these changes. Thus, the sensory retina was thickened not only in the acute phase but also after the SRD was resolved and the only the macular OPs were abnormal. These findings suggest that the functional changes in eyes with CSC may result from the SRD and by the macular edema.

5. Multifocal VEP and its clinical applications

The visual evoked potential (VEP) has traditionally been an important method for assessing the state of visual pathways. However, the conventional VEP has limited ability to reflect field loss in non-central areas since the pattern VEP is predominantly generated by cortical elements receiving projections from the central retina and it has been estimated that the central 2° of visual field contributes 65% of the response (Gray et al., 1997). The multifocal stimulation techniques (Figure 12) have enabled assessment of multiple sites in the field out to 30° eccentricity. (Baseler et al., 1994; Klistorner et al., 1998; Betsuin et al., 2001)

It was reported that the topographic map of the amplitudes of the mfVEPs showed good agreement or concordance with the results of conventional visual field tests if occipital bipolar electrodes are used. Scotomas can be identified, and field defects in glaucomatous optic neuropathy and optic neuritis have been well defined. (Klistorner et al., 2000; Hood et al., 2000, 2003, 2004; Goldberg et al., 2002; Graham et al., 2005)

The mfERGs and multifocal visual evoked potentials (mfVEPs) recorded from a patient who developed an acute visual field loss after vitrectomy are shown in Figure 13. (Shinoda et al., 2000) The patient had undergone uncomplicated vitrectomy for a long-lasting vitreous hemorrhage associated with proliferative diabetic retinopathy. The patient complained of superior visual field defects on the following day. Visual field testing, mfERGs, and mfVEPs revealed that the visual field defect was not retinal but of optic nerve origin. A diagnosis of ischemic optic neuropathy was made.

Interestingly, the alterations of the topographic map of the mfVEPs may show discordance with the subjectively determined visual fields in some cases with hemianopic field defects.

(Figure 14) (Watanabe et al., 2007) In some patients with occipital lesions, the subjective (Goldmann’s perimetry etc) and objective (mfVEP) visual field results are discordant, and some of them will show a recovery of the visual field deficits.

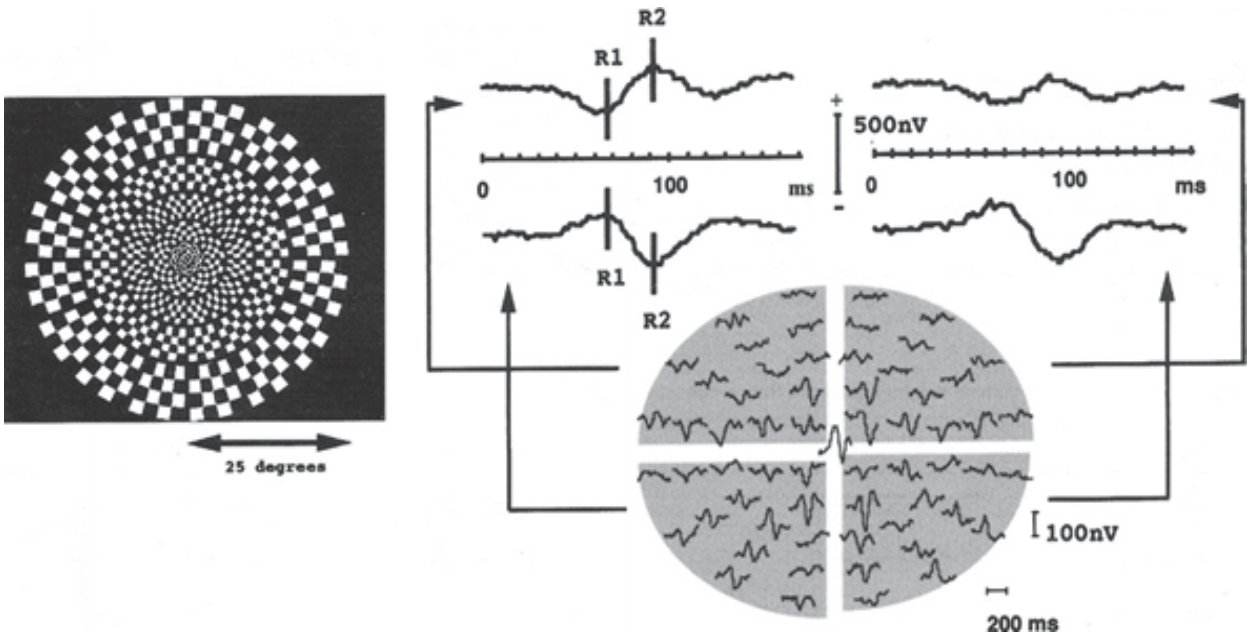


Fig. 12. Stimulus for multifocal visual-evoked potentials. (Left) Stimulus was a dartboard pattern consisting of 61 sectors. (Right) Individual second-order kernels of the multifocal visual evoked potentials (mfVEPs) are plotted retinotopically in the lower half. The sums of the responses in each of the four quadrants are plotted in the sectors in the upper half except for the response from the very central sector. Modified and reproduced from (Watanabe et al., 2007) with permission with permission from Elsevier.

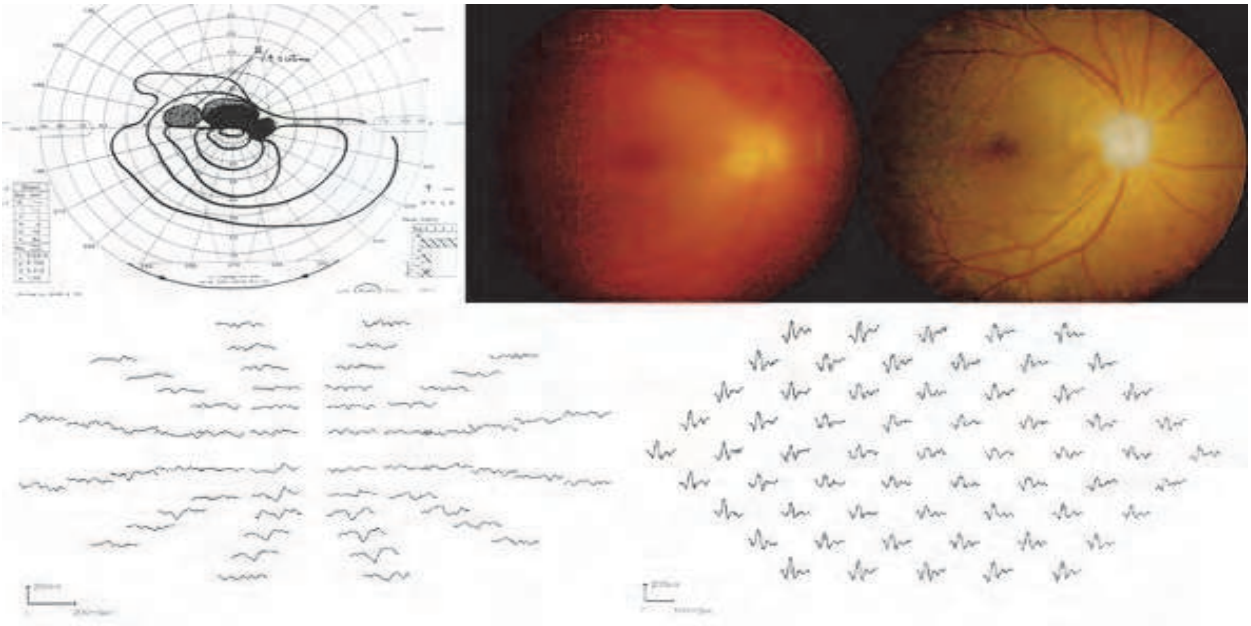


Fig. 13. Visual field, mfERGs, and mfVEPs from an eye with a superior hemianopsia which developed one day after vitrectomy. The pupil was dilated by the atropine instilled before

the surgery and residual mild vitreous hemorrhage hampered the light reflex and detailed fundus view (fundus picture taken on the next day: upper middle). A superior horizontal hemianopsia is present (upper left). The amplitudes of the mfERGs (lower left) were relatively reduced and the delayed implicit times in all retinal areas whereas the amplitudes of the mfVEPs (lower right) were reduced and delayed especially from the area corresponding to the visual field defect. With the resolution of the vitreous hemorrhage, the visual acuity improved to 0.7 but the visual field defects remained. Six months later the inferior margin of the optic disc appeared pale (upper right), supporting that the visual field defect had been optic nerve origin. Modified and reproduced from (Shinoda et al., 2000) with permission.

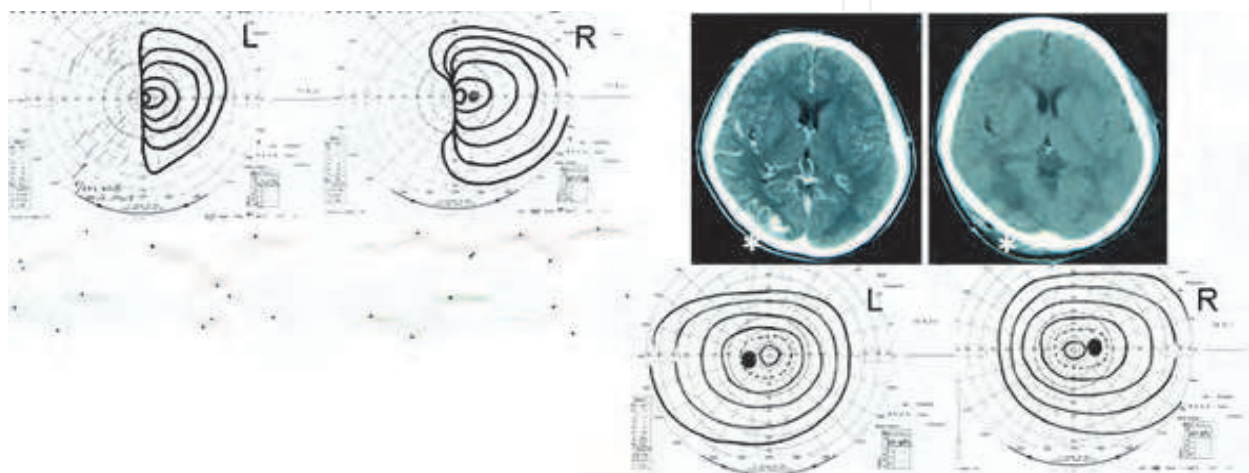


Fig. 14. Findings in a 28-year-old man who underwent neurosurgery for an arteriovenous malformation in the right occipital lobe. (Top left) Goldmann visual fields showing a left homonymous hemianopsia. (Bottom left) The multifocal visual evoked potentials (mfVEPs) are presented so that the average waveforms are seen in each of the quadrants where in the visual field each waveform originates. The mfVEPs were not extinguished in the temporal fields of the left eye and the nasal fields of the right eye. (Top right, left) Computed tomographic (CT) image showing an arteriovenous malformation in the right occipital lobe. (Top right, right) CT image showing a low-density area indicating postoperative edema in the right occipital region. (Bottom right) Goldmann perimetric fields showing complete recovery of visual fields three months later. Modified and reproduced from (Watanabe et al., 2007) with permission with permission from Elsevier.

6. Conclusion

Although evaluations of the macula of the retina by electrophysiological methods have been available for less than a quarter-of-a-century, their uses in clinical and research studies have been expanding with great enthusiasm. The techniques continue to advance for the diagnosis of macular diseases, and in determining the underlying pathology of macular diseases. In addition, focal ERGs have been used and will continue to be used to monitor the course of a disease process, to assess the favorable and adverse effects of therapy, and to discover new retinal and optic nerve diseases. Coupled with the development of imaging technology, advances in surgical techniques, psychophysical tests, circulatory evaluations,

and enthusiasm of clinical and laboratory electrophysiologists, fmERG and mfERG will certainly produce much more advances in ophthalmology.

7. Acknowledgements

We express our deepest appreciation to Professor Yozo Miyake for his critical and valuable advices concerning the interpretation and clinical importance of electrophysiological results throughout the chapter. We acknowledge Professor Duco Hamasaki for sharing his great knowledge in electrophysiology and English correction. Support of this chapter was provided by Researches on Sensory and Communicative Disorders from the Ministry of Health, Labor, and Welfare, Japan.

8. References

- Akahori M, Tsunoda K, Miyake Y, Fukuda Y, Ishiura H, Tsuji S, Usui T, Hatase T, Nakamura M, Ohde H, Itabashi T, Okamoto H, Takada Y, Iwata T. (2010). Dominant mutations in RP1L1 are responsible for occult macular dystrophy. *Am J Hum Genet.* Vol. 87, No.3pp.(424-9).
- Arai M, Nao-i N, Sawada A, Hayashida T. (1998). Multifocal electroretinogram indicates visual field loss in acute zonal occult outer retinopathy. *Am J Ophthalmol*, Vol.126, No.3, pp.(466-9).
- Baseler HA, Sutter EE, Klein SA, Carney T. (1994). The topography of visual evoked response properties across the visual field. *Electroencephal Clin Neurophysiol*, Vol.90, No.1, pp.(65-81).
- Betsuin Y, Mashima Y, Ohde H, Inoue R, Oguchi Y. (2001). Clinical application of the multifocal VEPs. *Curr Eye Res*, Vol.22, No.1, pp(54-63).
- Choshi T, Matsumoto CS, Nakatsuka K. (2003). Rod-driven focal macular electroretinogram. *Jpn J Ophthalmol*, Vol.47, No.4, pp.(356-61).
- Curcio CA, Sloan KR, Kalina RE, Hendrickson AE. (1990). Human photoreceptor topography. *J Comp Neurol*, Vol. 292, No.4, pp.(497-523).
- Dolan FM, Parks S, Keating D, Dutton GN, Evans AL. (2003). Multifocal electroretinographic features of central retinal vein occlusion. *Invest Ophthalmol Vis Sci*, Vol.44, No.11, pp.(4954-9).
- Falsini B, Porciatti V, Porrello G, Merendino E, Minnella A, Cermola S, Buzzonetti L. (1996). Macular flicker electroretinograms in Best vitelliform dystrophy. *Curr Eye Res*, Vol.15, No.6, PP.(638-46).
- Feigl B, Lovie-Kitchin J, Brown B. (2005). Objective functional assessment of age-related maculopathy: a special application for the multifocal electroretinogram. *Clin Exp Optom*, Vol.88, No.5, pp.(304-12).
- Fletcher WA, Imes RK, Goodman D, Hoyt WF. (1988). Acute idiopathic blind spot enlargement. A big blind spot syndrome without optic disc edema. *Arch Ophthalmol*, Vol.106, No.1, pp.(44-49).
- Frishman LJ. (2006). Origins of the Electroretinogram, In : 2nd eds *Principle and practice of clinical electrophysiology of vision*, Heckenlively JR & Arden GB, pp.(139-183), The mit press Cambridge, Massachusetts, London, England.

- Gass JD. (2003) Are acute zonal occult outer retinopathy and the white spot syndromes (AZOOR complex) specific autoimmune diseases? *Am J Ophthalmol*, Vol.135, No.3, pp.(380-381).
- Goldberg I, Graham SL, Klistorner AI. (2002). Multifocal objective perimetry in the detection of glaucomatous field loss. *Am J Ophthalmol*, Vol.133, No.1, pp.(29 -39).
- Gotoh Y, Machida S, Tazawa Y. (2004). Selective loss of the photopic negative response in patients with optic nerve atrophy. *Arch Ophthalmol*, Vol.122, No.3, pp.(341-6).
- Graham SL, Klistorner AI, Goldberg I. (2005). Clinical application of objective perimetry using multifocal visual evoked potentials in glaucoma practice. *Arch Ophthalmol*, Vol.123, No.6, , pp.(729-39).
- Gray LG, Galetta SL, Siegal T, Schatz NJ. (1997) The central visual field in homonymous hemianopia. Evidence for unilateral foveal representation. *Arch Neurol*, Vol.54, No.3, pp.(312-7).
- Hanazono G, Ohde H, Shinoda K, Tsunoda K, Tsubota K, Miyake Y. (2010). Pattern-reversal visual evoked potential in patients with occult macular dystrophy. *Clin Ophthalmol*, Vol.4, pp.(1515-20).
- Hasegawa S, Ohshima A, Hayakawa Y, Takagi M, Abe H. (2001). Multifocal electroretinograms in patients with branch retinal artery occlusion. *Invest Ophthalmol Vis Sci*, Vol.42, No.1, pp.(298-304).
- Hirose T, Miyake Y, Hara A. (1977). Simultaneous recording of electroretinogram and visual evoked response. Focal stimulation under direct observation. *Arch Ophthalmol*, Vol.95, No.7, pp.(1205-8).
- Holopigian K, Seiple W, Greenstein VC, Hood DC, Carr RE. (2001). Local cone and rod system function in patients with retinitis pigmentosa. *Invest Ophthalmol Vis Sci*, Vol.42, No.3pp.(779-88).
- Holopigian K, Seiple W, Greenstein VC, Hood DC, Carr RE. (2002). Local cone and rod system function in progressive cone dystrophy. *Invest Ophthalmol Vis Sci*, Vol.43, No.7, pp.(2364-73).
- Hood DC, Odel JG, Zhang X. (2000).Tracking the recovery of local optic nerve function after optic neuritis:a multifocal VEP study. *Invest Ophthalmol Vis Sci*, Vol.41, No.12, pp.(4032-8).
- Hood DC, Greenstein VC. (2003). Multifocal VEP and ganglion cell damage: applications and limitations for the study of glaucoma. *Prog Retin Eye Res*, Vol.22, No.2, pp.(201-51).
- Hood DC, Thienprasiddhi P, Greenstein VC, Greenstein VC, Winn BJ, Ohri N, Liebmann JM, Ritch R. (2004). Detecting early to mild glaucomatous damage: a comparison of the multifocal VEP and automated perimetry. *Invest Ophthalmol Vis Sci*, Vol.45, No.2, pp.(492- 498).
- Hood DC, Bach M, Brigell M, Keating D, Kondo M, Lyons JS, Palmowski-Wolfe AM. (2008). ISCEV guidelines for clinical multifocal electroretinography (2007 edition). *Doc Ophthalmol*, Vol.116, No.1, pp.(1-11).
- Kelly JP, Weiss AH. (2006). Topographical retinal function in oculocutaneous albinism. *Am J Ophthalmol*, Vol.141, No.6, pp.(1156-8).

- Klistorner AI, Graham SL, Grigg JR, Billson FA. (1998). Multifocal topographic visual evoked potential: improving objective detection of local visual field defects. *Invest Ophthalmol Vis Sci*. Vol.39, No.6, pp.(937-50).
- Klistorner A, Graham SL. (2000). Objective perimetry in glaucoma. *Ophthalmology*, Vol.107, No.12, pp.(2283-99).
- Kondo M, Miyake Y, Kondo N, Tanikawa A, Suzuki S, Horiguchi M, Terasaki H. (2001). Multifocal ERG findings in complete type congenital stationary night blindness. *Invest Ophthalmol Vis Sci*. Vol.42, No.6, pp.(1342-1348).
- Kondo M, Miyake Y, Kondo N, Ueno S, Takakuwa H, Terasaki H. (2004). Peripheral cone dystrophy: a variant of cone dystrophy with predominant dysfunction in the peripheral cone system. *Ophthalmology*, Vol.111, No.4, pp.(732-9).
- Kurtenbach A, Langrova H, Zrenner E. (2000). Multifocal oscillatory potentials in type 1 diabetes without retinopathy. *Invest Ophthalmol Vis Sci*, Vol.41, No.10, pp.(3234-41).
- Larsson J, Andreasson S. (2001). Photopic 30 Hz flicker ERG as a predictor for rubeosis in central retinal vein occlusion. *Br J Ophthalmol*, Vol.85, No.6, pp.(683-685).
- Machida S, Tamada K, Oikawa T, Gotoh Y, Nishimura T, Kaneko M, Kurosaka D. (2011). Comparison of photopic negative response of full-field and focal electroretinograms in detecting glaucomatous eyes. *J Ophthalmol*, in press..
- Mackay AM, Brown MC, Hagan RP, Fisher AC, Grierson I, Harding SP. (2007). Deficits in the electroretinogram in neovascular age-related macular degeneration and changes during photodynamic therapy. *Doc Ophthalmol*, Vol.115, No.2, pp.(69-76).
- Marmor MF, Choi SS, Zawadzki RJ, Werner JS. (2008) Visual insignificance of the foveal pit: reassessment of foveal hypoplasia as fovea plana. *Arch Ophthalmol*, Vol.126, No.7, pp.(907-13).
- Miyake Y, Shiroyama N, Ota I, Horiguchi M. (1988). Local macular electroretinographic responses in idiopathic central serous chorioretinopathy. *Am J Ophthalmol*, Vol.106, No.5, pp.(546-50).
- Miyake Y. (1998). Focal macular electroretinography. *Nagoya J Med Sci*, Vol.61, No.3-4, pp.(79-84).
- Miyake Y, Shiroyama N, Horiguchi M, Ota I. (1989a). Asymmetry of focal ERG in human macular region. *Invest Ophthalmol Vis Sci*, Vol.30, No.8, pp.(1743-9).
- Miyake Y, Ichikawa K, Shiose Y, Kawase Y. (1989b). Hereditary macular dystrophy without visible fundus abnormality. *Am J Ophthalmol*, Vol.108, No.3, pp.(292-9).
- Miyake Y, Shiroyama N, Ota I, Horiguchi M. (1993a). Focal macular electroretinogram in X-linked congenital retinoschisis. *Invest Ophthalmol Vis Sci*, Vol.34, No.3, pp.(512-5).
- Miyake Y, Miyake K, Shiroyama N. (1993b). Classification of aphakic cystoid macular edema with focal macular electroretinograms. *Am J Ophthalmol*, Vol.116, No.5, pp.(576-83).
- Miyake Y, Horiguchi M, Tomita N, Kondo M, Tanikawa A, Takahashi H, Suzuki S, Terasaki H. (1996). Occult macular dystrophy. *Am J Ophthalmol*, Vol.122, No.5, pp.(644-53).
- Miyake Y. (2006). *Electrodiagnosis of Retinal Disease*. pp.(1-234), Springer-Verlag Tokyo, Tokyo

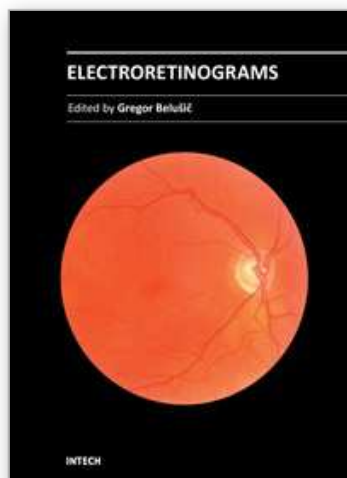
- Moschos MM, Brouzas D, Loukianou E, Apostolopoulos M, Moschos M. (2007). Intraocular triamcinolone acetonide for macular edema due to CRVO. A multifocal-ERG and OCT study. *Doc Ophthalmol*, Vol.114, No.1, pp.(1-7).
- Moschos MM, Moschos M. (2008). Intraocular bevacizumab for macular edema due to CRVO. A multifocal-ERG and OCT study. *Doc Ophthalmol*, Vol.116, No.2, pp.(147-52).
- Nakamura H, Miyamoto K, Yokota S, Ogino K, Yoshimura N. (2011). Focal macular photopic negative response in patients with optic neuritis. *Eye (Lond)*, Vol.25, No.3, pp.(358-64).
- Niwa T, Terasaki H, Kondo M, Piao CH, Suzuki T, Miyake Y. (2003). Function and morphology of macula before and after removal of idiopathic epiretinal membrane. *Invest Ophthalmol Vis Sci*, Vol.44, No.4, pp.(1652-6).
- Nusinowitz S, Hood DC, Birch DG. (1995). Rod transduction parameters from the a wave of local receptor populations. *J Opt Soc Am A Opt Image Sci Vis*, Vol.12, No.10, pp.(2259-66).
- Nusinowitz S, Sarraf D. (2008). Retinal function in X-linked ocular albinism (OA1). *Curr Eye Res*, Vol.33, No.9, pp.(789-803).
- Ogino K, Tsujikawa A, Nakamura H, Miyamoto K, Murakami T, Muraoka Y, Kurashige Y, Yoshimura N. (2011). Focal Macular Electroretinogram in Macular Edema Secondary to Central Retinal Vein Occlusion. *Invest Ophthalmol Vis Sci*, in press.
- Palmowski AM, Sutter EE, Bearse MA Jr., Fung W. (1997). Mapping of retinal function in diabetic retinopathy using the multifocal electroretinogram. *Invest Ophthalmol Vis Sci*, Vol.38, No.12, pp.(2586-2596).
- Palmowski AM, Allgayer R, Heinemann-Vernaleken B, Ruprecht KW. (2002). Influence of photodynamic therapy in choroidal neovascularization on focal retinal function assessed with the multifocal electroretinogram and perimetry. *Ophthalmology*, Vol.109, No.10, pp.(1788-92).
- Palmowski AM, Allgayer R, Heinemann-Vernaleken B, Scherer V, Ruprecht KW. (2003). Detection of retinal dysfunction in vitelliform macular dystrophy using the multifocal ERG (MF-ERG). *Doc Ophthalmol*, Vol.106, No.2, pp.(145-52).
- Park SJ, Woo SJ, Park KH, Hwang JM, Chung H. (2010). Morphologic photoreceptor abnormality in occult macular dystrophy on spectral-domain optical coherence tomography. *Invest Ophthalmol Vis Sci*, Vol.51, No.7, pp.(3673-3679).
- Piao CH, Kondo M, Tanikawa A, Terasaki H, Miyake Y. (2000). Multifocal electroretinogram in occult macular dystrophy. *Invest Ophthalmol Vis Sci*, Vol.41, No.2, pp.(513-7).
- Piao CH, Kondo M, Nakamura M, Terasaki H, Miyake Y. (2003). Multifocal electroretinograms in X-linked retinoschisis. *Invest Ophthalmol Vis Sci*, Vol.44, No.11, pp.(4920-30).
- Sabates R, Hirose T, McMeel JW. (1983). Electroretinography in the prognosis and classification of central retinal vein occlusion. *Arch Ophthalmol*, Vol.101, No.2, pp.(232-5).
- Salzman J, Seiple W, Carr R, Yannuzzi L. (1986). Electrophysiological assessment of aphakic cystoid macular oedema. *Br J Ophthalmol*, Vol.70, No.11, pp.(819-24).

- Sandberg MA, Pawlyk BS, Berson EL.(1996). Isolation of focal rod electroretinograms from the dark-adapted human eye. *Invest Ophthalmol Vis Sci*, Vol.37, No.5, pp.(930-4).
- Shimada Y, Li Y, Bearse MA Jr, Sutter EE, Fung W. (2001). Assessment of early retinal changes in diabetes using a new multifocal ERG protocol. *Br J Ophthalmol*, Vol.85, No.4, pp.(414-9).
- Shinoda K, Ohde H, Ishida S, Kawashima S, Kitamura S, Mita S, Inoue M, Katsura H. (2000). A case of proliferative diabetic retinopathy with development of ischemic optic neuropathy after pars plana vitrectomy. *Folia Ophthalmol Jpn*, Vol.51, pp.(925-929). Japanese.
- Spaide RF, Koizumi H, Freund KB. (2008). Photoreceptor outer segment abnormalities as a cause of blind spot enlargement in acute zonal occult outer retinopathy-complex diseases. *Am J Ophthalmol*, Vol.146, No.1, pp.(111-120).
- Sutter EE, Tran D. (1992). The field topography of ERG components in man--I. The photopic luminance response. *Vision Res*, Vol.32, No.3, pp.(433-46).
- Sutter EE, Shimada Y, Li Y, Bearse MA. (1999). Mapping inner retinal function through enhancement of adaptive components in the m-ERG, In: *Vision science and its applications. OSA Technical Digest Series*, Pp.(52-55), Optical Society of America, Washington, DC.
- Sugahara M, Shinoda K, Matsumoto CS, Satofuka S, Hanazono G, Imamura Y, Mizota A. (2011). Outer Retinal Microstructure in Case of Acute Idiopathic Blind Spot Enlargement Syndrome. *Case Reports in Ophthalmol*, Vol.2, No.1, pp.(116-22).
- Tanikawa A, Horiguchi M, Kondo M, Suzuki S, Terasaki H, Miyake Y. (1999). Abnormal focal macular electroretinograms in eyes with idiopathic epimacular membrane. *Am J Ophthalmol*, Vol.127, No.5, pp.(559-64).
- Terasaki H, Miyake Y, Nomura R, Piao CH, Hori K, Niwa T, Kondo M. (2001). Focal macular ERGs in eyes after removal of macular ILM during macular hole surgery. *Invest Ophthalmol Vis Sci*, Vol.42, No.1, pp.(229-34).
- Terasaki H, Miyake K, Miyake Y. (2003). Reduced oscillatory potentials of the full-field electroretinogram of eyes with aphakic or pseudophakic cystoid macular edema. *Am J Ophthalmol*, Vol.135, No.4, pp.(477-82).
- Terauchi N, Fujinami K, Shinoda K, Tsunoda K, Hanazono G, Miyake Y, Inomata K. (2007). Transient macular dysfunction determined by focal macular electroretinogram. *Br J Ophthalmol*, Vol.91, No.12, pp.(1709-10).
- Tsunoda K, Fujinami K, Miyake Y. (2011). Selective abnormality of cone outer segment tip line in acute zonal occult outer retinopathy as observed by Fourier domain optical coherence tomography. *Arch Ophthalmol*, in press.
- Ueno S, Kondo M, Piao CH, Ikenoya K, Miyake Y, Terasaki H.(2006). Selective amplitude reduction of the PhNR after macular hole surgery: ganglion cell damage related to ICG-assisted ILM peeling and gas tamponade. *Invest Ophthalmol Vis Sci*, Vol.47, No.8, pp.(3545-9).
- Watanabe K, Shinoda K, Kimura I, Mashima Y, Oguchi Y, Ohde H. (2007). Discordance between subjective perimetric visual fields and objective multifocal visual evoked potential-determined visual fields in patients with hemianopsia. *Am J Ophthalmol*, Vol.143, No.2, pp.(295-304).

- Yamada K., Matsumoto CS, Nakatsuka, K. (2006). Effect of spatial frequency of stimulus on focal macular ERGs in monkeys. *Doc Ophthalmol*, Vol. 113, pp.(83-91).
- Yonemura D, Aoki T, Tsuzuki K. (1962). Electroretinogram in diabetic retinopathy. *Arch Ophthalmol*, Vol.68, No.68, pp.(19-24).
- Yoon IH, Shiroyama N, Miyake Y, Awaya S. (1990). Oscillatory potentials of local macular ERG in diabetic retinopathy. *Korean J Ophthalmol*, Vol.4, No.1, pp.(40-5).

IntechOpen

IntechOpen



Electroretinograms

Edited by Dr. Gregor Belusic

ISBN 978-953-307-383-5

Hard cover, 238 pages

Publisher InTech

Published online 09, August, 2011

Published in print edition August, 2011

Electroretinography (ERG) is a non-invasive electrophysiological method which provides objective information about the function of the retina. Advanced ERG allows to assay the different types of retinal receptors and neurons in human and animal models. This book presents contributions on the recent state of the ERG. The book is divided into three parts. The first, methodological part, reviews standard methods and normatives of human ERG, reports about the advanced spatial, temporal and spectral methods of stimulation in human ERG, and deals with the analysis of the multifocal ERG signal. The second part deals with the ERG in different diseases of the human visual system and in diabetes. The third part presents the ERG in the standard animal models of human retinal disease: mouse, rat, macaque and fruitfly.

How to reference

In order to correctly reference this scholarly work, feel free to copy and paste the following:

Kei Shinoda, Celso Soiti Matsumoto and Hisao Ohde (2011). Objective Assessment of Local Retinal Function by Focal Macular and Multifocal Electroretinograms, *Electroretinograms*, Dr. Gregor Belusic (Ed.), ISBN: 978-953-307-383-5, InTech, Available from: <http://www.intechopen.com/books/electroretinograms/objective-assessment-of-local-retinal-function-by-focal-macular-and-multifocal-electroretinograms>

INTECH
open science | open minds

InTech Europe

University Campus STeP Ri
Slavka Krautzeka 83/A
51000 Rijeka, Croatia
Phone: +385 (51) 770 447
Fax: +385 (51) 686 166
www.intechopen.com

InTech China

Unit 405, Office Block, Hotel Equatorial Shanghai
No.65, Yan An Road (West), Shanghai, 200040, China
中国上海市延安西路65号上海国际贵都大饭店办公楼405单元
Phone: +86-21-62489820
Fax: +86-21-62489821

© 2011 The Author(s). Licensee IntechOpen. This chapter is distributed under the terms of the [Creative Commons Attribution-NonCommercial-ShareAlike-3.0 License](https://creativecommons.org/licenses/by-nc-sa/3.0/), which permits use, distribution and reproduction for non-commercial purposes, provided the original is properly cited and derivative works building on this content are distributed under the same license.

IntechOpen

IntechOpen