

# We are IntechOpen, the world's leading publisher of Open Access books Built by scientists, for scientists

6,900

Open access books available

185,000

International authors and editors

200M

Downloads

Our authors are among the

154

Countries delivered to

TOP 1%

most cited scientists

12.2%

Contributors from top 500 universities



WEB OF SCIENCE™

Selection of our books indexed in the Book Citation Index  
in Web of Science™ Core Collection (BKCI)

Interested in publishing with us?  
Contact [book.department@intechopen.com](mailto:book.department@intechopen.com)

Numbers displayed above are based on latest data collected.  
For more information visit [www.intechopen.com](http://www.intechopen.com)



# A Rare Gastric Carcinoma - Neuroendocrine Tumors

Petar Svorcan, Jelena Djordjevic and Branko Maksimovic  
Zvezdara Medical Center  
Belgrade,  
Serbia

## 1. Introduction

Neuroendocrine tumors, or more properly gastro-entero-pancreatic tumors (GEP-NETs), are cancers of the interface between the endocrine (hormonal) system and the nervous system. A neuroendocrine tumor begins in the hormone-producing cells of the body's neuroendocrine system, which is made up of cells that are a cross between traditional endocrine cells (or hormone-producing cells) and nerve cells. Neuroendocrine cells are found throughout the body in organs, such as the lungs and gastrointestinal tract (such as the stomach and intestines), and perform specific functions, such as regulating the air and blood flow through the lungs and controlling the speed at which food is moved through the gastrointestinal tract (1).

## 2. NETs epidemiology and characteristics

Neuroendocrine tumors (NETs) are rare, slow-growing neoplasms characterized by their ability to store and secrete different peptides and neuroamines. Some of these substances cause specific clinical syndromes, whereas other may have elevated plasma or urine levels that are not associated with specific syndromes or symptom complexes. The biochemical markers are those hormones or amines secreted by the neuroendocrine cells from which these tumors are derived. Some of these are not specific to any tumor, but are produced and secreted by most NETs, whereas other biochemical markers are more specific to the type of tumor and where their quantification can lead to the suspicion or confirmation of the presence of such a tumor (2). There are many types of neuroendocrine tumors, such as: pheochromocytoma, Merkel cell cancer, and neuroendocrine carcinoma, and also other types of cancer that begin in hormone-producing cells, including endocrine tumors, carcinoid tumors, thymoma, thyroid cancer, and islet cell tumors. Approximately 60% of neuroendocrine tumors are not able to be described as a specific type of cancer other than neuroendocrine carcinoma. Neuroendocrine carcinoma can be found in a number of places in the body, including the lungs, brain, and gastrointestinal tract. The annual incidence of NETs has risen to 40 to 50 cases per million, perhaps because of better diagnosis and the availability of highly specific and sensitive ways to measure these tumors products, improved immunohistochemistry, and enhanced techniques for tumor detection (3). There are a number of impediments to the diagnosis of these tumors. They are rare, comprising less than 2% of

gastrointestinal (GI) malignancies, and are therefore not high on the list of causes of specific symptom complexes. Symptoms themselves are often nonspecific and do not lend themselves readily to identifying the specific underlying tumor. In addition, the manifestations are protean and mimic a variety of disorders. Tumors may be found incidentally on laparoscopy for abdominal pain or during the surgical removal of an appendix or even during a computerized tomographic scan of the abdomen for unexplained symptoms (3,4).

3. Classification of GEP-NETs by site of origin and by symptoms

The clinical behavior of NETs is extremely variable; they may be functioning or not functioning, ranging from very slow-growing tumors (well-differentiated NETs), which are the majority, to highly aggressive and very malignant tumors (poorly differentiated NETs) (5).

Classification	Biological behavior	Metastases	Ki-67 index (%) <sup>†</sup>	Histological differentiation	Infiltration/angioinvasion	Tumor size (cm)
Well-differentiated NET	Benign	- <sup>‡</sup> ; $\pm$ <sup>§</sup>	<2	Well	-	$\leq$ 1
Well-differentiated neuroendocrine carcinoma	Low malignancy	$\pm$	>2	Well	+	>2 <sup>‡</sup> ; >3 <sup>§</sup>
Poorly-differentiated neuroendocrine carcinoma	High malignancy	+	>30	Poor	+	Any size

<sup>†</sup>Identical to MIB1.  
<sup>‡</sup>Gastrointestinal neuroendocrine tumor.  
<sup>§</sup>Pancreatic neuroendocrine tumor.  
NET: Neuroendocrine tumor.

Table 1. WHO classification of neuroendocrine tumors.

3.1 Nonfunctioning NETs

Nonfunctioning NETs are not associated with a distinct hormonal syndrome so are more difficult to detect than functioning NETs; owing to this, patients generally present late with large primary tumors and advanced disease. However, nonfunctioning NETs may secrete bioactive hormones or amines at subclinical levels, or secrete compounds that lead to other, still under-recognized hormonal syndromes. They can also cause nonspecific symptoms related to increased tumor mass and/or metastases such as weight loss, bleeding or abdominal pain.

3.2 Functioning NETs

NETs can arise in different organs and from different cell types and so present a clinical challenge to physicians owing to their diversity and the variety of symptoms they cause.

Functioning NETs are characterized by the hormones they produce and/or the symptoms they cause; clinical symptoms are typically observed following metastasis to the liver.

### 3.3 GEP-NETs classification

The vast majority of GEP-NETs fall into two nearly distinct categories: carcinoids, and pancreatic endocrine tumors (PETs). Despite great behavioral differences between the two, they are grouped together as GEP-NETs because of similarities in cell structure. PETs (1-2% of all pancreatic tumors) may secrete hormones (as a result, perhaps, of impaired storage ability), and those hormones can wreak symptomatic havoc on the body. Those PETs that do not secrete hormones are called *nonfunctioning* tumors. Secretory (*functioning*) tumors are classified by the hormone most strongly secreted – for example, insulinoma, which produces excessive insulin, and gastrinoma, which produces excessive gastrin. Carcinoid tumors are further classified, depending on the point of origin, as foregut (lung, thymus, stomach, and duodenum) or midgut (distal ileum and proximal colon) or hindgut (distal colon and rectum). Less than one percent of carcinoid tumors originate in the pancreas. But for many tumors, the point of origin is unknown. Carcinoid tumors tend to grow much more slowly than PETs (2,6).

### 3.4 Carcinoid syndrome

A carcinoid tumor may produce serotonin (5-HT), a biogenic amine that causes a specific set of symptoms including

- flushing
- diarrhea or increase in number of bowel movements
- weight loss
- weight gain
- heart palpitations
- congestive heart failure (CHF)
- asthma
- acromegaly
- Cushing's syndrome

This set of symptoms is called *carcinoid syndrome* which occurs in approximately 10% of patients with metastatic NETs. It is characterized by flushing (63–94% of patients), diarrhea (68–84%), abdominal pain (10–55%), telangiectasia (25%) and bronchoconstriction (3–19%). Carcinoid crisis is the most immediate life-threatening complication of carcinoid syndrome and is thought to result from a massive release of bioactive products from the tumor. Crises can occur spontaneously, but often arise in response to stress, anesthesia, chemotherapy or surgery. Symptoms are an exacerbation of the usual clinical symptoms of carcinoid syndrome, including severe flushing with or without bronchospasm, tachycardia and hypo/hypertension. Failure to effectively manage carcinoid syndrome can lead to exposure of the heart to high levels of vasoactive substances released from hepatic metastases, which causes carcinoid heart disease; between 10–20% of patients with carcinoid syndrome have heart disease at diagnosis. Carcinoid heart disease is characterized by plaque-like, fibrous thickening of the endocardium (classically on the right side of the heart); tricuspid and pulmonary valves; right-sided carcinoid heart disease is associated with substantial morbidity and mortality (7-10).

### 3.5 Summary of GEP - NETs classification (2,11,12)

- carcinoids (about two thirds of GEP-NETs)
  - with carcinoid syndrome (about 10 percent of carcinoids)
  - without carcinoid syndrome (about 90 percent of carcinoids)
- PETs (about one third of GEP-NETs)
  - nonfunctioning (15 to 30 percent of PETs)
  - functioning (70 to 85 percent of PETs)
    - gastrinoma, producing excessive gastrin and causing Zollinger-Ellison Syndrome (ZES)
    - insulinoma, producing excessive insulin
    - glucagonoma, producing excessive glucagon
    - vasoactive intestinal peptideoma (VIPoma), producing excessive vasoactive intestinal peptide (VIP)
    - PPoma, producing excessive pancreatic polypeptide (often classed with nonfunctioning PETs)
    - somatostatinoma, producing excessive somatostatin
    - watery diarrhea, hypokalemia-achlorhydria (WDHA)
    - CRHoma, producing excessive corticotropin-releasing hormone (CRH)
    - calcitoninoma, producing excessive calcitonin
    - GHRHoma, producing excessive growth-hormone-releasing hormone (GHRH)
    - neurotensinoma, producing excessive neurotensin
    - ACTHoma, producing excessive adrenocorticotrophic hormone (ACTH)
    - GRFoma, producing excessive Growth hormone-releasing factor (GRF)
    - parathyroid hormone-related peptide tumor
- Other NETs
  - medullary carcinoma of the thyroid
  - Merkel cell cancer (trabecular cancer)
  - small-cell lung cancer (SCLC)
  - large-cell neuroendocrine carcinoma (of the lung)
  - extrapulmonary small cell carcinomas (ESCC or EPSCC) in general
  - neuroendocrine carcinoma of the cervix
  - Multiple Endocrine Neoplasia type 1 (MEN-1 or MEN1) (usually nonfunctioning) (also causing ZES)
  - Multiple Endocrine Neoplasia type 2 (MEN-2 or MEN2)
  - neurofibromatosis type 1
  - tuberous sclerosis
  - von Hippel-Lindau (VHL) disease
  - neuroblastoma
  - pheochromocytoma (phaeochromocytoma)
  - paraganglioma
  - neuroendocrine tumor of the anterior pituitary
  - Carney's complex

### 4. Metastases and malignancy

GEP-NETs are often malignant, since the primary site often eludes detection for years, sometimes decades – during which time the tumor has the opportunity to metastasize. The

most common metastatic sites are the liver, the lymph nodes, and the bones. Liver metastases are so frequent and have such prominent blood supply that for many patients, they dominate the course of the cancer (13).

5. Well-differentiated neuroendocrine (carcinoid) tumors of the stomach

Neuroendocrine tumors (NETs) of the stomach comprise less than 1% of gastric neoplasms. In the pre-endoscopy era, they comprised 1.9% of all carcinoids, but in more recent studies, 10% to 30% of all carcinoids are reported in the stomach. They can be subclassified into 3 distinct groups: those associated with chronic atrophic gastritis/pernicious anemia (type 1; 70%-80%), those associated with Zollinger-Ellison syndrome (ZES) with multiple endocrine neoplasia type I (MEN I) (type 2; 5%), and sporadic NETs of the stomach (type 3; 15%-20%) (13-15).

5.1 Etiology

Both types 1 and 2 NETs of the stomach are associated with hypergastrinemia (Table 2). High levels of gastrin are thought to result in hyperplasia of the enterochromaffin-like cells in the stomach, ultimately leading to hyperplastic lesions and small, often multiple carcinoid tumors. In contrast to types 1 and 2 carcinoids, type 3 carcinoids develop in the absence of hypergastrinemia and tend to pursue an aggressive clinical course. Type 1 carcinoids are generally small and frequently multiple; limited to the mucosa-submucosa, and metastases occur in less than 2.5% to lymph nodes and less than 2.5% to the liver. Type 2 carcinoids are almost always multiple and generally small (<1 cm) and are usually limited to the mucosa-submucosa, but are slightly more aggressive than type 1 carcinoids, with up to 30% showing lymph node metastases, and up to 10% may show liver metastases. Type 3 carcinoids are usually single, generally larger (>1 cm in 70%), and invasive through the submucosa and deeper in most cases (>75%); 70% had accompanying lymph node metastases, and 69% had distant metastases (16,17).

	Hypergastrinemia	Gastric acid Secretion	Typical Size, cm	No. tumors	Clinical Features
Type 1 (in setting of chronic atrophic gastritis type A)	Yes (as a result of achlorhydria)	Low	< 1	Multifocal	Rarely invasive; endoscopic removal often adequate
Type 2 (in setting of ZES)	Yes (as a result of ectopic gastrin secretion)	High	< 1	Multifocal	Rarely invasive; may respond to somatostatin analogs
Type 3 (sporadic)	No	Normal	> 1	Solitary	Frequently invasive and metastatic

Table 2. Types of gastric NETs

5.2 Pathological classification

In general, NETs of the stomach and other NETs are divided into well-differentiated and poorly differentiated categories. The concept of differentiation is linked to the grade of the



tumors (see below), but there are subtle differences between differentiation and grade. Differentiation refers to the extent to which the neoplastic cells resemble their nonneoplastic counterparts. In NETs, well-differentiated examples have characteristic "organoid" arrangements of the tumor cells, with nesting, trabecular, or gyriform patterns. The cells are relatively uniform and produce abundant neurosecretory granules, reflected in the strong and diffuse immunoeexpression of neuroendocrine markers such as chromogranin A (CGA) and synaptophysin. Poorly differentiated NETs less closely resemble nonneoplastic neuroendocrine cells and have a more sheet-like or diffuse architecture, irregular nuclei, and less cytoplasmic granularity. Immunoeexpression of neuroendocrine markers is usually more limited. Grade, on the other hand, refers to the inherent biologic aggressiveness of the tumor. Low-grade NETs are relatively indolent, high-grade tumors are extremely aggressive, and intermediate-grade examples have a less predictable, moderately aggressive course. In general, well-differentiated NETs are either low or intermediate grade, and poorly differentiated NETs are considered high grade in all cases (Table 3 ) (18-22).

Differentiation	Grade
Well differentiated	Low grade (ENETS G1) Intermediate grade (ENETS G2)
Poorly differentiated	High grade (ENETS G3)

Table 3. Differentiation of gastric NETs

Grade	Lung, Thymus (WHO)	GEP NETs (ENETS)	GEP NETs (WHO 2010)
Low grade	Carcinoid tumor	NET grade 1 (G1)	Neuroendocrine neoplasm grade 1
Intermediate grade	Atypical carcinoid tumor	NET grade 2 (G2)	Neuroendocrine neoplasm grade 2
High grade	Small cell carcinoma	Neuroendocrine carcinoma grade 3 (G3), small cell carcinoma	Neuroendocrine carcinoma grade 3, small cell carcinoma
	Large cell neuroendocrine carcinoma	Neuroendocrine carcinoma grade 3 (G3), large cell neuroendocrine	Neuroendocrine carcinoma grade 3, large cell neuroendocrine carcinoma
The grade of the tumor must be included in the pathology report, along with a reference to the specific grading system being used. Unqualified terms such as neuroendocrine tumor or neuroendocrine carcinoma without reference to grade do not provide adequate pathology information.			

Table 4. Differentiation of gastric Nets (2)

Table 4 displays a comparison of the various systems of nomenclature currently in use for NETs, along with for which organ systems each system is most commonly used. Figures 1-3 are presenting histology evaluation of neuroendocrine gastric carcinoma-large cell type, that demonstrates trabecula and islet of round cells with rare eosinophilic cytoplasm. The nuclei are atypical, hyperchromatic, moderately pleomorphic, without prominent nucleolus. The stroma is edematous. Vascular invasion in mucosa and submucosa is also detected ( Stained H&E - Figure 1). Cytological immunophenotypes includes: marked and diffuse immunoreactivity in the majority of the cells to neuron specific-enolase (NSE) - ( Figure 2), chromogranin A( Figure 3 ) and synaptophysin.

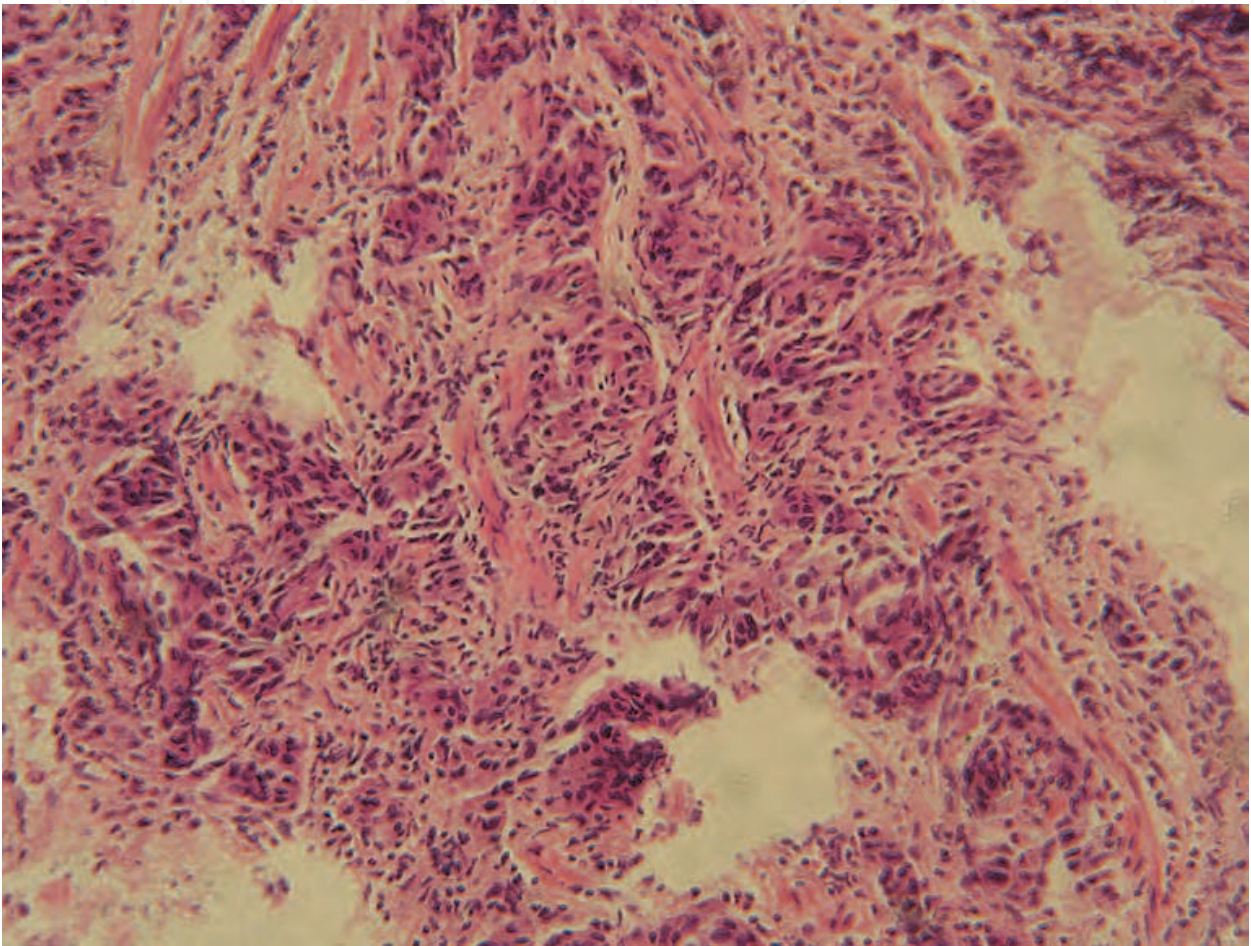


Fig. 1. Neuroendocrine gastric carcinoma-large cell type, Stained H&E, x400. Courtesy by Prof S.Usaj

The American Joint Committee on Cancer (AJCC) has recently published a new TNM staging manual that includes NETs of all anatomical sites, and the ENETS has previously published recommendations for TNM staging of GEP NETs. Additionally, the staging criteria for both systems rely predominantly on the size of the tumor and the extent of invasion into similar landmarks as used for the staging of nonneuroendocrine carcinomas of the same sites. It is recommended that the extent of involvement of these structures be specifically indicated in the pathology reports, in addition to providing a TNM stage based on a system that is specifically referenced (Table 5) (23-26). Figures 4 and 5 represent T2 and M1 GEP NET thru the EUS image.



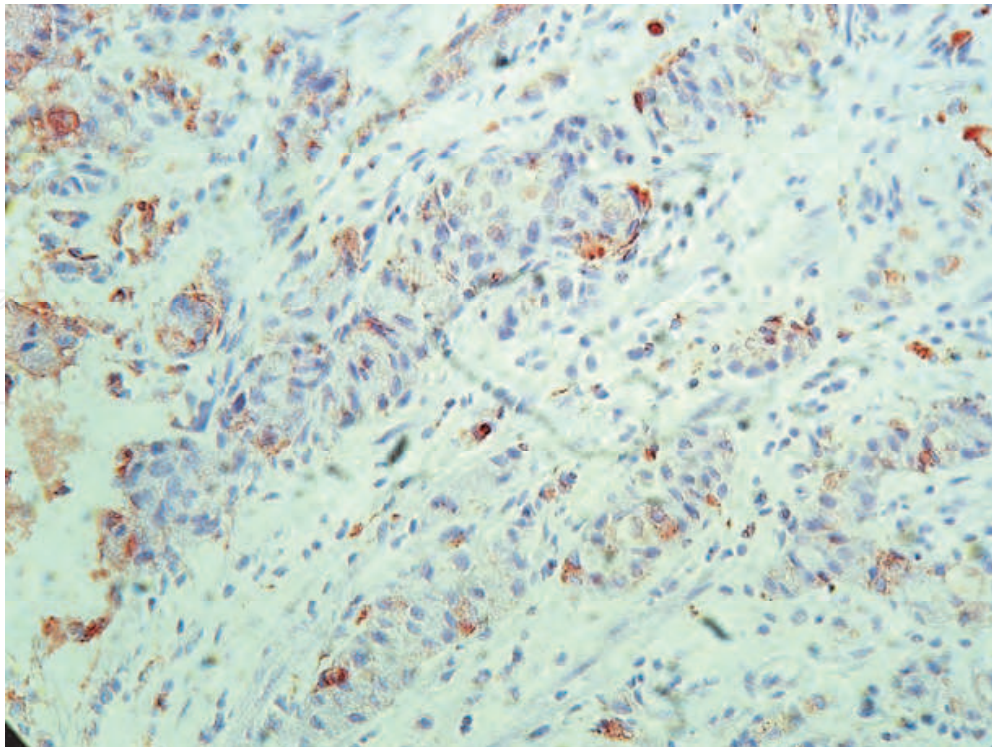


Fig. 2. Neuroendocrine tumor cells of the stomach wall -Immunostaining - NSE (LSAB+ , x200). Courtesy by Prof S.Usaj

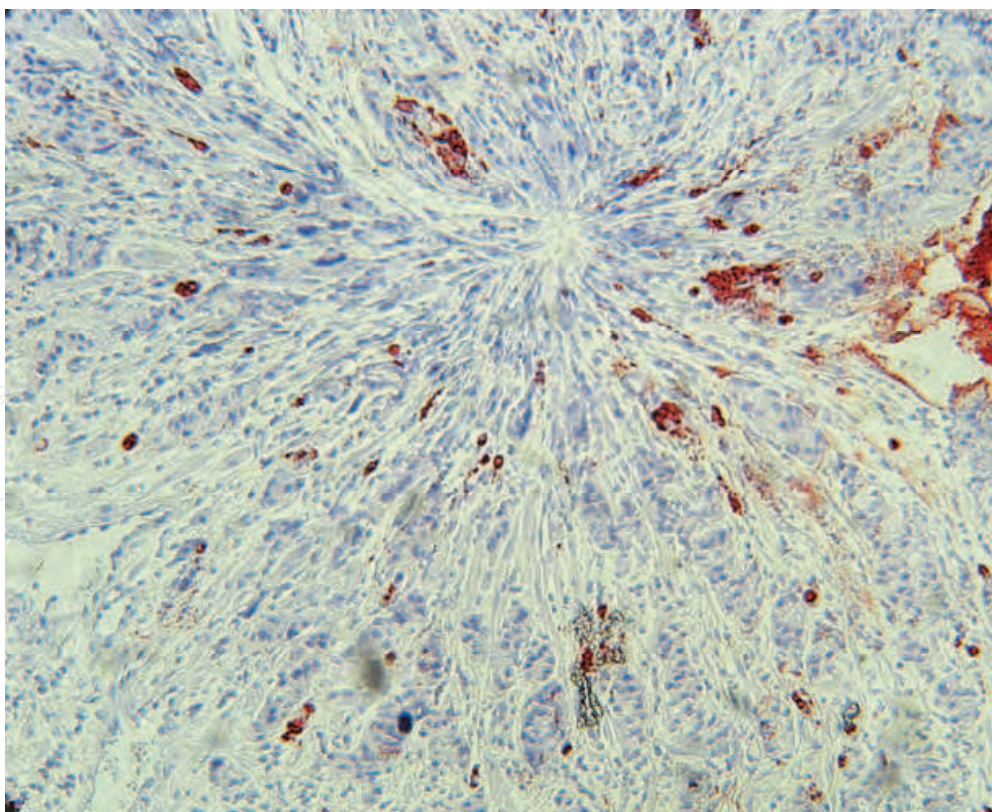


Fig. 3. Neuroendocrine tumor cells of the stomach wall- Immunostaining - chromogranin A (LSAB+ , x200). Courtesy by Prof S.Usaj

AJCC Primary tumor (T)				ENETS T-Primary Tumor			
TX		Primary tumor cannot be assessed		TX		Primary tumor cannot be assessed	
T0		No evidence of primary tumor		T0		No evidence of primary tumor	
Tis		Carcinoma in situ/dysplasia (tumor size <0.5mm), confined to mucosa		—			
T1		Tumor invades lamina propria or submucosa and ≤ 1 cm		T1		Tumor invades lamina propria or submucosa and ≤ 1 cm	
T2		Tumor invades muscularis propria or > 1 cm		T2		Tumor invades muscularis propria or > 1 cm	
T3		Tumor penetrates subserosa		T3		Tumor invades pancreas or retroperitoneum	
T4		Tumor invades serosa (visceral peritoneum) or other organs or adjacent structures		T4		Tumor invades peritoneum or other organs	
Regional Lymph nodes (N)				N-Regional Lymph Nodes			
NX		Regional lymph node(s) cannot be assessed		NX		Regional lymph node(s) cannot be assessed	
N0		No regional lymph node metastasis		N0		No regional lymph node metastasis	
N1		Regional lymph node metastasis		N1		Regional lymph node metastasis	
Distant metastasis (M)				M-distant metastasis			
—				MX		Distant metastasis cannot be assessed	
M0		No distant metastasis		M0		No distant metastasis	
M1		Distant metastasis		M1		Distant metastasis	
Stage	T	N	M	Stage	T	N	M
0	Tis	N0	M0	0	Tis	N0	M0
I	T1	N0	M0	I	T1	N0	M0
IIA	T2	N0	M0	IIa	T2	N0	M0
IIB	T3	N0	M0	IIb	T3	N0	M0
IIIA	T4	N0	M0	IIIa	T4	N0	M0
IIIB	Any T	N1	M0	IIIb	Any T	N1	M0
IV	Any T	Any N	M1	IV	Any T	Any N	M1

Table 5. The TNM NETs classification



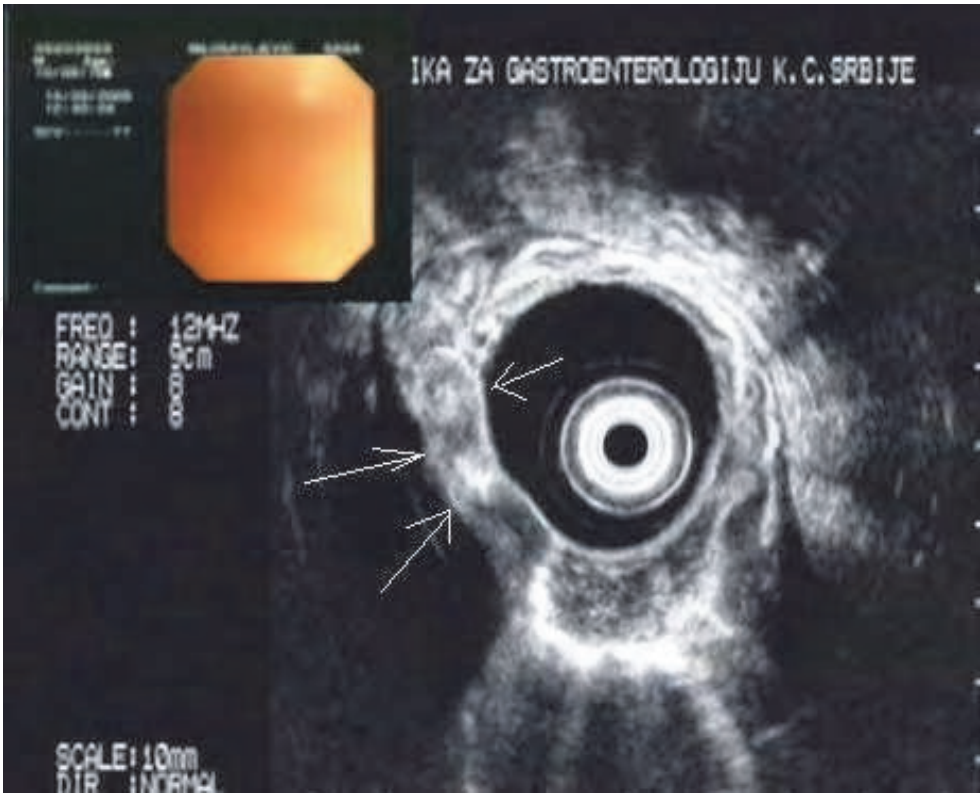


Fig. 4. EUS image: T2 tumor of the stomach wall. Courtesy by Prof M.Krstic

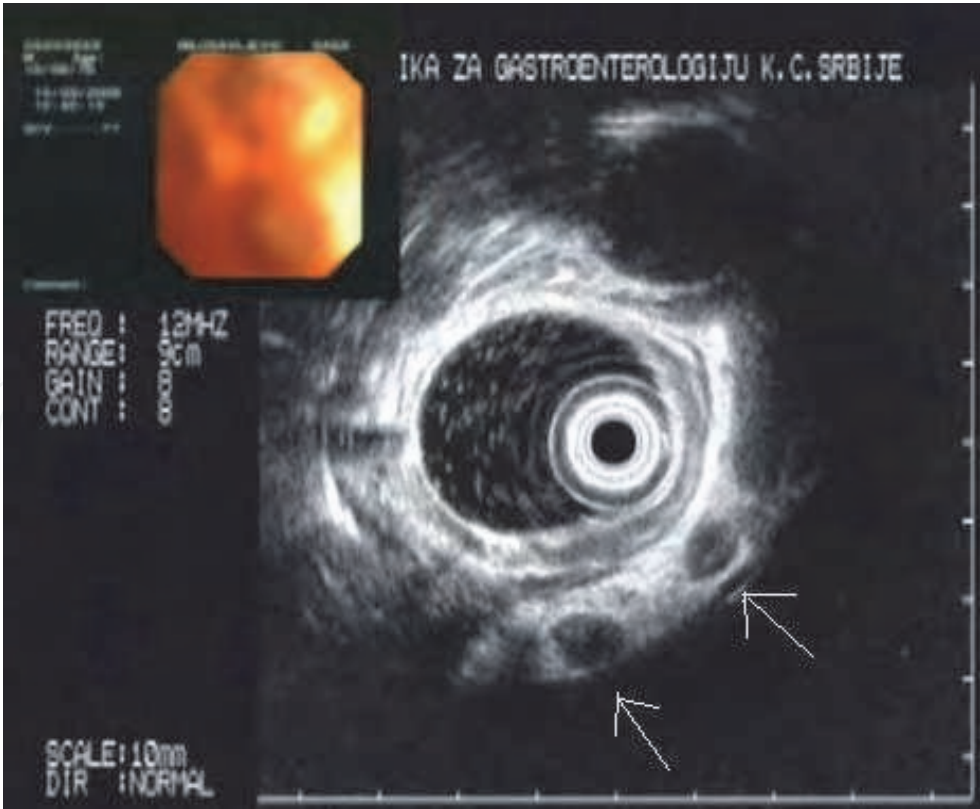


Fig. 5. EUS image of enlarged lymph nodes around the tumor (see white arrows). Courtesy by Prof M.Krstic

## 6. Imaging

Most NETs of the stomach are directly imaged and diagnosed during endoscopy. For larger lesions, endoscopic ultrasound (EUS) may be performed to assess whether the NETs of the stomach is invasive. Cross-sectional imaging with computed tomography (CT) or magnetic resonance imaging (MRI) is recommended to assess for metastases in patients with type 1 or 2 NETs of the stomach more than 2 cm in diameter, or for patients with type 3 NETs of the stomach in whom metastatic risk is a concern. Neuroendocrine tumors are generally vascular tumors that enhance intensely with intravenous contrast during early arterial phases of imaging with washout during the delayed portal venous phase. The key to detecting small NETs on CT is to maximize the contrast between the tumor and the adjacent normal parenchyma. For abdominal and pelvic imaging, recommendation is multiphasic CT that includes the arterial phase and the portal venous phase. Rapid intravenous bolus of intravenous contrast is also recommended. Thin sectioning and the use of a negative oral contrast agent also may be helpful in detecting small primary tumor in the small bowel that may not otherwise be seen. Magnetic resonance imaging is preferred over CT for patients with a history of allergy to iodine contrast material or for those with renal insufficiency. Somatostatin receptor scintigraphy (SRS) provides a second useful imaging modality for the detection of metastatic disease in patients with malignant NETs of the stomach. Indium In 111-labeled somatostatin analog [<sup>111</sup>In-DTPA<sup>0</sup>]octreotide was developed for scintigraphy of NETs. It shares the receptor-binding profile of octreotide, which makes it a good radiopharmaceutical for imaging of somatostatin receptor 2- and receptor 5-positive tumors. The overall sensitivity of [<sup>111</sup>In-DTPA<sup>0</sup>]octreotide scintigraphy seems to be about 80% to 90%. Unlike cross-sectional imaging, which is generally site directed, [<sup>111</sup>In-DTPA<sup>0</sup>]octreotide scintigraphy is done as whole-body imaging and thus can detect disease at unsuspected sites. Chest x-ray can be used as a screening examination for patients without evidence of thoracic disease (27,29).

## 7. Biochemical monitoring

Fasting serum gastrin levels are important to differentiate types 1 and 2 NETs of the stomach from type 3. 5-Hydroxyindoleacetic acid (5-HIAA) levels are generally not useful in patients with NETs of the stomach, because development of the carcinoid syndrome is uncommon. Furthermore, carcinoid syndrome, if it occurs in these patients, is reported to be characteristically atypical with normal serotonin and 5-HIAA levels, although a recent study reports the typical carcinoid syndrome can occur in rare patients with NETs of the stomach. Plasma CGA levels are recommended because CGA is frequently elevated in both patients with types 1 and 2 as well as type 3 NETs of the stomach, and changes in CGA levels may be helpful in the follow-up. Chromogranin A should be used with caution as a marker of disease activity in patients treated with somatostatin analogs, because these agents significantly reduce plasma CGA levels, a change that may be more reflective of changes in hormonal synthesis and release from tumor cells than an actual reduction in tumor mass. In patients on stable doses of somatostatin analogs, consistent increases in plasma CGA levels over time may reflect loss of secretory control and/or tumor growth. Plasma CGA levels have also been shown to have a prognostic value in patients with metastatic disease (16,17,30,31).

8. Management of localized NETs of the stomach

Because types 1 and 2 NETs of the stomach generally pursue an indolent course, tumors less than 2 cm (up to 6) should be resected endoscopically, with subsequent interval follow-up (15,27,32). Patients with tumors measuring more than 2 cm, with recurrent tumors or with more than 6 polyps, generally require more aggressive management, and local surgical resection is recommended. In patients with type 1 NETs of the stomach arising in the setting of chronic atrophic gastritis, antrectomy may be performed to eliminate the source of gastric production. Antrectomy has been reported to result in tumor regression in such cases. In patients with type 2 NETs of the stomach secondary to ZES/MEN I syndrome, treatment with somatostatin analogs may be initiated and has resulted in tumor regression.(33-35) The surgical management of type 3 isolated sporadic NETs of the stomach requires more aggressive surgery, generally with partial gastrectomy and lymph node dissection (Table 6). Surgery is the only therapy that can cure GEP-NETs. However, the typical delay in diagnosis, giving the tumor the opportunity to metastasize, makes most GEP-NETs ineligible for surgery (non-resectable). The most common nonsurgical therapy for all GEP-NETs is chemotherapy, although chemotherapy is reported to be largely ineffective for carcinoids, not particularly durable (long-lasting) for PETs, and inappropriate for PETs of nonpancreatic origin. When chemotherapy fails, the most common therapy, in the United States, is more chemotherapy, with a different set of agents. Some studies have shown that the benefit from one agent is not highly predictive of the benefit from another agent, except that the long-term benefit of any agent is likely to be low. Strong uptake of somatostatin analogs is a negative indication for chemo. There are two major somatostatin-analog-based targeted therapies. The first of the two therapies provides symptomatic relief for patients with secretory tumors. In effect, somatostatin given subcutaneously or intramuscularly

	Size, cm	No. tumors	Therapy	Clinical Features
Type 1 (in setting of chronic atrophic gastritis type A)	< 2	< 6	Resected endoscopically	Rarely invasive; endoscopic removal often adequate
	> 2	> 6	Local surgical resection/antrectomy	
Type 2 (in setting of ZES)	< 2	< 6	Resected endoscopically	Rarely invasive; may respond to somatostatin analogs
	> 2	> 6	Local surgical resection/antrectomy	
Type 3 (sporadic)	> 1	Solitary	Partial gastrectomy and lymph nodes resection	Frequently invasive and metastatic-Chemotherapy, chemotherapy with different agents

Table 6. Management of localized NETs of the stomach



"clogs up" the receptors, blocking the secretion of hormones from the tumor cells. The second of the two major somatostatin-analog-based targeted therapies is called *peptide receptor radionuclide therapy* (PRRT), though we might simply call it *hormone-delivered radiotherapy*. In this form of *radioisotope therapy* (RIT), radioactive substances (called *radionuclides* or *radioligands*) are chemically *conjugated* with hormones (peptides or neuroamines); the combination is given intravenously to a patient who has good uptake of the chosen hormone. The radioactive labelled hormones enter the tumor cells, and the attached radiation damages the tumor- and nearby cells. Not all cells are immediately killed this way. The process of tumor cells dying as result of this therapy can go on for several months, even up to two years. In patients with strongly overexpressing tumor cells, nearly all the radiation either gets into the tumors or is excreted in urine (10).

## 9. Management of metastatic NETs of the stomach

In general, metastatic NETs of the stomach, which are infrequent and therefore usually included in general studies including other more frequent malignant carcinoids (especially midgut), are treated in a similar fashion as these other malignant carcinoids. It has been proposed for the occasional, younger patient without any of these risk factors with a metastatic carcinoid tumor that is unresectable and limited to the liver that liver transplantation remains an option that should be considered (Table 7).

## 10. Hepatic resection and transplantation

A small percentage of patients (5%-15%) with metastatic liver disease with a limited number of hepatic metastases localized preferable to one lobe may be successfully treated with hepatic resection, providing both long-term symptomatic relief and likely increasing survival times. The number of patients with liver-isolated metastatic NETs in whom orthotopic liver transplantation (OLT) has been attempted remains small, resulting in the role of OLT in such patients being controversial and cannot, at this time, be routinely recommended (36-38).

## 11. Hepatic artery embolization

Hepatic arterial embolization is recommended as a palliative option in patients with hepatic metastases who are not candidates for surgical resection, have an otherwise preserved performance status, have disease primarily confined to the liver, and have a patent portal vein. The response rates associated with embolization, as measured either by decrease in hormonal secretion or by radiographic regression, are generally greater than 50% (39-41).

## 12. Cytotoxic chemotherapy

Because of its rarity, there have not been any specific studies of cytotoxic agents in only patients with malignant NETs of the stomach. However, with malignant carcinoids in general, cytotoxic chemotherapy plays only a limited role, and therefore, it is probable that similar results can be expected with malignant NETs of the stomach. Studies of single-agent

therapy with 5-fluorouracil, streptozocin, or doxorubicin in patients with metastatic carcinoid tumors have shown that these agents are associated with only modest response rates (41,42).

13. Systemic treatment of metastatic disease

Patients with metastatic NETs of the stomach may develop an "atypical" carcinoid syndrome related to release of histamine and/or 5-HTP or rarely a typical carcinoid syndrome as seen in patients with metastatic midgut carcinoids. These patients frequently benefit from treatment with somatostatin analogs for symptom control. The addition of  $\alpha$ -interferon to therapy with somatostatin analogs has been reported to be effective in controlling symptoms in patients with carcinoid syndrome who may be resistant to somatostatin analogs alone. Treatment with  $\alpha$ -interferon may therefore be considered in patients with metastatic NETs of the stomach refractory to somatostatin analogs. In clinical trials, doses of  $\alpha$ -interferon have ranged from 3 to 9 MU subcutaneously, administered from 3 to 7 times per week. The direct antineoplastic effects of somatostatin analogs either with or without interferon remain uncertain, although recent studies suggest they have a cytostatic effect in 40% to 70% of patients (41,42).

Metastasis or non resectable GEP NETs	Hepatic resection and transplantation
	Hepatic Artery Embolization
	Cytotoxic Chemotherapy
	Systemic treatment of metastatic disease- somatostatin analogs, interferon
	Radiofrequency Ablation and Cryoablation

Table 7. Management of metastatic NETs of the stomach

## 14. Radiofrequency ablation and cryoablation

Other approaches to the treatment of hepatic metastases include the use of radiofrequency ablation (RFA) and cryoablation, either alone or in conjunction with surgical debulking. These approaches can be performed using a percutaneous or laparoscopic approach.

## 15. Summary and conclusions

To conclude, neuroendocrine tumors are small, slow-growing neoplasms, usually with episodic expression that makes diagnosis difficult, erroneous, and often late; for these reasons, a high index of suspicion is needed, and it is important to understand the pathophysiology of each tumor to decide which biochemical markers are more useful and when they should be used. It is the purpose of this text to show the importance of recognizing, as early as possible, the clinical syndromes that suggest a NET as one of the differential diagnoses, and once suspected, look for the appropriate biochemical markers and radiological or other means that will confirm the diagnosis or confidently discard it. Ultimately, all 3 modalities are important to create a platform for monitoring response to therapy, determining prognosis, and choosing the right therapeutic intervention (43).

## 16. References

- [1] Arnold R, Göke R, Wied M, Behr T. "Chapter 15 Neuroendocrine Gastro-Enteropancreatic (GEP) Tumors". In Scheppach W, Bresalier RS, Tytgat GNJ. *Gastrointestinal and Liver Tumors*. Berlin: Springer. pp. 2003; 195-233.
- [2] Arnold R, Rinke A, Schmidt C, et al. Endocrine tumours of the gastrointestinal tract: chemotherapy. *Best Pract Res Clin Gastroenterol*. 2005; 19:649-656.
- [3] Capella C, Solcia E, LH LS, et al. Endocrine tumours of the stomach. In: Hamilton SR, Aaltonen LA, eds. *Pathology and Genetics of Tumours of the Digestive System*. Lyon, France: IARC Press; 2000; 137-139.
- [4] Delle Fave G, Capurso G, Milione M, et al. Endocrine tumours of the stomach. *Best Pract Res Clin Gastroenterol*. 2005; 19:659-673.
- [5] Eckhauser F, Lloyd R, Thompson N, et al. Antrectomy for multicentric, argyrophil gastric carcinoids: a preliminary report. *Surgery*. 1988; 104:1046-1053.
- [6] Fahy B, Tang L, Klimstra D, et al. Carcinoid of the rectum risk stratification (CaRRS): a strategy for preoperative outcome assessment. *Ann Surg Oncol*. 2007; 14:396-404.
- [7] Falconi M, Plockinger U, Kwekkeboom DJ, et al. Well-differentiated pancreatic non functioning tumors/carcinoma. *Neuroendocrinology*. 2006; 84:196-211.
- [8] Gibril F, Reynolds JC, Lubensky IA, et al. Ability of somatostatin receptor scintigraphy to identify patients with gastric carcinoids: a prospective study. *J Nucl Med*. 2000; 41:1646-1656.
- [9] Gupta S, Yao JC, Ahrar K, et al. Hepatic artery embolization and chemoembolization for treatment of patients with metastatic carcinoid tumors: the M.D. Anderson experience. *Cancer J*. 2003; 9:261-267.

- [10] Hirschowitz BI, Griffith J, Pellegrin D, et al. Rapid regression of enterochromaffinlike cell gastric carcinoids in pernicious anemia after antrectomy. *Gastroenterology*. 1992; 102:1409-1418.
- [11] Hochwald S, Zee S, Conlon K, et al. Prognostic factors in pancreatic endocrine neoplasms: an analysis of 136 cases with a proposal for low-grade and intermediate-grade groups. *J Clin Oncol*. 2002; 20:2633-2642.
- [12] Hou W, Schubert ML. Treatment of gastric carcinoids. *Curr Treat Options Gastroenterol*. 2007; 10:123-133.
- [13] Janson E, Holmberg L, Stridsberg M, et al. Carcinoid tumors: analysis of prognostic factors and survival in 301 patients from a referral center. *Ann Oncol*. 1997; 8:685-690.
- [14] Kaltsas GA, Besser GM, Grossman AB. The diagnosis and medical management of advanced neuroendocrine tumors. *Endocr Rev*. 2004; 25:458-511.
- [15] Kimura W, Kuroda A, Morioka Y. Clinical pathology of endocrine tumors of the pancreas. Analysis of autopsy cases", *Dig Dis Sci*. 1991;36 (7): 933-42.
- [16] Klöppel G, Perren A, Heitz PU. The gastroenteropancreatic neuroendocrine cell system and its tumors: the WHO classification. *Ann N Y Acad Sci*. 2004; 1014 (1): 13-27.
- [17] Krenning EP, Kooij PPM, Bakker WH, et al. Radiotherapy with a radiolabeled somatostatin analogue, [<sup>111</sup>In-DTPA-D-Phe1]-octreotide. *Ann N Y Acad Sci*. 1994; 733:496-506.
- [18] Kvols LK. Carcinoid Tumors and the Carcinoid Syndrome: What's New in the Therapeutic Pipeline. *The Carcinoid Cancer Foundation: Carcinoid Symposium 2002*, <http://www.carcinoid.org/pcf/lectures/docs/KVOLS.htm>.
- [19] Le Treut YP, Gregoire E, Belghiti J, et al. Predictors of long-term survival after liver transplantation for metastatic endocrine tumors: an 85-case French multicentric report. *Am J Transplant*. 2008; 8:1205-1213.
- [20] Lin O, Olgac S, Green O, et al. Immunohistochemical staining of cytologic smears with MIB-1 helps distinguish low-grade from high-grade neuroendocrine neoplasms. *Am J Clin Pathol*. 2003;120:209-216.
- [21] Massironi S, Sciola V, Peracchi M, et al. Neuroendocrine tumors of the gastro-entero-pancreatic system. *World J Gastroenterol*. 2008;14:5377-5384.
- [22] Metz DC, Jensen RT. Gastrointestinal neuroendocrine tumors: pancreatic endocrine tumors. *Gastroenterology*. 2008; 135:1469-1492.
- [23] Modlin IM, Lye KD, Kidd M. A 5-decade analysis of 13,715 carcinoid tumors. *Cancer*. 2003;97:934- 959.
- [24] Modlin IM, Shapiro MD, Kidd M. Siegfried Oberndorfer: origins and perspectives of carcinoid tumors. *Hum Pathol*. 2004; 35 (12): 1440-51.
- [25] Norton JA, Melcher ML, Gibril F, et al. Gastric carcinoid tumors in multiple endocrine neoplasia-1 patients with Zollinger-Ellison syndrome can be symptomatic, demonstrate aggressive growth, and require surgical treatment. *Surgery*. 2004;136:1267-1274.

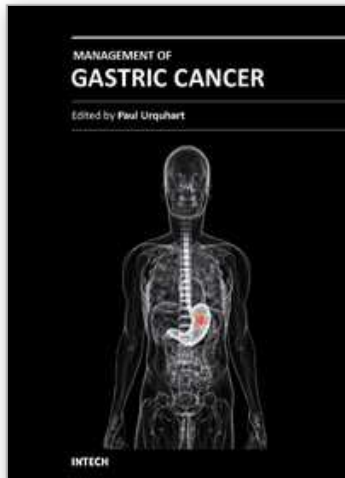
- [26] Olausson M, Friman S, Herlenius G, et al. Orthotopic liver or multivisceral transplantation as treatment of metastatic neuroendocrine tumors. *Liver Transpl.* 2007; 13:327-333.
- [27] O'Toole D, Ruszniewski P. Chemoembolization and other ablative therapies for liver metastases of gastrointestinal endocrine tumours. *Best Pract Res Clin Gastroenterol.* 2005; 19:585-594.
- [28] Öberg K. Carcinoid Tumors: Current Concepts in Diagnosis and Treatment. *Oncologist* 3. 1998; (5): 339-345.
- [29] Öberg K. Neuroendocrine Gastroenteropancreatic Tumours: Current Views on Diagnosis and Treatment. *Business Briefing: European Oncology Review* 2005 ;90-2.
- [30] Öberg K, Kvol L, Caplin M. Consensus report on the use of somatostatin analogs for the management of neuroendocrine tumors of the gastroenteropancreatic system. *Ann Oncol.* 2004; 15:966-973.
- [31] Pascher A, Klupp J, Neuhaus P. Endocrine tumours of the gastrointestinal tract. Transplantation in the management of metastatic endocrine tumours. *Best Pract Res Clin Gastroenterol.* 2005; 19:637-648.
- [32] Ramage JK, Davies AH, Ardill J, et al. "Guidelines for the management of gastroenteropancreatic neuroendocrine (including carcinoid) tumours, *Gut.* 2005; Suppl 4 (suppl\_4): iv1-16.
- [33] Rindi G, Bordi C, Rappel S, et al. Gastric carcinoids and neuroendocrine carcinomas: pathogenesis, pathology, and behavior. *World J Surg.* 1996; 20:168-172.
- [34] Ruszniewski P, Delle Fave G, Cadiot G, et al. Well-differentiated gastric tumors/carcinomas. *Neuroendocrinology.* 2006; 84:158-164.
- [35] Sarmiento JM, Que FG. Hepatic surgery for metastases from neuroendocrine tumors. *Surg Oncol Clin N Am.* 2003; 87:47-62.
- [36] Sun W, Lipsitz S, Catalano P, et al. Phase II/III study of doxorubicin with fluorouracil compared with streptozocin with fluorouracil or dacarbazine in the treatment of advanced carcinoid tumors: Eastern Cooperative Oncology Group Study E1281. *J Clin Oncol.* 2005; 23:4897-4904.
- [37] Tomassetti P, Migliori M, Caletti G, et al. Treatment of type II gastric carcinoid tumors with somatostatin analogs. *N Engl J Med.* 2000; 343:551-554.
- [38] Toumpanakis C, Meyer T, Caplin ME. Cytotoxic treatment including embolization/chemoembolization for neuroendocrine tumours. *Best Pract Res Clin Endocrinol Metab.* 2007;21:131-144.
- [39] Vinik AI, Silva MP, Woltering EA, et al. Biochemical testing for neuroendocrine tumors. *Pancreas.* 2009; 38:876-889. 93:1945-1948.
- [40] Washington M, Tang L, Berlin J, et al. Protocol for the examination of specimens from patient with neuroendocrine tumors (carcinoid tumors) of the appendix. *Arch Pathol Lab Med.* 2010; 134:171-175.
- [41] Washington M, Tang L, Berlin J, et al. Protocol for the examination of specimens from patient with neuroendocrine tumors (carcinoid tumors) of the colon and rectum. *Arch Pathol Lab Med.* 2010; 134:176-180.



- [42] Washington M, Tang L, Berlin J, et al. Protocol for the examination of specimens from patient with neuroendocrine tumors (carcinoid tumors) of the small intestine and ampulla. *Arch Pathol Lab Med.* 2010; 134:181-186.
- [43] Washington M, Tang L, Berlin J, et al. Protocol for the examination of specimens from patient with neuroendocrine tumors (carcinoid tumors) of the stomach. *Arch Pathol Lab Med.* 2010; 134:187-191.

IntechOpen

IntechOpen



## **Management of Gastric Cancer**

Edited by Dr Nabil Ismaili

ISBN 978-953-307-344-6

Hard cover, 146 pages

**Publisher** InTech

**Published online** 18, July, 2011

**Published in print edition** July, 2011

Gastric cancer is the fifth most common cancer and the second most common cause of cancer death worldwide. More than 50% of the patients have advanced disease at diagnosis and in this case the disease has a poor outcome. The staging of gastric cancers is based on endoscopic ultrasound, computed tomography, magnetic resonance imaging, positron emission tomography, in addition to the laparoscopic staging. Many improvements in the surgical techniques have been seen in the last decade. Laparoscopic surgery is an emerging approach which offers important advantages: less blood loss, reduced postoperative pain, accelerated recovery, early return to normal bowel function and reduced hospital stay. D1 lymphadenectomy, with a goal of examining 15 or greater lymph nodes is a standard. D2 dissection is considered as a standard in several institutions especially in eastern Asia. Perioperative chemotherapy and adjuvant concurrent radiochemotherapy are recognized as standards treatments. Palliative chemotherapy is the mainstay treatment of advanced stages of the disease (metastatic and non-operable tumors). Despite these treatment advances, the prognosis of gastric cancer remains poor with a 5-year survival ranging from 10 to 15% in all stages combined.

### **How to reference**

In order to correctly reference this scholarly work, feel free to copy and paste the following:

Petar Svorcan, Jelena Djordjevic and Branko Maksimovic (2011). A Rare Gastric Carcinoma- Neuroendocrine Tumors, Management of Gastric Cancer, Dr Nabil Ismaili (Ed.), ISBN: 978-953-307-344-6, InTech, Available from: <http://www.intechopen.com/books/management-of-gastric-cancer/a-rare-gastric-carcinoma-neuroendocrine-tumors>

**INTECH**  
open science | open minds

### **InTech Europe**

University Campus STeP Ri  
Slavka Krautzeka 83/A  
51000 Rijeka, Croatia  
Phone: +385 (51) 770 447  
Fax: +385 (51) 686 166  
[www.intechopen.com](http://www.intechopen.com)

### **InTech China**

Unit 405, Office Block, Hotel Equatorial Shanghai  
No.65, Yan An Road (West), Shanghai, 200040, China  
中国上海市延安西路65号上海国际贵都大饭店办公楼405单元  
Phone: +86-21-62489820  
Fax: +86-21-62489821

© 2011 The Author(s). Licensee IntechOpen. This chapter is distributed under the terms of the [Creative Commons Attribution-NonCommercial-ShareAlike-3.0 License](https://creativecommons.org/licenses/by-nc-sa/3.0/), which permits use, distribution and reproduction for non-commercial purposes, provided the original is properly cited and derivative works building on this content are distributed under the same license.

IntechOpen

IntechOpen