

# We are IntechOpen, the world's leading publisher of Open Access books Built by scientists, for scientists

6,900

Open access books available

185,000

International authors and editors

200M

Downloads

Our authors are among the

154

Countries delivered to

TOP 1%

most cited scientists

12.2%

Contributors from top 500 universities



WEB OF SCIENCE™

Selection of our books indexed in the Book Citation Index  
in Web of Science™ Core Collection (BKCI)

Interested in publishing with us?  
Contact [book.department@intechopen.com](mailto:book.department@intechopen.com)

Numbers displayed above are based on latest data collected.  
For more information visit [www.intechopen.com](http://www.intechopen.com)



# Diagnostic Value of Multisliced Computed Tomography in Coronary Arteries Atherosclerotic Lesions Detection in the Patients with Coronary Heart Disease – a Comparative Study

Maryna N. Dolzhenko, Sergey V. Potashev and Natalia N. Nosenko  
*The P.L.Shupik National Medical Academy Of Postgraduate Education/Cardiology And  
 Functional Diagnosis Department  
 Ukraine*

## 1. Introduction

Today method of X-ray conventional coronary angiography (CCA) is a “golden standard” in diagnosis and evaluation of severity of coronary vessels atherosclerosis (Fleisher et al., 2007; Scanlon et al., 1999). But being invasive, this method has certain limitations, and cannot be suitable for stratification the patients with coronary arteries disease (CAD) suspicion in order to decide the necessity of revascularization (Laissy et al., 2007 ; Leschka S. et al., 2008; Mahmarian, 2007).

On the other hand, promising data regarding high correlation of non-invasive evaluation of left ventricle (LV) ejection fraction (EF), for instance, between resting echocardiographic EFs and single photon emission computed tomography (SPECT) resting gated sestamibi images in patients with single-vessel disease, and a moderate correlation in patients with 2- and 3-vessel disease, respectively (Fleming, 2002), as well as pharmacologically induced stress acquired from gated SPECT sestamibi images, providing a valuable diagnostic marker as to the number of significantly diseased coronary arteries (Fleming&Boyd, 2002), give only indirect information, being inappropriate for a surgeon prior to myocardium surgeon revascularization.

That is why a significant influence today is paid to design of newer methods of coronary pathology diagnosis, especially non-invasive. Among the demands to up-to-date examination methods high specificity, sensitivity, accuracy and safety should be mentioned, as well as high repeatability and economical suitability (Hamon et al., 2006). All these features are attributes of multislice spiral computed tomography (MSCT) (Abdulla et al., 2007; Achenbach, 2006; Kyung-Jong et al, 2003), what explains constantly growing interest to this method. Over the past years there has been a large quantity of works discussing value of contrast MSCT in diagnosis and evaluation of severity of coronary arteries atherosclerosis in the patients with CAD as an future alternative to CCA (Hamon et al., 2006; Kyung-Jong et al, 2003; Meijboom et al., 2006; Mollet et al, 2005; Mozaffarian, 2005).

In Ukraine there has been no attempts to compare informative and diagnostic value of invasive and non-invasive methods of left ventricle (LV) structural anomalies and coronary arteries lesions in the patients with CAD and after acute myocardial infarction (AMI).

The aim of this study was to compare the efficacy of contrast MSCT coronary angiography in diagnosis and severity of coronary vessels lesion in the patients with CAD compared to the “golden standard” CCA.

## 2. Methods

The study was approved by local ethics committee.

In the study we prospectively included 116 patients after AMI with LV postinfarction aneurism (LVA) without significant valvular dysfunction eligible for CABG combined with LVA resection. Exclusion criteria were a history of recent myocardial infarction (4 weeks before pre-operative angiography), atrial fibrillation, significant valvular heart disease or previous CABG. During and after the CABG, standard laboratory markers for myocardial infarction were obtained and none of the patients was diagnosed with perioperative myocardial infarction. Medication treatment in all the post-infarction patients included aspirin, statin, beta-blocker, ACE inhibitor and nitrates, if indicated. All patients underwent MSCT prior to the operation. Forty age-matched subjects with CAD and without AMI history, who underwent CCA, and contrast MSCT for coronary revascularization decision, served as controls. Program of the study included X-ray contrast CCA and MSCT with chambers and coronary arteries contrast.

### 2.1 Coronary angiography

Coronary angiography with ventriculography was conducted and interpreted by trained physicians 1 week preceding CABG+AE. A 50% or more reduction of the luminal diameter in 2 orthogonal projections of a major coronary artery or one of its major branches or a bypass graft was considered to be significant for CAD<sup>3,10,15</sup>. Severity of coronary atherosclerosis were evaluated as coronary artery narrowing to 30% (grade 1), 50% (grade 2), 75% (grade 3), 90% (grade 4) of diameter or full occlusion (grade 5), respectively (Mollet et al, 2005; Scanlon et al., 1999).

### 2.2 Multislice computed tomography

MSCT was performed on tomographer «Light Speed-16» («General Electric Company», USA) using cardiological «Advantage Workstation 4.2» («General Electric Company», USA). Spiral mode of tomography with 2,5 mm thick slice and retrospective ECG synchronization was intravenous ed with 6-8 seconds scanning time and 360° rotation. Study was performed at breath held after infusomat “Omnipac” intravenous infusion. Exposure dose constituted 2,2 mSv per one study at 16 slices per 200 frames. Severity of coronary arteries stenosis was evaluated, as well as coronary calcium index (CI) by A.S. Agatston, as a general coronary atherosclerosis and calcinosis marker, was quantified (Achenbach, 2006).

### 2.3 Statistics

Comparison of different methods was performed using multiple regression analysis with 95% confidence interval and correlation analysis (Petry & Sabin, 2003; Rebrova, 2002). In comparison of diagnostic value of the studied methods we evaluated the following

characteristics: accuracy (diagnostic efficacy) – percentage of correct test results out of general quantity of both positive and negative results; sensitivity (Se) – percentage of subjects with positive test results in the population with the studied pathology; specificity (Sp) – percentage of subjects with negative test results in the population with the studied pathology; positive predictive value (+PV) – probability of symptom or disease in case of positive test result; negative predictive value (-PV) – case of negative (normal) test result. The above numbered indices were calculated by formulas:

$$\begin{aligned} Se &= N(TP) / (N(TP) + N(FN)) \times 100\%; \\ Sp &= N(TN) / (N(TN) + N(FP)) \times 100\%; \\ +PV &= N(TP) / (N(TP) + N(FP)) \times 100\%; \\ -PV &= (TN) / (N(TN) + N(FN)) \times 100\%; \end{aligned}$$

where N is the quantity of studied patients; TP – truly positive diagnosis; FP – false positive diagnosis; TN – truly negative diagnosis; FN – false negative diagnosis<sup>12,13</sup>. The results are expressed as the mean and 1 standard deviation. The parameters of patients and healthy subjects were compared using an unpaired t-test. A paired t-test was used to compare results within the same group. A P-value of <0,05 was considered significant.

3. Results

The main clinical features of the study group patients are presented in Table 1.

Index	Abs.	%
LV EF (%)	37,1±12,4	-
LV EDI (ml/m²)	112,4±28,2	-
LV ESI (ml/m²)	73,8±27,6	-
Diabetes mellitus (n)	14	12,1%
Hypertension (n)	75	64,7%
Angina pectoris	107	92,3%
Functional class I	15	12,9%
Functional class II	23	19,8%
Functional class III	64	55,2%
Functional class IV	14	12,1%

Heart failure (NYHA functional class)		
I (LV > 45%)	17	14,7%
II (LV < 45%)	86	74,1%
I (LV < 45%)	13	11,2%
Lesions localization (by CCA)		
3-vessels disease and/or left main (n)	41	35,4%
2-vessels disease (n)	39	33,6%
1 -vessel disease (n)	35	30,2%
No significant lesions	1	0,8%
Coronary atherosclerotic lesions localization (by CCA)		
Main left coronary artery (LCA)	15	12,9%
Anterior descending left coronary artery (AD LCA)	112	96,6%
Diagonal LCA	7	6,0%
Circumflex (Cx) LCA	62	53,5%
Right coronary artery (RCA)	79	68,1%
*Data are presented as total (n) or M±SD (n=116)		

Table 1. Clinical features of the patients studied

As it is seen from the table, according to CVG data there were predominantly patients with 2- and 3-vessels disease of left main coronary artery lesion. According to contrast MSCT results data, main LCA lesion was found in 8 (6,9%) patients (46,7% false negative results), AD LCA lesion - in 89 (76,7%) patients (20,5% false negative results), diagonal LCA lesion - in 0 cases (100% false negative results), Cx LCA lesion - in 32 (27,6%) patients (48,4% false negative results), and RCA lesion - in 48 (41,4%) patients (39,2% false negative results). Therefore, in approximately one third to one half of the patients contrast 16-slice MSCT was unable to reveal significant trunk coronary arteries stenosis.

Data of contrast MSCT results still significantly correlated with CCA data. Like this, quantity of stenotic arteries significantly correlated with CCA data ( $r=0,50$ ,  $p<0,0001$ ). High enough correlation was found in main LCA stenosis diagnosis ( $r=0,75$ ,  $p<0,0001$ ), proximal segments of RCA ( $r=0,61$ ,  $p<0,0001$ ) and Cx LCA ( $r=0,49$ ,  $p<0,0001$ ). Still, there was weak correlation between MSCT data and CCA in diagnosis of AD LCA, especially its distal segments ( $r=0,33$ ,  $p=0,0002$ ). Besides, contrast MSCT wasn't able to diagnose significant stenosis of diagonal LCA and a. intermedia (9 false negative results).

On the other side, we found significant, not very high, though, correlation between value of CI by A.S. Agatston and quantity of stenotic coronary arteries both by contrast MSCT results data ( $r=0,45$ ,  $p<0,0001$ ) and CCA ( $r=0,39$ ,  $p=0,0004$ ) (Fig. 1 and 2).

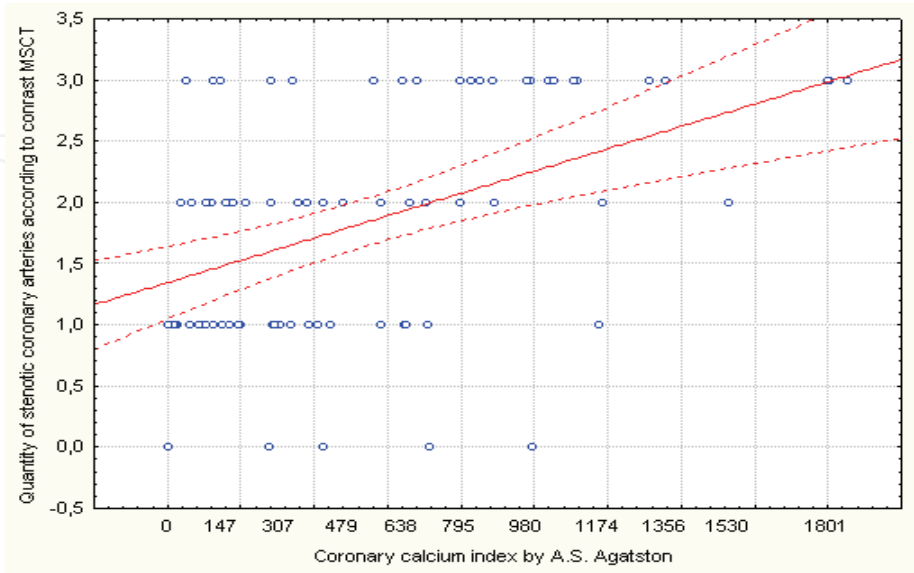


Fig. 1. Correlation between coronary calcium index by A.S. Agatston and quantity of stenotic coronary arteries according to contrast MSCT results data

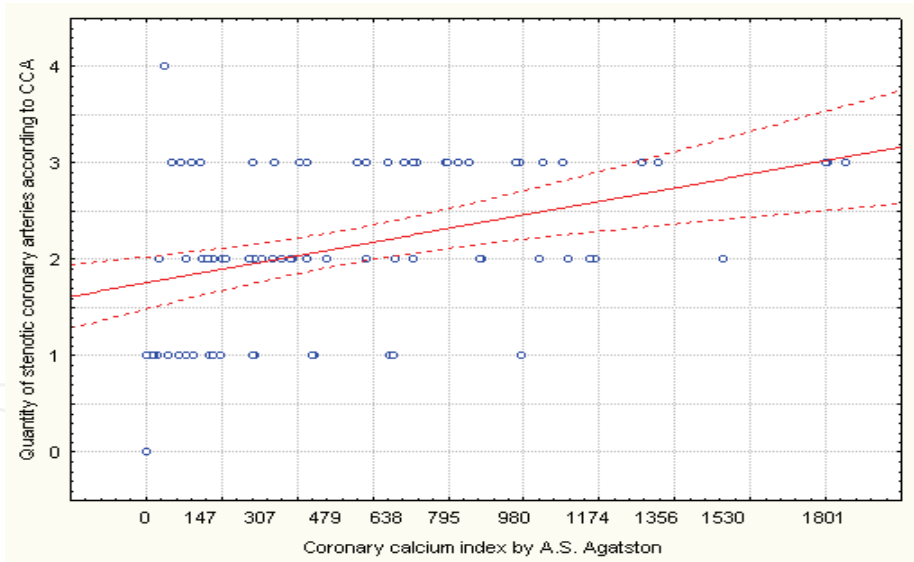


Fig. 2. Correlation between coronary calcium index by A.S. Agatston and quantity of stenotic coronary arteries according to CCA results data

At estimation of general diagnostic value of contrast MSCT compared to CCA the accuracy of the method (percentage of correct results in general quantity of positive and negative results) constituted 80,1%,  $p<0,0001$ . Still, overall sensitivity of 16-slice contrast MSCT was rather low (66,1%  $p<0,0001$ ) with rather high specificity (94,75%,  $p=0,013$ ) and positive presictive value of the method (91,7%,  $p=0,0017$ ). Overall negative presictive value of MSCT was 76,1%,  $p<0,0001$ . We also found significant discrepancies in diagnostic value of contrast



MSCT compared to CCA depending on localization and level of atherosclerotic coronary lesions (Table 2).

Main LCA	AD LCA	Cx LCA	RCA
Se = 53,3%, p<0,0001	Se = 79,5%, p<0,0001	Se = 51,6%, p<0,0001	Se = 60,8%, p<0,0001
Sp = 96,0%, p=0,031	Sp = 50,0%, p<0,0001	Sp = 87,0%, p=0,0001	Sp = 91,9%, p=0,002
+PV = 66,7%, p<0,0001	+PV = 97,8%, p=0,11	+PV = 82,1%, p<0,0001	+PV = 94,1%, p=0,0085
- PV = 93,3%, p=0,005	- PV = 8,0%, p<0,0001	- PV = 61,0%, p<0,0001	- PV = 52,3%, p<0,0001

Table 2. Diagnostic value of 16-slice contrast MSCT in diagnosing coronary atherosclerosis compared to CCA

4. Discussion

Results of our study showed rather low sensitivity and negative predictive value of contrast MSCT, at relatively high high specificity and positive predictive value of the method campared to CCA. This data is relevant to results of many later foreign studies, dedicated to comparison of diagnostic value of MSCT and CCA (Abdulla et al., 2007; Kyung-Jong et al, 2003; Mollet et al, 2005; Mozaffarian, 2005). According to results of our study, indices of diagnostic value of contrast MSCT were significantly higher in diagnosis of more proximal segments of coronary arteries, which is confirmed by higher correlation indices between MSCT and CCA in examining main LCA ( $r=0,75$ ,  $p<0,0001$ ) and RCA ( $r=0,61$ ,  $p<0,0001$ ), with rather low rates of diagnostic value in diagnosing distal segments and minor coronary arteries lesions. For instance, according to our data, MSCT wasn't able to show lesions of diagonal LCA and intermedia, and showed rather low correlation with CCA in diagnosing Cx LCA stenosis ( $r=0,49$ ,  $p<0,0001$ ) and AD LCA ( $r=0,33$ ,  $p=0,0002$ ). These results coincide with relevant references (Abdulla et al., 2007; Hamon et al., 2006; Mollet et al, 2005). Therefore, our data allows to view 16-slice MSCT as a attractive safe non-invasive method for screening, primary diagnosis and decision about invasive methods necessity in the patients with high suspicion of significant coronary atherosclerosis, especially taking into account significant correlation between values of CI by A.S. Agatston and extent of coronary atherosclerosis regardless of the method of coronary arteries contrast visualization (Leschka S. et al., 2008; Mahmarian, 2007; Mozaffarian, 2005). On the other hand, in evaluating the extent of coronary atherosclerosis in the patients with CAD prior to the planned surgeon revascularization 16-slice MSCT could not be trusted enough to replace CCA.

4.1 Study limitations

Latest publications show results obtained from newer generations of MSCT using 32 or 64 slices per 200 frames, which explains higher resolution and better quality of coronary

arteries visualization (Abdulla et al., 2007; Mollet et al, 2005), while we used only 16 slices per 200 frames, which surely influenced results of our study (Mollet et al, 2005; Romeo et al, 2005).

## 5. Conclusion

Contrast 16-sliced MSCT is unable to diagnose the distal and medium-to-minor coronary lesions and cannot be viewed as an alternative to CCA in the patients with verified CAD before planned surgeon revascularization due to shortcomings difficult to overcome in daily practice. Still, significant correlation between estimating coronary CI according to MSCT with results of multi-vessel coronary atherosclerosis by contrast MSCT ( $r=0,45$ ,  $p<0,0001$ ) and CCA ( $r=0,39$ ,  $p=0,0004$ ) allows to view 16-slice contrast MSCT as an attractive and trustworthy screening method in low-symptomatic patients with high risk of CAD for primary diagnosis, stratification and decision about reasonability of invasive diagnosis and revascularization.

## 6. Acknowledgment

Authors thank Prof. Anatoliy Rudenko, Head of Coronary Heart Disease Surgeon Treatment Department of The N.M.Amosov Institute Of Cardiovascular Surgery Of AMS Of Ukraine, and Dr. Oleg Sharayevskiy, Head of MSCT Department of NSC “The N.D.Strazhesko Institute Of Cardiology” Of AMS Of Ukraine, for the provided CCA and MSCT results data for the studied patients.

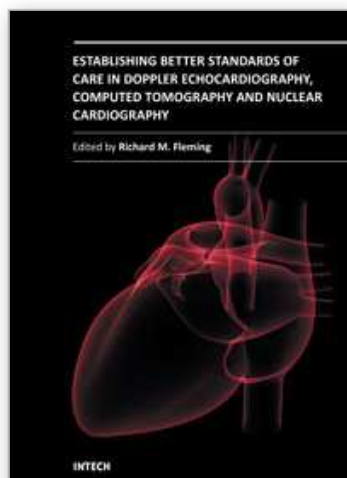
## 7. References

- Abdulla J., Abildstrom S.Z., Gotzsche O. 64-multislice detector computed tomography coronary angiography as potential alternative to conventional coronary angiography: a systematic review and meta-analysis. *Eur. Heart J.*, Vol. 28 (December 2007), pp. 3042 - 3050.
- Achenbach S. Computed Tomography Coronary Angiography. *J. Am. Coll. Cardiol.*, Vol. 48 (November 2006), pp. 1919 - 1928.
- Fleisher Lee A. et al. ACC/AHA 2007 Guidelines on Perioperative Cardiovascular Evaluation and Care for Noncardiac Surgery: A Report of the American College of Cardiology/American Heart Association Task Force on Practice Guidelines (Writing Committee to Revise the 2002 Guidelines on Perioperative Cardiovascular Evaluation for Noncardiac Surgery. *Circulation*, Vol. 116 (October 2007), pp. e418 - e500.
- Fleming R.M. A Tate-en-Tate Comparison of Ejection Fraction and Regional Wall Motion Abnormalities as Measured by Echocardiography and Gated Sestamibi SPECT. *Angiology*, Vol. 53, 3 (May 2002), pp. 313-321.
- Fleming R.M., Boyd L.D. High-Dose Dipyridamole and Gated Sestamibi SPECT Imaging Provide Diagnostisic Resting and Stress Ejection Fractions Useful for Predicting the Extent of Coronary Artery Disease. *Angiology*, 53, 4 (July 2002), pp. 415-421.
- Hamon M. et al. Diagnostic Performance of Multislice Spiral Computed Tomography of Coronary Arteries as Compared With Conventional Invasive Coronary



- Angiography: A Meta-Analysis. *J. Am. Coll. Cardiol.*, Vol. 48 (November 2006), pp. 1896 - 1910.
- Kyung-Jong Yoo, Donghoon Choi, Byoung Wook Choi, et al. The comparison of the graft patency after coronary artery bypass grafting using coronary angiography and multi-slice computed tomography. *Eur. J. Cardiothorac. Surg.*, Vol. 24 (July 2003), pp. 86.
- Laissy Jean-Pierre et al. Comprehensive evaluation of preoperative patients with aortic valve stenosis: usefulness of cardiac multidetector computed tomography. *Heart*, Vol. 93 (September 2007), pp. 1121 - 1125.
- Leschka S. et al. Combining dual-source computed tomography coronary angiography and calcium scoring: added value for the assessment of coronary artery disease. *Heart*, Vol. 94, (September 2008), pp. 1154 - 1161.
- Mahmorian J.J. Computed Tomography Coronary Angiography as an Anatomic Basis for Risk Stratification: Déjà Vu or Something New? *J. Am. Coll. Cardiol.*, Vol. 50 (September 2007), pp. 1171 - 1173.
- Meijboom W.B. et al. Pre-Operative Computed Tomography Coronary Angiography to Detect Significant Coronary Artery Disease in Patients Referred for Cardiac Valve Surgery. *J. Am. Coll. Cardiol.*, Vol. 48 (October 2006), pp. 1658 - 1665.
- Mollet N.R. et al. High-Resolution Spiral Computed Tomography Coronary Angiography in Patients Referred for Diagnostic Conventional Coronary Angiography. *Circulation*, Vol. 112 (October 2005), pp. 2318 - 2323.
- Mozaffarian D. Electron-Beam Computed Tomography for Coronary Calcium: A Useful Test to Screen for Coronary Heart Disease? *JAMA*, Vol. 294 (December 2005), pp. 2897 - 2901.
- Petry A., Sabin K. (2003). *Demonstrable statistics in medicine*, GAOTAR-MED, Moscow
- Rebrova O.Y. (2002). *Statistical analysis of medical data*, Media Sphere, Moscow
- Romeo G. et al. Coronary Stenosis Detection by 16-Slice Computed Tomography in Heart Transplant Patients. *J.Am.Coll.Cardiol*, Vol. 45 (June 2005), pp. 1826-1831.
- Scanlon P.J. et al. ACC/AHA Guidelines for Coronary Angiography: Executive Summary and Recommendations. *Circulation*, Vol. 99 (May 1999), pp. 2345-57.

IntechOpen



## **Establishing Better Standards of Care in Doppler Echocardiography, Computed Tomography and Nuclear Cardiology**

Edited by Dr. Richard M. Fleming

ISBN 978-953-307-366-8

Hard cover, 260 pages

**Publisher** InTech

**Published online** 13, July, 2011

**Published in print edition** July, 2011

Since the introduction of Doppler Echocardiography, Nuclear Cardiology and Coronary CT imaging, clinicians and researchers have been searching for ways to improve their use of these important tools in both the diagnosis and treatment of heart disease. To keep up with cutting edge improvements in these fields, experts from around the world have come together in this book to provide the reader with the most up to date information to explain how, why and when these different non-invasive imaging tools should be used. This book will not only serve its reader well today but well into the future.

### **How to reference**

In order to correctly reference this scholarly work, feel free to copy and paste the following:

Maryna N. Dolzhenko, Sergey V. Potashev and Natalia N. Nosenko (2011). Diagnostic Value of Multisliced Computed Tomography in Coronary Arteries Atherosclerotic Lesions Detection in the Patients with Coronary Heart Disease - a Comparative Study, Establishing Better Standards of Care in Doppler Echocardiography, Computed Tomography and Nuclear Cardiology, Dr. Richard M. Fleming (Ed.), ISBN: 978-953-307-366-8, InTech, Available from: <http://www.intechopen.com/books/establishing-better-standards-of-care-in-doppler-echocardiography-computed-tomography-and-nuclear-cardiology/diagnostic-value-of-multisliced-computed-tomography-in-coronary-arteries-atherosclerotic-lesions-det>

**INTECH**  
open science | open minds

### **InTech Europe**

University Campus STeP Ri  
Slavka Krautzeka 83/A  
51000 Rijeka, Croatia  
Phone: +385 (51) 770 447  
Fax: +385 (51) 686 166  
[www.intechopen.com](http://www.intechopen.com)

### **InTech China**

Unit 405, Office Block, Hotel Equatorial Shanghai  
No.65, Yan An Road (West), Shanghai, 200040, China  
中国上海市延安西路65号上海国际贵都大饭店办公楼405单元  
Phone: +86-21-62489820  
Fax: +86-21-62489821

© 2011 The Author(s). Licensee IntechOpen. This chapter is distributed under the terms of the [Creative Commons Attribution-NonCommercial-ShareAlike-3.0 License](https://creativecommons.org/licenses/by-nc-sa/3.0/), which permits use, distribution and reproduction for non-commercial purposes, provided the original is properly cited and derivative works building on this content are distributed under the same license.

IntechOpen

IntechOpen