

We are IntechOpen, the world's leading publisher of Open Access books Built by scientists, for scientists

6,900

Open access books available

185,000

International authors and editors

200M

Downloads

Our authors are among the

154

Countries delivered to

TOP 1%

most cited scientists

12.2%

Contributors from top 500 universities



WEB OF SCIENCE™

Selection of our books indexed in the Book Citation Index
in Web of Science™ Core Collection (BKCI)

Interested in publishing with us?
Contact book.department@intechopen.com

Numbers displayed above are based on latest data collected.
For more information visit www.intechopen.com



High Resolution Ultrasound Imaging of Melanocytic and Other Pigmented Lesions of the Skin

Laurent Machet, Mahtab Samimi, Gabriella Georgesco,
Youssef Mourtada, Michaël Naouri, Jean Marc Grégoire,
Frédéric Ossant, Frédéric Patat and Loïc Vaillant

*Department of Dermatology, CHRU Tours,
UMRS Inserm U930, CNRS ERL 3106, Tours,
CIC-IT, CHRU Tours,
Université François Rabelais, Tours,
France*

1. Introduction

For two main reasons, dermatology is one of the later medical disciplines to use imaging techniques: 1) skin lesions are readily visible to the naked eye or through a magnifying glass, allowing clinical diagnosis with no invasive examination, 2) skin lesions can easily be biopsied or removed for histological study. This approach has therefore remained the basis of clinicopathological diagnosis of skin diseases for a long time. There has also been a third factor, i.e. the technical factors limiting image resolution (1-12). It is often necessary to visualise sub-centimeter lesions or even smaller, as in the case when measuring the thickness of a melanoma, and this cannot be achieved using traditional 7-10 MHz ultrasound. However, such techniques are useful in dermatology, especially in detecting lymph node spread of melanoma (6,13,14).

Other techniques such as optical coherence tomography and confocal microscopy are now available, with better resolution than 20-100 MHz ultrasound. However, both are more expensive and more time-consuming than ultrasound. Moreover, in certain European countries (e.g. France and Germany) ultrasound examination of the skin is reimbursed by health insurance services.

High resolution ultrasound imaging systems enable ultrasound to differentiate structures of less than 100 microns on the beam axis (axial resolution) and 200 microns on the scan axis (resolution axis). This can be achieved by the use of ultrasound frequencies above 15 MHz. Several groups have been working to extend the limits of existing machines by increasing the frequency (11,12,15,16). Working in our group, Berson et al. proposed a new ultrasound device operating at 17 MHz (1). This device was compact and had a very handy probe with an acoustic window enclosed by a thin membrane, allowing easier exploration of skin tumours on the face where they are more frequent than on other sites of the skin. We currently use a device derived from this prototype (Dermcup 2020®, Atys Medica, St

Soucieu en Jarrest, France) (2). The frequency ranges from 20 to 50 MHz, allowing visualisation of the superficial layer of the skin (epidermis and dermis, and the upper part of hypodermis) (Fig. 1), where the majority of lesions and skin tumors are located.

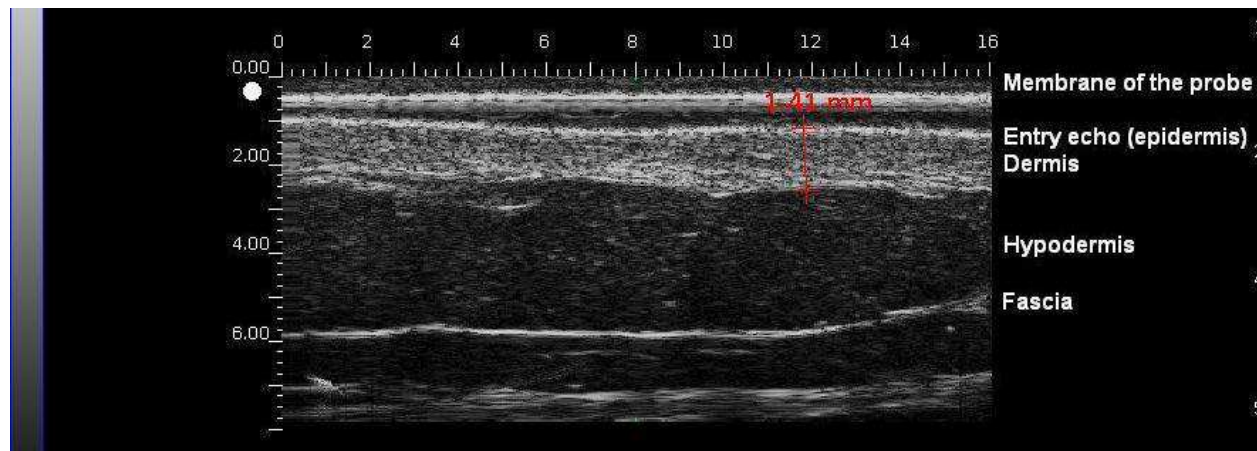


Fig. 1. Normal skin

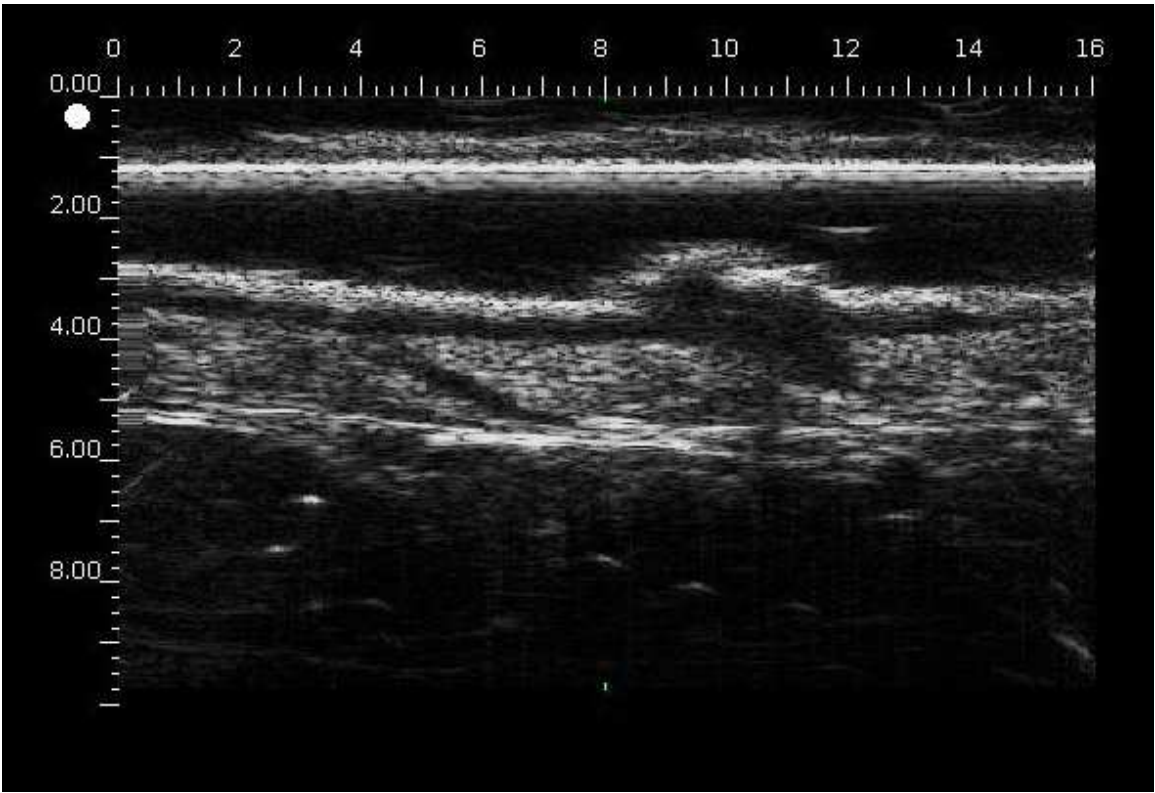
Ultrasound imaging has been routinely used by dermatologists in our department for over ten years. The main indication is in the initial management of malignant tumors (including helping in the differential diagnosis and measurement of thickness). Moreover, ultrasound of the skin may be useful in the diagnosis of local recurrence and of locoregional melanoma, especially on certain very fibrous scars that are not easily accessible to palpation.

2. Ultrasound imaging of melanocytic lesions

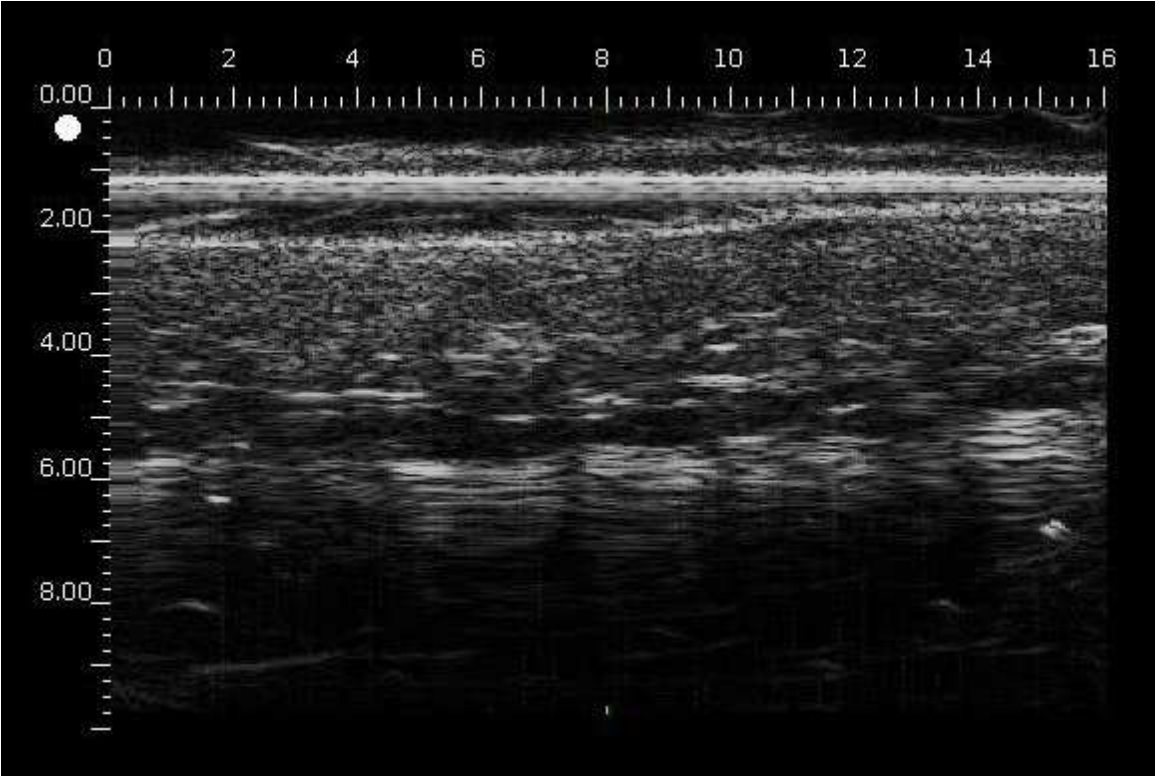
Melanocytic lesions are often benign (melanocytic naevus) and affect many individuals. Melanoma is a highly malignant tumor, whose incidence has doubled every 20 to 30 years (1 to 2 new cases/10 000 inhabitants/year, representing a 1% probability of developing melanoma during a lifetime). The overall mortality rate is 20% and it is greater in the case of lesions thicker than 4 mm (50%). On the other hand, the overall survival of thin lesions (less than 0.5 mm thick) is excellent. The diagnosis of melanocytic lesions is initially clinical, frequently assisted by dermoscopy, and in the case of suspected malignancy, the second step is surgical removal and histology examination which remains the gold standard. Dermoscopy and ultrasound are both non-invasive techniques that can be combined to increase preoperative diagnostic accuracy in pigmented skin lesions (17). Dermoscopy has been proved to improve the sensitivity and the specificity of clinical examination. The goal is to remove all *in situ* or less than 0.5 mm thick melanomas and to reduce the unnecessary removal of benign melanocytic lesions. How can ultrasound imaging help in the management of such lesions?

2.1 Ultrasound imaging of naevi

The lesions are mainly hypoechoic, with many small echoes, symmetrical, and usually well delimited from the adjacent dermis (Fig. 2a). They are usually very thin in the case of junctional naevi (Fig. 2b) and thicker in the case of dermal naevi. However, the ultrasound image of clinically atypical naevi (which are often those that pose a problem of differential diagnosis) may be only slightly different from that observed in thin melanoma. Acoustic



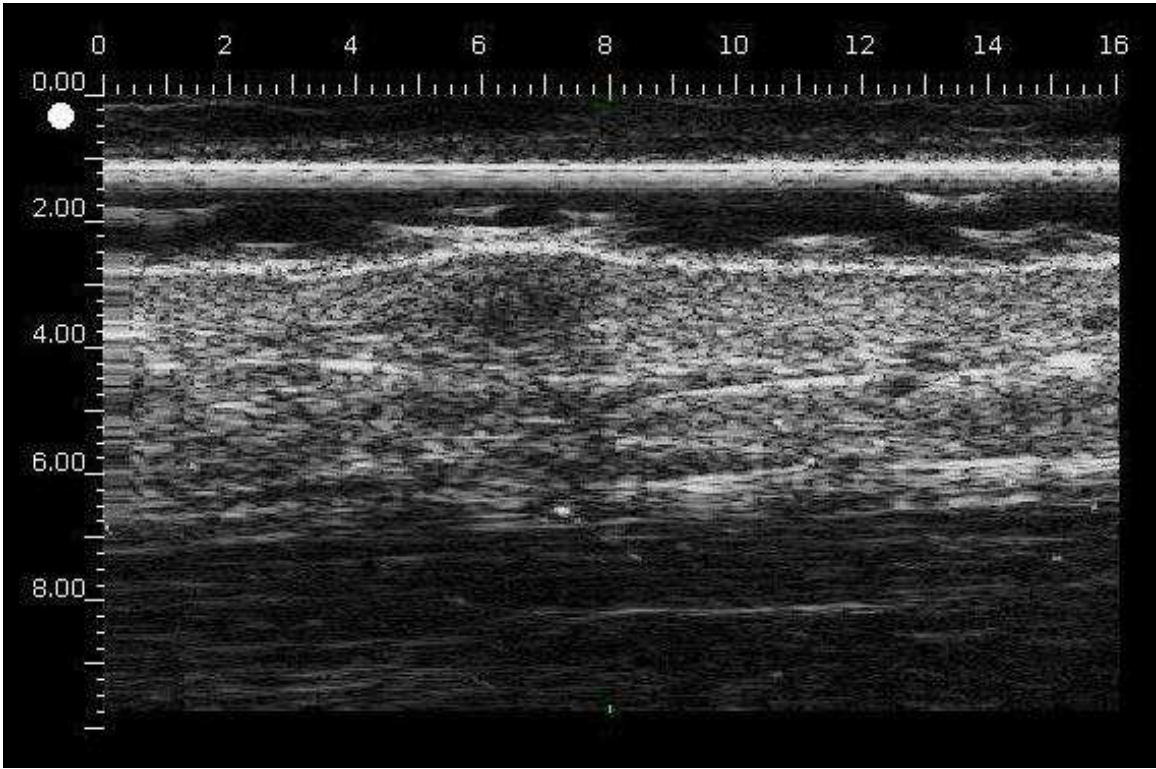
(a)



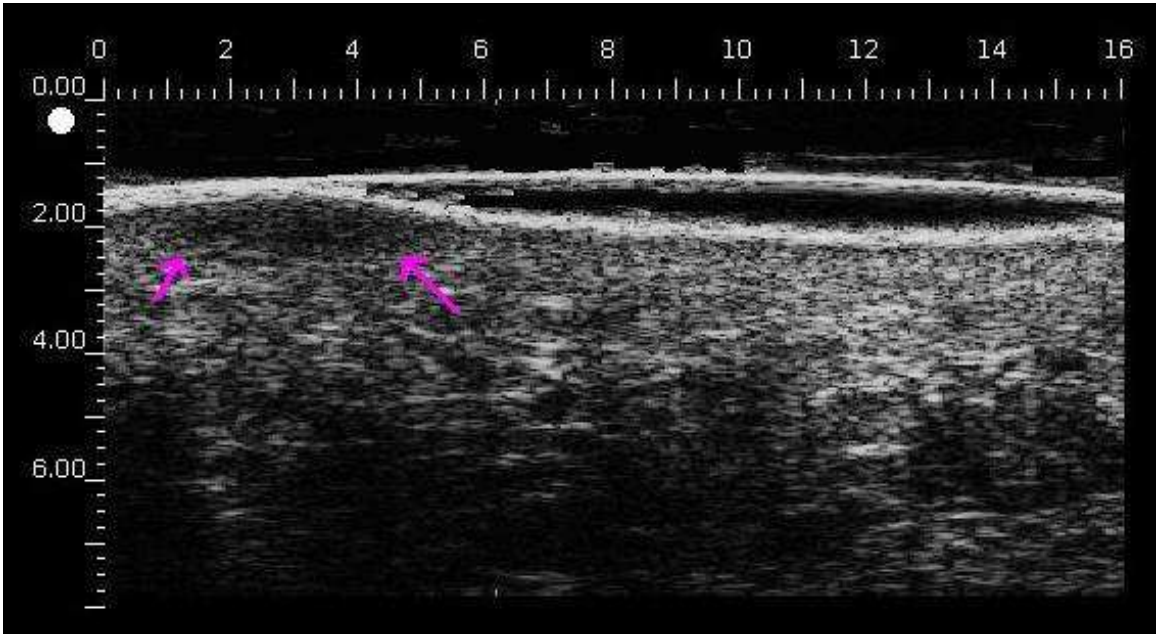
(b)

Fig. 2. a) echographic appearance of benign congenital melanocytic naevus; b) small acquired melanocytic naevus.

shadowing and retrolesional echogenicity may assist the diagnosis between benign naevus and melanoma (18) Quantitative discrimination of pigmented lesions seems possible using three-dimensional high-resolution ultrasound reflex transmission imaging (19). Blue naevi are also hypoechoic, and often have a dish shape or an ovoid shape (Fig.3a and 3b) (20).



(a)



(b)

Fig. 3. a) Ovoid shaped benign blue naevus, b) dish shaped naevus

2.2 Ultrasound imaging of primary melanomas

The lesions are homogeneous and hypoechoic, often more so than benign naevi in our experience. Echo entry is usually clearly visible, but it is less visible in the case of ulcerated lesions. The lateral dermal component of superficial spreading melanoma is usually well delimited from the dermis, but the intra-epidermal part cannot be seen (Fig. 4) A thin melanoma with Breslow thickness below 0.5 mm may be hard to visualise on the face of an elderly person due to the Sub Epidermal NonEchogenic Band (SENEB). The vertical part of the lesion is easily shown within the dermis and to a lesser extent within the hypodermis (Fig. 5).

2.3 Ultrasound imaging of local or in transit recurrence and distant cutaneous metastasis:

Recurrences appear as hypoechoic nodules located within the dermis or the hypodermis. They are not well delimited and often infiltrate adjacent structures (Fig. 6). They are often visible or palpable, and may simulate a benign blue naevus. However, the shape of the lesion is different for a blue naevus and a recurrence of melanoma (20). Moreover, ultrasound examination is able to detect subclinical in transit recurrence in some cases.

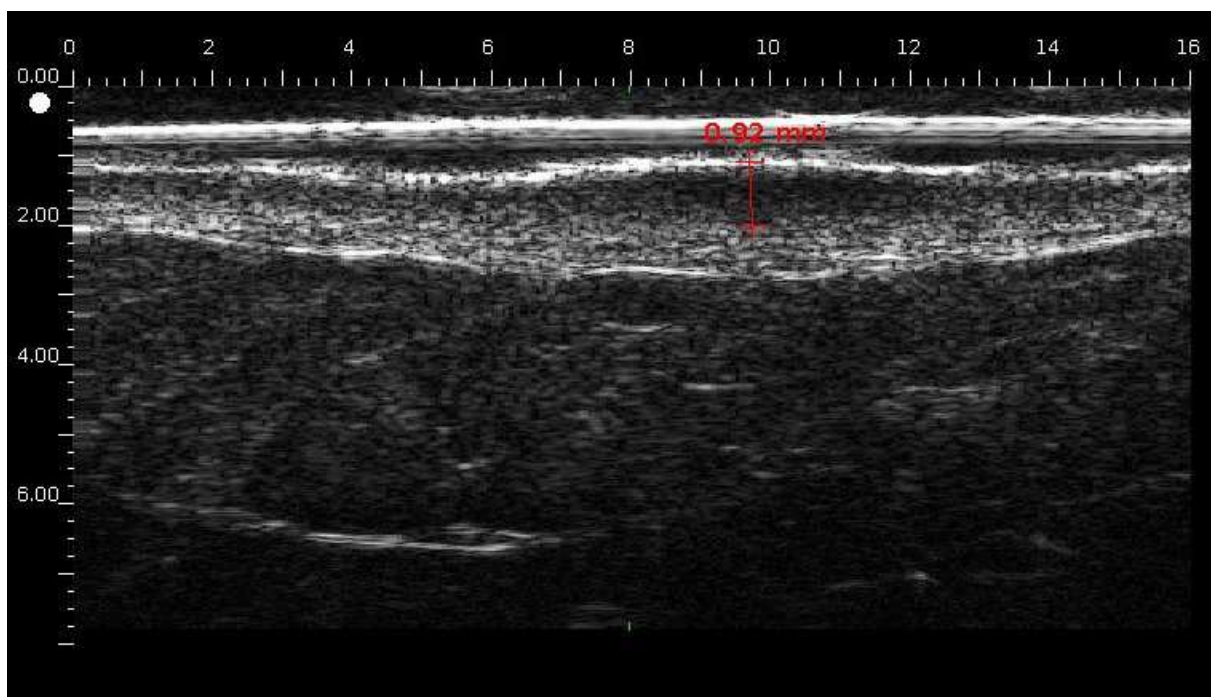


Fig. 4. Thin malignant melanoma.

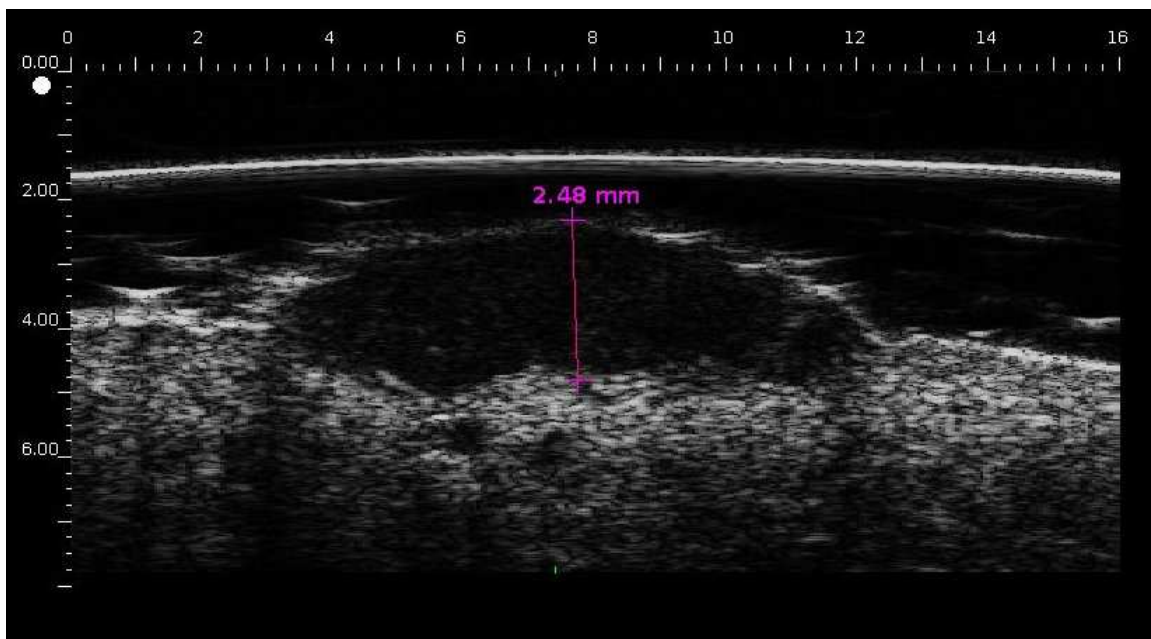


Fig. 5. Thick and ulcerated nodular malignant melanoma.

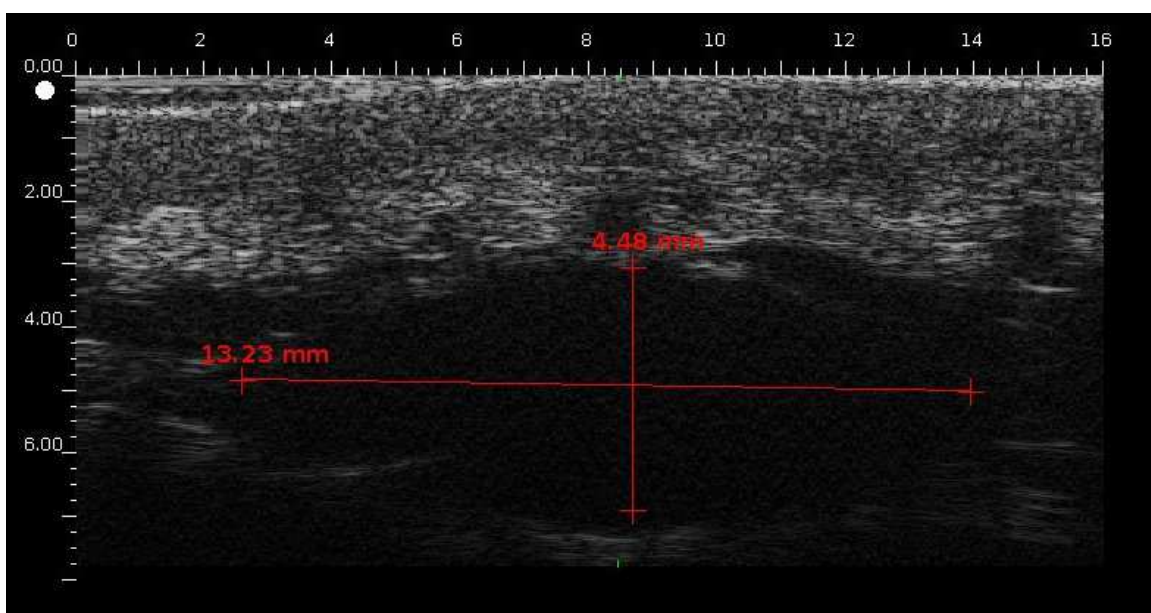

Fig. 6. In transit skin metastasis of malignant melanoma

2.4 Ultrasound measurement of thickness of melanocytic lesions:

The shape of a melanoma is often different from that of a benign naevus. However, the value of ultrasound imaging is mainly to measure the thickness of the lesion (3, 15,16,17, 21,23,24). Ultrasound thickness is well correlated with histological thickness (Fig. 7). This was recently demonstrated in a systematic review of the literature which identified 14 studies. Pearson's coefficient is generally good, ranging from 0.88 to 0.97 (21). However, there are some marked differences, as demonstrated in some cases using the graph of Bland and Altman (Fig. 8). This is particularly clear for thick melanomas, and in some particular locations (nail or plantar melanoma). Nevertheless, the width of surgical margins can be

correctly determined from ultrasound thickness, allowing the patient to be operated on in a single operation in nearly 75% of cases (Table 1) (21).

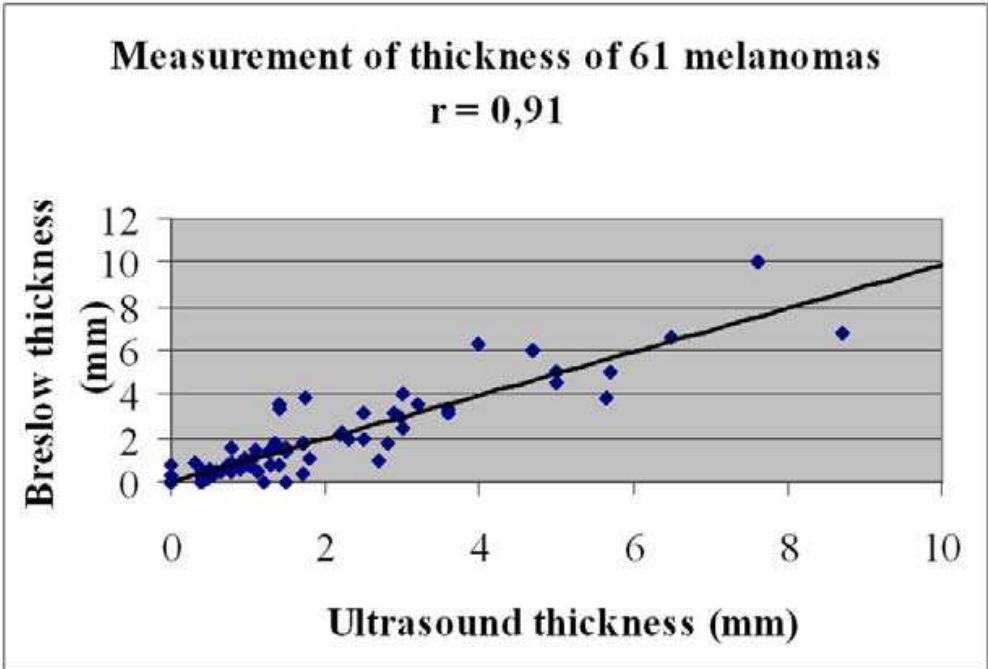


Fig. 7. Measurement of melanoma thickness with ultrasound (horizontal axis) as compared with histology, i.e. Breslow thickness (vertical axis), in a series of 61 melanomas treated in department.

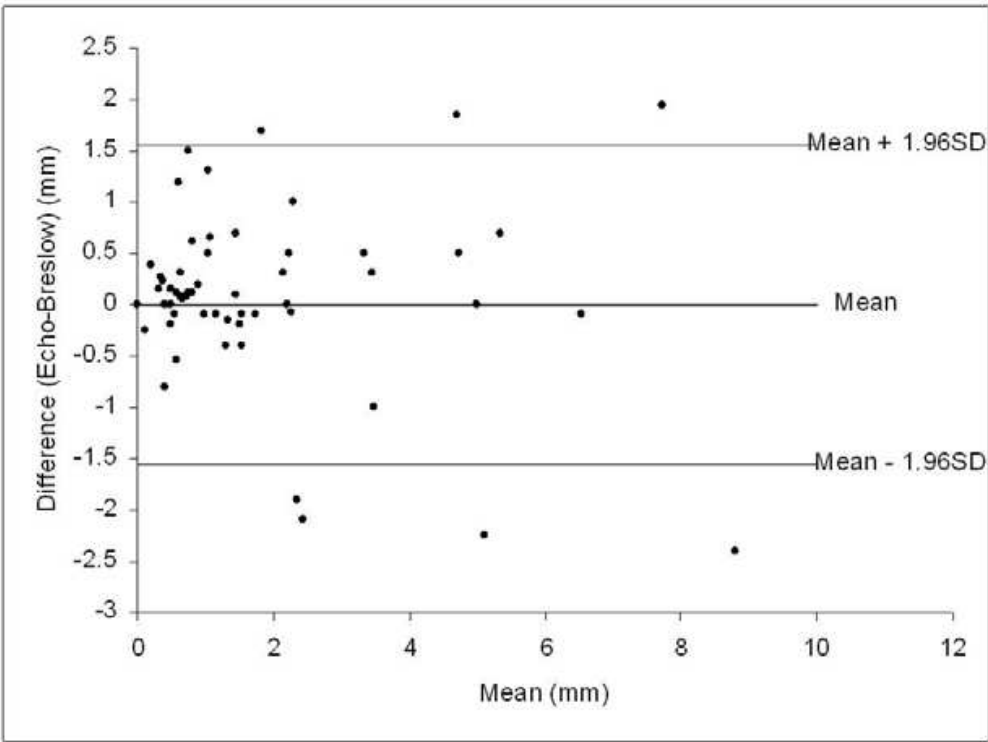


Fig. 8. Graph of Bland and Altman.

3. Differential diagnosis: ultrasound imaging of other frequent lesions

Ultrasound may assist the diagnosis of other pigmented or non pigmented tumors, as melanomas are sometimes achromic.

3.1 Basal Cell Carcinoma (BCC)

This is the most common skin cancer, most often located on areas of skin subjected to chronic sun exposure. The incidence is steadily increasing due to population aging and sun exposure habits. The pigmented variant of BCC may be confused with melanoma. In elderly subjects the tumor is mainly located on the face of. The first line of treatment is surgery, which allows complete excision and histological diagnosis. Radiotherapy or cryosurgery are therapeutic alternatives to surgery, with somewhat lower success rates (7% and 10% recurrence, respectively, versus 5% after surgery).

Ultrasound imaging may help in the diagnosis of BCC (25,26). The sonographic appearance is often stereotyped: overall anechoic tumor, including large focally dense echoes (Fig. 9). It is usually well delimited from the surrounding dermis. Ultrasound may also assist the detection of early recurrence, especially when surgical removal is incomplete or in cases treated with radiotherapy or cryosurgery. Ultrasound may also be used to help to determine the surgical margins or to delimitate the area treated with radiotherapy or cryosurgery (25, 27-32). This may decrease the rate of relapse.

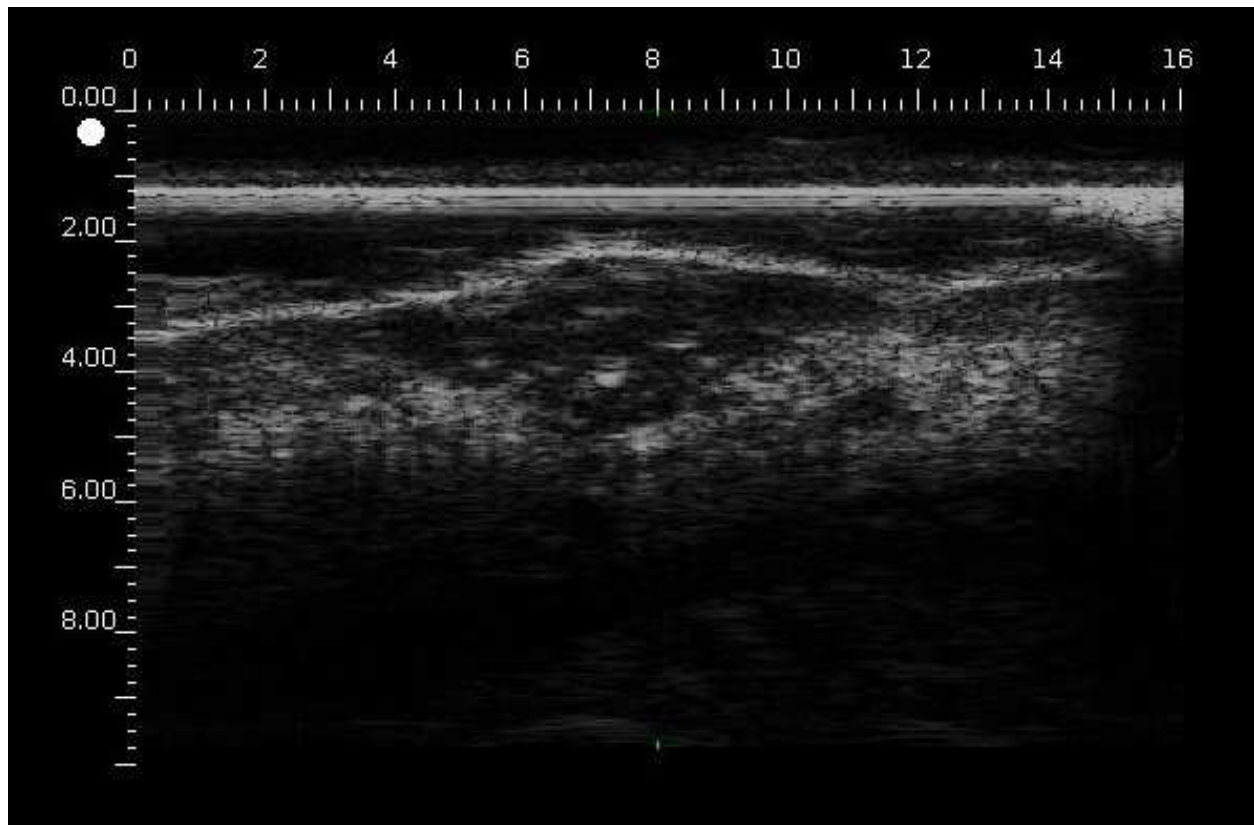


Fig. 9. Pigmented basal cell carcinoma showing some thick echoes within the tumor.

Epidermal cysts are limited, pushing the adjacent structures, and they have a heterogeneous structure, with both very echogenic and low echogenic areas (Fig. 10).

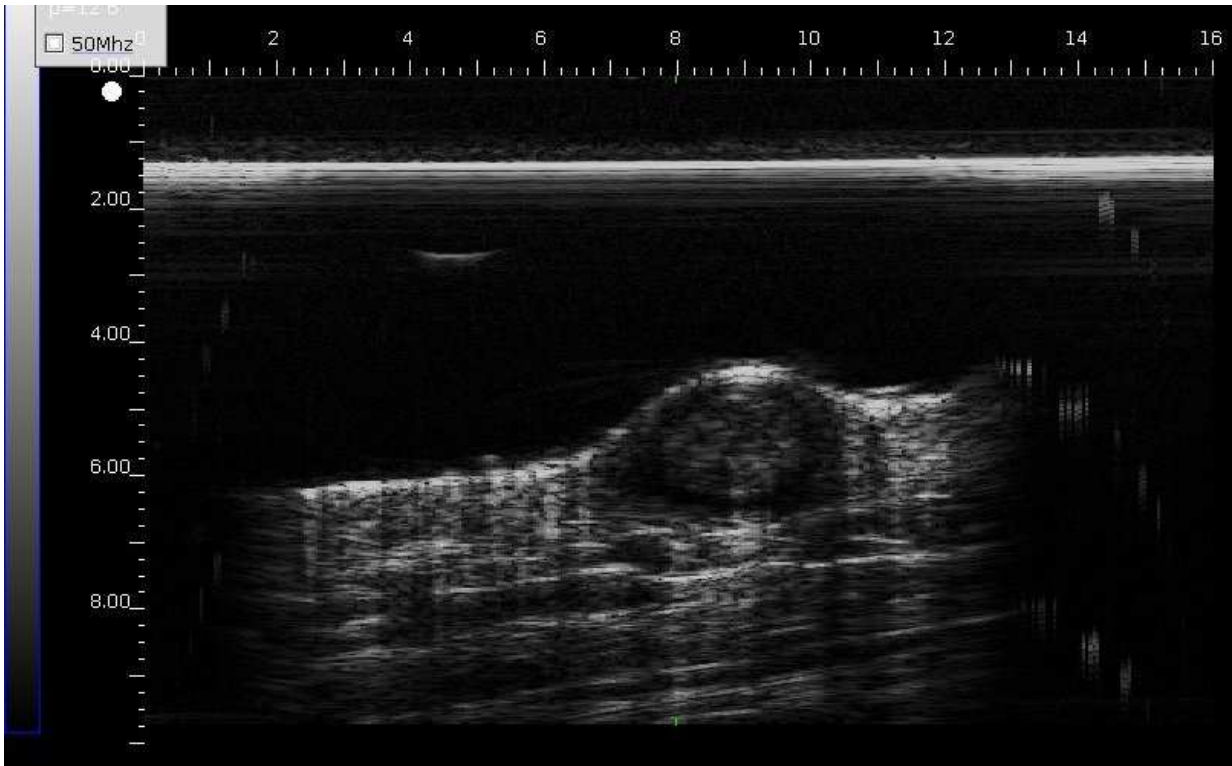


Fig. 10. Epidermal cysts showing a heterogeneous structure, with both very echogenic and low echogenic areas

*Fibrous histiocyto*mas are fairly homogeneous, less echogenic than the normal dermis , with multiple small echoes, and their boundaries are poorly demarcated from the surrounding dermis (Fig. 11).

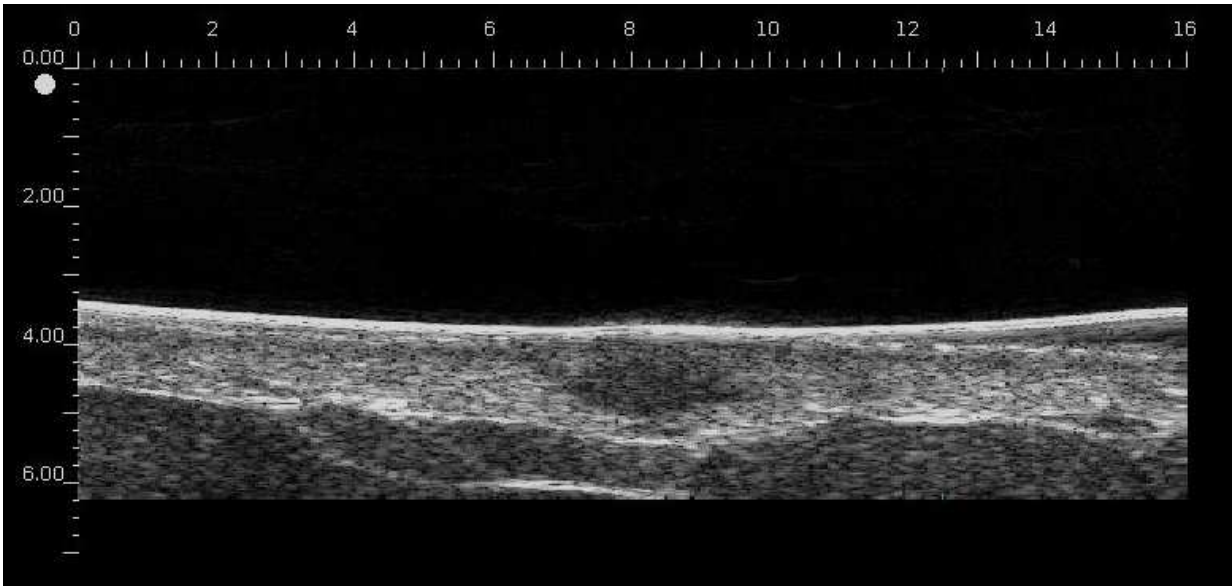


Fig. 11. Pigmented fibrous histiocyoma

Seborrheic keratoses are very well delimited, very superficial, as though laid on the skin, and may be misdiagnosed as melanoma. Ultrasound examination shows a dense echo input, under which there are very hypoechogenic lesions, in which one can sometimes see dense echoes (horny pseudocysts) (18) (Fig.12).

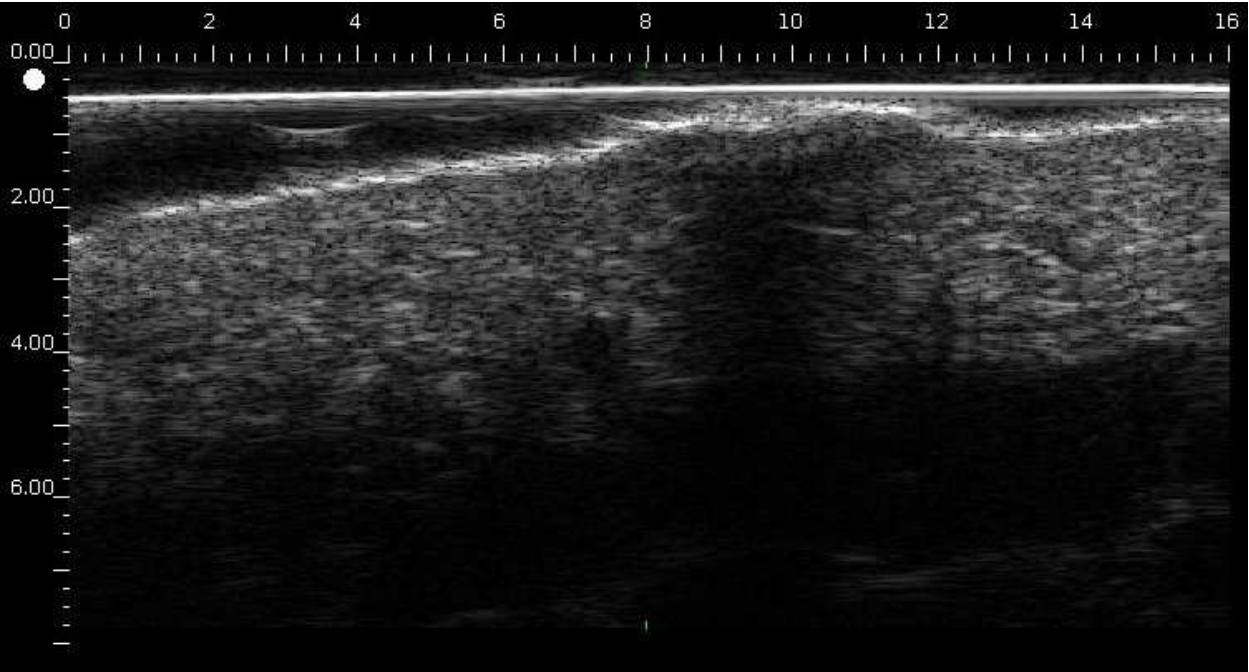


Fig. 12. Seborrheic keratosis with retrolesional acoustic shadowing

Acquired angiomas are sometimes a cause for concern especially in cases of inflammation or thrombosis, or sometimes in the differential diagnosis with amelanotic melanoma. They are fairly homogeneous lesions, less echogenic than the dermis, whose echogenicity is quite similar to that of the lip structure that is richly vascularized (Fig. 13).

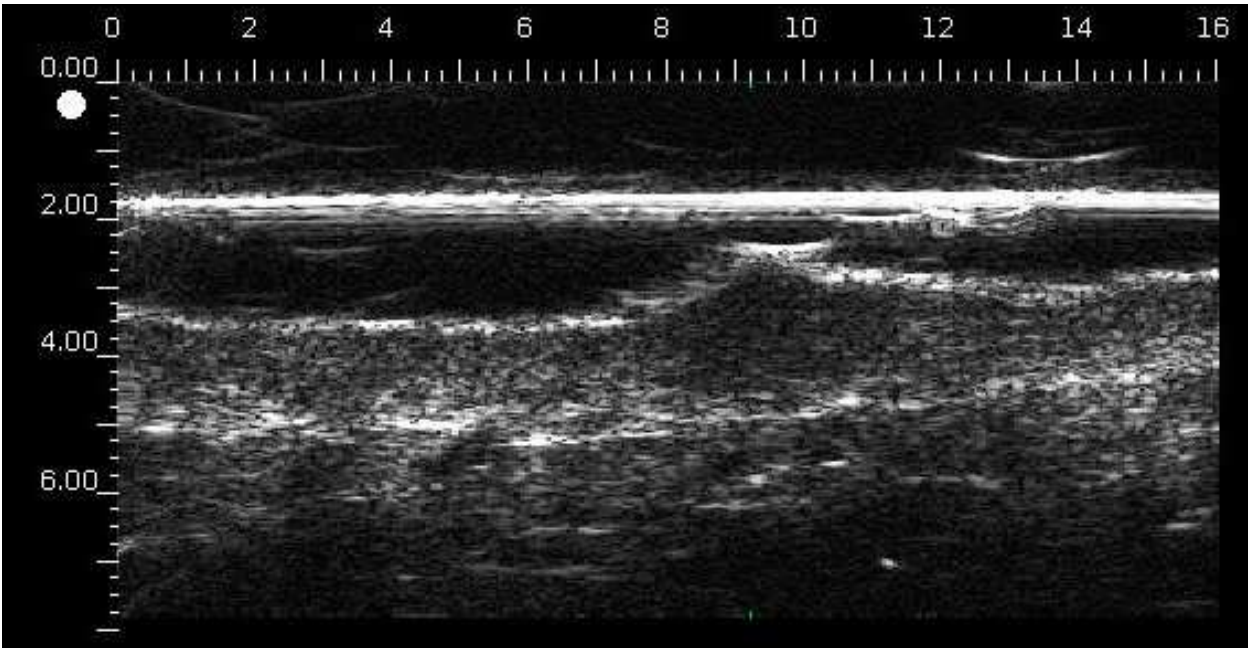


Fig. 13. Acquired hemangioma of the jaw.

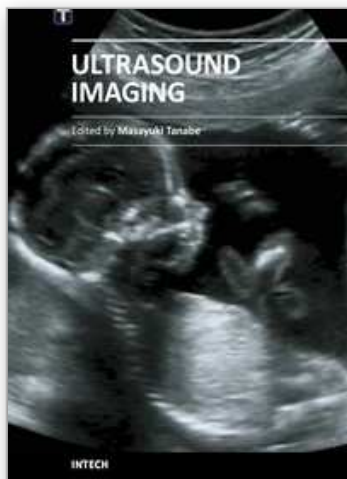
4. Conclusion

Pathology examination remains the ultimate gold standard for diagnosis of skin tumors. However, it is not conceivable to remove every skin lesion. Clinical examination (possibly assisted by dermoscopy) is often sufficient to determine whether a lesion has to be removed. However, ultrasound imaging provides additional information such as depth and lateral delimitation of the lesion, homogenous or heterogeneous structure, and hypo or hyperechoic appearance. These elements may of themselves be effective in terms of diagnostic accuracy and they are also valuable in the initial management or surveillance of patients.

5. References

- [1] Berson M, Vaillant L, Patat F, Pourcelot L. High-resolution real-time ultrasonic scanner. *Ultrasound Med Biol* 1992;18:471-8.
- [2] Berson M, Gregoire JM, Gens F, Rateau J, Jamet F, Vaillant L, Tranquart F, Pourcelot L. High frequency (20 MHz) ultrasonic devices: advantages and applications. *Eur J Ultrasound* 1999;10:53-63.
- [3] Hoffmann K, Jung J, el Gammal S, Altmeyer P. Malignant melanoma in 20-MHz B scan sonography. *Dermatology* 1992;185:49-55.
- [4] Fornage BD, McGavran MH, Duvic M, Waldron CA. Imaging of the skin with 20-MHz US. *Radiology* 1993;189:69-7.
- [5] Harland CC, Bamber JC, Gusterson BA, Mortimer PS. High frequency, high resolution B-scan ultrasound in the assessment of skin tumours. *Br J Dermatol* 1993;128:525-32.
- [6] Schmid-Wendtner MH, Burgdorf W. Ultrasound scanning in dermatology. *Arch Dermatol* 2005;141:217-24.
- [7] Rallan C, Harland CC. Ultrasound in dermatology. *Clin Exp Dermatol* 2003 ;28 :632-638.
- [8] Zymanska E, Nowicki A, Mlosek K, Litniewski J, Lewandowski M, Secomski W, Tymkiewicz R. Skin imaging with high frequency ultrasound - preliminary results. *J Ultrasound* 2000;12:9-16.
- [9] Rallan D, Harland CC. Ultrasound in dermatology--basic principles and applications. *Clin Exp Dermatol* 2003;28:632-8.
- [10] Rallan D, Harland CC. Skin imaging: is it clinically useful? *Clin Exp Dermatol*. 2004;29:453-9.
- [11] Turnbull DH, Starkoski BG, Harasiewicz KA et al. A 40-100 MHz B-scan ultrasound backscatter microscope for skin imaging. *Ultrasound Med Biol* 1995;21:79-88.
- [12] Vogt M, Opretzka J, Perrey C, Ermert H. Ultrasonic microscanning. *Proc Inst Mech Eng H* 2010;224:225-40.
- [13] Machet L, Nemeth-Normand F, Giraudeau B, Perrinaud A, Tiguemounine J, Ayoub J, Alison D, Vaillant L, Lorette G. Is ultrasound lymph node examination superior to clinical examination in melanoma follow-up? A monocentre cohort study of 373 patients. *Br J Dermatol* 2005;152:66-70.
- [14] Ulrich J, Voit C. Ultrasound in dermatology. Part II. Ultrasound of regional lymph node basins and subcutaneous tumours. *Eur J Dermatol* 2001;11:73-9.
- [15] Guitera P, Li LX, Crotty K et al. Melanoma histological Breslow thickness predicted by 75-MHz ultrasonography. *Br J Dermatol* 2008; 159: 364-9
- [16] Gambichler T, Moussa G, Bahrenberg K et al. Preoperative ultrasonic assessment of thin melanocytic skin lesions using a 100-MHz ultrasound transducer: a comparative study. *Dermatol Surg* 2007; 33: 818-824.

- [17] Krahn G, Gottlob P, Sander C, Peter RU. Dermatoscopy and high frequency sonography: two useful non-invasive methods to increase preoperative diagnostic accuracy in pigmented skin lesions. *Pigment Cell Res* 1998;11:151-4.
- [18] Harland CC, Kale SG, Jackson P, Mortimer PS, Bamber JC. Differentiation of common benign pigmented skin lesions from melanoma by high-resolution ultrasound. *Br J Dermatol* 2000;143:281-9.
- [19] Rallan D, Bush NL, Bamber JC, Harland CC. Quantitative discrimination of pigmented lesions using three-dimensional high-resolution ultrasound reflex transmission imaging. *J Invest Dermatol* 2007 ;27: 189-95.
- [20] Samimi M, Perrinaud A, Naouri M, Maruani A, Perrodeau E, Vaillant L, Machet L. High resolution ultrasonography helps the differential diagnosis between blue naevi and cutaneous metastases of melanoma. *Br J Dermatol* 2010; 163: 550-56.
- [21] Machet L, Belot V, Naouri M, Boka M, Mourtada Y, Perrinaud A, Giraudeau B, Laure B, Machet MC, Vaillant L. Preoperative measurement of thickness of cutaneous melanoma using high-resolution 20 mhz ultrasound imaging: feasibility and pitfalls to predict surgical margins. A prospective study of 31 cases and a systematic review of the litterature. *Ultrasound Med Biol* 2009;35:1411-20.
- [22] Pellacani G, Seidenari S. Preoperative melanoma thickness determination by 20-MHz sonography and digital videomicroscopy in combination. *Arch Dermatol* 2003;139:293-8.
- [23] Serrone L, Solivetti FM, Thorel MF, Eibenschutz L, Donati P, Catricala C. High frequency ultrasound in the preoperative staging of primary melanoma: a statistical analysis. *Melanoma Res* 2002;12:287-90.
- [24] Lassau N, Spatz A, Avril MF, Tardivon A, Margulis A, Mamelle G, Vanel D, Leclere J. Value of high-frequency US for preoperative assessment of skin tumors. *Radiographics* 1997;17:1559-65.
- [25] Vaillant L, Grogard C, Machet L, Cochelin N, Callens A, Berson M, Aboumrard J, Patat F, Lorette G. Imagerie ultrasonore haute résolution: utilité pour le traitement des carcinomes basocellulaires par cryochirurgie. *Ann Dermatol Venereol* 1998;125:500-504.
- [26] Uhara H, Hayashi K, Koga H, S Toshiaki. Multiple hypersonographic spots in basal cell carcinoma. *Dermatol Surg* 2007; 33: 1215-9.
- [27] Desai TD, Desai AD, Horowitz DC, Kartono F, Wahl T. The use of high-frequency ultrasound in the evaluation of superficial and nodular basal cell carcinomas. *Dermatol Surg* 2007;33:1220-7
- [28] Mogensen M, Nürnberg BM, Forman JL, Thomsen JB, Thrane L, Jemec GB. In vivo thickness measurement of basal cell carcinoma and actinic keratosis with optical coherence tomography and 20-MHz ultrasound. *Br J Dermatol* 2009;160:1026-33.
- [29] Marmur ES, Berkowitz EZ, Fuchs BS, Singer GK, Yoo JY. Use of high-frequency, high-resolution ultrasound before Mohs surgery. *Dermatol Surg* 2010;36:841-7.
- [30] Jambusaria-Pahlajani A, Schmults CD, Miller CJ, Shin D, Williams J, Kurd SK, Gelfand JM. Test characteristics of high-resolution ultrasound in the preoperative assessment of margins of basal cell and squamous cell carcinoma in patients undergoing Mohs micrographic surgery. *Dermatol Surg* 2009;35:9-15
- [31] Bobadilla F, Wortsman X, Muñoz C, Segovia L, Espinoza M, Jemec GB. Pre-surgical high resolution ultrasound of facial basal cell carcinoma: correlation with histology. *Cancer Imaging* 2008;8:163-72.
- [32] Moore JV, Allan E. Pulsed ultrasound measurements of depth and regression of basal cell carcinomas after photodynamic therapy: relationship to probability of 1-year local control. *Br J Dermatol* 2003;149:1035-40.



Ultrasound Imaging

Edited by Mr Masayuki Tanabe

ISBN 978-953-307-239-5

Hard cover, 210 pages

Publisher InTech

Published online 11, April, 2011

Published in print edition April, 2011

In this book, we present a dozen state of the art developments for ultrasound imaging, for example, hardware implementation, transducer, beamforming, signal processing, measurement of elasticity and diagnosis. The editors would like to thank all the chapter authors, who focused on the publication of this book.

How to reference

In order to correctly reference this scholarly work, feel free to copy and paste the following:

Laurent Machet, Mahtab Samimi, Gabriella Georgesco, Youssef Mourtada, Michaël Naouri, Jean Marc Grégoire, Frédéric Ossant, Frédéric Patat and Loïc Vaillant (2011). High Resolution Ultrasound Imaging of Melanocytic and Other Pigmented Lesions of the Skin, Ultrasound Imaging, Mr Masayuki Tanabe (Ed.), ISBN: 978-953-307-239-5, InTech, Available from: <http://www.intechopen.com/books/ultrasound-imaging/high-resolution-ultrasound-imaging-of-melanocytic-and-other-pigmented-lesions-of-the-skin>

INTech
open science | open minds

InTech Europe

University Campus STeP Ri
Slavka Krautzeka 83/A
51000 Rijeka, Croatia
Phone: +385 (51) 770 447
Fax: +385 (51) 686 166
www.intechopen.com

InTech China

Unit 405, Office Block, Hotel Equatorial Shanghai
No.65, Yan An Road (West), Shanghai, 200040, China
中国上海市延安西路65号上海国际贵都大饭店办公楼405单元
Phone: +86-21-62489820
Fax: +86-21-62489821

© 2011 The Author(s). Licensee IntechOpen. This chapter is distributed under the terms of the [Creative Commons Attribution-NonCommercial-ShareAlike-3.0 License](https://creativecommons.org/licenses/by-nc-sa/3.0/), which permits use, distribution and reproduction for non-commercial purposes, provided the original is properly cited and derivative works building on this content are distributed under the same license.

IntechOpen

IntechOpen