

We are IntechOpen, the world's leading publisher of Open Access books Built by scientists, for scientists

6,900

Open access books available

185,000

International authors and editors

200M

Downloads

Our authors are among the

154

Countries delivered to

TOP 1%

most cited scientists

12.2%

Contributors from top 500 universities



WEB OF SCIENCE™

Selection of our books indexed in the Book Citation Index
in Web of Science™ Core Collection (BKCI)

Interested in publishing with us?
Contact book.department@intechopen.com

Numbers displayed above are based on latest data collected.
For more information visit www.intechopen.com



Usability of CT Images of Frontal Sinus in Forensic Personal Identification

Ertugrul Tatlisumak, Mahmut Asirdizer and Mehmet Sunay Yavuz
*Celal Bayar University
 Turkey*

1. Introduction

Forensic personal identification is a fundamental topic of forensic sciences and technologies to identify lived subjects, recently deceased bodies and human remains often at a crime scene by using several appropriate techniques.

Throughout human history, many different methods were used for personal identification. The most commonly used method was relying on one's memory to identify the distinguishing features and characteristics of other humans, such as their outward appearance or the sound of their voice before the introduction of computer technology (Michael & Michael, 2006). In Ancient Egypt and China, criminals and victims of several medico-legal events was often identified through visual characteristics such as sex, human height, body weight, deformation of the body, tattoos, old scars or caste marks and clothing, etc. In the forensic personal identification, progressions based on science accelerated in 19th century. Italian Cesare Lombroso (1835-1909) had studied on body structures of prison inmates and had claimed that criminals have particular physiognomic attributes or deformities. In 1823, known first documentation of fingerprints were defined in a thesis by Johannes Evangelists Purkinje (1787-1869), a Czech anatomist and physiologist. French Police Officer Alphonse Bertillon (1853-1914) created first anthropometric scientific system based on physical measurements for identifying criminals in 1880. Sir Francis Galton (1822-1911) was an English inventor, devised a method for classifying fingerprints that proved useful in forensic science and he wrote first book about fingerprints in 1892 (Soysal & Eke, 1999). In November 1895, the detection of electromagnetic radiation in a wavelength range - today known as x-rays or Röntgen rays - by Wilhelm Conrad Röntgen (1845-1923), a German physicist, marked an era in forensic science as well as in clinical diagnosis. The discovery of ABO blood group system by Karl Landsteiner (1868-1943), an Austrian biologist and physician, in 1901 and rhesus blood system by Landsteiner and Alexander Solomon Wiener (1907-1976), American Scientist, in 1937, and description of Coombs test by British immunologists Robin Coombs (1921-2006), et al., blood samples was used to be a unique profile that could be used for personal identification in legal and criminal areas. At 9:05 am on Monday 10 September 1984, Sir Alec John Jeffreys (1950-....), British geneticist, looked at the X-ray film image of a deoxyribonucleic acid (DNA), then he developed techniques for DNA fingerprinting and DNA profiling, which provided a significant contribution for forensic personal identification in all over the world (Soysal & Eke, 1999).

Although the development of new techniques, forensic imaging studies have continued to increase until now and has not lost its importance especially in difficult cases of DNA analysis—for example, relatives, twins, or cases of poorly conserved remains (Cameriere et al., 2008).

In the last years of 20th century and first decade of 21st century, the use of radiological techniques improved and became widespread by the creation of computerized tomography (CT), magnetic resonance imaging (MRI), multislice computed tomography (MSCT) and ultrasound (USG). These creations provided opportunity for developing newer techniques in the forensic sciences.

In this chapter, we aimed to present the usage of radiographic technique especially CT images in forensic sciences, morphological structure of frontal sinus, usability of CT images of frontal sinus in forensic personal identification, and techniques for forensic personal identification by using CT images of frontal sinus.

2. Usage of radiographic techniques in forensic sciences

Historically, early application of x-ray in forensic sciences was introduced in 1896 - just one year following the x-ray discovery - by Prof. Arthur Schuster (1851-1934) of Owens College, Manchester in England, to demonstrate the presence of lead bullets inside the head of a victim (Eckert & Garland, 1984).

It was expressed that, Schüller from Vienna proposed the possibility of utilizing by comparison of radiological images of the frontal sinuses with plates formerly taken for identification purposes in 1921 and the first complete radiological identification by using pneumatic cells of the skull was described by Culbert & Law, in 1927 (Culbert & Law, 1927; Gruber & Kameyama, 2001; Carvalho et al., 2009).

Today, forensic scientists have regularly used radiographic images as part of the autopsy procedures and clinical forensic applications.

2.1 Usage of radiographic techniques in autopsy procedure

Radiological techniques are part of autopsy techniques and they have been fairly common used in modern forensic facilities. The stage at which radiology is implemented during autopsy varies according to the individual circumstances, but usually it is be after the external examination and prior to the dissection (Kahana & Hiss, 1999).

Radiological techniques may provide important clues to determine the manner of death. In the autopsy procedure, radiography is best and earliest method of demonstrating air embolism to the heart, brain or vascular tree and forensics can be alerted in advance to the presence of pneumothorax, pneumoperitonium, pneumopericardium, pneumomediastinum or abnormal air collections associated with abscess, obstruction or paralytic dysfunction (Brogdon, 1998).

Whilst, the identification of some fractures, fracture sequels, baro-traumas and soft tissue injuries present some difficulties, the determination of them by radiological techniques may be relatively easy. Radiological determination of manner of death in medico-legal cases by using CT, MRI, MSCT and USG was defined to be “*virtopsy (virtual autopsy) technique*”.

Virtopsy has been proposed as an alternative to conventional autopsy in cases when the next of kin oppose the necroscopy and as a complementary tool for better visualization of postmortem findings such as fractures, especially pelvic and extremity fractures; visceral and vascular injuries and pathologies like intracranial hemorrhages, cerebral contusions and

edema, splenomegaly, aneurysms, air and fat embolism, hemothorax and pneumothorax, pneumonia, aspiration of foreign bodies, food or blood, subcutaneous emphysema, myocardial infarction, some tumors (Kahana & Hiss, 2005; Poulsen & Simonsen, 2007).

Bullet or bullet fragments in death related firearms, bomb fragments or shrapnel in death related bombings and glass or metallic fragments in death related traffic or air-craft accidents, animals, plants or minerals, which embedded, aspirated or injected, in several deaths, etc., can be determined and exerted, to be presented as evidence in court, by using x-rays and other radiological techniques during medico-legal autopsy applications (Brogdon, 1998; Gruber & Kameyama, 2001; Carvalho et al., 2009). It was reported that CT data and the 3-D reconstruction could provide valuable information in the forensic assessment of patients with gunshot wounds for determination of firing distance (Stein et al., 2000).

The angiographic techniques including corpuscular radiopaque material such as menninge (a red lead oxide), barium sulfate, bismuth chloride, potassium iodide, corn syrup; oily liquids such as iodized oil, propyliodone, mixture of diesel oil and paraffin oil; hydro-soluble preparations such as diatrizoate meglumine, diatrizoate sodium, ioxithalamate; casts such as mixtures of lead, bismuth, and cadmium, celluloid and celloidin, nylon, neoprene latex, polyester resin, vinyl and silicon rubber; and their special mixtures was defined very useful for postmortem investigation of cardiovascular system (Grabherr et al., 2007) (Fig-2). The usage of radiological techniques in postmortem applications allows creating of permanent records of autopsy findings for reevaluation, comparison in personal identification and submission to be evidence to courts (Swift & Rutty, 2006).

Also, radiological techniques allow forensic personal identification of the ripped, lacerated, carbonized, macerated, putrefied or skeletonized corpses (Gruber & Kameyama, 2001; Carvalho et al., 2009) and in mass disasters (Kahana & Hiss, 1999; Swift & Rutty, 2006).

2.2 Usage of radiographic techniques in clinical forensic applications

The importance of radiological techniques in clinical forensic application is widely recognized for definition type, severity, healing degree and mechanism of injuries (Kahana & Hiss, 2005; Swift & Rutty, 2006). It was defined that some skull fractures can not be diagnosed on conventional CT; they can be distinguished with the use of plain x-rays (Yavuz et al., 2001).

Radiological examinations play significant role in differential diagnosis to non-accidental fractures from accidental fractures (Asirdizer & Zeyfeoglu, 2005); in determination of radiological evidence of physical child abuse (Asirdizer & Zeyfeoglu, 2005; Kahana & Hiss, 2005; Yavuz et al., 2008), torture (Vogel et al., 2007) and medical malpractice cases (Ulucay et al., 2010); localization and type of bullets remained within body (Brogdon, 1998).

Also, radiological techniques have been used by aim of personalization and age determination of victims or defendants in criminal cases and persons in civil litigations (Brogdon, 1998; Kahana & Hiss, 1999; Kahana & Hiss, 2005).

2.3 Usage of radiographic techniques in forensic personal identification

In forensic personal identification, forensic scientists have benefited from the variations of normal anatomical structures in radiographs and they compared shapes, contours, distinctive trabecular patterns, healed fractures, deformities, abnormal calcifications or other pathological features of several bones in radiographs, which taken to determine the identity, with previously existent radiographs (Jablonski & Shum, 1989). Also, they take into account

the absence or replacing of some anatomical structures, and the presence of metallic materials such as prosthesis.

Among radiographs used for forensic personal identification, there were several parts of skull (Bodey et al., 2003; Teke et al., 2007), ribs (Rejtarová et al., 2004), hip (Varga & Takács, 1991), dental, chest and abdominal areas (Kahana & Hiss, 1999). Identification of human remains by comparison of antemortem and postmortem radiographs of frontal sinuses is a well established procedure among forensic scientists and even some of the authors claim to use them as a substitute for fingerprints and frontal sinuses in particular have always been assumed to be different in every person (Yoshino et al., 1987; Harris et al., 1987; Kullman et al., 1990). Computerized tomography is an advanced and new technique and in literature there are only a few reports on identification of unknown bodies using CT scans of frontal sinus (Reichs, 1993; Riepert et al., 2001; Tatlisumak et al., 2007; Pfaeffli et al., 2007; Blau et al., 2008; Uthman et al., 2010).

3. Morphological structure of frontal sinus

3.1 The location of frontal sinus

The frontal sinuses are a part of paranasal sinuses and they located in the frontal bone above each eye (Fig-1). They make an important contribution to normal forehead and glabellar contour.

3.2 The development of frontal sinus

According to classical knowledge based on x-rays, frontal sinus is not apparent at birth and development begins during the second year of life (Yoshino et al., 1987; Quatrehomme et al., 1996; Kirk et al., 2002). However, CT studies show that frontal sinus begins development in

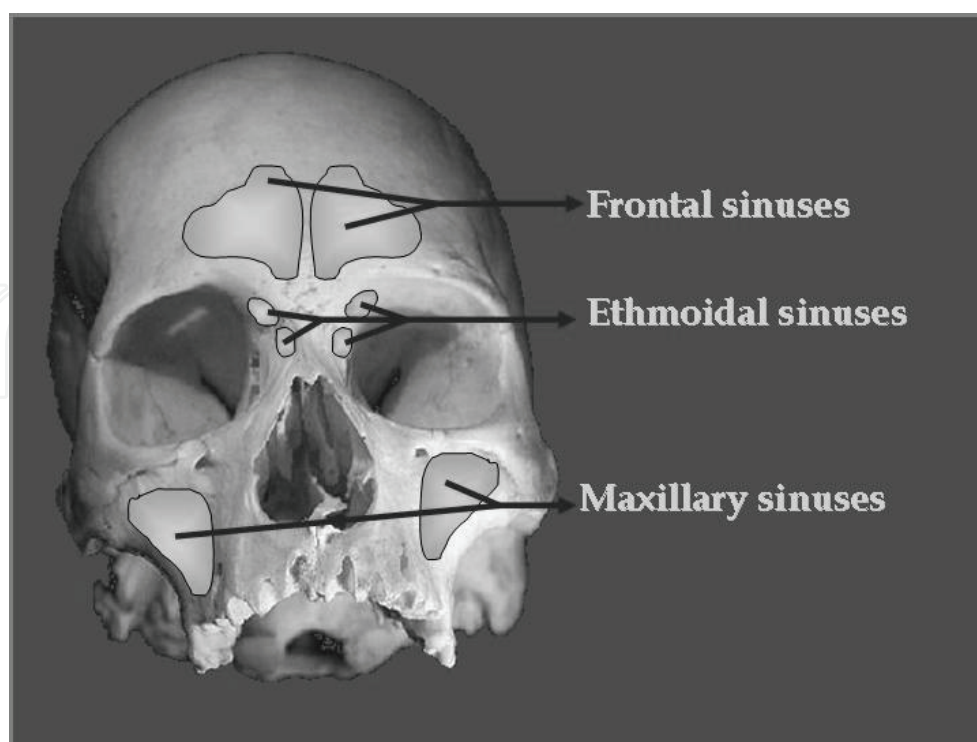


Fig. 1. Location of Paranasal Sinuses

the region of frontal recess of the frontal nasal meatus in a fetus aging 4th months of gestation. In the latter weeks of the fetal life, the frontal recess of the middle nasal meatus transforms upwards into an oval thin-walled space corresponding to the developing frontal sinus. It adheres to the ethmoidal labyrinth, integrating with it (Miller & Amedee, 1998; Porowski et al., 1999).

The frontal sinus rarely is visible on radiographs earlier than the second year of life. The sinus invades the frontal bone by about 5 years of age and slowly grows to reach an adult size in late adolescence (Miller & Amedee, 1998).

Whilst it is widely accepted that the development of the frontal sinus is complete by about 20 years of age and remains stable until further enlargement of the chambers can occur from bone resorption during the advanced ages (Yoshino et al., 1987; Quatrehomme et al., 1996; Kirk et al., 2002); Tatlisumak et al., reported that, the highest values of measurements of frontal sinus were at the 31–40 age group in both sexes and there were a tendency to decrease with aging (Tatlisumak et al., 2008). Also, McLaughlin et al., suggested that the frontal sinus continued to expand until the age of 40 years because of mechanical stresses of mastication and growth hormone levels (McLaughlin et al., 2001).

3.3 Morphological structure of frontal sinus

The frontal sinus is a triangular, pyramid-shaped (its apex is superior and its base is inferior) cavity extending between the anterior and posterior tables of the ascending portion of the frontal bone (Clemente, 2004). The structure of frontal sinus can be variable from person to person and its sizes might be different in different populations (Miller & Amedee, 1998; Tatlisumak et al., 2008). Yoshino et al. described 20,000 types of frontal sinus (Yoshino et al., 1987). Although, Miller and Amedee reported that height of frontal sinus was between 5 and 66 mm, and its width between 17 and 49 mm (Miller & Amedee, 1998); the maximum and minimum sizes of frontal sinus were defined variable by several scientists in several populations.

Usually, there was a complete intersinus septum between both frontal sinuses. The anterior wall of frontal sinus is the strongest of the sinus walls and its thickness can reach to 12 mm. In the entire sinus wall, there were diploë, although the diploë is minimal in the posterior wall and floor of sinus (inferior wall). The posterior wall is a plate of thin, compact bone (1–2 mm) whose upper part is vertical. It separates the frontal sinus from the anterior cranial fossa and can extend to lesser wing of sphenoid bone. The floor of the sinus also functions as the supraorbital roof in the lateral side and naso-ethmoid floor in the medial side. The drainage ostium is located in the posteromedial portion of the sinus floor. The frontal infundibulum is a more narrow area within the sinus that leads to the ostium. The frontal sinus-ostium-frontal recess complex is shaped like an hourglass. The size of the bottom half depends on the dimensions of the frontal recess (Miller & Amedee, 1998; Clemente, 2004).

3.4 Functions of frontal sinus

The functions of frontal sinuses which are a part of paranasal sinuses greatly resemble to paranasal sinus functions. The functional significance of paranasal sinuses remains largely unknown. The sinuses have been believed to play numerous roles, but no substantive

laboratory studies have confirmed any of these hypothetical functions (Miller & Amedee, 1998).

Prevailing theories suggest that the paranasal sinuses perform: (a) humidifying and warming inspired air, (b) assisting in regulation of intranasal pressure, (c) increasing the surface area of the olfactory membranes, (d) lightening the skull to maintain proper head balance or assist in flotation, (e) imparting resonance to the voice, (f) absorbing shock to the head, (g) contributing to facial growth, (h) existing as evolutionary remains of useless air spaces, (i) secreting of immunoglobulin, interferon and lysozyme (Miller & Amedee, 1998; Wang & Berke, 1998). Also, Qian et al described a role of frontal sinus in nitric oxide output (Qian et al, 2005).

The complete function of the paranasal sinuses is probably not described by a single theory but is instead most likely a combination of several of the foregoing theories (Miller & Amedee, 1998).

4. Usage of radiology of frontal sinus in forensic personal identification

Some of the features of frontal sinus morphology make it most convenient part of the skeleton for forensic identification (Fig-2 & Fig-3). Firstly, it presents highly variable nature and shows variation even among the monozygotic twins (Yoshino et al., 1987; Quatrehomme et al., 1996; Cox et al., 2009). This empirically accepted variability was proven

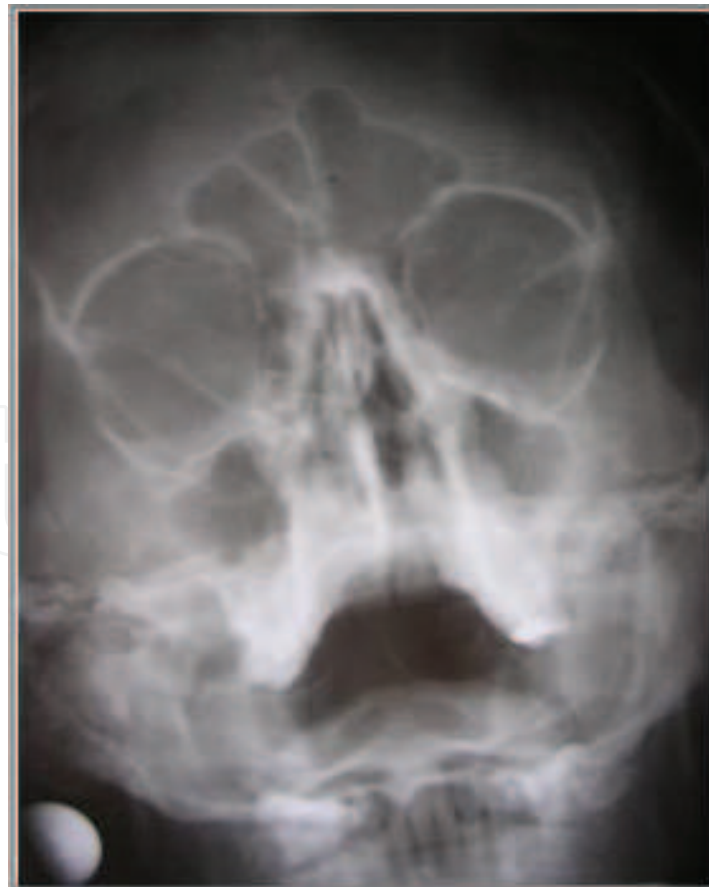

Fig. 2. Appearance of Frontal Sinus in an x-ray

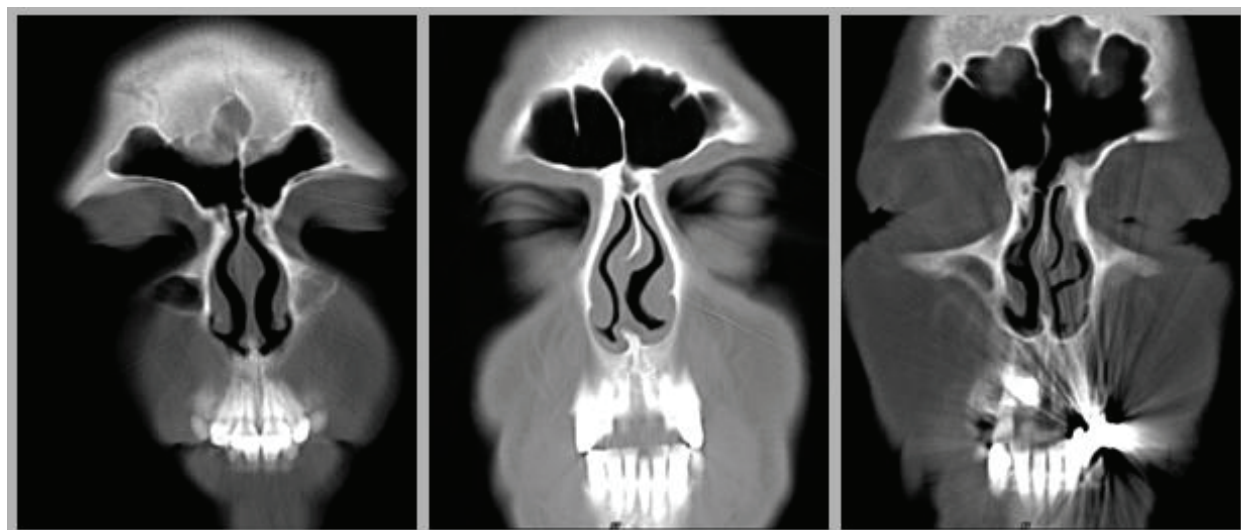


Fig. 3. Appearance of Several Frontal Sinuses in CTs

mathematically using Elliptical Fourier analysis by Christensen (Christensen, 2005). Second feature is its relatively stable structure during adult life (Cox et al., 2009). But changes in the dimensions of the frontal sinus throughout the adult life were shown by the investigators (McLaughlin, et al., 2001; Tatlisumak et al., 2008). Therefore, writers of this text is suggesting that the radiographs not older than ten years are more reliable for the identification purposes. Thirdly, the resiliency of the frontal sinus makes it useful for forensic purposes. It has very strong walls and preserved intact in human remains (Marlin, et al., 1991; Nambiar, et al., 1999; Fairgrieve, 2008). Fourthly, paranasal sinus radiographs are taken commonly for diagnostic purposes and almost everybody has one in his/her health folder (Tatlisumak, et al., 2007; Cox, et al., 2009).

Radiographic comparison permits the matching of unique anatomical features and has the advantage of making possible the matching of external and internal bony anatomy, therefore increasing by several-fold the potential number of points of correspondence available for identification (Jablonski & Shum, 1989).

In the presence of an antemortem radiograph, it can be compared with a postmortem one and personal identification of a human remain can be made. It is a widely accepted procedure in forensic sciences. Comparison of the antemortem and postmortem radiographs of the frontal sinus can be made by superimposition or coding systems. Superimposition is accepted as a reliable method (Yoshino, et al., 1987; Riberio Fde, 2000; Kirk, et al., 2002; Nambiar, et al., 1999; Marlin, et al., 1991). But there are some disadvantages: Data can not be stored and the evaluation should be made again and again for every case and both radiographs should be in hands for comparison. To overcome this problem, systems were proposed for coding frontal sinuses (Yoshino, et al., 1987; Tatlisumak, et al., 2007; Cameriere, et al., 2008). But none of them is perfect and there is always a possibility of false positive results (Tatlisumak, et al., 2007; Tang, et al., 2009).

These systems are still far from being as useful as fingerprints. Today, discrimination of the most of the radiographs by using simple features and applying pattern matching for the remaining ones is seen logical as an algorithm (Tatlisumak, et al., 2007).

Computerized tomography is a significant advance in radiology and it is becoming increasingly available and replacing gradually the conventional radiographs (Haglund &

Fligner., 1993; Tatlisumak, et al., 2007). Computerized tomography is a suitable imaging method in the identification of unknown human remains and presents a lot of advantages as compared with conventional radiographs. Firstly, it gives the opportunity of avoiding the superimposition of structures beyond the plane of interest and allowing the visualization of small differences of density (Reichs, 1993; Jackowski, et al., 2008; Carvalho, et al., 2009). Secondly, the images can be easily manipulated and internal points that should be evaluated can be shown by images segmentation. Thirdly, Craniometric points can be precisely located and measurements can be more accurately performed than on conventional radiographs. Volumes and areas can be determined. Fourthly, the film includes a description of the technical details and knowledge about the patient which can be very useful for the identification process (Jackowski, et al., 2008; Carvalho, et al., 2009).

There are several studies in the literature presenting successful identification using CT images of frontal sinus (Reichs, 1993; Haglund & Fligner., 1993; Smith, et al., 2002; Tatlisumak, et al., 2007). It is expected that forensic scientists will make more identification in the future by using CT scans. The identification technique by conventional radiography was based on the comparison to ante-mortem images of frontal sinuses recorded in clinics and radiology departments with post-mortem radiographic images obtained in autopsy rooms or during autopsy procedure.

5. References

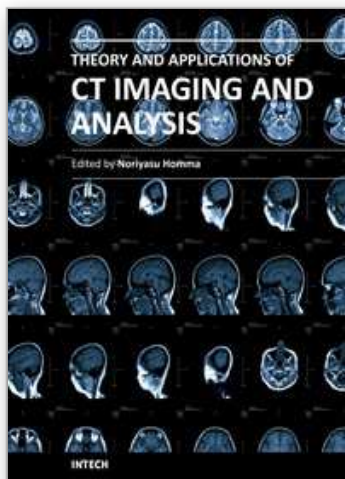
- Michael, K. & Michael, M.G. (2006). The proliferation of identification techniques for citizens throughout the ages, In: *The Social Implications of Information Security Measures on Citizens and Business*, (Eds., K. Michael & M.G. Michael), pp.7-26, University of Wollongong, Centre for eBusiness Application Research (CeBAR), ISBN: 1-74128-118-0, NSW-Australia
- Soysal, Z. & Eke, M. (1999). The history and development of forensic medicine in the world, In: *Forensic Medicine, Volume: 1*, (Eds. Z. Soysal & C. Cakalir), pp. 1-29, Printing House and Film Center of Istanbul University, ISBN: 975-404-540-2, Istanbul-Turkey
- Cameriere, R.; Ferrante, L.; Molleson, T. & Brown, B. (2008). Frontal sinus accuracy in identification as measured by false positives in kin groups. *Journal of Forensic Sciences*. Vol. 53, No. 6, p. 1280-1282, ISSN: 0022-1198
- Eckert, W.G. & Garland N. (1984). The history of the forensic applications in radiology. *The American Journal of Forensic Medicine and Pathology*. Vol. 5, No. 1, p. 53-56, ISSN: 0195-7910
- Culbert, W.L. & Law, F.M. (1927). Identification by comparison of roentgenograms of nasal accessory sinuses and mastoid processes. *The Journal of American Medical Association*. Vol. 88, No. 21, p. 1634-1636, ISSN: 0098-7484
- Gruber, J. & Kameyama, M.M. (2001). The role of radiology in forensic dentistry. *Pesquisa Odontológica Brasileira*. Vol. 15, No. 3, p. 263-268, Print ISSN: 1517-7491
- Carvalho, S.P.M.; Alves da Silva, R.H.; Lopes-Júnior, C. & Peres, A.S. (2009). Use of images for human identification in forensic dentistry. *Radiologia Brasileira*. Vol. 42, No. 2, p. 125-130, ISSN: 0100-3984

- Kahana, T. & Hiss, J. (1999). Forensic Radiology. *The British Journal of Radiology*. Vol. 72, No. 854, p. 129-133, ISSN: 0007-1285
- Brogdon, B.G. (1998). Scope of forensic radiology. In: *Forensic Radiology*, (Ed., B.G. Brogdon), pp. 35-52, CRC Press LLC, ISBN: 0-8493-8105-3, Boca Raton, Florida-USA
- Kahana, T. & Hiss, J. (2005). Forensic Radiology. In: *Forensic Pathology Reviews, Volume-3*, (Ed., M. Tsokos), pp. 443-460, Humana Press, ISBN: 1-59259-416-1, Totowa, New Jersey-USA.
- Poulsen, K. & Simonsen J. (2007). Computed tomography as routine in connection with medico-legal autopsies. *Forensic Science International*. Vol. 171, No. 2-3, p. 190-197, ISSN: 0379-0738
- Stein, K.M.; Bahner, M.L.; Merkel, J.; Ain, S. & Mattern, R. (2000). Detection of gunshot residues in routine CTs. *International Journal of Legal Medicine*. Vol. 114, No. 1-2, p. 15-18, ISSN: 0937-9827
- Grabherr, S.; Djonov, V.; Yen, K.; Thali, M.J. & Dirnhofer, R. (2007). Postmortem angiography: review of former and current methods. *American Journal of Roentgenology*. Vol. 188, No. 3, p. 832-838, ISSN: 0361-803X
- Swift, B. & Rutty G.N. (2006). Recent advances in forensic radiology, In: *Forensic Pathology Reviews, Volume-4*, (Ed., M. Tsokos), pp. 355-404, Humana Press Inc, ISBN: 1-59259-921-4, Totowa, New Jersey-USA
- Yavuz, M.S.; Asirdizer, M.; Cetin Agirbas, A. & Altinkok, M. (2001). The importance of cranial x-ray to diagnoses linear skull fractures cannot be seen by CT. *Clinical Forensic Medicine*. Vol. 1, No. 2, p. 81-88, ISSN: 1302-9908
- Asirdizer, M. & Zeyfeoglu, Y. (2005). Femoral and tibial fractures in a child with myelomeningocele. *Journal of Clinical Forensic Medicine*. Vol. 12, No. 2, p. 93-97, ISSN: 1353-1131
- Yavuz, M.S.; Buyukyavuz, I.; Savas, C.; Ozguner, I.F.; Kupeli, A. & Asirdizer M. (2008). A battered child case with duodenal perforation. *Journal of Forensic and Legal Medicine*. Vol. 15, No. 4, p. 259-262, ISSN: 1752-928X
- Vogel, H.; Schmitz-Engels, F. & Grillo, C. (2007). Radiology of torture. *European Journal of Radiology*. Vol. 63, No. 2, p. 187-204, ISSN: 0720-048X
- Ulucay, T.; Dizdar, M.G.; Yavuz M.S. & Asirdizer, M. (2010). The importance of medico-legal evaluation in a case with intraabdominal gossypiboma. *Forensic Science International*. Vol. 198, No. 1-3, p. e15-e18, ISSN: 0379-0738
- Jablonski, N.G. & Shum B.S.F. (1989). Identification of unknown human remains by comparison of antemortem and postmortem radiographs. *Forensic Science International*. Vol. 42, No. 3, p. 221-230, ISSN: 0379-0738
- Bodey, T.E.; Loushine, R.J. & West, L.A. (2003). A retrospective study evaluating the use of the panoramic radiograph in endodontics. *Military Medicine*. Vol. 168, No. 7, p. 528-529, ISSN: 0026-4075
- Teke, H.Y.; Duran, S.; Canturk, N. & Canturk, G. (2007). Determination of gender by measuring the size of the maxillary sinuses in computerized tomography scans. *Surgical and Radiological Anatomy*. Vol. 29, No. 1, p. 9-13, ISSN: 0930-1038

- Rejtarová, O.; Slízová, D.; Smoranc, P.; Rejtar, P. & Bukac, J. (2004). Costal cartilages – a clue for determination of sex. *Biomedical Papers*. Vol. 148, No. 2, p.241-243, ISSN: 1213-8118
- Varga, M. & Takács, P. (1991). Radiographic personal identification with characteristic features in the hip joint. *American Journal of Forensic Medicine and Pathology*. Vol. 12, No. 4, p. 328-331, ISSN: 0195-7910
- Yoshino, M.; Miyasaka, S.; Sato, H. & Seta, S. (1987). Classification system of frontal sinus patterns by radiography: Its application to identification of unknown skeletal remains. *Forensic Science International*. Vol. 34, No. 4, p. 286-299, ISSN: 0379-0738
- Harris, A.M.; Wood, R.E.; Nortjé, C.J. & Thomas, C.J. (1987). The frontal sinus: Forensic fingerprint? A pilot study. *Journal of Forensic Odonto-Stomatology*. Vol. 5, No. 1, p. 9-15. ISSN: 0258-414X
- Kullman, L.; Eklund, B. & Grundin, R. (1990). Value of the frontal sinus in identification of unknown persons. *Journal of Forensic Odonto-Stomatology*. Vol. 8, No. 1, p. 3-10. ISSN: 0258-414X
- Reichs, K.J. (1993). Quantified comparison of frontal sinus patterns by means of computed tomography. *Forensic Science International*. Vol. 61, No. 2-3, p. 141-168, ISSN: 0379-0738
- Riepert, T.; Ulmcke, D.; Schweden, F. & Nafe, B. (2001). Identification of unknown dead bodies by X-ray image comparison of the skull using the X-ray simulation program FoXSIS. *Forensic Science International*. Vol. 117, No. 1-2, p. 89-98, ISSN: 0379-0738
- Tatlisumak, E.; Yilmaz Ovali, G.; Aslan, A.; Asirdizer, M.; Zeyfeoglu, Y. & Tarhan, S. (2007). Identification of unknown bodies by using CT images of frontal sinus. *Forensic Science International*. Vol. 166, No. 1, p. 42-48, ISSN: 0379-0738
- Pfaeffli, M.; Vock, P.; Dirnhofer, R.; Braun, M.; Bolliger, S.A. & Thali, M.J. (2007). Post-mortem radiological CT identification based on classical ante-mortem X-ray examinations. *Forensic Science International*. Vol. 171, No. 2-3, p. 111-117, ISSN: 0379-0738
- Blau, S.; Robertson, S. & Johnstone, M. (2008). Disaster victim identification: new applications for postmortem computed tomography. *Journal of Forensic Sciences*. Vol. 53, No. 4, p. 956-961, ISSN: 0022-1198
- Uthman, A.T.; Al-Rawi, N.H.; Al-Naaimi, A.S.; Tawfeeq, A.S. & Suhail, E.H. (2010). Evaluation of frontal sinus and skull measurements using spiral CT scanning: an aid in unknown person identification. *Forensic Science International*. Vol. 197, No. 1-3, p. 124e1-124e7, ISSN: 0379-0738
- Quatrehomme, G.; Fronty, P.; Sapanet, M.; Gre´vin, G.; Baillet, P. & Ollier, A. (1996). Identification by frontal sinus pattern in forensic anthropology. *Forensic Science International*. Vol. 83, No. 2, p. 147-153, ISSN: 0379-0738
- Kirk, N.J.; Wood, R.E. & Goldstein, M. (2002). Skeletal identification using the frontal sinus region: A retrospective study of 39 cases. *Journal of Forensic Sciences*. Vol. 47, No. 2, p. 318-323, ISSN: 0022-1198

- Miller, A.J. & Amedee, R.G. (1998). Sinus anatomy and function. In: *Head and Neck Surgery-Otolaryngology, 5th edition*, (Eds., B.J. Bailey & K.H. Calhoun), pp. 457-461, Lippincott-Raven, ISBN: 0-78175-561-1 Philadelphia-USA
- Porowski, L.; Skórzewska, A.; Radziemski, A. & Szpakowska-Rzyska, I. (1999). Development of frontal sinus in human fetuses as seen in computerized tomography. *Folia Morphologica*. Vol. 58, No. 3, p. 215-221, ISSN: 0015-5659
- Tatlisumak, E.; Ovali, G.Y.; Asirdizer, M.; Aslan, A.; Ozyurt, B.; Bayindir, P. & Tarhan, S. (2008). CT study on morphometry of frontal sinus. *Clinical Anatomy*. Vol. 21, No. 4, p. 287-293, ISSN: 0897-3806
- McLaughlin, R.B. Jr.; Rehl, R.M. & Lanza, D.C. (2001). Clinically relevant frontal sinus anatomy and physiology. *Otolaryngologic Clinics of North America*. Vol. 34, No. 1, p. 1-22, ISSN: 0030-6665
- Clemente, M.P. (2004). Surgical anatomy of paranasal sinus, In: *Sinus Surgery: Endoscopic and Microscopic Approaches, 1st edition*, (Eds., H.L. Levine & M.P. Clemente), pp. 1-56, Thieme Medical Publisher, ISBN: 0-86577-972-3, New York-USA.
- Wang, M.B. & Berke, G.S. (1998). Paranasal sinus endoscopy, In: *Endoscopy of the Central and Peripheral Nervous System*, (Eds., W.A. King; J.G. Frazee & A.A.F. De Salles), pp. 147-154, Thieme Medical Publisher, ISBN: 0-86577-690-3, New York-USA.
- Qian, W.; Makitie, A.A.; Witterick, I. & Haight, J.S. (2005). A comparison between nitric oxide output in the nose and sinuses: A pilot study in one volunteer. *Acta Otolaryngologica*. Vol. 125, No. 10, p. 1080-1085, ISSN: 0001-6489
- Christensen, A.M. (2005). Assessing the variation in individual frontal sinus outlines. *American Journal of Physical Anthropology*. Vol. 127, No. 3, pp. 291-295, ISSN: 1096-8644
- Cox, M; Malcolm, M. ; Fairgrieve, S.I. (2009). A new digital method for the objective comparison of frontal sinuses for identification. *Journal of Forensic Sciences*. Vol. 54, No. 4, p. 761-772, ISSN: 0022-1198
- Marlin, D.C.; Clark, M.A.; Standish, S. M. (1991). Identification of human remains by comparison of frontal sinus radiographs: a series of four cases. *Journal of Forensic Sciences*. Vol. 36, No. 6, p. 1765-1772, ISSN: 0022-1198
- Nambiar, P.; Naidu, M.D. ; Subramaniam, K. (1999). Anatomical variability of the frontal sinuses and their application in forensic identification. *Clinical Anatomy*. Vol. 12, No. 1, p. 16-19, ISSN: 0897-3806
- Fairgrieve, S.I. (2008). *Forensic cremation: recovery and analysis*. CRC Press, ISBN: 0-84939-189-X, Boca Roton
- Ribeiro Fde A. (2000). Standardized measurements of radiographic films of the frontal sinuses: an aid to identifying unknown persons. *Ear, Nose and Throat Journal*. Vol. 79, No. 1, pp. 26-33, ISSN: 0145-5613
- Tang, J.P.; Hu, D.Y.; Jiang, F.H.; Yu, X.J. (2009). Assessing forensic applications of the frontal sinus in a Chinese Han population. *Forensic Science International*. Vol. 183, No. 1-2, p. 104e1-104e3, ISSN: 0379-0738
- Haglund, W.D.; Fligner, C.L. (1993). Confirmation of human identification using computerized tomography (CT). *Journal of Forensic Sciences*. Vol. 38, No. 3, p. 708-712, ISSN: 0022-1198

- Jackowski, C.; Wyss, M., Persson, A.; Classens, M.; Thali, M.J. & Lussi, A. (2008). Ultra-high-resolution dual-source CT for forensic dental visualization-discrimination of ceramic and composite fillings. *International Journal of Legal Medicine*. Vol. 122, No. 43, p. 301-307, ISSN: 0937-9827
- Smith, D.R; Limbird, K.G. & Hoffman, J.M. (2002). Identification of human skeletal remains by comparison of bony details of the cranium using computerized tomographic (CT) scans. *Journal of Forensic Sciences*. Vol. 47, No. 5, p. 1-3, ISSN: 0022-1198



Theory and Applications of CT Imaging and Analysis

Edited by Prof. Noriyasu Homma

ISBN 978-953-307-234-0

Hard cover, 290 pages

Publisher InTech

Published online 04, April, 2011

Published in print edition April, 2011

The x-ray computed tomography (CT) is well known as a useful imaging method and thus CT images have continually been used for many applications, especially in medical fields. This book discloses recent advances and new ideas in theories and applications for CT imaging and its analysis. The 16 chapters selected in this book cover not only the major topics of CT imaging and analysis in medical fields, but also some advanced applications for forensic and industrial purposes. These chapters propose state-of-the-art approaches and cutting-edge research results.

How to reference

In order to correctly reference this scholarly work, feel free to copy and paste the following:

Ertugrul Tatlisumak, Mahmut Asirdizer and Mehmet Sunay Yavuz (2011). Usability of CT Images of Frontal Sinus in Forensic Personal Identification, Theory and Applications of CT Imaging and Analysis, Prof. Noriyasu Homma (Ed.), ISBN: 978-953-307-234-0, InTech, Available from: <http://www.intechopen.com/books/theory-and-applications-of-ct-imaging-and-analysis/usability-of-ct-images-of-frontal-sinus-in-forensic-personal-identification>

INTECH
open science | open minds

InTech Europe

University Campus STeP Ri
Slavka Krautzeka 83/A
51000 Rijeka, Croatia
Phone: +385 (51) 770 447
Fax: +385 (51) 686 166
www.intechopen.com

InTech China

Unit 405, Office Block, Hotel Equatorial Shanghai
No.65, Yan An Road (West), Shanghai, 200040, China
中国上海市延安西路65号上海国际贵都大饭店办公楼405单元
Phone: +86-21-62489820
Fax: +86-21-62489821

© 2011 The Author(s). Licensee IntechOpen. This chapter is distributed under the terms of the [Creative Commons Attribution-NonCommercial-ShareAlike-3.0 License](https://creativecommons.org/licenses/by-nc-sa/3.0/), which permits use, distribution and reproduction for non-commercial purposes, provided the original is properly cited and derivative works building on this content are distributed under the same license.

IntechOpen

IntechOpen