

# We are IntechOpen, the world's leading publisher of Open Access books Built by scientists, for scientists

6,900

Open access books available

186,000

International authors and editors

200M

Downloads

Our authors are among the

154

Countries delivered to

TOP 1%

most cited scientists

12.2%

Contributors from top 500 universities



WEB OF SCIENCE™

Selection of our books indexed in the Book Citation Index  
in Web of Science™ Core Collection (BKCI)

Interested in publishing with us?  
Contact [book.department@intechopen.com](mailto:book.department@intechopen.com)

Numbers displayed above are based on latest data collected.  
For more information visit [www.intechopen.com](http://www.intechopen.com)



## Telemedicine in Dentistry (Teledentistry)

Branko Mihailovic<sup>1</sup>, Milan Miladinovic<sup>1</sup> and Biljana Vujicic<sup>2</sup>

<sup>1</sup>*University of Pristina, Mitrovica*

<sup>2</sup>*University of Nis  
Serbia*

### 1. Introduction

As expected, technologic innovations in the field of dentistry have been extensive in recent years. Most important advances have been made in the use of computers, telecommunication technology, digital diagnostic imaging services, devices and software for analysis and follow-up. Nowadays, it is hard to imagine a dentistry clinic without computerized patient registry, electronic invoicing, digital radiography, intraoral cameras, digital cameras, and better equipped centres have 3D computerized systems for prosthetic dental reconstruction, and 3D cone beam computerized tomography systems for precise intratissue imaging, measurements, and navigation in operative oral and maxillofacial surgery. There are also lots of other high-quality computer systems used.

What was considered relatively distant future some twenty years ago, today is the reality in dental clinics. Using most advanced information technology, the science of dentistry crosses much longer distances than it was ever able in the preceding twenty centuries. i.e. the beginning of the new era. New information technology not only improve the quality of management of dental patients, but also makes possible their partial or complete management at distances of thousands of kilometres away from health care centres or qualified dentists (Kopycka-Kedzierawski & Billings, 2006). However, the primary purpose of these intelligent systems is adequate diagnosis, since the natural disease course has changed (Jevtović, 2008).

These systems would not mean a lot without telecommunication assisting the process and sending information almost instantly to interested parties within an institution and all over the world. Networking, sharing digital dentistry information, distant consultations, workup and analysis is dealt with by a segment of the science of telemedicine concerned with dentistry: **teledentistry**.

The beginnings of teledentistry can be roughly traced back to the beginnings of telemedicine, but more specific the birth of teledentistry as a subspecialist field of telemedicine could be linked to 1994 and a military project of the United States Army (U.S. Army's Total Dental Access Project), aiming to improve patient care, dental education, and effectuation of the communication between dentists and dental laboratories. Teledentistry demonstrated that dental professionals can consult each other even at large distances. This military project demonstrated that teledentistry was able to reduce total patient care costs, extending dental care to distant and rural areas and offering complete information required for deeper analyses (Rocca et al., 2004; Duka et al., 2009).

A system of teledentistry further enables dentists to share patient information, radiographs, graphical representations of periodontal and hard tissues, therapies applied, lab results, tests, remarks, photographs, and other information transportable through multiple providers. This data sharing can be of an extreme importance for patients, especially those in need of specialist consultation, and co-operation of dentists facilitates and improves clinical decision-making (Sanhez et al., 2004).

Though the research in telemedicine systems in medicine has advanced a lot, being always emphasized and widely present, research in teledentistry, a science dealing with use of telemedicine in dentistry, has been markedly neglected. The search of MEDLINE, the largest base of medical information, produces only 42 publications if the searched word is „teledentistry“, out of which approximately half are descriptive, review papers (PubMed, 2010). With the availability of high quality education, appropriate telecommunication technologies, and computerized systems, we have been increasingly able to scientifically examine and prove the results of diagnosis and treatment done at large distances, as well as to observe possible faults and areas in which they tend to occur.

## 2. Internet as the basis of teledentistry

Internet is the basis of modern systems of teledentistry, being up-to-date and fast, and able to transport large amounts of data. Almost all new systems of teledentistry are Internet-based (*fixed* and *mobile*), as well as all kinds of distant consultation (*Real Time, Store and Forward*, but *Late* as well). As the result of all the qualitative and quantitative characteristics of Internet, all other Internet-independent forms of telecommunication are thought to be of secondary importance.

There are numerous reasons why Internet-based teledentistry has taken precedence over other ways of communication:

- speed,
- low cost,
- efficacy,
- documented consultation,
- minimized occupancy,
- simultaneous communication of multiple participants,
- asynchronism,

while potential shortcomings are:

- necessity of appropriate training,
- pressure for an instant response,
- impression,
- message misunderstanding,
- privacy concerns,
- possibility to overlook/neglect the message.

It is clear that Internet offers the highest speeds in sending documents or accessing desired information. If international teledentistry is concerned, Internet is the oasis of speed with minimal associated costs, being indispensable in peer-to-peer and dentist-patient communication. Cheap and rapid transfer of digital documents, images, radiographs, laboratory assays is unrivalled both nationally and locally. Using on-line communication, dental patients can be instantly advised or referred to other available Internet resources,

with additional information about the necessary procedures in their further management (Jadad et al., 2000).

Asynchronous communication and web pages are often an ideal choice both for patients and their dentists. For instance, an oral surgeon postoperatively advises his patients about the procedures and actions necessary for a successful postoperative course. The instruction can take a printed A4 page form, containing the information such as „do not wash out the mouth and wound during the first day“, „on the second day use a specific solution to wash out the mouth“, „do not take hot food“, „do not use pain killers with anticoagulant properties“, etc. These instructions may be written, but it is often the case that patients forget orally given advice or lose their written instructions. In such cases, 24 hours teledentistry access of www pages with detailed relevant instructions can be of huge practical importance, especially because of the fact that their scope does not need to be limited.

More and more used every day, the forms of teledentistry consultations popular with students and young dentists, are „e-learning“, Internet-based instructions, on-line libraries, search tools, computer-based student-professor interactions, with students in fact subjecting themselves a large portion of their academic life to living on-line. In that regard, information and communication technologies used in conjunction with Internet have become a central part of academic life in colleges and campuses in many developed countries (Jones et al., 2008). Internet-based teledentistry education enables students to choose themselves the place, time, and mode of learning. It is invaluable especially for students outside university centres. There are numerous message boards where students can post their questions. The availability of free-of-charge and necessary on-line journals adjusted for undergraduates should be mentioned too. In postgraduate and continued professional education, modern telecommunication systems offer on-line video-conferencing, broadcasting operations and treatments, and on-line training courses (Reynolds & Mason, 2002).

### 3. Computerized dentistry

Massive use of computers and informatics in dentistry practice has produced the requirement of processing and understanding of huge amounts of digital data. Since these processes cannot always be performed at the place of data entry, computerized dentistry requires the methods of telemedical data transport and expert consideration of obtained data. Digital data, relying on telemedical methods, are convenient for both interhuman and intermachine data exchange and processing, leading to improved patient care in dentistry, better research, education, and management.

Computerization in dentistry begins with use of software to manage the clinic, electronic patient histories, appointment scheduling, through non-invasive and invasive diagnostic systems, problem-solving softwares, computerized prediction of complex color patterns, consideration of esthetic requirements, planning of osteotomy routes and use in other radical maxillofacial and oral surgery interventions and other applications, all the way to support in the processes of intelligent decision-making and research.

If we imagine these applied elements of computerized dentistry as cars, the methods of telemedicine would be the roads to drive on.

The main classification of computerized systems in dentistry (Schleyer & Spallek, 2001), relying on telemedical methods, would be as follows.

COMPUTERIZED METHOD	DESCRIPTION	TELEMEDICAL METHOD
OralCDx	System for imaging oral lesions, brush biopsies, and computerized analysis of histologic slides.	Telemedical consultation with pathologists to confirm the diagnosis. Distant access to slides by clinicians and therapists.
Digital radiology	Equivalent to traditional x-ray, but with lower level of radiation of both patients and staff. Exceptional image quality, 2D and 3D computerized reconstruction and immediate measurements of anatomic structures.	Telemedical transfer of files from x-ray centre to dentistry clinic, distant consultations of doctors and specialists, and distant planning of dentistry interventions and reconstructions.
Decision support systems	Support to dental clinicians in making proper decisions and choice of adequate therapy. Especially important for complex or rare cases, and in differential diagnosis.	Case reporting through Internet to the provider of support system for decision-making, and downloading of received file with suggestions for diagnosis and treatment of the case.
CAD/CAM systems	Computer-guided machines for the production of prosthetic restorations (crowns, bridges, onlays and inlays).	Distant support in designing the shape of dental prosthetic restoration and in determining interjaw relationships. Sending of digital models in the lab for the production of restoration.
Dental practice management	Automation of many routine activities in dentistry clinics, running of electronic patient histories and support in general management of the clinic.	Distant appointments, provisional review of the situation to be resolved, exchange of information with health insurance companies.
Educational resources	Educational interactive softwares, mechanical media or on-line resources in learning the manifestations of dental pathology, therapy, and practical use of critical knowledge and thinking.	On-line accessible integrated educational courses, certificateas, and titles for students and post-graduates, or acquirement of new and updated knowledge by present professionals and specialists.
Computerized research	Analysis of large amounts of data to generate new knowledge, complex analysis of data obtained with research.	Telemedical infrastructure facilitates the work of research teams in different geographic locations.

Table 1. Foundation of computerized dentistry systems on telemedical technology.

### 3. Telemedicine in oral and maxillofacial surgery

Use of new technologies in dental surgery provided better diagnosis, situational analysis, and planning of appropriate treatment solutions. Technologic development has been at its highest level in computerized support in dental implants placement, where it is possible to observe the patient in one part of the world, and in the other part make a digital project of complete implant and prosthetic construction and route the direction for navigational technique of dental implantation. One of the first cases was scientifically presented by the Karl Landsteiner Institute for Biotelematics, Vienna (Schicho & Ewers, 2008), consisting of a specially devised telenavigation server and telenavigation clients.

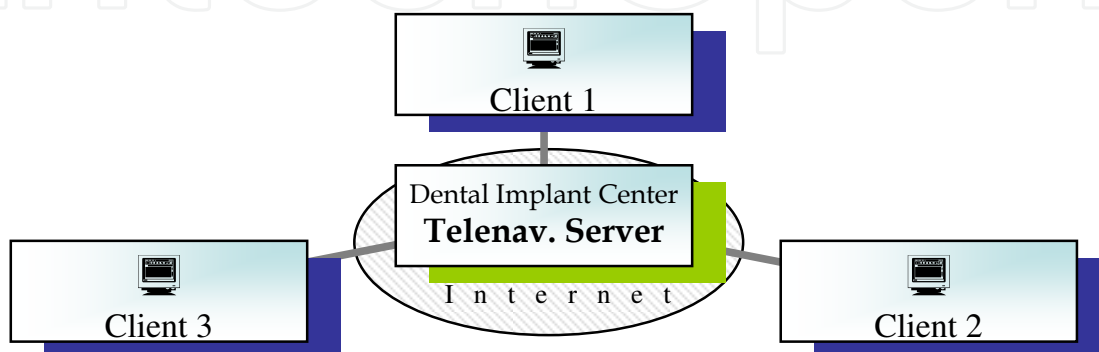


Fig. 1. Scheme of teleimplant distribution of information via Internet

Generally, the procedure of teleimplantologic consultation is as follows: at the site of surgical dental implantation, it is first necessary to obtain CBCT image and 3D computerized jaw reconstruction. DICOM files are then transferred to the main server for storage, enabling multiple downloading of the files for review or intervention planning. Dentists, distant teleconsultants, then download the files, perform the requested actions such as software planning of the position, size, and shape of dental implants. If necessary, based on the digital placement scheme, a template for the implantation process is made, leading surgical drill in the jaw area, and navigation markers are positioned, enabling intraoperative navigation of surgical instruments during surgery itself. At the end, teleconsultants post the amended files to the server, and operators are then ready to begin the process of dental implantation (Mihailovic, 2009).

During the intervention, telenavigation server is able to send information to a large number of telenavigation clients, with live data on the surgical process of dental implantation. Teleconsultants are able to watch the intervention, giving advice to operators if necessary, or present the procedure further to other distant colleagues. During the operation, each computer client functions as an independent navigation system, and each user is therefore able to choose 2D or 3D view or section plane. In essence, users actively participate in the operation, without any negative impact on computer performance or navigation system in the surgical room (Schicho & Ewers, 2008).

Some very good telemedical results have been achieved in one of the principal areas of oral surgery, impacted wisdom teeth. Impacted third molars take up a high percentage of oral surgery pathology, both in incidence and the consequences they produce. Clinical picture of impacted third molars may markedly vary, from scarce and asymptomatic, to very difficult, associated with dramatic, life-threatening complications (Mihailovic, 2006).

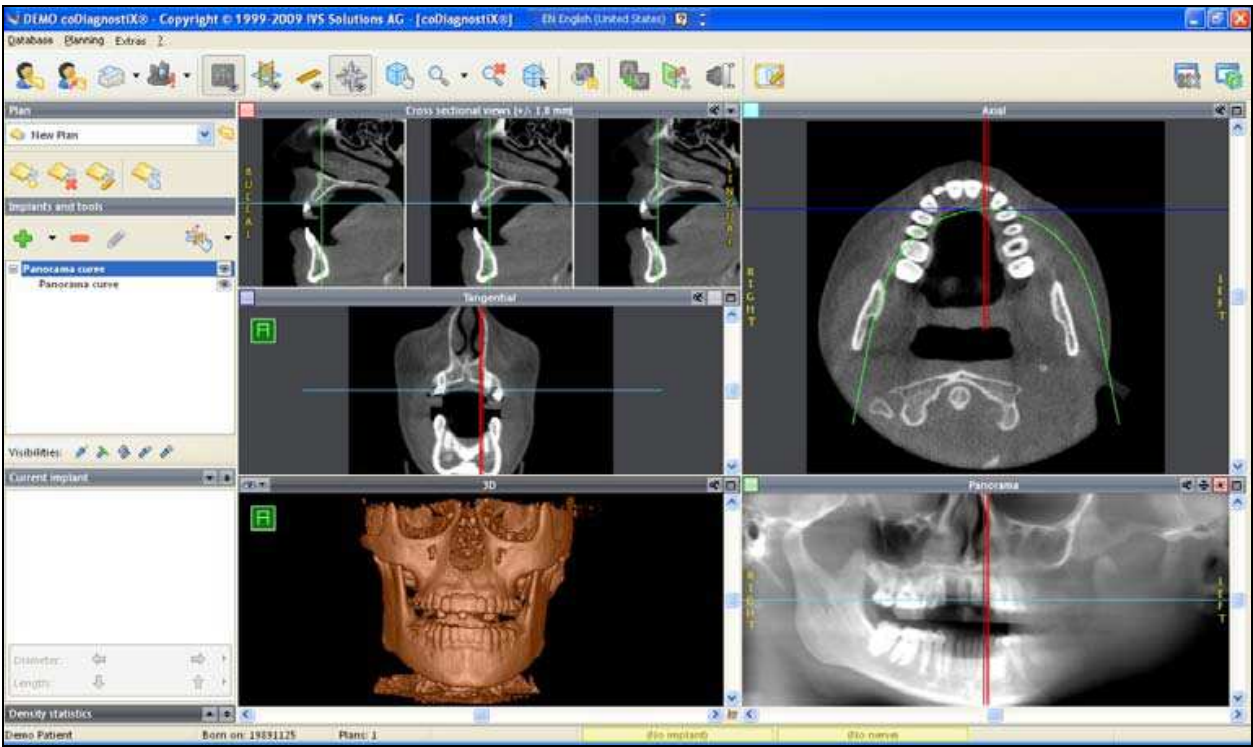


Fig. 2. Distant computer analysis and design of the whole project of surgical-prosthetic reconstruction with dental implants. The screen of software for dental implant planning and other oral surgery interventions is shown in the figure: coDiagnostiX, IVS Solutions AG, Germany.

A very common practical problem is differential diagnosis by dentists or doctors who are not specialists of oral surgery that the cause of patient's complaints is an impacted or half impacted third molar. Then, an appropriate treatment should be established in the form of extraction, some minor surgery or conservative treatment. As the presence of oral surgeons outside large centres is very limited, the availability of high quality telemedical consultation is essential. It has been documented by a study that telemedical examination does not differ from clinical examination of the dentists of this specialty (Duka et al., 2009).

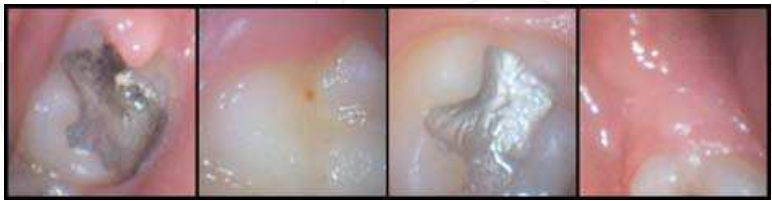

Fig. 3. Photographs of the region of all four third molars with intraoral camera, as the key element of telemedical oral surgery consultations

A proven procedure should be described. In regular orthopantomographic jaw imaging or after the suspicion of a dentist of possible consequences of some other form of impaction or retention of the third molar, 2D digital orthopan image is translated into a binary record on HDD as a JPEG file of minimal size, 998 x 494 pixels, and 83 pixels per inch with 24-bit RGB color palette. Facial and bilateral en face photographs of the patient are taken with digital camera, as well as photographs of intraoral structures and teeth of both jaws, using the technique of dental photographing.

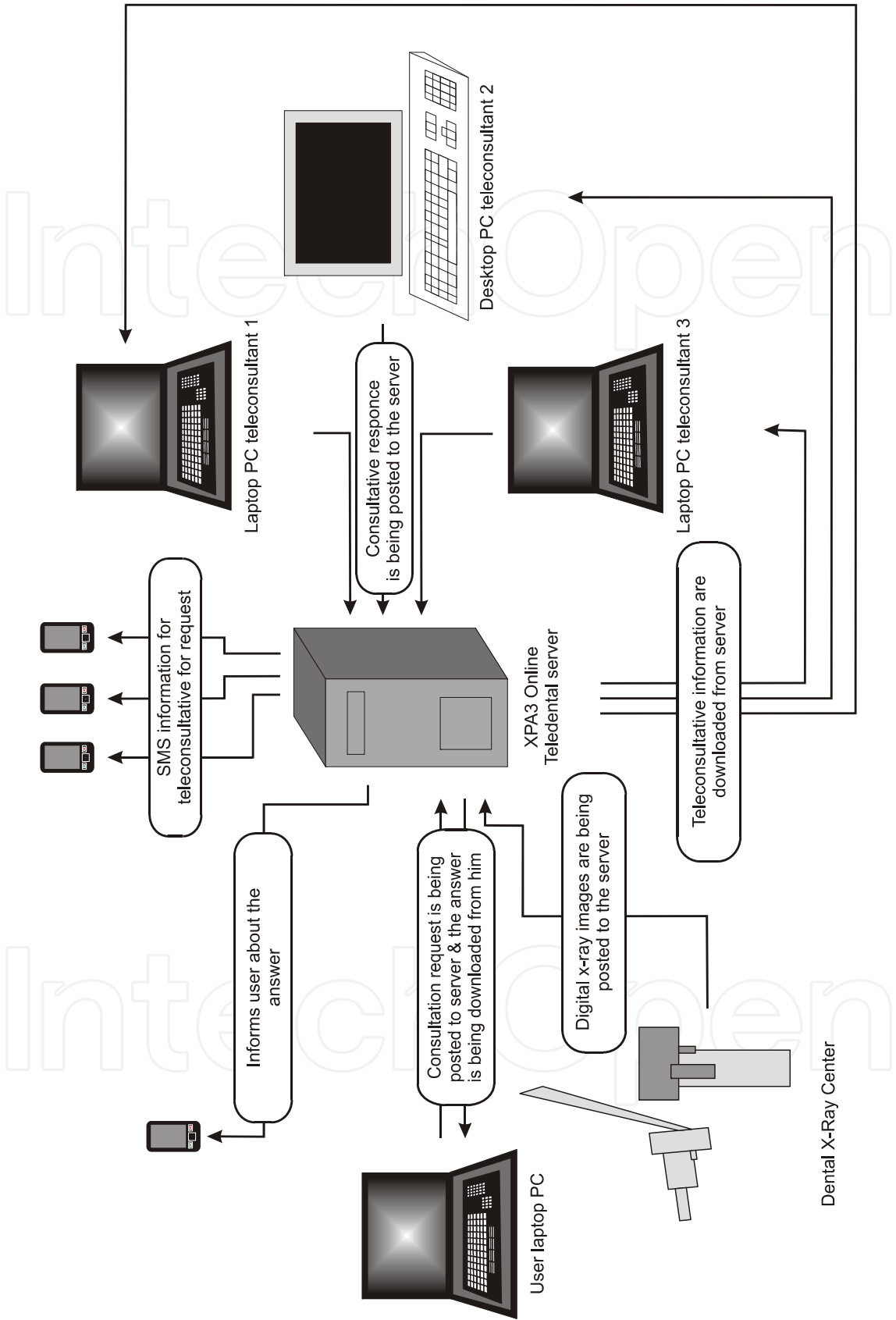


Fig. 4. Scheme of telemedical transfer of information in oral surgery – *Store-and-Forward* technology.

Digital photographs are stored in JPEG format of minimally 2592 x 1944 pixels and 300 pixels per inch resolution, with 24 bit RGB color palette. Then, using intraoral camera, photographs of all four third molar areas are taken, with images having the following minimal characteristics: 640 x 480 dimensions, 72 pixels per inch resolution, and 24-bit RGB color palette. Each patient therefore has one digital orthopan radiogram, frontal facial image, intraoral photograph of both upper and lower jaws, as well as four images of third molar areas obtained with intraoral camera. All these data are uploaded on the Internet server, with specially developed application with user interface for direct uploading of personal patient information, uploading of accompanying images, patient history and questions related to the areas of possible impacted molars. Authorization and used authenticity check are done before being allowed to access the application, and server access is secured using minimally the SSL (Secure Sockets Layer) cryptography protocol. With the SMS sending system oral surgeons are informed about the received requests for distant consultation. Teleconsultants access the server via computers or smartphones, and based on the available information give their opinion, including diagnosis and treatment recommendation. In some cases, there are requests for additional information. In this way, using teledentistry methods, the problems related to the growth, position, and status of the third molars can be assessed equally well as in real time. Based on the obtained information, a plan of oral surgical management can be devised in the sense of treatment or extraction (Duka et al., 2009).

The advances and availability of smartphone technology have contributed to the feasibility and availability of telemedicine in oral and maxillofacial surgery. Smartphones are able to read and display 3D computer reconstructions of head skeleton, giving instantly the necessary information to distant teleconsultants in oral and maxillofacial surgery. Even on the move, they are able to record the consultation and send an answer. It is very useful in emergency conditions requiring immediate interdisciplinary consultation. Maxillofacial surgeons are thus able to monitor the condition of their patients even after very complex interventions, such as osteotomies, removal of ameloblastic fibromas, and so on (Aziz & Ziccardi, 2009).

#### 4. Telemedicine in orthodontics

Clinical orthodontics advanced the most in routine use of computerized technology, and the presence of distant assistance in everyday work cannot be compared to any other area of dentistry. The matter is, above all, about the fact that instead of traditionally used study casts present orthodontics makes use of digital 2D and 3D models and all specialist analyses, measurements, and assessment of relationships are done using software to process the images (Mladenović et al., 2009). Orthodontic specialists, after taking dental impressions of the jaws, instead of casting jaw models in plaster, send the impressions by special postal service to specialized companies for 3D digitization of working models; then they create digital 3D models using patent-protected systems for 3D scanning and digitization, form a computer file, and return it via Internet to the therapist. The therapist share this digital model of the jaws with others via network, effectuating necessary consultations with his colleagues. Peer teleconsultants, if required, may also participate from a distance in the creation of a plan and program of orthodontic management, using digital patient model (Mihailovic et al., 2009). The two most renown computerized digitization systems are OrthoCad i eModels.

We should describe the functioning of this method of telemedicine. An orthodontic specialist takes impressions in hydrocolloid alginate and bite impression using polyvinyl siloxane, wax, or compatible materials. The impressions and bite are then sent to the OrthoCAD™ company by post. There, casts are made from the impressions, being after that scanned with special methods of 3D digitization. Upper and lower jaw models are articulated using the bite impression. Few days after being contacted, OrthoCAD™ uploads on its Internet servers the electronic file containing digital study model. The orthodontist is informed, and he downloads the file from the Internet and analyzes it with special 2D and 3D orthodontic softwares. Such a teleorthodontic system offers numerous benefits in the practice and markedly reduces processing and model storage costs (Okunami et al., 2007; Peluso et al., 2004).

In the age of intense development of mobile communications, telemedicine in orthodontics has one more simple and, above all, practical use. Patients get distant consultations and help in everyday problem with orthodontic devices. A specialist in orthodontics is able to offer appropriate expert support if rubber bands fall off the braces, in cases of discomfort wearing braces, and in assessment of the solution if irritations occur, without the need for patient visits to the clinic (Favero et al., 2009). Patients are able to take photos of the areas of their mouth and the devices producing complaints with high resolution digital cameras, and to send the photographs to their orthodontist in order to get proper advice. Such a solution is especially attractive to younger patients (most common orthodontic patients).

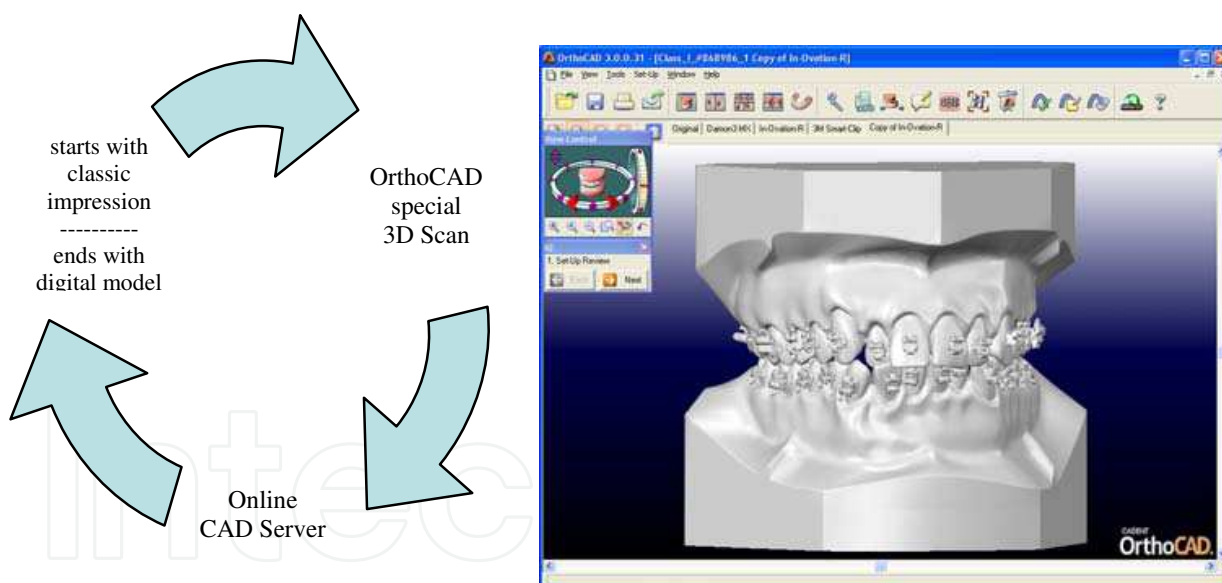


Fig. 5. OrthoCAD system for distant 3D digitization and easy analysis of digital models

Orthodontics is able to successfully help in the management of children with special needs. Travelling-associated problems constitute an aggravating factor in such cases, and distant management is the approach of choice whenever possible. In spite of the presence of some insuperable limitations, orthodontic treatment monitored from a distance via teledentistry systems (intraoral cameras, digital cameras, transfer of digital radiographs, video-conferencing approach) has still been very promising in the management of occlusions in these children (Berndt et al., 2008).

5. Telemedicine in endodontics

Any faults in differential diagnosis and prognosis of treatment of periapical lesions can be the source of subsequent complications, problems, additional waste of time and money, sometimes being the cause of complete revisions of prosthetic restorations based on poorly treated teeth. Periapical lesions constitute a large portion of dental pathology and their treatment is commonly performed by dentists who are not specialists in endodontics. Modern telemedical systems are an ideal solution for seeking and obtaining timely expert help in that regard. Zivkovic et al. have practically demonstrated that with the use of teledentistry methods based on Internet, diagnosis of periapical lesions can be adequately assessed; based on that, a necessary plan can be devised for a proper endodontic or oral surgical management of these lesions. Teledentistry based on Internet as a medium for distant communication enables its use worldwide, wherever the world wide web is present as a wire or wireless connection, reducing the costs of management and increasing the availability of urgent help to all patients (Zivkovic et al., 2010).

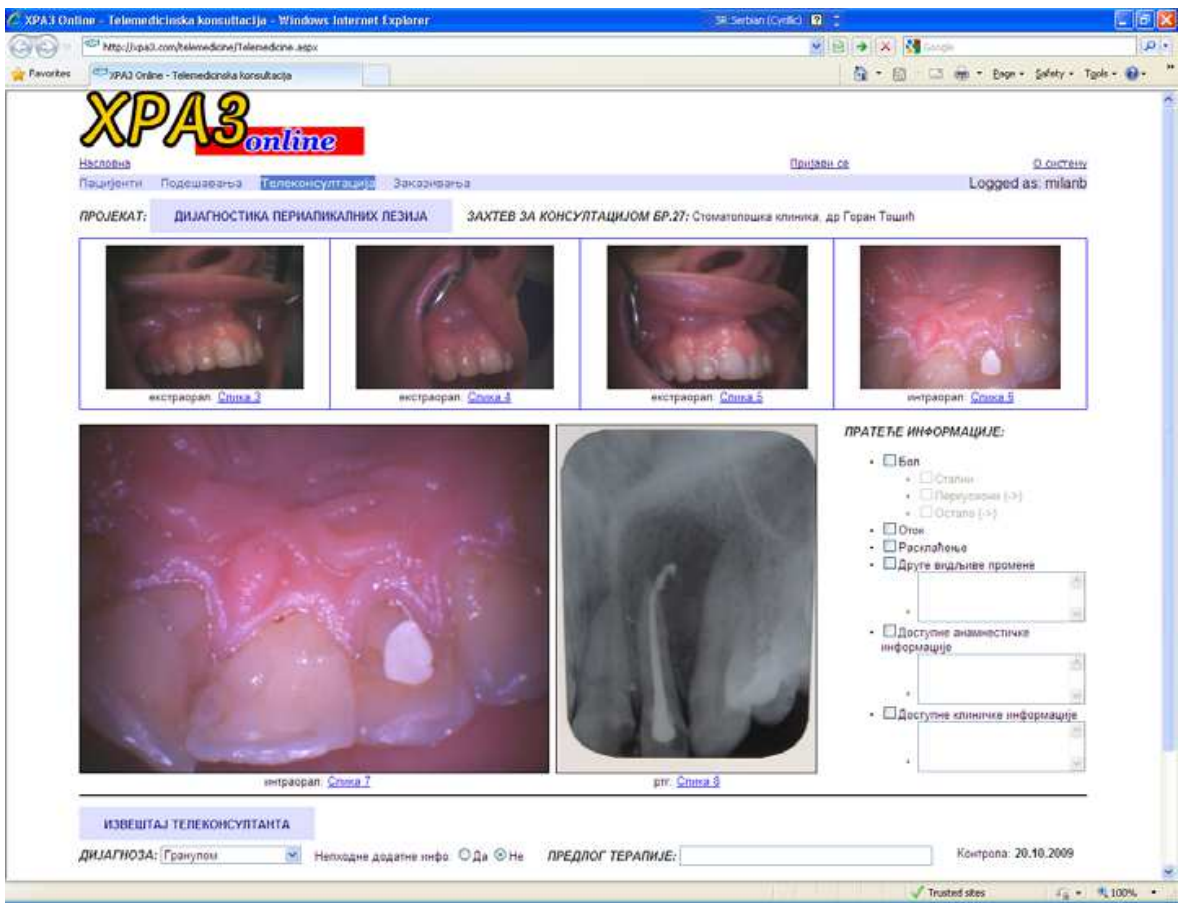


Fig. 6. Telemedical online server XPA3 Online, Serbia, distant help in cases of periapical lesions

- The method is based on the creation of digital information for each of the teeth of interest:
- sequence of digital extraoral photographs (frontal and bilateral),
  - sequence of digital intraoral photographs (vestibular portion of the alveolar ridge in the area at the level of tooth root, palatal/lingual portion of the alveolar ridge of the target tooth, and dental crown),

- retroalveolar dental digital x-ray,
- anamnestic information in the format of text.

Using mobile Internet connection, photographs and text are uploaded to an on-line server. Distant consultants, specialist in endodontics, are informed via their mobile phones about the received request, after which they download the digital images and accompanying anamnestic data. They establish the diagnosis and suggest a treatment, then post these information on an on-line server, which informs the consultation-requester dentist about the received response.

Baker et al. have also demonstrated that there is no statistically significant difference in the interpretation of periapical lesions between the images viewed locally (using a viewbox) and images transmitted via a video-conferencing system and viewed on monitor screen (Baker et al., 2000).

## 6. Telemedicine in pediatric and preventive dentistry

Prevention and early detection of caries are the key factors in the suppression of this mass disease of etiologically insufficiently known nature. In that sense, in children and young people regular dental systematic check-ups are performed, and in adults regular control examinations. Telemedicine is here too a method of choice in many situations where direct clinical inspections are not possible. Amável et al. have demonstrated in real conditions that distant diagnosis of pediatric dental problems, based on non-invasive imaging, is a valid grounding for an appropriate insight into dental problems and dental treatment preparation (Amável et al., 2009). Kopycka-Kedzierawski et al. have successfully performed the study of prevalence of dental caries in children using the telemedicine method and dental photographs taken with intraoral cameras and web-based storage of images (Kopycka-Kedzierawski et al., 2008). These authors, in their study evaluating a telemedical system of distant systematic dental check-up in children, using again the transmission of digital images taken with intraoral cameras in the children mouths, have been able to get a complete insight into the status of teeth of these children, with special emphasis on early dental caries (Kopycka-Kedzierawski et al., 2007). The success with these teledentistry systems largely depends on the quality of intraoral cameras. An intraoral camera should be adequately shaped to be easily placed in any place of interest and take dental photographs from any available angle; in addition, sufficiently strong and focused illumination from the camera itself is required, as well as optical or software reduction of light reflected from the smooth surface of the teeth. Together with high resolution, the obtained digital image is able to demonstrate initial caries stages or enamel and dentine pigmentations. In addition to its basic role in providing dental screening in distant, rural, and other inaccessible areas, the method of teledentistry has been demonstrated as a high quality alternative in children afraid of dentists, reducing their fear and anxiety compared to clinical examination in real time.

## 7. Telemedicine in oral medicine

Even beyond general indications for telemedical approach in clinical setting and with the presence of specialists, the significant need for adequate consultation with a colleague of the same or different specialty may exist. Practical examples can always be found in oral medicine and dermatology (as its closest medical specialty). When histopathologic sampling

is not possible or when it can result in impaired esthetics and function, one of the principal steps is intercollegial (peer) consultation. Telemedicine, based on high resolution images and a broad spectrum of colors (32-bit or more), is able to provide high quality consultation even with the colleagues at a distance of several hundreds of kilometers (between two or several experts at a time) (Janković, 2007).

Torres-Pereira et al. have shown an effective distant access to oral lesions and benefits of use of e-mail services and a Store-And-Forward image system. Oral lesions are electronically photographed using a 50 mm macro lens and circular illumination system, and clinical and anamnestic data are stored in a textual file with minimal resolution of 600 dpi. The files are appropriately renamed according to the patients' identification numbers in order to avoid confounding and identity errors. Specialist of oral medicine then analyze independently the obtained images and clinical information. They make the diagnosis (usually one or two) and electronically return the results (Torres-Pereira et al., 2008). The approach such as this is able to produce good results, which could be further improved with the use of a comprehensive electronic patient history, containing the complete history of all current and past diseases, medications taken, diagnostic and therapeutic procedures, and recorded all other factors of influence on the status of currently assessed lesion.

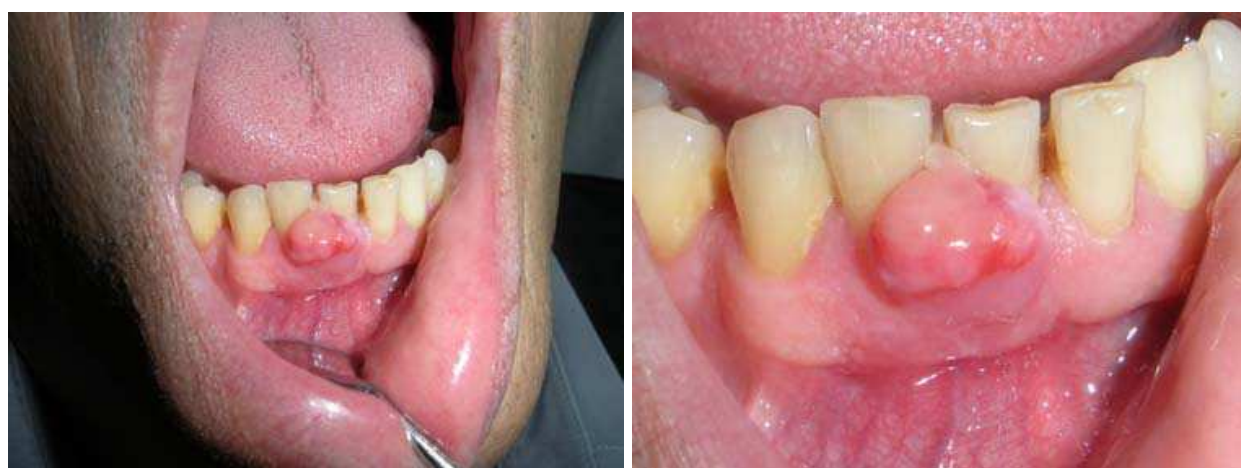

Fig. 7. Achieved teleconsultant diagnostic agreement for the Dg. Giant cell epulis (K06.8) and treatment agreement: surgical removal.

## 8. Telemedicine in dental prosthetics

CAD/CAM (computer-aided design and computer-aided manufacturing) systems are gaining precedence in the manufacturing of individual dental crowns, dental inlays and onlays, over traditional hand modelling and casting of prosthetic reconstructions. Modern computerized systems are capable of manufacturing even the bridges of up to three units, with satisfactory medical characteristics. The process of manufacture of these dental structures is based on 3D imaging of the status after tooth-carrier preparation with intraoral camera using the active triangular principle. Then, CAD projection of tooth restoration is then performed, and if inlay or onlay is to be done, the software is capable of automation of a large part of the job; however, if crowns are to be done, greater participation of the user (computer operator) is required. Since there are dentists and dental technicians who are not very skillful doing this somewhat complicated process of designing shapes and interjaw relationships using CAD softwares, the usual practice is to request teledentistry help of

computerized dentistry specialists. The resulting project file is encrypted and sent by e-mail to a teleconsultant for model analysis, projection of the shape of restoration, of its height and interjaw relationships using a virtual articulator; the completed project is then encrypted and returned to the clinic, usually by e-mail (Späth & Kordass, 2006; Hartung & Kordass, 2006). The clinic put the CAM system into motion, which in a short time produces dental restoration using the project file, and submit it to the patient.

Some dental companies offer the service of 3D scanning of already cast and posted model obtained from the impression of the teeth prepared by the dentist. These are large, specific, and patented systems for 3D digitization, in which the errors with approximate imaging (as with 3D intraoral cameras) are excluded, but require destruction of the plaster model in the process. On the obtained 3D digital model the company produces the restoration design, tests for digital interjaw and interdental relationships, and the completed project is made accessible to the requesting dentist or technician on the company web server. After distant receipt of the project, the dentist is able to precisely cut out the restoration using his CAM system (Mihailovic et al., 2009).

In addition to its vital role in the CAD/CAM systems, telemedicine is often used in the practice of dental prosthetics in the examination of patients in order to obtain general information about the choice of prosthetic solution and gross costs of the job. Patient in search for high quality and/or cheaper dentists often use google.com and after finding the clinics send to them their request for additional information and digital photographs of the mouth and/or 2D orthopantomograms of the jaws. In practice, dentists usually state that assessments that could be made based on such information are satisfactory and usable. Though this type of communication is fairly common, we have not been able to find the studies to confirm the quality of such consultations.

## **9. Systems for the storage of dental data, their analysis, and *Evidence Based Dentistry***

Dental institutions are nowadays extensively using computer systems to register their patients, diagnoses, and treatments. These systems are divided into two basic groups related to the type of data storage and sharing:

- Central
- Local

Central systems are still scarcely present, although they represent the choice for the future. Being continually Internet-based and serving a large number of dentists and dental hygienists, they are able to offer the best performance in the collection, triage, analysis, and timely information of distant users in almost every aspect of dental disease and treatment, using the potentials of modern telemedicine.

Local systems are represented by smaller computer networks or individual computers present in dental clinics and institutions, without planned data sharing with other users. These systems are abundantly present. There are potentials for scientific research of information from electronic patient histories within Evidence Based Dentistry, then for statistical analysis of large datasets and possible discovery of interesting patterns from them. The new challenge appeared of distant access for research purposes to the data stored locally, but there is also the challenge of automated data collection from a number of local systems and their merging into a large dataset for the purpose of more reliable queries over large amounts of data.

In such situations, telemedicine in the service of scientific research becomes an indispensable tool in confirming or rejecting of scientific hypotheses, improving the ability of researchers to undertake case-control studies using dental information collected at distances of thousands of kilometers (Miladinovic et al., 2010; Ballini et al., 2007).

Finally, effectuating distant access to dental data, the systems of teledentistry enable high speed and effective forensic identification of victims based on their dental status recorded in electronic histories of dental patients (Hanaoka et al., 2007).

## 10. Future research

The research of telemedicine in dentistry has been neglected for no reason compared to other disciplines of medicine (Kopycka-Kedzierawski & Billings, 2006). The results achieved so far are very encouraging, setting the roadsigns for future investigations. The issues to be addressed are the use of telemedicine in emergency dental conditions, not covered by the present adequate distant support, posttraumatic and postoperative controls, postprosthetic patient surveillance and so on.

If we consider the situations with long-term inavailability of dental care, e.g. during space flights, on transoceanic ships, in various rural areas, distant telemedical control of robotized instruments could be an appropriate solution.

Telemedicine can also be of help in the application of dental nanotechnologies, stem cell research, research and control of bioinductive and bioregenerative materials, and so on.

Probably the most important area of use of these valuable methods is to support the processes of collection, triage, sorting, counting, and analysis of raw electronic data for the purpose of induction in the systems of artificial intelligence.

## 11. Acknowledgement

This chapter is created and published in the name of God and our Savior Jesus Christ.


## 12. References

- Amável, R., Cruz-Correia, R. & Frias-Bulhosa, J.(2009).Remote diagnosis of children dental problems based on non-invasive photographs - a valid proceeding?.*Stud Health Technol Inform*,Vol.50,pp:458-62.
- Aziz, SR. & Ziccardi, VB.(2009).Telemedicine using smartphones for oral and maxillofacial surgery consultation, communication, and treatment planning.*J Oral Maxillofac Surg*.Vol.67,No.11,pp:2505-9.
- Baker, WP., 3rd., Loushine, RJ., West, LA., Kudryk, LV. & Zadinsky, JR.(2000).Interpretation of artificial and in vivo periapical bone lesions comparing conventional viewing versus a video conferencing system. *J Endod*. Vol.26,No.1,pp:39-41.
- Ballini, A., Capodiferro, S., Toia, M., Cantore, S., Favia, G., De Frenza, G. & Grassi, FR.(2007).Evidence-Based Dentistry: What's New?.*Int J Med Sci*,Vol.4,pp:174-178. Available from URL:[www.medsci.org/v04p0174.htm](http://www.medsci.org/v04p0174.htm)
- Berndt, J., Leone, P. & King, G.(2008).Using teledentistry to provide interceptive orthodontic services to disadvantaged children. *Am J Orthod Dentofacial Orthop*. Vol.134, No.5,pp:700-6.

- Duka, M., Mihailović, B., Miladinović, M., Janković, A. & Vujčić, B.(2009).Evaluation of telemedicine systems for impacted third molars diagnosis.(In Serbian).*Vojnosanit Pregl*.Vol.66,No.12,pp:985-91.
- Favero, L., Pavan, L. & Arreghini, A.(2009).Communication through telemedicine: home teleassistance in orthodontics. *Eur J Paediatr Dent*.Vol.10,No.4,pp:163-7.
- Hanaoka, Y., Ueno, A., Tsuzuki, T., Kajiwar, M., Minaguchi, K. & Sato, Y.(2007).Proposal for internet-based Digital Dental Chart for personal dental identification in forensics.*Forensic Sci Int*.Vol.168,No.1,pp:57-60.
- Hartung, F. & Kordass, B.(2006).Comparison of the contact surface pattern between virtual and milled Cerec 3D full-ceramic crowns.*Int J Comput Dent*.Vol. 9,No.2,pp:129-36.
- Kopycka-Kedzierawski, DT & Billings, RJ.(2006).Teledentistry in inner-city child-care centres. *J Telemed Telecare*. Vol.12, No.4,pp.176-81, ISSN 1357-633X.
- Kopycka-Kedzierawski, DT., Billings, RJ. & McConnochie, KM.(2007).Dental screening of preschool children using teledentistry: a feasibility study. *Pediatr Dent*. Vol.29, No.3,pp:209-13.
- Kopycka-Kedzierawski, DT., Bell, CH. & Billings, RJ.(2008).Prevalence of dental caries in Early Head Start children as diagnosed using teledentistry. *Pediatr Dent*. Vol.30,No.4,pp:329-33.
- Jadad, AR., Haynes, RB., Hunt, D. & Browman, GP.( 2000).The Internet and evidence-based decision-making: a needed synergy for efficient knowledge management in health care. *Canadian Medical Association Journal*,Vol.162, No.3,pp: 362-5.
- Janković, A.( 2007).Validity evaluation of clinical dermoscopic and histologic diagnosis by the method of teledermatology,[ In Serbian], *dissertation*. School of Medicine,Niš.
- Jevtović, I. (2008).*Telemedicine – the future that has already begun*,[In Serbian],School of Medicine Kragujevac.
- Jones, S., Johnson-Yale, C., Millermaier, S. & Seoane Pérez, F.(2008).Academic work, the Internet and U.S. college students.*Internet and Higher Education*.Vol.11,No.3-4,pp: 165-177.
- Mihailovic, B.(2006).Impacted teeth – etiology, frequencies, clinical manifestations and therapy,[ In Serbian], *dissertation*, School of Medicine, Priština-Kosovska Mitrovica.
- Mihailovic, B., Miladinovic, M., Mladenovic, D., Lazic, Z., Jankovic, A, Zivkovic, D. & Vujcic, B.( 2009). *Computerized dentistry [In Serbian]*. Obelezja, Belgrade.
- Miladinovic, M., Mihailovic, B., Jankovic, A., Tosic, G., Mladenovic, D., Zivkovic, D., Duka, M. & Vujcic, B.(2010).The reasons of the extraction obtained by artificial intelligence. *Acta Fac Med Naiss*. In Press.
- Mladenović, D., Popović, L, Mihailović, B., Janković, A., Stojković, M., Živković. D. & Miladinović, M.(2009).Comparison of measurements made on digital 2d models and study casts. *Acta Fac Med Naiss*.Vol.26,No.4,pp:187-94.
- Okunami, TR., Kusnoto, B., BeGole, E., Evans, CA., Sadowsky, C. & Fadavi, S.(2007).Assessing the American Board of Orthodontics objective grading system: digital vs plaster dental casts. *Am J Orthod Dentofacial Orthop*.Vol.131,No.1,pp:51-6.
- Peluso, M., Josell, S., Levine, S. & Lorei, B.(2004)Digital Models: An Introduction. *Seminars in Orthodontics*.Vol. 10,No.3,pp:226-238.
- PubMed, The National Center for Biotechnology Information.(2010). *U.S. National Library of Medicine National Institutes of Health*. Available on Internet. URL: [www.ncbi.nlm.nih.gov/sites/entrez](http://www.ncbi.nlm.nih.gov/sites/entrez). [accessed august 2010].

- Reynolds, P. & Mason, R.(2002).On-line video media for continuing professional development in dentistry.*Computers & Education*.Vol.39,No.1,pp:65-98.
- Rocca, MA.; Kudryk. L.; Pajak. JC. & Morris T. (2004).The evolution of a teledentistry. URL:[www.amia.org/pubs/symposia/D005388.pdf](http://www.amia.org/pubs/symposia/D005388.pdf). Accessed 20 August 2004.
- Sanhez, D. E., Lefebvre. C. & Abeyta, K.(2004).Teledentistry in the United States: a new horizon of dental care.*Int J Dent Hyg*. Vol.2,No.4,pp:161-4.
- Schicho, K. & Ewers, R.(2008).Teleplanning in Image-Guided Dental Implantology,In: *Teleradiology*, Ed. By Sajeesh, K. Et al. Springer, Verlag.
- Schleyer, T. & Spallek, H.(2001).Dental informatics. A cornerstone of dental practice.*J Am Dent Assoc*.Vol.132,No.5,pp:605-13.
- Späth, C. & Kordass, B.( 2006).Optimization of the static occlusion by "occlusal surface settling" in the Cerec 3D software.*Int J Comput Dent*.Vol.9,No.2,pp:121-6.
- Torres-Pereira, C., Possebon, RS., Simões, A., Bortoluzzi, MC., Leão, JC., Giovanini, AF. & Piazzetta, CM.(2008).Email for distance diagnosis of oral diseases: a preliminary study of teledentistry.*J Telemed Telecare*.Vol.14,No.8,pp:435-8.
- Zivković, D., Tošić, G., Mihailović, B., Miladinović, M. & Vujičić, B.(2010 In Press).Diagnosis of periapical lesions of the front teeth using the Internet. *PONS Med J*.

IntechOpen



## **Advances in Telemedicine: Applications in Various Medical Disciplines and Geographical Regions**

Edited by Prof. Georgi Graschew

ISBN 978-953-307-161-9

Hard cover, 296 pages

**Publisher** InTech

**Published online** 22, March, 2011

**Published in print edition** March, 2011

Innovative developments in information and communication technologies (ICT) irrevocably change our lives and enable new possibilities for society. Telemedicine, which can be defined as novel ICT-enabled medical services that help to overcome classical barriers in space and time, definitely profits from this trend. Through Telemedicine patients can access medical expertise that may not be available at the patient's site. Telemedicine services can range from simply sending a fax message to a colleague to the use of broadband networks with multimodal video- and data streaming for second opinioning as well as medical telepresence. Telemedicine is more and more evolving into a multidisciplinary approach. This book project "Advances in Telemedicine" has been conceived to reflect this broad view and therefore has been split into two volumes, each covering specific themes: Volume 1: Technologies, Enabling Factors and Scenarios; Volume 2: Applications in Various Medical Disciplines and Geographical Regions. The current Volume 2 is structured into the following thematic sections: Cardiovascular Applications; Applications for Diabetes, Pregnancy and Prenatal Medicine; Further Selected Medical Applications; Regional Applications.

### **How to reference**

In order to correctly reference this scholarly work, feel free to copy and paste the following:

Branko Mihailovic, Milan Miladinovic and Biljana Vujcic (2011). Telemedicine in Dentistry (Teledentistry), Advances in Telemedicine: Applications in Various Medical Disciplines and Geographical Regions, Prof. Georgi Graschew (Ed.), ISBN: 978-953-307-161-9, InTech, Available from:  
<http://www.intechopen.com/books/advances-in-telemedicine-applications-in-various-medical-disciplines-and-geographical-regions/telemedicine-in-dentistry-teledentistry->

**INTeCH**  
open science | open minds

### **InTech Europe**

University Campus STeP Ri  
Slavka Krautzeka 83/A  
51000 Rijeka, Croatia  
Phone: +385 (51) 770 447  
Fax: +385 (51) 686 166  
[www.intechopen.com](http://www.intechopen.com)

### **InTech China**

Unit 405, Office Block, Hotel Equatorial Shanghai  
No.65, Yan An Road (West), Shanghai, 200040, China  
中国上海市延安西路65号上海国际贵都大饭店办公楼405单元  
Phone: +86-21-62489820  
Fax: +86-21-62489821

© 2011 The Author(s). Licensee IntechOpen. This chapter is distributed under the terms of the [Creative Commons Attribution-NonCommercial-ShareAlike-3.0 License](https://creativecommons.org/licenses/by-nc-sa/3.0/), which permits use, distribution and reproduction for non-commercial purposes, provided the original is properly cited and derivative works building on this content are distributed under the same license.

IntechOpen

IntechOpen