

# We are IntechOpen, the world's leading publisher of Open Access books Built by scientists, for scientists

6,900

Open access books available

185,000

International authors and editors

200M

Downloads

Our authors are among the

154

Countries delivered to

TOP 1%

most cited scientists

12.2%

Contributors from top 500 universities



WEB OF SCIENCE™

Selection of our books indexed in the Book Citation Index  
in Web of Science™ Core Collection (BKCI)

Interested in publishing with us?  
Contact [book.department@intechopen.com](mailto:book.department@intechopen.com)

Numbers displayed above are based on latest data collected.  
For more information visit [www.intechopen.com](http://www.intechopen.com)



# Advantages of Right-Sided Implantation of Permanent Cardiac Pacemakers Performed by a Surgeon

Davor Horvat  
*General Hospital in Karlovac,  
Croatia*

## 1. Introduction

A pacemaker is a medical device which uses electrical impulses, delivered by electrodes contacting the heart muscles, to regulate the beating of the heart. The primary purpose of a pacemaker is to maintain an adequate heart rate, either because the heart's native pacemaker is not fast enough, or there is a block in the heart's electrical conduction system (Fig. 1,2a,2b,3) (McWilliam, JA. 2007., Gregoratos, G. 2005).



Fig. 1. A puls generator of a pacemaker

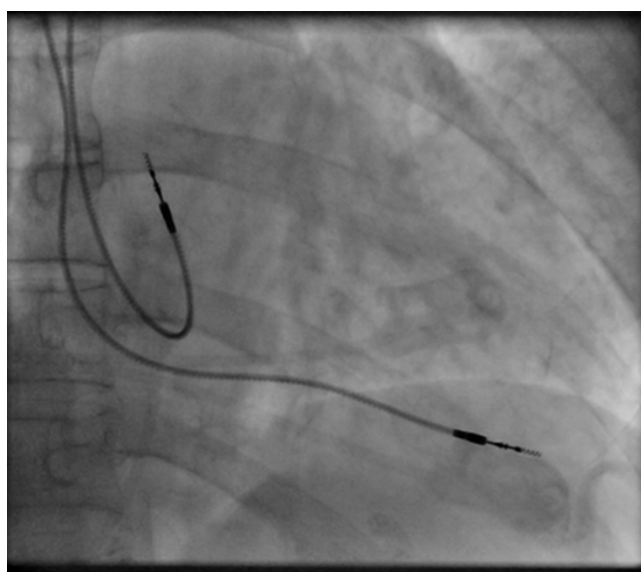


Fig. 2a. A leads of a pacemaker

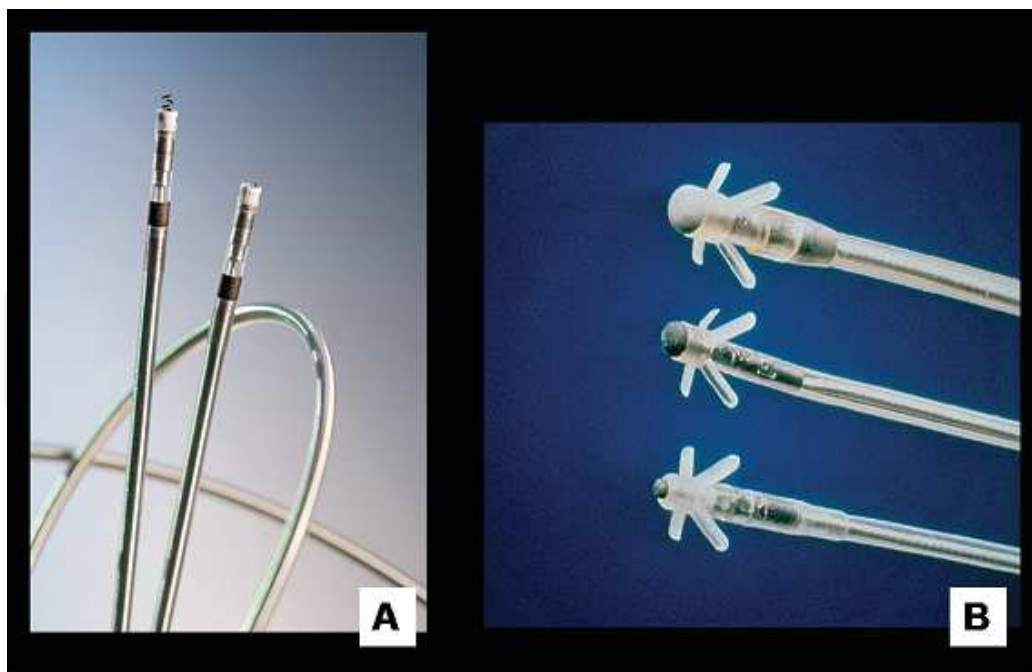


Fig. 2b. A leads of a pacemaker



Fig. 3. A puls generator of a pacemaker with electrode

The first use of transvenous pacing in conjunction with an implanted pacemaker was by Parsonnet in the USA (Parsonnet, V. 1978, a Parsonnet, V.; Zucker, IR. & Asa, MM. 1962, b Parsonnet, V; Zucker, IR. & Asa, MM.1962)., Lagergren in Sweden (Lagergren, H. 1978., Lagergren H, & Johansson, L.1963) and Jean-Jaques Welti in France (Welti, JJ. 2009) in 1962-63. The transvenous procedure involved incision of a vein into which was inserted the catheter electrode lead under fluoroscopic guidance, until it was lodged within the trabeculae of the right ventricle. This method was to become the method of choice by the mid-1960s (McWilliam, JA. 2007).). Permanent pacing with an implantable pacemaker involves transvenous placement of one or more pacing electrodes within a chamber, or

chambers, of the heart. The procedure is performed by incision of a suitable vein into which the electrode lead is inserted and passed along the vein, through the valve of the heart, until positioned in the chamber. The procedure is facilitated by fluoroscopy which enables the physician or cardiologist to view the passage of the electrode lead. After satisfactory lodgement of the electrode is confirmed the opposite end of the electrode lead is connected to the pacemaker generator. There are three basic types of permanent pacemakers, classified according to the number of chambers involved and their basic operating mechanism. In single-chamber pacemaker type, only one pacing lead is placed into a chamber of the heart, either the atrium or the ventricle. In dual-chamber pacemaker type, wires are placed in two chambers of the heart. One lead paces the atrium and one paces the ventricle. This type more closely resembles the natural pacing of the heart by assisting the heart in coordinating the function between the atria and ventricles ("Heart Rhythm Society", 2004). A pacemaker is typically inserted into the patient through a simple surgery using either local anesthetic or a general anesthetic. The patient may be given a drug for relaxation before the surgery as well. An antibiotic is typically administered to prevent infection (de Oliveira, JC et al. 2009). In most cases the pacemaker is inserted in the left shoulder area where an incision is made below the collar bone creating a small pocket where the pacemaker is actually housed in the patient's body. The lead or leads (the number of leads varies depending on the type of pacemaker) are fed into the heart through a large vein using a fluoroscope to monitor the progress of lead insertion. A temporary drain may be installed and removed the following day. The actual surgery may take about an hour (McWilliam, JA. 2007).

## **2. Important**

### **2.1 What is the problem?**

The aim of this paper is to point out the advantages of right-sided implantation of cardiac pacemakers, to stress the advantages of the cooperation with a surgeon while preparing the pacemaker's layer as well as to critically judge the frequency of developed complications in such a treatment. The second problem is to show the better place for the generator's implantation.

### **2.2 What has been done by other researchers and where you can contribute?**

In today's practice implantation of the generator of cardiac pacemakers beneath the right clavicle by means of surgical preparation of the layer is not so often used as a method of implantation of cardiac pacemakers.

The reason for this is greater practicality of the left-sided implantation due to a simpler anatomic position of the subclavian vein as well as easier organisation of work in case only a cardiologist performs an operation without the help of a surgeon.

### **2.3 What have you done and which method or tools were used ?**

However, in case of right-sided implantation of a cardiac pacemaker, the position of an electrode is in the form of the letter «S», which means that the electrode bends in two contralateral curves which is in contrast to left-sided implantation where the electrode has only one curve on its path from the generator to the peak of the heart. It is these two curves of the electrode that cause its better stability and a fewer number of post-operative dislocations.

An example of such a way of implantation of an electrode of a cardiac pacemaker is presented in Figure 4. This Figure also shows right-sided implantation of an atrium electrode where each of these two arrows indicates one of the two curves of the electrode. The same principle can also be applied to the ventricular electrode and as a result of these two curves of the electrode better stability of the electrodes is achieved (Fig. 5).

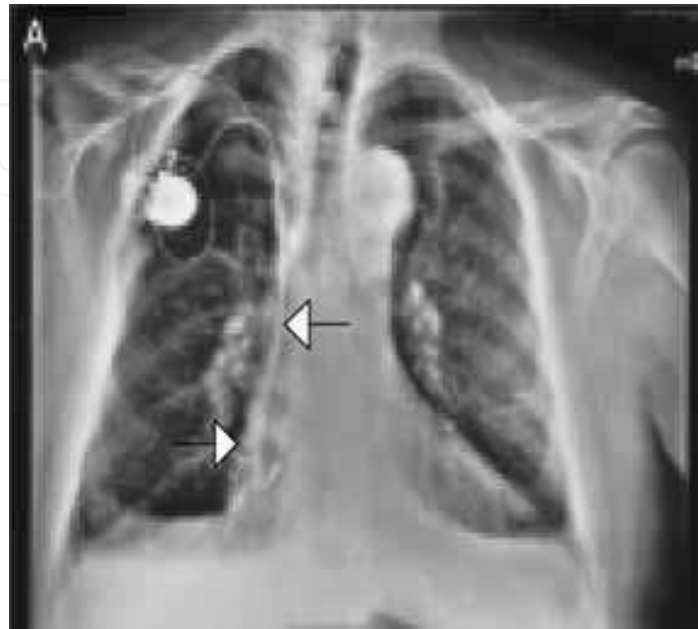


Fig. 4. Right-sided implantation of an atrial electrode

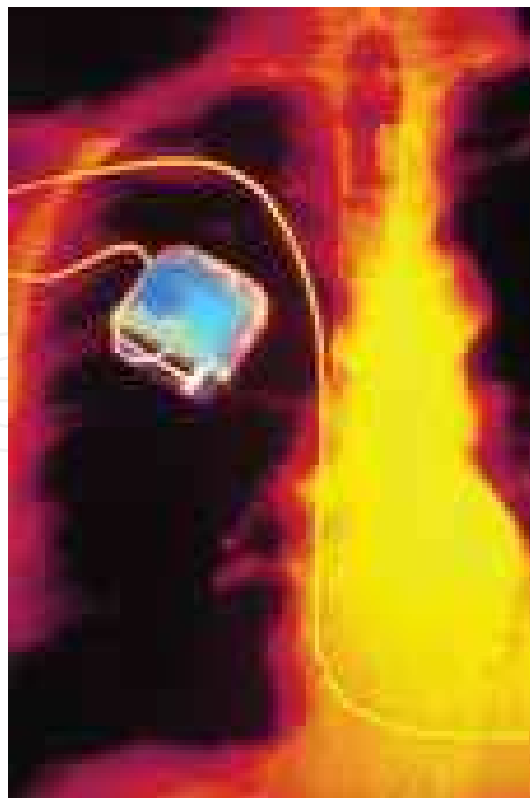


Fig. 5. Right-sided implantation of a ventricular electrode

In contrast to this, Figure 6 shows left-sided way of implantation of a ventricular electrode where only one bigger curve of the electrode is visible. However, such one curve of the electrode cannot give satisfactory stability of the electrode of a cardiac pacemaker (Fig. 7a,7b). Finally, due to greater instability of the electrode, this causes greater possibility of dislocations (8). Moreover, additional efforts for displacing the electrode are needed in such a case. This requires some extra time, new expenses, and partly, it affects the self-confidence of the operator.

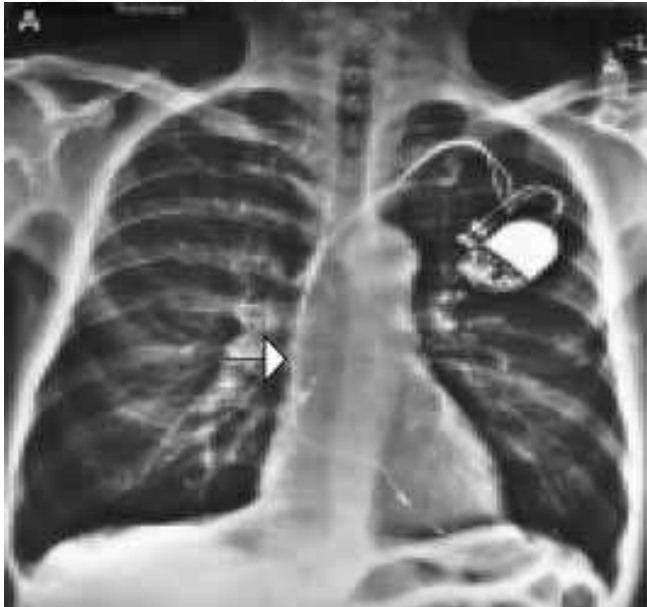

Fig. 6. Left-sided implantation of a ventricular electrode

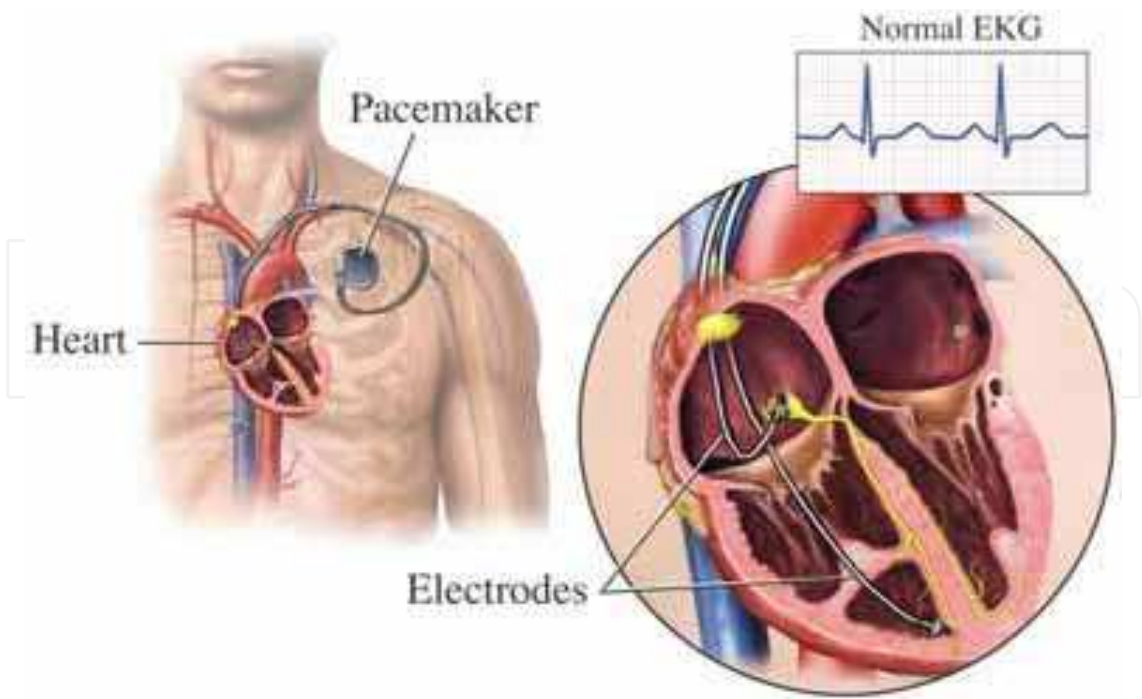


Fig. 7a. The scheme of left-sided electrodes implantation



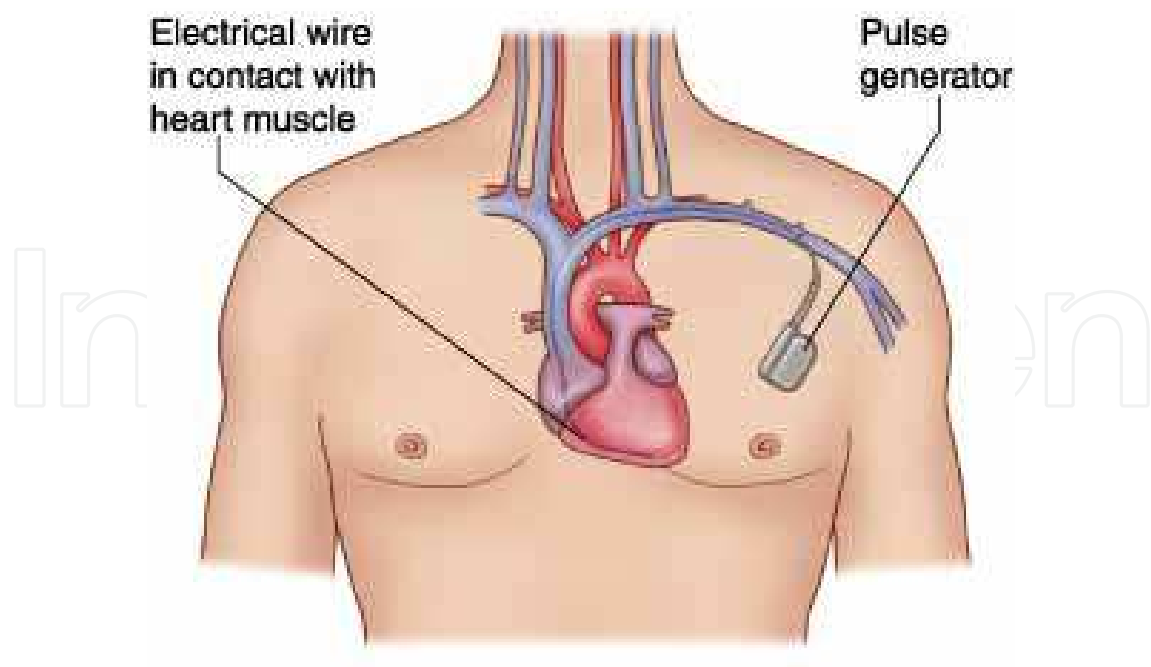


Fig. 7b. The scheme of left-sided electrodes implantation

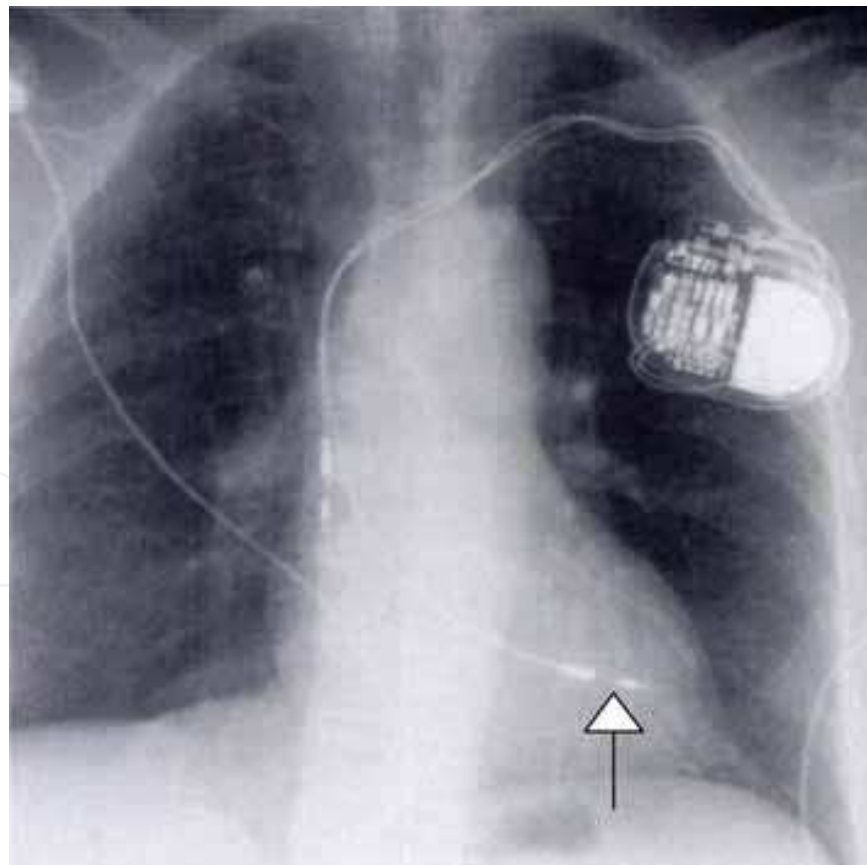


Fig. 8. Chest radiograph obtained after pacemaker implantation shows that ventricular lead is displaced superiorly in left ventricle

Also, the surgeon's help while implanting a cardiac pacemaker beneath the clavicle makes it possible for the generator's layer to be formed between the big and the small pectoral muscle. In such a way a better aesthetic impression for the patient is achieved because the place of implantation cannot be practically seen from the outside at all. Furthermore, frequency of decubitus of the skin is reduced due to prolapse of the generator in thin patients as well as frequency of the puncture of the subclavian vein is reduced, too. Namely, the vena cephalica is shown by a surgical approach through which placing of the electrode into the subclavian vein is made possible. In this way the possibility of complications such as haematomae and iatrogenic pneumothorax (Fig. 9) is reduced because the access through the vena cephalica is considerably less traumatic than a direct access through the subclavian vein.

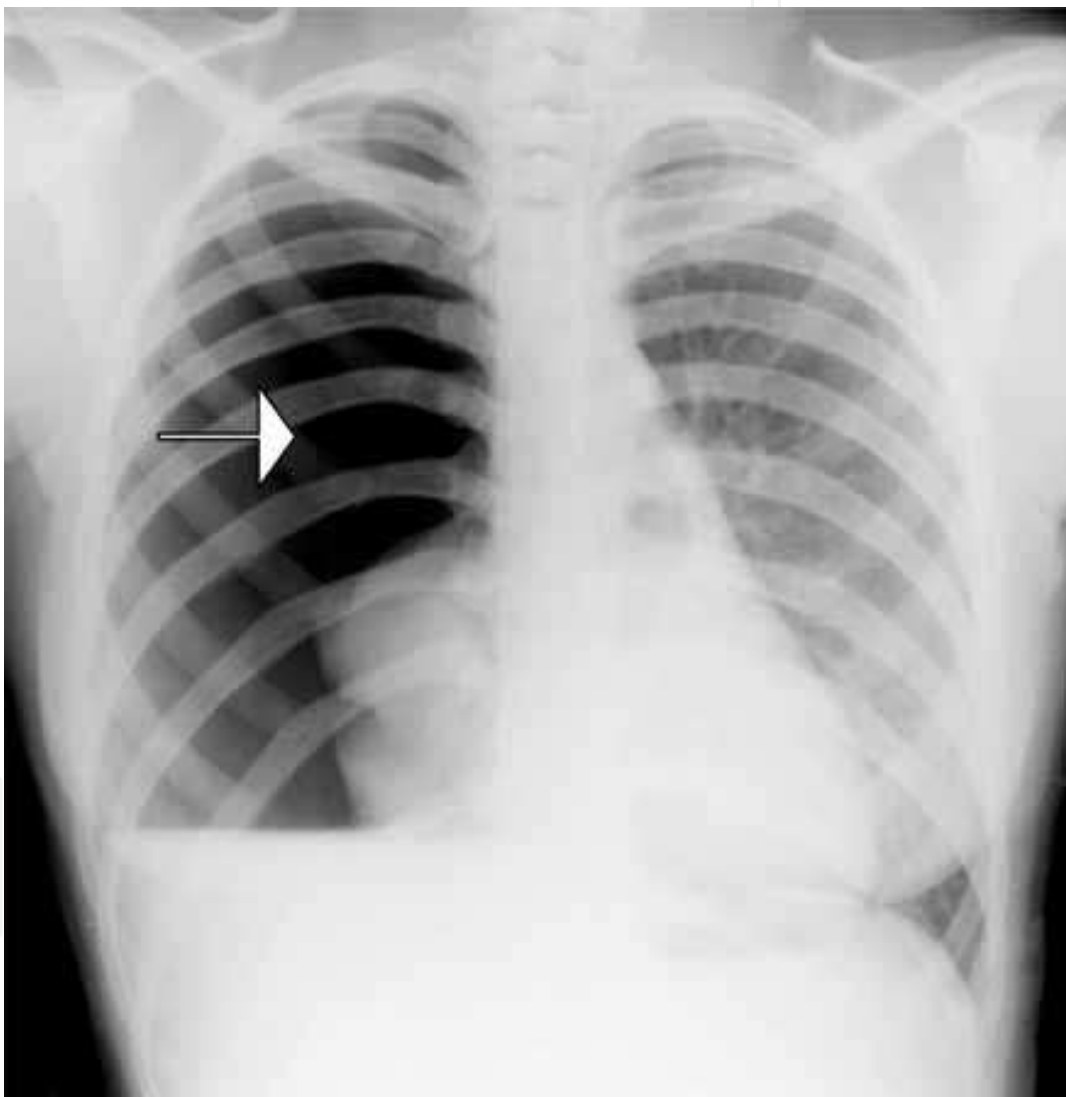

Fig. 9. Iatrogenic pneumothorax

Such an example of «deep» implantation of the generator of a cardiac pacemaker is presented in Figures 10a,10b,10c. Namely, a formed layer of the generator of a cardiac pacemaker beneath the pectoral muscle means that above the very generator one can see a muscle which additionally stabilizes it.



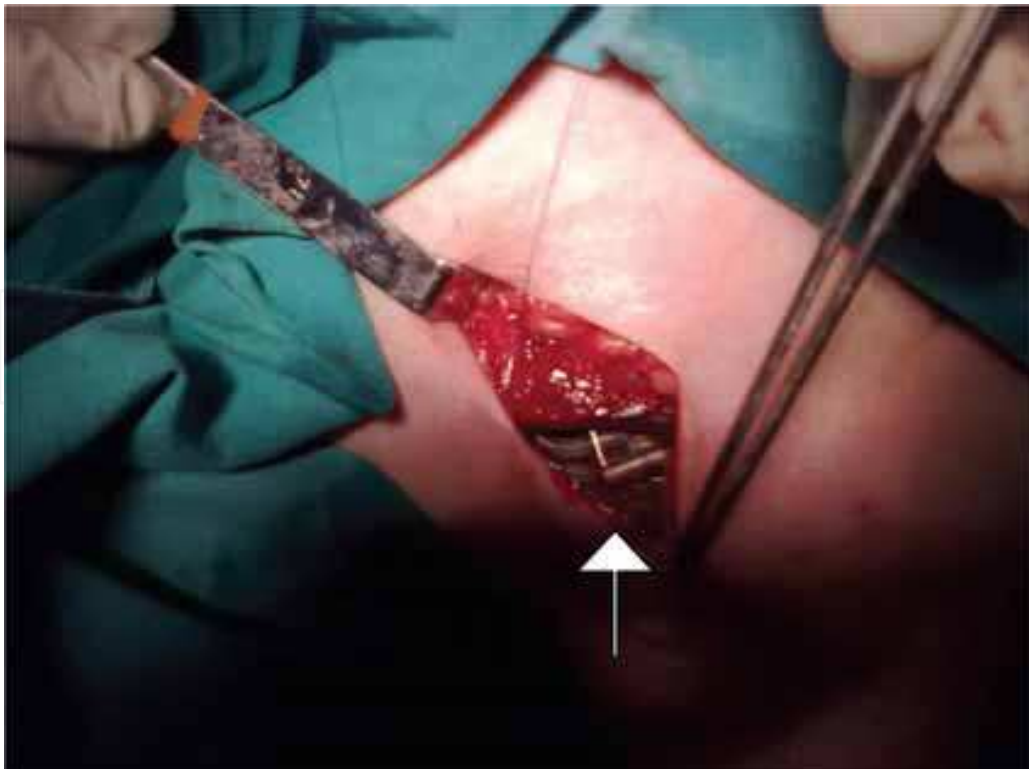

Fig. 10a. Implantation of the pulse generator of a cardiac pacemaker beneath a pectoral muscle

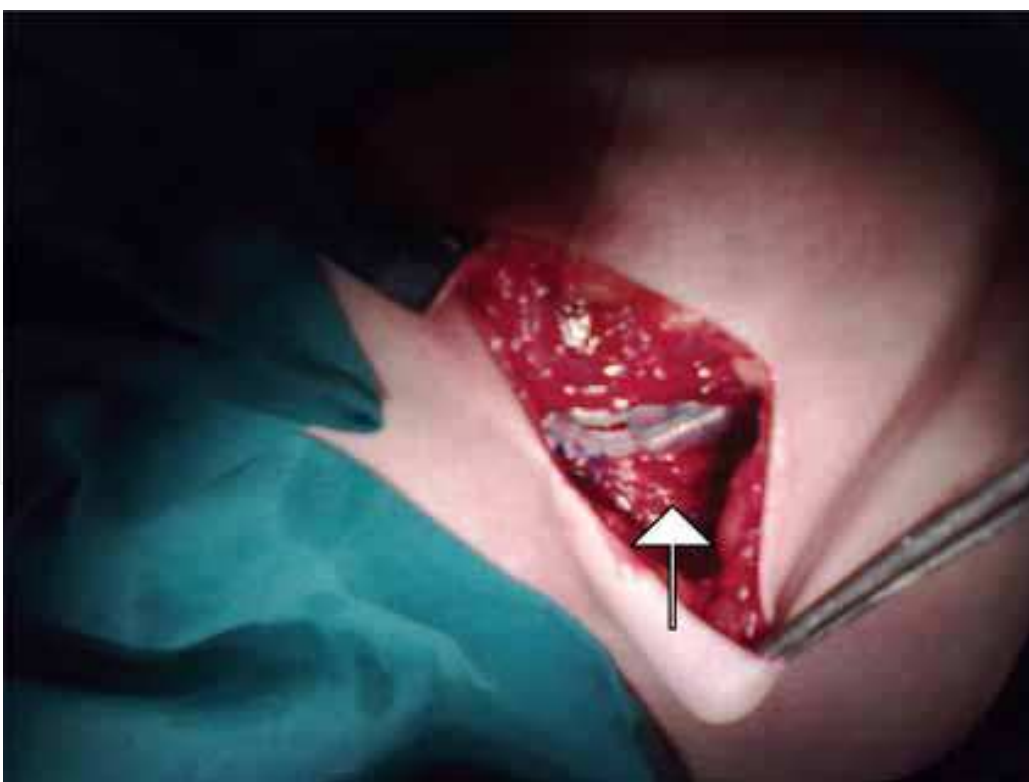


Fig. 10b. Implantation of the pulse generator of a cardiac pacemaker beneath a pectoral muscle

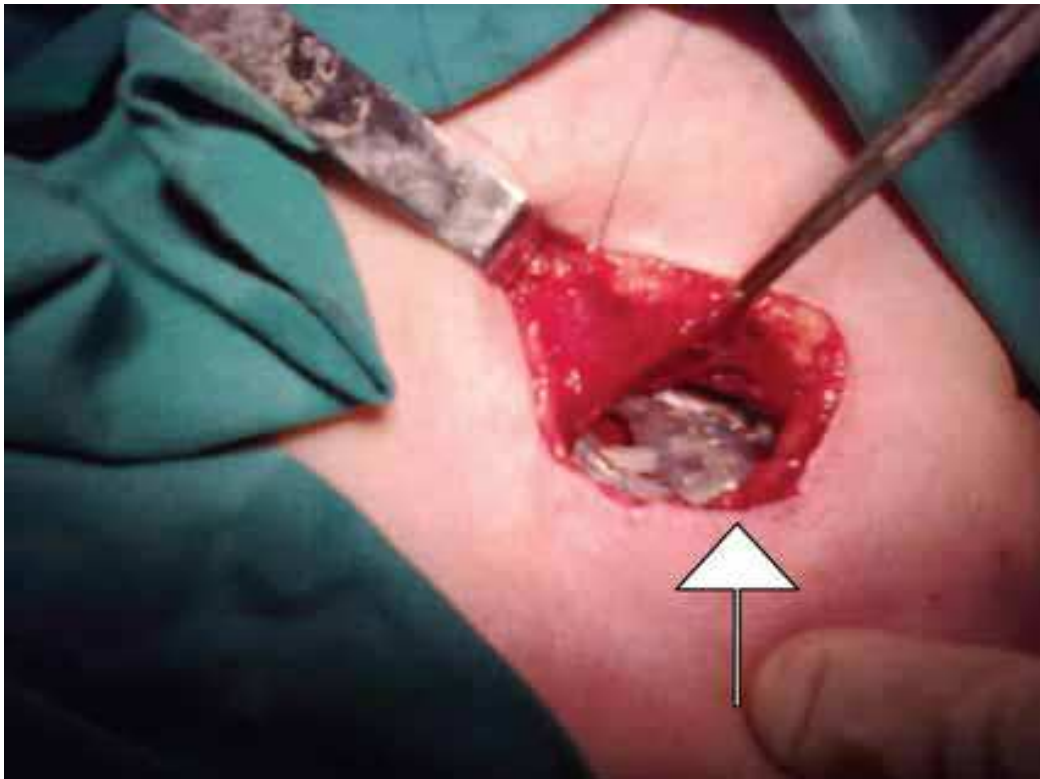


Fig. 10c. Implantation of the pulse generator of a cardiac pacemaker beneath a pectoral muscle

#### 2.4 What are my results?

In order to support this thesis from a practical point of view, a research involving 281 patients with right-sided primoimplantation of permanent cardiac pacemakers by a surgeon was carried out. The correction of dislocated electrode in the course of the first year was determined in 11 patients (3.9%). The puncture of subclavian vein due to inadequate vena cephalica was determined in 62 patients (22.1%). However, the care of the local haematomae was determined in 4 patients (1.4%) and local infections in 2 patients (0.7%). The need for an access to the other side was determined in 6 patients (2.1%). However, only 3 patients polled (1.1%) had, during a follow-up, a subjective feeling of discomfort at the place of implantation of a cardiac pacemaker.

One should especially point out that frequency of dislocation of an electrode, puncture of the vena subclaviae, changes of the side of implantation and looking after local surgical complications such as infections, haematomae and decubitus were better in our hospital than in other centres (Ellenbogen et al., 2002, Harcombe et al., 1998, Aggarwal et al., 1995).


#### 2.5 What is new and good, what is not good?

To sum up, frequency of complications during right-sided implantation of cardiac pacemakers performed by a surgeon is satisfactory low and patients are highly satisfied. Also, the frequency of decubitus of the skin, prolapse of generator, frequency of the puncture of the subclavian vein, complications such as haematomae and iatrogenic pneumothorax are reduced. This method is complicate because a cardiologist works with a surgeon, but the positive effects are bigger.

### 3. References

- McWilliam, JA. (2007). "Electrical stimulation of the heart in man". *Br Med J* Vol.,1., 348-50.
- Gregoratos, G. (2005). Indications and Recommendations for Pacemaker Therapy. *Am Fam Physician*, Vol.,71.,1563-70.
- Parsonnet, V. (1978). "Permanent Transvenous Pacing in 1962". *PACE*, Vol.,1., 285.
- a Parsonnet, V.; Zucker, IR. & Asa, MM. (1962). "Preliminary Investigation of the Development of a Permanent Implantable Pacemaker Using an Intracardiac Dipolar Electrode". *Clin Res*, Vol.,10., 391.
- b Parsonnet, V; Zucker, IR. & Asa, MM. (1962). "An intracardiac bipolar electrode for interim treatment of complete heart block". *Am JCardiol*, Vol.,10., 261-5.
- Lagergren, H. (1978). "How it happened: my recollection of early pacing". *Pacing Clin Electrophysiol*, Vol.,1(1),140-3.
- Lagergren H, & Johansson, L. (1963). "Intracardiac stimulation for complete heart block". *Acta Chir Scand*, Vol.,125., 562-6. PMID 13928055.
- Welti, JJ. Biography, (2009). Heart Rhythm Foundation.  
[http://www.wikidoc.org/index.php/Artificial\\_pacemaker#\\_ref-11](http://www.wikidoc.org/index.php/Artificial_pacemaker#_ref-11)  
 "Pacemakers, Patient and Public Information Center. Heart Rhythm Society". 2004.  
<http://www.hrspatients.org/patients/treatments/pacemakers.asp>.
- de Oliveira, JC et al. (2009). "Efficacy of antibiotic prophylaxis prior to the implantation of pacemakers and cardioverter-defibrillators: Results of a large, prospective, randomized, double-blinded, placebo - controlled trial". *Circ Arrhythmia Electrophysiol*, Vol., 2.(1), 29-34.
- Ellenbogen, KA et al. (2002). Delayed Complications Following Pacemaker Implantation. *Pacing Clin Electrophysiol*, Vol., 25.(8), 1155-8.
- Harcombe, A et al. (1998). Late complications following permanent pacemaker implantation or elective unit replacement. *Heart*, Vol., 80.(3), 240-4.
- Aggarwal, RK et al. (1995). Early complications of permanent pacemaker implantation: no difference between dual and single chamber systems. *Br Heart J* Vol., 73.(6), 571-5.

IntechOpen



### **Modern Pacemakers - Present and Future**

Edited by Prof. Mithilesh R Das

ISBN 978-953-307-214-2

Hard cover, 610 pages

**Publisher** InTech

**Published online** 14, February, 2011

**Published in print edition** February, 2011

The book focuses upon clinical as well as engineering aspects of modern cardiac pacemakers. Modern pacemaker functions, implant techniques, various complications related to implant and complications during follow-up are covered. The issue of interaction between magnetic resonance imaging and pacemakers are well discussed. Chapters are also included discussing the role of pacemakers in congenital and acquired conduction disease. Apart from pacing for bradycardia, the role of pacemakers in cardiac resynchronization therapy has been an important aspect of management of advanced heart failure. The book provides an excellent overview of implantation techniques as well as benefits and limitations of cardiac resynchronization therapy. Pacemaker follow-up with remote monitoring is getting more and more acceptance in clinical practice; therefore, chapters related to various aspects of remote monitoring are also incorporated in the book. The current aspect of cardiac pacemaker physiology and role of cardiac ion channels, as well as the present and future of biopacemakers are included to glimpse into the future management of conduction system diseases. We have also included chapters regarding gut pacemakers as well as pacemaker mechanisms of neural networks. Therefore, the book covers the entire spectrum of modern pacemaker therapy including implant techniques, device related complications, interactions, limitations, and benefits (including the role of pacing role in heart failure), as well as future prospects of cardiac pacing.

#### **How to reference**

In order to correctly reference this scholarly work, feel free to copy and paste the following:

Davor Horvat (2011). Advantages of Right-Sided Implantation of Permanent Cardiac Pacemakers Performed by a Surgeon, Modern Pacemakers - Present and Future, Prof. Mithilesh R Das (Ed.), ISBN: 978-953-307-214-2, InTech, Available from: <http://www.intechopen.com/books/modern-pacemakers-present-and-future/advantages-of-right-sided-implantation-of-permanent-cardiac-pacemakers-performed-by-a-surgeon>

**INTECH**  
open science | open minds

#### **InTech Europe**

University Campus STeP Ri  
Slavka Krautzeka 83/A  
51000 Rijeka, Croatia  
Phone: +385 (51) 770 447  
Fax: +385 (51) 686 166

#### **InTech China**

Unit 405, Office Block, Hotel Equatorial Shanghai  
No.65, Yan An Road (West), Shanghai, 200040, China  
中国上海市延安西路65号上海国际贵都大饭店办公楼405单元  
Phone: +86-21-62489820  
Fax: +86-21-62489821

[www.intechopen.com](http://www.intechopen.com)

IntechOpen

IntechOpen

© 2011 The Author(s). Licensee IntechOpen. This chapter is distributed under the terms of the [Creative Commons Attribution-NonCommercial-ShareAlike-3.0 License](https://creativecommons.org/licenses/by-nc-sa/3.0/), which permits use, distribution and reproduction for non-commercial purposes, provided the original is properly cited and derivative works building on this content are distributed under the same license.

IntechOpen

IntechOpen