

# We are IntechOpen, the world's leading publisher of Open Access books Built by scientists, for scientists

6,900

Open access books available

186,000

International authors and editors

200M

Downloads

Our authors are among the

154

Countries delivered to

TOP 1%

most cited scientists

12.2%

Contributors from top 500 universities



WEB OF SCIENCE™

Selection of our books indexed in the Book Citation Index  
in Web of Science™ Core Collection (BKCI)

Interested in publishing with us?  
Contact [book.department@intechopen.com](mailto:book.department@intechopen.com)

Numbers displayed above are based on latest data collected.  
For more information visit [www.intechopen.com](http://www.intechopen.com)



# Application of Advanced Virtual Reality and 3D Computer Assisted Technologies in Computer Assisted Surgery and Tele-3D-computer Assisted Surgery in Rhinology

Ivica Klapan<sup>1,2</sup>, Pero Raos<sup>3</sup>, Tomislav Galeta<sup>3</sup>, Ljubimko Šimičić<sup>4</sup>,  
Juraj Lukinović<sup>5</sup>, Željko Vranješ<sup>2,6</sup>, Josip Maleš<sup>6</sup>,  
Stanko Belina<sup>7</sup> and Višeslav Ćuk<sup>7</sup>

<sup>1</sup>*Klapan Medical Group Polyclinic, Zagreb,*

<sup>2</sup>*Faculty of Medicine at University of Osijek,*

<sup>3</sup>*Mechanical Engineering Faculty in Slavonski Brod at University of Osijek,*

<sup>4</sup>*Department of Physics at University of Zagreb,*

<sup>5</sup>*ENT Department, Faculty of Medicine at University of Zagreb,*

<sup>6</sup>*ENT Department, Faculty of Medicine at at University of Osijek,*

<sup>7</sup>*Division of Radiology and Otorhinolaryngology, General Hospital Zabok,  
Croatia*

## 1. Introduction

Every physician using computer for diagnostic and therapeutic purposes should know that images are processed by use of graphic and computer systems, as well as by specialized program systems, in order to better present the anatomy of a particular part of the body with identified diseased areas (Ecke et al., 1998; Urban et al., 1998). The possibility of exact preoperative, non-invasive visualization of the spatial relationships of anatomic and pathologic structures, including extremely fragile ones, size and extent of pathologic process, and of precisely predicting the course of surgical procedure, allows the surgeon to achieve considerable advantage in the preoperative examination of the patient and to reduce the risk of intraoperative complications (Knezović et al., 2007), all this by use different virtual reality (VR) methods (Fig.1.).

Beside otorhinolaryngology, this has also been used in other fields (Klimek et al., 1998; Hassfeld et al., 1998). The more so, in addition to educational applications, virtual endoscopy (VE), virtual surgery (VS), application of 3D models, etc., has offered us the possibility of preoperative planning in rhinology (sinus surgery), and has become a very important segment in surgical training and planning of each individual surgical intervention. These analyses are becoming routine procedures in other otorhinolaryngology, oral, maxillofacial and plastic surgery, etc.

Classical endoscopic procedures performed with rigid endoscopes are invasive and often uncomfortable for patients, and some of them may have serious side effects such as perforation, infection and hemorrhage (Belina et al., 2008). VE is a new method of diagnosis

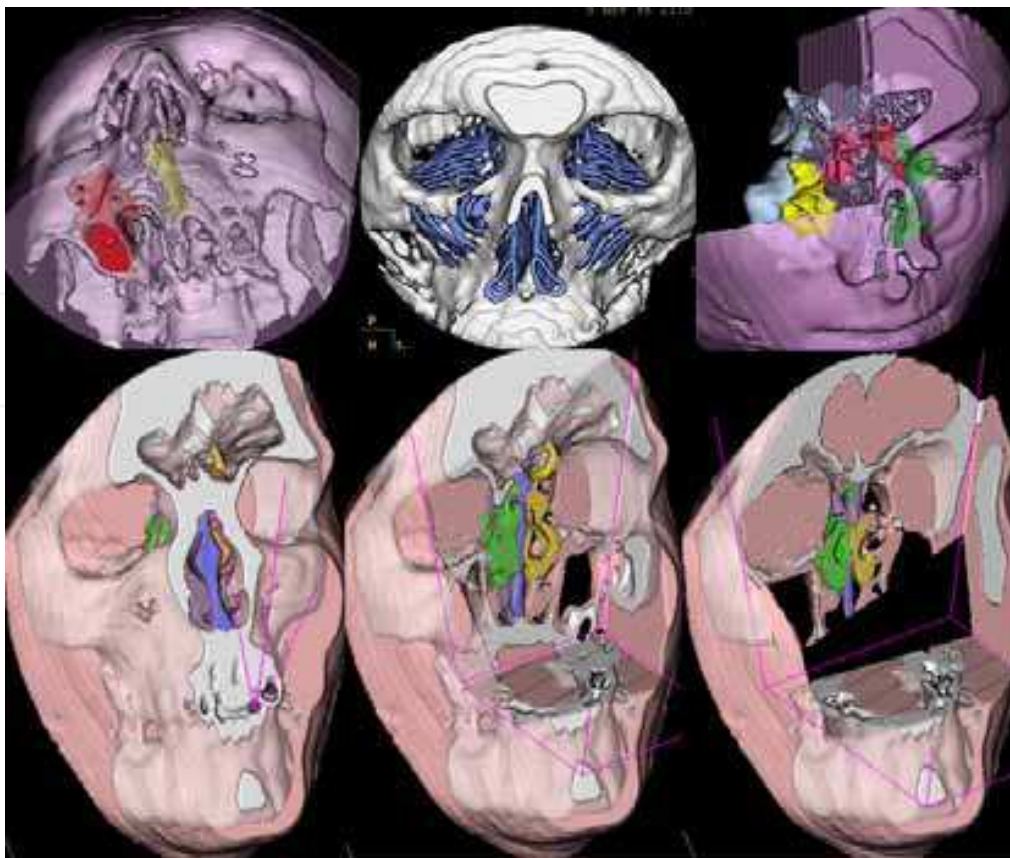


Fig. 1. 3D models of the human head in different projections. Visualization of the paranasal sinuses and surrounding regions from different 3D aspects (taken with permission from Klapan et al., *Otolaryngology Head Neck Surg*, 2002 and Klapan Medical Group Polyclinic, Zagreb, Croatia).

using computer processing of 3D image datasets (such as 2D multi slice computed tomography - MSCT and/or MRI scans) to provide simulated visualizations of patient specific organs similar or equivalent to those produced by standard endoscopic procedures (Robb, 2000; Wickham et al., 1994). Development of new computer techniques and fly through algorithms offer valuable non-invasive additional tools in diagnostics and preoperative planning in otorhinolaryngology (Fig.2.). Virtual endoscopy visualization avoids the risks associated with real endoscopy, and when used prior to performing an actual endoscopic exam can minimize procedural difficulties and decrease the rate of morbidity, especially for endoscopists in training (Robb, 2000), which was proved in our first Croatian 3D computer assisted- functional endoscopic sinus surgery (3D-CA-FESS) in June 3, 1994 (Klapan et al., 1997).

Definitely, the basic goal of 3D-computer assisted (3D-CA) support in diagnostic and surgical activities is to achieve safer surgical procedure using new computer and medical technologies in surgical (Anon et al., 1998) and /or telesurgical procedures (Fig.3.), and provide visualization of the anatomy as well the pathology in the 2D as well as in the form of 3D-models. Using our own approach in computer assisted-endoscopic surgery, we were able to "look inside" the patient during the real surgical procedure. According to our original idea, the computer network, essential for computer collaboration between surgical sites for telesurgical purposes, has to be built in parallel to the video network. Every

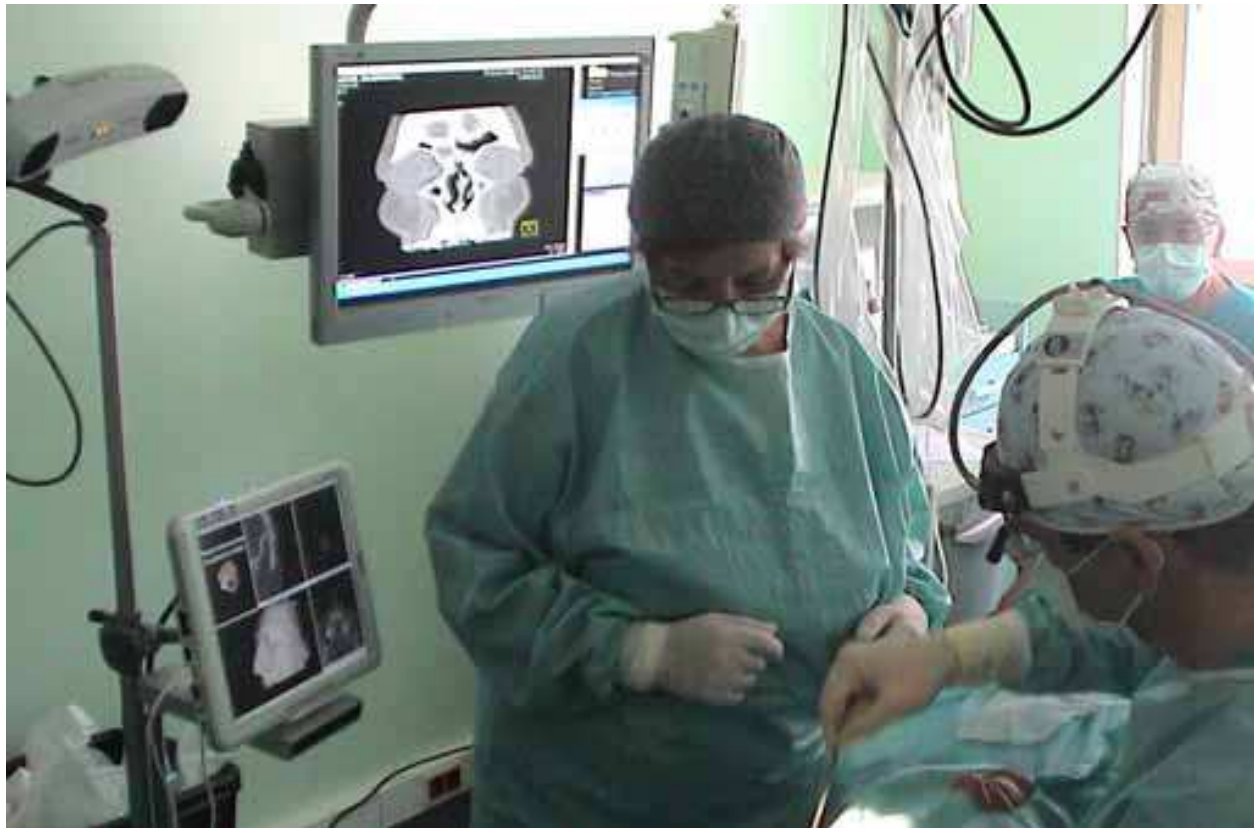

Fig. 2. An example of 3D-computer assisted navigation surgery of the nose and paranasal sinuses with simulation and planning of the course of subsequent endoscopic operation *per viam* VE which overcomes some difficulties of conventional endoscopy, such as “standard” FESS or tele-FESS (taken with permission of Klapan Medical Group Polyclinic, Zagreb, Croatia)

telesurgical site must have compliant collaboration software. On computer workstations, all sites have computed tomography (CT) images and 3D models with appropriate movies, and then the consultant, an experienced surgeon, assists the less experienced surgeon to reach the pathology in the operating field.

This kind of our Tele-3D-computer assisted surgery (Tele-3D-CAS) has to enable less experienced surgeons to perform critical surgeries using guidance and assistance from a remote, experienced surgeon. In telesurgery, more than two locations can be involved; thus less experienced surgeon can be assisted by one, two or more experienced surgeons, depending on the complexity of the surgical procedure. Our Tele-3D-CAS provides also the transfer of computer data (images, 3D-models) in real time during the surgery and, in parallel, of the encoded live video signals. Through this network, the two encoded live video signals from the endocamera and operation room camera have to be transferred to the remote locations involved in the telesurgery/consultation procedure (Klapan et al., J Telemed Telecare, 2002).

The first kind of our Tele-3D-C-FESS took place between two locations in the city of Zagreb, 10 km apart, with interactive collaboration from a third location. A surgical team carrying out an operative procedure at the Šalata ENT Department, Zagreb University School of Medicine and Zagreb Clinical Hospital Center, received instructions, suggestions and guidance through the procedure by an expert surgeon from an expert center. The third



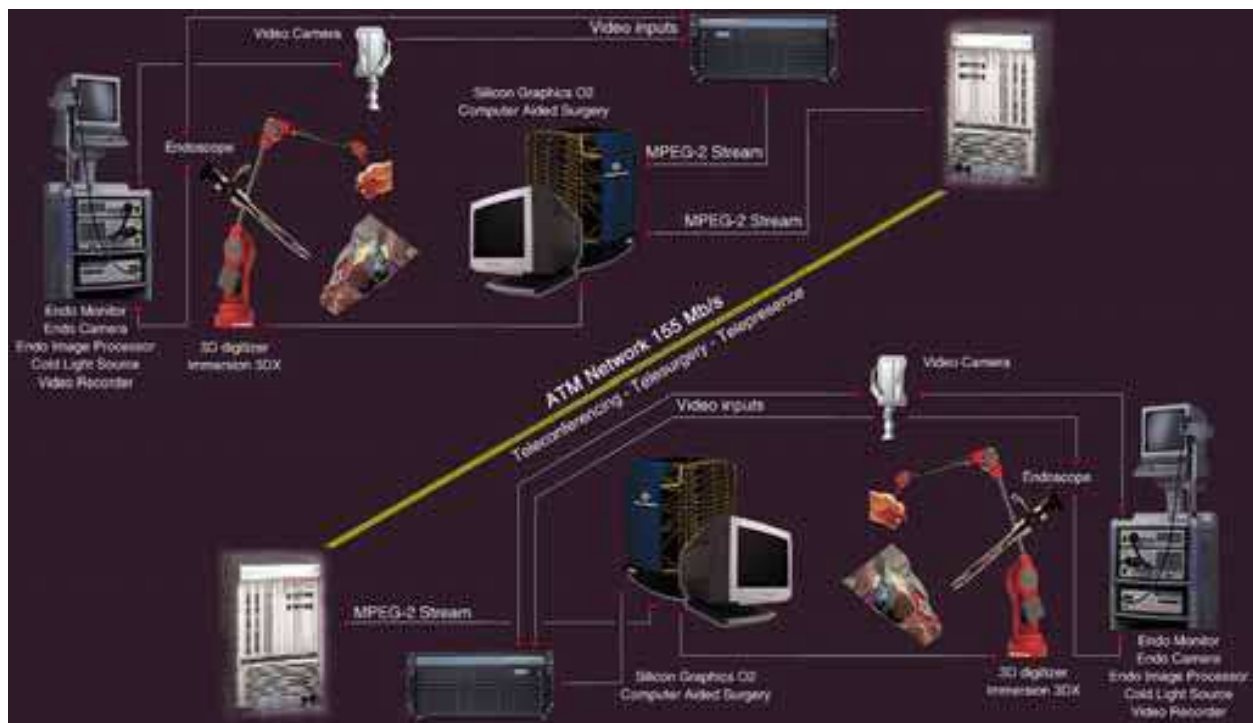


Fig. 3. Our tele-3D-computer assisted surgery of the nose and paranasal sinuses realized during our 3D computer assisted-FESS in June 3, 1994., proved the main advantage of VE and/or tele-VE that there are no restrictions on the movement of virtual endoscope prior the real procedure, and requires no hospitalization (taken with permission from Klapan et al., Otolaryngology Head Neck Surg, 2002 and Klapan Medical Group Polyclinic, Zagreb, Croatia)

active point was the Faculty of Electrical Engineering and Computing. The 2<sup>nd</sup> Tele-3D-C-FESS took place between two locations, two cities in Croatia (Osijek and Zagreb, 300 km apart). The surgical team carrying out an operative procedure at the ENT Department, Osijek Clinical Hospital, received instructions, suggestions and guidance through the procedure by an expert surgeon and radiologist from the Expert Center in Zagreb. This Tele-3D-C-FESS surgery, performed as described above, was successfully completed in 25-30 minutes.

Taking into account the opinion of the leading world authorities in endoscopic surgery, we believe that each endoscopic operation is a demanding procedure, including those described in the first two Tele-3D-C-FESS surgeries presented. Nevertheless, we would like to underline herewith that ordinary, and occasionally even expert surgeons may need some additional intraoperative consultation (or VE/3D support), for example, when anatomical markers are lacking in the operative field due to trauma (war injuries) or massive polypous lesions/normal mucosa consumption, bleeding, etc. Now, imagine that we can substitute artificially generated sensations for the real standard daily information received by our senses. In this case, the perception system in humans could be deceived, creating an impression of another 'external' world around the man (e.g., 3D navigation surgery). In this way, we could replace the true reality with the simulated reality that enables precise, safer and faster diagnosis as well as surgery. All systems of simulated reality share the ability to offer the user to move and act within the apparent worlds instead of the real world.

What do experts think about additional support *per viam* computer assisted reconstruction of the anatomy and pathology of the head and neck; what is the truth and level of reliability

of the computer reconstruction of CT images in telesurgery transmission; the question of availability and very expensive equipment; 3D image reality; control parameters; what is the use of computer 3D image of the surgical field and isn't a real live video image much better for telesurgery? Computer simulation by use of the simulated reality system allows for the medical diagnostic procedure to repeat over and over again on the virtual body, many functions can be simulated for realistic simulation as it is usually done, the surgeon is warned if the procedure does not proceed correctly, etc.

Sinus CT scan in coronal projection is a term familiar to every radiologist dealing with CT in the world. Layer thickness, shift, gantry, and window are internationally standardized and accepted values, thus being reproducible all over the world. The method is standardized, reproducible and distinctly defined (Stewart et al., 1999, Kenny et al., 1999), and it is by no means contradictory. But on the other side, the basic CT diagnostics has also limited possibilities, first of all because it presents summation images in a single plane (layer) but cannot present the continuity of structures. This has been solved by 3D reconstruction which is now available on PCs equipped with Pentium IV processors/2,0 GHz, or better. By presenting the continuity of structures (0.5-1 mm sections), this reconstruction allows visualization of the region as a whole, avoiding the loss of images by use of the standard approach in sinus CT imaging (3-5 mm sections).

During the 3D-CA-telesurgery, the computer with its operative field image allows the surgeon, by means of up-to-date technologies, to connect the operative instrumentarium to spatial digitalizers connected to the computer. Upon the completion of the tele-operation, the surgeon compares the preoperative and postoperative images and models of the operative field, and studies video records of the procedure itself. Using intraoperative records, animated images of the real tele-procedure performed can be designed. By means of computer records labelled coordinate shifts of 3D digitalizer during the surgery, an animated image of the course of operation in the form of journey, i.e. operative field fly-through in the real patient, can be designed. Beside otorhinolaryngology (Klimek et al., 1998; Ecke et al., 1998; Mann et al., 1998), this has also been used in other fields. The more so, in addition to educational applications, VS offers the possibility of preoperative planning in sinus surgery, and has become a very important segment in surgical training and planning of each individual surgical or telesurgical intervention, not only in the region of paranasal sinuses (Keeve et al., 1998; Hassfeld et al., 1998).

The complex software systems allow tele-visualization of CT or MRI section in its natural course (the course of examination performed), or in an imaginary, arbitrary course. Particular images can be transferred, processed and deleted, or can be presented in animated images, as it was done during our first telesurgery (Fig. 6). Multiple series of images can be simultaneously observed in different color tables and at various magnifications, with various grades of transparency, observing them as a unique 3D model system. The work with such models allows different views, shifts, cuts, separations, labelling, and animation. The series of images can be changed, or images can be generated in different projections through the volume recorded, as we have showed in our OR (Klapan et al., 2001).

Before the development of 3D spatial model, each individual image or the whole series of images have to be segmented, in order to single out the image parts of interest, because the basic requirement, in human medicine, resulting from the above mentioned needs refers to the use of a computer system for visualization of anatomic 3D-structures and integral operative field to be operated on. Thus, separate models of bones, healthy tissue, affected

tissue, and all significant anatomic entities of the operative field can be developed (Klapan et al., Am J ORL, 2002). The complete tele-3D-CA-procedure planned can be developed on computer models and a series of animations describing the procedure can be produced.

Comparative analysis of 3D anatomic models with intraoperative finding, in any kind of telesurgery, shows the 3D volume rendering image to be very good, actually a visualization standard that allows imaging likewise the real intraoperative anatomy (Burtscher et al., 1998; Holtel et al., 1999; Thral., 1999). Mentioned technologies represent a basis for realistic simulations that are useful in many areas of human activity (including medicine), and can create an impression of immersion of a physician in a non-existing, virtual environment (John et al., 2004).

Using routable shared and switched Ethernet connections (Fig. 4), 25 frames were transferred *per* second in full PAL (phase alternating line or phase alternation by line) resolution but with 20% of dropped frames. After some tests, it was found that the routing protocol between two or more sites could not offer a constant frame rate. Packages sent from the source travel to the destination using different network paths, thus some packages may be lost during communication or some may reach the destination with unacceptable delays.

Another problem we faced with video signals was how to transfer multiple video signals to remote locations. The native, uncompressed video required a bandwidth of about 34Mb/s, thus the video signals had to be compressed for the transfer of multiple video streams to remote locations using 155Mb/s.

The video image is critical in tele-endoscopic surgery and must be of the highest quality. Using software and hardware M-JPEG compression, it was found that one video stream from the endocamera in full PAL resolution and with audio required a bandwidth of about 20-30Mb/s. Our M-JPEG encoders were upgraded with MPEG1 and later with MPEG2 encoders, because we had a bandwidth of only 155Mb/s for data, video, audio and control communication. MPEG1 seems very good for conferencing; however, the endoscope video signal of the operating field required better image quality. The encoded MPEG1 video stream with audio was transferred to the remote location in full frame resolution using a bandwidth of about 6Mb/s (multiple T1 lines). When our encoder was upgraded to the MPEG2 standard, the quality of the video image was adequate for the operating field endocamera. A bandwidth of 8Mb/s produced a high quality video stream at the remote site. Using MPEG streams, the video signal could be transferred from the endocamera to the remote location for consultancy or education.

As known in the circles of telemedicine/telesurgery, the basic cost of the presented system is known. It includes standard telemedicine equipment which should be mounted at any institution for the institution to be connected to the telemedicine network. This equipment allows for transfer of live video image of the operative field, CT images, commentaries, surgery guidance, etc. In addition, a computer with appropriate volume rendering software support should be introduced in the operating theater. All these devices are now standard equipment available on the market at quite reasonable prices. For comparison, the overall price of these devices is by far lower than the price of a system for image guided surgery, currently mounted in many hospitals all over the world. Once installed and tested, the whole system can be used without any special assistance of technical personnel (computer experts and/or network specialties). Clinical institutions (e.g., Klapan Medical Group Polyclinic, Zagreb, Croatia), which have expert clinical work places, employ properly educated and trained technical personnel who can be readily included in the preparation and performance of tele-3D-C-FESS surgery as well as in the storage of the procedure itself

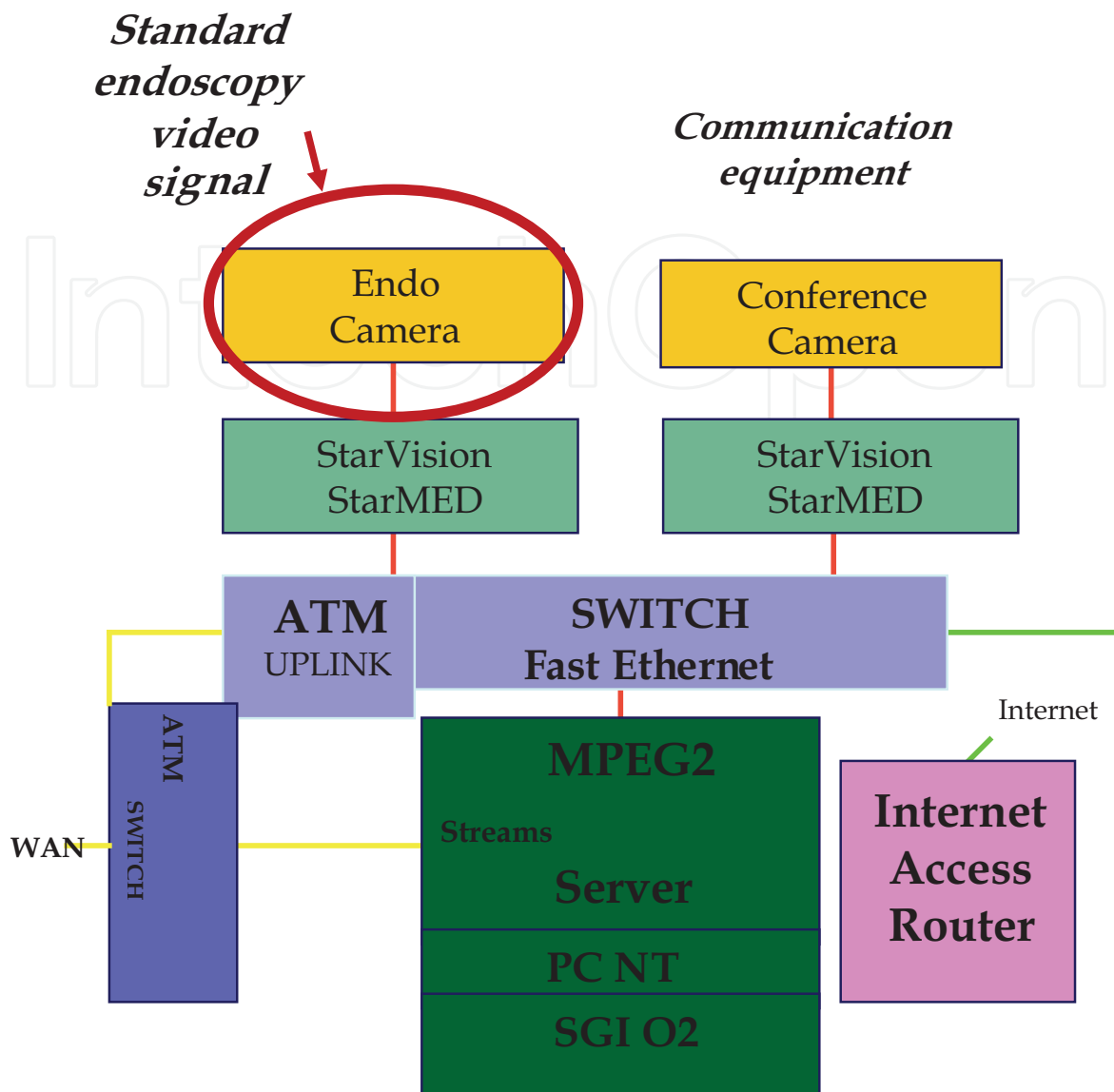


Fig. 4. Using routable shared and switched Ethernet connections, 25 frames/sec were transferred in full PAL resolution (taken with permission from Klapan et al., Otolaryngology Head Neck Surg, 2002)

and of intraoperatively generated computer 3D animations. It is of the higher importance, because if we would like to understand the idea of virtual reality (VR), it is necessary to recognize that the perception of surrounding world created in our brain is based on information coming from the human senses and with the help of a knowledge that is stored in our brain. The usual definition says that the impression of being present in a virtual environment, such as virtual endoscopy (VE) of the patient's head, that does not exist in reality is called virtual reality. The physician, e.g., any member of our surgical team, has impression of presence in the virtual world and can navigate through it and manipulate virtual objects. A VR system may be designed in such a way that the physician is completely immersed in the VE.

It should be made clear that the main message of the tele-3D-CA-endoscopic surgery, as differentiated from the standard telesurgeries worldwide, is the use of the 3D-model operative field, and thus of VE and VS (Fig. 5).



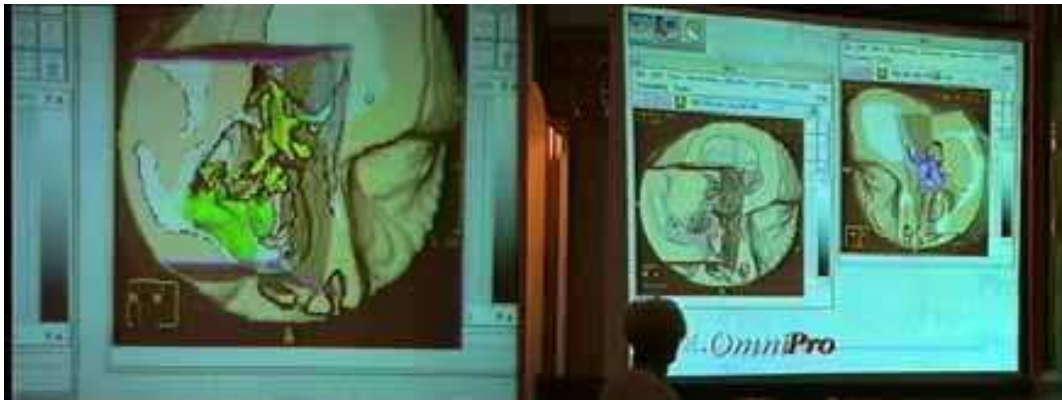

Fig. 5. Virtual endoscopy, realized during our tele-3D-C-FESS in 1999 (taken with permission from Klapan et al., J Telemed Telecare, 2002 and Klapan Medical Group Polyclinic, Zagreb, Croatia)

Research in the area of 3D image analysis, visualization, tissue modelling, and human-machine interfaces provides scientific expertise necessary for developing successful 3D visualization of the human head during 3D-CAS (Fig. 6), Tele-3D-CAS (Fig. 7), and other VR applications. Such an impression of immersion can be realized in any medical institution using advanced computers and computer networks that are required for interaction between a person and a remote environment, with the goal of realizing tele-presence.

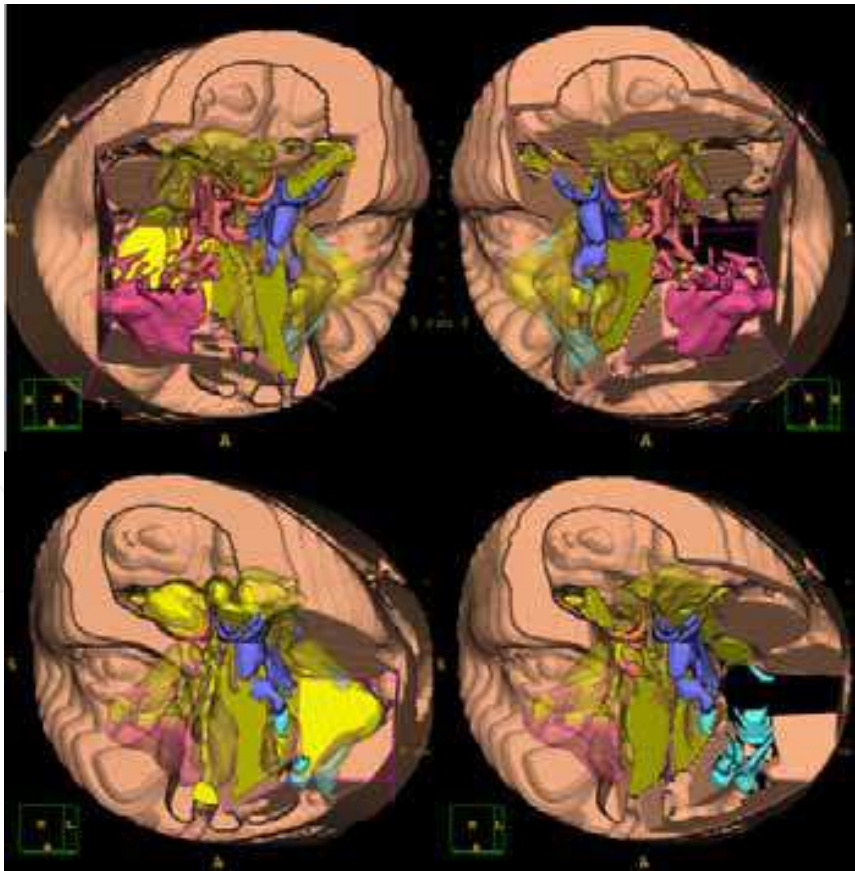


Fig. 6. Transmission of 3D models as virtual endoscopy (VE) of the human head, realized during one of the first Croatian 3D-CA-navigation endoscopic surgeries in October 1994 (taken with permission from Klapan et al., J Telemed Telecare, 2002)

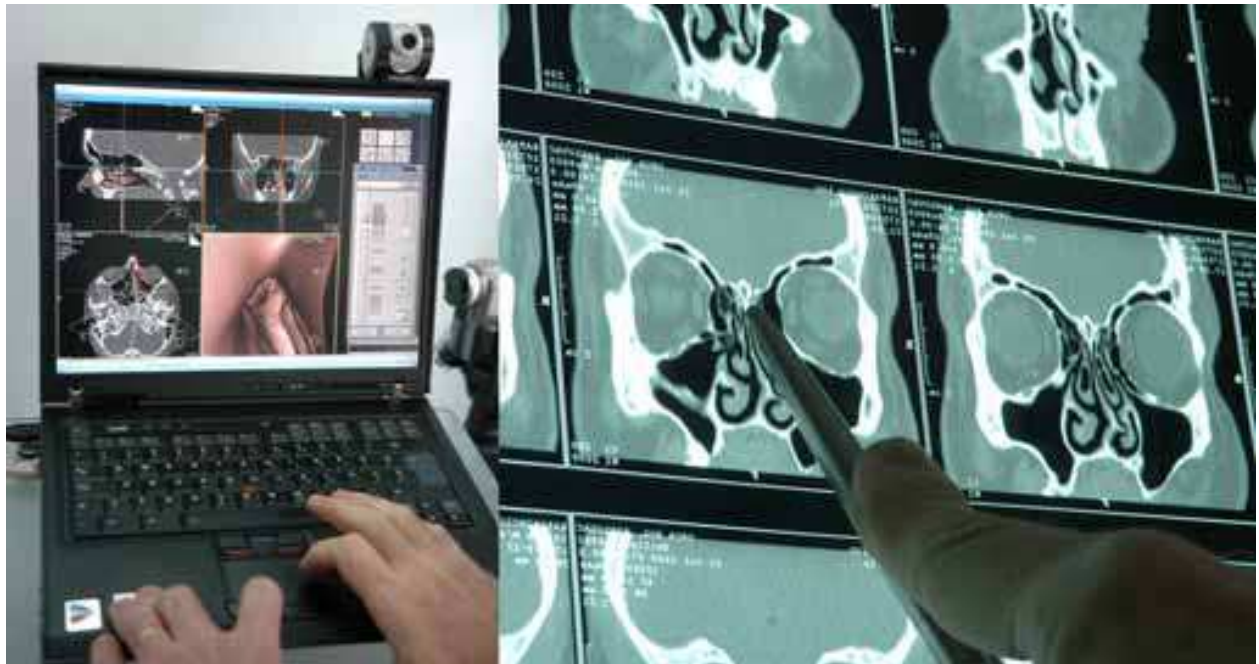

Fig. 7. 3D-VE-navigation of the human head during tele-3D-computer assisted-FESS (taken with permission of Klapan Medical Group Polyclinic, Zagreb, Croatia)

In human medicine, extremely valuable information on anatomic relationships in particular regions while planning and performing endoscopic surgery is provided by high quality CT or MRI diagnosis (Mladina et al., 1995), thus contributing greatly to the safety of this kind of surgery (Rišavi et al., 1998). Once created from 2D cross-section images with 3D modeling software, virtual 3D surface models or volume rendered models can be further used in virtual reality for measuring, operation planning, simulations, finite element analysis. However, virtual 3D models also can be used in actual reality for tangible models obtained from rapid prototyping applications. Rapid Prototyping (RP) techniques look most promising to satisfy medical need for tangible models. While prototyping is a usually slow and expensive process of building pre-production models of a product to test various aspects of its design, rapid prototyping techniques are methods that allow quick production of physical prototypes (Fig. 8.). Nowadays even more often, rapid prototyping techniques provide to medicine actual products e.g. prosthesis and implants with the important benefit in significant shortening of the Time to Market (Raos & Galeta, 2004). The mode of computer visualization of anatomic structures (Elolf et al., 1998) of the human body used to date could only provide diagnostic information and possibly assist in the preoperative preparation. Intraoperative use of computer generated operative field 3D-model has not been widely adopted to date. The intraoperative use of computer in real time requires development of appropriate hardware and software to connect medical instrumentarium with the computer, and to operate the computer by thus connected instrumentarium and sophisticated multimedia interfaces. In rhinology, such an revolutionary approach is of paramount importance for the surgeon because of the proximity of intracranial structures and limited operative field layout hampering spatial orientation during the “standard” operative procedure.

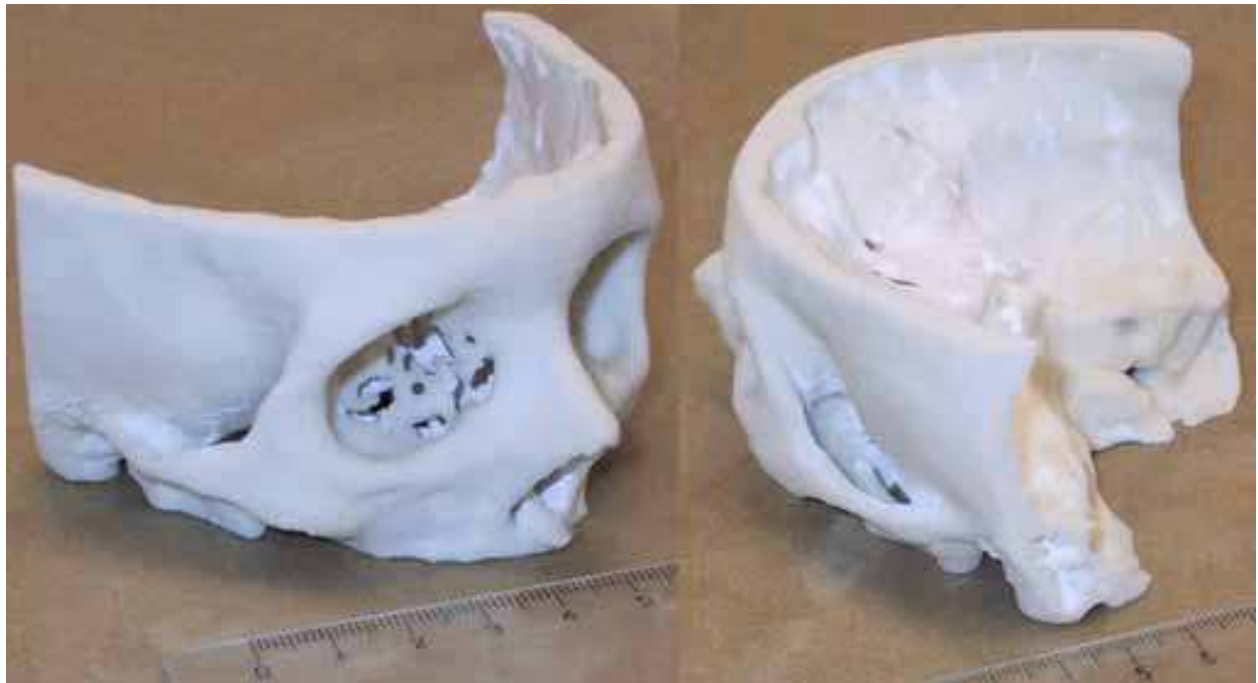

Fig. 8. Real 3D model produced with Rapid Prototyping technique

## 2. Methods

### 2.1 High quality diagnosis (DICOM standard)

High quality diagnostic image is the main prerequisite for appropriate utilization of computer systems during the preparation, performance and analysis of an operative procedure (Fig. 9.). Development of a system for data exchange between multiple medical diagnostic devices as well as between diagnostic devices and computer networks has led to the establishment of DICOM (digital imaging and communication in medicine) standards describing the forms and modes of data exchange.

Before the introduction of DICOM standards, image recordings were stored on films, where the information obtained from the diagnostic device was in part lost (Knezović et al., 2007). In ideal conditions, sixteen different image levels could be distinguished on films at the most. When film images were to be stored in computer systems, films had to be scanned, thus inevitably losing a part of significant data and probably introducing some unwanted artefacts. The level setting and window width to be observed on the images could not be subsequently changed. Visualization of the image on the diagnostic device monitor was of a considerably higher quality, thus it was quite naturally used for record receipt and storage in computer media. Video image allows for the receipt of 256 different levels at the most. Neither it is possible to subsequently modify the level setting and window width to be observed on the images that have already been stored in the computer system. When stored in computer systems by use of DICOM protocol, images are stored in the form generated by the diagnostic device detector. These image recordings can then be properly explored by use of powerful computer systems. This is of special relevance when data in the form of images are to be used for complex examinations and testing, or in preoperative preparation where rapid and precise demarcation between the disease involved and intact tissue is required (Knezović et al., 2007). It is also very important for the images to be visualized in various



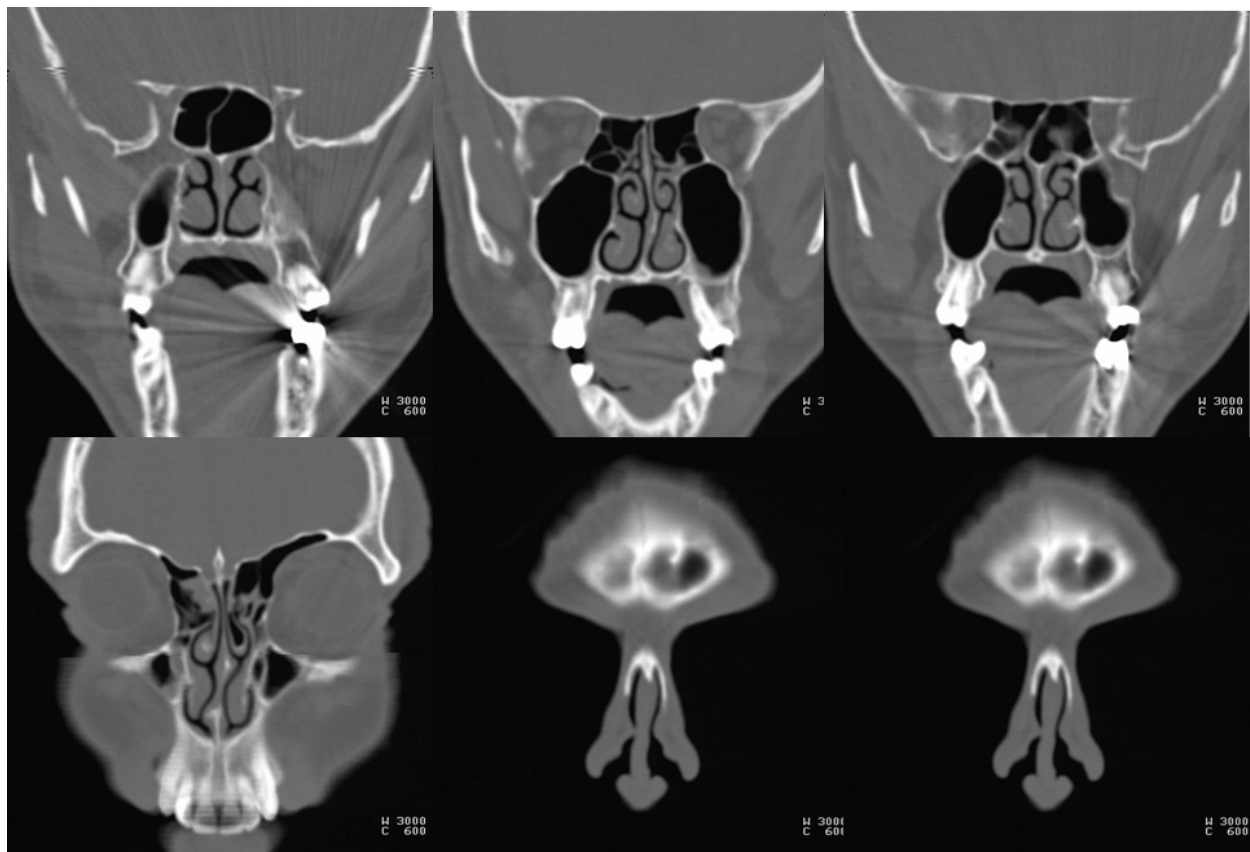

Fig. 9. MSCT slices of the nose and paranasal sinuses (taken with permission of Klapan Medical Group Polyclinic, Zagreb, Croatia)

forms and from different aspects and then – which is most demanding indeed – to develop spatial models to aid the surgeon in preparing and performing the procedure as well as in postoperative analysis of the course of the procedure.

The entire operative procedure can be simulated and critical areas avoided during the real procedure by employing real patient images in the operation preparatory phase using complex spatial models and simulated operative field entry (VE,VS) (Klapan et al., 2001).

## 2.2 Preoperative preparation

The real-time requirement means that the simulation must be able to follow the actions of the user that may be moving in the virtual environment. The computer system must also store in its memory a 3D model of the virtual environment (3D-CAS models). In that case a real-time virtual reality system will update the 3D graphical visualization as the user moves, so that up-to-date visualization is always shown on the computer screen. For realistic simulations it is necessary for the computer to generate at least 30 such images per second, which imposes strong requirements to computer processing power.

Use of the latest program systems enables development of 3D spatial models, exploration in various projections, simultaneous presentation of multiple model sections and, most important, model development according to open computer standards (Open Inventor) (Knezović et al., 2007). Such a preoperative preparation can be applied in a variety of program systems that can be transmitted to distant collaborating radiologic and surgical work sites for preoperative consultation as well as during the operative procedure in real time (telesurgery) (Klapan et al., J Telemed Telecare, 2002) (Fig. 10.).



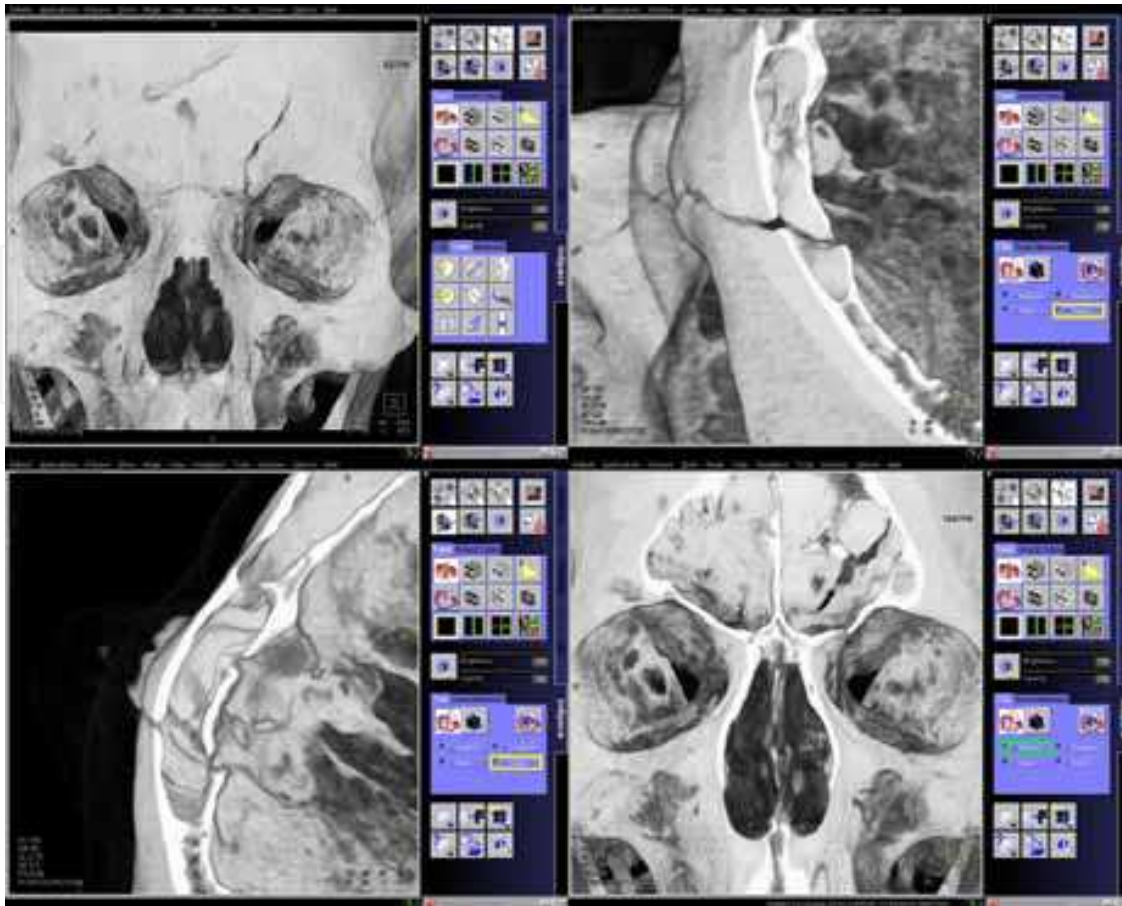


Fig. 10. Our 3D models of the human head in different projections. Virtual reality systems may be used for visualization of anatomical structures, virtual endoscopy, 3D-image-guided surgery as well as of pathology and/or anatomy during the planning of therapy (taken with permission from Belina et al., 2009)

Such a model in medical applications will enable simulation of changes that the tissue undergoes when compressed, stretched, cut, or palpated. The computer must then generate, in real-time, an appropriate visualization of the tissue as it is deformed by the user. Biological tissue modeling represents an important research area with applications in many medical areas. In this context, physics-based deformable models represent a powerful simulation tool. In the context of VR applications, 3D visualization techniques in real-time are particularly important. The goal here is to develop methods for fast and realistic visualization of 3D objects that are in the VE. Advanced technologies of exploring 3D spatial models allow for simulation of endoscopic surgery and planning the course of the future procedure (VE) or telesurgery (Tele-VE). By entering the models and navigating through the operable regions the surgeon becomes aware of the problems he will encounter during the real operation. In this way, preparation for the operation could be done including identification of the shortest and safest mode for the real operation to perform (Klapan, J Telemed Telecare, 2002; Klapan, Am J ORL, 2002) (Fig. 11).

The two main approaches to visualization are surface rendering and volume rendering (Burtscher et al., 1998; Vannier, 1996). Surface rendering is a classical visualization method where object surfaces are approximated using a set of polygonal shapes such as triangles. Most general-purposed computers use this approach and such wide availability represents

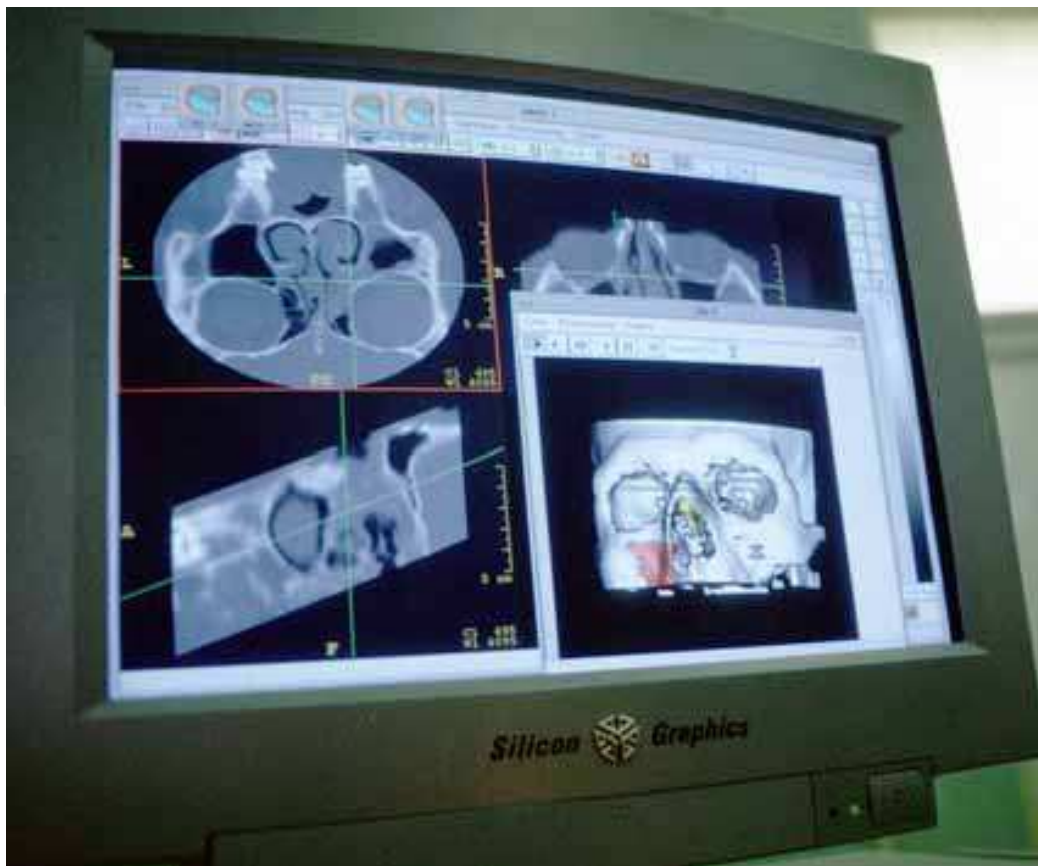


Fig. 11. An example of 3D-CA-FESS of the nose and paranasal sinuses with simulation and planning of the course of subsequent endoscopic operation (VE) (November 1994) (taken with permission from Klapan et al., Orbit 2001)

an important advantage of surface rendering. A disadvantage is that surface rendering cannot represent volume interior. Volume rendering can create very nice visualizations of volume interiors, but a disadvantage is that a special hardware is required for acceleration because of computational complexity.

### 2.3 Virtual endoscopy

Siemens Somatom Emotion 16 MSCT (from 2004) and 64 MSCT (from 2006) scanners were used for image acquisition from the very beginning of our VE activities (2004). CT images were stored in DICOM format and transferred to Xeon-based workstation running standard postprocessing software 3D Syngo CT 2006G from Siemens Medical Systems. Initial postprocessing was performed by radiologist and ENT specialist working together on In-space and Fly-through software. Working area during fly-through was divided in four windows showing CT image reconstruction in three major planes and resulting 3D rendered VE view for current position of virtual endocamera. Fly-through path planning was performed by moving mouse pointing device. Recordings of VE images together with appropriate CT images in three major planes during fly-through was performed with Camtasia recorder in real-time. 3D Syngo CT 2006G is the overall platform for the imaging workstation of Siemens Medical Systems. VE on the Syngo platform is performed using ray casting method with space leaping as major acceleration technique, and provides an automatic navigation mode (Fig. 12.).

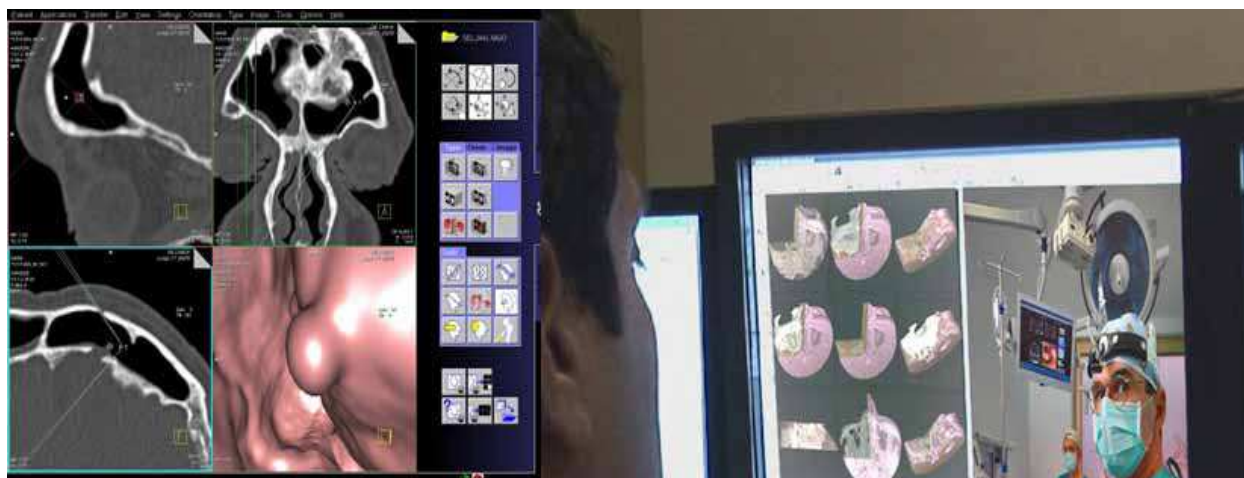


Fig. 12. An example of VE of the nose and paranasal sinuses with CT image reconstruction in three major planes and resulting 3D rendered VE view for current position of virtual endocamera (taken with permission from Belina et al. 2009, and Klapen Medical Group Polyclinic, Zagreb, Croatia)

We performed 644 VEs of the nasal cavity, skull base, and paranasal sinuses of patients with different pathology of paranasal sinuses as a part of diagnostic or preoperative management, such as: chronic sinus diseases, maxillary sinus cancer, different head traumas which involved paranasal sinuses, with multifragment fractures of maxillary sinus walls, ethmoids and lamina papyracea as well as the fracture of the sphenoid sinus wall.

## 2.4 Rapid prototyping models

In a rapid prototyping process, the product is firstly designed on a computer and then created based on the computer data. Therefore an essential prerequisite is the digital computer representation, usually made in a 3D geometrical modelling computer system like a CAD system, a 3D scanner, computer tomography, etc. Precision of a computer representation is a key parameter for controlling the tolerances of the future model. An important difference between rapid prototyping and traditional techniques is the fact that most of these new techniques build parts by adding material (e.g. layer by layer) instead of removing it (Raos & Galeta, 2004).

The first commercial rapid prototyping process - Stereo Lithography was brought on the market in 1987. Today, there are many different rapid prototyping techniques with high accuracy and large choices of materials available on the market. However, some of specially developed rapid prototyping techniques are still not commercialized. The most successfully developed techniques are: Stereo Lithography, Selective Laser Sintering, Laminated Object Manufacturing, Fused Deposition Modelling, Solid Ground Curing and nowadays the most popular 3D Printing.

During last two decades rapid prototyping techniques have been tested and used in many different areas in medicine (Petzold et al., 1999). Such areas include:

- The physical models of human organs that are extremely effective in realizing the anatomy and enhancing discussion and collaboration among teachers, students, researchers and physicians;
- Virtual planning and simulation of operation for orthopaedic surgery, vascular surgery and maxilla surgery with complex spatial relationships;



- Prosthesis like titanium dental cast crowns, free of porosity, with excellent functional contour and a smooth surface finish, could be obtained from the first casting trial;
- Implants are also very interesting for possible rapid production, therefore many researches' have been;
- Biomedical devices like a rapid produced polymeric implant consisted of a drug embedded in a polymeric matrix that was surgically implanted into the body.

Some of common advantages of rapid prototyping techniques when used in medicine are: speed; manufacturing flexibility; high degree of control over part microstructure; wide variety of engineering and medical materials.

Existing rapid prototyping techniques also have some common shortcomings like: lack of required mechanical properties depending on material combination; low accuracy; high computational demands and poor bio-compatibility. Yet, most of listed shortcomings can be successfully avoided in particular case with proper selection of techniques and materials (Galeta et al., 2008).

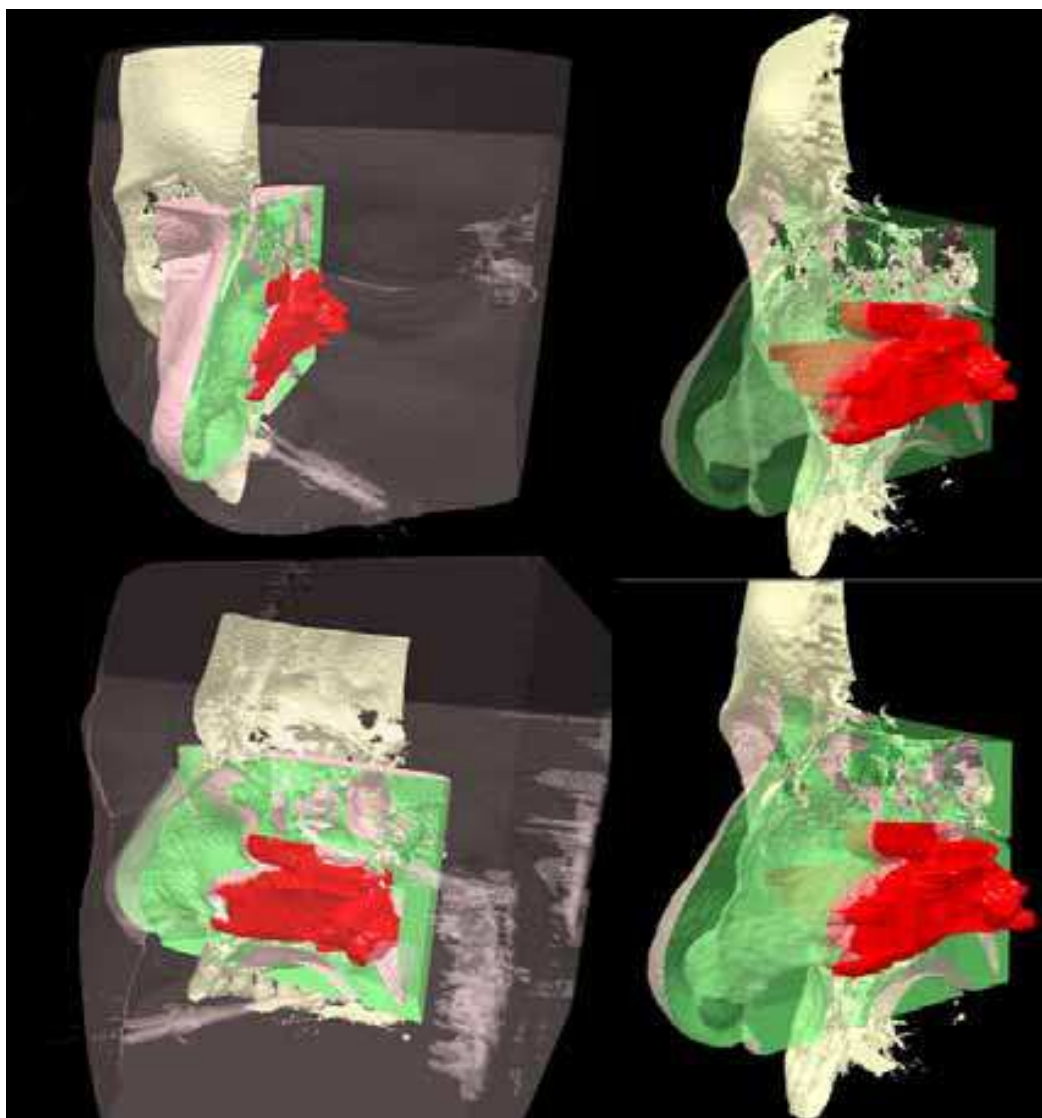


Fig. 13. Rapid prototyping models (taken with permission of Klapan Medical Group Polyclinic, Zagreb, Croatia)



## 2.5 Computer assisted navigation surgery

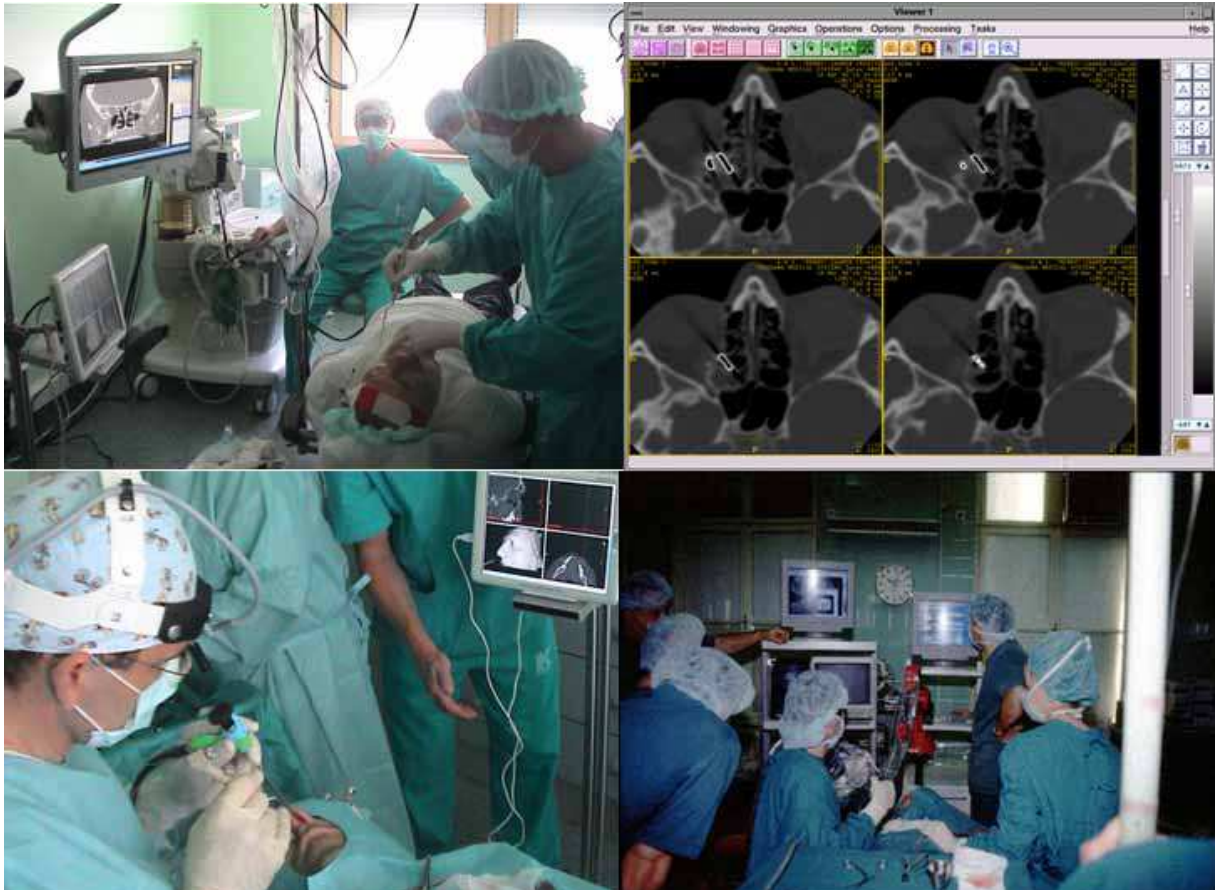

Fig. 14. Computer assisted navigation operations (taken with permission of Klapan et al., Orbit, 2001., and Klapan Medical Group Polyclinic, Zagreb, Croatia)

## 2.6 Computer assisted telesurgery

Computer technologies allow for computer assisted surgery to be performed at distance. The basic form of telesurgery can be realized by using audio and video consultations during the procedure. Sophisticated endoscopic cameras show the operative field on the monitor mounted in the operating theater, however, the image can also be transmitted to a remote location by use of video transmission. The latest computer technology enables receipt of CT images from a remote location, examination of these images, development of 3D spatial models, and transfer of thus created models back to the remote location (Klapan et al., 2006). All these can be done nearly within real time. These procedures also imply preoperative consultation. During the surgery, those in the operating theater and remote consultants follow on the patient computer model the procedure images, the 'live' video image generated by the endoscopic camera, and instrument movements made by the remote surgeon (Klapan et al., 1999). Simultaneous movement of the 3D spatial model on the computers connected to the system providing consultation is enabled (Klapan et al., J Telemed Telecare 2002; Klapan et al., ORL H&N Surg, 2002). It should be noted that in most cases, intraoperative consultation can be realized from two or more locations, thus utmost care should be exercised to establish proper network among them.

The extreme usage of computer networks and telesurgery implies the use of robot technologies operated by remote control. In such a way, complicated operative procedures could be carried out from distant locations. The main idea considering the use of computer networks in medicine is: *it is preferable to move the data rather than patients* (Fig. 15). In the future, we can expect more applications of VR in medicine. Advances in computer science will make possible more realistic simulations. VR, 3D-CAS, and Tele-3D-CAS systems of the future will find many applications in both medical diagnostics and computer-aided intervention.

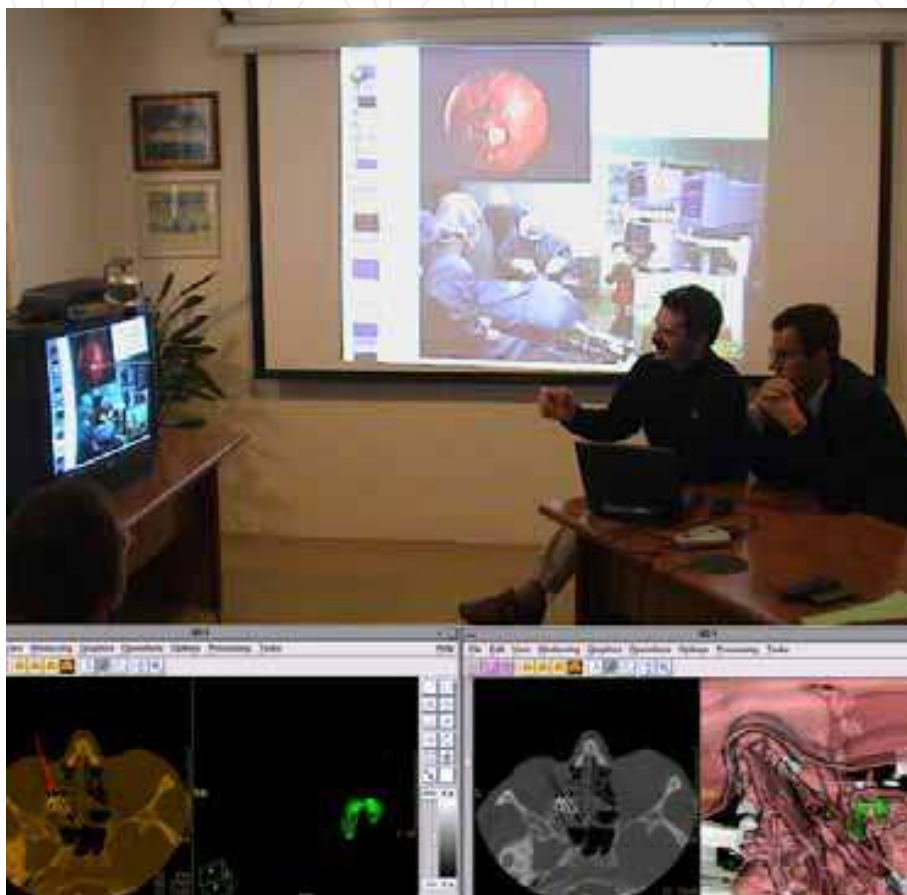

Fig. 15. An example of our tele-3D-CA-surgeries of the nose and paranasal sinuses in 1998/2000., representing the use of 3D imaging of the organ of interest (e.g using CT, or MRI) (taken with permission from Klapan et al., Otolaryngology Head Neck Surg 2002., and Klapan Medical Group Polyclinic, Zagreb, Croatia)

## 2.7 Computer networks

Very important factor for realization of 3D-CAS, and Tele-3D-CAS applications which represent a typical VR philosophy in routine daily diagnostic and surgical practice, and VR systems is a fast computer network. The network is the basis for any tele-activity. Fast computer networks are also the basis for telemedical applications, which may also be viewed as a kind of teleoperation systems.

Following the application of computers in surgery and connecting diagnostic devices with computer networks by use of DICOM protocol, the next step is directed toward connecting these local computer networks with broad range networks, i.e. within a clinical center, city,

country, or countries. The establishment of complex computer networks of diagnostic systems across the country offers another significant application of computer networks in medicine, i.e. telemedicine. Current computer networks using ATM technology allow for very fast and simultaneous communication among a number of physicians for joint diagnostic or therapeutic consultation. Textual, image, audio and video communication as well as exchange of operative field spatial models are thus enabled. Patient images and 3D spatial models can be simultaneously examined by a number of physicians, who then can outline and describe image segments by use of textual messages, indicator devices, sound or live image. The course and conclusions of such a consultation can be stored in computer systems and subsequently explored, used or forwarded to other users of the computer assisted diagnostic system.

The use of computer networks in medicine allows for high quality emergency interventions and consultations requested from remote and less equipped medical centers in order to achieve the best possible diagnosis and treatment (e.g., surgery). In addition to this, through consultation with a surgeon, a physician in a remote diagnostic center can perform appropriate imaging of a given anatomic region, which is of utmost importance for subsequent operation to be carried out by the consultant surgeon from the remote hospital center.

## **2.8 Video technologies**

During telesurgical transmission, two video signals have to be transferred from the OR site and one video signal from every remote site involved in the telesurgery procedure. As about 24 Mb/s of bandwidth are needed for the native video signal, and there are only 155 Mb/s or multiple 2Mb/s lines of bandwidth, the video signals must be compressed using standard video compression systems (Satava, 1996; Klapan et al., 1999). At each of the four locations involved in the telesurgical procedure there was a remotely controlled video switch with 8 video inputs and 8 video outputs. At the expert location, remote from the OR, there was a video processor for the acquisition of all video signals from all sites involved in the telesurgery procedure and software for the remote control of all video inputs/outputs and pan/tilt/zoom cameras of all locations. Thus, from this point in the telesurgery network, a consultant or conference moderator (Schlag et al, 1998) can view all the video signals or just the primary display. For all these possibilities, a bandwidth of at least 155Mb/s asynchronous transfer mode (ATM OC-3) is needed.

## **2.9 Network technologies**

ATM switches and adaptation layer type 5 (AAL-5) were used for video transmission and native or LANE for TCP/IP (transmission control protocol/internet protocol) computer communications in our tele-3D-CAS.

## **2.10 Collaboration**

InPerson teleconferencing software and the native TCP/IP network was used for communication between all sites in our tele-3D-CAS. Consultations using computer images and 3D-models were performed using the video network; outputs from the computer were encoded into video stream and transmitted to the remote locations through video communication protocols. The advantage is that only standard video equipment, without any type of computer, needs to be installed at the remote location; the disadvantage is the image or 3D-model from the local computer can only be viewed at the remote location and cannot be manipulated with computer software.

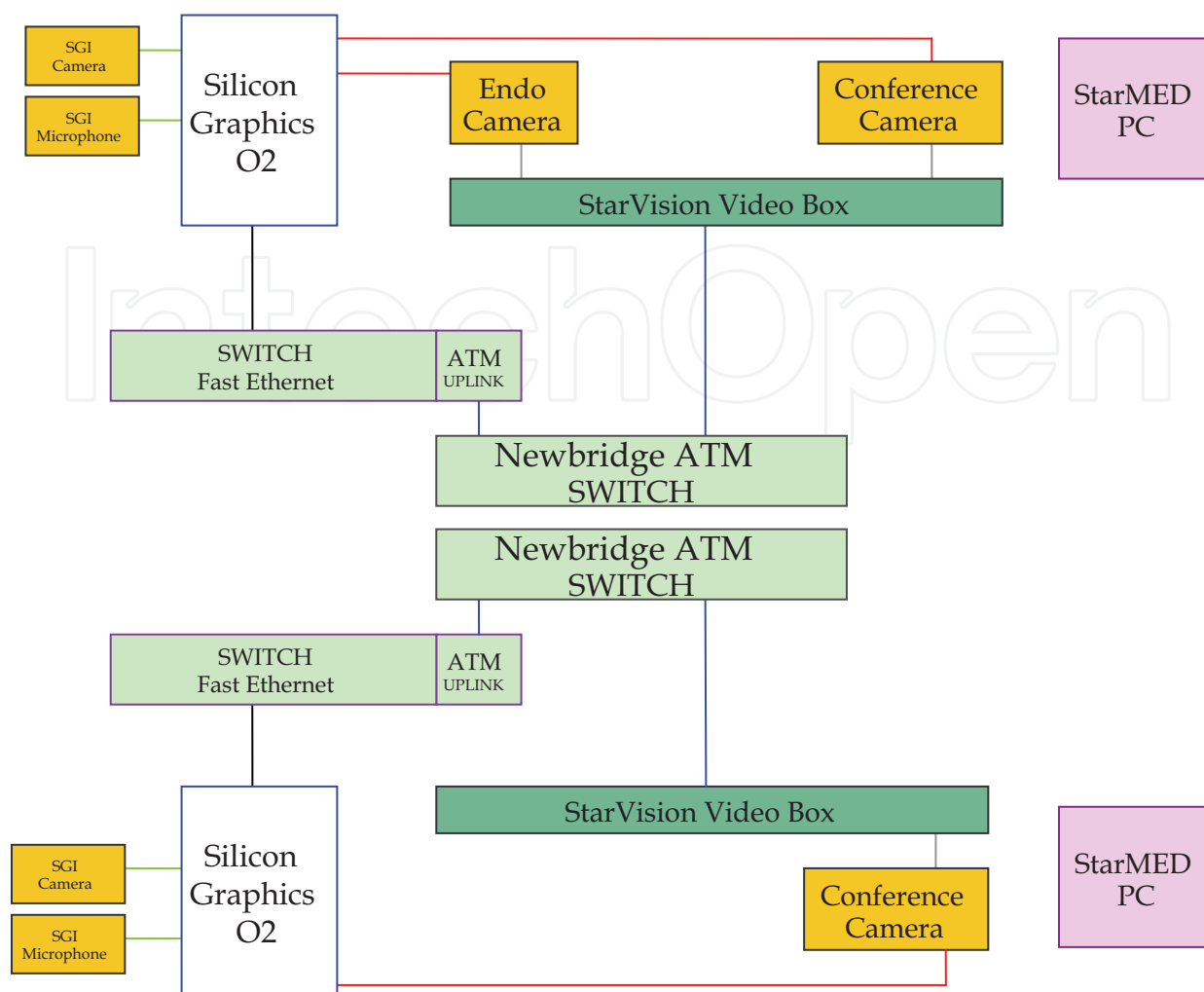


Fig. 16. Our Telesurgical equipment in ATM Network (OC-3, 155Mb/s) (taken with permission from Klapan et al., J Telemed Telecare 2002)

Video records of the procedure, MPEG streams of the procedure in combination with CT images and 3D models are essential for the creation of a computer database system for education and the preparation of future surgical procedures (Broadcasting, Tele-education, DVD-ROM, CD-ROM, www). In the real procedure, 3D computer models (Open Inventor) can be texture-mapped using the live video signal from the endocamera. The live video signal can be positioned using a 3D digitizer or any other spatial localizer. The texture mapped 3D model, with live video signal during the surgery, provides the surgeons with a more realistic computer presentation of the real surgical field. In our the 1<sup>st</sup> tele-3D-CAS, we used the following (Klapan et al., J Telemed Telecare 2002) (Fig. 16):

- SGI O2 workstation,
- Newbridge ATM Switch,
- ATM switched networks,
- Video streams over AAL-5,
- Computer communications over LANE (TCP/IP),
- 3Com Inverse Multiplexing (4xT1),
- Optivision MPEG1/MPEG2 encoders,
- Newbridge M-JPEG/MPEG1/MPEG2 encoders.



Network topologies:

- point to point T1 lines,
- nonroutable/routable shared FastEthernet/Ethernet,
- nonroutable/routable switched FastEthernet/Ethernet,
- ATM switched networks with AAL-5 and LANE,
- multiple T1 lines (today).

Usage of collaboration tools (H.120, H.323):

- SGI InPerson (Video, Audio, WhiteBoard),
- SGI Meeting (Whiteboard, Application Share/Collaboration),
- Microsoft NetMeeting(Video, Audio, Whiteboard, Application Share/Collaboration),
- StarVison StarMED, StarED.

From the very beginning of our 3D-CAS (Klapan et al., 2006; Klapan et al., 2008), and tele-3D-CA-surgeries (Klapan et al., 1997), the modeling was done by use of the VolVis, Volpack/Vprender, GL Ware programs on a DEC Station 3100 computer .With the advent of 3D Viewnix V1.0 software, we started using this program, and then 3D Viewnix V1.1 system, AnalyzeAVW system, T-Vox system and OmniPro 2 system on Silicon Graphics O2, Origin200 and Origin2000 computers. Our team used several standards to encode live video signals in telesurgery, such as M-JPEG, MPEG1, MPEG2 and MPEG4. For conferencing/consultation cameras used between two or more connected sites during the surgery, we used JPEG and MPEG1 stream with audio. Operation rooms (OR) were connected using several computer network technologies with different bandwidths, from T1, E1 and multiple E1 to ATM-OC3 (from 1Mb/s to 155Mb/s). For computer communications using X-protocol for image/3D-models manipulations, we needed an additional 4Mb/s of bandwidth, instead of the 1Mb/s when we used our own communication tools for the transfer of surgical instrument movements (Table 1.).

	First tele-3D-CAS	Second tele-3D-CAS
<b>Video technology</b>	M-JPEG, H.323	MPEG1/2, H.323
<b>Network technology</b>	ATM OC-3 155Mb/s	Inverse multiplexing 4xT1 8Mb/s
<b>Collaborative computing</b>	N.A.	SGImeeting, NetMeeting, T.120
<b>Consultancy</b>	Through video	Collaborative tools T.120 Through video
<b>Preoperative consultancy</b>	Through video InPerson, H.323	Collaborative computing T.120, H.323
<b>Number of involved locations</b>	3	2
<b>Video acquisition/processing</b>	Multiple In/Out (8/8) Quad split	N.A. Manually controlled switch
<b>Number of video signals</b>	2 from O.R. 1 from other sites	1 from O.R. 1 from other sites
<b>Hardware</b>	SGI O2, PC	SGI O2
<b>Software</b>	SGI IRIX, MS Windows, StarMED, OmniPro, InPerson	SGI IRIX, MS Windows, OmniPro, SGImeeting, NetMeeting, InPerson

Table 1. Comparison between our first and second Tele-3D-CAS (FESS) (taken with permission from Klapan et al., J Telemed Telecare, 2002)

### 3. Discussion

In 1992, when we tried to establish the first system implementation for our CA-surgery, a scientific research rhinosurgical team was organized at the University Department of ENT-Head & Neck Surgery, Zagreb University School of Medicine and Zagreb University Hospital Center in Zagreb, who have developed the idea of a novel approach in head surgery. This computer aided FESS with 3D-support has been named 3D-CA-FESS. The first 3D-CA-FESS operation in Croatia was carried out at the Šalata University Department of ENT, Head & Neck Surgery in June 3, 1994., when a 12-year-old child, was inflicted a gunshot wound in the region of the left eye. Status: gunshot wound of the left orbit, injury to the lower eyelid and conjunctiva of the left eye bulb. Massive subretinal, retinal and preretinal hemorrhage was visible. The vitreous diffusely blurred with blood. The child was blinded on the injured eye (today, sixteen years after the operation, 29 year old patient shown in the Fig. 17) (Klapan et al., 1996, 1997, 2002).

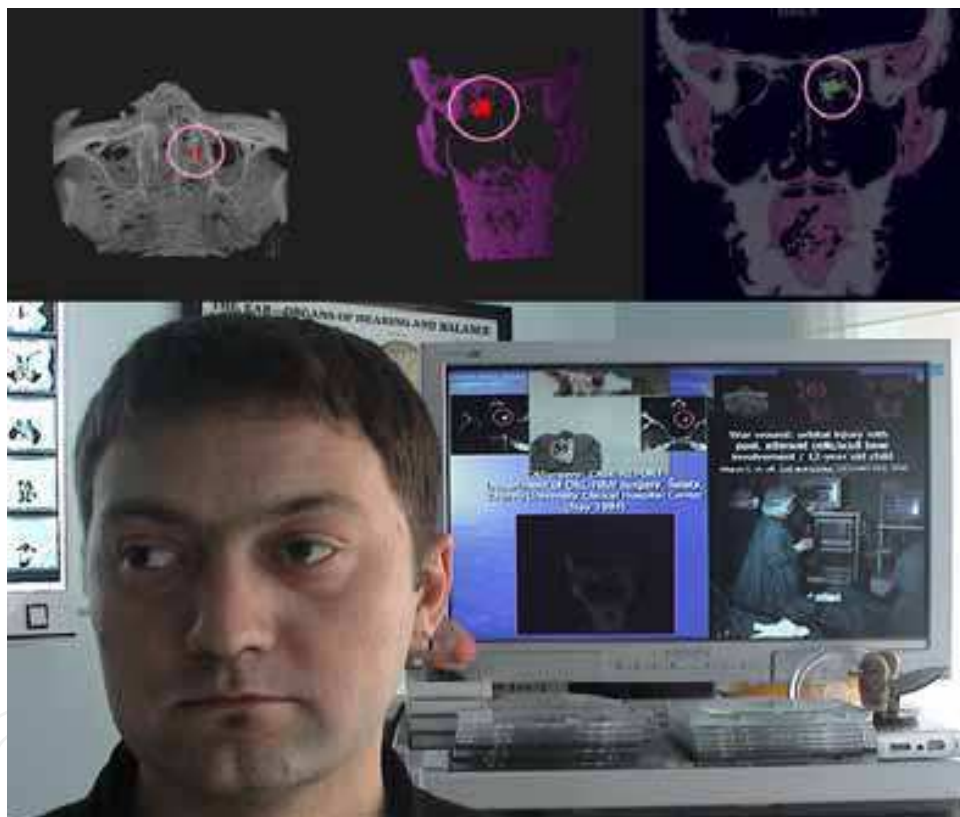


Fig. 17. Different 3D models with evidence of the metallic foreign body. Using the *static 3D model* elaborated from 2D CT sinus section, we obtained relative relationships of the borderline areas that are important for the diagnosis of pathologic conditions in the region, which proved to be a significant improvement in comparison with 2D visualization in the form of stratified images (taken with permission from Klapan et al., Am J Otolaryngol, 2002. and Klapan Medical Group Polyclinic, Zagreb, Croatia)

Additionally, with due understanding and support from the University Department of ENT, Head & Neck Surgery, Zagreb University Hospital Center; Merkur University Hospital; T-Com Company; InfoNET; and SiliconMaster, in May 1996 the scientific research rhinosurgical team from the Šalata University Department of ENT-Head & Neck Surgery organized and

successfully conducted the first distant radiologic-surgical consultation (teleradiology) within the frame of the 3D-C-FESS project. The consultation was performed before the operative procedure between two distant clinical work posts in Zagreb (Šalata University Department of ENT, Head & Neck Surgery and Merkur University Hospital) (outline/network topology). In October 1998, and on several occasions thereafter, the team conducted a number of first tele-3D-computer assisted operations as unique procedures of the type not only in Croatia but worldwide ([www.mef.hr/MODERNRHINOLOGY](http://www.mef.hr/MODERNRHINOLOGY) and [www.poliklinika-klapan.com](http://www.poliklinika-klapan.com)) (Klapan et al., 1997; Klapan et al., 1999). During the first telesurgery of this kind, a surgical team carrying out an operative procedure at the Šalata ENT Department, Zagreb University School of Medicine and Zagreb Clinical Hospital Center, received instructions, suggestions and guidance through the procedure by an expert surgeon from an expert center. The third active point was the Faculty of Electrical Engineering and Computing, where ENT specialists, students and residents took an active part in the entire surgical procedure. This tele-3D-CA-FESS surgery, performed as described above, was successfully completed in 15 minutes (Fig. 18).

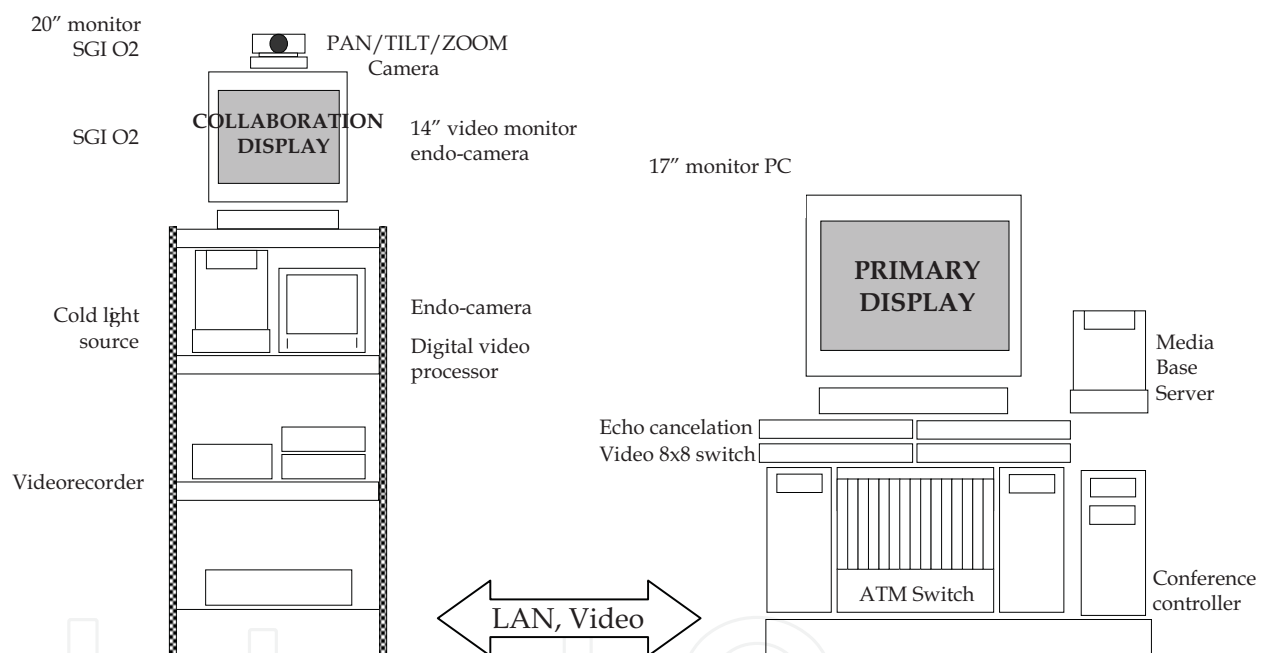


Fig. 18. An example of our Tele-3D-C-FESS surgery initially performed in 1998 (taken with permission from Klapan et al., Otolaryngology Head Neck Surg, 2002)

The complex software systems allow visualization of a 2D CT or MRI section in its natural course (the course of examination performed), or in an imaginary, arbitrary course. Particular images can be transferred, processed and deleted, or can be presented in animated images. The series of images can be changed, or images can be generated in different projections through the volume recorded.

Before the development of 3D spatial model, each individual image or a series of images have to be segmented, in order to single out the image parts of interest. 3D-model completely presents the relative relations of borderline areas that are of utmost diagnostic importance, which is a considerable advancement compared with standard 2D stratified imaging. Comparative analysis of 3D anatomic models with intraoperative finding shows the 3D volume rendering image to be very good, actually a visualization standard that

allows imaging likewise the real intraoperative anatomy (Mann & Klimek, 1998; Hamadeh et al., 1998).

The technique of examination intended to realize in the proposed study provides, according to many authors, optimal visualization of the paranasal sinus anatomy. Moreover, by use of this approach, some substantial advancements are achieved in the diagnosis of the pathologic state of paranasal sinuses, based on CT analysis, e.g. (a) basic CT diagnostics has become an important aid in the diagnosis of chronic sinusitis, in terms of the follow-up and prognosis of the course and treatment outcome; (b) additional axial or coronal sections are avoided by the development and use of 3D model (so-called volume-rendering technique) for diagnostic purposes; (c) as indicated in (b), the dose of irradiation to which the patient is exposed is considerably reduced by the use of volume rendering technique; etc.

Therefore, we made endeavors to implement all these concepts and advantages of the new mode of 3D visualization not only in daily 3D-CAS performed in our operating theaters but also as a specific form of telesurgery with 3D computer assisted support, currently a completely new and original type of telesurgery in the world, with the use of most sophisticated computer technology in any OR. The surgeon and consultants view four split video signals (quad split video processing) on the primary video display: one from the endocamera, one from the OR camera, one from the first remote site and one from the second remote site. However, during real surgery, all locations involved in such telesurgery usually view only the video signal from the endocamera procedure on their primary displays. In real surgery, there is one patient at one location included in the "telesurgical procedure", with one or more consultants at one or more remote locations (the local location is where the surgery is performed, and remote locations are the other locations included in the telesurgery procedure) (Sezeur, 1998). As we already discussed, two video streams (the endocamera and the conference camera) have to be transferred from the local location (patient location), and one video stream (the conference camera) has to be transferred from each remote location (consultants). At each location, video monitors are needed for video streams from any other location included in the telesurgery procedure (up to four video streams on one large video monitor, quad-split, can be used). An LCD/TFT video projector can be put in the OR. Using such tele-CA-system, the possibility of exact preoperative, non-invasive visualization of the spatial relationships of anatomic and pathologic structures, including extremely fragile ones (Hauser et al., 1997, Vinas et al., 1997), size and extent of pathologic process (Elolf et al., 1998; Burtcher et al., 1998), and to precisely predict the course of surgical procedure (Mann & Klimek, 1998), definitely allows the surgeon in any 3D-CAS or Tele-CAS procedure to achieve considerable advantage in the preoperative examination of the patient, and to reduce the risk of intraoperative complications, all this by use of VS or diagnosis. With the use of 3D model, the surgeon's orientation in the operative field is considerably facilitated (Burtcher et al., 1998) ("patient location" as well as the "location of the tele-expert consultant"), and all procedures and manipulations are performed with higher certainty and safety (Olson & Citardi, 1999).

As it can be seen, one of their main applications of Tele-3D-C-FESS is 3D-navigation (VE) in the study of anatomy and surgery ("computed journey through the nose and paranasal sinuses"). From this point of view this approach can be compared with similar simulator systems for the training of endoscopic sinus surgery presently available on the market, but definitely we have to be aware that it is not the study of or training in anatomy or surgery, but pure implementation of live surgical procedure with computer support in real time, the



prime and foremost aim being the achievement of faster and safer procedure. So, it should be made clear that the main message of our Tele-3D-C-FESS surgery, as differentiated from the standard tele-surgeries worldwide, is the use of the 3D-model operative field, and thus of "VS", which in addition to higher safety allows for successful course of operation, especially in small, detached medical institutions where advanced endoscopic techniques are not available. This is of paramount importance for emergency surgical interventions which have to be performed in distant medical institutions where the service of "well known surgical experts" (e.g., skull base surgery) is not available.

### 3.1 Postoperative analysis

Surgical workstation includes 3D vision, dexterous precision surgical instrument manipulation, and input of force feedback sensory information. The surgeon and/or telesurgeon operates in a virtual world (Klapan et al., 2006). The use of computer technology during preoperative preparation and surgery performance allows for all relevant patient data to store during the treatment. CT images, results of other tests and examinations, computer images, 3D spatial models, and both computer and video records of the course of operation and teleoperation are stored in the computer and in CD-R devices for subsequent analysis ([www.mef.hr/MODERNRHINOLOGY](http://www.mef.hr/MODERNRHINOLOGY)). Also, these are highly useful in education on and practice of different approaches in surgery for surgery residents as well as for specialists in various surgical subspecialties.

VR has many applications in CA-surgery. Statistical studies show that physicians are more likely to make errors during their first several to few dozen surgical procedures. Surgical training may be done on cadavers, but the problem is a chronic shortage of cadavers for medical research. It would be helpful if medical training could be performed using a realistic imitation of a human body inside the computer. Such computer-based training can be used for minimally invasive surgery, and for open surgery. Training on cadavers has several drawbacks: a) if trainee cuts a nerve or a blood vessel in a cadaver nothing will happen, b) no action can be reversed on cadavers (what is cut is cut), c) dead tissue is harder, color is changed, and arteries do not pulsate. Advantages of computer simulations are that the procedures can be repeated many times with no damage to virtual body, virtual body does not have to be dead - many functions of living body can be simulated for realistic visualizations, and organs can be made transparent and modeled. The trainee may be warned of any mistakes in the surgical procedure using a multimedia-based context-sensitive help.

In this way, the real surgery and/or telesurgery procedures can be subsequently analyzed and possible shortcomings defined in order to further improve operative treatment. The use of latest computer technologies enables connection between the computer 3D spatial model of the surgical field and video recording of the course of surgery to observe all critical points during the procedure, with the ultimate goal to improve future procedures and to develop such an expert system that will enable computer assisted surgery and telesurgery with due account of all the experience acquired on previous procedures (Klapan et al., ORL H&N Surg, 2002) . Also, using the computer recorded co-ordinate shifts of 3D digitalizer during the telesurgery procedure, an animated image of the course of surgery can be created in the form of navigation, i.e. the real patient operative field fly-through, as it was done from the very beginning (from 1998) in our telesurgeries.

The real-time requirement means that the simulation must be able to follow the actions of the user that may be moving in the virtual environment (Belina et al., 2008). The computer system must also store in its memory a 3D model of the virtual environment, as we did in our first activities in 1994 (3D-CAS models; Fig. 19). In that case a real-time virtual reality (VR) system will update the 3D graphical visualization as the user moves, so that up-to-date visualization is always shown on the computer screen (Belina et al., 2009) (Fig. 20).

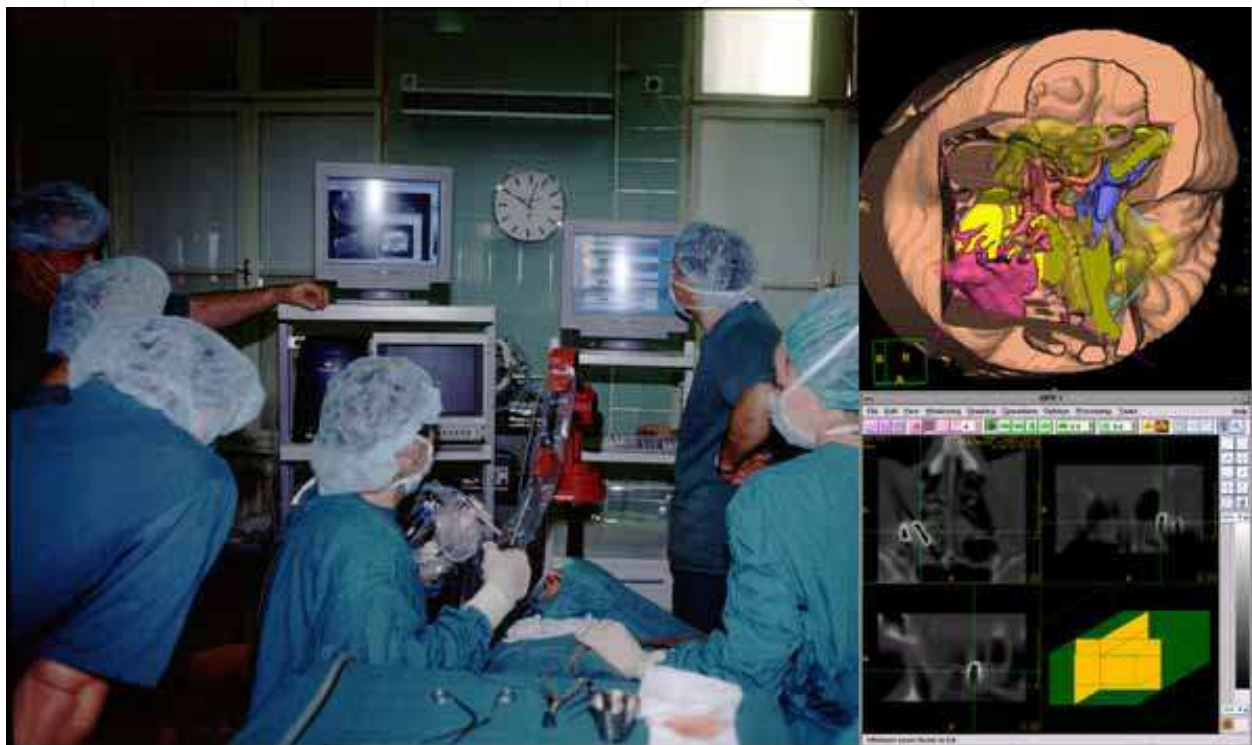


Fig. 19. Transmission of 3D-models as VE of the human head, realized during our tele-3D-CA-endoscopic sinus surgeries in 1998., when we used 3D image analysis to create the model of the desired anatomical structures (segmentation) (taken with permission from Klapan et al., Ear Nose Throat J, 2006. and Klapan Medical Group Polyclinic, Zagreb, Croatia)

Upon the completion of the CAS and/or tele-CAS-operation, the surgeon compares the preoperative and postoperative images and models of the operative field, and studies video records of the procedure itself. In otorhinolaryngology, especially in rhinology, research in the area of 2D and 3D image analysis, visualization, tissue modelling, and human-machine interfaces provides scientific expertise necessary for developing successful VR applications (Johnson, 2007). The basic requirement in rhinology, resulting from the above mentioned needs refers to the use of a computer system for visualization of anatomic 3D-structures and integral operative field to be operated on (Fig. 21). To understand the idea of 3D-CAS/VR it is necessary to recognize that the perception of surrounding world created in our brain is based on information coming from the human senses and with the help of a knowledge that is stored in our brain. The usual definition says that the impression of being present in a virtual environment, such as virtual endoscopy (VE) of the patient's head, that does not exist in reality, is called VR.

The physician has impression of presence in the virtual world and can navigate through it and manipulate virtual objects. A 3D-CAS/VR system may be designed in such a way that the physician is completely impersed in the virtual environment.

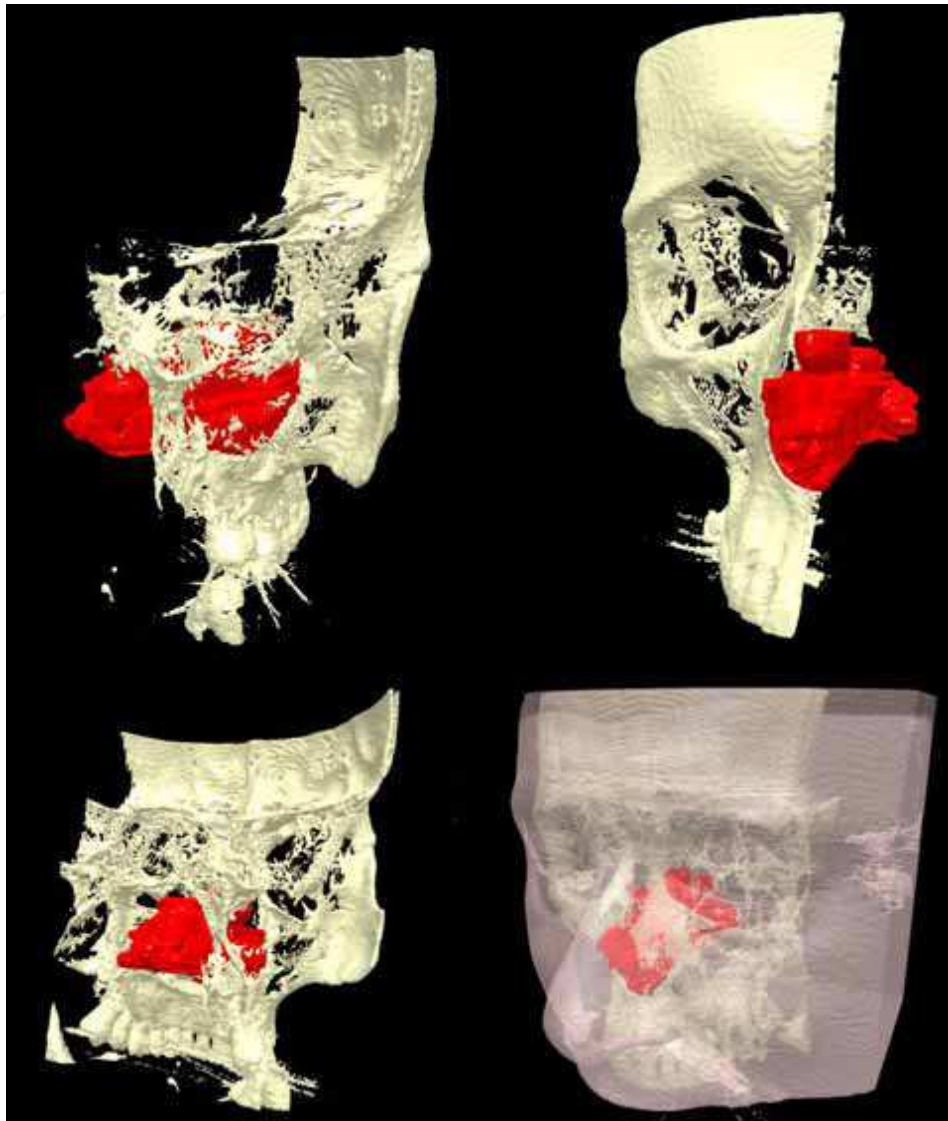


Fig. 20. 3D volume rendering technique can show the surface of the air-tissue interfaces, using a separate segmentation of air, soft tissue, bone, and pathologic tissue (taken with permission of Klapen Medical Group Polyclinic, Zagreb, Croatia)

#### 4. Conclusions

Different VR applications become a routine preoperative procedure in human medicine, as we already shown in our surgical activities in the last two decades (from June 03, 1994), providing a highly useful and informative visualization of the regions of interest, thus bringing advancement in defining the geometric information on anatomical contours of 3D-human head-models by the transfer of so-called “image pixels” to “contour pixels” (Rubino et al., 2002).

Telemedicine attempts to break the distance barrier between the provider and the patient in health-care delivery. VR is able to simulate remote environments and can therefore be applied to telemedicine. Physicians can have VR produced copy of a remote environment including the patient at their physical location. One of the simplest telemedical applications is medical teleconsultation, where physicians exchange medical information, over computer



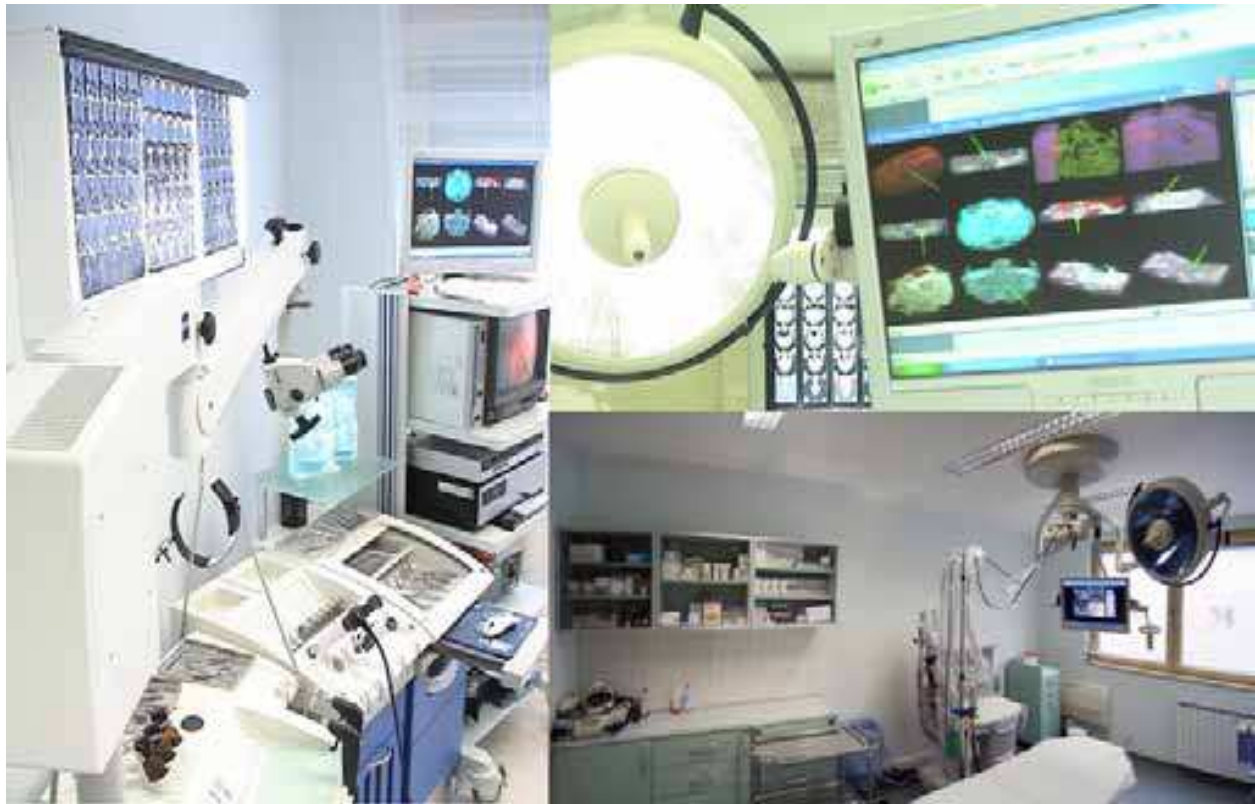

Fig. 21. Postoperative analysis, done after one our tele-3D-CA-suggeries in rhinology, where we defined the precise relationships of the borderline areas that are important for the diagnosis of pathologic conditions in the patient's head (taken with permission of Klapan Medical Group Polyclinic, Zagreb, Croatia)

networks, with other physicians in the form of image, video, audio, and text. Teleconsultations can be used in radiology, pathology, surgery, and other medical areas. One of the most interesting telemedical applications is tele-surgery. Telesurgery is a telepresence application in medicine where the surgeon and the patient are at different locations, but such systems are still in an early research phase. Patients, who are too ill or injured to be transported to a hospital, may be operated remotely. In all these cases, there is a need for a surgeon specialist who is located at some distance. Generally speaking, the purpose of a tele-presence system is to create a sense of physical presence at a remote location. Tele-presence is achieved by generating sensory stimulus so that the operator has an illusion of being present at a location distant from the location of physical presence. A tele-presence system extends operator's sensory-motor facilities and problem solving abilities to a remote environment. A tele-operation system enables operation at a distant remote site by providing the local operator with necessary sensory information to simulate operator's presence at the remote location. Tele-operation is a special case of tele-presence where in addition to illusion of presence at a remote location operator also has the ability to perform certain actions or manipulations at the remote site. In this way it is possible to perform various actions in distance locations, where it is not possible to go due to a danger, prohibitive price, or a large distance. Realization of VR systems require software (design of VE) for running VR applications in real-time. Simulations in real-time require powerful computers that can perform real-time computations required for generation of visual displays.

Different goals can be achieved by using different VR applications. These goals range from teaching, diagnosis, intervention planning, providing insight into the potentially complicated and non-standard anatomy, as well pathology of the patients, intra-operative navigation, etc.

VE or fly-through methods which combine the features of endoscopic viewing and cross-sectional volumetric imaging provided more effective and safer endoscopic procedures in diagnostics and management of our patients, especially preoperatively, as we already discussed (Fig.22). This approach can also be applied for training and familiarize the surgeon with endoscopic anatomic appearance.

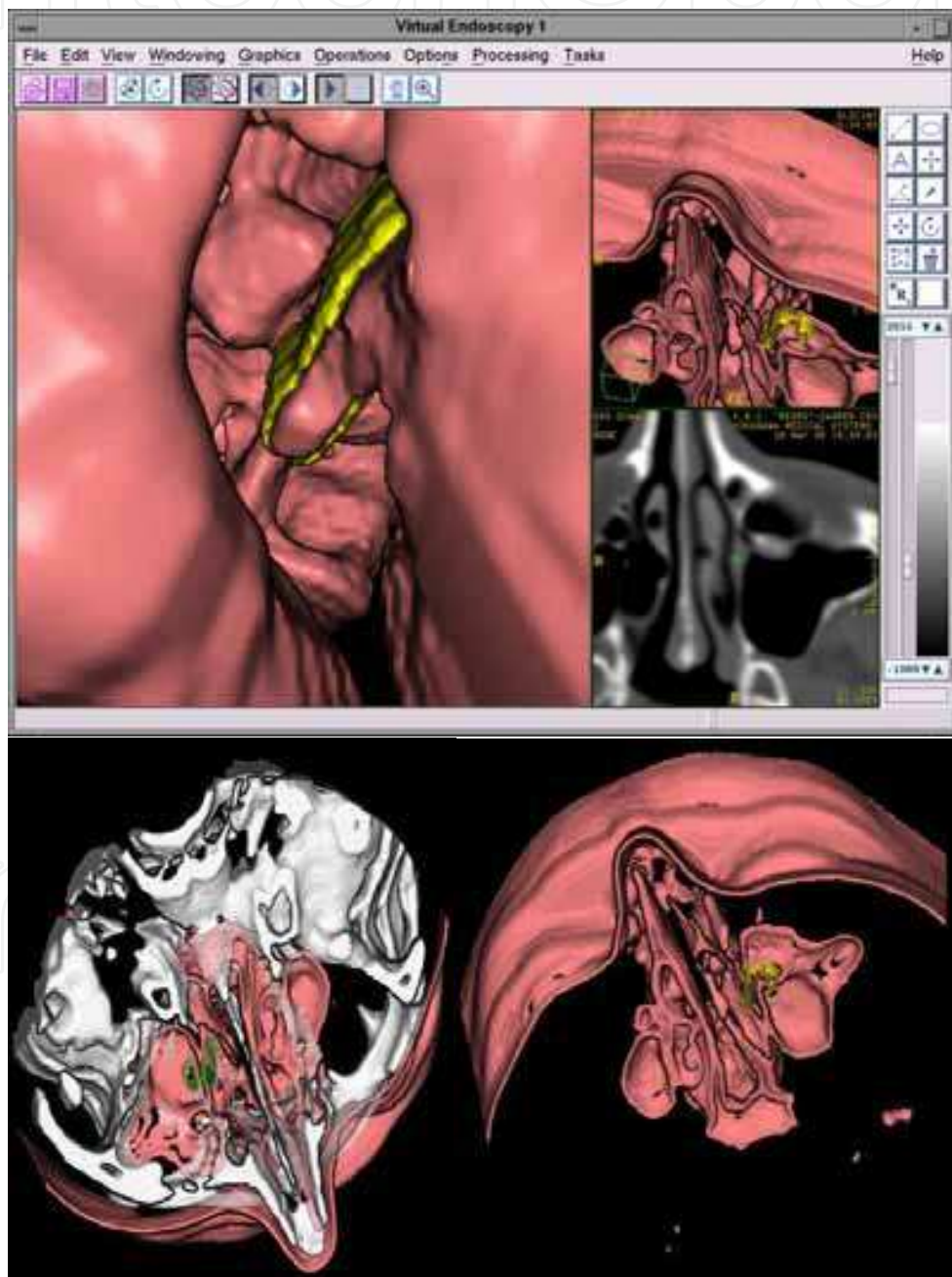


Fig. 22. Virtual endoscopy during our 3D-CA-endoscopic surgery (taken with permission of Klapan Medical Group Polyclinic, Zagreb, Croatia)

Definitely, the presentation of image data in such a way enables the operator not only to explore the inner wall surfaces but also to navigate inside the virtual organs extracted from MSCT and/or MR images of nasal cavity, paranasal sinuses and skull base, and in combination with in-space skull bone rendering, offers plastic and accurate additional 3D information for head and neck surgeon in combination with classical 2D black and white CT images (Belina et al., 2008). Interactive display of correlated 2D and 3D data in a four-window format may assist the endoscopist in performing various image guided procedures. In comparison with real endoscopy, the VE is completely non-invasive. It is possible to repeat the same procedure several times, therefore it may be a valuable tool for training, as well as the interactive control of all virtual camera parameters, including the field-of-view, and the viewing as opposed to the extend of lesions within and beyond the wall which gives the potential to stage tumors by determining the location and the extent of transmural extension (Belina et al., 2008). In the nasal or sinus cavity, VE can clearly display the anatomic structure of the paranasal sinuses (Di Rienzo et al., 2003), nasopharyngeal cavity and upper respiratory tract, revealing damage to the sinus wall caused by a bone tumor or fracture (Tao et al., 2003; Belina et al., 2009), and use the corresponding cross-sectional image or multiplanar reconstructions to evaluate structures outside the sinus cavity. A major disadvantage of VE is its inability to make an impact on operating room performance, as well as the considerable time consumption (Caversaccio et al., 2003), to evaluate the mucosal surface (Belina et al., 2008), or to provide a realistic illustration of the various pathologic findings in cases with highly obstructive sinonasal disease (Bisdas et al., 2004).

Even more, our vision of 3D-CA-navigation surgery and/or tele-3D-CA-navigation surgery allows surgeons not only to see and transfer video signals but also to transfer 3D computer models and surgical instrument movements with image/3D-model manipulations in real time during the surgery (Šimičić et al., 1998) (Fig. 23). Considering the specificities and basic features of 3D-CA-navigation surgery and tele-3D-CAS, we believe that this type of surgery would be acceptable to many surgeons all over the world for the following reasons: a) the technology is readily available in collaboration with any telecom worldwide, b) the improved safety and reduced cost will allow the inclusion of a greater number of patients from distant hospital institutions in such a telesurgical expert system, c) the “presence” of leading international surgical experts as tele-consultants in any OR in the world will thus be possible in the near future, which will additionally stimulate the development of surgery in all settings; and d) the results obtained in the tele-3D-CAS project in Croatia are encouraging and favor the further development of the method.

The possibility of data analysis and storage in the 3D form and development of 3D centers at clinical institutions, as well as the development of the surgery using a remote-controlled robots (Vilbert et al., 2003) should provide a new quality in proper training of future surgeons in 3D-CAS as well as tele-3D-CAS activities ([www.mef.hr/MODERNRHINOLOGY](http://www.mef.hr/MODERNRHINOLOGY) and [www.poliklinika-klapan.com](http://www.poliklinika-klapan.com)).

Finally, modelling of the biological material and tissue properties is an important field of research. In the future, we can expect a new generation of diagnostic imaging techniques that use simulated reality techniques for effective visualization of organ anatomy and function. Such systems will enable not only better medical diagnosis but also more appropriate intervention.



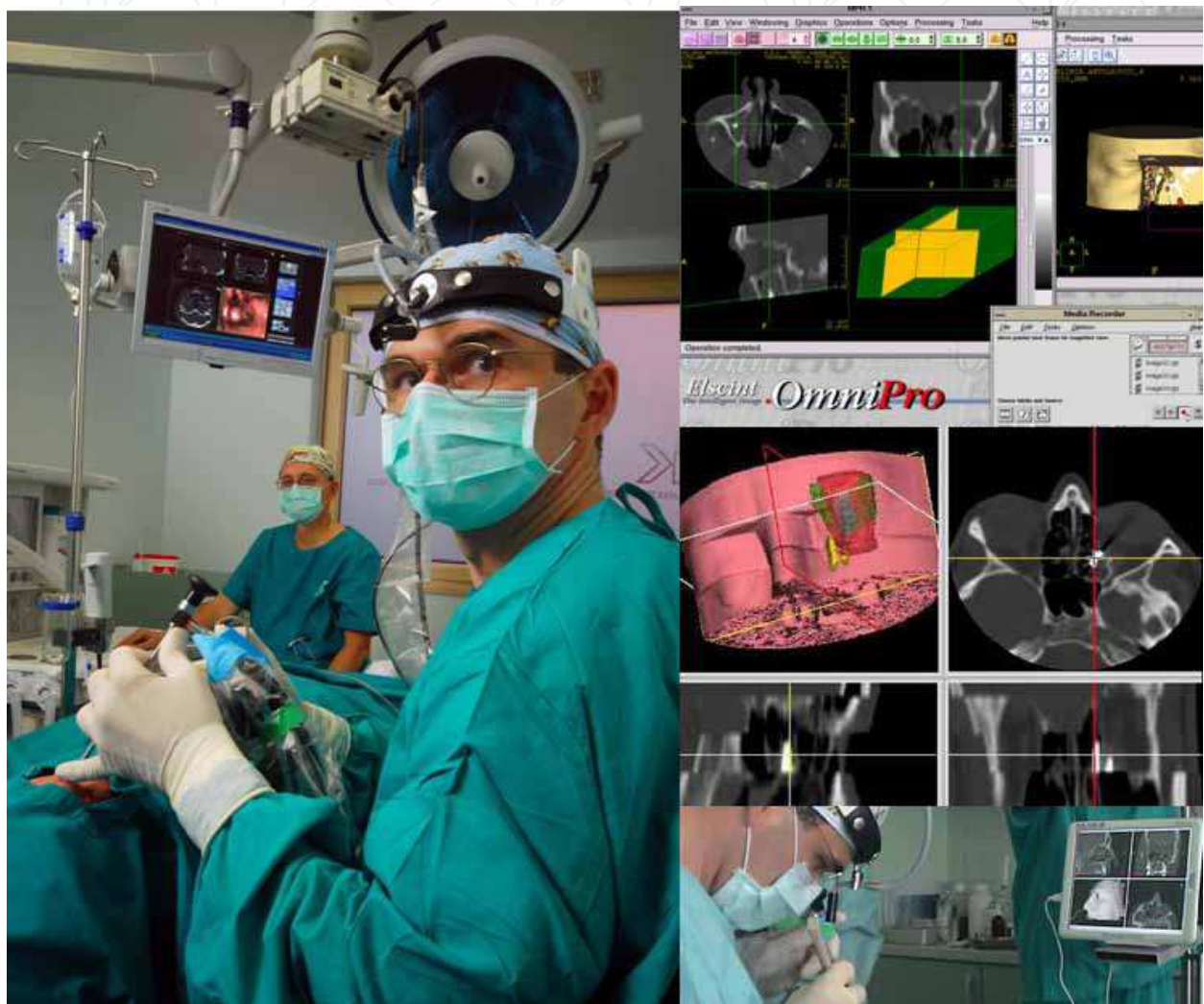

Fig. 23. Different VR applications can be applied for preoperative analysis, intraoperative surgery (as well as postoperative training and education), and completely familiarize the surgeon with endoscopic anatomy and pathology in the real operation (taken with permission from Klapan et al. Coll Anthropol 2008., and Klapan Medical Group Polyclinic, Zagreb, Croatia)

## 5. References

- Aleid, W.; Watson, J.; Sidebottom, AJ.; Hollows, P. (2009). Development of in-house rapid manufacturing of three-dimensional models in maxillofacial surgery. *British Journal of Oral and Maxillofacial Surgery*, Article in press, 2010.
- Anon, J. (1998). Computer-aided endoscopic sinus surgery. *Laryngoscope*, 108 (1998):949-961.
- Bisdas, S.; Verink, M.; Burmeister, HP.; Stieve, M. & Becker, H. (2004). Three-dimensional visualization of the nasal cavity and paranasal sinuses. Clinical results of a standardized approach using multislice helical computed tomography. *J Comput Assist Tomogr*, 28(5) (2004):661-9.
- Belina, S.; Ćuk, V.; Klapan, I.; Vranješ, Ž. & Lukinović, J. (2008). Our experience with virtual endoscopy of paranasal sinuses. *Coll Antropol*, 32(3) (2008) :887-892.
- Belina, S.; Ćuk, V. & Klapan, I. (2009). Virtual endoscopy and 3D volume rendering in the management of frontal sinus fractures. *Coll Antropol*, 33(2) (2009) :115-119.
- Burtscher, J.; Kremser, C.; Seiwald, M.; Obwegeser, A.; Wagner, M.; Aichner, F.; Twerdy, K. & Felber, S. (1998). 3D-computer assisted MRI for neurosurgical planning in parasagittal and parafalcine central region tumors. *Comput Aided Surg*, 3 (1998):27-32.
- Caversaccio, M.; Eichenberger, A. & Hausler, R. (2003). Virtual simulator as a training tool for endonasal surgery. *Am J Rhinol*, 5 (2003) :283-90.
- Di Rienzo, L.; Coen Tirelli, G.; Turchio, P.; Garaci, F. & Guazzaroni, M. (2003). Comparison of virtual and conventional endoscopy of nose and paranasal sinuses. *Ann Otol Rhinol Laryngol*, 112(2) (2003) :139-42.
- Ecke, U.; Klimek, L.; Muller, W.; Ziegler, R. & Mann, W. (1998) Virtual reality: preparation and execution of sinus surgery. *Comput Aided Surg*, 3 (1998):45-50.
- Elolf, E.; Tatagiba, M. & Samii, M. (1998). 3D-computer tomographic reconstruction: planning tool for surgery of skull base pathologies. *Comput Aided Surg*, 3 (1998):89-94.
- Galeta, T.; Kljajin, M. & Karakašić, M. Geometric Accuracy by 2-D Printing Model. *Strojniški vestnik - Journal of Mechanical Engineering*, Vol. 10, No. 54, April 2008, 725-733, 0039-2480.
- Hamadeh, A.; Lavalley, S. & Cinquin, P. (1998). Automated 3D CT and fluoroscopic image registration. *Comput Aided Surg*, 3 (1998):11-19.
- Hassfeld, S. & Muhling, J. (1998). Navigation in maxillofacial and craniofacial surgery. *Comput Aided Surg*, 3 (1998):183-187.
- Hauser, R.; Westermann, B. & Probst, R. (1997). Non.invasive 3D patient registration for image guided intranasal surgery. *Medical Robotics Comput Assisted Surg*, New York, Springer, str. 1997; 327-336.
- Holtel, MR.; Burgess, LP. & Jones, SB. (1999). Virtual reality and technologic solutions in Otolaryngology. *Otolaryngol Head Neck Surg*, 121(2) (1999):181.
- Johnson, E. (2007). Surgical simulators and simulated surgeons: reconstituting medical practice and practitioners in simulations. *Social Studies of Science*, 37: 585-608
- Keeve, E.; Girod, S.; Kikins, R. & Girod, B. 1998). Deformable modeling of facial tissue for craniofacial surgery simulation. *Comput Aided Surg*, 3 (1998):228-238.

- Kenny, T.; Yildirim, A.; Duncavage, JA.; Bracikowski, J.; Murray, JJ. & Tanner, SB. (1999). Prospective analysis of sinus symptoms and correlation with CT scan. *Otolaryngol Head Neck Surg*, 121(2) (1999):111.
- Klapan, I.; Šimičić, Lj.; Kubat, M. & Rišavi, R. (1996). Fracture of the ethmoid and medial orbital wall. Removal of the bullet per viam 3D C-FESS technique, In: *3rd EUFOS* (ed. Ribari O, Hirschberg A), Monduzzi Editore, Bologna, 2 (1996):83-87.
- Klapan, I.; Šimičić, Lj. & Kubat, M. (1997).. Our three-dimensional Computer Assisted Functional Endoscopic Sinus Surgery (3D C-FESS). In: *McCafferty G, Coman WB, eds. XVI World Congress of Otorhinolaryngology, Head and Neck Surgery, Sydney, Australia*. Bologna: Monduzzi Editore, (1997):1543-1547.
- Klapan, I.; Šimičić, Lj. & Rišavi, R. (1999). Tele-3D-Computer Assisted Functional Endoscopic Sinus Surgery (Tele-3D-C-FESS). In: *Proceedings of the 13th CARS'99*, Lemke HU, Vannier MW, Inamura K, Farman AG (Eds.), Elsevier, Amsterdam, New York, Oxford, Shannon, Singapore, Tokyo, (1999):784-789.
- Klapan, I.; Šimičić, Lj.; Rišavi, R.; Bešenski, N.; Bumber, Ž.; Stiglmaier, N. & Janjanin, S. (2001). Dynamic 3D computer-assisted reconstruction of metallic retrobulbar foreign body for diagnostic and surgical purposes. Case report: orbital injury with ethmoid bone involvement. *Orbit*, 20 (2001):35-49.
- (a) Klapan, I.; Šimičić, Lj.; Bešenski, N.; Bumber, Ž.; Janjanin, S.; Rišavi, R. & Mladina, R. (2002). Application of 3D-computer assisted techniques to sinonasal pathology. Case report: war wounds of paranasal sinuses with metallic foreign bodies. *Am J Otolaryngol*, 23 (2002):27-34.
- (b) Klapan, I.; Šimičić, Lj.; Rišavi, R.; Bešenski, N.; Pasarić, K.; Gortan, D.; Janjanin, S.; Pavić, D. & Vranješ, Ž. (2002). Tele-3D-computer assisted functional endoscopic sinus surgery: new dimension in the surgery of the nose and paranasal sinuses. *Otolaryngology Head Neck Surg*, 127 (2002):549-557.
- (c) Klapan, I.; Šimičić, Lj.; Rišavi, R.; Pasarić, K.; Sruk, V.; Schwarz, D. & Barišić, J. (2002). Real time transfer of live video images in parallel with three-dimensional modeling of the surgical field in computer-assisted telesurgery. *J Telemed Telecare*, 8 (2002):125-130.
- Klapan, I.; Vranješ, Ž.; Rišavi, R.; Šimičić, Lj.; Prgomet, D. & Glušac, B. (2006). Computer assisted surgery and computer-assisted telesurgery in otorhinolaryngology. *Ear Nose Throat J*, 85(5) (2006):318-321.
- Klapan, I.; Vranješ, Ž.; Prgomet, D. & Lukinović, J. (2008). Application of advanced virtual reality and 3D computer assisted technologies in tele-3D-computer assisted surgery in rhinology. *Coll Antropol*, 32(1) (2008):217-219.
- Klimek, L.; Mosges, M.; Schlondorff, G. & Mann, W. (1998). Development of computer-aided surgery for otorhinolaryngology. *Comput Aided Surg*, 3 (1998):194-201.
- Knezović, J.; Kovač, M.; Klapan, I.; Mlinarić, H.; Vranješ, Ž.; Lukinović, J. & Rakić M. (2007). Application of novel lossless compression of medical images using prediction and contextual error modeling. *Coll Antropol*, 31 (4) (2007):315-319.
- Mann, W. & Klimek, L. (1998). Indications for computer-assisted surgery in otorhinolaryngology. *Comput Aided Surg*, 3 (1998):202-204.




- Mladina, R.; Hat, J.; Klapan, I. & Heinzel, B. (1995). An endoscopic approach to metallic foreign bodies of the nose and paranasal sinuses. *Am J Otolaryngol*, 16(4) (1995):276-279.
- Olson, G. & Citardi, M. (1999). Image-guided functional endoscopic sinus surgery. *Otolaryngol Head Neck Surg*, 121 (1999):187.
- Petzold, R.; Zeilhofer, H.-F. & Kalender, W. A. Rapid prototyping technology in medicine - basics and applications. *Computerized Medical Imaging and Graphics*, 23 (1999) 277-284.
- Raos, P. & Galeta, T. (2004). Rapid Prototyping. In : *Proceedings of 2nd Croatian Congress on Telemedicine with International Participation (TeleMED)*, pp. 74-75, Fakultet elektrotehnike i računarstva, May 2004, Zagreb, Croatia
- Rišavi, R.; Klapan, I.; Handžić-Čuk, J. & Barčan, T. (1998). Our experience with FESS in children. *Int J Pediatric Otolaryngol*, 43 (1998):271-275.
- Robb, RA. (2000). Virtual endoscopy: Development and evaluation using the Visible Human Datasets. *Computerized Medical Imaging and Graphics*, 24 (2000):133-151.
- Rubino, F.; Soler, L.; Marescaux, J. & Maisonneuve, H. (2002). Advances in virtual reality are wide ranging. *BMJ* 324 (2002): 612-612
- Satava, RM. (1996). Telesurgery - acceptability of compressed video for remote surgical proctoring - invited commentary. *Arch Surg*, 131 (1996): 401.
- Schlag, PM.; Engelmurke, F. & Zurheyde, MM. (1998). *Teleconference and telesurgery*. *Chirurg*, 69 (1998):1134-1140.
- Sezeur, A. (1998). Surgical applications of telemedicine. *Ann Chir*, 52 (1998):403-411.
- Stewart, MG.; Donovan, D.; Parke, RB. & Bautista, M. (1999). Does the sinus CT scan severity predict outcome in chronic sinusitis? *Otolaryngol Head Neck Surg*, 121(2) (1999):110.
- Šimičić, Lj.; Klapan, I.; Simović, S.; Brzović, Z.; Vukoja, M.; Rišavi, R. & Gortan, D. (1998). Computer assisted functional endoscopic sinus surgery. Video texture mapping of 3D models. *Proceedings of ERS&ISIAN Meeting*, pp. 281-285., Vienna, Austria, 1998 (ed. H. Stammberger, G. Wolf), Monduzzi Editore, Bologna.
- Tao, X.; Zhu, F.; Chen, W. & Zhu, S. (2003). The application of virtual endoscopy with computed tomography in maxillofacial surgery. *Chin Med J*, 116(5) (2003):679-81
- Thrall, JH. (1999). Cross-sectional era yields to 3D and 4D imaging. *Diagn Imaging Eur*, 15(4) (1999):30-31.
- Urban, V.; Wapler, M.; Neugenbauer, J.; Hiller, A.; Stallkamp, J. & Weisener, T. (1998). Robot-assisted surgery system with kinesthetic feedback. *Comp Aided Surg*, 3 (1998):205-209.
- Vannier, MW. & Marsh, JL. (1996). 3D imaging, surgical planning and image guided therapy. *Radiol Clin North Am*, 34 (1996):545-563.
- Vibert, E.; Denet, C. & Gayet, B. (2003). Major digestive surgery using a remote-controlled robot: the next revolution. *Arch Surg*, 138 (2003): 1002-1006.
- Vinas, FC.; Zamorano, L.; Buciu, R. & Shamsa, F. (1997). Application accuracy study of a semipermanent fiducial system for frameless stereotaxis. *Comput Aided Surg*, 2 (1997):257-263.

- Wickham, J.E.A. (1994). Minimally invasive surgery: future developments. *BMJ* 308(1994):193-6.
- Winder, J. & Bibb, R. (2005). Medical Rapid Prototyping Technologies: State of the Art and Current Limitations for Application in Oral and Maxillofacial Surgery. *Journal of Oral and Maxillofacial Surgery*, 63 (2005):1006-1015, 02782391

IntechOpen

IntechOpen



## **Virtual Reality**

Edited by Prof. Jae-Jin Kim

ISBN 978-953-307-518-1

Hard cover, 684 pages

**Publisher** InTech

**Published online** 08, December, 2010

**Published in print edition** December, 2010

Technological advancement in graphics and other human motion tracking hardware has promoted pushing "virtual reality" closer to "reality" and thus usage of virtual reality has been extended to various fields. The most typical fields for the application of virtual reality are medicine and engineering. The reviews in this book describe the latest virtual reality-related knowledge in these two fields such as: advanced human-computer interaction and virtual reality technologies, evaluation tools for cognition and behavior, medical and surgical treatment, neuroscience and neuro-rehabilitation, assistant tools for overcoming mental illnesses, educational and industrial uses. In addition, the considerations for virtual worlds in human society are discussed. This book will serve as a state-of-the-art resource for researchers who are interested in developing a beneficial technology for human society.

### **How to reference**

In order to correctly reference this scholarly work, feel free to copy and paste the following:

Ivica Klapan, Pero Raos, Tomislav Galeta, Ljubimko Šimičić, Juraj Lukinović, Željko Vranješ, Josip Maleš, Stanko Belina and Višeslav Ćuk (2010). Application of Advanced Virtual Reality and 3D Computer Assisted Technologies in Computer Assisted Surgery and Tele-3D-Computer Assisted Surgery in Rhinology, Virtual Reality, Prof. Jae-Jin Kim (Ed.), ISBN: 978-953-307-518-1, InTech, Available from:  
<http://www.intechopen.com/books/virtual-reality/application-of-advanced-virtual-reality-and-3d-computer-assisted-technologies-in-computer-assisted-s>

**INTECH**  
open science | open minds

### **InTech Europe**

University Campus STeP Ri  
Slavka Krautzeka 83/A  
51000 Rijeka, Croatia  
Phone: +385 (51) 770 447  
Fax: +385 (51) 686 166  
[www.intechopen.com](http://www.intechopen.com)

### **InTech China**

Unit 405, Office Block, Hotel Equatorial Shanghai  
No.65, Yan An Road (West), Shanghai, 200040, China  
中国上海市延安西路65号上海国际贵都大饭店办公楼405单元  
Phone: +86-21-62489820  
Fax: +86-21-62489821

© 2011 The Author(s). Licensee IntechOpen. This chapter is distributed under the terms of the [Creative Commons Attribution-NonCommercial-ShareAlike-3.0 License](https://creativecommons.org/licenses/by-nc-sa/3.0/), which permits use, distribution and reproduction for non-commercial purposes, provided the original is properly cited and derivative works building on this content are distributed under the same license.

IntechOpen

IntechOpen